

1

ANATOMY AND PHYSIOLOGY OF THE HORSE

For massage therapy to be effective, its practitioner must have a good knowledge of a horse's makeup. In this chapter, we will examine the systems of the horse and the way in which these systems work together to promote the horse's health. To begin, we have:

- ❖ The nervous system (brain, spinal cord, sensory and motor nerves), which controls all the other systems.
- ❖ The respiratory system (trachea and lungs), which transmits oxygen to the bloodstream and removes carbon dioxide.
- ❖ The cardiovascular system (heart, blood, arteries, and veins), which conveys nutrients, oxygen and other essential components throughout the body.
- ❖ The lymphatic system (lymph channels and lymph glands), which provides a cleansing, filtering, and defense mechanism to deal with anything that could have a toxic effect on the body (lactic acid, bacteria, and viruses).
- ❖ The endocrine system, which is composed of glands that permit a range of functions in the body systems.
- ❖ The digestive system (mouth, stomach, intestines, and bowel), which extracts nutrients from food and eliminates waste.
- ❖ The urinary system (bladder and kidneys), which removes excess water and unwanted substances by filtering the blood through the kidneys.
- ❖ The reproductive system, which ensures the continuance of the species.
- ❖ The skeletal system, which is the bony frame that supports the body. Within the skeletal system there are joints which permit part of the bony frame to articulate (move).
- ❖ The muscular system, which provides the power and means to move the bony frame.

These systems are described briefly so that you can understand how each functions and relates to the other systems. More detailed information is beyond the scope of this book.

THE NERVOUS SYSTEM

The nervous system integrates and controls every body function; it processes all information and governs all commands to the body. In the nervous system we find:

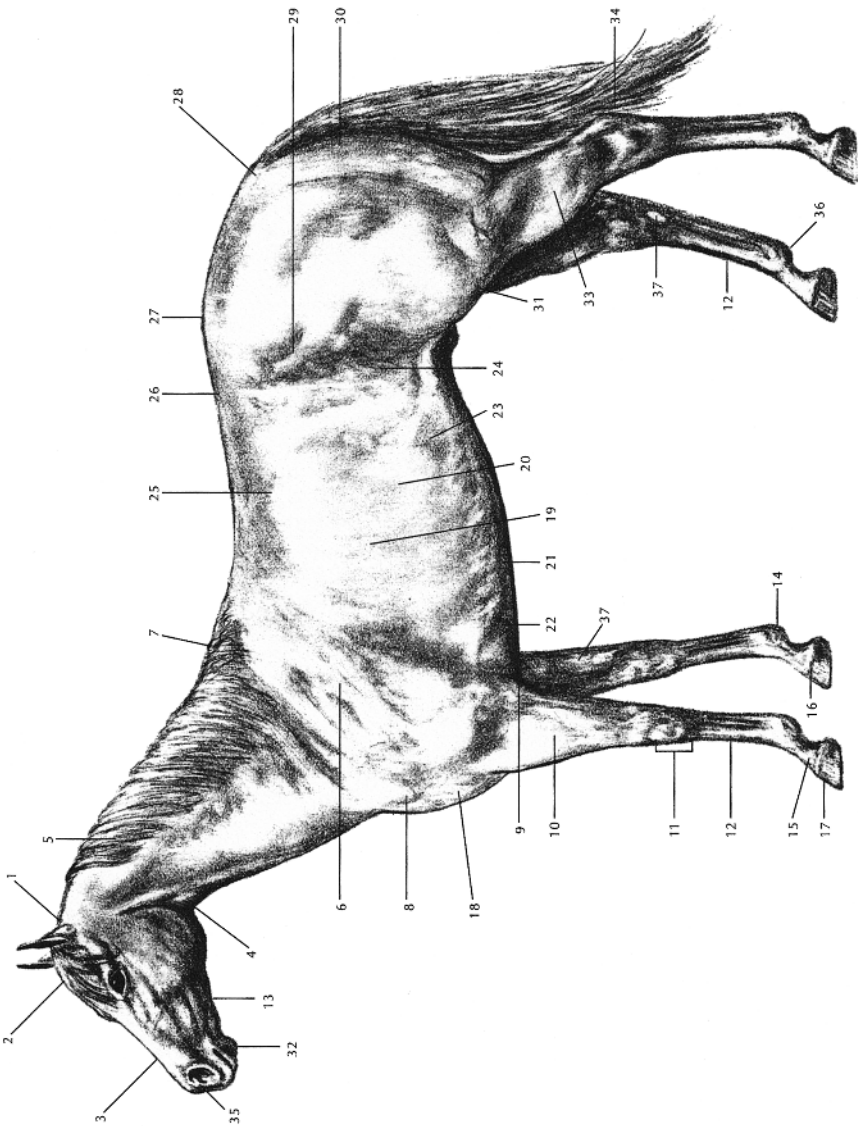
- ❖ The central nervous system (CNS) consists of the brain and spinal cord, which perform very specific functions. The CNS is often compared to a complex computer.
- ❖ The peripheral nervous system (PNS) consists of numerous pairs of nerves that exit the spinal column at the vertebral level (spinal bones). There are sensory nerves (or afferent nerves) which carry information from the body to the CNS, and there are motor nerves (or efferent nerves) which carry information from the CNS to the body parts.
- ❖ The specialized sensory organs.

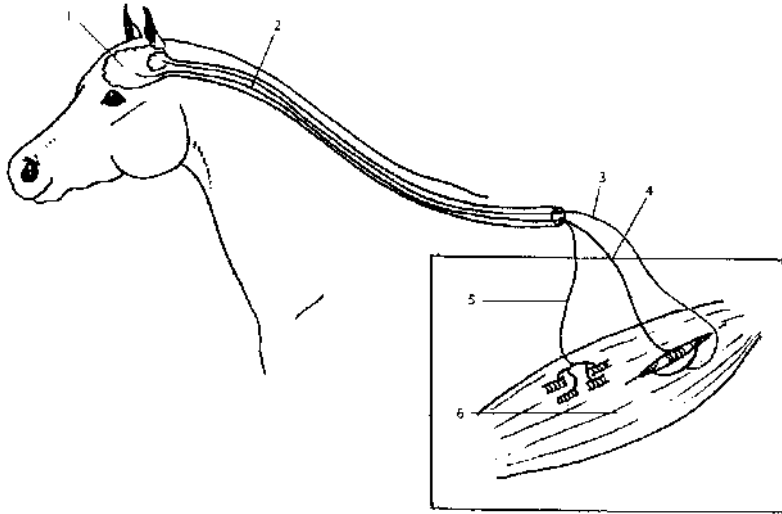
Complex in their makeup, nerve tissues are composed of many filaments that are very susceptible to pressure. In a case of severe trauma, when significant or strong pressure is applied to a nerve, nerve impulses can stop traveling along it. As a consequence, two things can happen: a loss of sensation or feedback from the nerve area to the CNS; and degeneration with eventual shrinking of the tissue in the immediate area of the affected nerve, as a result of lost motor nerve impulses from the CNS to the body part.

A *sweeney* is a typical example of a loss of motor nerve conduction. It is caused by a direct trauma to the point of the horse's shoulder. In this case, the suprascapular nerve that activates the muscles of the scapula is damaged.

The functioning of the nervous system is ensured by the autonomic nervous system (ANS), which maintains a stable internal environment. The ANS governs the vital organs and their complex functions that are normally carried out involuntarily, such as breathing, circulation, digestion, elimination, and the immune response. This system has two major divisions: the sympathetic and the parasympathetic. Both originate in the brain.

The *sympathetic division* causes the body to respond to danger, adversity, stress, anger, and pleasure by increasing the heart rate, blood pressure, air exchange volume, and blood flowing to muscles—all of which are needed for the horse to spring into action. The sympathetic division is responsible for the horse's "fight or flight" reaction. General stimulation of the sympathetic division results in





1.2 Nervous System

- | | |
|-------------------------------------|------------------------------------|
| (1) brain | (4) afferent nerve, muscle spindle |
| (2) spinal cord | sensory nerve |
| (3) afferent nerve, Golgi apparatus | (5) efferent motor nerve |
| sensory nerve | (6) muscle |

mobilization of resources to prepare the body to act or to deal with emergencies. (The warm-up routine in chapter 6 is designed to stimulate the nervous system.) The *parasympathetic division* monitors body functions during times of rest, sleep, digestion, and elimination, when the body is not ready to go into action. General stimulation of the parasympathetic division promotes relaxation and vegetative functions of the body such as breathing, circulation, digestion, immune response, and reproduction. (The relaxation routine in chapter 6 is designed to relax the nervous system.)

THE RESPIRATORY SYSTEM

The respiratory system includes the nose, mouth, pharynx, windpipe (or trachea), bronchial tubes, and lungs.

- ❖ The larynx is the organ of the voice.
- ❖ The lungs are somewhat elastic (expandable) and filled with numerous sacs (pulmonary alveoli) like a sponge. In the lungs, the blood takes on oxygen and gives off carbon dioxide (or waste).
- ❖ The diaphragm is a large, flat, muscular organ that separates the thoracic and abdominal cavities. Its action aids inhalation, expiration, and defecation.

Proper breathing is essential for good body metabolism. An exchange of oxygen and carbon dioxide is necessary for the body to remain vital and healthy. The horse's respiratory system also plays an important role in regulating his body heat and in maintaining the acid-base pH balance.

Oxygen is integral to the anabolic and catabolic processes that occur naturally in all structures. The oxygen/carbon dioxide exchange rate depends on how clean the lung tissues are, the depth of respiration, the animal's temperature (which causes expansion or dilation of blood vessels in tissues), and the rate of respiration. The rate of breathing for a horse at rest is around 12 to 16 breaths per minute; during heavy exercise, the rate is between 120 and 180. A cool-down period after strenuous exercise is essential to allow more time for the lungs to exchange gases, release toxins, and take in fresh oxygen.

Depth of respiration is very important. A girth that is too tight restricts the expansion of the rib cage. An improperly fitted saddle and a rider's tense legs also restrict the expansion of the rib cage, consequently limiting lung capacity.

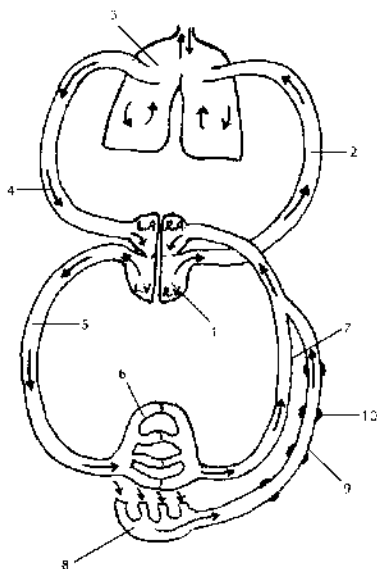
Muscular problems such as *chronic stress points* (small spasms) and *trigger points* (areas of lactic acid build-up) will restrict the muscle action required to expand and contract the rib cage. (The recuperation massage routine in chapter 6 is designed to assist this problem.) Massage will help release any undue tension and relieve stress and trigger points around the rib cage, thus allowing for deeper breathing. (The stress point check-up massage routine in chapter 10 is designed to help you recognize potential stress point locations in and around the rib cage area.)

Massage indirectly assists in the oxygenation of tissues by increasing circulation throughout the body. Massage also relaxes the nervous system, thus allowing for deeper and steadier breathing, and better oxygen/CO₂ gas exchange.

THE CIRCULATORY SYSTEM

The circulatory system consists of the cardiovascular system and the lymphatic system. Circulation has a number of functions:

- ❖ Distributing oxygen and nutrients to every cell of a horse's body.
- ❖ Carrying antibodies to fight infections that invade the body.
- ❖ Removing metabolic waste and carbon dioxide.
- ❖ Distributing heat throughout the body, thereby regulating the horse's temperature.



1.3 Circulatory System

- (1) heart
- (2) pulmonary artery
- (3) lungs
- (4) pulmonary vein
- (5) artery
- (6) blood capillaries
- (7) vein
- (8) lymph capillaries
- (9) lymphatic vessel
- (10) lymph node

THE CARDIOVASCULAR SYSTEM

The bulk of circulatory work is done by the cardiovascular system, which is made up of the heart, arteries, veins, capillaries, and the blood that flows through them. This is a closed-circuit system.

Arterial blood carries oxygen, nutrients, immune defense agents, glandular secretions, and blood-clotting agents throughout the body. Arterial blood circulation is generated by the pumping action of the heart and the contraction of the arterial wall muscles.

The normal heart rate at rest is 28 to 40 beats per minute, and up to between 210 and 280 beats per minute during exercise. The heart forces blood into the arteries, to the *arterioles* (smaller arteries) and then to the *capillaries* (minute blood vessels in the tissues), where the oxygen/carbon dioxide and nutrients/waste exchanges occur.

The blood returns via the *venules* (small veins) to the veins, to the heart, to the lungs, then back again to the heart for another cycle into the arteries. The venous blood transports metabolic waste and carbon dioxide from the cells of the tissues to the heart and lungs (where the oxygen/carbon dioxide exchange takes place). The venous return of blood is assisted by the movement of the large locomotor muscle groups of the body. Veins are equipped with little cuplike valves to prevent the backward flow of blood. Each muscle contraction squeezes the venous blood in one direction, toward the heart.

Normal functioning of all body tissue depends on the proper circulation of blood. However, after an injury it is even more

important that an adequate supply of blood—bearing nutrients, oxygen, and healing material—reaches the site of injury. The blood will also remove waste, debris, or any toxins formed as a result of the injury.

The circulatory system controls the horse's body temperature. When the body is cold, the capillaries in those parts of the body farthest away from the heart constrict. Blood circulation is therefore reduced in the extremities, keeping most of the blood at the body's core in order to warm vital organs (brain, heart, and lungs.) Conversely, if the body is hot, the capillaries dilate, allowing more blood through the capillaries that are near the surface of the skin. Therefore, heat from the core of the body is released through the skin.

The pressure of massage movements has an effect on the circulation of blood throughout the body. Chapter 6 contains massage routines that can be used to deal with problems related to, or caused by, poor circulation.

THE LYMPHATIC SYSTEM

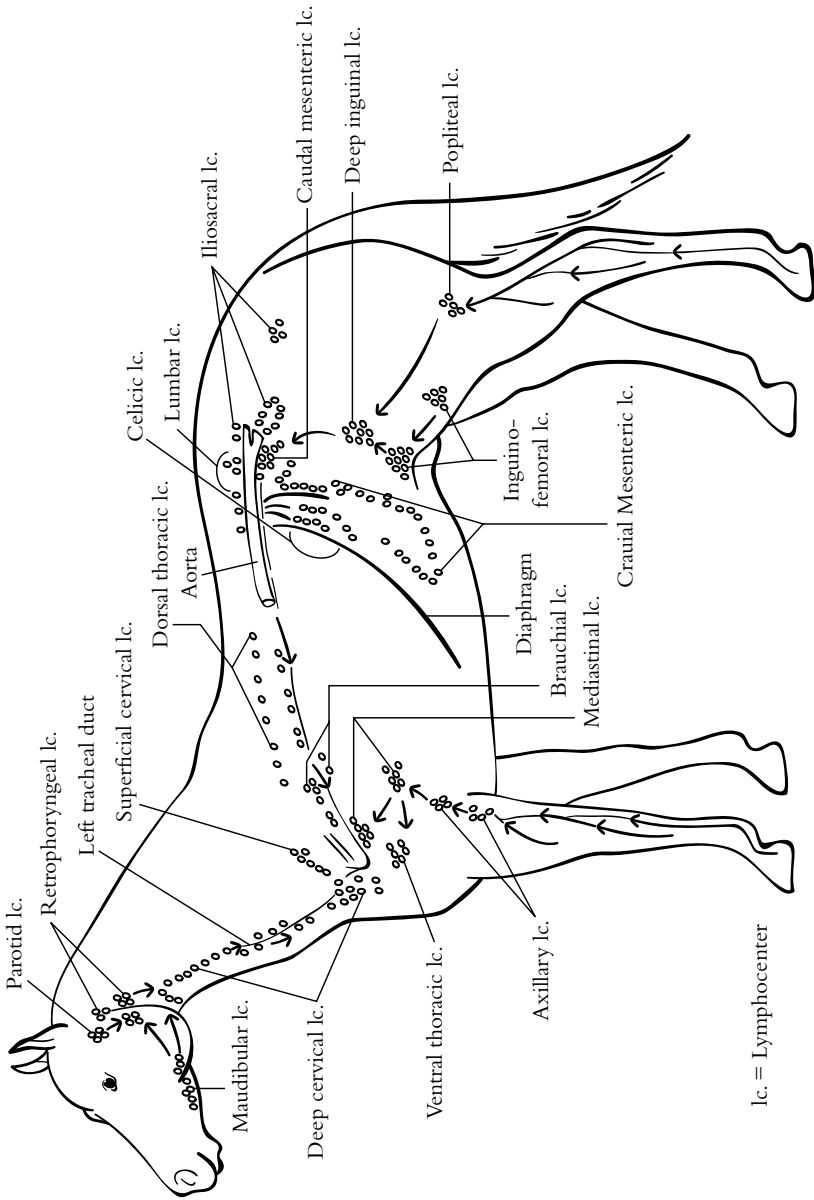
The lymphatic system plays an important role in the body's defense mechanism in that it contains *lymphocytes* (white blood cells that aid in fighting viral and bacterial infections). It is the body's first line of defense. When the body is injured, an increase of lymphatic fluid occurs at the site of trauma and produces swelling.

The lymphatic system consists of a network of small vessels containing lymphatic fluid and structures called *lymph nodes* (which are like miniature cleansing factories). There are twice as many lymph vessels as there are blood vessels. This system also filters and removes debris and waste material.

The lymphatic system sends fluid in only one direction—from the periphery of the body toward the heart. The circulation of the lymphatic fluid is slow, almost sluggish. Like veins, lymph vessels are equipped with cup-shaped valves to prevent backflow of the fluid. Muscle activity, breathing movements, and peristaltic activity of the bowels all contribute to the flow of lymphatic fluid.

Lack of exercise can contribute to *lymphatic congestion*, which results in swelling in the limbs. Overloading the lymphatic system as a result of too much exercise can cause a buildup of toxins, which leads to an inflammation of the lymph vessels and lymph nodes.

Following an injury, reduced muscular activity contributes to the slowing of lymphatic circulation. Massage with light drainage (effleurage movements) will assist lymphatic circulation. (Chapter 6 offers a recuperation routine that can help speed up recovery. Basically, the purpose of the recuperation routine is to prevent lactic



1.4 The Lymphatic System: *Lymphocenters made of lymphnodes.*

acid buildup after heavy training, racing, or competition. This routine will help prevent muscle stiffness, cramps, or tying up.) Massage does not directly affect the following four systems, but it does assist with the circulation of fluids (blood and lymph), allowing more nutrients and oxygen to reach the associated tissues. Massage also relaxes the central nervous system, contributing to an improved overall functioning of these four systems.

THE ENDOCRINE SYSTEM

Made up of glands and associated organs, the endocrine system produces and releases hormones directly into the bloodstream. These hormones regulate growth, development, and a variety of other functions, including reproduction and metabolism.

THE DIGESTIVE SYSTEM

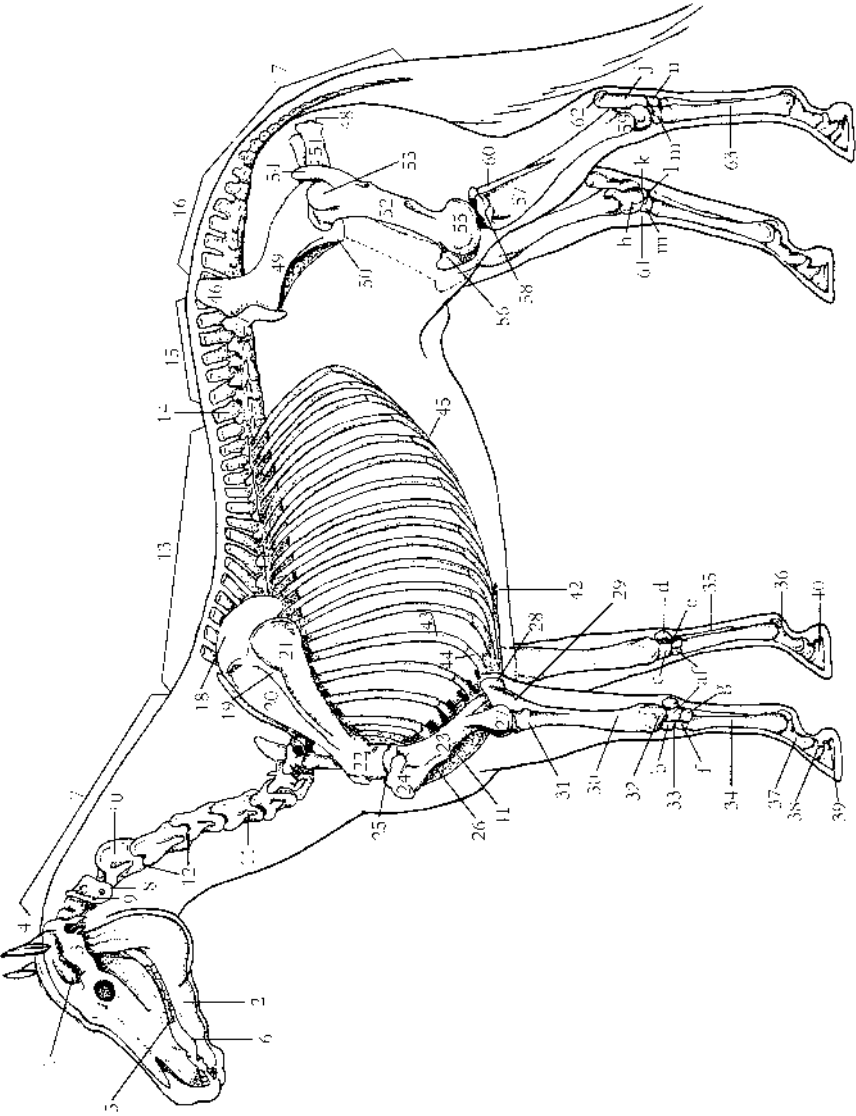
The digestive system alters the chemical and physical composition of food so it can be absorbed and utilized by the horse's body. The gastrointestinal tract is a musculo-membranous tube that extends from the mouth to the anus (approximately 100 feet long). The digestive organs of the horse are the mouth, pharynx, esophagus, stomach, small intestine, cecum, large intestine, and anus. A healthy digestive tract is vital for the efficient assimilation of food. A balanced diet is very important for good performance and general well-being.

THE URINARY SYSTEM

The urinary system maintains the balance of fluids in the body and eliminates waste products from the body. The urinary system consists of a pair of kidneys, the ureters, the bladder, and the urethra. The kidneys provide a blood-filtering system to remove many waste products, and to control water balance, pH, and the level of many electrolytes. The kidney filtrate is urine, which is conveyed to the bladder by the 2 ureters. From there it is evacuated via the urethra. Proper urinary functioning avoids kidney failure and all its consequences: swelling, toxicity, and weight loss.

THE REPRODUCTIVE SYSTEM

The reproductive system ensures the continuation of the species. The male reproductive system consists of the testicles, the accessory glands and ducts, and the external genital organ. The female reproductive system consists of the ovaries, oviducts, uterus,



1.5 Skeleton of the Horse

- | | | |
|--|--|--|
| (1) cranium | (26) deltoid tuberosity of humerus | (45) costal arch |
| (2) mandible | (27) lateral condyle of humerus | (46) tuber sacral (point of croup) |
| (3) zygomatic arch | (28) olecranon process of the ulna (point of elbow) | (47) tuber coxae (point of hip or haunch) |
| (4) poll | (29) ulna | (48) tuber ischii (point of buttock or seat bone) |
| (5) teeth | (30) radius | (49) ilium |
| (6) bar | (31) head of radius | (50) pubis |
| (7) cervical vertebrae [7] | (32) lateral styloid process of radius | (51) ischium |
| (8) atlas, first cervical vertebra | (33) carpus [a] ulnar carpal bone (pyramidal or cuneiform), [b] intermediate carpal bone (lunate or semilunar), [c] radial carpal bone (scaphoid), [d] accessory carpal bone (pisiform), [e] second carpal bone (trapezoid), [f] third carpal bone (unciform), [g] fourth carpal bone (trapezium), [h] fifth carpal bone (trapezoid) | (52) femur |
| (9) wings of atlas | | (53) head of femur |
| (10) axis (second cervical vertebra) | | (54) greater trochanter of femur (cranial and caudal part) |
| (11) expanded transverse process of fifth cervical vertebra | | (55) lateral condyle of femur |
| (12) intervertebral foramina, for passage of spinal nerves and blood vessels | | (56) patella |
| (13) thoracic vertebrae [18] | | (57) tibia |
| (14) last thoracic vertebra | | (58) lateral condyle of tibia |
| (15) lumbar vertebrae [6] | | (59) lateral malleolus of tibia |
| (16) sacrum [5 fused vertebrae] | | (60) fibula |
| (17) coccygeal vertebrae [usually 18] | | (61) tarsus (hock), [h] talus (astragalus or tibial bone), [i] calcaneus (os calcis or fibular tarsal bone), [k] central tarsal bone (scaphoid), [l] fused first and second tarsal bones (small cuneiform), [m] third tarsal bone (great cuneiform), [n] fourth tarsal bone (cuboid) |
| (18) scapula | | |
| (19) scapular spine (bone ridge) | | |
| (20) supraspinous fossa of scapula | | |
| (21) infraspinous fossa of scapula | | |
| (22) neck of scapula | | |
| (23) humerus | | |
| (24) head of humerus | | |
| (25) point of shoulder | | |
| | | (62) tuber calcanei (point of hock or tuber calcis) |
| | | (63) cannon (large metatarsal) |

vagina, and external genitalia. Proper fluid circulation and relaxation of the nervous system will ensure peak performance for reproduction purposes.

THE SKELETAL SYSTEM

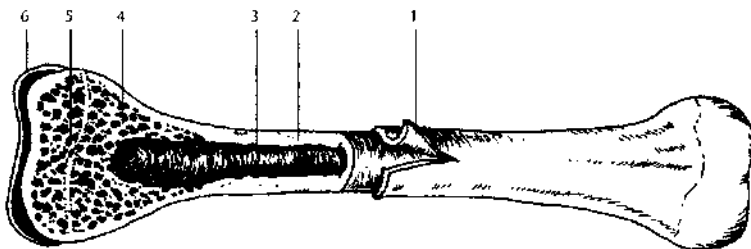
The skeletal system serves as a framework for the horse's body, giving the muscles something to work against, and defining the animal's overall size and shape. The skeleton also protects the horse's vital internal tissues and organs. For example, the skull protects the brain; the rib cage protects the lungs and heart; the vertebral column protects the spinal cord. The skeleton is made up of over 200 bones.

BONES

Bones vary in size and shape according to their function. With the exception of the enamel-covered teeth, bones are the body's hardest substances and can withstand great compression, torque, and tension. A tough membrane called the *periosteum* covers and protects the bones and provides for the attachment of the joint capsules, ligaments, and tendons. Injury to the periosteum may result in undesirable bone growths such as splints, spavin, and ringbone. Bones are held together by *ligaments*; muscles are attached to the bones by *tendons*.

The articulating surface of the bone is covered with a thick, smooth cartilage that diminishes concussion and friction.

Long bones are found in the limbs; short bones in the joints; flat bones in the rib cage, skull, and shoulder; and irregularly shaped bones in the spinal column and limbs.



1.6 A Bone

- | | |
|-----------------------------|---|
| (1) <i>periosteum</i> | (4) <i>spongy bone with marrow cavities</i> |
| (2) <i>compact bone</i> | (5) <i>epiphyseal plate</i> |
| (3) <i>medullary cavity</i> | (6) <i>articulate hyaline cartilage</i> |

The *long bones* of the limbs (humerus, radius, femur, tibia, cannon bones) function mainly as levers and aid in the support of weight.

Short bones, found in complex joints such as the knee (carpus), hock (tarsus), and ankle (fetlock), absorb concussion.

Flat bones protect and enclose the cavities containing vital organs: skull (brain) and ribs (heart and lungs). Flat bones also provide large areas for the attachment of muscles.

Components of the skeleton of the horse are as follows:

- ❖ The skull consists of 34 irregularly shaped bones.
- ❖ The spine consists of 7 cervical vertebrae, 17 to 19 thoracic vertebrae (usually 18), 5 to 6 lumbar vertebrae (sometimes fused together), and 5 fused sacral vertebrae (the sacrum). The tail consists of 18 coccygeal vertebrae, although this number can vary considerably.
- ❖ The rib cage consists of 18 pairs (usually) of ribs springing from the thoracic vertebrae, curving forward and meeting at the breastbone (sternum).
- ❖ The forelegs carry 60 percent of the horse's body weight. Comprising the forelegs are the shoulder blade (scapula), humerus, radius, knee (8 carpal bones), cannon, splints, long and short pasterns, and the pedal (or coffin) bone.
- ❖ Comprising the hind legs are the pelvis (ilium, ischium, pubis), femur, tibia and fibula, the tarsus or hock (7 bones), canons and splints, pasterns (long and short), and the pedal (or coffin) bone.

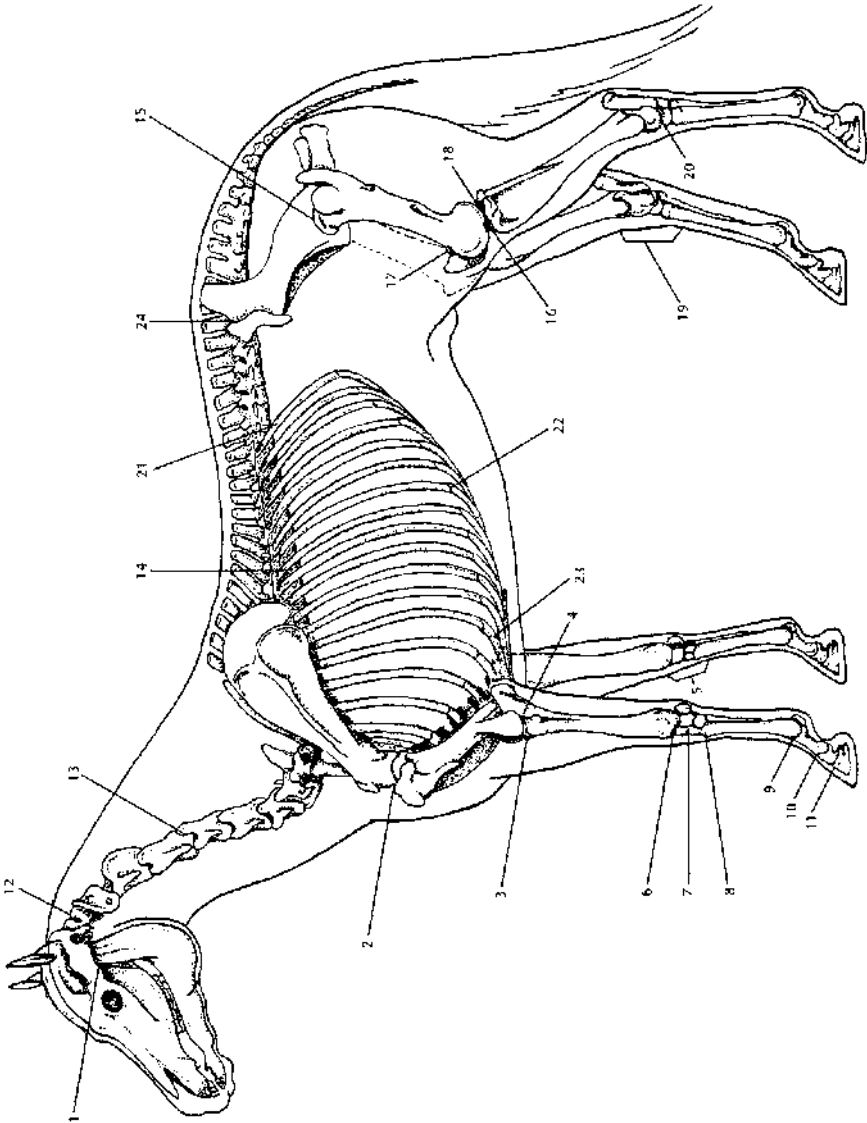
THE JOINTS

Joints are the meeting places between two bones. Movement of the horse is dependent upon the contraction of muscles and the corresponding articulation of the joints.

Some joints in the horse's body are not movable, but most are and permit a great range of motion.

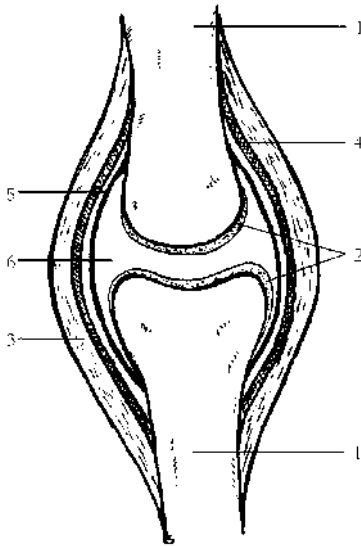
The ends of the bones are lined with hyaline cartilage, which provides a smooth surface between the bones and acts as a shock absorber when compressed—for example, during takeoff and landing while jumping, and for torque during quick turns.

The *joint capsule*, also known as the capsular ligament, is sealed by the synovial membrane, which produces a viscous, lubricating secretion, the synovial fluid.



1.7 Joints of the Horse

- | | | |
|---|---|---|
| (1) jaw joint (temporomandibular joint [TMJ]) | (9) fetlock joint | (17) femoropatellar component of stifle joint |
| (2) shoulder joint | (10) pastern joint | (18) femorotibial component of stifle joint |
| (3) humeroradial component of elbow joint | (11) coffin joint | (19) hock joint (tarsus) |
| (4) humeroulnar component of elbow joint | (12) atlanto-occipital joint | (20) talocrural joint |
| (5) knee joint (carpus or wrist) | (13) cervical intervertebral disc joint | (21) costovertebral joint |
| (6) radiocarpal joint | (14) thoracic intervertebral disc joint | (22) costochondral joint |
| (7) intercarpal joint | (15) hip joint | (23) costosternal joint |
| (8) carpometacarpal joint | (16) stifle joint | (24) sacroiliac joint |



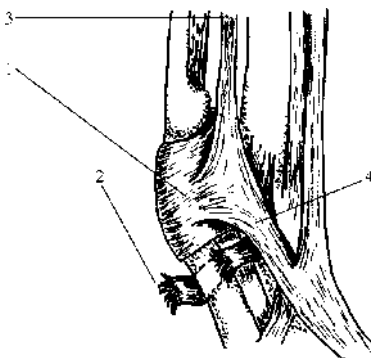
1.8 A Joint

- (1) bone
- (2) hyaline cartilage
- (3) ligament
- (4) fibrous capsule
- (5) synovial lining
- (6) joint cavity (with synovial fluid)

THE LIGAMENTS

A ligament is a band of connective tissue that links one bone to another (*tendons* connect muscles to bones). Ligaments are made up of collagen fiber, a fibrous protein found in the connective tissue. Ligaments have a limited blood supply. Consequently, if a ligament is injured, say by a sprain, it tends to heal slowly and sometimes incorrectly.

Most ligaments are located around joints to give extra support (capsular ligaments and collateral ligaments) or to prevent an excessive or abnormal range of motion and to resist the pressure of lateral torque (a twisting motion). (See figure 1.10, page 24.) The horse experiences lateral torque when turning sharply.



1.9 Ligaments of the Fetlock Joint

- (1) palmar annular ligament, which provides strong support
- (2) example of a torn ligament, the digital annular ligament
- (3) suspensory ligament (superior sesamoid part)
- (4) suspensory ligament extension to common digital extensor tendon

Ligaments have little contracting power and therefore must work in conjunction with muscle action. Within very narrow limits, ligaments are somewhat elastic but are inflexible enough to offer support in normal joint play. If overstretched or repeatedly stretched, a ligament might lose up to 25 percent of its strength. Such a ligament may need surgical stitching to recover its full tensile strength. Severe ligament sprain will lead to joint instability.

Several ligamentous structures help support and protect the vertebral column, pelvis, neck, and limbs from suddenly imposed strain.

THE MUSCULAR SYSTEM

There are three classes of muscles: smooth, cardiac, and skeletal. The *smooth* and *cardiac muscles* are involuntary, or autonomic; they play a part in the digestive, respiratory, circulatory, and urogenital systems.

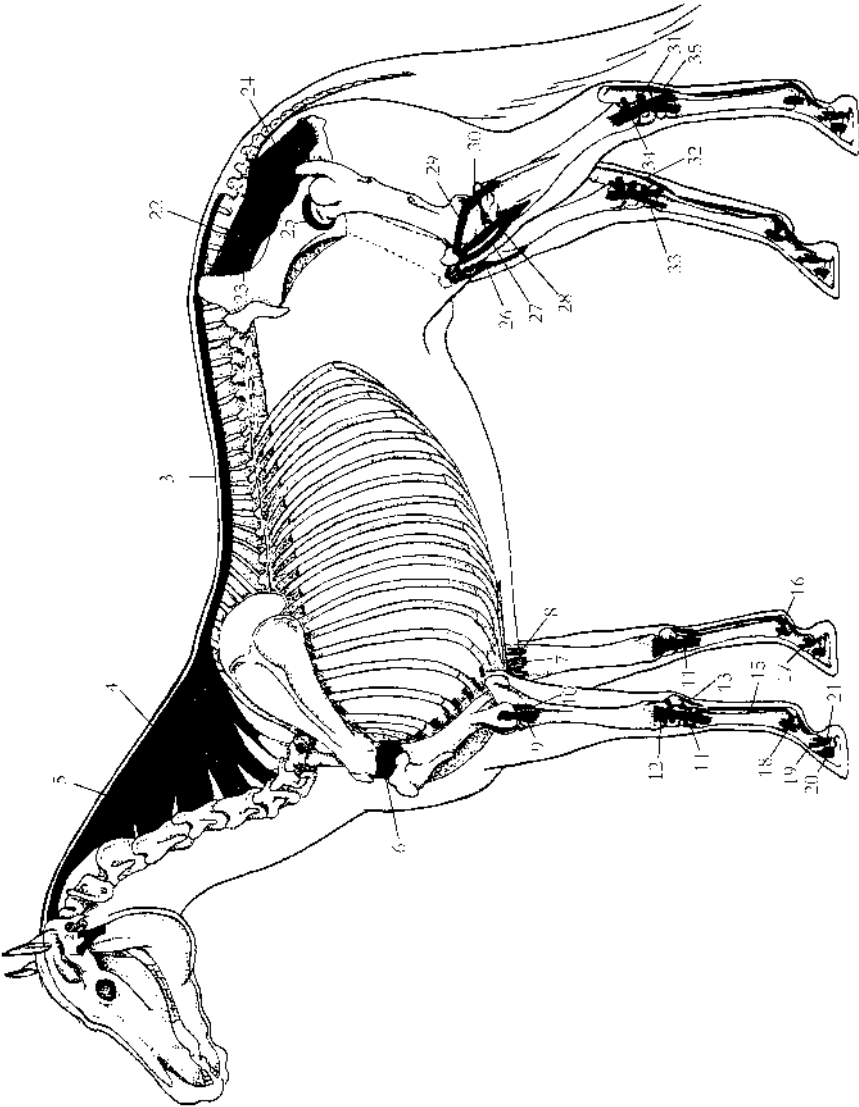
For the most part, *skeletal muscles* are voluntary; they function in the horse's movements. In massage, we are concerned with the more than 700 skeletal muscles that are responsible for the movement of the horse.

There are two types of skeletal muscle fibers: slow twitch fibers (ST) and fast twitch fibers (FT).

Slow twitch fibers are aerobic fibers; they need oxygen in order to do their job. Thus ST fibers require a good supply of blood to bring oxygen to them and to remove waste products created during exercise. ST fibers have strong endurance qualities.

Fast twitch fibers are anaerobic fibers; they do not need oxygen to work and therefore are able to deliver the quick muscular effort required for a sudden burst of speed. However, FT fibers are only able to perform for short periods of time.

The ratio of ST to FT fibers is genetically inherited. Careful selective breeding can emphasize these features in a horse. For example, the muscles of the Quarter Horse are mostly FT fibers, and the breed is noted for its dazzling sprint. On the other hand, a heavy horse, such as a draft horse, has more ST fibers and is noted for its strength and endurance abilities. Whether we are talking about FT or ST fibers, a muscle is made up of a fleshy part and two tendon attachments. The fleshy part, or *muscle belly*, is the part that contracts in response to nervous command. During contraction, the muscle fibers basically fold on themselves, shortening the fibers and resulting in muscle movement. The muscle belly is made up of many muscle fibers arranged in bundles, with each bundle wrapped in connective tissue (*fascia*). The fascia covers, supports, and separates the muscle bundles and the whole muscle



1.10 Ligaments of the Horse

- (1) lateral ligament of jaw joint
- (2) caudal (posterior) ligament of jaw joint
- (3) supraspinous ligament
- (4) funicular part of nuchal ligament
- (5) lamellar part of nuchal ligament
- (6) capsular ligament of shoulder joint
- (7) medial collateral ligament of elbow joint
- (8) medial transverse radioulnar ligament
- (9) lateral collateral ligament of elbow joint
- (10) lateral transverse radioulnar ligament
- (11) medial collateral ligament of carpal joint
- (12) lateral collateral ligament of carpal joint
- (13) distal ligament of accessory carpal bone
- (14) dorsal ligaments of carpal joints
- (15) suspensory ligament (superior sesamoid ligament derived from interosseous muscle)
- (16) distal or inferior sesamoid ligaments
- (17) medial collateral ligament of fetlock joint
- (18) lateral collateral sesamoid ligament (fetlock joint)
- (19) lateral collateral ligament of pastern joint
- (20) lateral collateral ligament of coffin joint
- (21) suspensory ligament of navicular bone
- (22) dorsal sacroiliac ligament
- (23) lateral sacroiliac ligament
- (24) sacrosiatic ligament
- (25) capsular ligament
- (26) medial patellar ligament
- (27) middle patellar ligament
- (28) lateral patellar ligament
- (29) lateral femoropatellar ligament
- (30) lateral collateral ligament of stifle joint
- (31) ligament connecting talus and calcaneus
- (32) branches of medial collateral ligament
- (33) medial collateral ligament of tarsal joint
- (34) lateral collateral ligament of tarsal joint
- (35) calcaneometatarsal ligament (plantar ligament)

itself. This arrangement allows for greater support, strength, and flexibility in the movement between each of the muscle groups.

TENDONS

The tendon is the portion of the muscle that attaches to the bone. It is made up of *connective tissue*—a dense, white, fibrous tissue much like that of a ligament. The *origin tendon* is the tendon that attaches the muscle to the least movable bone; the *insertion tendon* attaches the muscle to the movable bone, so that on contraction the insertion is brought closer to the origin. Tendons attach to the periosteum of the bone; the fibers of the tendon blend with the periosteum fibers because of their similar collagen make-up. Tendons can be fairly short, or quite long as is seen with the flexor and extensor muscles of the lower legs. Usually, tendons are rounded but they can be flattened like the tendons that attach along the spine.

Because of their high-tensile strength, tendons can endure an enormous amount of tension, usually more than the muscle itself can produce; consequently, tendons do not rupture easily. They are not as elastic as muscle fibers, but they are more elastic than ligament fibers.

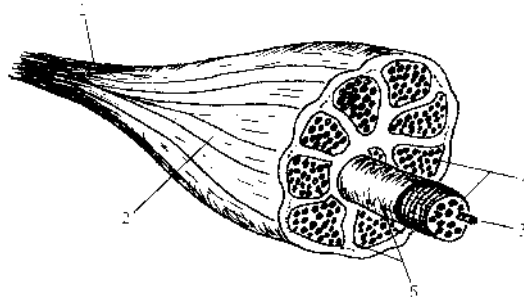
Tendons can “stress up” after heavy exercise, meaning that they can stay contracted. Gentle massage and stretching exercises will loosen residual tension. (See the neuromuscular technique in chapter 5.) Inflamed tendons are at great risk of being strained or overstretched. The horse has no muscles below the knee or hock; consequently, many leg muscles have long tendons that run down the legs over the joints. These tendons are protected by sheaths, or tendon bursae. Chronic irritation of the sheath can result in excess fluid production and soft swellings. Cold hydrotherapy (chapter 4) and massage will help increase circulation and keep inflammation down. If the inflammation persists, check with your veterinarian.

MUSCLES

Muscles come in all shapes and sizes. Some are small, some are large; some are thin, some are bulky. Look at the muscle charts to note the variety of shapes in the horse's muscle structure.

Muscles act together to give the horse his grace and power. Muscles work in three different ways: isometric contraction, concentric contraction, and eccentric contraction.

Isometric contraction occurs when a muscle contracts without causing any movement. During standing, for example, isometric contraction ensures stability.

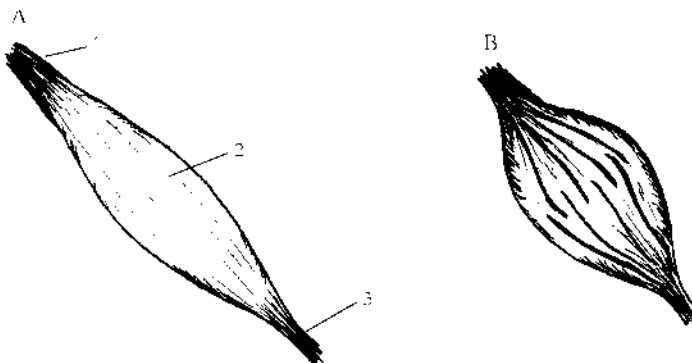


1.11 Cross-Section of a Skeletal Muscle

- (1) tendon
- (2) muscle belly
- (3) muscle fiber (containing thick and thin filaments)
- (4) bundles (made up of fibers)
- (5) fascia

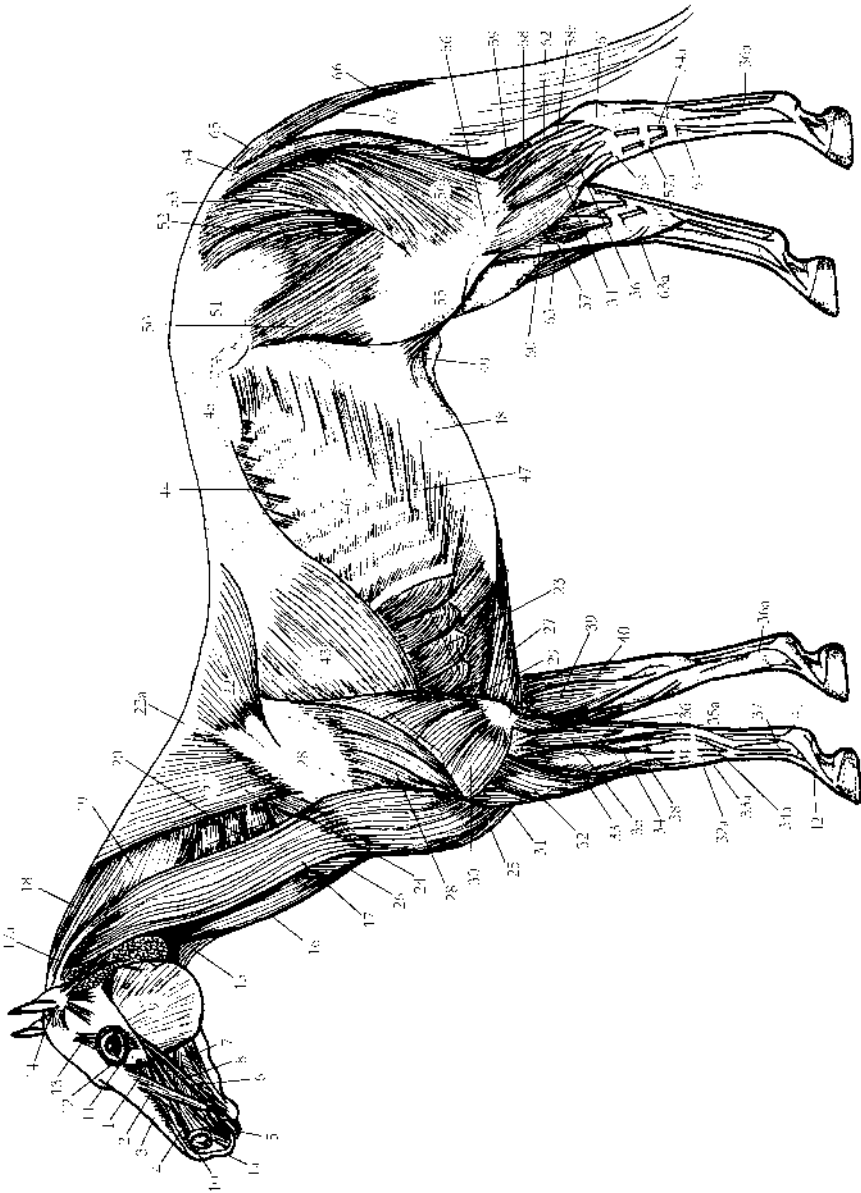
Concentric contraction occurs when a muscle shortens as it contracts, causing articular movements. Concentric contraction is mostly seen in regular movements such as *protraction* (forward movement) or *retraction* (backward movement) of the limbs, and in any movement of the neck or back.

Eccentric contraction occurs when a muscle gradually releases as it elongates. Eccentric contraction assists regular movements to avoid jerky, unstable actions; it also plays a role in shock absorption during the landing phase of jumping.



1.12 A Muscle

- (A) Relaxed
- (B) Contracted
- [1] origin tendon
- [2] muscle belly
- [3] insertion tendon



1.13 Superficial Muscles of the Horse

- | | | |
|--|--|--|
| (1, 1a) levator muscle of upper lip and its tendon | (23) thoracic part of ventral serrate muscle | (41) suspensory ligament (superior sesamoidian section) |
| (2) levator muscle of upper lip and nostril wing | (24) cranial deep pectoral muscle (anterior part of deep pectoral) | (42) extensor branch of suspensory ligament, attaching to common digital extensor tendon |
| (3) dorsal part of lateral nasal muscle | (25) cranial superficial pectoral muscle (anterior part of superficial pectoral) | (43) latissimus dorsi muscle |
| (4) lateral nostril dilator muscle | (26) remains of skin muscle of neck | (44) caudal part of dorsal serrate muscle |
| (5) orbicular muscle of the mouth | (27) caudal deep pectoral muscle (posterior part of deep pectoral) | (45) lumbodorsal fascia (thoracolumbar fascia) |
| (6) buccinator muscle | (28) deltoideus muscle | (46) external intercostal muscle |
| (7) depressor muscle of lower lip | (29) long head of triceps | (47) external abdominal oblique muscle |
| (8) zygomatic muscle | (30) lateral head of triceps | (48) aponeurosis (broad and flattened tendon of attachment) |
| (9) masseter muscle | (31) brachialis muscle | (49) remains of skin muscle in fold of flank |
| (10) transverse nasal muscle | (32, 32a) radial carpal extensor muscle and tendon | (50) tensor muscle of lateral fascia of thigh (musculus tensor fasciae latae, or TFL) |
| (11) depressor muscle of lower eyelid | (33, 33a) common digital extensor muscle and tendon | (51) gluteal fascia |
| (12) orbicular muscle of the eye | (34, 34a) lateral digital extensor muscle and tendon | (52) superficial gluteal muscle |
| (13) corrugator supercilii muscle | (35, 35a) lateral carpal flexor muscle and its two tendons, long and short | (53) biceps femoris muscle (part of hamstring group) |
| (14) auricular muscles | (36, 36a) deep digital flexor muscle and tendon | (54) semitendinosus muscle (part of hamstring group) |
| (15) sternohyohyoid and omohyoid muscles | (37) superficial digital flexor tendon | (55) lateral femoral fascia |
| (16) sternomandibular part of sternocephalic muscle and tendon | (38) oblique carpal extensor muscle | (56) lateral crural fascia |
| (17, 17a) brachiocephalic muscle and tendon | (39) medial carpal flexor muscle | (57, 57a) long digital extensor muscle |
| (18) cervical part of rhomboid muscle | (40) middle carpal flexor muscle | (58) Achilles tendon of triceps surae muscle |
| (19) splenius muscle | | (58a) lateral head of gastrocnemius muscle |
| (20) cervical part of ventral serrate muscle | | |
| (21) cervical part of trapezius muscle | | |
| (22) thoracic part of trapezius muscle | | |
| (22a) tendinous intersection between the two parts of trapezius muscle | | |

(continued)

1.13 Superficial Muscles of the Horse (continued)

- (59) soleus muscle
- (60) popliteal muscle
- (61) common calcaneal tendon (the aggregate of tendons attached to tuber calcanei, i.e., Achilles tendon, superficial digital flexor tendon, and accessory or tarsal tendon from the hamstring muscles)
- (62) accessory or tarsal tendon (from musculus biceps femoris and musculus semitendinosus of the hamstring group of muscles)
- (63) cranial tibial muscle (anterior part of flexor metatarsi)
- (63a) medial tendon of insertion of the cranial tibial muscle (cunean tendon or cuneiform insertion)
- (64, 64a) annular ligaments
- (65) short tail levator muscles
- (66) long tail levator muscles
- (67) tail depressor muscles

Skeletal muscles are highly elastic and have strong contractile power. They respond to motor nerve impulses; as a result, the contraction mechanism is a generated process. The release process is not a generated process, but rather is a natural relaxation of the muscle as a result of the cessation of the motor nerve impulses that originally “asked” the muscle to contract.

When a muscle develops a *contracture*, the muscle fibers stay contracted, eventually resulting in a spasm—at which point the natural relaxation process will not happen. Pain and motion problems will develop as a result.

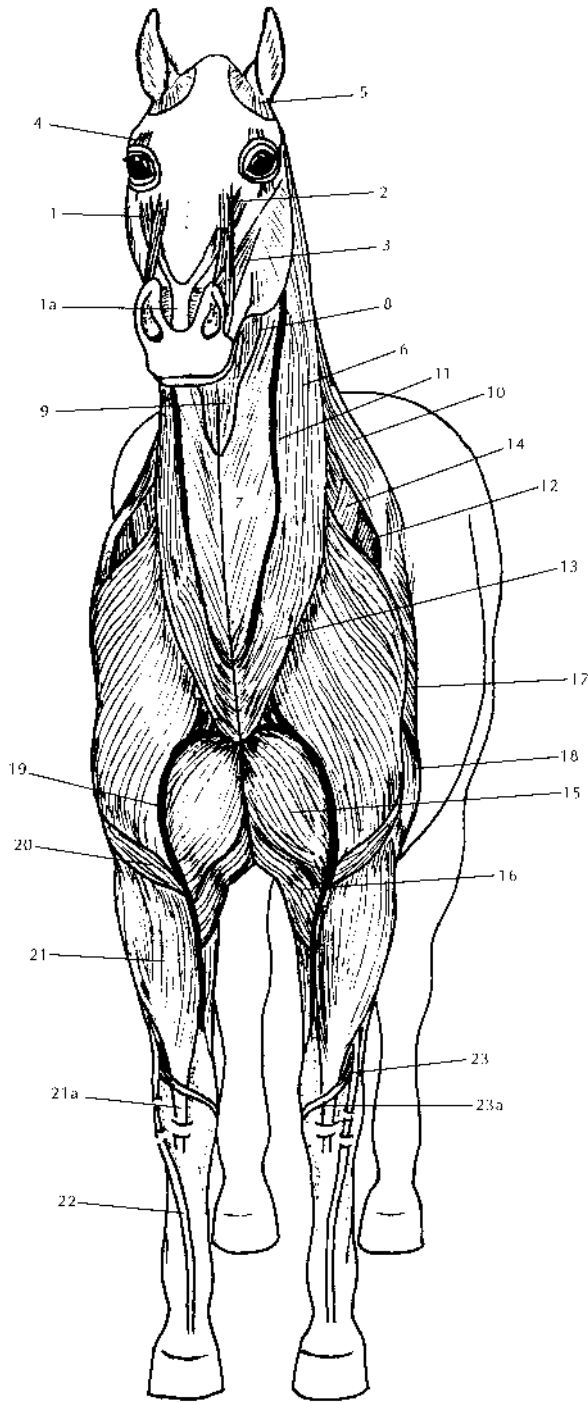
Muscles are equipped with two types of sensory nerve endings: the Golgi apparatus and the muscle spindle. The *Golgi apparatus* nerve endings send feedback impulses to the brain as to the whereabouts of the muscles; this process is referred to as *proprioception*. The Golgi nerve endings are mostly located where the muscles and the tendons come together.

The nerve endings of the muscle spindle prevent overstretching of the muscle fibers. As its name implies, this nerve fiber coils around the length of the muscle bundle. Reaching a given length, the muscle spindle fires nerve impulses that trigger a fast reflex motor nerve reaction to induce immediate contraction of the muscle fibers. Thus the overstretching and potential tearing of fibers is prevented. This is a safety reflex mechanism.

When a muscle overstretches, a spasm often results. This is a *tetanic* (violent) contraction of a muscle in response to overstretching or trauma, whereby the muscle is unable to release its rigidity. A *microspasm*, on the other hand, is a small spasm occurring in just a few fibers of the muscle bundle. Microspasms have a cumulative effect over a period of time, resulting in a full spasm.

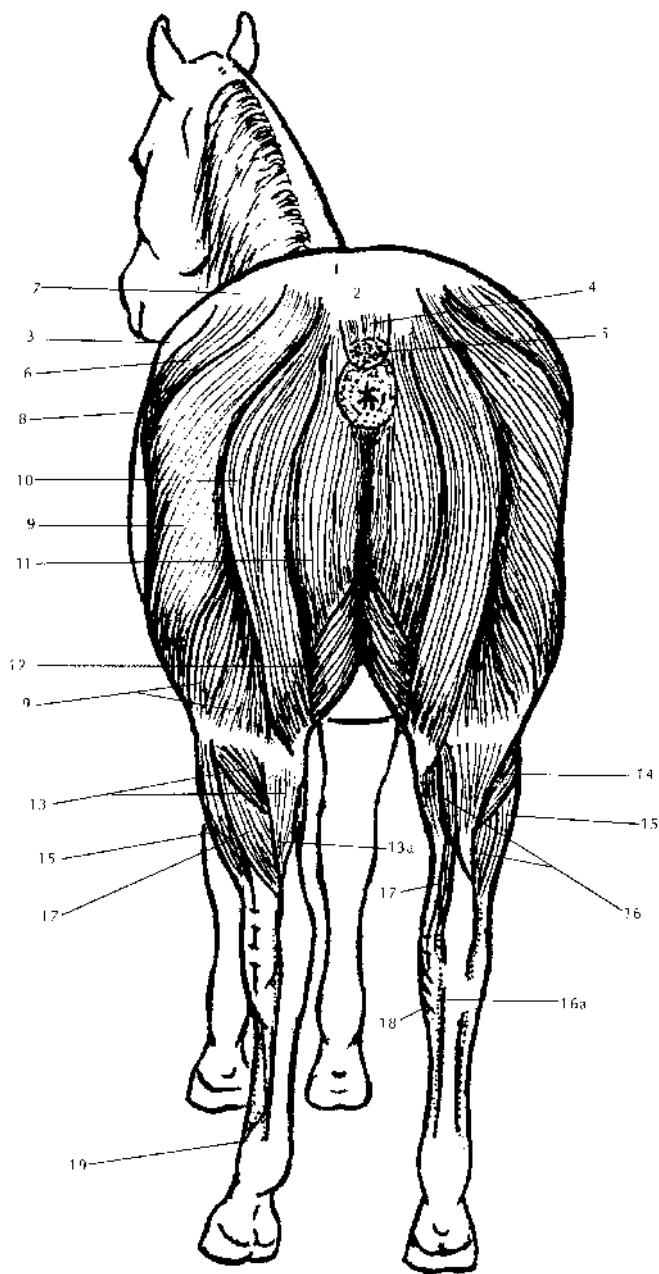
Sometimes a muscle is stretched past its limit and muscle fibers will tear. This causes an immediate muscle spasm and triggers an inflammation response, with swelling at the site of injury. As part of the healing process, new connective tissue is laid down in an irregular, scattered pattern within the muscle fiber arrangements. Unfortunately this scar tissue reduces the muscle's tensile strength, flexibility, and elasticity. Massage therapy can reduce the amount of scar tissue by applying deep kneadings and frictions after proper warm-up of the tissues. Also, stretching is a great technique for prevention and reduction of the formation of scar tissue.

A heavily exercised muscle will often develop light inflammation within its fibers. This is a normal process that promotes formation of new muscle fibers. But it is important to keep any inflammation under control to avoid the formation of scar tissue. To keep inflammation down, use cold hydrotherapy, ultrasound,



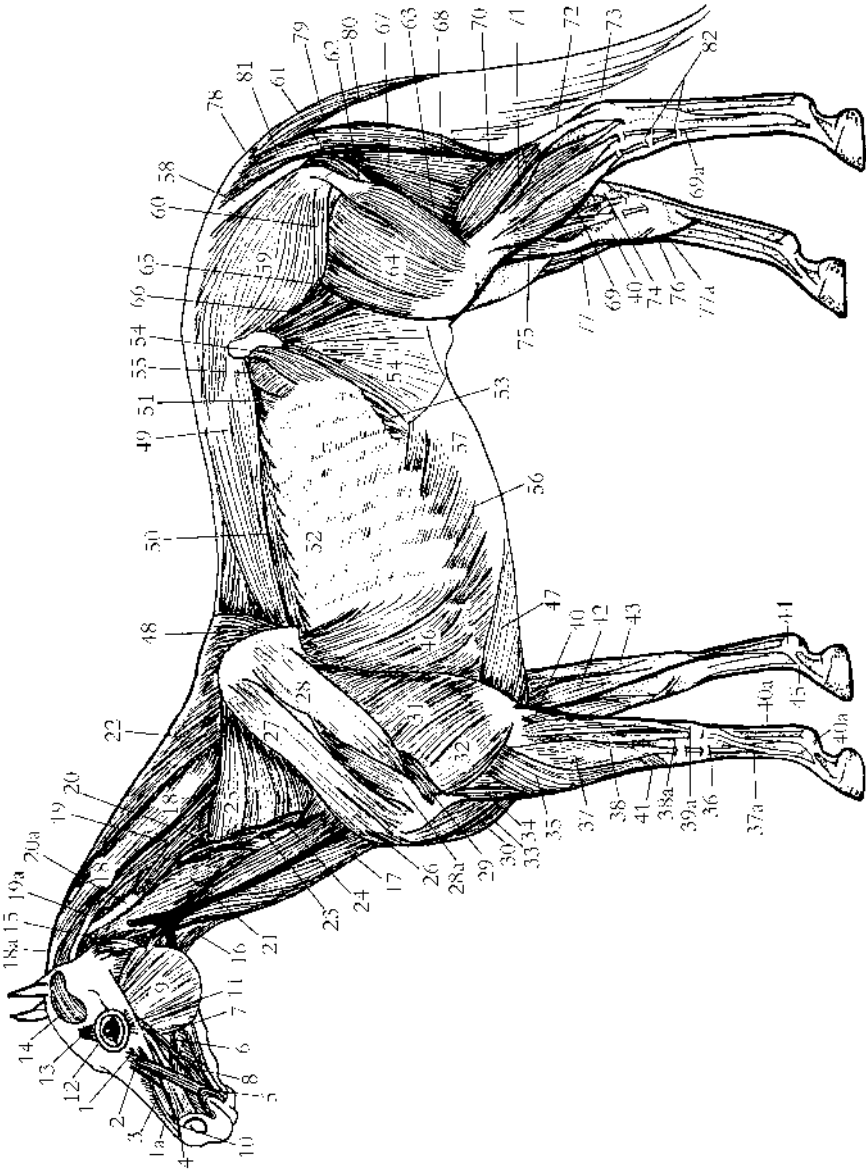
1.14 Muscles of the Horse, Front View

- (1, 1a) levator muscle of upper lip and tendon
- (2) levator muscle of upper lip and nostril wing
- (3) lateral nostril dilator muscle
- (4) corrugator supercilii muscle
- (5) interscutular muscle
- (6) brachiocephalic muscle
- (7) sternomandibular part of sternocephalic muscle
- (8) omohyoid muscle
- (9) sternothyroid muscle
- (10) cervical part of trapezius muscle
- (11) jugular vein
- (12) supraspinous muscle
- (13) remains of skin muscle in the neck
- (14) cranial deep pectoral muscle
- (15) cranial superficial pectoral muscle
- (16) caudal superficial pectoral muscle
- (17) long head of triceps muscle
- (18) lateral head of triceps muscle
- (19) cephalic vein
- (20) brachial muscle
- (21, 21a) radial carpal extensor muscle and tendon
- (22) common digital extensor tendon
- (23, 23a) oblique carpal extensor muscle and tendon



1.15 Muscles of the Horse, Rear View

- (1) point of croup
- (2) dock of tail
- (3) point of hip or haunch (*tuber coxae*)
- (4) levator muscles of tail
- (5) depressor muscles of tail
- (6) superficial gluteal muscles
- (7) gluteal fascia
- (8) tensor muscle of lateral femoral fascia
- (9) biceps femoris muscle
- (10) semitendinosus muscle
- (11) semimembranosus muscle
- (12) gracilis muscle
- (13, 13a) gastrocnemius muscle and tendon
- (14) soleus muscle
- (15) lateral digital extensor muscle
- (16, 16a) superficial digital flexor muscle and tendon
- (17) deep digital flexor muscle
- (18) inner or medial tendon of the cranial tibial muscle
- (19) suspensory ligament



1.16 Deeper Muscles of the Horse

- | | | |
|---|--|--|
| (1, 1a) levator muscle of upper lip and its tendon | (22) rhomboideus muscle | (41) oblique carpal extensor muscle |
| (2) levator muscle of upper lip and nostril wing | (23) scalene muscle | (42) medial carpal flexor muscle |
| (3) dorsal part of lateral nasal muscle | (24) intertransverse muscle | (43) middle carpal flexor muscle |
| (4) lateral nostril dilator muscle | (25) cervical part of ventral serrate muscle | (44) suspensory ligament (superior sesamoid ligament derived from interosseous muscle) |
| (5) orbicular muscle of the mouth | (26) cranial deep pectoral muscle (the anterior part of the deep pectoral) | (45) suspensory ligament, extensor branch, attaching to the common digital extensor tendon |
| (6) buccinator muscle | (27) supraspinatus muscle | (46) thoracic part of ventral serrate muscle |
| (7) depressor muscle of lower lip | (28, 28a) infraspinatus muscle and tendon | (47) caudal deep pectoral muscle (posterior part of deep pectoral) |
| (8) zygomatic muscle | (29) teres minor muscle | (48) spinalis dorsi muscle (musculus spinalis and semispinalis thoracis and cervicis) |
| (9) masseter muscle | (30) cranial superficial pectoral muscle (anterior or clavicular part of superficial pectoral) | (49) longissimus dorsi muscle (musculus longissimus thoracis and lumborum) |
| (10) transverse nasal muscle | (31) long head of triceps muscle | (50) iliocostalis dorsi muscle (musculus iliocostalis thoracis and lumborum) |
| (11) depressor muscle of lower eyelid | (32) lateral head of triceps muscle | (51) retractor costae muscle |
| (12) orbicular muscle of the eye | (33) biceps brachii muscle | (52) external intercostal muscles |
| (13) corrugator supercilii muscle | (34) brachialis muscle | (53) internal intercostal muscles |
| (14) temporal muscle | (35) radial carpal extensor muscle | (54) internal abdominal oblique muscle |
| (15) occipitomandibular muscle (jugulo-mandibular) | (36) radial carpal extensor tendon | (55) transverse abdominal muscle |
| (16) sternothyrohyoid and omohyoid muscles | (37, 37a) common digital extensor muscle and tendon | (56) external abdominal oblique muscle |
| (17) sternomandibular part of sternocephalic muscle | (38, 38a) lateral digital extensor muscle and tendon | |
| (18, 18a) complexus muscle and tendon (part of semispinalis capitis muscle) | (39, 39a) lateral carpal flexor muscle and its two tendons, long and short | |
| (19, 19a) longissimus capitis muscle and tendon | (40, 40a) deep digital flexor muscle and tendon | |
| (20, 20a) longissimus atlantis muscle and tendon | | |
| (21) rectus capitis ventralis muscle | | |

(continued)

1.16 Deeper Muscles of the Horse (continued)

- | | | |
|--|--|--|
| (57) aponeurosis (flattened tendon) | (66) iliac muscle | (74) accessory or tarsal tendon |
| (58) sacrosciatic ligament | (67) semimembranosus muscle (part of the hamstring group of muscles) | (75) popliteal muscle |
| (59) medial gluteal muscle | (68) semitendinosus muscle (part of the hamstring group of muscles) | (76) saphenous vein |
| (60) deep gluteal muscle | (69, 69a) long digital extensor muscle and tendon | (77, 77a) peroneus tertius muscle and its tendon |
| (61) gemellus muscle | (70) lateral head of gastrocnemius | (78) short tail levator muscles |
| (62) quadratus femoris muscle | (71) soleus muscle | (79) long tail levator muscles |
| (63) adductor femoris muscle | (72) Achilles tendon (tendon for gastrocnemius and soleus muscles) | (80) tail depressor muscle |
| (64) lateral vastus muscle (part of quadriceps muscle) | (73) superficial digital flexor tendon | (81) coccygeus muscle |
| (65) rectus femoris muscle (part of quadriceps muscle) | | (82) annular ligament |

and deep massage. These techniques will promote blood circulation, bringing new oxygen and nutrients to affect healing and to break down scar tissue within the muscle fibers.

As a result of heavy training and exercise, a stress point may develop close to the origin tendon of the muscle. A *stress point* is a small spasm in the muscle fiber. Keep the horse free of stress points by using the stress point technique in chapter 5. (Chapter 10 describes the stress points specific to each body part and chapter 15 describes the stress points specific to each discipline.) Another side effect of an intense training program and vigorous exercise is the formation of trigger points. A *trigger point* is a combination of lactic acid build-up and motor nerve ending irritation, mostly in the fleshy part (belly) of the muscle. The term “trigger point” derives from the fact that when pressure is applied to a particular point, a pain signal will be sent to other parts of the body. Trigger points can be found in any muscle of the body. Keep your horse free of trigger points by using the trigger point technique in chapter 5.

Study all the charts and learn about all aspects of the horse’s body. Understanding the interrelation of all the various systems will contribute greatly to your expertise in assessing the various problems you may encounter and wish to treat with massage.

A solid understanding of equine anatomy will assist your ability to properly massage each body part of your horse. Knowing all the muscles, the joints they influence, and the bones involved will give you a more assertive approach in your massage care. You will be amazed at how much information you can learn from this chapter. This knowledge will give you confidence in your practice.