

## **SECTION I**

### **FUNDAMENTALS AND CLINICAL APPLICATIONS OF HEMODYNAMICS:**

COPYRIGHTED MATERIAL



## UNDERSTANDING THE PRESSURE WAVES IN THE HEART: THE WIGGER'S DIAGRAM

Everything you want to know about hemodynamics starts here. All pressure waves of the cardiac cycle can be understood by reviewing and knowing how electrical and mechanical activity of the heart's contraction and relaxation are related.

Every electrical activity is followed normally by a mechanical function (either contraction or relaxation) resulting in a pressure wave. The timing of mechanical events can be obtained by looking at the ECG and corresponding pressure tracing.

The ECG "P" wave, the QRS, and the "T" wave are responsible for atrial contraction, ventricular activation, and ventricular relaxation, respectively. The periods between electrical activation reflect impulse transmission times to different areas of the heart. These time delays permit the mechanical functions to be in synchrony and generate efficient cardiac output and pressure. When the normal sequence of contraction and relaxation of the heart muscle are disturbed by arrhythmia, cardiac function is inefficient or ineffective as demonstrated on the various pressure waveforms associated with the arrhythmia.

The cardiac cycle is begun with the P wave. The P wave is the electrical signal for atrial contraction. The atrial pressure wave ("A" wave, point #1 in Figure I.1) follows the P wave by 30–50 msec. Following the A wave peak, the atrium relaxes and pressure falls, generating the x-descent (point b).

The next event is the depolarization of the ventricles with the QRS (point b). The LV pressure after the "A" wave is called the *end-diastolic pressure*. It can be denoted by a vertical line dropped from the R wave to the intersection of the LV pressure (point b). About 15–30 msec after the QRS, the ventricles contract and both the LV and RV pressures increase rapidly. This period with rise in LV pressure without change in LV volume is called the *isovolumetric contraction period* (interval b–c).

When LV pressure rises above the pressure in the aorta, the aortic valve opens and blood is ejected into the circulation (point c). This point is the beginning of systole. Some hemodynamicists include isovolumetric contraction as part of systole.

About 200–250 msec after the QRS, the heart begins relaxing and repolarization starts, thereby generating a "T" wave. At the end of the "T" wave (point e), the LV contraction has ended and LV relaxation produces a fall in the LV (and aortic pressure). When the LV pressure falls below the aortic pressure, the aortic valve closes (point e). Systole is concluded and diastole is underway. After aortic valve closure the ventricular pressure continues to fall. When the LV pressure falls below the LA pressure, the mitral valve opens and the LA empties into the LV (point f). The period from aortic valve closure to mitral valve opening is called the *isovolumetric relaxation period* (interval e–f). Diastole is the period from mitral valve opening to mitral valve closing.

Following the atrial pressure wave across the cycle, it should be noted that after the A wave, pressure slowly rises across systole, continuing to increase until the end of systole when the pressure and volume of the LA are nearly maximal, producing a ventricular filling wave, the "V" wave. The "V" wave (point f, #4) peak is followed by a rapid fall when the mitral valve opens. This V wave pressure descent is labeled the "y"-descent. The peaks and descents of the atrial pressure waves are changed by pathologic conditions and used to support the diagnosis of these pathologies, as will be seen in the examples dealing with heart failure, constrictive physiology, and RV infarction.

After the "V" wave, the LV is filled by the small pressure gradient assisting blood flow from the atria into the ventricles over the diastolic period (called diastasis) until the cycle begins again with atrial pressure building until activated to contract and generate the A wave, ejecting atrial blood into the LV.

To appreciate valve function and dysfunction, we study the pressure changes that normally open and close the valves. The aortic and pulmonary valves open in

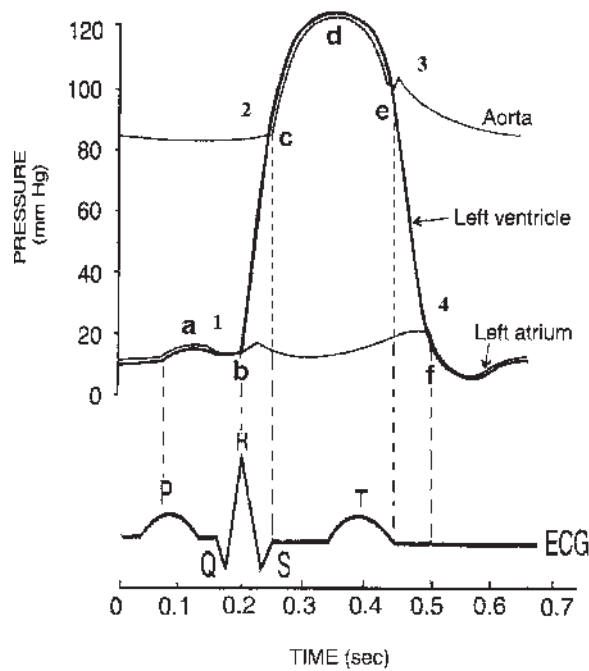


Fig. Section I.1. The cardiac cycle.

systole, when ventricular pressure exceeds aortic pressure (and RV exceeds PA pressure). Stenosis of these valves produces high-velocity systolic murmurs.

The mitral and tricuspid valves are closed in systole when LV pressure is greater than atrial pressure. A mitral or tricuspid regurgitant valve that fails to close is characterized by a low-velocity systolic murmur with a rumbling quality.

Conversely, incompetent aortic valves failed to seal and let blood continue to rush backward into the LV in diastole. The blood rushes into the LV with a diastolic murmur. At the beginning of diastole, LA pressure is at its highest. If the mitral valve is stenotic, the high LA pressure emptying into the LV produces a diastolic rumble.

When reviewing the cardiac hemodynamics, we can always refer to the Wigger's diagram to determine what the expected normal hemodynamic responses should be.

The Wigger's diagram with periods of systole, diastole, and isovolumetric contraction and relaxation periods identified on Figure I.2.

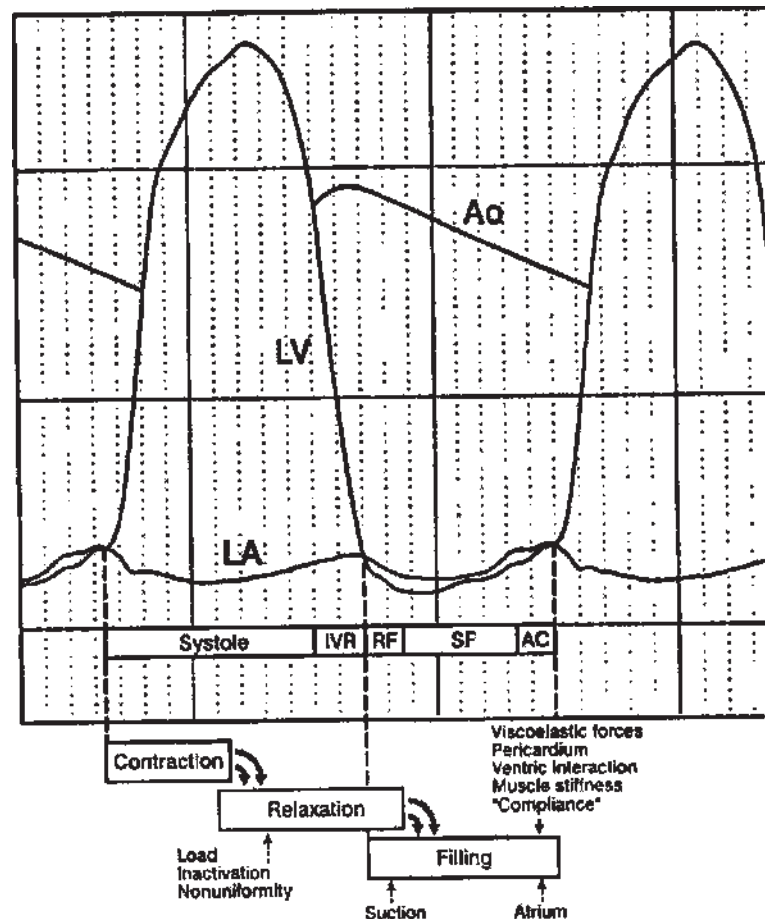
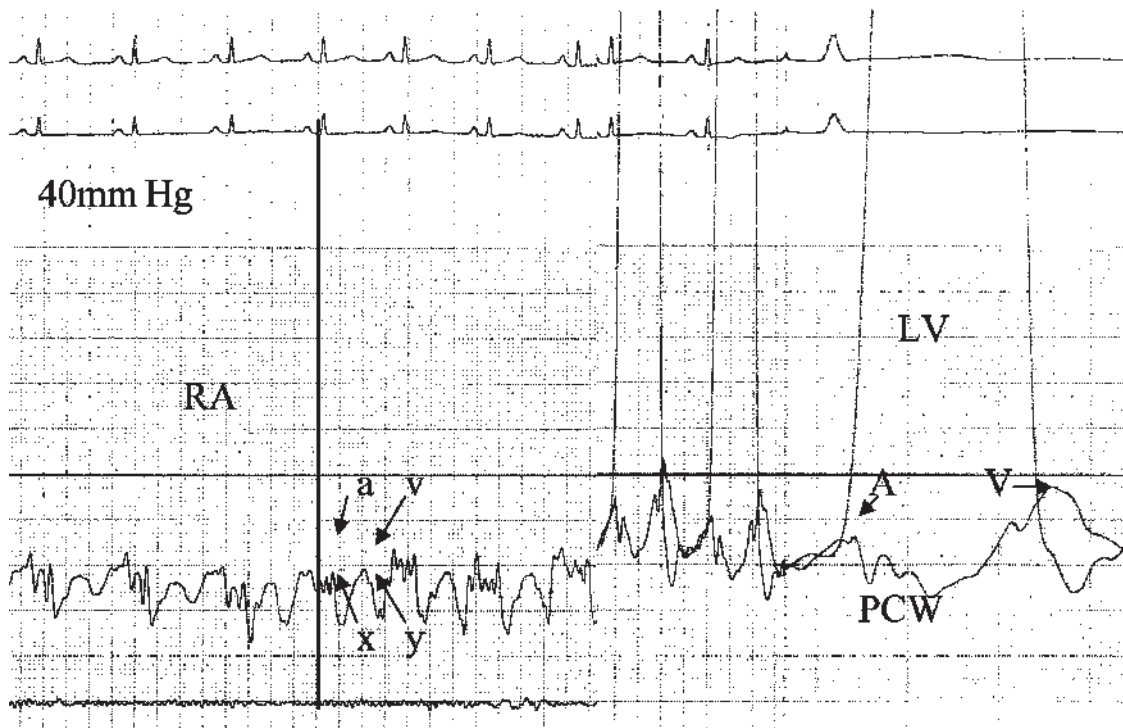


Fig. Section I.2. Wigger's diagram.



**Fig. Section I.3.** Normal RA, PCW and LV pressure waveforms. LV, left ventricle; 0–40 mm Hg scale.

A normal right atrial (RA) and pulmonary capillary wedge (PCW) pressure tracing (used as left atrial pressure) is shown in Figure I.3 demonstrating normal “A”

and “V” waves with the associated “x”- and “y”-descents.



## **PART 1**

### **HEMODYNAMIC WAVEFORMS NORMAL AND PATHOPHYSIOLOGIC:**





## PRESSURE WAVE ARTIFACTS: MEASUREMENT SYSTEMS AND ARTIFACTS\*

MORTON J. KERN, MD, AND STEVEN APPLEBY, MD

If the measurement of blood pressure were automatically available without having to attend to transducer flushing, pressure line and manifold connections, and mis-settings on the recorders or kinks in catheters, the study of hemodynamics would be as routine and reliable as that of electrocardiography. However, as with any recording system that requires specially trained personnel and multiple combinations of different types of connectors, the mechanical and electrical artifacts of both fluid-filled tubes and high-fidelity recording instruments produce pressure wave artifacts that must be recognized as the major flaw in accurate hemodynamic data interpretation.

Probably the most common of the pressure wave artifacts of fluid-filled systems are (a) the exaggerated “ringing” of underdamping and (b) the overly damped “rounded” waveforms.

### PRESSURE SYSTEM RESONANCE: THE UNDER- AND OVERDAMPED WAVEFORM

An “underdamped” pressure tracing is one in which the pressure wave is rapidly reflected within the system and produces an oscillating sinusoidal distortion of the pressure waveform [1]. This underdamped tracing is also called “ringing,” as in continued bounding of sound waves in a bell with a characteristic demonstration of the physics of reflected waves [2]. Commonly, an air bubble in the pressure line will be small enough to be rapidly accelerated and decelerated, moving the fluid column

back and forth, resulting in ringing of the pressure tracing. The effect of a bubble in the pressure line connected to a 7 F pigtail catheter and fluid-filled transducer used to measure left ventricular pressure is illustrated in Figure I.1 (left panel). The bubble causes a high spike on the left ventricular upstroke and causes a large negative overshoot wave on the left ventricular pressure downstroke. When the pressure line and transducer are properly flushed, the left ventricular pressure (Figure I.1, right panel) shows an excellent and normal waveform which should be expected with modern fluid-filled systems.

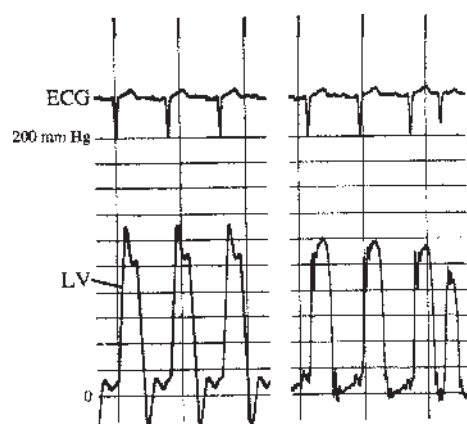
An overdamped waveform reduces the impact of the pressure wave, rounding the contours and delaying the upstroke and downstroke of the pressure wave. An example of pressure overdamping will be described later and depicted in Figure I.7.

### CALIBRATION ERRORS: HIDDEN ARTIFACTS

Observe the underdamped pressure waveform on Figure I.2. The pulmonary capillary wedge (PCW) and pulmonary artery pressures were recorded during the balloon catheter deflation. The fluid-filled transducer was properly flushed. Note the oscillations making precise waveform analysis difficult. The ringing was due to vigorous catheter movement in the right heart. This amount of underdamping is common with the right heart balloon-tipped catheters and can be reduced with instillation of a 50% saline/contrast flush. However, there are two additional artifacts that will contribute to misinterpretation. While looking for the hidden artifacts, consider the question, What is the maximal pressure of the V wave, the pulmonary artery diastolic pressure, and the heart rate? Check the pressure scale again. How many lines are there from 0 to 50 mm Hg? The recording technician inadvertently omitted line 10. Nine lines are placed on the screen with the standard

\* Kern MJ, Aguirre F, Donohue T. Hemodynamic rounds: Interpretation of cardiac pathophysiology from pressure waveform analysis: Pressure wave artifacts. *Cathet Cardiovasc Diagn* 27:147–154, 1992.

*Hemodynamic Rounds: Interpretation of Cardiac Pathophysiology from Pressure Waveform Analysis, Third Edition*, edited by Morton J. Kern, Michael J. Lim, and James A. Goldstein.  
Copyright © 2009 John Wiley & Sons, Inc.



**Fig. 1.1.** Left ventricular (LV) pressure with 7 F pigtail catheter using fluid-filled transducers. Left panel demonstrates “ringing” artifact. See text for details.

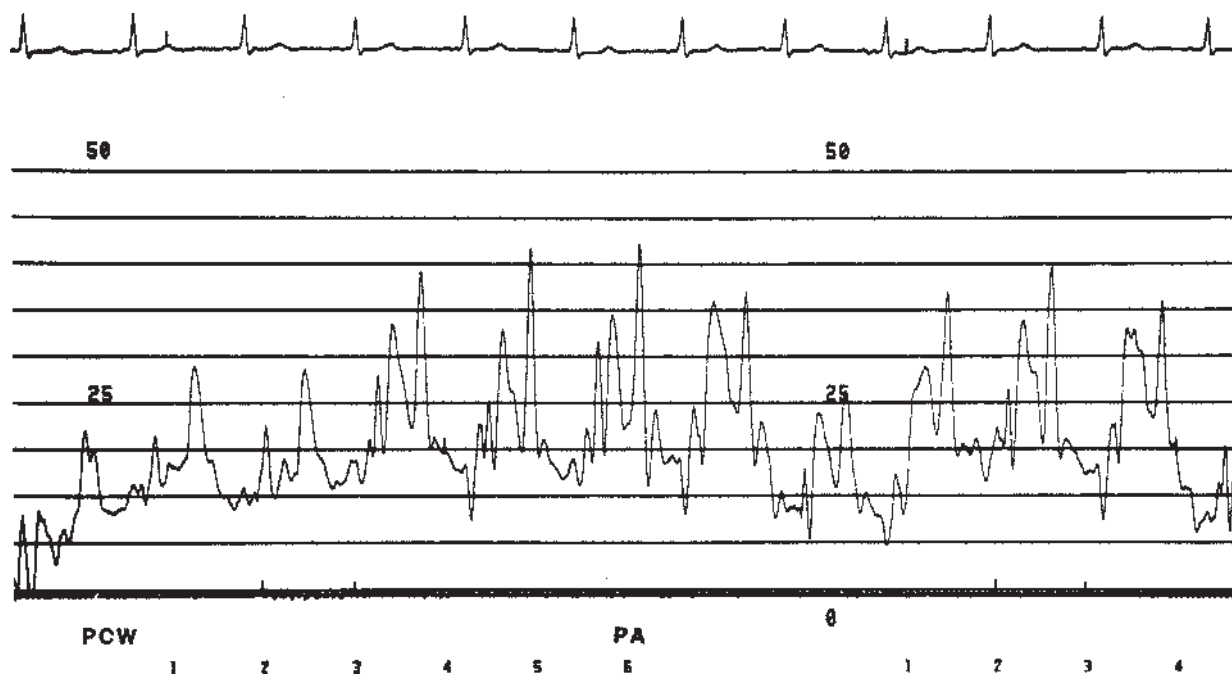
notations of 0, 25, and 50 mm Hg. The V wave is 24 mm Hg if the “25 mm Hg” marker is low and line 10 is omitted from the top. Otherwise, the V wave equals 27 mm Hg ( $50/9 \text{ mm Hg} = 5.6 \times 4.8$ ) if nine divisions are equal to 50 mm Hg. In most settings, this degree of error is clinically unimportant; but in cases where valve areas are considered worthwhile hemodynamically, this error is unacceptable. The pulmonary artery pressure is computed as for the V wave.

What is the heart rate? Traditional teaching methods count the RR intervals in 10 sec and multiply by 6.

Unfortunately, this recording is also missing the time lines. The heart rate might be estimated by assuming the usual recording speed of 25 mm/sec and measuring the distance on the paper. However, this patient may have had tachycardia and the recording speed could be 50 mm/sec. Again, although minimally important for clinical decisions, the operator’s confidence in his data is not optimal. These deficiencies should be minimized for accurate and reliable data collection.

Consider the hemodynamics obtained in a 60-year-old man who has mild dyspnea, chest pain, and a systolic murmur (Figure I.3). Central aortic and femoral arterial pressures were matched using fluid-filled catheters (6 F arterial sheath and 5 F pigtail catheter) before assessing the aortic valve gradient. Report your readings of left ventricular and aortic pressures, heart rate, estimated valve gradient, and quick area calculations given a thermodilution cardiac output of 3.0 liters/min. A problem again arises because of the two recording artifacts of pressure scale and time lines. Left ventricular systolic pressure is either 140 mm Hg or 155 mm Hg ( $200/9 \times 7 = 22.2 \times 7$ ). The aortic pressure is 130 mm Hg or 144 mm Hg ( $22.2 \times 6.5$ ). The peak-to-peak gradient is 10 or 11 mm Hg with valve area of  $3.0/\sqrt{10} = 0.95$  or  $3.0/\sqrt{11} = 0.90 \text{ cm}^2$ , respectively. The heart rate in Figure I.3 must be estimated as discussed for Figure I.2 because the time lines were again omitted.

Pressure lines can also be malpositioned if the switch that controls the pressure line scale is accidentally moved



**Fig. 1.2.** Pulmonary capillary wedge (PCW) pulmonary artery (PA) pressures in an underdamped system. There are also two “hidden” artifacts. See text for details.

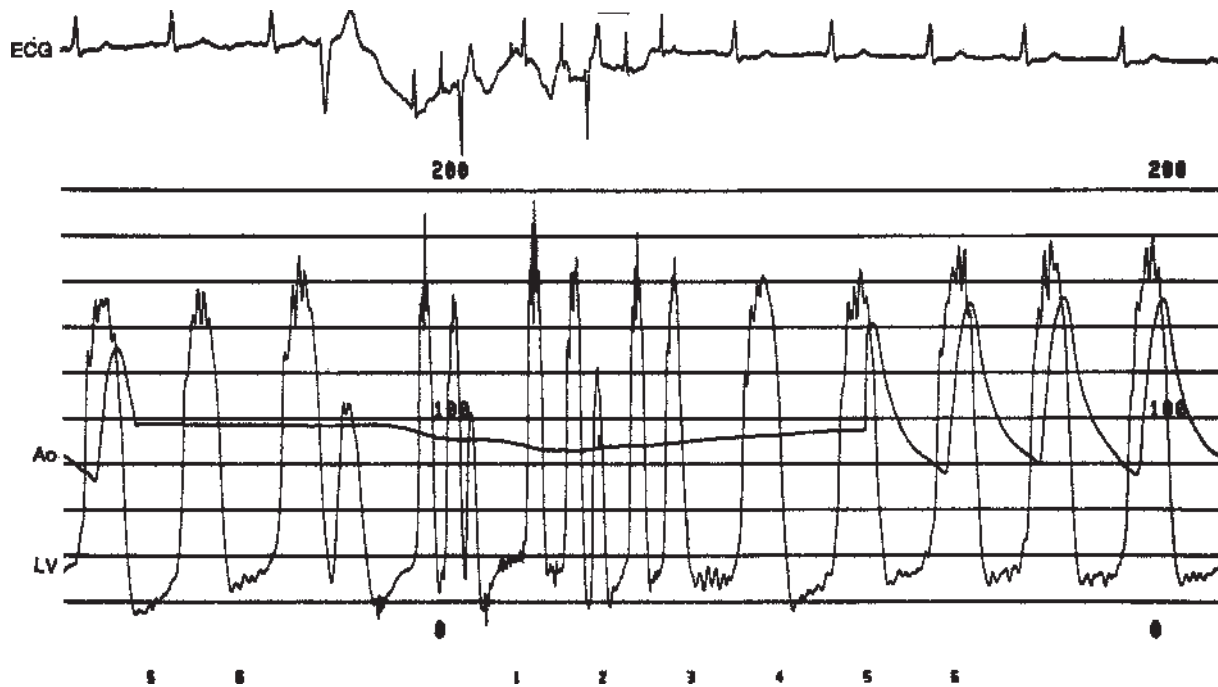


Fig. 1.3. Left ventricular (LV) and aortic (Ao) pressures in a patient with mild aortic stenosis. What is the left ventricular pressure and heart rate? See text for details.

during recording (Figure I.4). On some recorders this switch is next to the dial controlling the number of pressure lines displayed and the event marker button. This rarely occurs with modern recorders where a slip of the technician's finger could change pressure data. Note that the aortic pressure is artificially higher when the pressure scale is shifted downward. We know that aortic pressure is not truly different because of the unchanged zero base starting and ending points (arrows).

A final comment on the time lines is that physiologic recorders provide options whether the vertical lines should be only at the edges, top, bottom, or fully across the page (Figure I.5A). Use of the full-page lines is preferable as timing markers for hemodynamic events in

our laboratory. Partial-page time lines make confirmation of waveform events more difficult and possibly erroneous to the imprecise observer. The selection of interval markers (e.g., one line every 1 sec) for clinical purposes is usually standard. Use of more frequent markers (e.g., one line every 0.04 sec) is helpful for research studies or high-speed recordings to measure hemodynamic events (Figure I.5B).

#### A TRANSIENTLY WIDE PULSE PRESSURE: EPISODIC AORTIC INSUFFICIENCY?

A continuous hemodynamic tracing was recorded during 7 F left ventricular catheter pullback after ventriculography

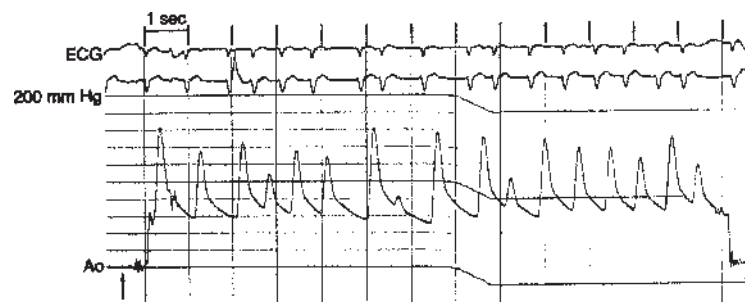
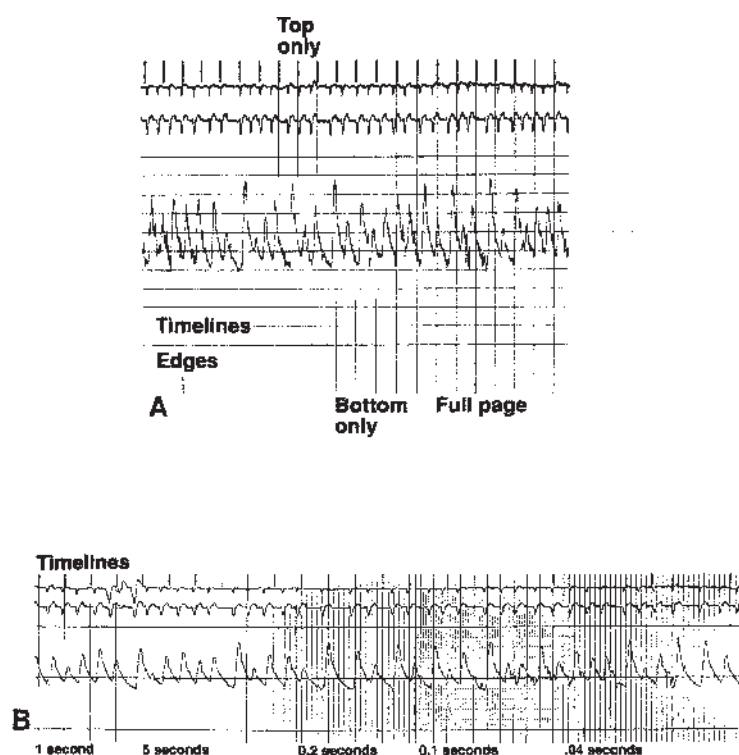


Fig. 1.4. Aortic (Ao) pressure recording. Pressure at left side is 140/60 mm Hg; Pressure at right side is 160/85 mm Hg. Why? See text for details.



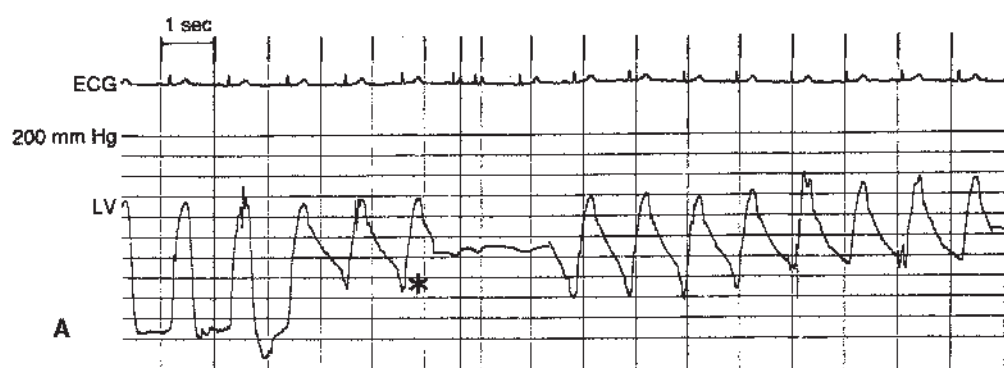
**Fig. 1.5.** A: Demonstration of time line presentations on recording paper. Time lines (left to right) are at edges only, top only, bottom only, and full page. Hemodynamic events are most easily timed with full-page lines. B: Demonstration of time-line interval spacing. Five full-page lines occur between dark divisions of 0.2-, 0.1-, and 0.04-sec intervals.

(Figure I.6A). The pullback was easily and smoothly, but slowly, performed. The operator noted a wide pulse pressure that appeared to diminish over the next several beats. Should the operator reload for aortography to demonstrate transient aortic insufficiency? To a new student of hemodynamics, this mystifying physiology of waxing aortic insufficiency might require more study. However, a slow pigtail catheter pullback from the left ventricle might be incomplete, leaving a portion of the uncoiled pigtail in the left ventricle with several side holes still transmitting the lower left ventricular diastolic pressure falsely reducing aortic diastolic pressure. This phenomenon is demonstrated again with simultaneous femoral arterial and pigtail catheter pressures (Figure I.6B,C). The changing diastolic pressure is due to catheter movement with a different number of pigtail catheter side holes moving across the aortic valve.

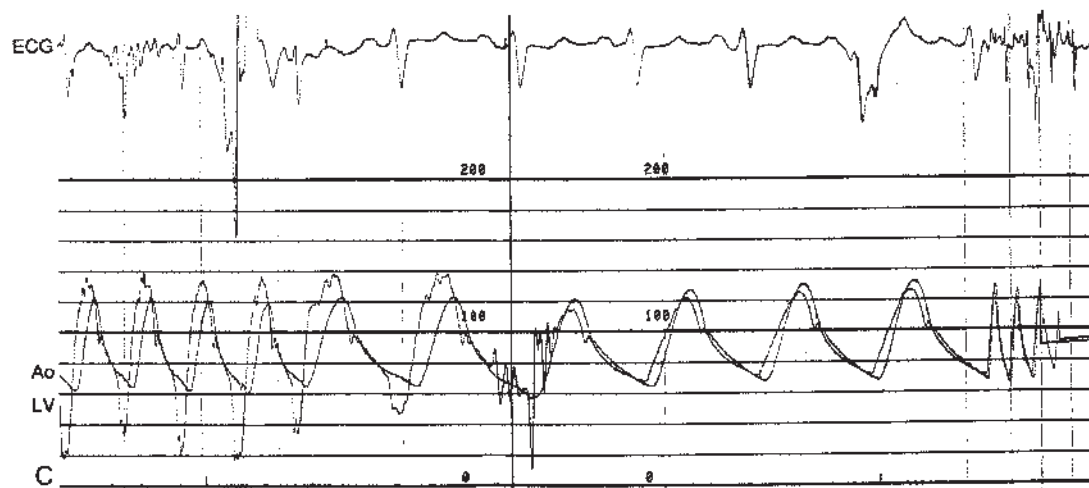
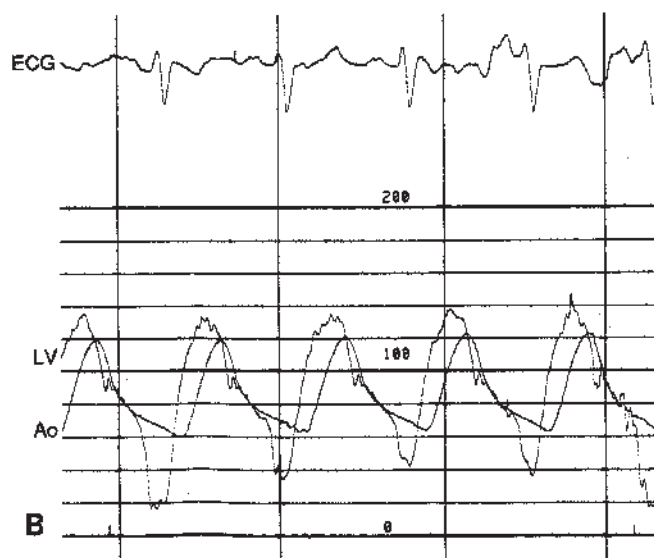
With complete catheter removal, two systemic pressures match without the diastolic pressure artifact (Figure I.6C, right side). This artifact can be easily recognized by the unusual diastolic waveform with a late diastolic shoulder and rapid dip, differentiating it from a wide pulse pressure of valvular insufficiency.

#### CAUSES OF DELAYED OR LATE RISING CENTRAL AORTIC PRESSURE

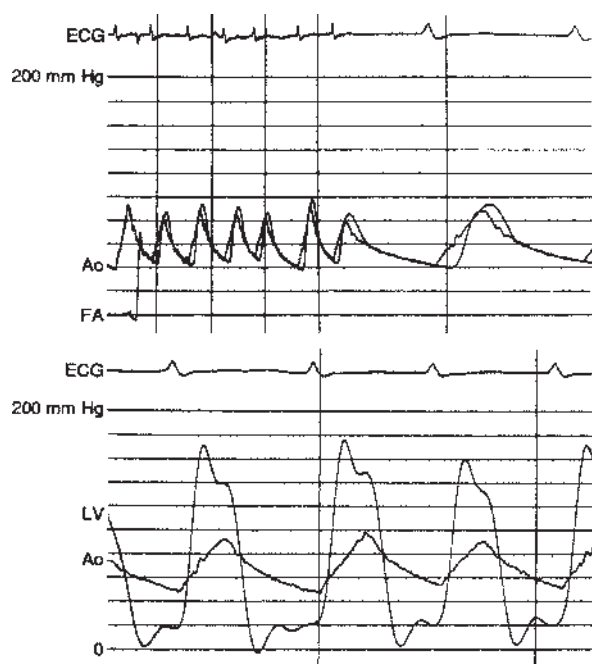
The most proximally measured aortic pressure wave rises before the pressure waves measured more distally. This constant physiologic requirement may be disturbed only by pressure waveform artifacts. Consider the hemodynamic data obtained in a 72-year-old man with aortic stenosis (Figure I.7). Because of mild peripheral vascular disease, simultaneous pressures were initially obtained with a 6 F femoral arterial sheath and a 5 F pigtail catheter with fluid-filled transducers. The pressures measured before crossing the aortic valve demonstrated a good correspondence with two notable features: (a) a slightly reduced femoral pressure overshoot consistent with mild peripheral vascular disease and (b) a slow central aortic pressure upstroke consistent with aortic stenosis. These pressure waveforms are acceptable for routine clinical use. Crossing the heavily calcified valve in the enlarged aortic root was accomplished with the pigtail catheter and a 0.038-in. straight guide wire as previously described [3]. Mild difficulty in advancing the pigtail catheter over the valve and into the left ventricle was encountered.



**Pigtail Catheter Pullback**



**Fig. 1.6. A:** Left ventricular (LV) catheter pullback with transient aortic insufficiency. Note unusual diastolic waveform. See text for details. **B,C:** Left ventricular (LV) and simultaneous aortic (Ao) pressures. See text for details.



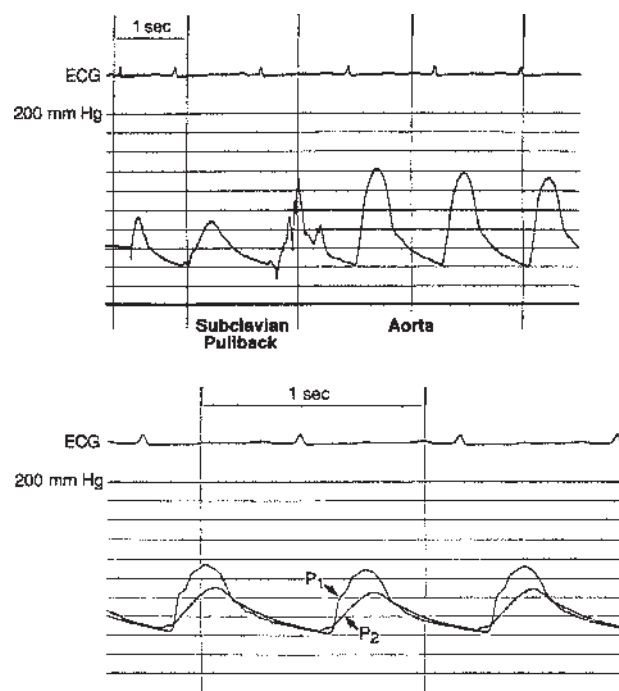
**Fig. 1.7. Top:** Central and femoral (FA) pressures. **Bottom:** Left ventricular (LV) and aortic (Ao) pressures in a patient with aortic stenosis. Note delay and unusual waveform in left ventricular pressure. Explain. See text for details.

Examine the simultaneous left ventricular and aortic pressures (Figure I.7, lower panel). Why does left ventricular pressure rise after aortic pressure? The left ventricular pressure is overly damped with a rounded contour. A delay in pressure transmission is caused by an LV catheter kink in crossing the valve which could not be eliminated by vigorous flushing. Pressure over-damping can be caused by inadequate flushing, leaving an air bubble or blood in the line and thereby reducing the fidelity of pressure transmission. This problem may be exaggerated in small diameter tubes and catheters. Increasing the fluid viscosity with contrast media would also produce the damped and delayed tracing. This artifact was eliminated by changing catheters—in this case, to a 7 F or 8 F sheath with a 6 F or 7 F pigtail. A second arterial puncture or the transseptal approach as discussed elsewhere [4] is an alternative solution. In Figure I.7 (top panel), why is the central aortic (Ao) pressure different from the femoral pressure (FA)? The presence of peripheral vascular disease creates a gradient measurement between the central aortic (Ao) pressure measured by a second small pigtail catheter placed in the ascending aorta and the original femoral artery catheter.

Another example of a late rising proximal aortic pressure is shown in Figure I.8 (lower panel). P1 and P2 are pressure tracings from two fluid-filled catheters

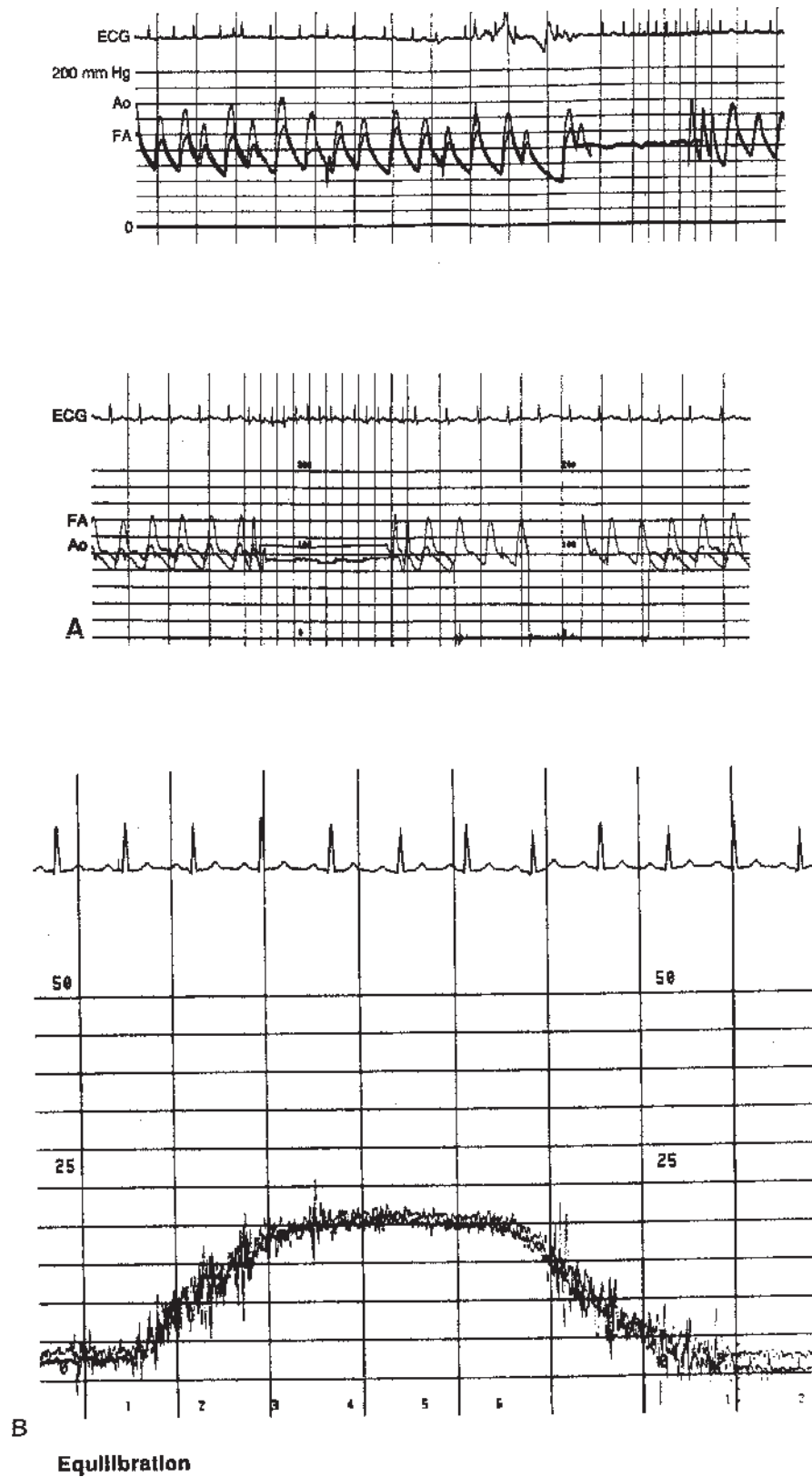
located in the thoracic aorta. P1 has a brisk upstroke with an anacrotic shoulder and dicrotic notch. P2 is an earlier rising tracing with a considerably slower upslope and attenuated resonant waveform characteristics. What conditions produced this pattern, and from which locations are these pressures obtained? P1 is in the descending aorta below the left subclavian artery origin. P2 is inadvertently just beyond the ostial portion of the left subclavian artery, which had a significant narrowing producing a 30–40 mm Hg systolic gradient, slow upstroke, and loss of the anacrotic shoulder and dicrotic notch. On pullback from the subclavian artery to the aorta, the systolic gradient and changing waveform are evident (Figure I.8, upper panel). Subclavian stenosis and coarctation are the two conditions that can cause this pressure with catheters in the central aorta.

In the consideration of aortic coarctation (Figure I.9 top panel), one pressure waveform should be delayed with a slightly slower upstroke, but this pressure waveform will occur with the most distal pressure (e.g., not with P<sub>2</sub> but with P<sub>1</sub>) because the delay in pulse transmission usually occurs in the aorta below the subclavian take-off narrowing, not as above in the subclavian artery as shown on Figure I.8.



**Fig. 1.8. Upper panel:** Catheter pullback from subclavian artery to aorta. Note gradient and waveform change. **Lower panel:** Two central aortic pressures. P1 is in the aorta at the level of the left subclavian origin. Where is P2? See text for details.





**Fig. 1.9.** **A:** Unmatched central (Ao) and femoral (FA) arterial pressures despite matched zero points. Why? See text for details. **B:** Demonstration of equisensitivity and calibration of three fluid-filled transducers.

## DISEQUILIBRATION

Differences in transducer signal response to the same pressure can cause false readings, artifactual gradients, and erroneous clinical decisions. Precision in measurement requires equisensitive amplifier settings and matched transducer gain settings. Matching of peripheral with central aortic pressure to assess the aortic valve gradient requires properly flushed transducers with equisensitive pressure responses. Although most transducers are highly reliable, an occasionally defective product or loose connection may produce a disparity in pressures expected to be equivalent. Examine the femoral artery sheath and central aortic pressures in Figure I.9A. The pressure differences were not attributable to a loose pressure connection, overdamped or unflushed tubing, or unmatched amplifier settings. The aortic pressure transducer was faulty and subsequently replaced, permitting matching of the pressures similar to that shown in Figure I.7. One way to quickly check equisensitivity of pressure transducers is shown on Figure I.9B. Hold all manifolds (in this example, three manifolds are connected to three transducers) at the same level, and then raise and lower the manifolds together while observing the equivalency of pressure responses. A separation of one of the transducer tracings indicates a faulty calibration or defective transducer.

Pressure waveform artifacts are produced by mechanical (tubing, connections, stopcocks, catheters), electrical (amplifier settings, loose cable fittings), or technician-induced (recording without proper pressure or time lines or paper speed, or scale) artifacts. Recognition of these

artifacts will save time and prevent hemodynamic data misinterpretation.

### Key Points

1. The most common pressure wave artifact of a fluid-filled system is exaggerated “ringing” of underdamping.
2. Recording artifacts such as mislabeled pressure scale and unlabeled time lines can affect data quality.
3. Slow pigtail catheter pullback (leaving side holes in LV) from the left ventricle can falsely reduce aortic diastolic pressure.

## REFERENCES

1. Lambert CR, Pepine CJ, Nichols WW. Pressure measurements. In: Pepine CJ (ed.), *Diagnostic and Therapeutic Cardiac Catheterization*. Baltimore: Williams & Wilkins, 1989, pp. 283–293.
2. Nichols WW, O'Rourke MF (eds.). Measuring principles of arterial waves In: *McDonald's Blood Flow in Arteries: Theoretical, Experimental and Clinical Practices*, 3rd ed. Philadelphia: Lea & Febiger, 1990, pp. 143–161.
3. Kern MJ. Catheter selection for the stenotic aortic valve. *Cathet Cardiovasc Diagn* 17:190–191, 1989.
4. Kern MI, Deligonul U. Hemodynamic rounds: Interpretation of cardiac pathophysiology from pressure waveform analysis. I. The stenotic aortic valve. *Cathet Cardiovasc Diagn* 21:112–120, 1990.