

CHAPTER 1

Examination of the Ear, Nose and Throat

Harold Ludman¹ and Patrick J. Bradley²

¹King's College Hospital and National Hospital for Neurology and Neurosurgery, London, UK

²Nottingham University Hospitals, Queen's Medical Centre Campus, Nottingham, UK

OVERVIEW

- Taking a history of the symptoms, followed by inspection, palpation and site specific examination of the ENT should be performed in its entirety when a patient first presents with an ENT complaint
- The ability for the non-specialist to perform such an examination is limited because of lack of appropriate equipment and clinical expertise
- Examination of each site; ear, nose, mouth and neck when examined by the non-specialist should be performed in a repetitive systematic manner and the positive findings recorded, thus ensuring that should a patient present at a later time the previous findings can be reviewed in the light of any new findings
- The specialist examination and investigation is the only *definitive* current method to ensure a definitive correct diagnosis can be made thus resulting in a correct and appropriate patient management

Examination

Equipment necessary

- *For the ear* – an otoscope (auriscope), comprising a handle, with battery power, light source and cone specula of various sizes and low-level magnification lens; a tuning fork vibrating at 512 kHz (lower frequencies excite vibration sense and higher ones decay too rapidly) (Figure 1.1).
- *For the nose* – Thudichum's or Killian's nasal speculae.
- *For the mouth and oropharynx* – Lack's tongue depressors, or spatulae (not as good, because the hand blocks the view and there is a lack of leverage)
- *For the neck* – a systematic plan is described below.
- *For all* – Good lighting; ideally from a headlight, or heard mirror and light source (Figure 1.1).
- *The larynx, pharynx (nasopharynx [or postnasal space], oropharynx and hypopharynx)* – essential parts of the specialty (Figure 1.2)

ABC of Ear, Nose and Throat, Sixth Edition.
 Edited by Harold Ludman and Patrick J. Bradley.
 © 2013 John Wiley & Sons, Ltd. Published 2013 by John Wiley & Sons, Ltd.

require specialist equipment, which is described in the relevant chapters.

Normal ear anatomy

The external auditory canal

The external auditory canal is 2.5 cm long in adults, extending to the tympanic membrane. The outer one-third passes through elastic




Figure 1.1 Equipment necessary for examination of the ear.

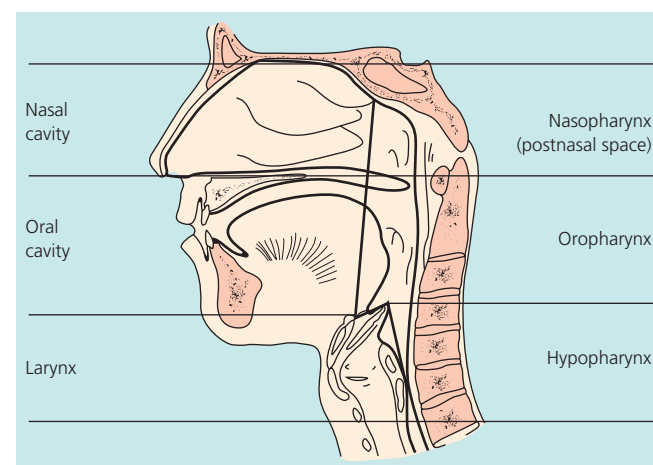


Figure 1.2 Diagram of the anatomical mucosal areas of the head and neck.

cartilage, with hair bearing skin, the inner third is through bone, with no hair and much thinner skin, adherent to the periosteum. The canal is S-shaped and must be straightened by pulling the pinna upward and backward in the adult (straight back in the child) for a better view of the tympanic membrane. The tympanic membrane lies at an angle to the canal, facing forwards and downwards, with an antero-inferior recess, where debris or foreign bodies may collect.

The tympanic membrane (TM or drumhead)

The tympanic membrane consists of a lower pars tensa and an upper pars flaccida, hiding the attic of the middle ear (Figure 1.3). The malleus handle lies in the middle layer of the pars tensa. Its handle runs downwards and backwards from a lateral process – the

most easily recognisable structure of the drumhead at its tip (called the umbo), which is in the centre of the pars tensa. From there a cone of light – the light reflex extends antero-inferiorly.

Examination of the ear

Inspection

Compare the pinnae for symmetry.

- Examine the face for evidence of muscle weakness, as in a cranial nerve examination.
- Seek scars, from surgical or other trauma, skin inflammation, swellings, pits or sinuses around the pinna. Scars from previous surgery may be difficult to find.

Palpation

- Feel the mastoid tip, mastoid bone, the pinna itself, and also the parotid and temporomandibular joint area. Pressure on the mastoid tip and the region above and behind it must allow for any pain and tenderness of which the patient complains.

Otoscopy (with auriscope)

Choose a speculum appropriate for the patient's canal. Hold the otoscope with the hand of the same side as the ear to be examined. The otoscope should be held braced against the subject's cheek to avoid injury if the patient suddenly moves. The otoscope should be held with a 'pencil or pen grip' (as if writing), with the little finger gently touching the face, to protect against accidental over-insertion. A 'hammer' hold of the instrument is wrong (Figure 1.4a and b).

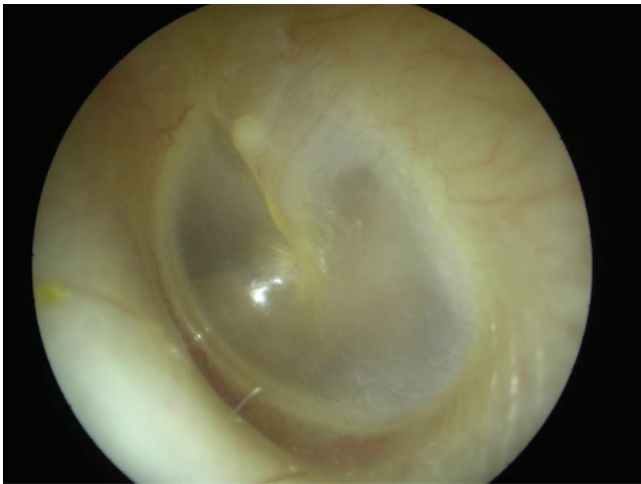
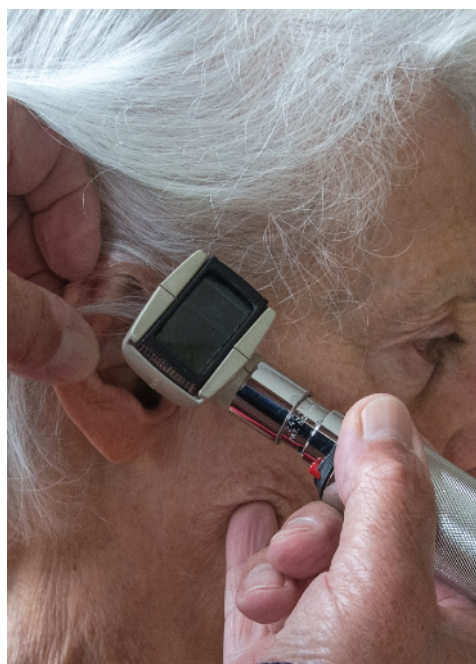
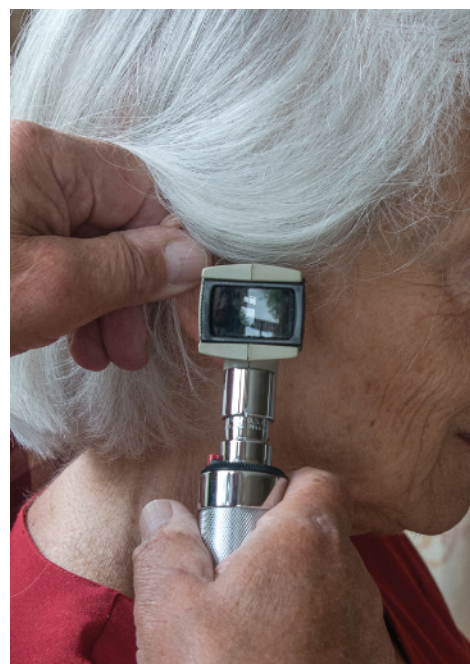Figure 1.3 The normal tympanic membrane.



(a)



(b)

Figure 1.4 Use of an otoscope: (a) correct; (b) incorrect.

The meatus and then the tympanic membrane should be inspected systematically, with attention to all the pars tensa and the pars flaccida, which may be obscured by a crust. Most importantly, obstruction of view of the pars flaccida.

A sketch of the tympanic membrane showing any observed abnormalities is very useful.

Hearing tests

- Speech material can be used in a quiet room as a Free Field Speech Test (FFST).
- Use conversational material and so-called 'spondee' two-syllable words.
- Tuning fork tests in the non-specialist clinic include: the Rinne test and the Weber's test, which usually allow differentiation between conductive and sensorineural hearing loss.
- Pure tone audiometry and tympanometry.

Rinne test – The fork is set vibrating quietly and held adjacent to the external ear canal and then, after a few seconds, the base of the tuning fork is moved and held against the mastoid bone behind ear. The patient has been asked whether he or she can hear the sound in each position and whether it is perceived to be louder at the side of the ear canal or when placed on the mastoid bone behind the ear. A positive Rinne test result indicates that the patient heard the sound louder through the ear canal than through the mastoid bone (air conduction > bone conduction). This positive result is found if the patient has normal hearing in the test ear, or a sensorineural loss. If the patient perceives the ringing to be louder by bone conduction than through the ear canal, drum and ossicles, then there must be a fault in the conducting mechanism. In a conductive hearing loss, the Rinne test is negative (bone conduction > air conduction) (Figure 1.5). Watch out for the so-called 'false negative' Rinne test. If the patient has a very severe sensorineural deafness in one ear only, when the vibrating tuning fork is placed on the mastoid process of that side, the sound waves are transmitted through the bones of the skull to the other cochlea. The patient hears this, so that bone conduction seems louder than air conduction (which was not heard at all). This negative Rinne test does *not* indicate a conductive deafness on the side of the tested ear but is a false negative due to the totally deaf ear on that side.

Weber's test – Use a vibrating 512 kHz tuning fork placed firmly in the midline of the forehead to localise the side of the sound (see Chapter 8) (Figure 1.6). If the Weber's test is not lateralised, it indicates normal hearing or a symmetrically equal sensorineural loss. If it is lateralised to the ear with better hearing, a sensorineural loss is suggested. Lateralisation to the ear with worse hearing indicates a conductive, mechanical loss.

Tests with pure tones – To produce a **pure tone audiogram (PTA)**, for sound conducted through air and bone, require specialist facilities using an audiometer in a soundproofed room. The PTA plots the threshold of hearing at frequencies from 125 Hz to 8 kHz against the amplification in decibels needed for audibility. Air-conducted pure tones (sine waves)

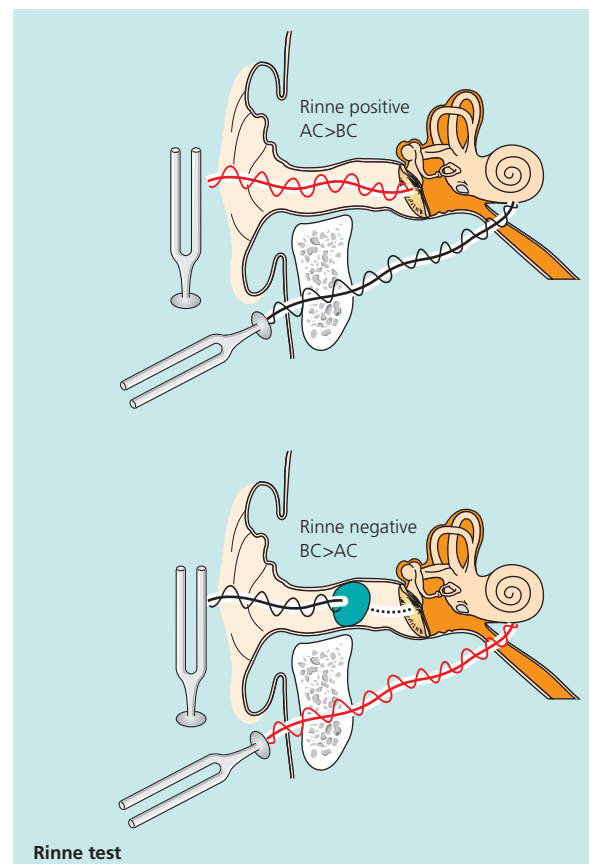


Figure 1.5 Rinne test.

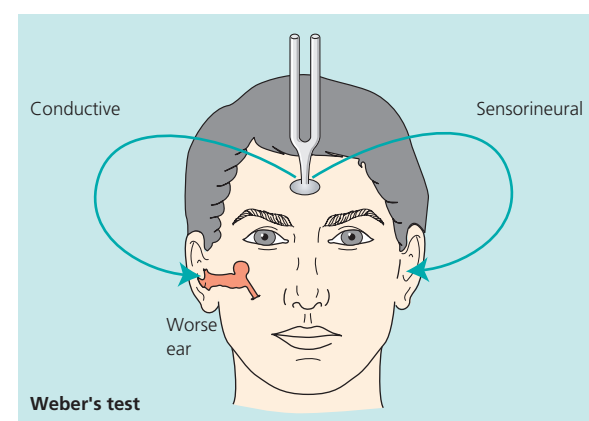


Figure 1.6 Weber's test.

are delivered through headphones. Bone-conducted sound is presented through a transducer held tightly against bone behind the pinna with a spring headband, while a suitable 'masking' noise is delivered to the opposite ear, to protect it from skull-transmitted signals. The audiograms obtained enable the assessment of the severity of hearing loss in each ear, and what proportion of the loss is conductive or sensorineural (Figure 1.7). Specialist texts are available that describe audiometric testing in detail.

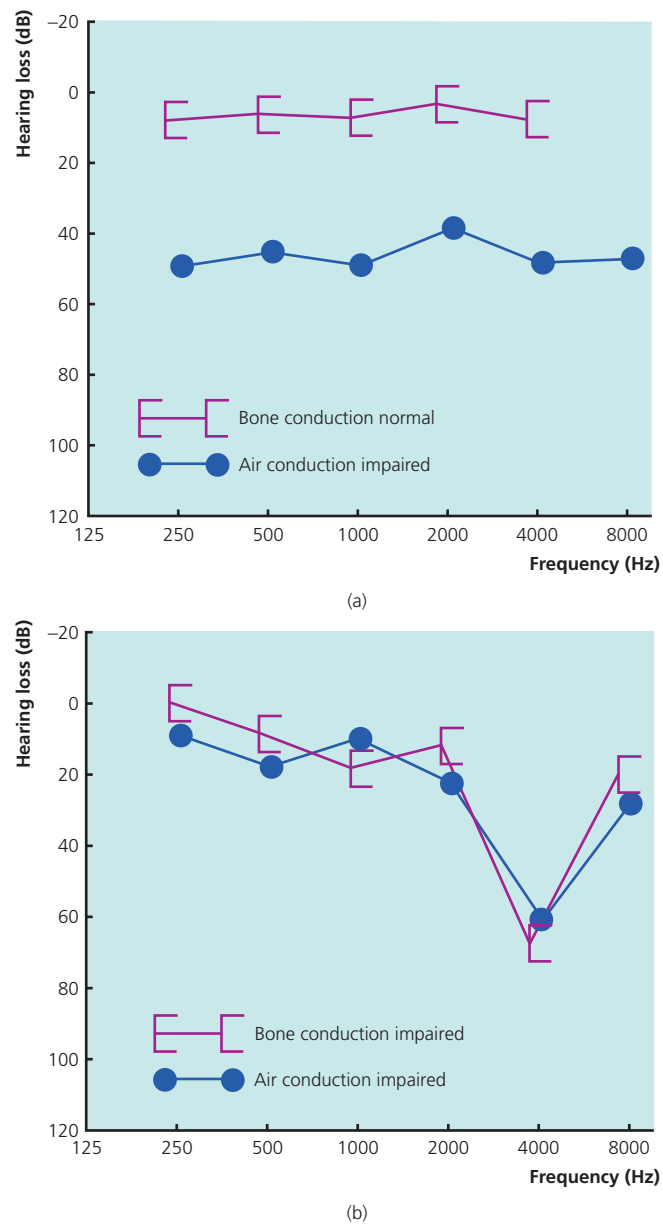


Figure 1.7 Audiograms. a) Upper shows conductive hearing loss, and b) lower sensorineural loss from noise damage.

Tympanometry

The measurement of the 'impedance' of the middle ear to conducted sound is fully described in Chapter 5.

This process can be automated by a 'tympanometer', for use in non-specialist clinics to offer a quick, *but often unreliable* suggestion of middle ear fluid – as in 'glue ear'.

Examination of the nose

Inspection

Look at the nose from the front, from either side and from above and below (see Figure 15.3).

Evaluate the size of each nostril and the nasal septum. Airway patency can be tested by placing a cold Lack's depressor underneath and asking the patient to exhale (Figure 1.8).

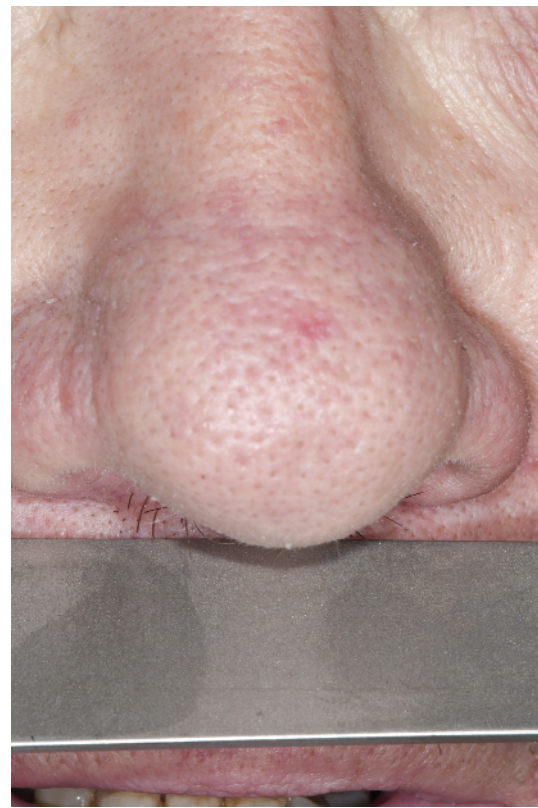

Figure 1.8 Test of nasal patency using a Lack's spatula.

Inspect the nasal cavity using an otoscope or a nasal speculum (Figure 1.9a and b) commenting on the nasal septum, the floor of the nose and the laterally placed turbinate. (If in doubt, a nasal polyp is insensitive to touch!)

Examination of the mouth

Inspection

Examine the vermillion borders of the lips.

Using a light source, preferably head mounted, ask the patient to open their mouth and protrude their tongue. Observe the width of the opening, which should be more than 2 cm allowing a two-handed examination using two Lack's tongue depressors; move the tissues about and inspect the mouth contents.

The contents should be inspected using a systematic plan. Commence superiorly with the hard and soft palate, tonsils and upper teeth, followed by the lateral mouth (the buccal mucosa), and then inferiorly with the tongue, floor of the mouth (Figure 1.10), lower teeth and lower lateral buccal area.

In a normal adult there are 32 teeth (4 'wisdom' teeth, 8 molars, 8 premolars, 4 canines and 8 incisors). When their teeth are fully erupted, children should have 20 primary teeth, which will all be replaced by permanent teeth during childhood and teens. Teeth present, absent, broken and carious should be noted and recorded.

Palpation

Palpation of the mouth floor should be bimanually from within and without, allowing the submandibular glands and the mucosa

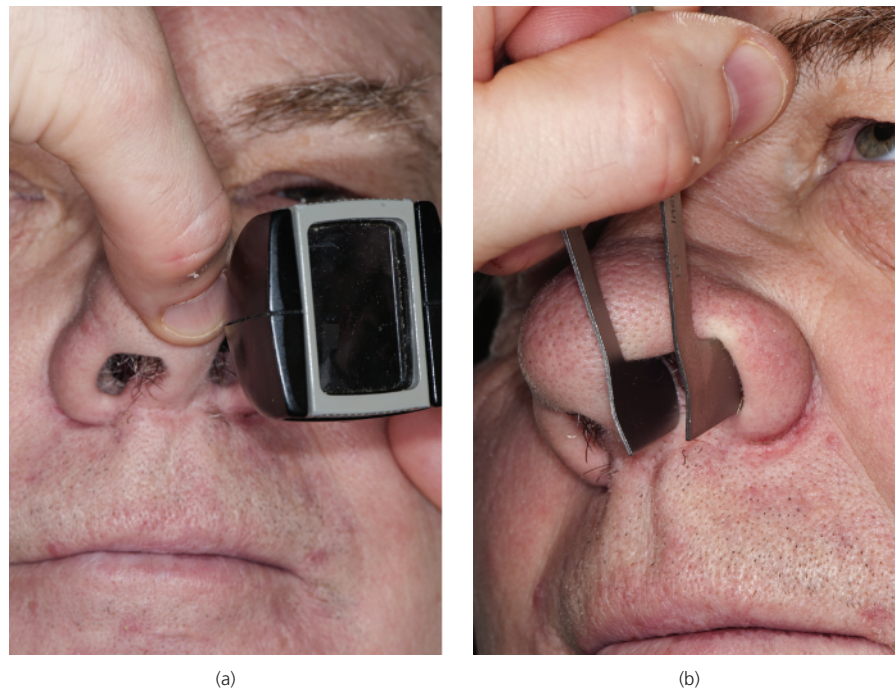


Figure 1.9 Inspection of the nasal cavity using: (a) an otoscope; (b) Thudicum's speculum.

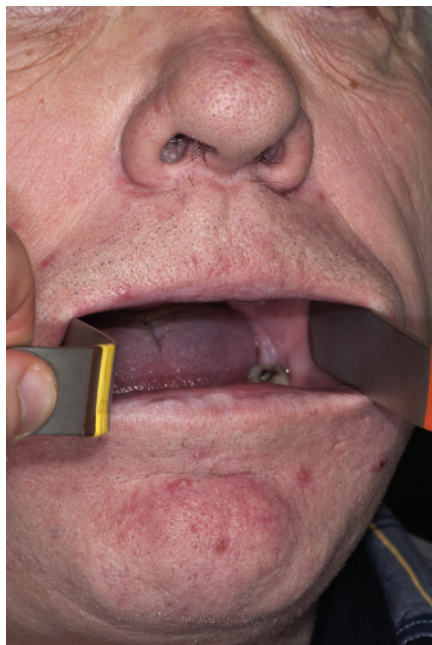

Figure 1.10 Inspection of the mouth.

to be checked for thickening or other abnormalities, such as stones, cysts or ulcers that might suggest early cancer (Figure 1.11).

Examination of the neck

Inspection

The neck must be fully exposed from the chin above to below the level of the 'collar bones'.

Look for any swellings, skin lesions, skin discolouration, scars, etc.

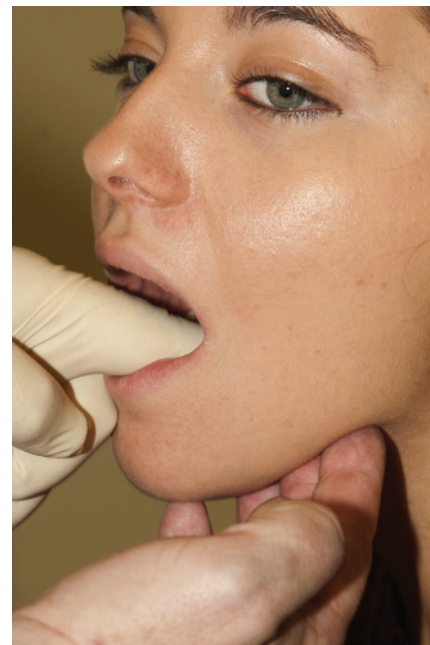

Figure 1.11 Bimanual palpation of floor of mouth and submandibular gland.

Then ask the patient to identify the lump, swelling, fullness or soreness.

Any confirmed lump or lumps must be evaluated systematically by noting size, site, shape, skin (scars and colour), surface and margin, pulsation (if pulsatile, whether it is transmitted pulsation) and cross fluctuation.

Palpation

Several normal structures can be felt in the neck. In women, the cricoid cartilage is often obvious, while in men, the thyroid cartilage

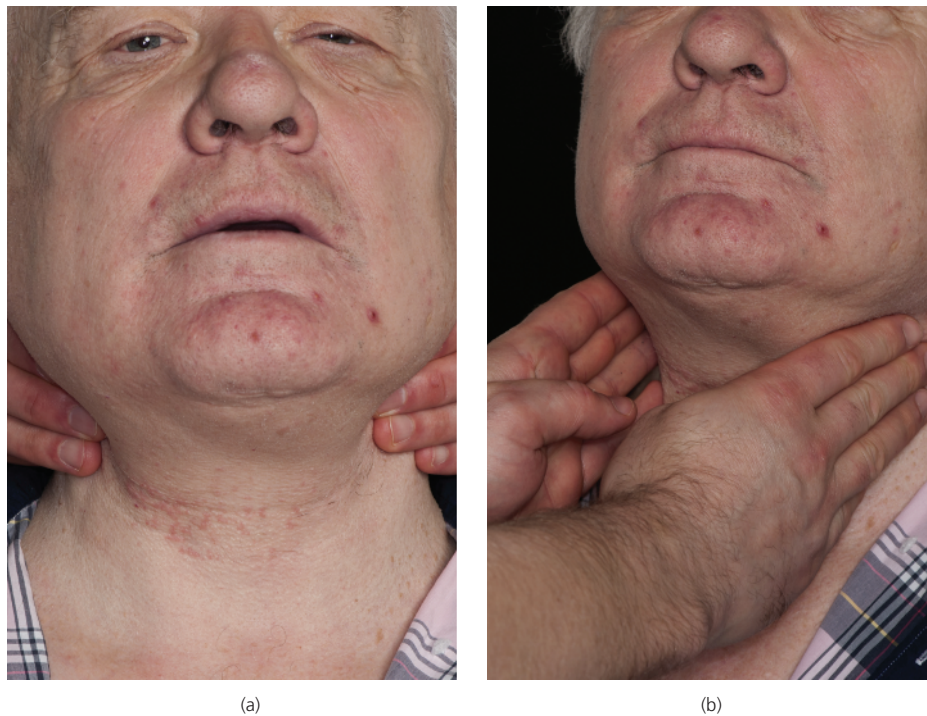

Figure 1.12 Examination of the neck: (a) correct from behind; (b) incorrect from in front.

is easily seen. The mastoid tip is readily felt behind the ear. Between the mastoid tip and the angle of the mandible, the transverse process of the C1 vertebra is sometimes palpable, especially in underweight females. The carotid bulb or bifurcation can also be felt pulsating at about the level of the hyoid bone, just beneath the sternocleidomastoid (SCM) muscle, and it can be mistaken for a mass.

The neck should be felt from behind, so that both sides can be compared (Figure 1.12a and b).

If the patient has an obvious swelling, or can point to one, then start there. Any lump should be recorded as: single or multiple, discrete or diffuse, and within a more specific list: surface, edge, temperature, consistency, fluctuation, compressibility, reducibility, pulsatility and fixation. Performing auscultation using a stethoscope may reveal a vascular bruit, but this must be done in quiet surroundings. Movement of a midline lump on the patient sticking out or the physician protruding the tongue will confirm whether the lesion is adherent to the trachea.

A systematic method for examining the neck is essential to avoid missing some areas which may later become important (Figure 1.13).

Begin at the submental area, moving along to the submandibular area. Then move from the lower pole of the parotid gland up onto the lateral parotid tissue lying on the body of the mandible up to the zygomatic arch. Onwards posteriorly to the mastoid tip, behind the ear and finally, complete the upper neck examination to include the occipital area and the cervical spine.

My practice (PJB), is to palpate the cervical spinal area down to the upper thoracic spines, extending palpation to feel the whole of the posterior triangle – tissue between the anterior border

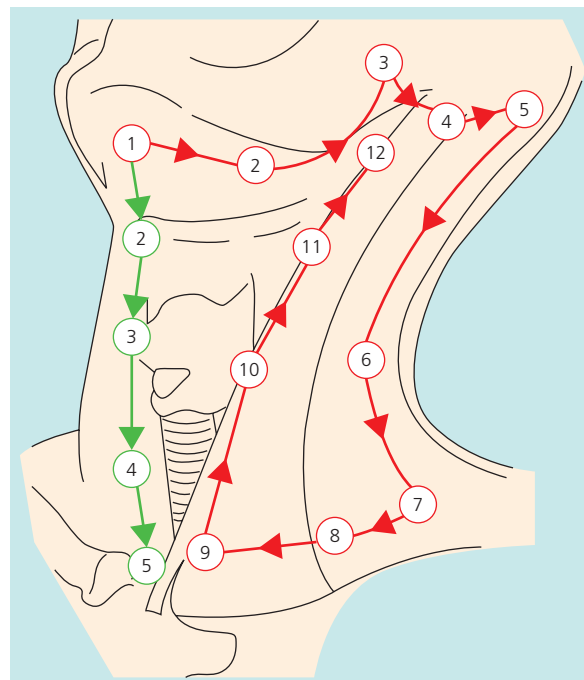


Figure 1.13 Diagram of a suggested palpation examination of the neck.

of the trapezius and the posterior border of the SCM muscle (see Figure 23.2). Palpating the supraclavicular area (from the acromioclavicular joint to the sternoclavicular joint) is followed by lateral neck palpation moving from below upwards along the anterior border of the SCM muscle to the mastoid tip.

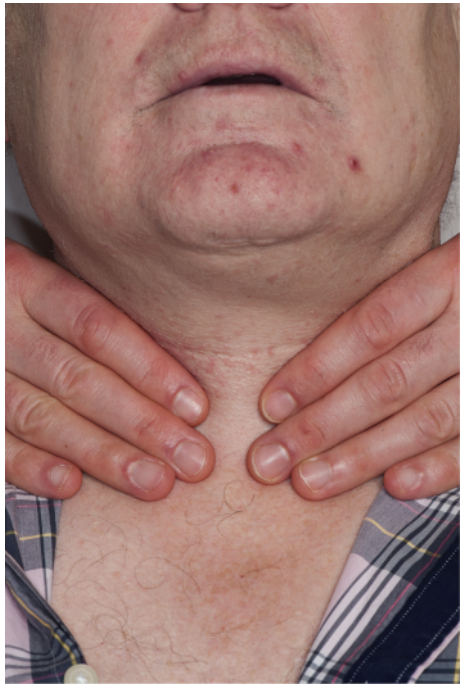

Figure 1.14 Examination of the midline of the neck.

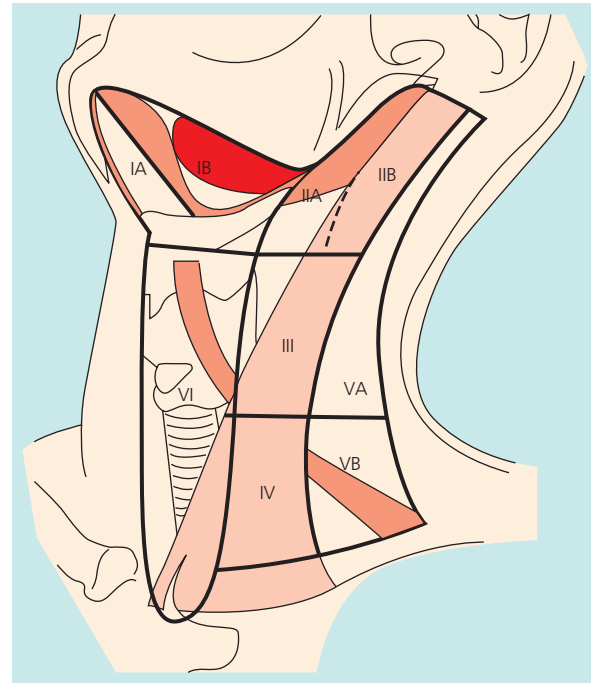


Figure 1.15 Diagram of the six divisions of the neck.

Relaxation of the SCM muscle allows one to feel deeply underneath with confidence.

The neck examination ends in the midline of the neck, from the submental area, to the hyoid, thyroid, cricoid, thyroid gland, trachea and inferiorly the sternal notch (Figure 1.14).

If a second palpation is needed, the clinician should return to that area or organ and examine that site specifically – say sub-mandibular or parotid gland, as well as the thyroid gland. The identification of a ‘neck lump’ in an adult may suggest a mucosal site for a potential primary malignancy. Surgical oncologists divide the neck into six regions in the neck, with three areas having subregions (Figure 1.15). The region IIA is the most frequent site presenting in clinical practice and the differential diagnosis most frequently requires a needle biopsy and a CT scan to make a firm diagnosis.

Neck examination is a supplementary examination of the throat (see earlier). In non-specialist environments, examination of the pharynx and larynx is limited, and *reliance must be placed and acted upon from symptoms*. ‘Guestimation’ of the seriousness of a likely cause based on symptoms alone relating to breathing, hoarseness and swallowing are statistically more likely to have a benign diagnosis than a malignancy. But the specialist examination and investigation is the only *definitive* current method to ensure a definitive correct diagnosis resulting in correct and appropriate management.

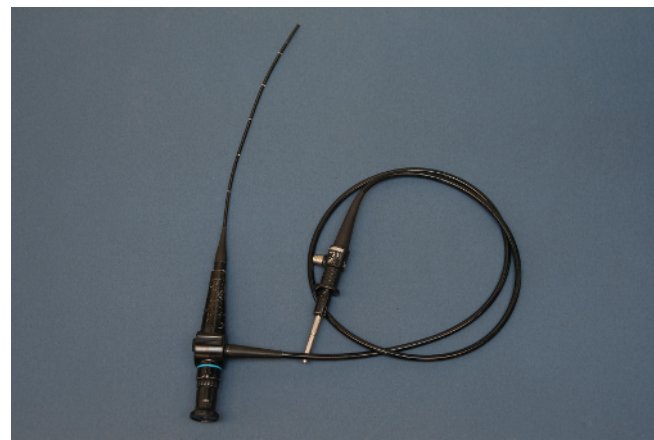

Figure 1.16 Nasendoscope used in specialist clinic to examine the pharynx and larynx.

Nasendoscopy

Examination of the nose, pharynx and larynx can be achieved without much discomfort in the majority of patients, even children, with a flexible fibre-optic instrument (Figure 1.16). It is also possible to perform more extensive evaluation of the trachea and bronchi, and oesophogscopy with a mild sedative and topical anaesthesia (see Figure 20.3).