

PART **1**

Principles

COPYRIGHTED MATERIAL

Basic Concepts in Neuropsychiatry

Anthony S. David

Institute of Psychiatry, King's College, London

What is neuropsychiatry?

In most psychiatric illnesses the clinical picture is profoundly coloured and sometimes decisively shaped by factors specific to the individual and his environment. Hence the notorious difficulty in identifying separate disease processes in psychiatry. This is compounded still further, where most mental disorders are concerned, by the lack of collateral evidence by means of tissue pathology. Alwyn Lishman used the term 'organic psychiatry' to describe those disorders 'in which there is a high probability that appropriate examination and investigation will uncover some cerebral or systemic pathology responsible for, or contributing to, the mental condition'. He contrasted this with the term 'neuropsychiatry', which he took to be a more specific discipline at the interface between neurology and psychiatry, concerned with disorders that can be demonstrated to owe their origins 'to brain malfunction of a clearly identifiable nature' and thus not including endocrine, toxic and metabolic disorders. While these disorders operate via disturbances in brain function, they are, according to Lishman, the concern of general medicine rather than neurology. Despite the clarity and merits of this distinction, 'neuropsychiatry' has become the more widely used term and is generally not used in its more restrictive sense. It is used here synonymously with organic psychiatry but broader still to include those conditions that might appear at first sight to be caused by pathology of the nervous system with manifestations in the neurological domain, but which turn out not to be so; in fact psychological and social factors predominate in the clinical formulation – in other words, the so-called conversion disorders. Inclusion of such disorders may be justified on pragmatic grounds since they contribute to a sizeable proportion of the workload of the neuropsychiatrist and related health professional. Further, the differential diagnosis of conversion is, by definition, neurological; likewise, conversion dis-

orders contribute to the differential diagnoses of most neuropsychiatric conditions.

Before leaving the issue of definitions, it is worth reiterating here two other aspects dealt with by Alwyn Lishman in his preface to the second and third editions of his textbook. First, we wholly subscribe to Lishman's injunction that neuropsychiatry 'must capitalise on all that psychiatry has to offer' including psychodynamic, social and cultural aspects, and that 'neuropsychiatric practice requires a widening not a narrowing of psychiatric skills and interests'. Second, neuropsychiatry does not claim to be the only branch of psychiatry where the brain and other biological systems are relevant, far from it. The term 'biological psychiatry' is rightly reserved for the approach (rather than the clinical discipline) concerned with 'pathophysiologies of a biological nature' which can be brought to bear on increasingly numerous if not all forms of psychiatric disorder to varying extents.

The psychological disturbances which result from brain pathology often share common ground that cuts across differences in background, personality and social situation. They are related to pathological processes within the brain, or acting on the brain, which can often be identified by the techniques of medical investigation. In these respects neuropsychiatry draws closer to the rest of medicine, and should at least in theory be amenable to a similar approach in leading towards useful clinicopathological correlations.

In large measure this is so. However, psychological symptoms are hard to identify objectively and can rarely be measured accurately. Difficulties of assessment increase abruptly as we ascend from basic motor and sensory processes to mental phenomena, and especially when we move from simple cognitive impairments to changes in emotion, personality and other complex aspects of behaviour. Moreover, when symptoms characteristic of the neuroses or major psychoses emerge in the brain-damaged person, it is necessary to consider the possibility that he may have been specially

predisposed to their development. Ultimately, indeed, we are often forced back again to the problems of the main body of psychiatry, since the more complex effects of cerebral disorder can be properly assessed only when the whole individual is viewed in the context of his personal history and environment. The situation is therefore a good deal more complex than in most other branches of medicine, and the opportunities for relating abnormalities of behaviour to precise aspects of cerebral pathology are limited in several important respects.

Fortunately for the diagnostic process, neuropsychiatric disorders tend to have certain features in common that usually allow them to be distinguished from non-organic mental illnesses. Different varieties of pathological change are often associated with similar forms of impairment. Bonhoeffer (1909), who coined the term 'exogenous psychoses', deserves the credit for recognising this and discarding the Kraepelinian view that each noxious agent affecting the brain evokes a specific psychiatric picture. Impairment of consciousness, for example, may result from a number of toxic processes acting on the brain or from raised intracranial pressure; dementia may result from anoxia, from trauma or from primary degenerative disease. It is therefore possible to extract important symptoms and syndromes that indicate the possibility of cerebral disorder whatever the basic pathology and despite the colouring lent by pathoplastic features. Such symptoms form the cornerstone of diagnosis in neuropsychiatry and it is essential to recognise their earliest and most minor manifestations. Many disease processes affecting the brain will come to attention with psychological symptoms alone and well before the appearance of definite neurological signs, and it is often by the correct appreciation of these common forms of reaction that a mistaken diagnosis of non-organic (or so-called 'functional') psychiatric disorder will be avoided.

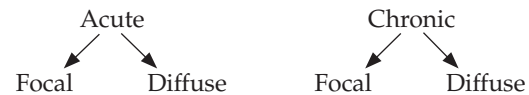
Other forms of presentation may indeed occur with change of personality, affective disturbance, neurotic symptoms or even pictures indicative of schizophrenia. The clinician must remain aware that occasionally a mental illness presenting in this way may be related to the early stages of cerebral disease. Such cases are not infrequent and their detection by judicious application of ever more sensitive and non-invasive investigations such as magnetic resonance imaging increasingly likely; however, as the condition progresses, organic mental symptoms will usually appear.

Basic concepts and terminology

This chapter describes various frameworks for grouping together the cardinal psychological symptoms and signs of cerebral disorder. The principal accent will be on the shared forms of reaction common to most individuals and to different pathological processes, though features particular to individuals are also briefly described where appropriate. The feature that distinguishes neuropsychiatric

disorders from the rest of psychiatry is cognitive impairment.

A main division is the temporal one, i.e. 'acute' and 'chronic' reactions. These terms are clinically useful for broad classification and for shorthand description of groups of clinical phenomena. A topographical distinction, namely 'focal' versus 'generalised' or 'diffuse', can be superimposed on this temporal division, so that both acute and chronic conditions can be focal or diffuse in nature.



Acute versus chronic cerebral disorder

Acute organic reaction and *chronic organic reaction* are the terms best used for the first major division of organic psychiatric illnesses, each functioning as no more than a pointer to a class of problems, and serving only as starting points for further enquiries into aetiology. These terms carry implications for abruptness and onset and to some extent for the constellation of symptoms most in evidence. Each may show features not seen in the other, and requiring specific approaches for their identification. The terms also carry implications for likely duration, but not directly for ultimate prognosis. It is more usual for acute than for chronic organic reactions to recover, but the prognosis in each case will depend on the precise aetiology at work. A separate category of 'subacute organic reactions' is sometimes demarcated, and merely implies less sudden onset than the acute disorders, somewhat longer continuation, and an admixture of clinical symptoms characteristic of acute and chronic reactions. It must be accepted, however, that both acute and chronic reactions will vary in the degree of their acuteness or chronicity, and that in some cases the former will, with time, prove to merge into the latter.

The temporal dimension or time course is one of the most critical indicators in the evaluation of chronic neuropsychiatric conditions. The clinical course of the disorder reveals many clues as to its nature. These may be variously described as progressive, stepwise, relapsing and remitting, etc. A progressive course implies degeneration or the gradual expansion of a space-occupying lesion. A stepwise course classically describes the intermittent but accumulating deficit as a consequence of repeated vascular events. A relapsing and remitting course suggests an inflammatory processes, such as multiple sclerosis, especially where each relapse adds a residuum of impairment or disability. Acute disturbances followed by complete recovery suggest disorders of function such as physiological disruptions to cerebral or neural activity without the enduring stamp of tissue pathology, as occurs with electrical disturbances or transient metabolic upsets or indeed a 'non-organic' aetiology.

Generalised versus focal cerebral disorder

A great number of organic psychiatric disorders are due to widespread disturbance of brain function. This may be the result of diffuse disease processes within the brain, as in certain degenerative diseases, or of systemic disturbances, for example those leading to anoxia which impair brain function indirectly. Moreover, well-localised brain lesions may declare themselves only when secondary diffuse effects supervene, as with raised intracranial pressure in association with cerebral tumour. The majority of acute and chronic organic reactions therefore reflect widespread disorder of cerebral activity and contain symptoms of defective function in many spheres.

It has become customary to talk of 'generalised cerebral disorder' and to distinguish this from the effects of strictly focal pathology. However, it must be appreciated that both generalised and focal disturbances of brain function represent theoretical extremes that are rarely if ever encountered in practice. It is most unlikely that intrinsic brain disease is ever uniformly distributed throughout the brain, and some degree of focal emphasis can usually be discerned with careful observation. Extrinsic factors that impair brain function are likewise selective in their effects, sparing some neural or neurochemical systems while disrupting others. Impairment of consciousness, for example, represents interference with brainstem alerting functions while cardiovascular and respiratory functions are little affected. Similarly, disruption of cortical and subcortical functions very rarely occurs to an equivalent extent.

Strictly focal disorder, on the other hand, is also very rare except when purposely produced by surgical procedures. In naturally occurring disease we merely see a focal emphasis of pathology, which in greater or lesser degree is complicated by the additional effects of damage elsewhere.

Nevertheless it is of great importance in practical clinical terms to preserve the distinction between clinical pictures that result from widely disseminated or from relatively circumscribed brain dysfunction. The distinction is essential in the formulation of likely causes and thence in deciding the lines which investigation must follow. Each, in practice, contains different symptoms of fundamental importance.

The plan in this chapter will be first to describe in broad terms the characteristic clinical pictures seen in 'generalised' acute and chronic reactions, and then to summarise the salient features seen with focal damage or focal emphasis of pathology in specific brain regions. The focal significance of certain symptoms and symptom complexes is dealt with in more detail in Chapter 2.

Commonly used terms

The following are some commonly used terms of general clinical description.

Confusion refers to symptoms and signs which indicate that the patient is unable to think with his customary clarity and coherence. Cognitive impairment is often used nowadays as a portmanteau term in preference to confusion. It is seen in both organic and non-organic mental disturbances, and the term is useful merely as a shorthand clinical description of an important aspect of such mental states. In acute organic reactions, confusion is due largely to impairment of consciousness. In chronic organic reactions, it betrays the disruption of thought processes due to structural brain damage. In a whole range of psychiatric disorders, confusion of thinking may be much in evidence without any identifiable brain pathology whatever; similarly when powerful emotions from any cause interfere with the efficient ordering of cognitive processes. The term 'toxic confusional state' is widely used but can properly be applied only when toxic influences on the brain have been established.

Clouding of consciousness denotes the mildest stage of impairment of consciousness which is detectable clinically, on the continuum from full alertness and awareness to coma. As such it is manifest as slight impairment of thinking, attending, perceiving and remembering, in other words as mild global impairment of cognitive processes in association with reduced awareness of the environment. The patient will frequently, though not always, appear to be drowsy but this is not to be confused with the normal transition to sleep.

Twilight states. Among Bonhoeffer's 'forms of exogenous reaction' due to pathogenic factors acting on the brain, twilight states and delirium were separately demarcated. The essential features appear to include abrupt onset and ending, variable duration from hours to weeks, and the interruption of quiet periods of behaviour by unexpected and sometimes violent acts or outbursts of rage or fear. Other descriptions include dream-like 'oneiroid' states, vivid hallucinations and delusional ideas that dictate powerful affective disturbance. Clearly, therefore, the term is used to cover a variety of syndromes and can now have little useful meaning. It is, moreover, widely employed to describe hysterical manifestations in addition to acute organic reactions (particularly some types of complex partial seizure).

Coma represents the extreme of a graded continuum of impairment of consciousness, at the opposite pole of the spectrum from full alertness and awareness of the environment. The patient is incapable of sensing or responding adequately to external stimuli or inner needs, shows little or no spontaneous movement apart from respiration, and no evidence whatever of mental activity.

Coma is itself a graded phenomenon. At its deepest there is no reaction to stimuli of any intensity, and corneal, pupillary, pharyngeal, tendon and plantar reflexes are absent. Respiration is slow and sometimes periodic (Cheyne-Stokes respiration) and cardiovascular regulating processes may

show signs of failure. Lighter degrees of coma (semicoma) allow partial response to stimulation, though this is incomplete, mostly non-purposive and usually consists of ineffectual movements or rubbing and scratching of the stimulated area. Bladder distension may call forth groaning or ill-coordinated motor stirring but the patient is still incontinent. Tendon reflexes may or may not be obtainable, and the plantars may be either flexor or extensor. The Glasgow Coma Scale, which has proved its usefulness for the grading of depth of coma, is described in Chapter 4, Measuring head injury severity.

Coma needs to be distinguished from deep sleep and from stupor. In deep sleep and in coma the pictures may be closely similar on superficial observation, but the sleeper can be roused again to normal consciousness by the efforts of the examiner. He may wake spontaneously to unaccustomed stimuli, or in response to inner sensations such as hunger or bladder distension. In sleep there is sporadic continuing mental activity in the form of dreams which leave traces in memory. Coma is more difficult to demarcate from stupor, which is described below. The distinguishing features usually accepted are that in coma the eyes remain shut even in response to strong arousal stimuli, do not resist passive opening, and do not appear to be watchful or follow moving objects; movements in response to stimulation are never purposeful, and there is no subsequent recall of events or inner fantasies from the time in question (see also persistent vegetative state, Chapter 4).

Stupor is an exceedingly difficult term to define, principally because it has been used widely in neurological and psychiatric practice to refer to conditions with markedly different causation. Sometimes it is used loosely and wrongly to refer to an intermediate stage on the continuum of impairment of consciousness that leads ultimately to coma; sometimes to refer to a syndrome characteristic of lesions in the neighbourhood of the diencephalon and upper brainstem and called akinetic mutism; and sometimes to clinical states superficially similar to this but due to hysterical, depressive or schizophrenic illness. Stupor is thus a term without definite nosological status, but valuable when properly used in referring, in essence, to a clinical syndrome of akinesis and mutism but with evidence of relative preservation of conscious awareness. There is a profound lack of responsiveness, and evidence of impairment, or at least putative or apparent impairment, of consciousness. Speech and spontaneous movement are absent or reduced to a minimum, and the patient is inaccessible to the great majority of external stimuli. Unlike coma and semicoma, however, the patient may at first sight appear to be conscious, since the eyes may be open and seem to be watchful. The patient may direct his gaze towards the examiner and the eyes may follow moving visual stimuli in a manner which appears to be purposeful rather than random. When the eyes are shut

they may resist passive opening. Relative preservation of consciousness is also betrayed by the response to stimulation: strong painful stimuli may induce blinking or purposeful coordinated efforts to dislodge the noxious agent. Moreover, in some cases there is subsequent recall of events or delusional fantasies occurring in the stuporose state.

Typically, spontaneous movements are absent but there may be tremors, coarse twitching or, in light stupor, restless stereotyped motor activity. The latter may seem to occur in response to hallucinatory experiences, or to display special meaning in stupors due to psychotic illness. Here also the resting posture may be awkward or bizarre, or it may be meaningful in the context of the patient's delusions. Reflexes are usually entirely normal. Complete mutism is the rule, but again there may sometimes be partially coherent muttering, or arousal may be possible to the extent of brief stereotyped exclamations. In light stupor there may be no sphincter disturbance, and even feeding may be possible with coaxing. Simple responses to commands may then be obtained, though these are slow, inaccurate and often ill-coordinated. The least severe examples may merge indefinitely with severe psychomotor retardation in psychotic depression, or with severe blocking of thought and volition in catatonic schizophrenia. The causes of stupor and their differential diagnoses are considered later in this chapter.

Organic personality change. Brain damage often results in changes of temperament, or changed patterns of reaction to events and to other people. As a result, behavioural tendencies that have previously been enduring characteristics of the individual are found to be altered. Areas typically affected include the control of emotions and impulses and aspects of motivation and social judgement (Lipowski 1980). Such 'change of personality' is usually prominent in dementia, and is then seen along with cognitive defects. But sometimes brain damage may operate more directly by disruption of regional cerebral systems upon which the synthesis of the personality depends. This situation is compatible with excellent preservation of intellect to formal testing, yet the personality change is nonetheless organic in origin. Thus when disturbance of cognitive processes cannot be identified, the term 'organic personality change' is preferable to 'dementia'. Most examples occur with strictly focal brain damage, the best known being with lesions of the frontal lobes of the brain. A clear discontinuity between the current and premorbid personality is essential if this term is to retain its meaning.

Chronic amnesic syndrome. Disorder of memory, especially for recent events, is an integral part of dementia, but can also exist without global impairment of intellect. Such memory disturbance may emerge as the sole defect, as after bilateral hippocampal lesions, or more commonly may stand out as the obtrusive defect while other cognitive processes are but little affected. Such a syndrome may follow an acute organic

reaction which clears to reveal a relatively isolated defect of memory, as when Wernicke's encephalopathy leads to Korsakoff's syndrome.

The term 'chronic amnesic syndrome' usefully describes the essential features of disorder in all such cases, and emphasises the distinction from dementia. It may be defined as an organic impairment of memory out of all proportion to other cognitive changes. A focal rather than a diffuse brain pathology can be confidently predicted as described. Unfortunately, the terms 'chronic amnesic syndrome' and 'Korsakoff's amnesic syndrome' are sometimes used interchangeably, the territory of the latter being allowed to expand considerably. Strictly speaking, the term 'Korsakoff's syndrome' should be restricted to those patients whose amnesia depends on lesions in the hypothalamus and diencephalon and is consequent upon thiamine deficiency.

Organic hallucinosis refers to a syndrome of recurrent or persistent hallucinations, occurring in a setting of full preservation of consciousness and awareness of the environment yet attributable to organic factors. The patient is not disoriented and proves capable of thinking with normal clarity throughout. The hallucinations occur mostly in the auditory or visual modalities but any sensory modality can be affected. Insight into the unreal nature of the phenomena may vary markedly in degree, but any delusions that occur are secondary to the hallucinatory experiences. Such a syndrome may be occasioned by circumscribed brain lesions, strategically placed to irritate cortical or subcortical areas, but is more commonly seen as a result of toxic processes. The hallucinations occurring during the early phase of alcohol withdrawal or after ingestion of hallucinogenic drugs are typical examples.

The prototypical acute and chronic organic reactions are delirium and dementia respectively. These have been operationally defined in the two current major classificatory systems, the Diagnostic and Statistical Manual of Mental Disorders (DSM)-IV and the International Classification of Diseases (ICD)-10 (Boxes 1.1 and 1.2).

Delirium. There are many meanings and definitions of this term, sometimes embracing all varieties of acute organic reaction, sometimes referring to the degree of overt disturbance, and sometimes confining its use to clinical pictures with certain specific features. Special characteristics have included wakefulness with ability to respond verbally, increased psychomotor activity, pronounced disturbance of affect, defective reality testing, or the appearance of productive symptoms in the form of illusions and hallucinations. Delirium tremens is often taken as a prototype for delirium, and contrasted with the 'simple confusion' of subdued cognitive impairment in other illnesses, although this is categorised separately in DSM and ICD. In the UK it was formerly

Box 1.1 DSM-IV and ICD-10 classifications of delirium

DSM-IV criteria

- A** Disturbance of consciousness (i.e. reduced clarity of the environment) with reduced ability to focus sustain or shift attention.
- B** A change in cognition (such as memory deficit, disorientation, language disturbance) or the development of a perceptual disturbance.
- C** The disturbance develops over a short period of time (usually hours to days) and tends to fluctuate during the course of the day.
- D** There is evidence from the history, physical examination or laboratory findings that the disturbance is caused by the direct physiological consequences of a general medical condition/substance intoxication/withdrawal/multiple aetiologies. [Each subcategory has its own additional criteria including 'Delirium not otherwise specified'.]

ICD-10 criteria

- (a)** Impairment of consciousness and attention, with reduced ability to direct, focus, sustain, and shift attention.
- (b)** Global disturbance of cognition: perceptual distortions, illusions and hallucinations, mostly in the visual modality; impairment of abstract thinking and comprehension; impairment of immediate recall and recent memory; disorientation for time and sometimes place and person as well.
- (c)** Psychomotor disturbance which may consist of hypoactivity or hyperactivity or unpredictable shifts between the two.
- (d)** Disturbance of the sleep-wake cycle: insomnia, daytime drowsiness, sleep reversal; nocturnal worsening of symptoms; or disturbing dreams and nightmares which may continue as hallucinations on awakening.
- (e)** Emotional disturbances: depression, anxiety, fear, irritability, euphoria, apathy or perplexity.

traditional to reserve the term for patients whose acute cerebral disorder resulted in some degree of disturbed or disruptive behaviour, i.e. to emphasise the restless hyperactivity and emotional disturbance which is so commonly part of the picture. It is clear, however, that not all patients who meet current criteria for delirium present like this, some showing predominant listlessness, inertia and dulling of the senses. In a daily evaluation of 125 patients who met DSM-III criteria for delirium in a general hospital, Liptzin and Levkoff (1992) classified 15% as hyperactive, 19% as hypoactive, 52% as mixed and 14% as neither.

It is important to appreciate that consciousness is not merely quantitatively reduced in delirium, but also qualitatively changed. Typically the patient becomes preoccupied with his own inner world which is distorted by illusions, hallucinations and delusions, and sometimes by powerful

Box 1.2 DSM-IV and ICD-10 classifications of dementia

For an ICD-10 research diagnosis of dementia (World Health Organization 1993) there must be evidence of the following.

- 1** A decline in memory affecting both verbal and non-verbal material, sufficient at least to interfere with everyday activities.
- 2** A decline in other cognitive abilities, characterised by deterioration in judgement and thinking and in the general processing of information. Deterioration from a previously higher level of performance should be established. For a confident diagnosis both 1 and 2 must have been present for at least 6 months.
- 3** Preserved awareness of the environment during a period sufficiently long to allow the unequivocal demonstration of the symptoms in 1 and 2; when there are superimposed episodes of delirium, the diagnosis of dementia should be deferred.
- 4** Decline in emotional control or motivation, or a change in social behaviour manifest as at least one of emotional lability, irritability, apathy or coarsening of social behaviour.

DSM-IV specifies individual criteria for dementia of the Alzheimer-type, vascular dementia, etc., the common elements being as follows.

- A** The development of multiple cognitive deficits manifested by both:
- 1** memory impairment;
 - 2** one or more of aphasia, apraxia, agnosia or disturbance of executive function (planning, organising, sequencing, abstracting).
- B** Such cognitive deficits cause significant impairment in social or occupational functioning, and represent a significant decline from a previous level of functioning.
- C** The course is characterised by gradual onset and continuing cognitive decline.
- D** The deficits do not occur exclusively during the course of a delirium.

Further inclusion and exclusion criteria then apply to the several varieties of dementia specified in DSM-IV.

affective changes derived therefrom or more directly from dysfunction of specific brain systems. Even though awareness of external events is impaired, arousal may be high, enabling these productive symptoms to occur. The fluctuations in severity are commonly accompanied by fluctuations in content, manifesting as a continuously changing clinical picture. Many different disturbances of cerebral function can lead to delirium, with little that can be regarded as specific in the clinical pictures that result. Toxic and metabolic disturbances are perhaps prone to be associated with listlessness and apathy, and infective processes and alcohol withdrawal syndromes with hyperactivity, fearfulness and prominent hallucinations.

DSM-IV divides the syndrome into delirium due to a general medical condition, substance-induced delirium, and delirium due to multiple aetiologies (American Psychiatric Association 1994). Fundamental to all is a disturbance of consciousness (i.e. reduced clarity of awareness of the environment) coupled with a reduced ability to focus, sustain or shift attention. Additional requirements are a change in cognition (such as memory deficit, disorientation or language disturbance) or the development of a perceptual disturbance (misinterpretations, illusions or hallucinations, mainly visual), with the proviso that these are not better accounted for by a pre-existing or evolving dementia. The disturbance develops over a short period of time (usually hours to days) and tends to fluctuate during the course of the day.

The ICD-10 classification (World Health Organization 1992) similarly stresses concurrent disturbances of consciousness and attention, along with changes in cognition, perception, psychomotor behaviour, sleep-wake cycle and emotion. The disorder is usually rapid in onset, with diurnal fluctuations, most cases recovering within 4 weeks or less but sometimes continuing for up to 6 months.

'*Dementia*' is used in two contexts which must be clearly distinguished: first to label a group of specific disease entities, and secondly to refer to a clinical syndrome that can have many other causes. The specific diseases for which the term is used are considered in Chapter 9. They are characterised by progressive and widespread and inexorable brain degeneration. When denoting a syndrome, however, the term may validly be used more widely, and can be defined very simply as an acquired global impairment of intellect, memory and personality, but without impairment of consciousness. As such it is almost always of long duration, usually progressive and often irreversible, but these features are not included as part of the definition.

The syndrome therefore consists of a constellation of symptoms that suggest chronic and widespread brain dysfunction. Global impairment of cognition or intellect is the central and essential feature, manifest as difficulty with memory, attention, thinking and comprehension. Other mental functions are usually affected concurrently, and changes of mood, personality and social behaviour may sometimes be the outstanding or even presenting features. Nevertheless '*dementia*' should not be used to describe such changes unless intellectual deterioration can be identified.

Historically the term has acquired implications for inevitable decline and irreversibility. This remains true for the disease entities of dementia, but not for all the settings in which the syndrome may appear. The dementia accompanying general paresis can be arrested, and that due to head injury or normal-pressure hydrocephalus may improve with time or treatment. We are now in a new era of effective treatment for Alzheimer's and related dementias, at least in the short and medium terms. Thus when matters of prognosis

are excluded from the definition, the term can be used whatever the cause of the syndrome and whatever future therapeutic discoveries may bring.

It is also important that the syndrome be defined in terms of global impairment of cognitive functions and not in terms of diffuse cerebral damage. Focal brain damage can sometimes lead to global impairment of intellect, memory and personality in addition to regional deficits. Frontal lobe tumours are notorious in this regard, and can produce a picture of dementia indistinguishable at first sight from other causes. In such cases it remains logical to use the term to describe the clinical picture which presents for attention, even though diffuse affection of brain tissue is not the immediate cause. Indeed some forms of dementia are best regarded as the end-result of multiple focal pathologies that coalesce and combine to impair functions globally, as in the vascular dementias. It is essential, therefore, to avoid defining the syndrome in terms of a pathology which has yet to be displayed.

The term is thus reserved for the description of a group of clinical symptoms, while all considerations of prognosis and aetiology are excluded from the definition. This has a certain practical importance, in that once the syndrome has been identified it must always dictate a search for ultimate causes. These may be focal or diffuse, within or without the brain, and may have possibilities for treatment.

Clinical picture in acute organic reactions (acute brain syndrome, acute confusional state, 'delirium')

The acute organic reactions are called forth by a great number of different pathological processes affecting the brain, including trauma, cerebral anoxia, epilepsy, metabolic derangements such as uraemia, or the toxic effects of drugs or alcohol. A list of causes is presented in Table 1.1. The onset is always fairly abrupt, though when slight in degree the disorder may not declare itself in an obvious fashion from the outset. The majority of acute organic reactions are reversible when the underlying pathology can be remedied, but some may progress directly to a chronic organic syndrome, as when an acute post-traumatic psychosis clears to reveal dementia or when Wernicke's encephalopathy results in an enduring amnesic syndrome.

The clinical pictures which result are essentially due to disruption of normal brain function by virtue of biochemical, electrical or mechanical disturbances. The symptomatology follows a surprisingly constant pattern despite these various causes. To some extent there are specific features depending on rate of development, the intensity and perhaps the nature of the noxious agent, but this variability is small in relative terms. The personality and background of the patient will also colour the picture, especially in minor affections and particularly where matters such as intensity of emotional

disturbance or content of delusional thinking are concerned. The main emphasis in what follows, however, will be on shared and common forms of reaction. There is a growing tendency to treat delirium as a problem in its own right with an epidemiology, collection of risk factors, prognosis and treatment strategies (see Burns *et al.* 2004 for review). This reverses years of neglect as a topic for clinical research. The settings in which delirium is most commonly seen, outside those in which acute infections of the central nervous system (CNS) are endemic, are services for the elderly, those undergoing palliative care and in the postoperative situation, especially following cardiothoracic procedures. Simple but comprehensive medical and nursing procedures to minimise and reduce the impact of delirium have now been the subject of clinical trials (Britton & Russell 2004). It is obvious that treatment of delirium should target the underlying cause, but managing a very disturbed patient in the mean time often requires judicious use of parenteral antipsychotic drugs or short-acting benzodiazepines.

Impairment of consciousness

Impairment of consciousness is the primary change in acute organic reactions, and in some degree is universal. It therefore holds a fundamentally important place in the detection of acute disturbances of brain function and in the assessment of their severity. Other features, such as disordered psychomotor activity, perception and emotion, may be more striking but are less constantly found and are also more variable in their manifestations.

Impairment of consciousness lies on a continuum that ranges from barely perceptible dulling of awareness to profound coma. Characteristically the impairment fluctuates when mild in degree, often worsening at night with fatigue and with decreased environmental stimulation. The fluctuations and the appearance of lucid intervals are observations of great clinical importance in the differential diagnosis of organic from non-organic psychiatric disorders, and also in distinguishing acute from chronic organic reactions. Daytime visits may find the patient at his best, and it is thus essential to pay attention to reports of changed behaviour as nightfall approaches.

Disorders of attention

In most conditions impairment of consciousness is accompanied by diminished arousal and alertness which become clinically apparent at some stage of the disorder. However, in others, such as delirium tremens, the patient may be hyperaroused and hyperalert. Arousal and alertness, in this context, refer to the readiness with which the patient responds to environmental stimuli, 'arousal' being best used to describe the physiological state of the organism and 'alertness' to describe the observational data from which this state is inferred.

However, preserved alertness is not the sole yardstick by which preservation of normal consciousness is assessed. To be useful alertness must be coupled with an ability to select discriminatingly between

Table 1.1 Causes of acute organic reactions.*Degenerative*

Dementias complicated by infection, anoxia, etc.
 Episode in Lewy body dementia

Space-occupying lesions

Cerebral tumour, subdural haematoma, cerebral abscess

Trauma

'Acute post-traumatic psychosis'

Infection/inflammation

Encephalitis, meningitis, HIV infection, subacute meningovascular syphilis, exanthemata, streptococcal infection, septicaemia, pneumonia, influenza, typhoid, typhus, cerebral malaria, trypanosomiasis, rheumatic chorea

Vascular

Acute cerebral thrombosis or embolism, episode in multi-infarct dementia, transient cerebral ischaemic attack, subarachnoid haemorrhage, hypertensive encephalopathy, systemic lupus erythematosus

Epileptic

Complex partial seizures, petit mal status, postictal states

Metabolic

Uraemia, liver disorder, electrolyte disturbances, alkalosis, acidosis, hypercapnia, remote effects of carcinoma, porphyria

Endocrine

Hyperthyroid crises, myxoedema, Addisonian crises, hypopituitarism, hypoparathyroidism and hyperparathyroidism, diabetic precoma, hypoglycaemia

Toxic

Alcohol: Wernicke's encephalopathy, delirium tremens

Drugs: benzodiazepines and other sedatives (including withdrawal), salicylate intoxication, cannabis, LSD, MDMA ('ecstasy'), prescribed medications (antiparkinsonian drugs, scopolamine, antidepressants, steroids, antiretrovirals, anticonvulsants, etc.)

Others: lead, arsenic, organic mercury compounds, carbon disulphide

Anoxic

Bronchopneumonia, congestive cardiac failure, cardiac dysrhythmias, silent coronary infarction, silent gastrointestinal bleeding, carbon monoxide poisoning, post anaesthesia

Vitamin lack

Thiamine (Wernicke's encephalopathy), nicotinic acid (pellagra, acute nicotinic acid deficiency encephalopathy), B₁₂ and folic acid deficiency

LSD, lysergic acid diethylamide; MDMA, 3,4-methylenedioxyamphetamine.

those stimuli which are important and meaningful and those which are not. Moreover, the relevant stimuli must gain access to conscious awareness where they can be related to past experience and present needs. For these purposes alertness must be accompanied by a capacity to attend. When consciousness is impaired, certain qualities of attention will invariably be found to be defective, qualities referred to as *phasic, modulated, selective* or *directed* attention.

These involve the capacity not merely to allow a stimulus to elicit a response, but to mobilise, focus, sustain and shift attention in a fluid and changing manner according to the needs of the moment. Whether the patient is hypoalert or hyperalert, it will often soon become apparent that such mechanisms are at fault. Failure to be selective can result in indiscriminate, often excessive, responses to stimuli with the result

that the patient is *distractible*; failure to mobilise and sustain attention is seen in *impaired concentration*; inability to shift attention can lead to *perseveration*. The examiner's difficulty in engaging with the patient may owe much to all these factors. A more pervasive change may also occur, whereby internal percepts, thoughts and images come to hold attention more readily than percepts from the environment, allowing them to become elaborated in an unrestrained manner. This would appear to be important in the genesis of the vivid affects, fantasies and hallucinations of 'delirium', as described earlier in this chapter.

A true appreciation of the patient's level of consciousness must therefore include assessment not only of alertness and responsivity, but also of capacity to attend in a discriminating manner to what is going on around.

A minor degree of impairment of consciousness may present merely with complaints of vague malaise and feelings of uncertainty. It may escape detection at the time and be revealed only in retrospect by the amnesic gap left for the period in question. Other sensitive indicators are minor difficulties in judging the passage of time, in focusing attention as described above, or in thinking coherently. The latter again may initially be more apparent subjectively than to external observation. Sometimes there may be neglect of appearance and of needs, or an episode of incontinence may be an early sign. The sleep–wakefulness cycle is almost universally disturbed in some degree, with various combinations of insomnia, vivid dreams and dream-like mentation (Lipowski 1980, 1990). The diurnal rhythm of activity is sometimes clearly disordered, with a tendency to somnolence by day and excitability at night.

With more severe degrees of impairment, the patient is observed to be slow in responding, loses the thread in conversation, and attention to outside events is hard to arouse and sustain. Responses to requests may betray inadequate understanding or lack of volition to carry them out. Later still the patient is clearly drowsy, sleeps excessively and, if rousable, shows only a torpid and muddled awareness.

Psychomotor behaviour

Motor behaviour usually diminishes progressively as impairment of consciousness increases. When left alone the patient shows little spontaneous activity and habitual acts such as eating are carried out in an automatic manner. The capacity for purposive action is diminished. When pressed to engage in activities the patient is slow, hesitant and often perseverative. He responds to external stimuli apathetically if at all, though highly charged subjective events such as hallucinatory experiences may still call forth abrupt and even excessive reactions. Speech is slow and sparse, answers stereotyped or incoherent, and difficult questions are usually ignored. There is often slurring, perseveration, or dysphasic difficulties. In severe cases there may be no more than incoherent muttering.

While the above is the rule with most acute affections of the brain, some show the reverse with restless hyperactivity and noisy disturbing behaviour. Delirium tremens and the deliria which accompany certain systemic infections are the well-known examples. Not surprisingly these florid cases figure disproportionately highly in most published accounts of acute organic reactions. Psychomotor activity is greatly increased, with an excessive tendency to startle reactions. Typically the overactivity consists of repetitive, purposeless behaviour, such as ceaseless groping or picking movements. Behaviour may be dictated by hallucinations and delusions, the patient turning for example to engage in imaginary conversation, or ransacking the bedclothes for objects thought to be hidden there. More rarely he may perform complex

stereotyped movements, re-enacting the driving of a car or miming his usual work (occupational delirium). Sometimes there is dangerously belligerent behaviour. When purposive, the activities are usually misdirected, inappropriate or bizarre, and voluntary movements are often jerky and uneven. The overactivity is often accompanied by excitement with noisy shouting, laughing or crying. There may be pressure of speech with incoherent flight of ideas. Most of the behaviour is obviously dictated by the patient's own internal world, and alertness to external stimuli is seen to be impaired. Not uncommonly the clinical picture shows rapid changes from phases of overactivity to periods of apathy and asponaneity.

Thinking and reasoning

Thought processes show characteristic changes when consciousness is impaired. In the early stages there is subjective slowing, with difficulty in focusing thoughts or formulating complex ideas. Mental fatigue may be obvious in the course of examination. Later, reasoning becomes less clear and coherent, logic is impaired and thinking is more concrete and literal. Even when speeded by high arousal, the thought content is seen to be banal and impoverished. Trains of thought become chaotic, showing in speech as fragmentation and incoherence.

An important change is in the relative importance of the internal and external worlds, and in the decreasing ability to preserve the distinction between the two. Thus perceptions and thoughts become inextricably interwoven (defective 'reality testing'). Comprehension of events is impaired, with inability to embrace the elements of experience and relate them meaningfully to one another (impaired 'grasp'). The patient may be unaware of the most obvious features of his situation, whether he is standing or lying, whether indoors or in the street. At the same time increased significance is attached to subjective experiences, ideas or false perceptions, which come to dominate the content of consciousness. Bizarre thoughts and fantasies intrude into awareness, and false significance is attached to external cues. Illusions and hallucinations readily arise, and vivid dream material may be carried over into waking life.

Ideas of reference and delusion formation may become prominent, depending to some extent on qualities in the pre-morbid personality. Delusions of persecution are especially common, and may well up suddenly with conviction. They usually betray their organic origin in being poorly elaborated, vague, transient and inconsistent. When consciousness is relatively clear, however, the delusions may be more coherently organised, with a picture more closely resembling schizophrenia. In rare cases delusions may persist when the patient has recovered from the acute illness, with an obstinate belief in the reality of the hallucinatory experiences that occurred.

Insight into cognitive difficulties is typically lost early, but may vary with fluctuations in the level of consciousness. Sometimes even in moderately severe affections the patient may be briefly roused to self-awareness and to a better appreciation of reality.

Memory

With impairment of consciousness there is disturbance of registration (encoding and learning), retention and recall. Registration of current experience is hampered by defects in attention, perception and comprehension. Accordingly, the immediate memory span for digits or similar material (working memory) is found to be reduced. Defective retention leads to difficulty with new learning and this is a sensitive clinical indicator in mild stages of disorder. Recent (episodic) memories prove to be faulty while long-term memories are reasonably intact, though with moderate impairment of consciousness both are found to suffer.

An early change is defective appreciation of the flow of time, and the jumbling of time sequences for recent events. This quickly leads to disorientation in time, which is sometimes regarded as the hallmark of acute organic reactions. However, disorientation may be transient in the early stages, and a normally orientated patient may prove later to be amnesic for all that passed during the interview in which he was examined.

Disorientation for place, and later still for person, follow with worsening of perceptual and cognitive disorganisation. Patients may maintain two incompatible attitudes towards their orientation without seeming aware of the inconsistency. This can emerge strikingly where orientation for place is concerned, the patient saying quite correctly, for example, that he is in hospital in one town yet interpreting his surroundings and behaving in every other way as though he were at home in another part of the country, a condition known as reduplicative paramnesia. Such correct and incorrect orientations may exist side by side in a vacillating and unrelated manner, or be reconciled by shallow rationalisations. The patient may insist that the two places are the same, or contiguous with each other, or confabulate a recent journey between the two. Reduplicative paramnesias may take a number of forms and are sometimes associated with misrecognition or reduplication of persons. They can be seen with chronic organic reactions as well, perhaps particularly in association with right hemisphere pathology (Ellis & Lewis 2001; see also Illusions of transformation, displacement or reduplication, later in this chapter). False memories and confabulation may occasionally be in evidence, and misidentifications, including pseudorecognition, are facilitated by the perceptual abnormalities described below.

On recovery there is typically a dense amnesic gap for the period of the acute illness, though where fluctuation has been marked islands of memory may remain. Sometimes sensory impressions, and especially vivid hallucinations,

stand out clearly and are remembered in great detail when all else is forgotten, attesting again to the importance of subjective experience over external reality in severe stages of the disorder.

Perception

Quite commonly it is the more florid perceptual abnormalities that draw attention to the presence of an acute organic reaction in a patient suffering from some physical disease. However, these are not essential features in every case, and the diagnosis should be made by seeking out the subtle deficits in thinking, memory and attention which betray impairment of consciousness.

Early on the patient may be aware that perception requires unusual effort, particularly where vision is concerned. Sometimes, in contrast, perceptions appear subjectively to be hyperacute. Disturbances of vision include micropsia, macropsia or distortions of shape and position. Disordered auditory perception may hinder clear communication. There may be distortions of weight and size, or bizarre disorders of the body image in which body parts feel shrunken, enlarged, misplaced or even disconnected. The whole body may feel as though it is tilted or floating. Disordered perception of internal bodily sensations leads sometimes to bizarre complaints. Genuine physical symptoms such as vertigo, headache and paraesthesiae are likewise often reported in distorted fashion.

Depersonalisation and derealisation are common, though usually incompletely expressed. Dissolution of the perceptual boundaries between the self and the environment may give rise to terrifying feelings of imminent dissolution or loss of bodily and personal integrity.

Perceptual abnormalities readily lead to misinterpretations and illusions which are typically fleeting and changeable. The visual modality is affected most often. Difficulty with visual recognition combines with faulty thinking and memory to produce false recognitions and faulty orientation in place. The unfamiliar tends to be mistaken for the familiar, or may be interpreted as hostile or persecutory. Thus the patient may misidentify a nurse as a relative, or the doctor as an old friend or enemy. The hospital ward may be mistaken for home or prison. Chance noises may similarly be misinterpreted, contributing to delusion formation. The whole is often reinforced by disordered affects of fear and suspicion.

Hallucinations are also commonest in the visual modality, though tactile and auditory hallucinations occur as well. They probably derive partly from failure to distinguish inner images from outer percepts, and partly from vivid dreams carried over into the waking state as consciousness waxes and wanes. Simple visual hallucinations consist of flashes of light, geometrical patterns or colours. More complex phenomena, sometimes kaleidoscopic in nature, may occur, with fully formed hallucinations of scenes, people and animals. A bizarre fantastic quality is not uncommon. The hallucinated

material may be grossly distorted, as with Lilliputian hallucinations where objects and people appear to be minute in size. The reality of the phenomena is fully accepted by the patient, who may react with fear and alarm but sometimes with interest or even amusement.

Hallucinations appear to be particularly characteristic of the acute organic reactions occasioned by certain pathological processes. Delirium tremens remains the classic example, with extremely florid hallucinations as described in Chapter 11. Along with hallucinogenic drugs, prescribed drugs with potent anticholinergic properties are also notorious for the wealth of formed and unformed hallucinations they may provoke. Animals are said to feature particularly frequently in the hallucinations of delirium tremens, and visual hallucinations of 'nets' were said to characterise the organic reactions seen in bromide intoxication when this was common. In the setting of delirium, sensory impairments appear to predispose to hallucinations in the corresponding modality and hence are common in the elderly.

Emotion

In early stages, mild depression, anxiety and irritability may be expected, though typically the affect is shallow. With deeper impairment, and further impoverishment of mental processes, apathy usually becomes the striking feature, and the whole course of the illness may pass with indifference and emotional withdrawal. More lively affects are seen in conjunction with increased psychomotor activity when affective disturbance may become intense. Anxiety and fear are especially common, increasing sometimes to terror and panic. A state of wondering perplexity forms a common background to other affective states. Depression is frequent, elation or anger less so. Paranoid attitudes may show in marked hostility and suspicion. The affective reactions are often fleeting and changeable with changing delusional ideas. Sudden displays of primitive and highly charged emotion are often called forth by hallucinatory experiences.

In part the emotional state is likely to be determined by the stress of the physical illness, and in part by a vague awareness of cognitive impairments. The individual's personality structure may contribute in considerable measure, some patients being predisposed to react by apathetic withdrawal and others by projection of fantasised dangers onto the environment. The extent of such influences has not been determined, nor the degree to which the picture is shaped by different pathogenic agents. There are strong clinical impressions that delirium tremens tends to be accompanied by intense fear, hepatic encephalopathy by euphoria or depression, and uraemia by apathy, but reliable and systematic comparisons have not been made. It is clear, moreover, that several factors are often operative together in leading to delirium in the individual patient, particularly in the elderly (Francis *et al.* 1990).

Other features

In the milder stages in particular, the definitive organic features may be less in evidence than those which depend on individual traits and characteristics. Psychological reactions to early cognitive impairment, or to the stress of the underlying physical disease, may dominate the picture and emerge in the form of neurotic symptoms. Similarly, vulnerable aspects of personality may be exaggerated, with the appearance of depressive, hypochondriacal or phobic features. Histrionic and importunate behaviour may sometimes be much in evidence. Hysterical conversion symptoms, usually transient but sometimes persistent, may lead to mistakes in diagnosis. Paranoid developments occur frequently, and can become the overriding feature at an early stage in susceptible individuals. A distinct schizophrenic colouring to the total clinical picture is likewise not uncommon. With progression of cognitive disorganisation the true situation usually becomes apparent, but mild self-limiting acute organic reactions can be misdiagnosed for some time as non-organic psychiatric illness.

Clinical picture in chronic organic reactions (chronic brain syndrome, chronic confusional state, 'dementia')

Chronic organic reactions, like acute organic reactions, result from many different pathological processes, yet the clinical picture shows a large measure of similarity from one condition to another. A focal emphasis of pathology may produce special patterns of impairment, but the purpose in what follows is to describe the general clinical picture and to emphasise the shared and common forms of reaction that occur.

While the majority of chronic organic reactions are due to diffuse and widespread affections of the brain, some owe their origins to focal pathology, so careful examination for signs of localising value must always be undertaken. The principal causes are listed in Table 1.2. Most of the illnesses concerned are slowly progressive with increasing disablement, but static pictures may be seen as with arrested general paresis, or gradual improvement may occur as after head injury. In a small but extremely important group, therapeutic intervention can decisively reverse the process, for example with myxoedema or normal-pressure hydrocephalus, or when a frontal meningioma is discovered to be the cause.

Mode of presentation

Some chronic organic reactions follow acute episodes such as trauma or anoxia, and are then revealed in full when the patient recovers consciousness, or else emerge by a process of transition from an acute organic reaction. The great majority, however, develop insidiously from the start.

Table 1.2 Causes of chronic organic reactions.*Degenerative*

Alzheimer's disease, multi-infarct dementia, Lewy body dementia, frontal lobe dementia, Pick's, Huntington's and Creutzfeldt–Jakob diseases, normal-pressure hydrocephalus, multiple sclerosis, Parkinson's, Schilder's and Wilson's diseases, progressive supranuclear palsy, progressive multifocal leucoencephalopathy, progressive myoclonic epilepsy, metachromatic leucodystrophy, neuroacanthocytosis, Kufs' disease, mitochondrial myopathy, etc.

Space-occupying lesions

Cerebral tumour, subdural haematoma

Trauma

Post-traumatic dementia

Infection/inflammation

HIV-associated dementia, general paresis, chronic meningovascular syphilis, subacute and chronic encephalitis, multiple sclerosis

Vascular

Cerebral vascular disease, *état lacunaire*, cerebral autosomal-dominant arteriopathy with subcortical leucoencephalopathy (CADASIL)

Epileptic

'Epileptic dementia'

Metabolic

Uraemia, liver disorder, remote effects of carcinoma

Endocrine

Myxoedema, Addison's disease, hypopituitarism, hypoparathyroidism and hyperparathyroidism, hypoglycaemia

Toxic

Korsakoff's syndrome, 'alcoholic dementia', chronic intoxication with sedative drugs, manganese, carbon disulphide

Anoxic

Anaemia, congestive cardiac failure, chronic pulmonary disease, post anaesthesia, post carbon monoxide poisoning, post cardiac arrest

Vitamin lack

Lack of thiamine, nicotinic acid, B₁₂, folic acid

The commonest mode of onset is with evidence of impairment of memory or more general cognitive impairment with disorganisation of intellect. Failures of memory are usually noted earlier by relatives and workmates than by the patient himself. They show in missed appointments, apparent unawareness of recent happenings, a tendency to mix up times or to lose things. More general cognitive failure emerges in slipshod work and loss of overall efficiency. The patient may be noticed to think and speak less coherently than usual, to muddle money or to fail to grasp essentials.

Change in personality as the first manifestation is much less common, but when it occurs the patient is especially likely to come before the psychiatrist. Here intellectual deficits are mild or absent in the early stages, or pass unnoticed because of curtailment of activities and the use of props and evasions. Deterioration of manners may be the earliest sign,

or diminished awareness of the needs and feelings of others. Some social blunder may disclose the problem, such as stealing or disinhibited behaviour out of character for the individual. Sometimes the earliest change is merely the exaggeration of long-standing personality traits such as suspiciousness or egocentricity. Neurotic traits may be elaborated with the production of depressive, obsessional, hysterical or hypochondriacal symptoms. More rarely the illness presents with the picture of a psychotic illness of depressive, paranoid or schizophrenic type in especially predisposed individuals. It is then only by careful examination that the onset of cognitive impairment is revealed.

Whatever the form of presentation, the illness may declare itself abruptly even though its evolution has been insidious. Some episode of acute mental disturbance may bring the disease to attention. Or relatives may have adjusted to the

slow decline until some dramatic instance forces their attention to the true situation. Not infrequently a tenuous adjustment is concealed until new demands must be met, for example on the death of a partner or a move to a new environment. Admission to hospital may be the step which reveals the disorder, and only careful retrospective enquiry then establishes that the onset has been gradual. Intercurrent illness may bring the situation to light by pushing the patient below the threshold at which the brain was previously coping, especially infection, anoxia or postoperative metabolic derangements.

General behaviour

Although cognitive impairment is the hallmark of chronic organic reactions, this may be manifest only indirectly by way of behavioural change. Typical early signs are loss of interest and initiative, inability to perform to the usual standard, or minor episodes of muddle and confusion. Episodes of bizarrely inappropriate behaviour may occur, as when a woman unloads her shopping in the oven or prepares a meal at an inappropriate time. As described above, some cases present with changes in the field of social behaviour well before impairment of cognitive processes is overt.

As the disorder progresses the same division is seen, some aspects of behaviour reflecting the intellectual disorganisation, and some the change in emotional control and social awareness. Intellectual impairment shows as incapacity for decisive action, loss of application and inability to persist in a consistent course of conduct. Despite full alertness and the preservation of normal levels of consciousness the patient fatigues readily on mental effort. He responds appropriately to stimuli within his limited range of comprehension and is capable of directed attention as the need arises, but powers of concentration are impaired. Various behavioural changes may come into play that reflect the attempts of the personality to cope with such defects. There is often restlessness, with purposeless overactivity or, alternatively, rigid adherence to routines and stereotyped behaviour. In this manner the patient may be enabled to cope for a while. When taxed beyond his ability, however, he may become evasive and sullen, or react abruptly with an explosion of primitive affect such as anger, anxiety or tears ('catastrophic reaction' after Kurt Goldstein). In the later stages hygiene and personal appearance are neglected and ritualistic hoarding may develop. Food is eaten sloppily, habits deteriorate and there is indifference to urinary or faecal incontinence. In contrast, however, some patients preserve superficial social competence until surprisingly late in the course of the disease.

Eventually, behaviour becomes futile and aimless, often with stereotypies and mannerisms. Impoverishment of thought is reflected in lack of purposive activity, and physical deterioration follows with increasing weakness and emaciation.

Thinking

Thinking is impaired both qualitatively and quantitatively. It becomes slowed with reduced powers of concentration and ready mental fatigue. The content of thought is impoverished, with fewer associations, inability to produce new ideas, and a tendency to dwell on set topics and memories from the past. Themes are banal and perseveration usually marked. The ability to reason logically and to manipulate concepts is impaired, likewise the ability to keep in mind various aspects of a situation simultaneously. Specific skills such as calculation are usually impaired from an early stage.

Intellectual flexibility is lost, leading to difficulty in shifting from one frame of reference to another. The lack of effective counter-ideas leads the patient to become tied to the immediate situations that arise, so that he is distracted by accidental impressions and events and becomes 'stimulus bound' to them. Such difficulties are compounded by inability to extract the essentials of a situation or experience. Abstract ideas present especial difficulty and concepts tend to be given their most literal interpretation (termed 'concretisation').

Judgement is impaired early. The patient's insight is poor and there may be little awareness of illness at all. The more the complexity of the domain of functioning, the greater the discrepancy between the individual's appraisal of his abilities and that of his carer. False ideas readily gain ground and paranoid ideation is particularly common. Ideas of reference may reflect an exaggeration of premorbid tendencies. Delusions are typically persecutory in nature and may owe much to limbic dysfunction (Cummings 1992). The complexity of their content tends to be inversely proportional to the severity of cognitive impairment, patients with severe dementia usually harbouring only simple and loosely structured false beliefs. Occasionally, however, they become entrenched and unshakeable. As Roth and Myers (1969) point out, they may be delusions in the technical sense, in that the beliefs are held in the face of evidence of their falsehood, but this is largely because the evidence fails to be understood not because it is rejected. Delusional themes are often crude and bizarre, typically of being robbed, poisoned, threatened or deprived. The exception is delusional misidentification, which appears to be particularly associated with organic brain changes. In the later stages thinking appears to be restricted to circumscribed reiterative themes, and becomes grossly fragmented, incoherent and disorganised.

Speech

The disturbances in thinking are mirrored in speech. The most characteristic disturbance is poverty of speech with excessive employment of clichés and set phrases. The pool of vocabulary is greatly reduced, and speech initiative is poor.

Sentences are often simple, incomplete and poorly constructed, with perseveration, stereotyped utterances and echolalia.

Paraphasic errors, and nominal dysphasia, are not uncommon. Barker and Lawson (1968) suggest that difficulty in word-finding is a general feature in dementia if care is taken to test with words of low frequency of usage. There may be little evidence of disability until the patient is pressed to name an object, whereupon he may show little awareness of his errors. This is in contrast to the situation in nominal dysphasia due to focal brain lesions. Sometimes he may improvise to produce new words, showing perseveration and 'clang' associations. Concretisation shows in the excessive use of words which refer to the self and the tendency for external stimuli to influence the words that are chosen.

Ultimately, speech becomes grossly disorganised and fragmented, and used exclusively in the service of bodily needs. The patient may become mute or capable only of a restricted range of semicoherent ejaculations.

Memory

Memory disturbance is frequently the earliest sign of a developing chronic organic reaction, and at first may be intermittent. Allison (1962) makes the important point that with diffuse as opposed to focal cerebral lesions the onset of memory disturbance can rarely be dated accurately because it has been of such gradual evolution. The onset may be marked by minor forgetfulness and 'absent-mindedness', or by more definite episodes in which new impressions fail to register and striking lapses of memory occur. Loss of topographical memory is often seen, with the patient losing his way when away from home. Disorientation in time is a frequent early sign; disorientation for place and person are found much later in development.

The memory defect is typically global, affecting all categories of material and remote as well as recent events, as described in Chapter 2. Failure at new learning is usually the most conspicuous sign, but rarely there is the sharp demarcation between remote and recent memory that characterises the purer amnesic syndromes. Recall is affected as well as registration and retention, as shown by increased success with prompting and better performance at recognition than at free recall. Memory for names is sometimes particularly affected. Temporal sequences are disorganised early, with faulty appreciation of the flow of time and mislocation of past events. Berlyne (1972) found that over one-third of an unselected group of demented patients showed unequivocal confabulation, sometimes representing a true memory displaced in time, but sometimes consisting of more sustained and elaborate productions.

Characteristically the patient's awareness of his memory difficulties is impaired, or there may even be an apparently

motivated desire to hide the deficits with facile excuses and shallow confabulations. In the early stages the patient may show surprising ingenuity in covering up his failures, and may compensate by means of a rigid daily routine and the use of a notebook. Ultimately, however, memory for current events may fail completely and the patient may be able to produce only a few jumbled recollections from the past.

Emotion

Emotional changes form an integral part of the clinical picture in chronic organic reactions and deterioration of emotion and intellect frequently pursue a parallel course.

Early emotional changes probably reflect the struggle to cope with incipient intellectual deficits, and are coloured by premorbid personality characteristics. Anxiety is common, likewise depression with agitation and hypochondriacal features. Serious suicidal attempts may occur at this stage. Irritability leads to querulous morose behaviour, and sometimes to outbursts of anger and hostility. Perplexity and suspicion are other common early developments, leading to paranoid beliefs and attitudes.

Further deterioration produces emotional changes of a distinctive organic type. Affective blunting and shallowness may progress to states of apathy or empty euphoria. Emotions may take on a child-like aspect, with petulant importunate behaviour and short-lived excessive responses to trivial annoyances. Thus the death of a spouse may leave the patient unmoved, yet interference with some simple routine may provoke outbursts of anger.

Emotional control may show a characteristic threshold effect in which there is little response to mild stimulation but thereafter an excessive and prolonged disturbance. Emotional lability may be extreme, with episodes of pathological laughing and crying for little or no cause. The 'catastrophic reaction' may be observed when the patient is taxed beyond his ability to cope, as described in Chapter 2 (Psychiatric disturbance and aphasia) and Chapter 3 (Mood).

The ultimate picture in progressive disease represents a combination of these various emotional changes, but characterised above all by increasing emptiness of affect, shallowness, dullness and lack of emotional response.

Other features

The impact of chronic diffuse brain disease is not entirely unaffected by features specific to the individual. As already mentioned, neurotic manifestations may be conspicuous in mild stages of disorder. Hysterical conversion symptoms and obsessional disorders may figure prominently, the former perhaps by virtue of increased suggestibility and the latter as a mode of coping with reduced resources. A predisposition towards affective or schizophrenic psychosis may lend a distinctive colouring to the clinical picture and lead to mistaken diagnosis in the early stages. Hallucinations can

occur in visual, auditory and tactile modalities, and are typically paranoid in content. With progressive disease all such manifestations are usually ultimately engulfed in the general pattern of intellectual and social decline.

The combination of acute and chronic organic reactions is of course much more common than would be predicted by their chance co-occurrence. Delirium superimposed on dementia is a common clinical problem and is recognised in international disease classificatory systems. Indeed, a dementing condition may be exposed for the first time by the superimposition of delirium following a relatively minor metabolic or toxic insult, due to the unnoticed loss of some theoretical cerebral 'reserve'. Other general psychiatric disorders when they occur in the setting of organic brain disease may be classified separately in the ICD and DSM schemes from their 'idiopathic', 'non-organic' counterparts.

Clinical picture in focal cerebral disorder

Strictly focal brain damage can be responsible for both acute and chronic organic reactions as well as rather characteristic 'neurobehavioural syndromes'. Symptoms and signs of localizing significance may then be much in evidence, and must be kept in mind in the clinical assessment of all patients who show organic psychiatric illnesses.

Epileptic phenomena, especially those of temporal lobe epilepsy, are clear examples of acute psychological disturbances due to focal brain dysfunction, also some of the disturbances seen after small acute cerebrovascular accidents. Wernicke's encephalopathy is another classic example, with its own distinctive chronic end-state in the chronic amnesic syndrome. For obvious reasons, however, focal brain disorder has been most comprehensively studied in slowly progressive or static lesions of long duration, which allow the focal components to be disentangled from any generalised deficits that coexist.

In Chapter 2, the complex problems of the focal significance of psychological symptoms are dealt with in detail. Here, those which emerge with fair consistency after lesions of different parts of the brain are described in summary form. Neurological defects are in general more reliable than psychological symptoms in pointing to the site of focal pathology, and these too will be included. In general focal signs and symptoms serve only to indicate the site of likely pathology, and are of relatively little value in themselves in suggesting the nature of the lesion.

Frontal lobes

Frontal lesions may confer distinctive changes of disposition and temperament subsumed under the term 'change of personality'. Most characteristic is disinhibition, with expansive over-familiarity, tactlessness, over-talkativeness, childish

excitement (*moria*) or prankish joking and punning (*Witzelsucht*). Social and ethical control may be diminished, with lack of concern for the future and for the consequence of actions. Sexual indiscretions and petty misdemeanours may occur, or gross errors of judgement with regard to financial and interpersonal matters. Sometimes there is marked indifference, even callous unconcern, for the feelings of others. Lack of insight into their social inappropriateness or the presence of any perturbation of health and functioning is characteristic. Elevation of mood is often seen, mainly as an empty and fatuous euphoria rather than as a true elation that communicates itself to the observer. In other cases the principal changes are lack of initiative, spontaneity and profound slowing of psychomotor activity, particularly with frontal lobe tumours. This may progress to a state of extreme spontaneity amounting virtually to stupor.

Concentration, attention and ability to carry out planned activity are impaired by these changes, but performance on tests of formal intelligence is often surprisingly well preserved once the patient's cooperation has been secured. Even with sharply circumscribed frontal lesions, however, the overall picture may at first sight strongly resemble a generalised dementing process. The hazards of misdiagnosis are increased by the 'silent' nature of frontal lobe lesions, which can allow them to grow large before declaring themselves with neurological signs.

When frontal lesions encroach upon the motor cortex or motor projections there will be contralateral spastic paresis, usually seen earliest in the face and more obvious on voluntary movement than emotional expression. Paresis may be extremely slight, and show only as slowness of repeated movements or falling away of the outstretched arm. A grasp reflex may be the only definite sign. Firmer evidence may be found in hyperactive tendon reflexes and a positive Babinski response. Characteristic decomposition of gait may be seen, with trunk ataxia or awkward postures.

Lesions affecting the orbital part of the frontal lobes may be associated with the 'forced utilisation' of objects presented to the patient, as described in Chapter 2 (Classical case reports). This appears to be an extension of the more commonly observed forced grasping. Posterior lesions of the dominant lobe may produce a primary motor dysphasia, a motor agraphia or an apraxia of the face and tongue. Ipsilateral optic atrophy or anosmia may result from orbital lesions of the lobe, the latter being commonly overlooked in clinical examination. Sphincteric incontinence may occur surprisingly early in view of the reasonable preservation of intellect, and is a valuable added indication.

Parietal lobes

Parietal lobe lesions are associated with a rather bewildering variety of complex cognitive disturbances, including defects of language and number sense, defective appreciation of

external space, and disorders of the body image. Where some are concerned it is uncertain how far the lesions of the parietal lobe are alone responsible, or how far adjacent lesions in the temporal and occipital lobes contribute to the total picture. These matters are dealt with in Chapter 2, but the following is presented as a brief clinical guide.

Lesions of either parietal lobe may result in visuospatial difficulties and topographical disorientation. Visuospatial difficulties are most readily exposed by asking the patient to copy simple drawings or construct patterns from coloured blocks or matchsticks, tests which reveal the presence of visuospatial agnosia or constructional dyspraxia. Defective performance is seen more commonly with lesions of the non-dominant than dominant lobe but may occur with either. Difficulty in locating objects in space, or in describing the relationships between different objects by vision alone, may also be observed. Topographical disorientation is revealed by difficulty in learning or remembering the way about, with the result that the patient mislocates his bed in the ward, fails to find the bathroom or loses himself even in familiar surroundings.

Dominant parietal lobe lesions are associated with various forms of dysphasia, primary motor dysphasia being most in evidence with anterior lesions and primary sensory dysphasia with posterior lesions. The latter may include alexia in association with agraphia. Motor apraxia similarly accompanies dominant parietal lobe lesions, and usually affects the limbs of both sides of the body. Various components of Gerstmann's syndrome may be seen, namely finger agnosia, dyscalculia, right-left disorientation and agraphia. The syndrome is rarely seen in its entirety and individual components often occur along with other parietal lobe symptoms. Bilateral tactile agnosia is occasionally seen, as are various forms of visual agnosia when the lesion lies posteriorly in the parieto-occipital region.

Non-dominant parietal lobe lesions may produce disturbed appreciation of the body image and of external space, particularly involving the contralateral side. The left limbs may fail to be recognised or may be disowned by the patient. If paralysed or hemianaesthetic, the disability may be ignored or refuted (anosognosia), a part of the body may be felt to be absent (hemisomatognosia), or in rare cases there may be phantom reduplication of body parts. Neglect of the left half of external space may show in the omission of left-sided details when drawings are copied, or in the crowding of writing into the right-hand part of the paper. Left-hand turnings may be overlooked when finding the way about. 'Dressing dyspraxia' consists of muddle when inserting limbs into garments or putting garments over the head. In addition to visuospatial agnosia there may be a marked defect of the recognition of faces (prosopagnosia) when the lesion is posterior and involves the occipital lobe.

Neurological signs indicative of a parietal lobe lesion include cortical sensory loss and the phenomena of extinc-

tion and inattention. Cortical sensory loss consists not of analgesia but of a more complex impairment of sensation and difficulty with discrimination; objects cannot be identified by palpation (astereognosis), figures written on the hand cannot be named (agraphaesthesia), two-point discrimination is impaired, and the localisation of sensory stimuli is inaccurate. Sensory extinction (sensory inattention) is shown when two parts of the body are lightly touched simultaneously and that on the side contralateral to the lesion is not perceived. Visual inattention may be demonstrated by asking the patient to point to moving objects in both half-fields of vision; when two objects move simultaneously that in the contralateral half-field is ignored.

Sensory deficits are often accompanied by evidence of mild hemiparesis in the limbs contralateral to the lesion. Deep lesions affecting the optic radiation produce a contralateral homonymous hemianopia, usually more fully developed in the lower than the upper quadrants.

Temporal lobes

Lesions restricted to the poles of the temporal lobes can be entirely asymptomatic. More commonly, however, temporal lobe lesions are associated with disturbance of intellectual functioning, lesions of the dominant lobe more so than those of the non-dominant lobe.

Dominant temporal lesions may produce language difficulties alone. This is typically a sensory dysphasia, resulting in severe cases in jargon productions. More posterior lesions on the dominant side may also impair visual aspects of language in the form of alexia and agraphia. Parietal lobe symptomatology may then also appear by way of motor apraxia, constructional apraxia and aspects of Gerstmann's syndrome.

Non-dominant temporal lobe lesions often show a paucity of symptoms and signs. Sometimes, however, visuospatial difficulties are in evidence, also prosopagnosia and hemisomatognosia.

Bilateral lesions of the medial temporal lobe structures can produce amnesic syndromes of great severity and virtually uncontaminated by other intellectual disturbances (see Chapter 2, Medial temporal amnesia). Unilateral temporal lobe lesions lead to a more restricted disturbance of memory for certain classes of material along with related perceptual deficits, but this is rarely a spontaneous complaint and is usually revealed only by special testing. Lesions on the dominant side impair the learning and retention of verbal material even in the absence of overt dysphasia. Non-dominant lesions impair the learning and retention of non-verbal patterned stimuli, such as music, or faces and drawings to which a name cannot be attached.

Personality disturbances identical with those accompanying frontal lesions may occur, but will more commonly be associated with intellectual and neurological deficits.

Chronic temporal lobe lesions are notorious for their association with disturbance of personality, and particularly with emotional instability and aggression. Similarly lesions of the temporal lobe appear to carry an increased risk of psychotic disturbances akin to schizophrenia. Depersonalisation may be prominent, also disturbance of sexual function. Epileptic phenomena are common with temporal lobe lesions and give important evidence of localisation (Chapter 6).

The most reliable neurological sign of deep temporal lobe lesions is a contralateral homonymous upper quadrantic visual field defect, caused by interruption of the visual radiation in the central white matter. This sign alone may occasionally betray the presence of a temporal lobe lesion in a dementing process that has been attributed to diffuse brain damage. Deep lesions may also result in a mild contralateral hemiparesis or sensory loss due to encroachment upon fibres in the corona radiata. Equilibrium and hearing are not impaired, even by extensive unilateral lesions of the temporal neocortex.

Occipital lobes

Occipital lobe lesions lack well-established focal symptomatology except where vision is concerned. Complex disturbances of visual recognition characterise lesions of the parastriate areas. Agnosia for written or printed material (alexia without agraphia), colour agnosia and 'simultanagnosia' are characteristic of dominant occipital or occipitotemporal lesions, whereas bilateral pathology is usually present with visual object agnosia or prosopagnosia. Visuospatial agnosia occurs more commonly from non-dominant than from dominant occipitoparietal lesions, likewise metamorphopsia in which the appearance of objects is distorted. Complex visual hallucinations are said to occur more commonly from non-dominant than dominant occipital lesions.

Lesions of the striate cortex produce homonymous defects in the opposite half-field of vision and occasionally simple visual hallucinations of patterns, flashes of light, etc. Extensive bilateral lesions may produce cortical blindness, distinguished from peripheral blindness by the normal appearance of the optic fundi and the preservation of pupillary light reflexes.

Corpus callosum

Expanding corpus callosum lesions typically extend laterally into adjacent parts of the hemispheres, producing a picture of severe and rapid intellectual deterioration along with changes specific to the lobes involved. Anterior tumours produce marked frontal lobe disturbance, often with extreme psychomotor retardation and asponaneity. Dysphasia, apraxia and asymmetrical pyramidal signs are common when the parietal lobes are affected. Involvement of diencephalic structures leads to somnolence, stupor and akinesia. Bizarre postural motor abnormalities may strongly resemble

the pictures seen in catatonia. Disruption of communication between the two hemispheres may result in lack of access of the non-dominant hemisphere to the speech mechanisms in the dominant hemisphere; there will then be left-sided apraxia to verbal commands, with agraphia and astereognosis in the left hand (Geschwind 1965). Lesions restricted to the posterior part, in association with lesions of the left occipital lobe, may result in alexia without agraphia (or pure word blindness) for similar reasons.

Diencephalon and brainstem

The most characteristic symptoms of lesions in the deep midline structures of the brain are amnesia of the Korsakoff type and hypersomnia. These may stand out against a background of progressive intellectual deterioration or present initially as the sole disturbance. Amnesia that is strikingly more marked for recent than remote events, and is sometimes accompanied by confabulation, is characteristic of lesions in the neighbourhood of the third ventricle, aqueduct and posterior hypothalamus. Somnolence and hypersomnia suggest a lesion of the posterior diencephalon and upper midbrain. It may fluctuate in intensity, or occur in brief attacks suggestive of narcolepsy. Sometimes it may progress to states of profound stupor or coma. Akinetic mutism ('coma vigil') is a characteristic syndrome in which the patient lies immobile and mute, though the eyes may be open and follow moving objects (see Chapter 6, under Diencephalic tumours).

Intellectual deterioration may occur by virtue of raised intracranial pressure consequent upon obstruction of the cerebrospinal fluid circulation. Some focal lesions, however, produce rapidly progressive dementia without such generalised disturbance, particularly those originating within the thalamus. Features closely akin to the 'frontal lobe syndrome' may occur with diencephalic and brainstem lesions: disinhibition, indifference, carelessness and euphoria. Insight into the changes is said to be better preserved than with the equivalent pictures produced by frontal lobe lesions. Swings of mood and sudden outbursts of violent emotion are also held to be characteristic. Bilateral lesions within the upper brainstem and diencephalon, seen for example with pseudobulbar palsy, are associated with extreme emotional lability and 'emotional incontinence'. The patient laughs or cries excessively in response to trivial stimuli, yet if questioned he denies experiencing the degree of emotion he displays, and may well be distressed at his inability to control the response.

Focal neurological signs may be surprisingly absent in the early stages of progressive diencephalic lesions. Raised intracranial pressure with headache and papilloedema are found with the majority of obstructive lesions, though even here mental symptoms may be severe before this develops. Visual field defects will betray lesions such as

craniopharyngiomas which grow upwards from the sella turcica and compress the optic chiasma. However, the patient who has considerable intellectual loss may make no complaint of the visual field disturbance, and testing can sometimes be impossible.

Disturbance of hypothalamic function can result in polydipsia, polyuria, hyperphagia and obesity or elevation of temperature. Amenorrhoea or impotence may occur in the adult, delayed or precocious sexual development in the child. Involvement of the pituitary gland will result in a wide variety of endocrine changes, which may, however, be overlooked for a time when psychiatric disturbance is prominent.

Thalamic lesions cause the sensory disturbances characteristic of parietal lobe lesions with, in addition, hypalgesia or analgesia to painful stimuli. Brainstem lesions cause characteristic cranial nerve palsies, along with evidence of dense long-tract motor and sensory disturbances.

Basal ganglia

Disorders of the basal ganglia are, in classical neurology, liable to present with one of the involuntary movements as their more visible manifestation. However, neuropsychiatric presentations of basal ganglia lesions are being increasingly recognised. Such lesions are commonly the result of degenerative conditions such as Parkinson's disease and Huntington's chorea and hence present with a gradually deteriorating course. By virtue of the strong reciprocal connections between the basal ganglia and the frontal lobes, many presentations have a strong 'frontal' flavour. These tend to be of the more 'negative' type, with slowing of thought, speech and movement and lack of spontaneity and motivation being most prominent. Indeed, depressive disorders are a common accompaniment as well as being a major part of the differential diagnosis. However, apathy may give way to irritability and diffuse cerebral dysfunctions. Rigid patterns of behaviour and repetitiveness may lead to frank obsessional-compulsive disorders. There is a particular constellation of

cognitive deficits that has become known as the 'subcortical dementias' (see Table 1.3 and Chapter 12).

Differential diagnosis

The correct appraisal of patients with neuropsychiatric disorders is a test of both psychiatric and general medical skills. The detailed differential diagnosis of individual conditions will be considered in the appropriate sections elsewhere, but here certain general principles are outlined.

Of first importance is the ability to distinguish between organic and non-organic psychiatric illness, in other words to recognise when identifiable brain disorder is the root cause of the presenting clinical picture. The nature of the cerebral disorder must then be determined by a process of enquiry that proceeds logically in accordance with reasonable expectations. A distinction between acute and chronic organic reactions is often helpful in deciding on probabilities, as is the distinction between diffuse or focal cerebral disorder. Thereafter the range of possible causes remains wide, and will also be briefly discussed below.

Differentiation from non-organic conditions

There can be little difficulty in deciding on an organic aetiology when impairment of consciousness or of cognitive processes is marked, when there are epileptic fits, or when psychiatric symptoms are accompanied by obvious neurological symptoms and signs. But this is not always the case. Some organic disorders can present with hallucinations, affective change or schizophrenia-like symptomatology and lack clear organic accompaniments throughout their course. Others unfold very gradually, with indefinite organic features and with symptomatology suggestive of virtually any form of psychiatric illness. Special predisposition to neurotic forms of reaction, or to psychotic illness, may confer distinctive features which for some time obscure the true situation.

Table 1.3 Characteristics of the cortical and subcortical dementias.

Feature	Cortical (e.g. Alzheimer's disease)	Subcortical (e.g. Parkinson's and Huntington's diseases)
Language	Dysphasia early	Reduced output
Memory	Recall and recognition impaired	Some impairment in recall
Visuospatial	Impaired early	Impaired
Calculation	Impaired	Preserved until late
Executive function	Normal early	Reduced, especially spontaneity and flexibility
Psychomotor	Normal early	Slowed
Abnormal movements	None (myoclonus rare)	Chorea, tremor, stooped posture, etc.
Personality/behaviour	Preserved unless 'frontal lobe'	Apathetic, withdrawn
Mood	Euthymic; may lack awareness	Depression common

The converse is also true, since patients with non-organic psychiatric illness may show features that raise the possibility of cerebral disease. For example, disorientation and minor impairment of consciousness may be detected at the onset of acute schizophrenia, also sometimes in mania and agitated depression, yet without evidence of identifiable brain malfunction either at the time or subsequently. Similarly, cognitive impairment, including difficulty with recent memory, may accompany purely affective disorders particularly in later life, as discussed in Chapter 9. Features resembling delirium, including characteristic disturbances of thought processes and even hallucinations, can occur in mania (Hutchinson & David 1997) and follow psychological stress, as in sensory deprivation or sleep deprivation. It is probable that subtle perturbations of brain function underlie all such examples, though these are not yet identifiable by routine clinical investigation; moreover, the possibility of their presence has little practical implication for treatment.

Thus it is clear that the line of demarcation between organic and non-organic psychiatric disorders is not hard and fast, and in a substantial number of cases there can be continuing uncertainty. Some commentators use this to encourage an abandonment of the organic/non-organic distinction as if it were a primitive throwback to Cartesian dualism. However, while neuropsychiatry is the embodiment of an integrated approach to mind and body, it is not an excuse for woolly thinking or for ignoring the very real distinctions between classes of disorder. These distinctions remain valid and useful in practice for the great majority of cases. The margin for error is reduced when investigations are undertaken, but even so is not removed completely. Specialist investigations such as electroencephalography (EEG), psychometric testing, radiographic procedures and functional brain imaging techniques may all be helpful but can be equivocal and even misleading. It is important to remember that the more sensitive the technique, the more likely it is to yield false-positive results. Clinical examination therefore remains of the first importance, and is in any case the chief guideline that determines whether or not special investigations should be undertaken. Examples of patients in whom unusual problems in the differentiation between organic and non-organic disorder have arisen, often with surprising results, have been described by Lishman (1992).

Neurotic disorder may be simulated in the early stages of cerebral disease by virtue of diffuse complaints of anxiety, depression, irritability and insomnia. The patient may himself complain of forgetfulness and difficulty in concentration, but these tend to be discounted because of the multitude of other vague somatic symptoms. Involuntary movements, tremors and akathisia may be put down to simple anxiety. Phobic and obsessional symptomatology is not uncommon at the onset, and may remain a prominent feature for some considerable time. It is also well known that

one must be wary of neurotic developments beginning only in middle life and when the previous mental constitution was good, also to seek for clear evidence of adequate immediate causes for their appearance.

Sometimes the clue may lie in the patient's attitude towards his symptoms. The organic patient will often tend to play down his deficits so that a graver picture is obtained from relatives than from the patient himself. The neurotic patient, by contrast, presses home his symptoms and actively seeks a remedy for them. The patient's evasiveness may raise suspicion, or when pressed he may display abrupt 'catastrophic' reactions of distress or anger. Typically also the organic patient's symptomatology lacks the richness and diversity seen in purely neurotic disorders.

Conversion ('hysterical') disorder may also be simulated by organic conditions. Acute organic reactions tend to fluctuate with periods of lucidity, and symptoms may thus be fleeting. A shallow affective quality and a tendency to make light of symptoms may suggest the *belle indifférence* of hysteria. In mild delirium the cardinal features of impairment of consciousness and subtle deficits of attention may sometimes be hard to determine, and behaviour may be seemingly motivated for display. Thus it may be necessary to watch closely for signs of perseveration, slight dysarthria and other minimal features that betray the organic basis of the disorder.

Episodes of bizarre behaviour in hypoglycaemic attacks, or of paralysis in porphyria, provide well-known diagnostic hazards in which conversion disorders come to be suspected. Similar difficulty is sometimes found with periods of long-continued abnormal behaviour following encephalitis. Frank conversion symptoms may of course occur with chronic brain disease and be mistaken for the primary disorder. It is unclear how far these reflect in some way the direct effects of cerebral damage, or how far they merely represent a psychogenic response to the patient's partial awareness of his deficits. Again, it is axiomatic to view with grave suspicion 'hysterical' symptoms that make their first appearance only in middle life. The problem of the differential diagnosis of pseudodementia is discussed in Chapter 9.

Schizophrenic symptoms in association with cerebral disease can readily be misleading. A preponderance of visual over auditory hallucinations should raise suspicion of an organic disorder, similarly an empty or shallow affective colouring to delusional beliefs and passivity phenomena. Delusions in both acute and chronic organic reactions may take any of the forms seen in schizophrenia, but paranoid delusions are by far the most common. Certain qualities of the delusions strongly suggest an organic basis, namely those which are vague, poorly systematised, incoherent, fleeting and changeable, or restricted and stereotyped in content. Nevertheless, schizophrenic illnesses that are typical in every respect

occasionally prove ultimately to be founded on identifiable cerebral disease. Disorders of the temporal lobes are the most likely to present with schizophrenia-like features.

Depressive symptoms can also give rise to difficulty. Ordinary affective disorder can be associated with marked slowness of thinking, difficulty with concentration and uncertainty with memory. There may be considerable doubt about the correct evaluation of such features, and psychometric testing may give equivocal results. The difficulties are increased when electroconvulsive treatments have already been given.

Features that may help in distinguishing primary depressive illness from organic psychiatric disorder include the careful appraisal of the setting in which disturbances of concentration and memory occur. In depressive illness it can often be observed that lack of interest or excessive anxiety prevent the focusing of attention on the matter in hand, rather than any pervasive difficulty with the organisation of thought and memory. Preoccupation with morbid thoughts may operate similarly. Typically the patient with uncomplicated depression is able to give a more coherent account of his discomforts and a more accurate chronology of his illness than would be possible in the presence of cerebral disease. These important aspects of differential diagnosis are considered more fully in the section on depressive pseudodementia (Chapter 9).

Personality disorder is especially liable to be suspected where frontal lobe dysfunction is concerned, for example following injury or in the early stages of a frontal dementia. Irresponsible behaviour or lapses of social conduct may be attributed to pre-existing personality factors, particularly when there has been some recent stress or problem in the patient's life. Here the essential clue will lie in a careful history from an informant which reveals the change that has occurred. Other avenues to the differential diagnosis are less reliable. Thus the patient may fail to display the classic features of frontal lobe disturbance at interview. And psychometric testing cannot always be relied upon in making the distinction; cognitive ability may be well preserved, and even tests specially devised to reveal frontal deficits can occasionally be misleading. Examples of frontal tumours or chronic infections presenting with change of disposition and behaviour are described in Chapter 2. Functional neuroimaging is increasingly being used to investigate the possibility of focal and generalised cerebral disorders presenting diagnostic difficulties. Frontal lobe dementia is described in Chapter 9. Special difficulty will of course arise in patients whose personality has always been abnormal.

Differentiation between acute and chronic organic reactions

In practice this distinction is most directly made from the history of the mode of onset of the disorder. A short history and firm knowledge of an acute onset will make a chronic

organic reaction unlikely. Onset in association with a physical illness rather strongly suggests an acute organic reaction. However, when such leads are lacking close attention to phenomenology may be necessary.

Acute rather than chronic cerebral disorder is suggested when there are severe perceptual disturbances and distortions, with prominent illusions and hallucinations in the visual modality. Defective appreciation of reality may lead to rich and intrusive fantasies, in contrast to the emptiness and impoverishment of thought characteristic of chronic organic reactions. Similarly, in the presence of florid behaviour disturbance, this will be seen to be dictated by disturbed thought processes of a more sophisticated kind in acute than in chronic cerebral disorder. The affective state of the patient may also help with the distinction. In acute organic reactions the emotional disturbances are typically of a positive kind – fear or terror, perplexity and agitation – whereas the demented patient may be flat, apathetic and emotionally unresponsive. Emotional rapport can usually be established in patients showing clouding of consciousness, but tends to be poor in dementia.

This said, it must be recognised that in practice the differentiation between acute and chronic organic reactions can sometimes be very difficult. Despite careful observation, the distinction may come to be revealed only by the time course that is followed. For example, a prolonged subacute delirious state due to anoxia, uraemia or hepatic disorder can simulate dementia very closely. Or the patient may be admitted to hospital without a history to point to the acute and recent onset of the disorder. Perhaps most difficulty is encountered with elderly patients who show postoperative disturbances, due to metabolic derangements or anoxia, and in whom the mental state was incompletely evaluated beforehand. The electroencephalogram may provide some guidance in such examples (see Chapter 3, under Electroencephalography). The distinction between delirium and dementia may be aided by a simple list of contrasting features compiled by Butler and Zeman (2005) (Table 1.4).

Differentiation between diffuse and focal lesions

Symptoms and signs of localising significance must be carefully sought in all organic psychiatric disorders, and when discovered must not be ignored. Local disturbances of cerebral function can, of course, occur with progressive cortical disease before it is sufficiently extensive to produce a global dementia; well-known examples are a circumscribed amnesic syndrome in the early stages of Alzheimer's disease or a frontal lobe syndrome in Pick's disease (see Chapter 9). Evidence of focal brain damage may also emerge later in the course of such disorders when the pathological changes become especially advanced in certain regions of the brain. Signs of focal damage must therefore be carefully assessed in relation to the clinical picture as a whole, but will usually dictate that further investigations should be under-

Table 1.4 Delirium versus dementia. (From Butler & Zeman 2005.)

Feature	Delirium	Dementia
Onset	Abrupt/subacute	Insidious
Course	Fluctuating	Slow progression
Duration	Hours to weeks	Months to years
Alertness	Abnormally high or low	Typically normal
Sleep-wake cycle	Disrupted	Typically normal
Attention	Impaired	Relatively normal
Orientation	Impaired	Intact in early dementia
Working memory	Impaired	Intact in early dementia
Episodic memory	Impaired	Intact in early dementia
Thought	Disorganised, delusions	Impoverished
Speech	Slow/rapid, incoherent	Word finding difficulty
Perception	Illusions/hallucinations common	Usually intact in early dementia
Behaviour	Withdrawn/agitated	Varies: often intact early

taken. The important problem is to distinguish the essentially focal lesion from diffuse brain damage, because a remediable cause may then come to light. Finally, the neurological examination should always be supplemented by careful enquiry and observation for epileptic disturbances of focal origin.

Psychological symptoms of possible localising value include amnesia out of proportion to other cognitive deficits, dysphasia, somnolence, and the several aspects of parietal lobe symptomatology that have been discussed above. Mild dysphasia due to focal cerebral disease may be mistaken for early dementia when the patient's account is hesitant and incoherent, or when he is anxious and depressed as a result of his disability. However, careful observation usually shows that behaviour not involving language remains substantially intact. Dysphasic difficulties, and especially nominal dysphasia, may be seen with diffuse cerebral disorder, but then insight into the defect is less likely to be well preserved. Agnosic and apraxic deficits, and disturbances of the body image and of spatial orientation, likewise raise suspicion of focal cerebral disorder when severe and out of all proportion to other cognitive difficulties. Such deficits are, however, relatively common in acute organic reactions or when consciousness is impaired to a significant extent, and when chronic diffuse brain disease has progressed beyond the early stages.

Special investigatory procedures, as outlined in Chapter 3, are the most reliable arbiters in the distinction between focal and diffuse brain damage, and will often need to be undertaken before a firm differentiation is achieved.

Causes of acute and chronic organic reactions

The specific cause in the majority of cases will readily become apparent in the course of history-taking and examination. In

many it is self-evident from the outset. Sometimes, however, the cause may be elusive and it is then essential to consider systematically a wide range of possibilities. These are shown in Tables 1.1 and 1.2.

It is helpful in approaching a given case to consider first the possible causes arising within the CNS itself, then derangements of cerebral function consequent upon disorders in other systems of the body. This division is reflected approximately in the ordering of causes in Tables 1.1 and 1.2. Even some of the very rare conditions are remediable, and enquiry must therefore be extensive when the solution is not soon forthcoming.

The antecedent history will give important clues, and it is essential that a relative or close acquaintance should be seen. The time and mode of onset must always be carefully established. The classic presenile and senile dementias usually begin insidiously and their history commonly extends over several months, whereas remediable illnesses often have an abrupt and relatively recent onset. Careful enquiry should always be made for a history of head injury, fits, alcoholism, drug abuse, recent illness or anaesthesia. Even in the absence of known head injury the possibility of subdural haematoma should be kept in mind, since this may follow trivial injury in arteriosclerotic subjects or be forgotten in alcoholics. It may be followed by a latent interval, and be accompanied by minimal neurological signs. A known epileptic tendency may suggest that the present disturbance is an unusually prolonged complex partial seizure or postictal state. Fits of recent onset may indicate a space-occupying lesion, or some acute cerebrovascular accident or injury that has left a residual focus of brain damage. A history of alcoholism or drug abuse may be long concealed in some cases, even on occasion by relatives as well as by the patient. Suspicion may only be raised by indirect evidence from the patient's attitude to enquiry or unwillingness for hospitalisation. A history of

repeated episodes over a considerable period of time may strongly suggest that drug abuse is responsible.

Apart from self-administered drugs, it is always important to enquire about medication recently prescribed. This may have contributed by way of toxic effects, idiosyncratic reactions or the lowering of blood pressure. Diuretics given without proper supervision may have led to electrolyte depletion. If the patient is a known diabetic, enquiry must be made about previous hypoglycaemic reactions, the current dose of insulin and the current diet. The list of drugs that can affect cognitive functions is almost limitless and idiosyncratic reactions are always possible. Hence a high index of suspicion is required. A useful update on medications with propensity to cause neuropsychiatric effects is provided by Turjanski and Lloyd (2005).

A history of recent illness and operation should be noted, and also the quality of recovery from any recent anaesthetic. Previous episodes of dysphasia, paralysis or other neurological deficit will be suggestive of cerebral arterial disease. Any indications that the patient may be at risk of HIV infection should be noted, also a family history of illness such as Huntington's disease.

In patients with acute organic reactions it is still important to enquire for an antecedent history of failing memory or intellect over some period of time, since an incipient chronic dementia may be being aggravated by intercurrent disease. The adequacy of diet should be assessed in elderly patients, especially when living alone, or in patients of low intelligence and low economic means. Vitamin depletion is certainly not excluded in patients suffering from presenile or senile dementing illnesses and may be adding to the disability. Finally, in the more immediate history, specific enquiry should always be made for headache, vomiting or visual disturbance indicative of raised intracranial pressure, and in Elderly patients for breathlessness, ankle swelling or substernal pain which may indicate recent cardiac decompensation.

On examination one must pay attention to any appearance of physical ill health which may be token metabolic disorder, carcinoma or an infective process. The general appearance of the patient may indicate anaemia, or an endocrine disorder such as myxoedema that is otherwise easily missed. Dehydration may suggest uraemia or diabetic precoma. Muscular twitching suggests uraemia, electrolyte disturbance or hypoglycaemia. There may be skin lesions diagnostic of exanthemata or indicative of vitamin deficiency. It may be necessary to search closely, by 4-hourly temperature recording, for evidence of low-grade intermittent pyrexia indicating, for example, encephalitis or cerebral abscess. Finally, very careful general observation may sometimes reveal the choreiform movements diagnostic of early Huntington's chorea.

Examination of the CNS must pay careful attention to the optic fundi for signs of raised intracranial pressure, to abnormalities of pupil size or reactions indicative of syphilis, or

nystagmus which may suggest drug intoxication. Transient disorders of external ocular movement may be the essential sign for confirming a diagnosis of Wernicke's encephalopathy. Evidence of focal neurological defects in motor or sensory systems (including unsuspected visual field defects) will suggest a space-occupying lesion or cerebrovascular disease. Neck stiffness may indicate subarachnoid haemorrhage or meningitis, and evidence of recent ear infection will raise the possibility of cerebral abscess.

Signs of arteriosclerosis should be noted both at the periphery and in the optic fundi. The patency of the carotid arteries should be tested by palpation and auscultation in the neck. Hypertension must be assessed, likewise evidence of cardiac failure, heart block or recent coronary infarction. Respiratory infection or inadequacy must also be noted as possible causes of cerebral anoxia. Even in the absence of hepatic or splenic enlargement it may be necessary to examine for liver flap, spider naevi or fetor hepaticus. It can be important to examine for prostatic enlargement. Carcinoma with secondary cerebral deposits, or secondary 'remote' effects upon the CNS, may need to be excluded by palpation of breasts, neck, axillae, and rectal and vaginal examinations. A chest X-ray will be obligatory for exclusion of carcinoma of the lung.

Investigations in every case should include haematology, erythrocyte sedimentation rate, blood urea, serum electrolytes and proteins, liver function tests, serum thyroxine, estimation of blood sugar, serological tests for syphilis, urine examination and chest radiography, no matter what may appear to be the cause. Skull radiography and EEG may be required, and computerised tomography (CT) or magnetic resonance imaging (MRI) will quite often be undertaken. It may be necessary to proceed with estimation of serum B₁₂ and folate, or urinary examination for drugs or evidence of porphyria. An electrocardiogram may be indicated if silent myocardial infarction or Stokes-Adams attacks are suspected, along with other cardiovascular specialist investigations such as echocardiography, Doppler studies of the carotid arteries and coagulation screens. Immunological tests for autoantibodies and paraneoplastic markers may be valuable. The problems surrounding HIV testing and the need to obtain informed consent beforehand are discussed in Chapter 7. Lumbar puncture will sometimes be required when the diagnosis remains in doubt, in particular to confirm suspicions of intracranial infection. Further investigations such as a radioisotope scan or angiography will sometimes be indicated, though CT and MRI have greatly reduced the need for these.

Causes of stupor

Mention may be made of the differential diagnosis of stupor. The causes may be organic or non-organic, and the differential diagnosis must embrace schizophrenia, depression and hysteria in addition to organic brain dysfunction.

Joyston-Bechal (1966) examined the records of 100 cases of stupor diagnosed at the Bethlem Royal and Maudsley Hospitals in order to obtain an indication of the frequency of different causes. In this setting organic causes are seen in one-fifth. The essential features of the stupor were closely similar in the organic and non-organic cases. In 14 cases, the cause remained uncertain. Sometimes the true situation was unclear at the time of the patient's presentation, but was revealed in retrospect when the stupor had resolved. A more recent series (Johnson 1984) had twice the prevalence of 'organic' cases. This may reflect advances in diagnostic techniques, especially non-invasive neuroimaging. In Joyston-Bechal's (1966) series almost half of the stupors resolved within a week, and only one-fifth lasted more than a month. The six patients who remained in stupor for more than 6 months were all severely brain damaged.

Knowledge of the antecedent psychiatric history is often invaluable in suggesting the cause, and a careful neurological examination is always essential with special attention to signs that may indicate a diencephalic or upper brainstem lesion (see Diencephalon and brainstem, earlier in chapter). Patients with stupor due to non-organic psychiatric illness are more likely to show some partial preservation of ability to help with feeding or eliminative functions, though this is by no means invariable. The facial expression and posture is also more likely to be meaningful or show some emotional reaction to what is said or done. On recovery, patients with non-organic stupors often prove to have retained awareness of what transpired during the episode, whereas in organic stupor the level of awareness as well as the level of responsiveness is usually severely diminished.

Schizophrenic stupor is mainly a catatonic phenomenon, and is usually seen along with other catatonic features such as negativism, echopraxia, posturing or *flexibilitas cerea*. It tends to carry a poor prognosis in the long term. The patient's posture is often fixed and bizarre, and may have symbolic meaning in connection with his delusions. When disturbed the special posture is often resumed. The facial expression may be secretive or withdrawn, and may betray attention to hallucinatory experiences. Some schizophrenic stupors appear to represent withdrawal into a world of delusional fantasies, whereas in others it seems that nothing at all is experienced by the patient. The latter may represent a prolongation in severe form of schizophrenic blocking of thought and of willed action. After acute treatment with, for example, lorazepam or electroconvulsive therapy (ECT), some patients may dramatically recover and may then be able to explain that their immobile state was a response to beliefs or hallucinatory injunctions. In other cases the patient apparently has no recollection of the episode. An important diagnosis to consider is neuroleptic malignant syndrome, an idiosyncratic response to many antipsychotic drugs (see Chapter 11); regardless of cause, some authorities advocate ECT as an effective treatment (Fink & Taylor 2001).

Depressive stupor may occasionally be just as profound as the above, and the differentiation can be difficult if the antecedent psychiatric history is unknown. Usually it can be seen to develop out of severe psychomotor retardation, which increases until there is universal motor inhibition. The posture and expression are sometimes indicative of sadness and hopelessness, and silent tears may be shed. Sometimes, however, the expression is apathetic and vacant. Conscious awareness is usually fully retained and the patient can later relate most of what was said and done to him.

Manic stupor is usually described as uncommon. The expression may be of elation or ecstasy, and the patient may later report that his mind was filled with teeming ideas to the extent that he was unable to react to anything around him. Surprisingly, in Abrams and Taylor's (1976) prospective study of catatonic patients, mania emerged as the commonest diagnosis, applying also to the subgroup who had shown stupor.

Hysterical and psychogenic stupors usually occur in a situation of stress, and manifest superficial motives can often be discerned. Signs of conversion hysteria are commonly in evidence. The condition is more likely than others to wax and wane, and there may be a marked emotional reaction when sensitive subjects are discussed. Completely passive dependence on others for feeding and toilet functions is rare, and the patient may show signs of irritability and annoyance when moved against his wishes.

Organic stupor has many causes, the most urgent of which is raised intracranial pressure producing a medullary or midbrain pressure cone. Focal pathologies in the region of the posterior diencephalon or upper midbrain include tumours (especially craniopharyngiomas), infarctions, meningitis (especially tuberculous meningitis), neurosyphilis and formerly encephalitis lethargica. Senile or presenile dementias may lead to stupor late in their course, likewise HIV-associated dementia. Complex partial seizures may take this form, or alternatively stupor may follow briefly in the wake of an epileptic seizure.

When a brain lesion is responsible for stupor, the site will commonly lie in the upper brainstem or mesencephalon. Sometimes, however, it is due to involvement of the anteromedial frontal lobes and adjacent septal area (Segarra 1970). With stupors of brainstem origin the patient tends to be apathetic and somnolent most of the time and will frequently show pareses of external ocular movement. Patients with frontal stupor are more likely to appear alert, ready to be roused and with seeming vigilant gaze (hyperpathic akinetic mutism). Lesions of the anterior conglutinate and its subcortical connections seem to be implicated (Mega & Cohenour 1997).

Extracerebral causes that must be considered include a number of the conditions listed in Table 1.1. Pictures typical of stupor may occasionally be seen with uraemia, hypoglycaemia or liver disorder, or postoperatively with electrolyte

disturbance or water intoxication. Endocrine disorders include myxoedema, Cushing's disease, Addison's disease, hypopituitarism and hyperparathyroidism. Stupor may also emerge with severe alcoholic intoxication, other intoxications, nicotinic acid deficiency encephalopathy, or terminally with certain infections such as typhus fever. It is important to remember that it can occasionally be seen as an adverse reaction to psychotropic medication; in Johnson's (1982) series of 25 cases, two were due to intoxication with lithium and one to excessive medication with flupenthixol. The neuroleptic malignant syndrome in either its full-blown or partial form should also be considered in any person exposed to antipsychotic drugs presenting with stupor and abnormally increased muscle tone. The presence of pyrexia and a raised creatine phosphokinase level form part of the diagnostic criteria.

Fortunately, with the great majority of organic causes there will be evidence of neurological dysfunction or systemic disturbance. In equivocal cases the EEG is often helpful in deciding between a psychiatric or a neurological aetiology. The absence of alpha rhythm and reduced reactivity is expected while faster rhythms may indicate a toxic or drug-induced state. Triphasic waves may be seen in hepatic and renal insufficiency in young adults and spindle coma patterns are believed to indicate brainstem dysfunction; the EEG may reveal previously unsuspected non-convulsive status epilepticus (Kaplan 2004). When psychogenic causes are suspected, an interview under Sodium amytal or a benzodiazepine may confirm the situation, while in schizophrenic and depressive stupors the response to ECT can be dramatic.

Causes of mutism

Mutism is rarely an isolated phenomenon, often occurring along with catatonic signs such as negativism, stereotypy, posturing or stupor. It may therefore be associated with the several psychiatric conditions discussed above. Important organic causes include head injury, posterior fossa surgery, encephalitis, frontal lobe lesions, the postictal phase of epilepsy, and endocrine disorders including hyperparathyroidism, myxoedema, diabetic ketoacidosis and Addison's disease (Gordon 2001). Complete speechlessness is rare in aphasic disorders since there is frequently some attempt to communicate or vocalise. The exception is the end stage of frontotemporal dementia.

Mutism without catatonic features may also be due to organic or non-organic causes. Dissociative states are among the commoner associated conditions, though here it is essential that severe dysphasia is excluded, as outlined in Chapter 2, Conversion disorders. In younger people, elective mutism is a relatively common reaction to a range of emotional disturbances and social anxiety.

Altshuler *et al.* (1986) drew together collected series of patients presenting with mutism and attempted to assess the

Table 1.5 Causes of mutism. (After Altshuler *et al.* 1986.)

All causes	Organic causes		
Schizophrenia	6	Stroke	4
Schizoaffective disorder	2	Postencephalitic disturbance	2
Other psychosis	1	Organic affective disorder	2
Affective disorder	3	Organic delusion syndrome	1
Organic disease	10	Phencyclidine psychosis	1
Total	22	Total	10

frequency of various causes. The pooled results showed that some 40% were likely to have affective disorder, 30% schizophrenia, 9% personality disorder and 17% an organic cerebral cause. In the remainder the responsible factors were uncertain. The diagnoses in these authors' own series of 22 patients presenting over a 2-year period are shown in Table 1.5; 14 of these had shown additional catatonic signs but eight had presented with mutism alone. Not uncommonly organic causes had been overlooked initially, for example in a patient with stroke who was first diagnosed as having hysterical aphonia, and in a patient with herpes encephalitis who was first thought to have catatonic schizophrenia. This emphasises the importance of careful neurological examination in every case.

Features stressed by Altshuler *et al.* as important in pointing to a neurological cause include irregular respiration, abnormal pupil responses, roving eye movements, facial weakness and an exaggerated jaw jerk. A psychiatric cause is suggested in patients who resist eye opening. Occasionally patients with a primary psychiatric disorder may be induced to whisper or communicate in writing, though the latter may also occur with infarctions leading to pure word-dumbness as described in Chapter 2 (Pure word-dumbness). The presence of accompanying catatonic phenomena cannot be relied upon as aiding the distinction between organic and non-organic causes. Again, however, an abreactive interview can often be informative.

References

- Abrams, R. & Taylor, M.A. (1976) Catatonia: a prospective clinical study. *Archives of General Psychiatry* **33**, 579–581.
- Allison, R.S. (1962) *The Senile Brain: A Clinical Study*. Edward Arnold, London.
- Altshuler, L.L., Cummings, J.L. & Mills, M.J. (1986) Mutism: review, differential diagnosis, and report of 22 cases. *American Journal of Psychiatry* **143**, 1409–1414.
- American Psychiatric Association (1994) *Diagnostic and Statistical Manual of Mental Disorders*, 4th edn. American Psychiatric Association, Washington, DC.
- Barker, M.G. & Lawson, J.S. (1968) Nominal aphasia in dementia. *British Journal of Psychiatry* **114**, 1351–1356.
- Berlyne, N. (1972) Confabulation. *British Journal of Psychiatry* **120**, 31–39.

- Bonhoeffer, K. (1909) Exogenous psychoses. *Zentralblatt für Nervenheilkunde* **32**, 499–505. Translated by H. Marshall, in Hirsch, S.R. & Shepherd, M. (eds) *Themes and Variations in European Psychiatry*. John Wright, Bristol, 1974.
- Britton, A. & Russell, R. (2004) Multidisciplinary team interventions for delirium in patients with chronic impairment. Cochrane Database of Systematic Reviews, CD000395.
- Burns, A., Gallagley, A. & Byrne, J. (2004) Delirium. *Journal of Neurology, Neurosurgery and Psychiatry* **75**, 362–367.
- Butler, C. & Zeman, A.Z.J. (2005) Neurological syndromes which can be mistaken for psychiatric conditions. *Journal of Neurology, Neurosurgery and Psychiatry* **76** (suppl. 1), 31–38.
- Cummings, J.L. (1992) Psychosis in neurologic disease. Neurobiology and pathogenesis. *Neuropsychiatry, Neuropsychology and Behavioral Neurology* **5**, 144–150.
- Ellis, H.D. & Lewis, M.B. (2001) Capgras delusion: a window on face recognition. *Trends in Cognitive Science* **5**, 149–156.
- Fink, M. & Taylor, M.A. (2001) The many varieties of catatonia. *European Archives of Psychiatry and Clinical Neuroscience* **251** (suppl. 1), I8–I13.
- Francis, J., Martin, D. & Kapoor, W.N. (1990) A prospective study of delirium in hospitalized elderly. *JAMA* **263**, 1097–1101.
- Geschwind, N. (1965) Disconnexion syndromes in animals and man. *Brain* **88**, 237–294, 585–644.
- Gordon, N. (2001) Mutism: elective or selective, and acquired. *Brain and Development* **23**, 83–87.
- Hutchinson, G. & David, A. (1997) Manic pseudo-delirium: 2 case reports. *Behavioural Neurology* **10**, 21–23.
- Johnson, J. (1982) Stupor: its diagnosis and management. *British Journal of Hospital Medicine* **27**, 530–532.
- Johnson, J. (1984) Stupor: a review of 25 cases. *Acta Psychiatrica Scandinavica* **70**, 370–377.
- Joyston-Bechal, M.P. (1966) The clinical features and outcome of stupor. *British Journal of Psychiatry* **117**, 967–981.
- Kaplan, P.W. (2004) The EEG in metabolic encephalopathy and coma. *Journal of Clinical Neurophysiology* **21**, 307–318.
- Lipowski, Z.J. (1980) *Delirium: Acute Brain Failure in Man*. Charles C. Thomas, Springfield, IL.
- Lipowski, Z.J. (1990) *Delirium: Acute Confusional States*, 2nd edn. Oxford University Press, Oxford.
- Liptzin, B. & Levkoff, S.E. (1992) An empirical study of delirium subtypes. *British Journal of Psychiatry* **161**, 843–845.
- Lishman, W.A. (1992) Neuropsychiatry. A delicate balance. *Psychosomatics* **33**, 4–9.
- Mega, M.S. & Cohenour, R.C. (1997) Akinetic mutism: disconnection of frontal–subcortical circuits. *Neuropsychiatry, Neuropsychology and Behavioral Neurology* **10**, 254–259.
- Roth, M. & Myers, D.H. (1969) The diagnosis of dementia. *British Journal of Hospital Medicine* **2**, 705–717.
- Segarra, J.M. (1970) Cerebral vascular disease and behavior. 1 The syndrome of the mesencephalic artery (basilar artery bifurcation). *Archives of Neurology* **22**, 408–418.
- Turjanski, N. & Lloyd, G.G. (2005) Psychiatric side-effects of medications: recent developments. *Advances in Psychiatric Treatment* **11**, 58–70.
- World Health Organization (1992) *The ICD-10 Classification of Mental and Behavioural Disorders: Clinical Descriptions and Diagnostic Guidelines*. World Health Organization, Geneva.

