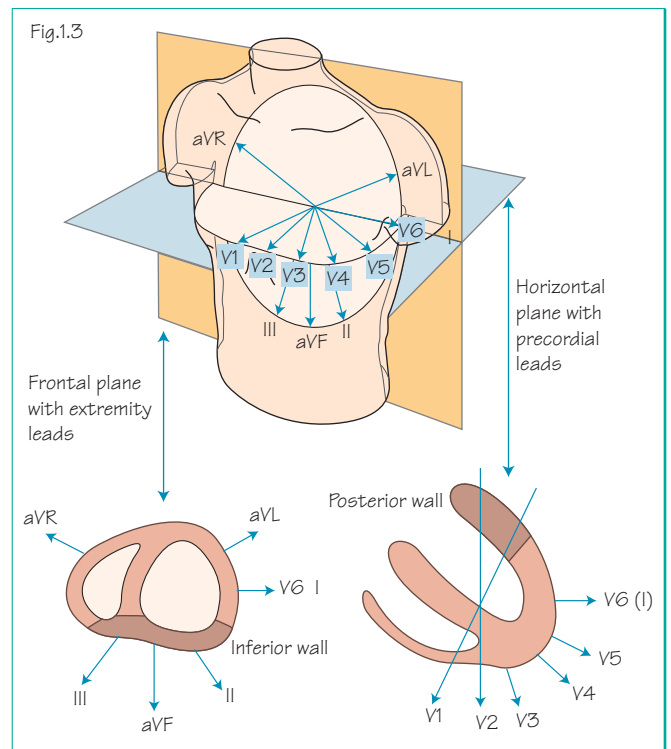
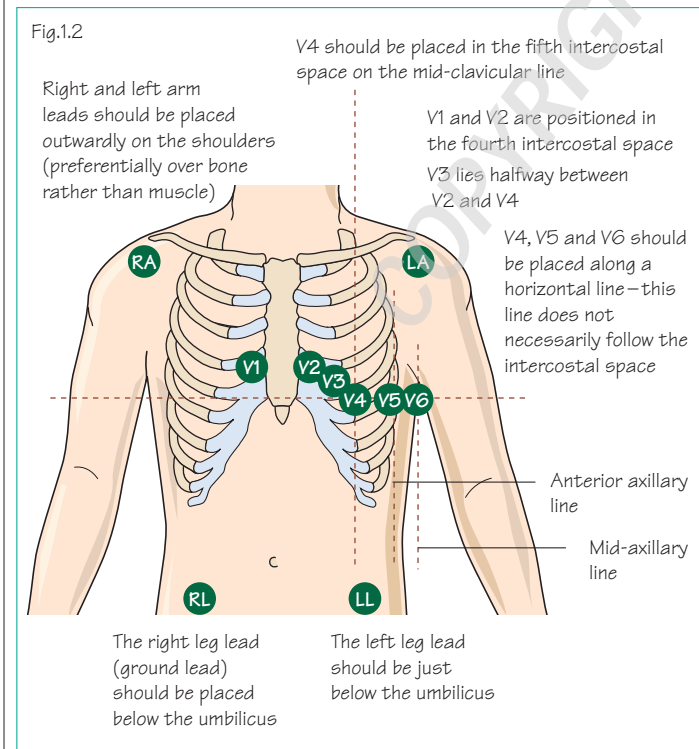
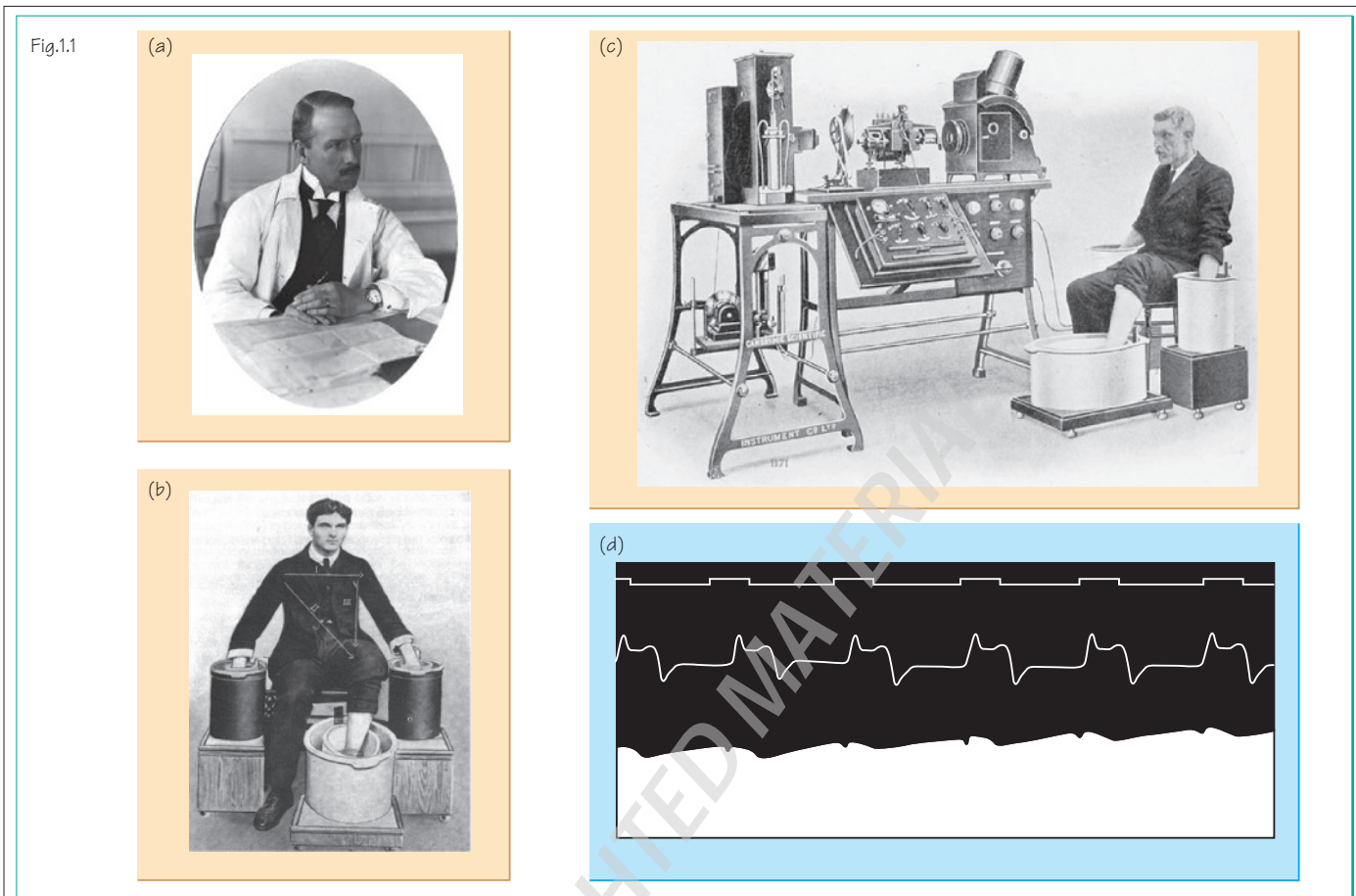


1 Introduction to the ECG



The electrocardiogram (ECG) is a wonderful tool, cheap, widely available, and incredibly useful. It informs diagnosis, guides and assesses the response to therapy and provides vital data on prognosis. In epidemiological use it gives great insights, e.g. it informs us that 30% of myocardial infarctions (MIs) are clinically silent, and that hypertensive heart disease when associated with certain ECG changes has a high mortality. The ECG informs us not only in acquired heart disease but also in genetic disease, e.g. hereditary long QT or Brugada syndrome. The diagnostic role extends beyond cardiac disease to pulmonary emboli, electrolyte imbalance, rheumatic disease, fitness level, liver disease, diabetes, starvation, etc. It is probably the most useful investigative tool in the whole of medicine.

A brief history of the ECG

The development of the ECG started in the mid 19th century with ideas concerning the role of electricity in the heart, then with the development of increasingly sensitive ways to measure this electricity. The early ECG machines were vast and required a water-cooled jacket! Technological advances in the early 20th century saw recording devices become increasingly small and by 1928 weighed 'only' 50 lbs (22 kg), described as being 'portable'. Weight and size reduction continued and current devices weigh only a few pounds. The modern 12 leads of the ECG were formalized in 1942, with:

- the addition of the three augmented limb leads (aVR, aVL and aVF) of Emanuel Goldberger; to the
- pre-existing three standard leads (I, II, III) so fully explored by the 'greats' of the ECG, Einthoven, Lewis, Mackenzie, and Wilson; and the
- six chest leads (V for voltage 1–6, the technical aspects being formalized in 1938 by the American Heart Association and the British Cardiac Society).

Subsequent years saw an explosion in ECG-based research, and > 150 000 articles on the ECG have now been published!

The ECG in arrhythmias

The early use of the ECG was in arrhythmias, with the classic finding of Wenckebach in 1899 (Wenckebach block), of John Hay in Liverpool in 1905 (Mobitz type II block) and Arthur Cushny, a London professor, in 1907 on atrial fibrillation, an arrhythmia subsequently greatly investigated by Thomas Lewis (University College Hospital, London). Lewis obtained an ECG from a horse with atrial fibrillation and confirmed the diagnosis by examining the atria when the horse was slaughtered! Einthoven made vital contributions and earned the Nobel prize in 1924, the same year that Mobitz published his seminal ECG findings in second degree heart block. The surface ECG findings in many cardiac

arrhythmias were elucidated in the mid 20th century, leading inexorably to greater understanding and better treatment. Catheters allowing the recording of intracardiac ECG signals became available in the mid-century, leading logically to protocols to stimulate the heart to provoke arrhythmias (the electrophysiological study). These intracardiac recordings led to major progress in the diagnosis and treatment of arrhythmias. The external ambulatory recorder, developed by the Montana physician Holter in the 1950s led to discoveries in arrhythmias, circadian rhythm, and cardiac autonomic function (heart rate variability). Technology allowed the development of implantable ECG recorders (the Reveal device), and defined the role of the tilt-table test and carotid sinus massage. Advances continue, e.g. the discovery of the genetic pro-arrhythmic disease by the Brugada brothers in 1992.

The ECG and arrhythmia device therapy

Pacing therapy for slow heart beats had been known of for many years before external devices (bulky and unreliable) became available in 1952. The real breakthrough came in 1958 with the first implantable pacemaker. Subsequent years saw increasing miniaturization, longer battery life, sensing functions and full programmability. Though the knowledge that large direct current applied across the heart could terminate ventricular fibrillation was known from the work of Prevost and Batelli, professors at Geneva, from 1899, it was not until 1947 that Beck, in Cleveland was able to successfully demonstrate defibrillation from ventricular fibrillation (VF) during heart surgery. This led to successful closed chest cardioversion in 1956, and by the 1960s external defibrillators were routinely saving many lives. A logical development was the internal defibrillator, widely available by the mid 1990s. Even more recent is cardiac resynchronization therapy, useful in treating heart failure.

The ECG and coronary disease

The early 19th century saw the discovery of the classic changes of 'full-thickness' myocardial infarction and angina. It was realized early on that many patients with coronary disease had normal resting ECGs. Using exercise to provoke angina, and then record an ECG became widely accepted by the middle third of the century and in 1963 Bruce proposed his classic exercise test. The ability to diagnose coronary disease became widespread, underpinning both the need for and the development of coronary angiography and revascularization. In the 1980s the role of thrombolytic therapy in ST segment elevation but not non-ST segment MI was understood. The role of the ECG in risk stratifying MI continues to evolve, with multiple ECG-based risk scores now available.

Fig. 1.1 (a) Willem Einthoven, in the early 1900s. (b) Early ECG recording required the arms and legs to be placed in saline buckets. (c) An early ECG machine. (d) One of the first ECGs recorded by Augustus Waller (top trace = time, middle trace = chest wall motion, bottom strip = the ECG).

Fig. 1.2 ECG lead placement for an exercise ECG – in a resting ECG the leads to the legs are attached to electrodes just above the

ankles. The ECG can be extended further beyond V6, to include leads V7–9, which extend posteriorly on the left chest. The leads can also be extended further rightward beyond lead V1, as 'right-sided chest leads'.

Fig. 1.3 The direction from which the basic 12-leads of the ECG examine the heart.