

---

# Functional Anatomy of the Equine Musculoskeletal System

## ANATOMIC NOMENCLATURE AND USAGE

Informative and logical names for parts of the horse's body, as well as positional and directional terms, have evolved through the efforts of nomenclature committees. *Nomina Anatomica Veterinaria* is the standard reference in veterinary science. Some older terminology is still widely used. For example, the following are acceptable synonyms: navicular bone for distal sesamoid bone, coffin joint for distal interphalangeal joint, pastern joint for proximal interphalangeal joint, and fetlock joint for metacarpophalangeal joint. It is useful to be familiar with the older terms because many times they are used interchangeably.

Figure 1.1 provides the appropriate directional terms for veterinary anatomy. With the exception of the eye, the terms anterior and posterior are not applicable to quadrupeds. Cranial and caudal apply to the limbs proximal to the antebrachiocondylar (radiocarpal) joint and the tarsocrural (tibiotarsal) joint. Distal to these joints, dorsal and palmar (on the forelimb) or plantar (on the hindlimb) are the correct terms. The term "solar" is used to designate structures on the palmar (plantar) surface of the distal phalanx and the ground surface of the hoof.

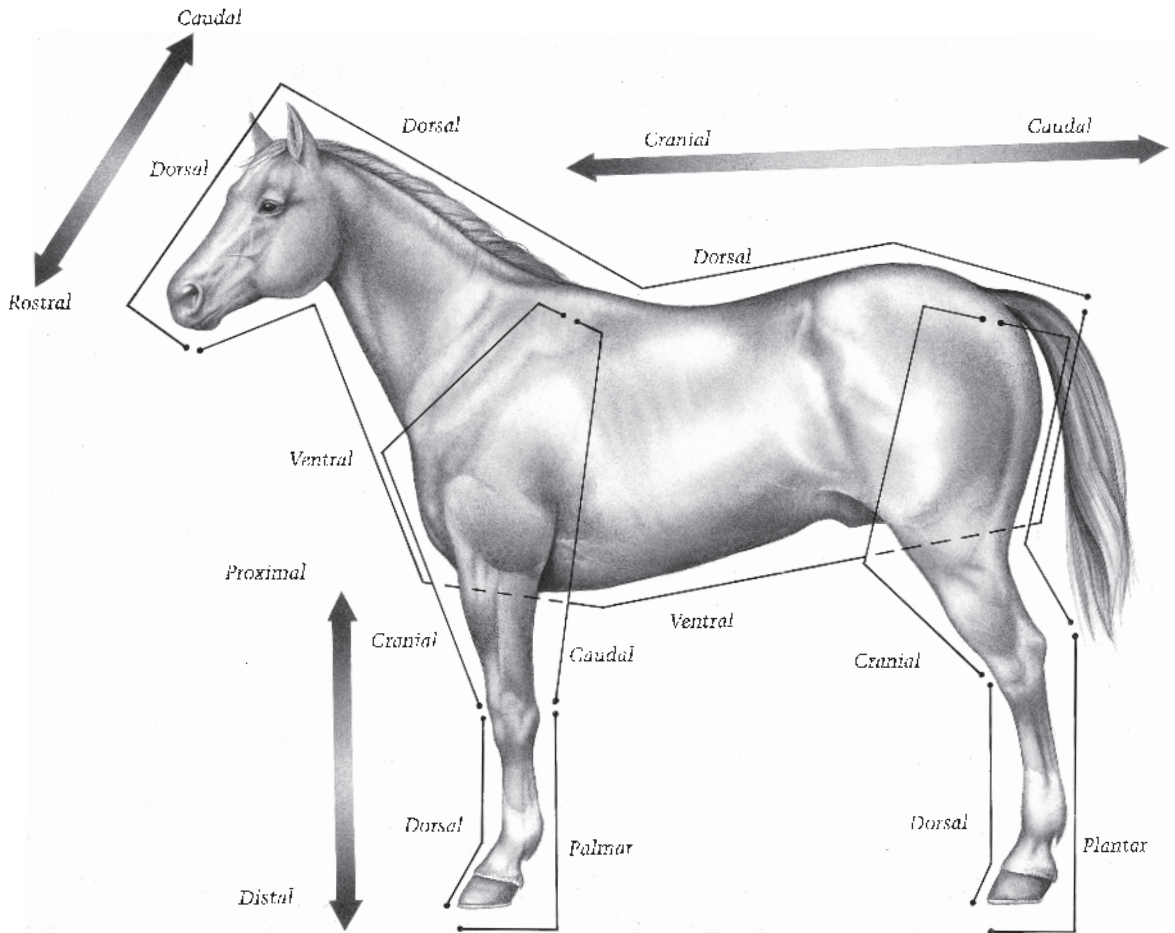
## THORACIC LIMB

### Digit and Fetlock

The foot and pastern comprise the equine digit, a region including the distal (third), middle (second), and proximal (first) phalanges and associated structures (Figure 1.2). The fetlock joint consists of the metacarpophalangeal (fetlock) joint and the structures surrounding it. The digits and fetlocks of the thoracic limb and the pelvic limbs are similar in most respects. The term "palmar" is used when referring to structures of the forelimb, whereas "plantar" is used when referring to the hindlimb.

### Foot

The foot consists of the epidermal hoof and all it encloses: the connective tissue corium (dermis), digital cushion, distal phalanx (coffin bone), most of the cartilages of the distal phalanx, distal interphalangeal (coffin) joint, distal extremity of the middle phalanx (short pastern bone), distal sesamoid (navicular) bone, podotrochlear bursa (navicular bursa), several ligaments, tendons of insertion of the common digital extensor and deep digital flexor muscles, blood vessels, and nerves. Skin between the heels is also part of the foot.



**Figure 1.1.** Positional and directional terms.

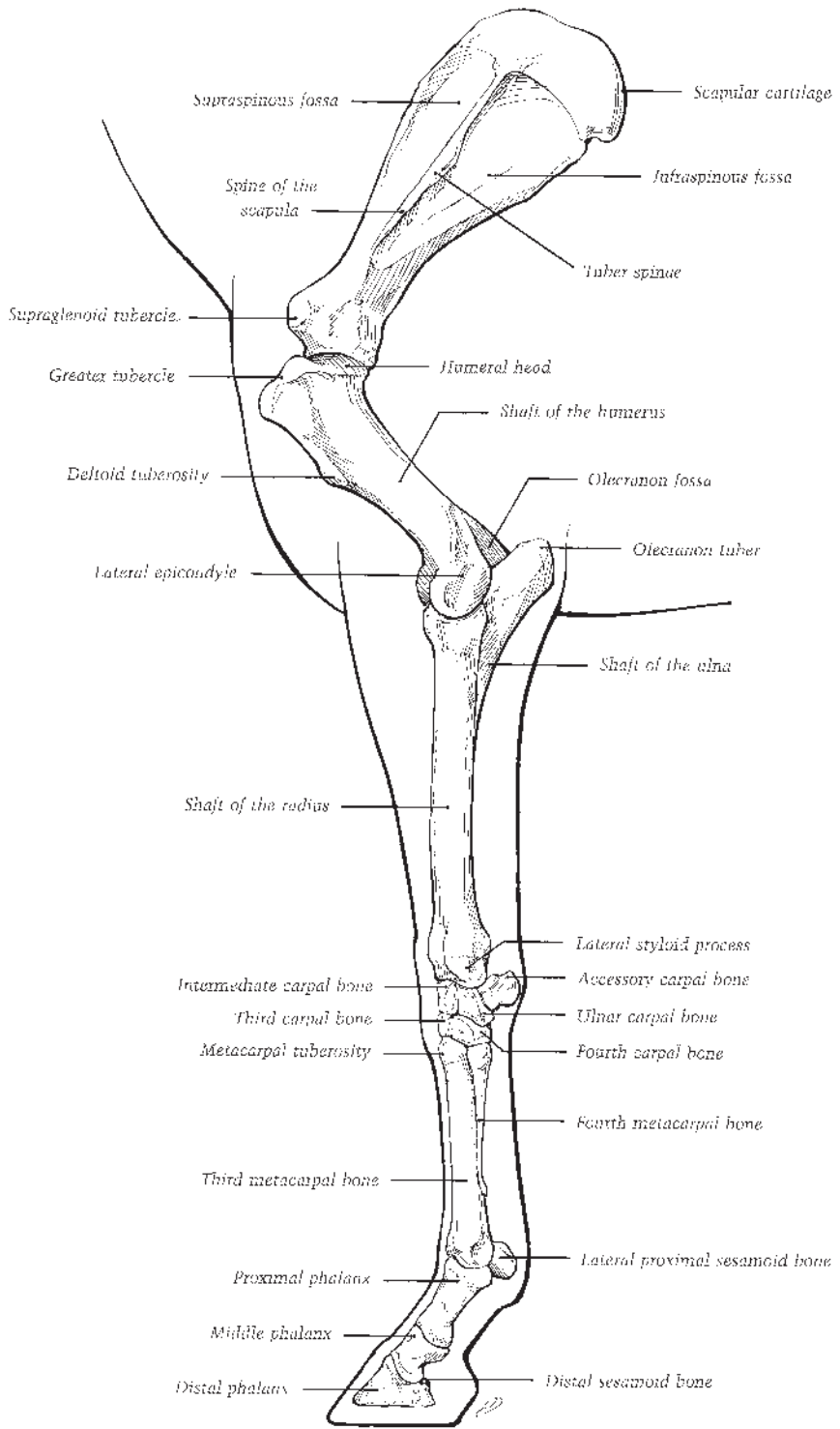
### HOOF WALL, SOLE, AND FROG

The hoof is continuous with the epidermis at the coronet. Here the dermis of the skin is continuous with the dermis (corium) deep to the hoof. Regions of the corium correspond to the parts of the hoof under which they are located: perioplic corium, coronary corium, laminar (lamellar) corium, corium of the frog, and corium of the sole. Examination of the ground surface of the hoof reveals the sole, frog, heels, bars, and ground surface of the wall (Figure 1.3). The ground surface of the forefoot is normally larger than that of the hind foot, reflecting the shape of the distal surface of the enclosed distal phalanx.

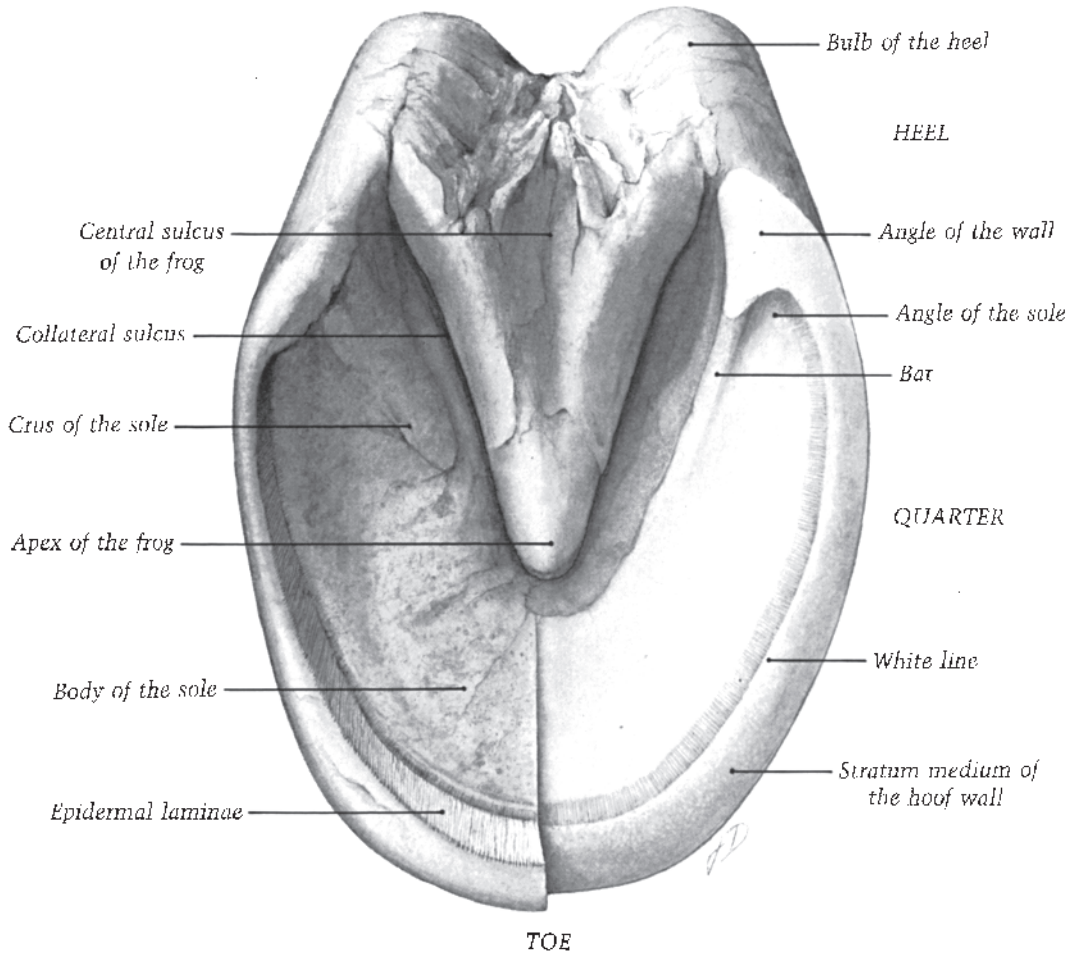
The hoof wall extends from the ground proximal to the coronary border where the soft white

horn of the periople joins the epidermis of the skin at the coronet. The regions of the wall are the toe, medial and lateral quarters, and heels (Figures 1.3, 1.4). From the thick toe, the wall becomes progressively thinner and more elastic toward the heels, where it thickens again where it reflects dorsad as the bars. Ranges for the angle of the toe between the dorsal surface of the hoof wall and the ground surface of the hoof vary widely. In the ideal digit, the dorsal surface of the hoof wall and the dorsal surface of the pastern should be parallel, reflecting the axial alignment of the phalanges.

The highly vascular and densely innervated collagenous connective tissue of the coronary corium (dermis) gives rise to elongated, distally directed papillae. Laminar (lamellar) corium



**Figure 1.2.** Bones of the left equine thoracic limb (lateral view).



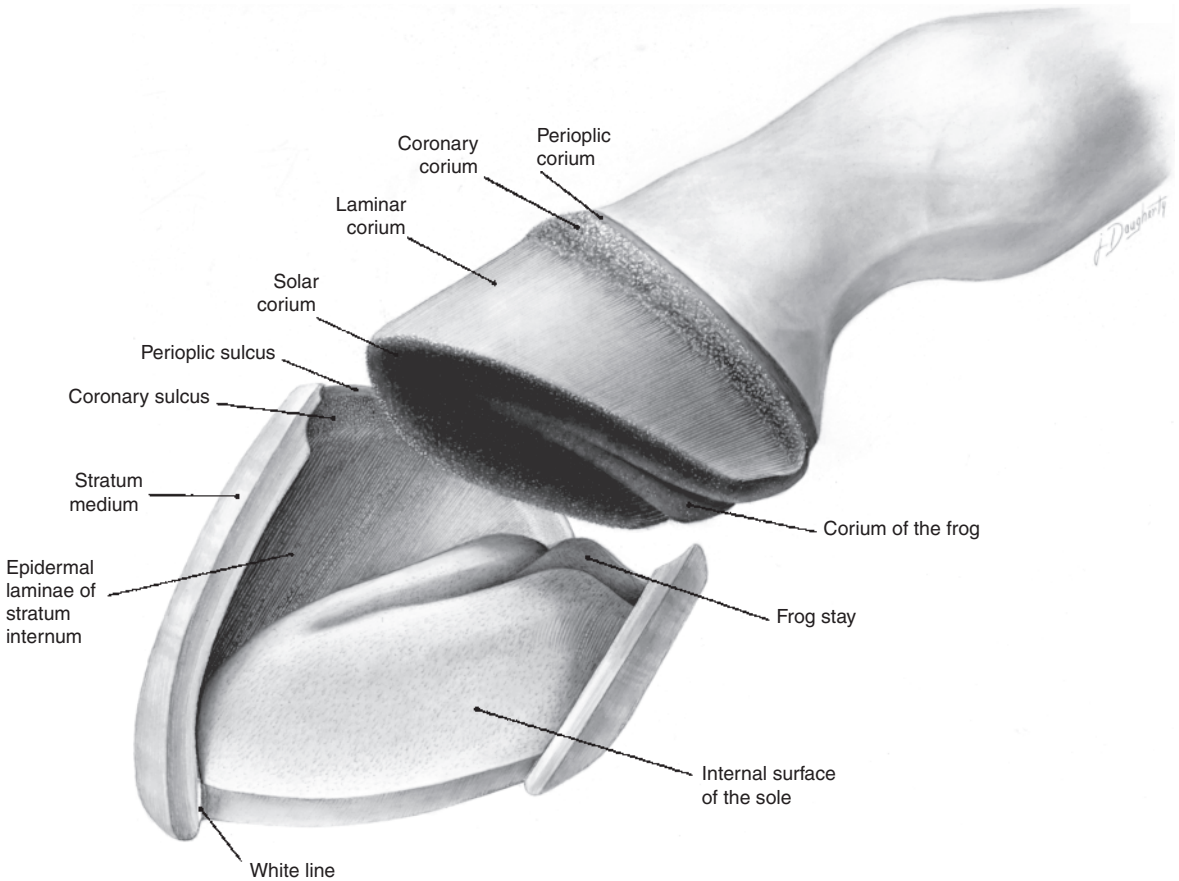
**Figure 1.3.** Topography of the solar surface of the hoof. The right half has been trimmed to emphasize the region of the white line.

forms a series of laminae that interdigitate with epidermal laminae of the stratum internum of the hoof wall. Shorter papillae extend from the periopic, solar, and cuneate (frog) coria. The corium provides sensation as well as nourishment and attachment for the overlying stratified squamous epithelium comprising the ungual epidermis (hoof).

Three layers comprise the hoof wall: the stratum externum, stratum medium, and stratum internum (Figure 1.5). The superficial stratum externum is a thin layer of horn extending distad from the coronet a variable distance; this thin, soft layer, commonly called the periople, wears from the surface of the hoof wall so that it is present only on the bulbs of the heels and the proximal parts of the hoof wall. The bulk of the

wall is a stratum medium consisting of horn tubules and intertubular horn. Horn tubules are generated by the stratum basale of the coronary epidermis covering the long papillae of the coronary corium. Intertubular horn is formed in between the projections.

Distal to the coronary groove, about 600 primary epidermal laminae of the stratum internum interweave with the primary dermal laminae of the lamellar corium (Figures 1.6, 1.7). Approximately 100 microscopic secondary laminae branch at an angle from each primary lamina, further binding the hoof and corium together (Figure 1.6). There is some confusion concerning the terms “insensitive” and “sensitive” laminae. In the strictest sense the keratinized parts of the primary epidermal laminae are



**Figure 1.4.** Dissected view of the relationship of the hoof to underlying regions of the corium (dermis).

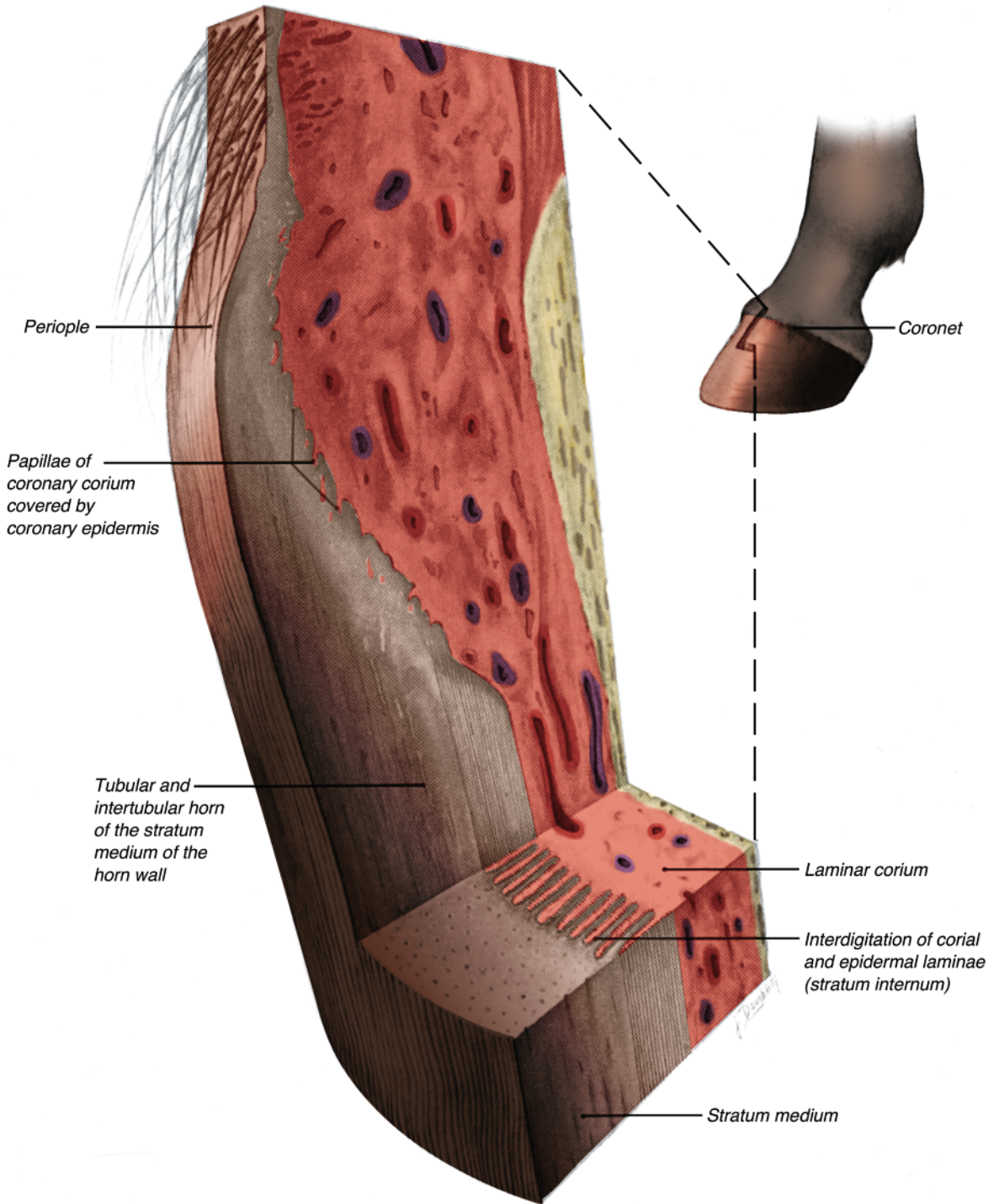
insensitive; the stratum basale, which includes all of the secondary epidermal laminae, and the laminar corium are “sensitive.” The terms “epidermal” and “dermal” (or corial) are more accurate adjectives to describe the laminae.

Growth of the hoof wall is primarily from the basal layer of the coronary epidermis toward the ground. The growth of the wall progresses at the rate of approximately 6 mm/month, taking nine to 12 months for the toe to grow out. The wall grows more slowly in a cold environment. Growth also is slower in a dry environment when adequate moisture is not present in the wall. The hoof wall grows evenly distal to the coronary epidermis so that the youngest portion of the wall is at the heel (where it is shortest). Because this is the youngest part of the wall, it is also the most elastic, aiding in heel expansion during concussion. Contrary to popular belief, there is no difference in the stress-strain behavior or ultimate strength properties of pigmented and

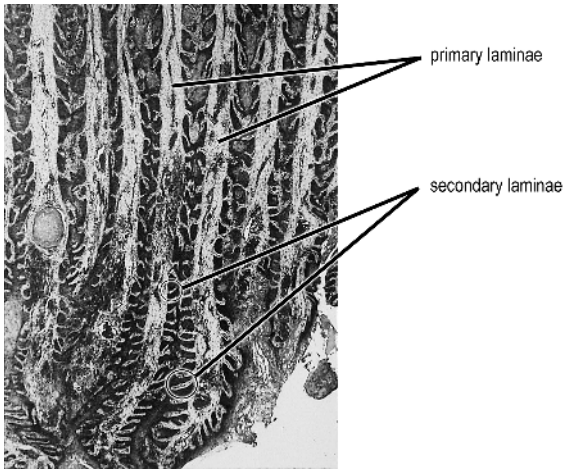
nonpigmented equine hooves. Water content of the hoof significantly affects its mechanical properties. A very dry or extremely hydrated hoof wall is more likely to crack than a normally hydrated hoof wall.

The frog (cuneus unguulae) is a wedge-shaped mass of keratinized stratified squamous epithelium rendered softer than other parts of the hoof by an increased water content. Apocrine glands, spherical masses of tubules in the corium of the frog, extend ducts that deliver secretions to the surface of the frog. The ground surface of the frog presents a pointed apex and central sulcus enclosed by two crura. Paracuneal (collateral) sulci separate the crura of the frog from the bars and the sole. The palmar aspect of the frog blends into the bulbs of the heels.

The coronary and periopic coria and the stratum basale of the coronary and periopic epidermis constitute the coronary band. Deep to the coronary band the subcutis is modified into the



**Figure 1.5.** Three-dimensional dissection of the coronary region of the hoof wall.



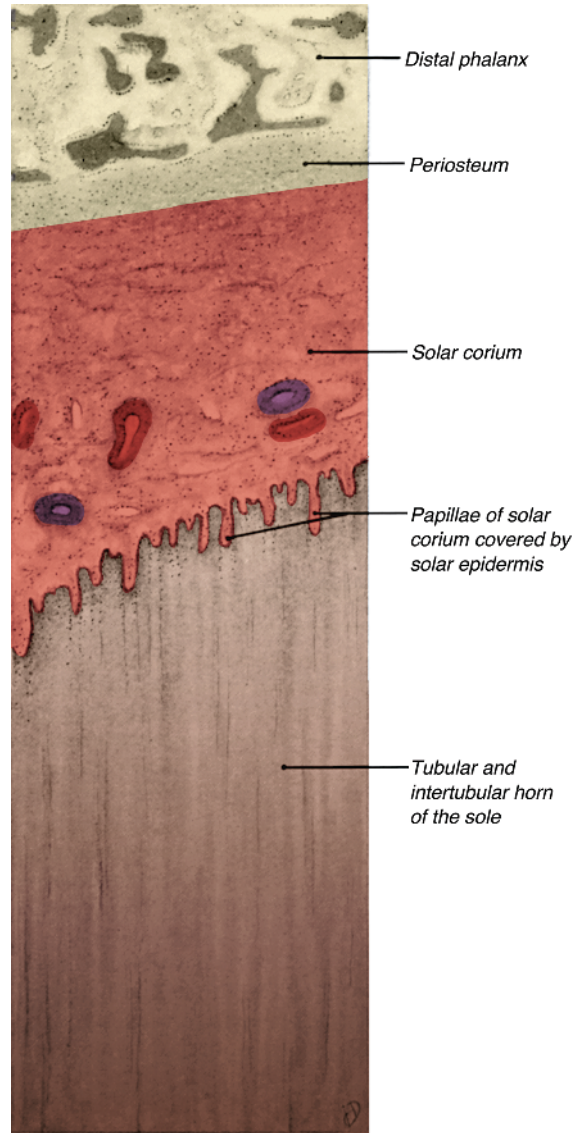
**Figure 1.6.** Photomicrograph of a cross section of equine hoof. Interdigitations of primary epidermal laminae and dermal (corial) laminae can be appreciated. Notice the small secondary laminae.

highly elastic coronary cushion. The coronary band and cushion form the bulging mass that fits into the coronary groove of the hoof. Part of the coronary venous plexus is within the coronary cushion. The plexus receives blood from the dorsal venous plexus in the laminar corium. Where the corium is adjacent to the distal phalanx, it blends with the bone's periosteum, serving (particularly in the laminar region) to connect the hoof to the bone (Figure 1.7).

#### INTERNAL STRUCTURES OF THE FOOT

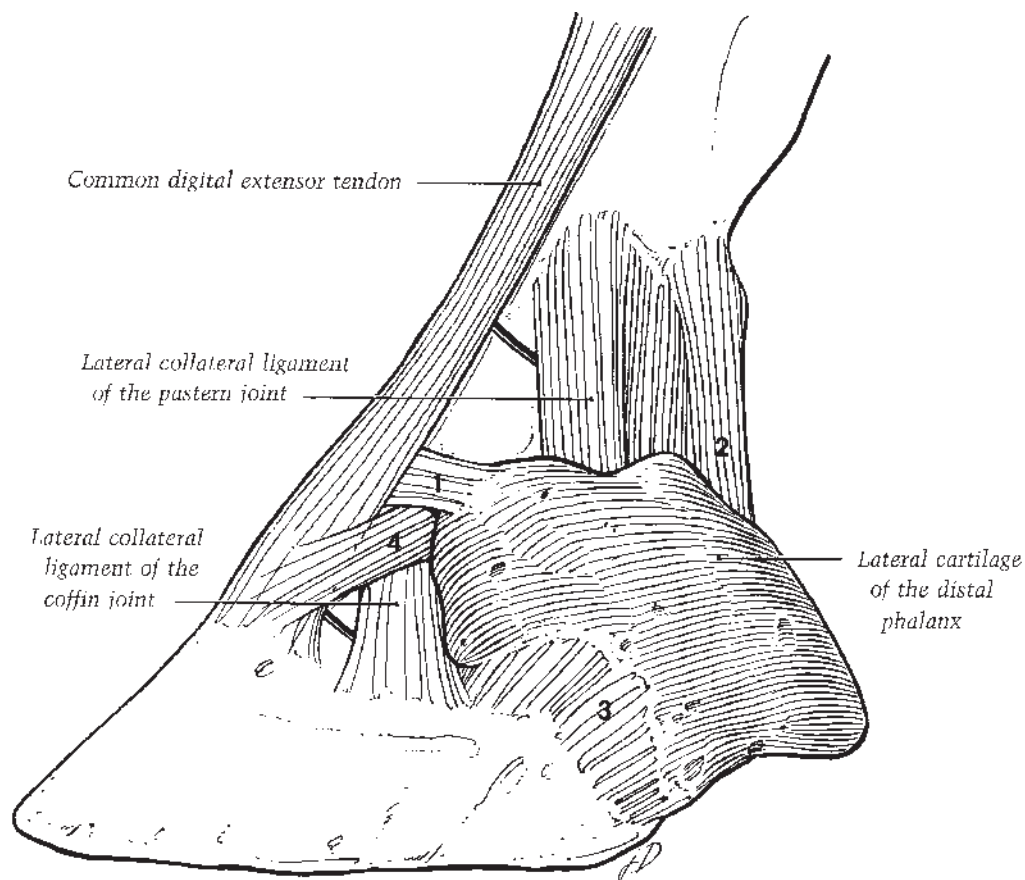
The medial and lateral cartilages of the distal phalanx (ungual cartilages) lie under the corium of the hoof and the skin, covered on their abaxial surfaces by the coronary venous plexus. They extend from each palmar process of the bone proximal to the coronary border of the hoof, where they may be palpated. The cartilages are concave on their axial surfaces, convex on their abaxial surfaces, and thicker distally where they attach to the bone. Toward the heels they curve toward one another. Each cartilage is perforated in its palmar half by several foramina for the passage of veins connecting the palmar venous plexus with the coronary venous plexus.

Five ligaments stabilize each cartilage of the distal phalanx (Figures 1.8, 1.9). Filling in between the cartilages is the digital cushion, a highly modified subcutis consisting of a meshwork of collagenous and elastic fibers, adipose tissue, and small masses of fibrocartilage (Figure



**Figure 1.7.** Histological relationship of the periosteum, corium, and horn of the sole.

1.9). Only a few blood vessels ramify in the digital cushion. Dorsoproximally the digital cushion connects with the distal digital annular ligament. The apex of the wedge-shaped digital cushion is attached to the deep digital flexor tendon (DDFT) as the latter inserts on the solar surface of the distal phalanx. The base of the digital cushion bulges into the bulbs of the heels, which are separated superficially by a central shallow groove. The structure and relationships of the digital cushion indicate its anticoncussive function.



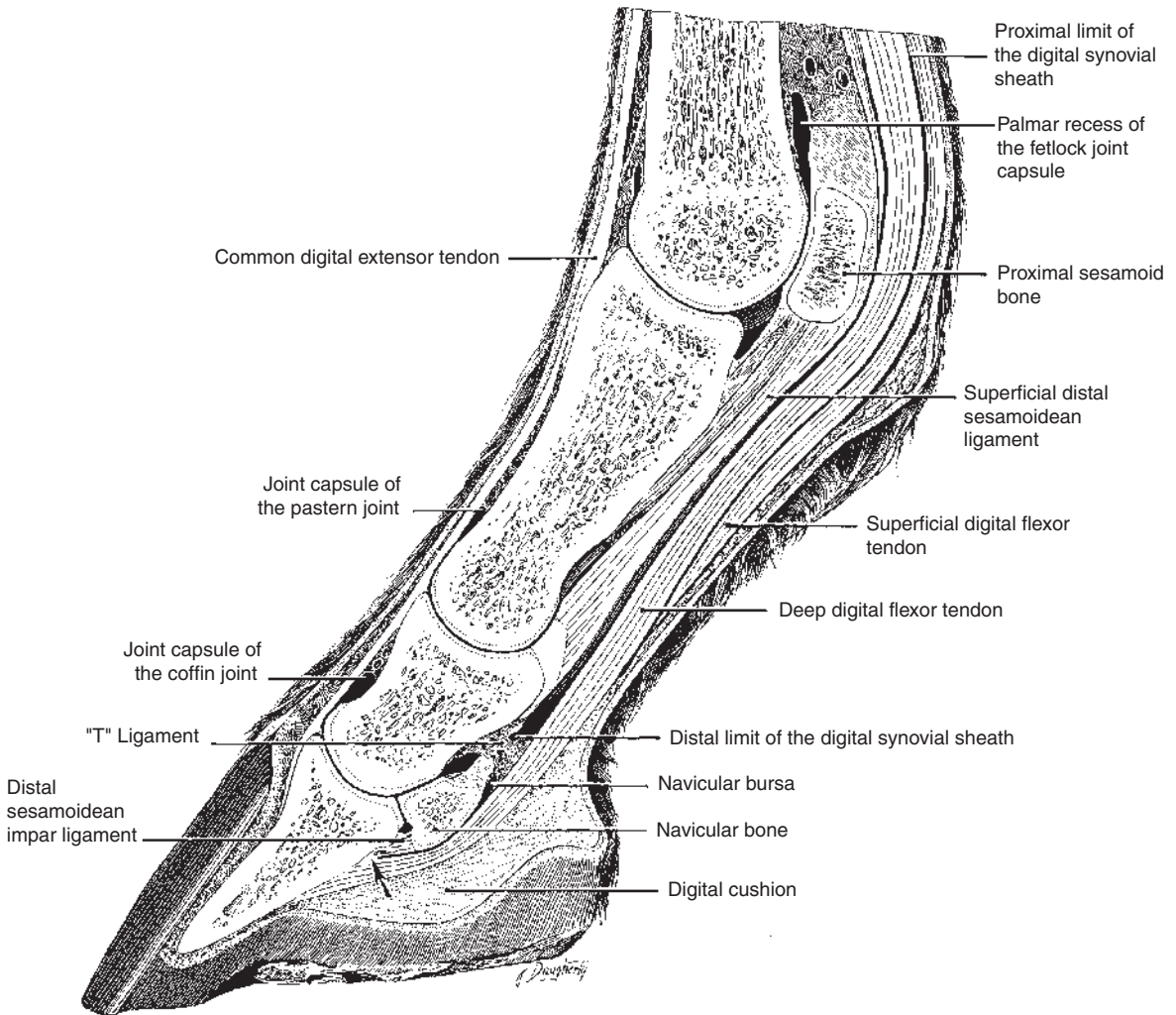
**Figure 1.8.** Four of the ligaments (1, 2, 3, and 4) that stabilize the cartilage of the distal phalanx.

As the DDFt courses to its insertion on the distal phalanx, it is bound down by the distal digital anular ligament (Figure 1.10) and passes over the complementary fibrocartilage, a fibrocartilaginous plate extending from the proximal extremity of the palmar surface of the middle phalanx. Then the tendon gives off two secondary attachments to the distal aspect of the palmar surface of the bone (Figure 1.11). Continuing distad toward its primary attachment on the flexor surface of the distal phalanx, the DDFt passes over the navicular bursa (bursa podotrochlearis) interposed between the tendon and the fibrocartilaginous distal scutum covering the flexor surface of the navicular bone.

The proximal border of the navicular bone presents a groove containing foramina for passage of small vessels and nerves. The distal border of the bone has a small, elongated facet that articulates with the distal phalanx. Several

variously enlarged, foramina-containing fossae lie in an elongated depression palmar to that facet (Figure 1.12). Two concave areas on the main articular surface of the navicular bone contact the distal articular surface of the middle phalanx. The navicular bone is supported in its position by three ligaments comprising the navicular suspensory apparatus. A collateral sesamoidean (suspensory navicular) ligament arises from the distal end of the proximal phalanx (Figures 1.10, 1.11). These collateral sesamoidean ligaments sweep obliquely distad, each ligament crossing the pastern joint, and then giving off a branch that joins the end of the navicular bone to the cartilage of the distal phalanx. Each collateral sesamoidean ligament terminates by attaching to the proximal border of the navicular bone and joining with the contralateral ligament. Distally, the navicular bone is stabilized by the distal sesamoidean impar ligament, a fibrous





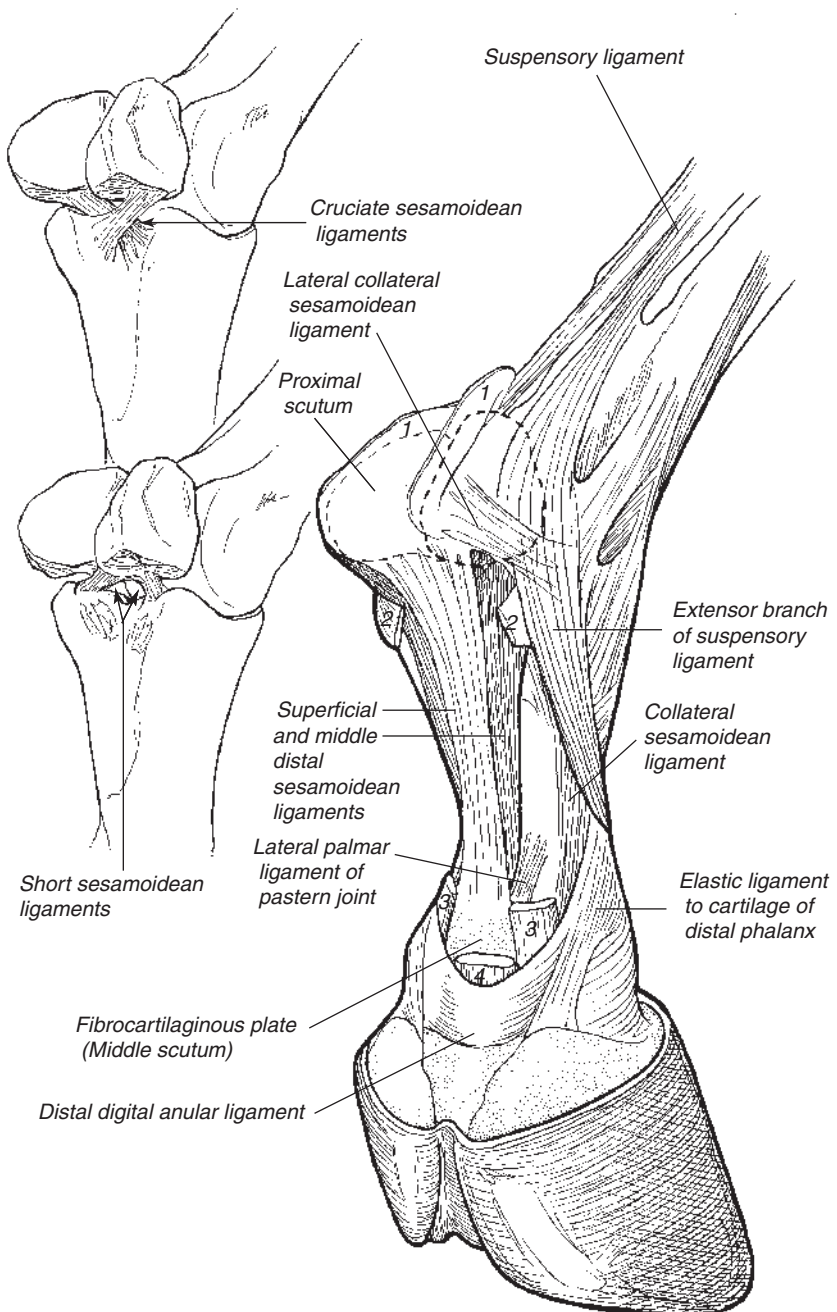
**Figure 1.9.** Sagittal section of the equine fetlock and digit.

sheet extending from the distal border of the bone to intersect with the DDFT (Figure 1.9).

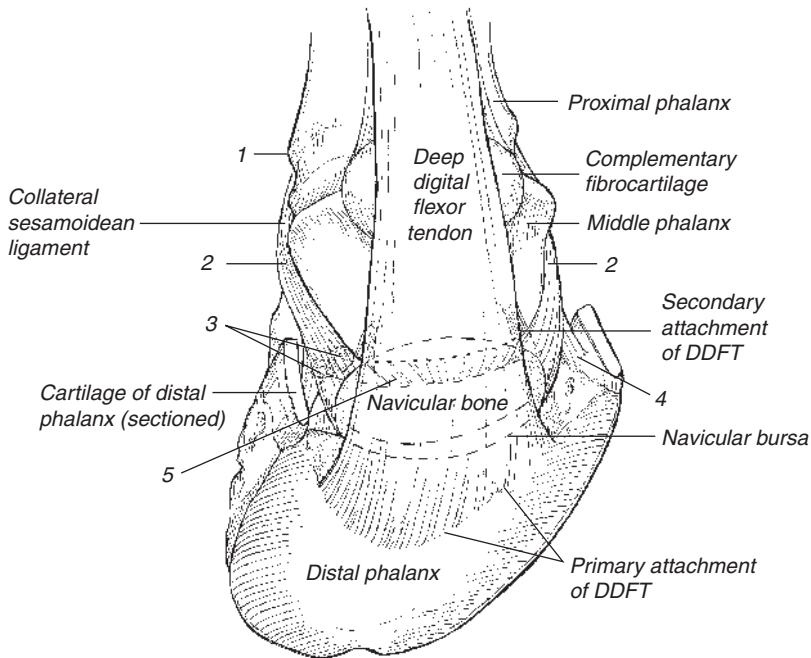
The distal articular surface of the middle phalanx, the articular surface of the distal phalanx, and the two articular surfaces of the navicular bone form the coffin joint, a ginglymus of limited range of motion. Short collateral ligaments arise from the distal end of the middle phalanx, pass distad deep to the cartilages of the distal phalanx, and terminate on either side of the extensor process and the dorsal part of each cartilage.

The synovial membrane of the coffin joint has a dorsal pouch that extends proximad on the dorsal surface of the middle phalanx under the common digital extensor tendon nearly to

the pastern joint. The synovium has a complex relationship on its palmar side to the ligaments and tendons that are found there. The proximal portions wrap around the distal ends of the collateral sesamoidean ligament and the distal palmar pouch forms a thin extension between the articulation of the navicular bone and the distal phalanx. Distally, this pouch's synovial membrane surrounds the distal sesamoidean impar ligament on each side where the DIP joint is closely associated with the neurovascular bundle that will enter the distal phalanx. Although a direct connection between the DIP joint and the navicular bursa is rare, passive diffusion of injected dye, anesthetics, and medications is thought to occur.

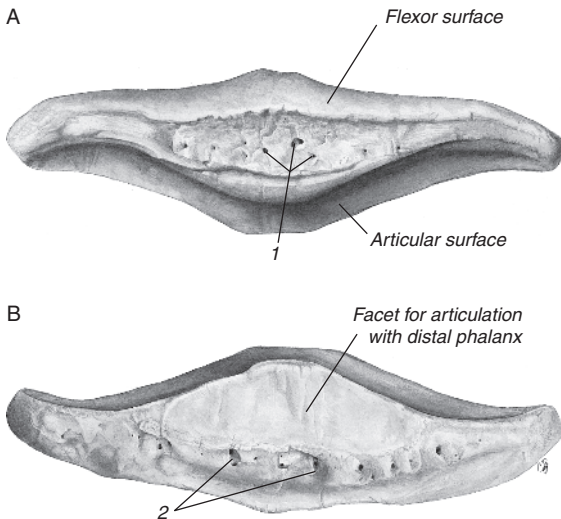


**Figure 1.10.** Sesamoidean ligaments. Dashed lines indicate positions of the proximal sesamoid bones embedded in the metacarpointersesamoidean ligament. Numbers indicate cut stumps of (1) palmar anular ligament, (2) proximal digital anular ligament, (3) superficial digital flexor, and (4) deep digital flexor tendon.



**Figure 1.11.** Attachments of the deep digital flexor tendon and collateral sesamoidean ligaments (CSL).

(1) Attachment of the CSL to the proximal phalanx, (2) attachment of the CSL to the middle phalanx, (3) abaxial outpocketings of the palmar pouch of the synovial cavity of the distal interphalangeal joint, (4) attachment of the CSL to cartilage of the distal phalanx, (5) attachment of the medial and lateral CSLs to the navicular bone.



**Figure 1.12.** Distal sesamoid (navicular) bone. (A) Proximal view. (B) Distal view. (1) Foramina, (2) fossae.

## Pastern

Deep to the skin and superficial fascia on the palmar aspect of the pastern, the proximal digital annular ligament adheres to the superficial digital flexor tendon (SDFT) and extends to the medial and lateral borders of the proximal phalanx (long pastern bone). This fibrous band of deep fascia covers the SDFT as it bifurcates into two branches that insert on the proximal extremity of the middle phalanx just palmar to the collateral ligaments of the proximal interphalangeal (PIP; pastern) joint. The DDFT descends between the two branches of the SDFT and the digital flexor tendon sheath (DFTS) enfolds both tendons as far distally as the so-called “T ligament” (Figure 1.9). The latter is a fibrous partition attaching to the middle of the palmar surface of the middle phalanx.

Deep to the digital flexor tendons a series of ligaments referred to as distal sesamoidean ligaments (DSLs) extends distad from the bases of the two proximal sesamoid bones. The superficial straight sesamoidean ligament attaches distally to the fibrocartilaginous plate on the

proximal extremity of the palmar surface of the middle phalanx, the triangular middle (oblique) sesamoidean ligament attaches distally to a rough area on the palmar surface of the proximal phalanx, and the deep pair of cruciate ligaments cross, each attaching distally to the contralateral eminence on the proximal extremity of the proximal phalanx (Figure 1.10). A short sesamoidean ligament extends from the dorsal aspect of the base of each proximal sesamoid bone to the palmar edge of the articular surface of the proximal phalanx (Figure 1.10).

The pastern joint is formed by two convex areas on the distal extremity of the proximal phalanx and two corresponding concave areas expanded by a palmar fibrocartilaginous plate on the proximal extremity of the middle phalanx. Bones of the pastern joint are held together by two short collateral ligaments and four palmar ligaments. A central pair of palmar ligaments extends from the triangular rough surface on the proximal phalanx to the palmar margin of the proximal extremity of the middle phalanx; medial and lateral palmar ligaments pass from the proximal phalanx to the palmar surface of the proximal extremity of the middle phalanx. The joint capsule of the pastern joint blends with the deep surface of the common digital extensor tendon dorsally (Figure 1.9) and with the collateral ligaments of the joint. The palmar aspect of the capsule extends slightly proximad, compressed between the middle phalanx and the terminal branches of the SDFT and the straight sesamoidean ligament. These taut, overlying structures subdivide the capsule into medial and lateral pouches that are accessible for arthrocentesis.

### Fetlock

The fetlock of the thoracic limb is the region around the metacarpophalangeal (MCP) joint. Deep to the skin and superficial fascia, the palmar annular ligament of the fetlock binds the digital flexor tendons and their enclosing digital sheath in the sesamoid groove. The smooth depression between the proximal sesamoid bones through which the digital flexor tendons pass is formed by the fibrocartilage of the metacarpointersesamoidean ligament which covers the flexor surfaces of the proximal sesamoid bones. Immediately distal to the canal formed by the palmar annular ligament of the fetlock, the DDFT perforates through a circular opening in the SDFT, the manaca flexoria.

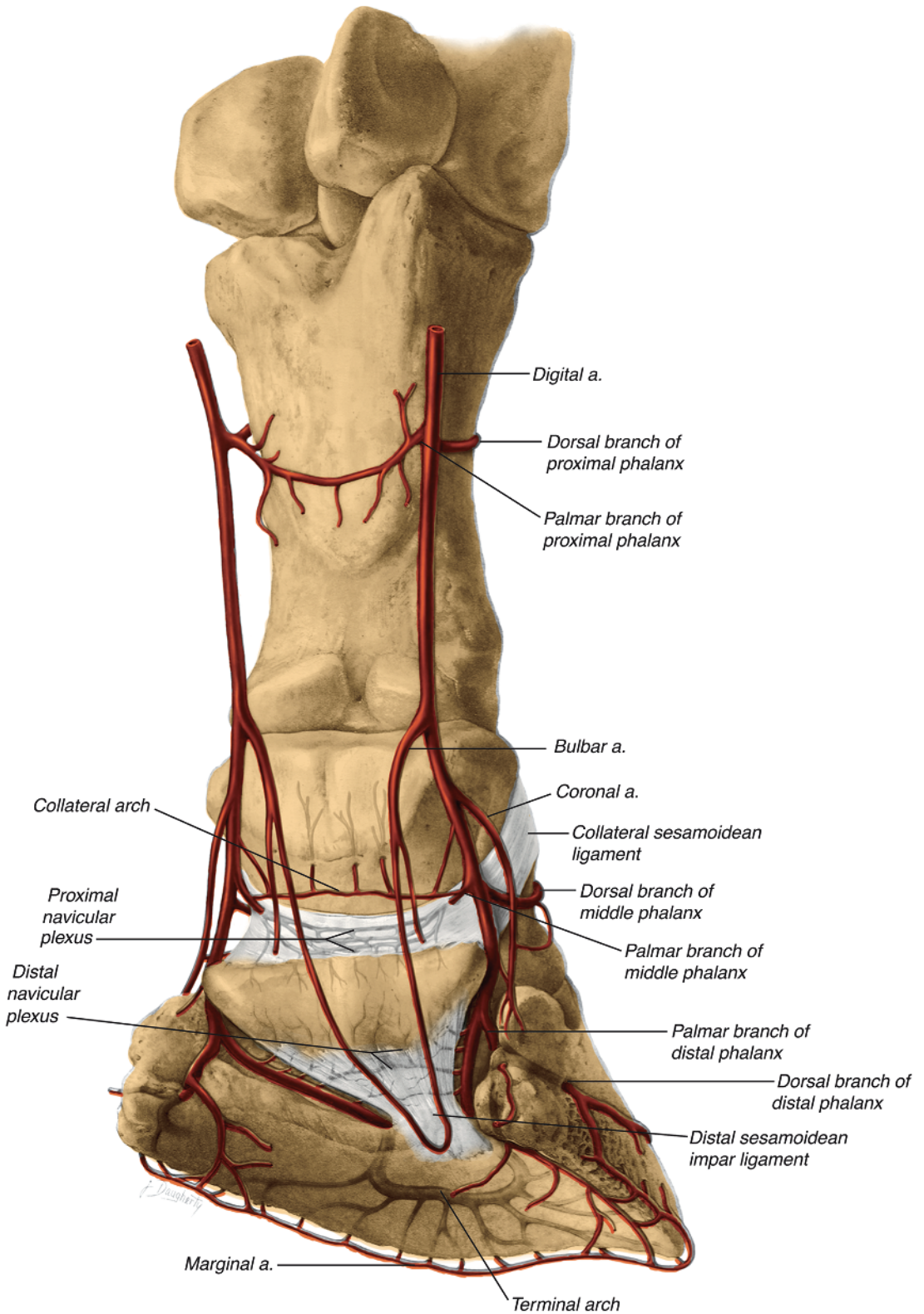
The distal extremity of the cannon bone, the proximal extremity of the proximal phalanx, the two proximal sesamoid bones, and the fibrocartilaginous metacarpointersesamoidean ligament in which the proximal sesamoids are embedded form the MCP joint. A somewhat cylindrical articular surface on MCIII/MTIII is divided by a sagittal ridge, and this surface fits into an accommodating depression formed by the proximal phalanx, the proximal sesamoid bones, and the metacarpointersesamoidean ligament. Collateral ligaments of the fetlock joint extend distad from the eminence and depression on each side of the third metacarpal bone. The superficial part of each ligament attaches distally to the edge of the articular surface of the proximal phalanx; the shorter, stouter deep part of the ligament attaches to the abaxial surface of the adjacent proximal sesamoid and the proximal phalanx.

The palmar part of the fetlock joint capsule is thicker and more voluminous than the dorsal part. A palmar recess (pouch) of the fetlock joint capsule extends proximad between the third metacarpal bone and the suspensory ligament. This pouch is palpable and even visible when the joint is inflamed, distending the palmar recess with synovial fluid. The joint capsule is reinforced on each side by the collateral ligaments and dorsally by fascia attaching to the common digital extensor tendon.

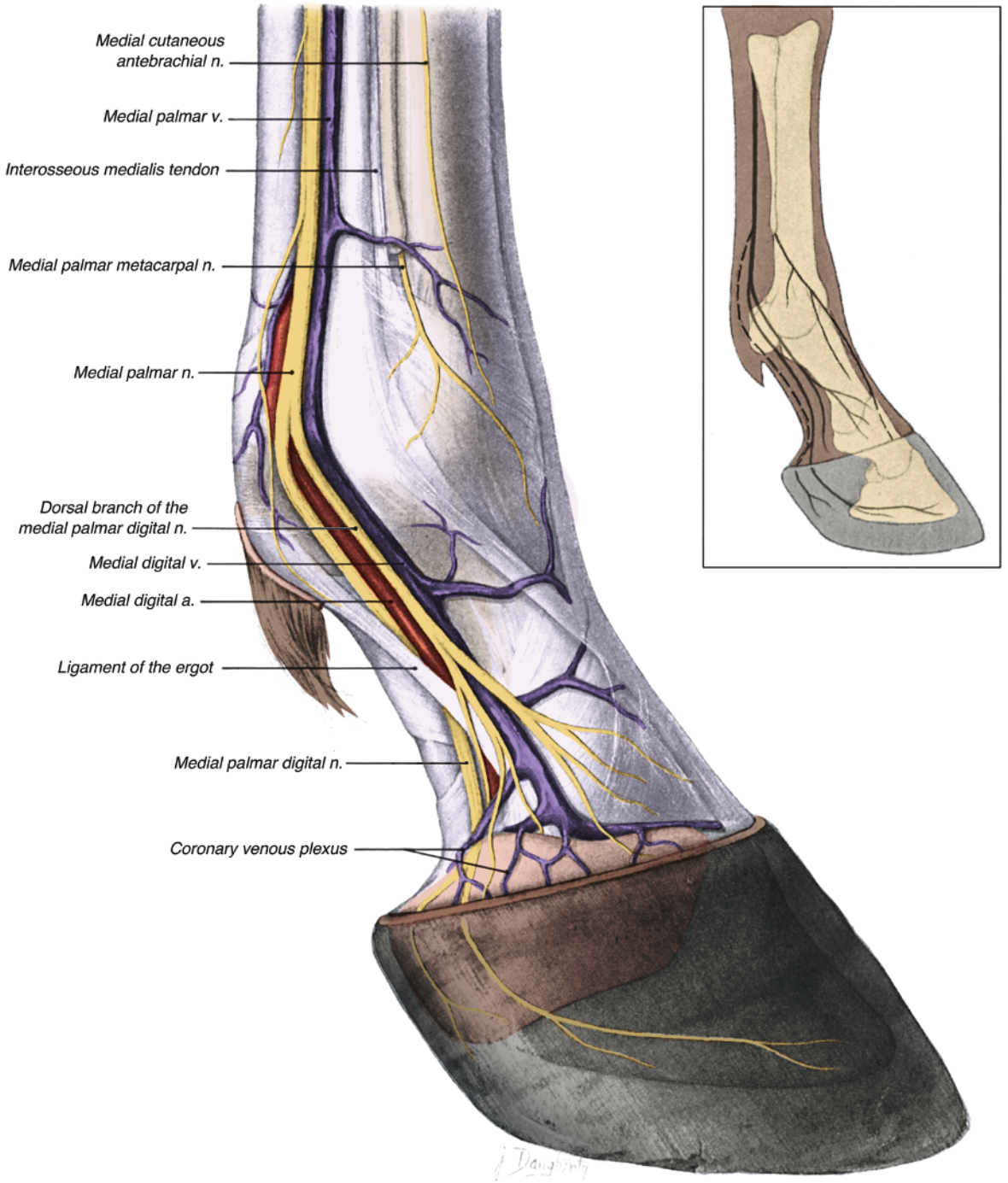
In the standing position, the fetlock and digit are prevented from non-physiologic hyperextension by the suspensory apparatus of the fetlock (interosseus muscle, intersesamoidean ligament, and distal sesamoidean ligaments), the digital flexor tendons, and the collateral ligaments of the joints. During flexion of the fetlock and digit, most of the movement is in the fetlock, the least amount of movement is in the pastern joint, and movement in the coffin joint is intermediate. Contraction of the common and lateral digital extensor muscles brings the bones and joints of the digit into alignment just before the hoof strikes the ground. The neurovascular supply to the digit and fetlock are illustrated in Figures 1.13 to 1.15.

### Metacarpus

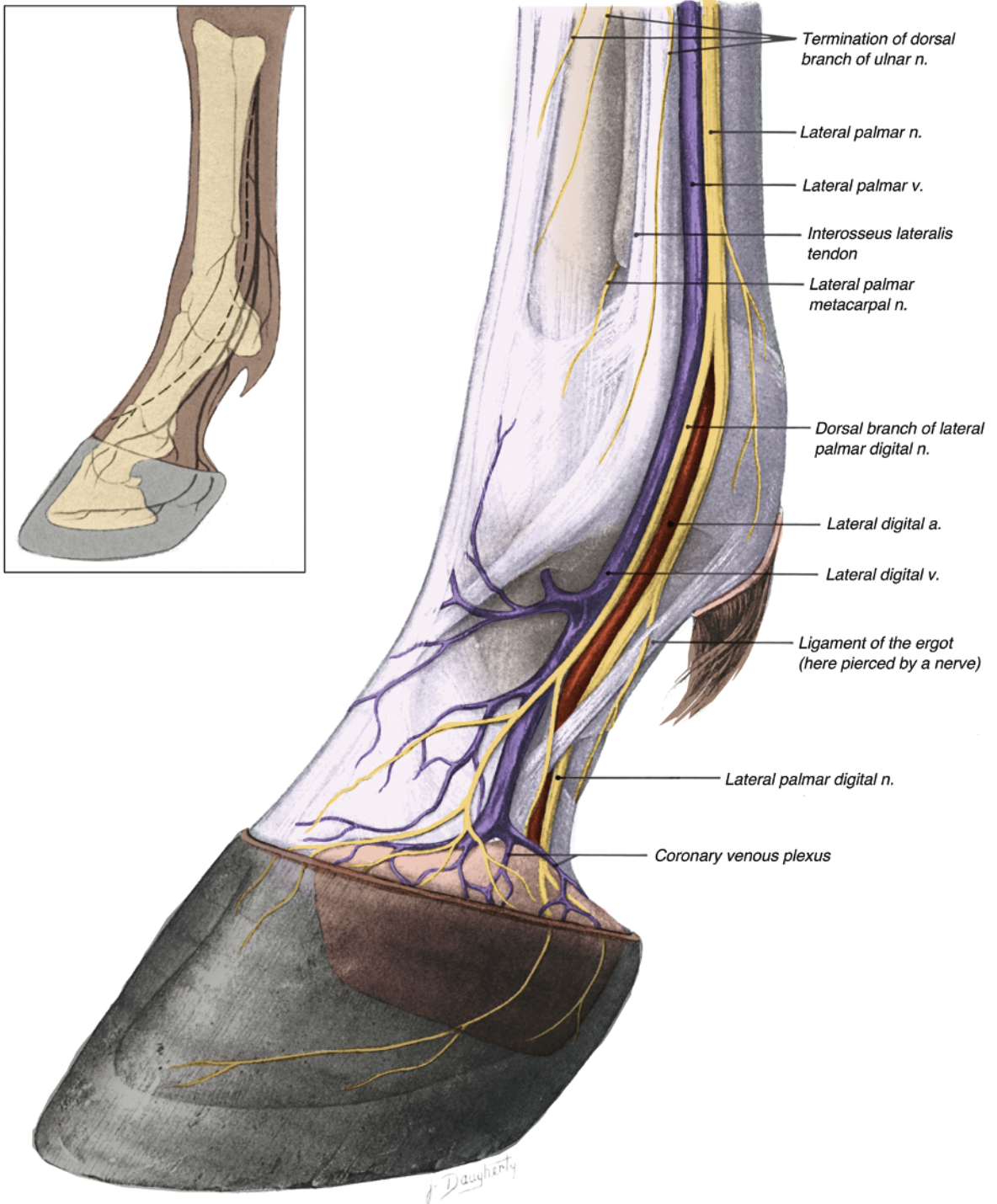
The equine metacarpus consists of the large third metacarpal (cannon) bone, the second (medial) and fourth (lateral) small metacarpal bones (splint bones), and the structures associated with them. The shaft of each small metacarpal



**Figure 1.13.** Arterial supply to the digit of the forelimb.



**Figure 1.14.** Medial aspect of the distal metacarpus, fetlock, and digit with skin and superficial fascia removed. Inset: schematic of the distribution of major nerves; dashed lines indicate variant branches.



**Figure 1.15.** Lateral aspect of the distal metacarpus, fetlock, and digit with skin and superficial fascia removed. Inset: schematic of the distribution of major nerves; dashed lines indicate variant branches.

bone is united by an interosseous ligament to the large metacarpal bone. The cortex under the rounded dorsal surfaces of the metacarpal bones is thicker than the cortex under their concave palmar surfaces. The length and curvature of the shafts and the prominence of the free distal extremities (“buttons”) of the small metacarpal bones are variable. The proximal extremities of the metacarpal bones articulate with the distal row of carpal bones; MCII articulating with the second and third carpals; MCIII articulating with the second, third, and fourth carpals; and MCIV with the fourth carpal bone.

### Dorsal Aspect

Deep to the skin, the main tendon of the common digital extensor muscle inclines proximolaterad from its central position at the fetlock across the dorsal surface of the third metacarpal bone. Proximally, the main tendon and the accompanying tendon of the radial head of the common digital extensor lie lateral to the insertional tendon of the extensor carpi radialis muscle on the prominent metacarpal tuberosity of MCIII. The tendon of the lateral digital extensor muscle is lateral to the common extensor tendon, and the small radial tendon of the latter usually joins the lateral digital extensor tendon. Occasionally the radial tendon pursues an independent course to the fetlock. A strong fibrous band from the accessory carpal bone reinforces the lateral digital extensor tendon as it angles dorsad in its descent from the lateral aspect of the carpus.

### Palmar Aspect

The SDFT is deep to the skin and subcutaneous fascia throughout the length of the metacarpus. Dorsally, it is intimately related to the fascial covering of the DDFT. The latter, in turn, lies against the palmar surface of the suspensory ligament (m. interosseus medius; middle or third interosseous muscle). The carpal synovial sheath, enclosing both digital flexor tendons, extends distad as far as the middle of the metacarpus. At this level, the DDFT is joined by its accessory ligament (carpal check ligament or “inferior” check ligament), the distal continuation of the palmar carpal ligament. The DFTS around the digital flexor tendons extends proximad into the distal fourth of the metacarpus (Figure 1.9).

The metacarpal groove, formed by the palmar surface of the third metacarpal bone and the

axial surfaces of the second and fourth metacarpal bones, contains the suspensory ligament. The suspensory ligament arises from the distal row of carpal bones and the proximal end of the third metacarpal bone (Figures 1.16, 1.17). It is broad, relatively flat, and shorter than the suspensory ligament of the hindlimb. Variable amounts of striated muscle fibers within the mainly collagenous suspensory ligament are organized into two longitudinal bundles within the proximal part and body of the ligament (hence, interosseus medius “muscle”). In the distal fourth of the metacarpus, the suspensory ligament bifurcates to become associated with the two proximal sesamoid bones (Figure 1.10). Each side crosses the abaxial surface of proximal sesamoid bone and extends across the abaxial aspect of the proximal phalanx, where it contacts the origin of the ipsilateral collateral sesamoidean ligament. An extensor branch continues on to join the tendon of the common digital extensor muscle on the dorsal surface of the proximal phalanx (Figure 1.10).

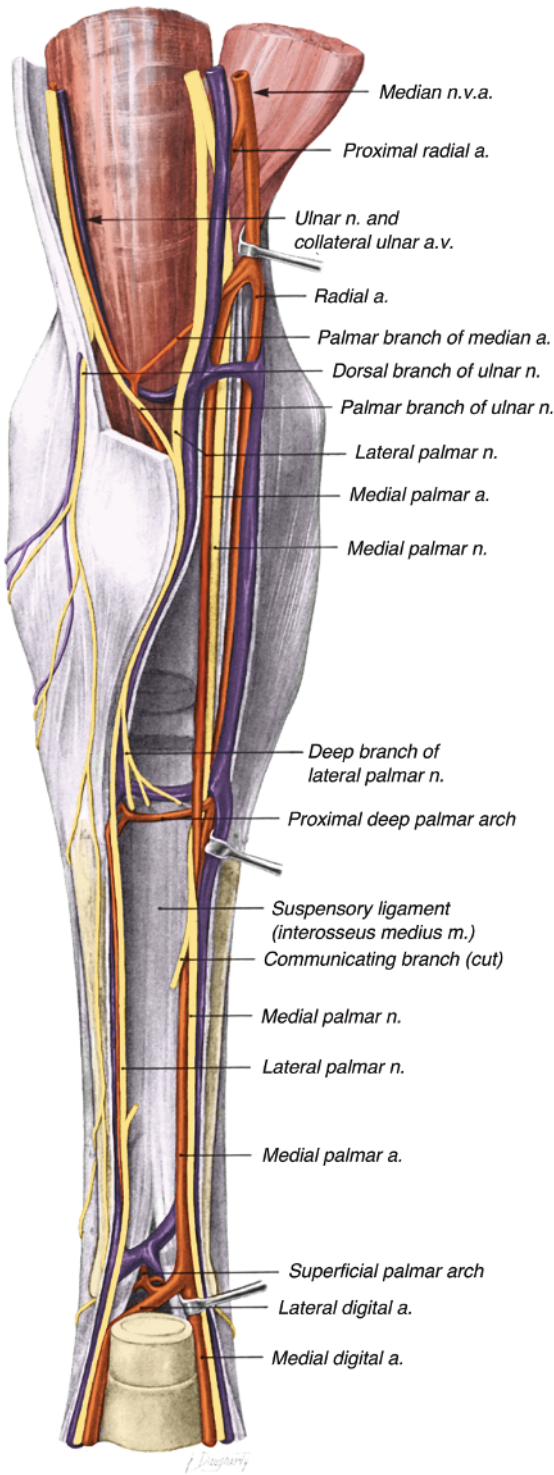
The nerves and vessels of the metacarpus are illustrated in Figures 1.16 and 1.17.

### Carpus

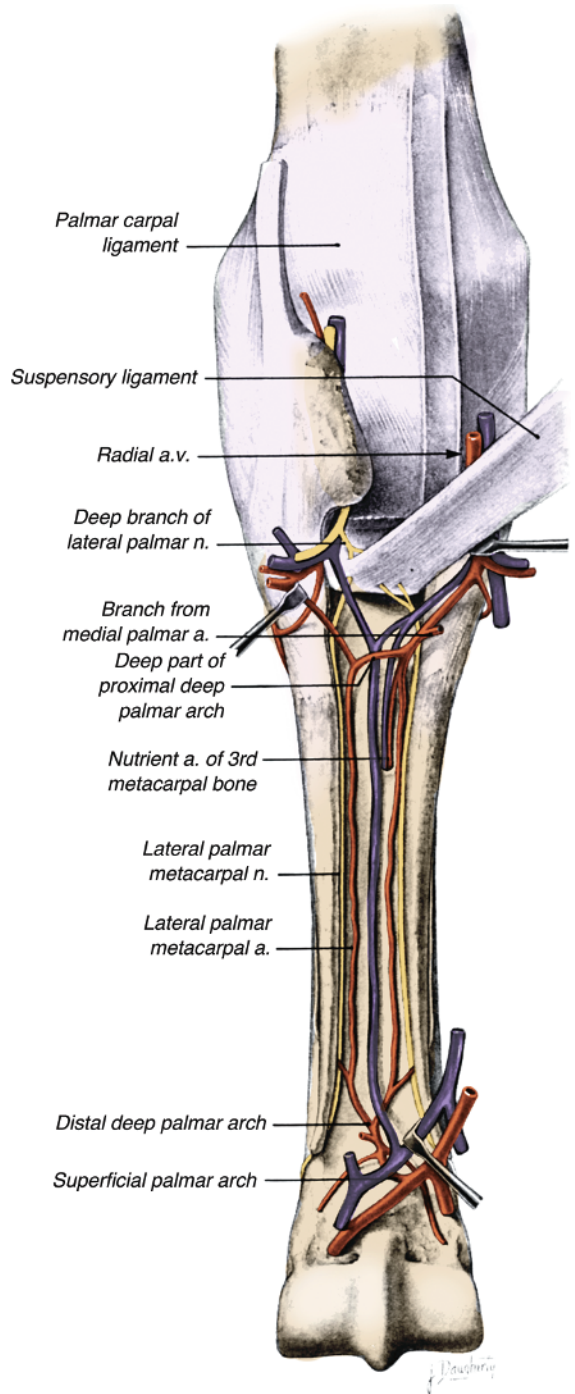
The carpal region includes the carpal bones (radial, intermediate, ulnar, and accessory in the proximal row; first, second, third, and fourth in the distal row), the distal extremity of the radius, the proximal extremities of the three metacarpal bones, and the structures adjacent to these osseous components. The joints between the radius and proximal carpal bones (radiocarpal joint), ulna, and proximal carpal bones (ulnocarpal joint) together constitute the antebrachio-carpal joint. It and the middle carpal joint between the proximal and distal rows of carpal bones act as hinge joints, whereas the carpometacarpal joint between the distal row of carpal bones and the three metacarpal bones is a plane joint with minimal movement. An extensive antebrachio-carpal synovial sac sends extensions between the carpal bones of the proximal row and also encompasses the joints formed by the accessory carpal bone. A palmarolateral pouch extends from the radiocarpal sac out between the long tendon of the extensor carpi ulnaris muscle and the lateral styloid process of the radius. The middle carpal synovial sac communicates with the small carpometacarpal sac between the third and fourth carpal bones.

On the dorsal carpus, the tendon sheaths of the extensor carpi radialis, extensor carpi

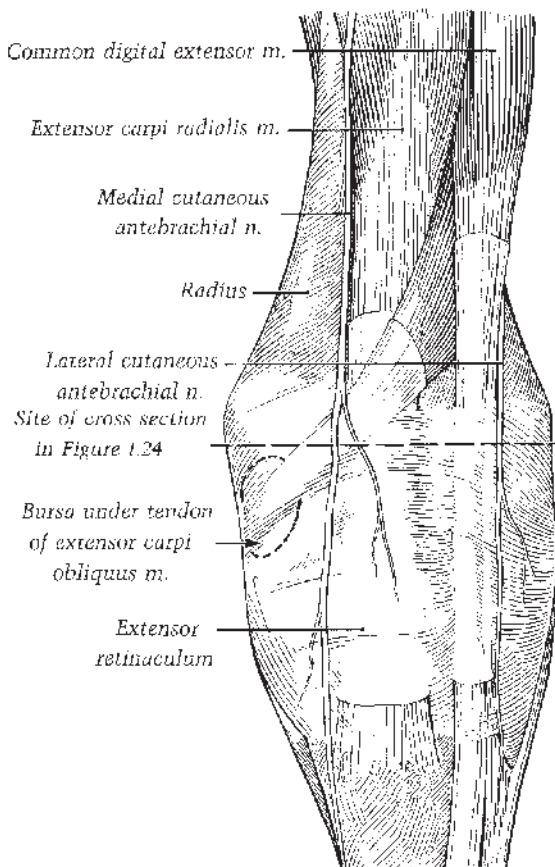




**Figure 1.16.** Deep dissection of the caudal aspects of the left carpus and metacarpus, with the medial palmar artery removed.



**Figure 1.17.** Caudal view of the left carpus and metacarpus; most of the digital flexor tendons are removed.

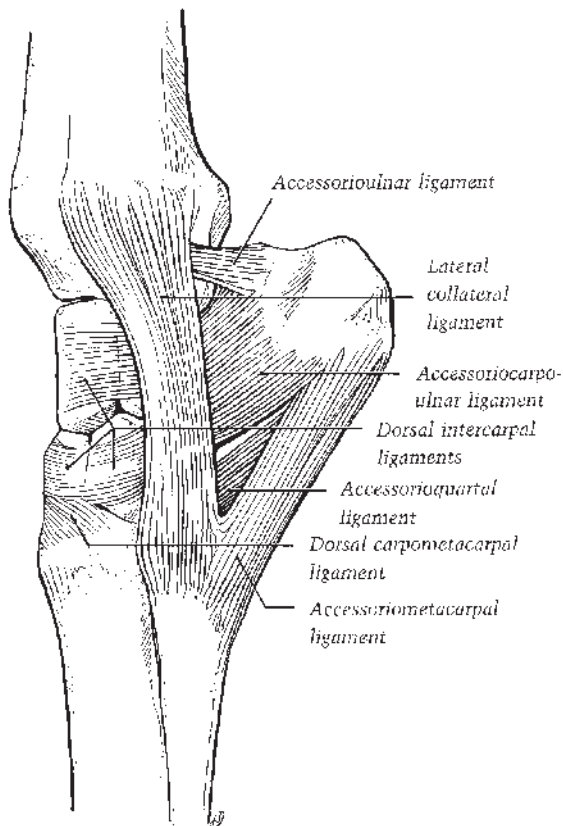


**Figure 1.18.** Dorsal view of the left carpus.

obliquus (abductor digiti I longus), and the common digital extensor muscles are enclosed in fibrous passages through the deep fascia and then through the extensor retinaculum. The tendon sheaths of the common digital and extensor carpi obliquus tendons extend from the carpometacarpal articulation proximad to 6 to 8 cm above the carpus (Figure 1.18). The tendon sheath of the extensor carpi radialis muscle terminates at the middle of the carpus, and then the tendon becomes adherent to the retinaculum as it extends to its insertion on the metacarpal tuberosity (Figure 1.18).

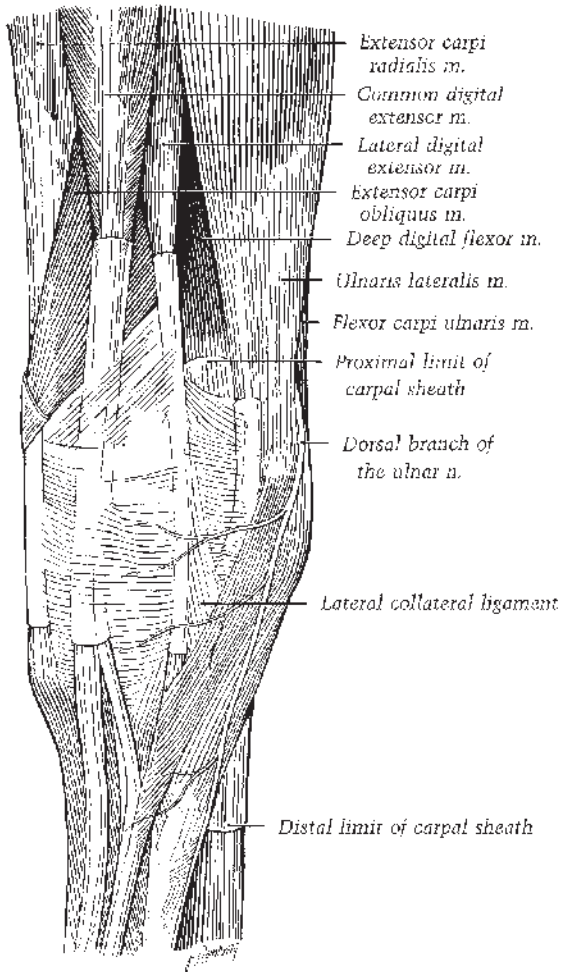
### Lateral Aspect

The lateral collateral carpal ligament extends distad from its attachment on the styloid process of the radius (Figure 1.19). The superficial part of the ligament attaches distally on the fourth



**Figure 1.19.** Carpal ligaments, lateral view.

metacarpal bone and partly on the third metacarpal bone. The deep part of the ligament attaches on the ulnar carpal bone. Palmar to the lateral collateral carpal ligament, four ligaments support the accessory carpal bone. These ligaments, named according to their attachments, are from proximal to distal, the accessorioulnar, accessoriocarpoulnar, accessorioquartal, and accessoriometacarpal ligaments (Figure 1.19). Tendons of two muscles are associated with the accessory carpal bone. The short tendon of the extensor carpi ulnaris muscle (formerly ulnaris lateralis m.) attaches to the proximal border and lateral surface of the bone; the muscle's long tendon, enclosed in a synovial sheath, passes through a groove on the bone's lateral surface and then continues distad to insert on the proximal extremity of the fourth metacarpal bone (Figure 1.20). The single tendon of the flexor carpi ulnaris muscle attaches to the proximal border of the accessory carpal bone, blending with the flexor retinaculum.



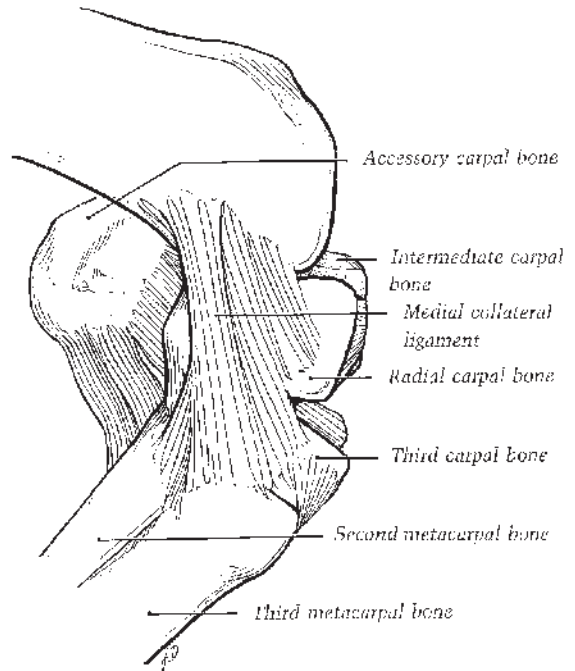
**Figure 1.20.** Lateral view of left distal forearm, carpus, and proximal metacarpus. Note that the ulnaris lateralis is now called extensor carpi ulnaris.

### Medial Aspect

The medial collateral carpal ligament extends from the medial styloid process of the radius and widens distally to attach to the proximal ends of the second and third metacarpal bones. Bundles of fibers also attach to the radial, second, and third carpal bones (Figure 1.21). Palmarly, the ligament joins the flexor retinaculum. The inconstant first carpal bone may be embedded in the palmar part of the medial collateral carpal ligament adjacent to the second carpal bone.

### Palmar Aspect

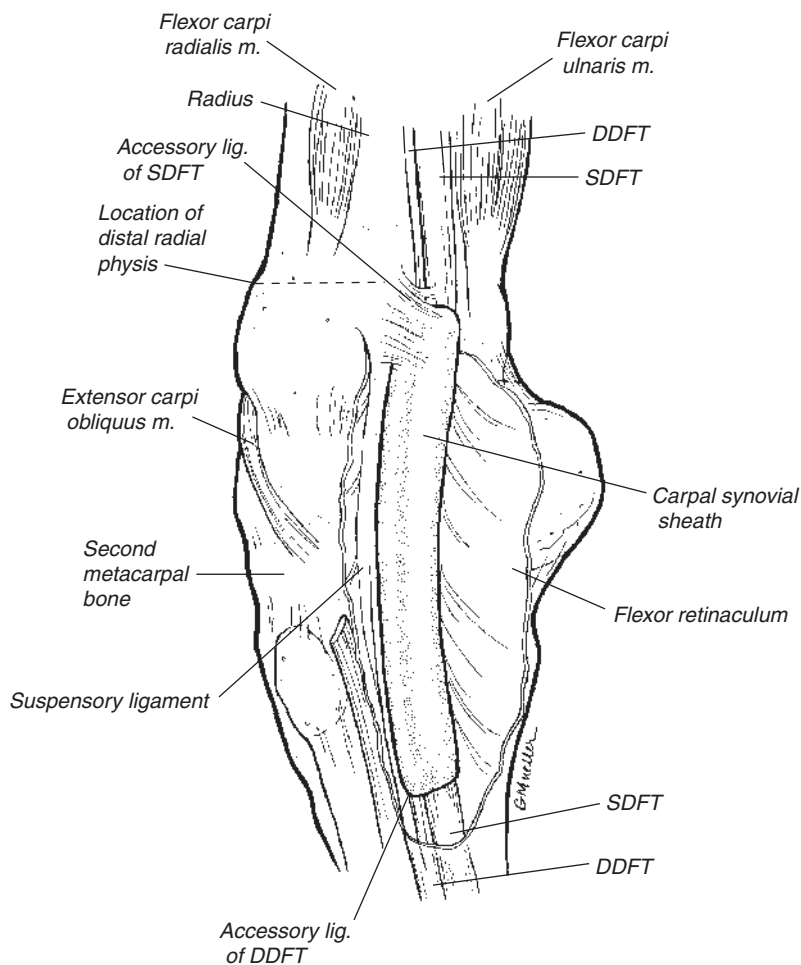
The flexor retinaculum is a fibrous band extending from the medial collateral ligament,



**Figure 1.21.** Carpal ligaments, medial view.

distal end of the radius, radial and second carpal bones, and proximal end of the second metacarpal bone laterad to the accessory carpal bone and the accessorioquartal and accessorio-metacarpal ligaments. By bridging the carpal groove, the flexor retinaculum forms the mediopalmar wall of the carpal canal. It blends proximally with the caudal antebrachial fascia; distally, with the palmar metacarpal fascia. Proximally, the fan-shaped accessory ligament of the SDFT (radial check ligament) completes the medial wall of the carpal canal. The lateral wall is formed by the accessory carpal bone and its two distal ligaments. The palmar carpal ligament forms the smooth dorsal wall, its deep surface serving as the palmar part of the common fibrous capsule of the carpal joints. It attaches to the three palmar radiocarpal, three palmar intercarpal, and four carpometacarpal ligaments as well as the carpal bones. Distally, the palmar carpal ligament gives origin to the accessory ligament (carpal check) of the DDFT, which joins the tendon at approximately the middle of the metacarpus.

The carpal canal (Figure 1.22) contains the following structures: the SDFT and DDFT enclosed in the carpal synovial sheath; the medial palmar nerve and artery; and the lateral palmar



**Figure 1.22.** Palmaromedial view of carpus with flexor retinaculum cut and reflected. SDFT = superficial digital flexor tendon; DDFT = deep digital flexor tendon.

nerve, artery, and vein. Medial to the carpal canal, the tendon of the flexor carpi radialis, enclosed in its tendon sheath, descends to its attachment on the proximal part of the second metacarpal bone. The carpal synovial sheath enclosing the digital flexor tendons extends from a level 8 to 10 cm proximal to the antebrachio-carpal joint distad to near the middle of the metacarpus (Figure 1.22). An intertendinous membrane attaches to the palmaromedial surface of the DDFT and the dorsomedial surface of the SDFT, dividing the carpal synovial sheath into lateral and medial compartments. The neurovascular supply to the carpus is illustrated in Figures 1.16, 1.17, 1.20).

## Antebrachium

The antebrachium (forearm) includes the radius and ulna and the muscles, vessels, nerves, and skin surrounding the bones. The prominent muscle belly of the extensor carpi radialis muscle bulges under the skin on the cranial aspect. A horny cutaneous structure, the chestnut, is present on the medial skin of the distal one-third of the forearm. The chestnut is considered to be a vestige of the first digit. Beneath the superficial antebrachial fascia, the thick, deep antebrachial fascia invests all of the muscles of the forearm and provides for insertion of the tensor fasciae antebrachii muscle medially, the cleidobrachialis muscle laterally, and

the biceps brachii muscle cranially by means of the lacertus fibrosus. The deep fascia merges with the periosteum on the medial surface of the radius and attaches to the collateral ligaments and bony prominences at the elbow. Extensor muscles are invested more tightly than the flexor muscles. Intermuscular septa extend from the deep fascia between the common and lateral digital extensors, between the common digital extensor and extensor carpi radialis muscles, and between the radial and ulnar carpal flexors.

### Extensor Muscles

The extensor carpi radialis is the largest of the extensor muscles of the antebrachium. It attaches proximally to the lateral epicondyle and radial fossa of the humerus (along with the tendon of origin of the common digital extensor); it also attaches to the elbow joint capsule, the deep fascia, and the septum between the two muscles. The extensive tendon traversing the extensor carpi radialis blends with the deep fascia of the forearm after the fascia receives the lacertus fibrosus from the biceps brachii muscle. A tendon lying obliquely across the tendon of insertion of the extensor carpi radialis is that of the smallest muscle of the extensor group, the extensor carpi obliquus muscle (abductor digiti I longus), which originates on the lateral surface of the distal half of the radius. In its oblique course the muscle is at first deep to the common digital extensor, then its tendon crosses that of the extensor carpi radialis superficially. Its tendon sheath is adherent to the extensor retinaculum as the tendon angles over the carpus toward its insertion on the head of the second metacarpal bone (Figure 1.18).

The common digital extensor muscle (humeral head) takes common origin along with the extensor carpi radialis on the lateral epicondyle and radial fossa of the humerus, with additional attachments to the ulna, deep fascia, lateral aspect of the radius, and the lateral collateral ligament of the elbow. Its tendon of insertion, enclosed in its tendon sheath, occupies its respective groove on the distal extremity of the radius. The lateral digital extensor muscle lies under the deep fascia against the radius and ulna between the extensor carpi ulnaris caudally and the larger common digital extensor muscle belly cranially. The lateral digital extensor originates from the radius, ulna, lateral collateral ligament of the elbow joint, and the intermuscular septum from the deep fascia.

### Flexor Muscles

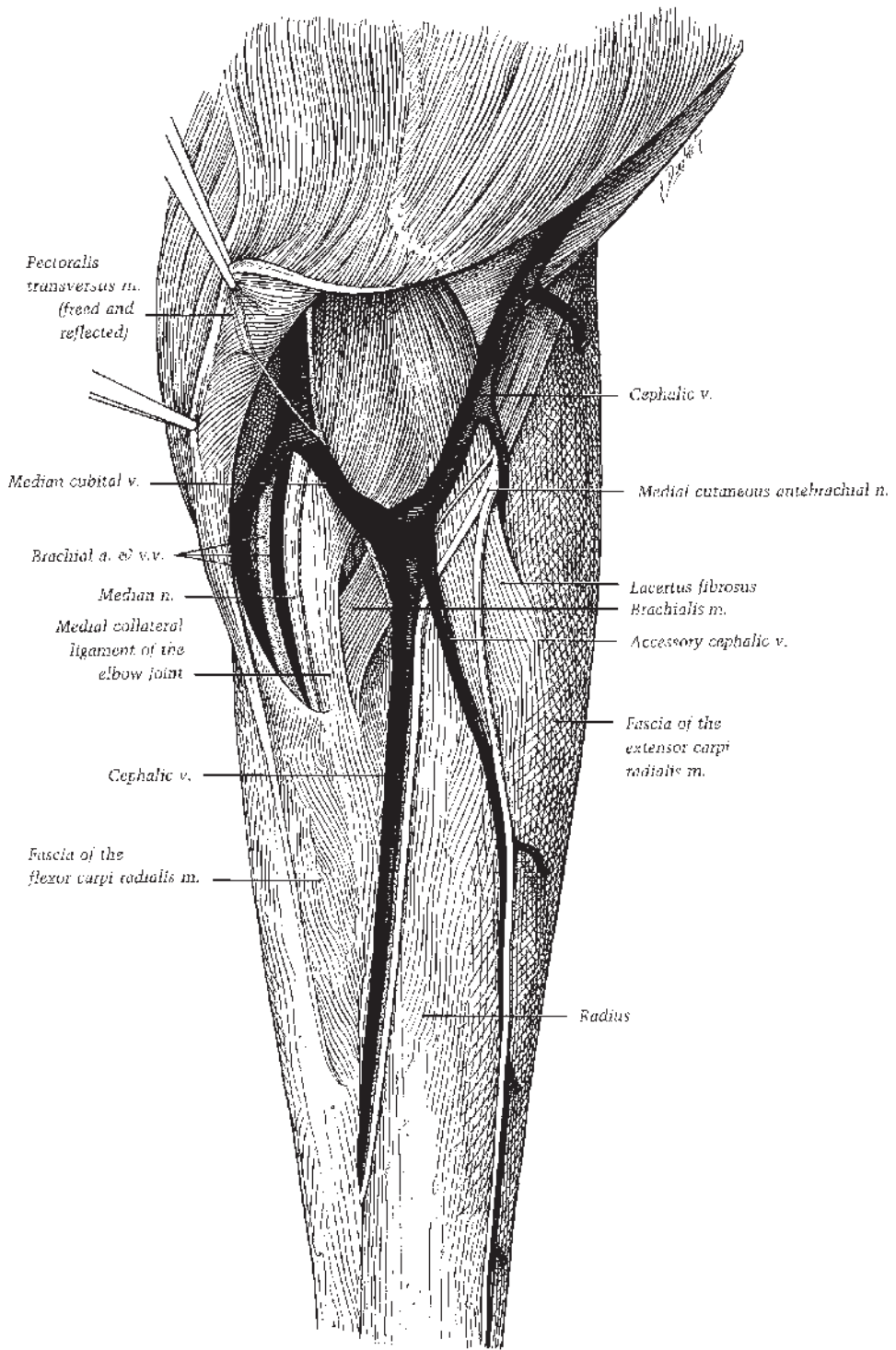
The flexor carpi radialis muscle is related to the mediocaudal surface of the radius (Figure 1.23), extending distad from the medial epicondyle of the humerus to the proximal extremity of the second metacarpal bone. Caudal and partially deep to the preceding muscle, the flexor carpi ulnaris muscle is formed by an ulnar head from the olecranon and a humeral head from the medial epicondyle and extends to the accessory carpal bone. The next muscle belly caudal to the flexor carpi ulnaris is that of the extensor carpi ulnaris muscle (formerly ulnaris lateralis) that originates on the lateral epicondyle of the humerus caudal to the lateral collateral ligament of elbow joint. The muscle extends distad to insert on the proximal and lateral aspects of the accessory carpal bone and, by means of a longer, sheathed tendon, to the proximal end of the fourth metacarpal bone. The preceding three muscles flex the carpal joint and extend the elbow joint, even though the extensor carpi ulnaris is morphologically an extensor of the carpal joint and supplied by the radial nerve.

The humeral head of the superficial digital flexor muscle originates from the medial epicondyle of the humerus and then lies deep to the ulnar head of the deep digital flexor (which is quite superficial as it originates from the medial surface of the olecranon) and the flexor carpi ulnaris. Under the proximal part of the flexor retinaculum the tendon of the humeral head of the superficial digital flexor is joined by a flat, wide fibrous band, its accessory ligament (really a radial head of the muscle), which comes from its attachment on a ridge on the mediocaudal surface of the distal half of the radius. The long, distinct tendon of the ulnar head of the deep digital flexor muscle joins the main tendon of the large humeral head proximal to the antebrachiocarpal joint just before the combined tendon becomes enclosed with the tendon of the superficial digital flexor in the carpal synovial sheath.

The neurovascular supply to the antebrachium is illustrated in Figures 1.16 and 1.23.

### Cubital (Elbow) Joint

Muscles adjacent to the equine cubital joint include two principal flexors, the biceps brachii and the brachialis (aided by the extensor carpi radialis and common digital extensor muscles), and three principal extensors, the tensor fasciae



**Figure 1.23.** Caudomedial view of a superficial dissection of left elbow and forearm.

antebrachii, triceps brachii, and the anconeus (assisted by the flexors of the carpus and digit).

Cranially, the terminal part of the biceps brachii muscle crosses the joint, its tendon of insertion branching into the lacertus fibrosus, which joins the deep fascia of the extensor carpi radialis, and a short tendon attaching to the radial tuberosity and medial collateral ligament of the cubital joint (Figure 1.24). The terminal part of the brachialis muscle, curving around from its location in the musculospiral groove of the humerus, passes between the biceps brachii and extensor carpi radialis muscles to attach to the medial border of the radius under the long part of the medial collateral ligament of the elbow joint (Figure 1.23). The medial collateral ligament represents the pronator teres muscle in the horse.

Over the medial aspect of the elbow joint deep to the cranial part of the pectoralis transversus muscle, the median nerve, cranial brachial vein, brachial artery, and caudal brachial vein lie caudal to the medial collateral ligament of the elbow joint (Figure 1.23). The short part of the collateral ligament is deep and attaches to the radial tuberosity. Proximocaudal to the joint the collateral ulnar artery and vein, the ulnar nerve, and its cutaneous branch (caudal cutaneous antebrachial nerve) cross obliquely between the medial head of the triceps brachii and tensor fasciae antebrachii muscles. All three principal extensors of the cubital joint insert on the olecranon tuberosity of the ulna. A subcutaneous bursa may cover the caudal aspect of the olecranon tuberosity; deeply a subtendinous bursa lies under the tendon of insertion of the long head of the massive triceps brachii muscle (Figure 1.25).

The medially located tensor fasciae antebrachii also inserts on and acts to tense the deep antebrachial fascia. Deep to the triceps brachii, the small anconeus muscle originates from the caudal surface of the humerus, covers the olecranon fossa, and attaches to the elbow joint capsule, acting to elevate it when the joint is extended.

A fovea on the head and a ridge on the proximal extremity of the radius and the trochlear notch of the ulna articulate with the trochlea of the humerus, forming a ginglymus. The cranial articular angle is approximately 150° with a range of movement up to 60°. In flexion, the forearm is carried laterad due to the slightly oblique axis of movement of the elbow joint. Laterally, the cubital joint is covered by the distal part of the cutaneous omobrachialis muscle. A

short, stout lateral collateral ligament extends from the lateral tuberosity of the radius to the lateral epicondyle of the humerus. Bands of fascia blend with the cranial part of the joint capsule. Caudally, the joint capsule becomes thinner as it extends into the olecranon fossa deep to the anconeus muscle. The joint capsule is adherent to the anconeus muscle and tendons of surrounding muscles. Extensions of the synovial lining project under the origins of the extensor carpi ulnaris and the digital flexor muscles and into the radioulnar articulation.

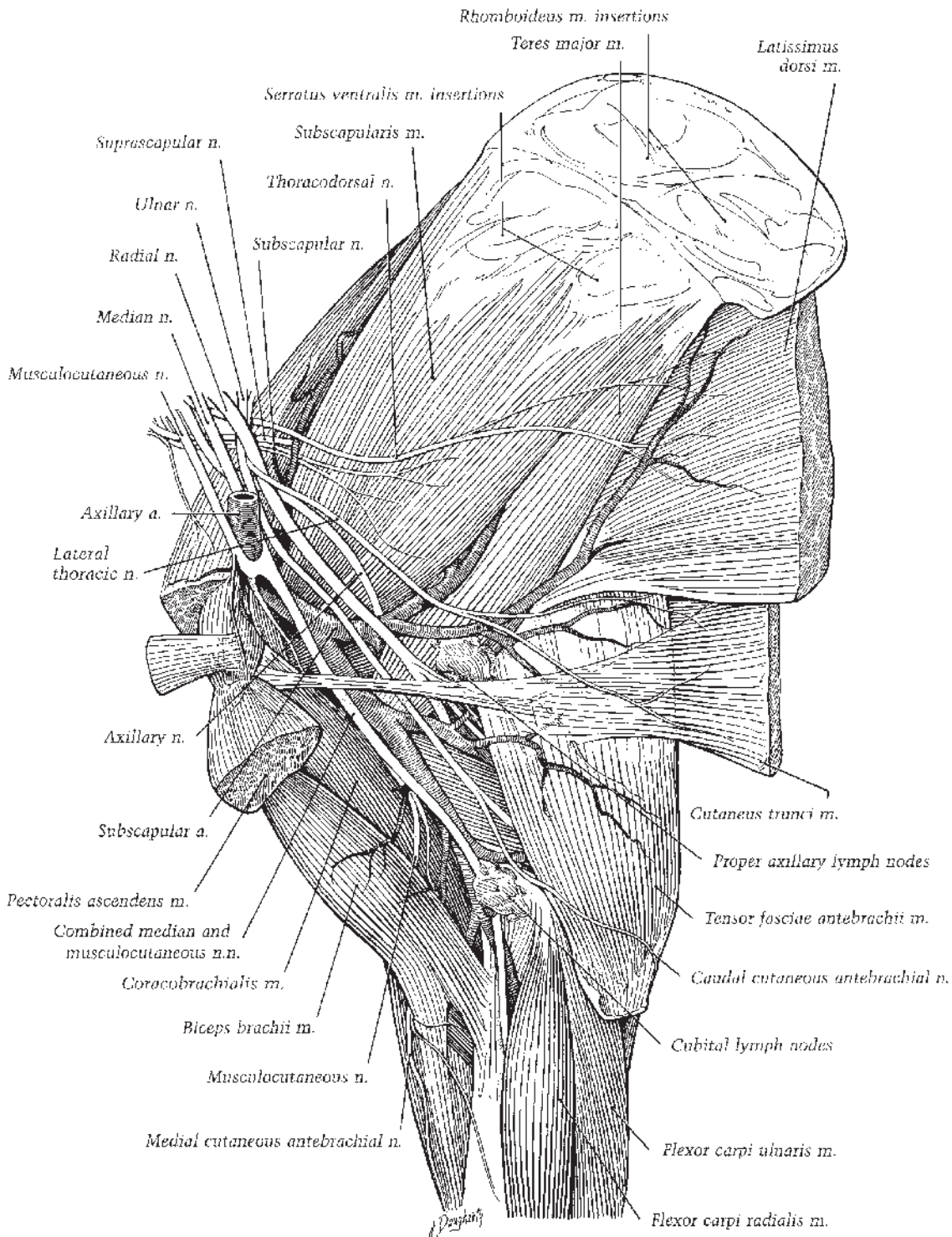
## Arm and Shoulder

The arm is the region around the humerus. The shoulder includes the shoulder joint (scapulohumeral joint) and the region around the scapula that blends dorsally into the withers. The heavy, deep fascia of the shoulder closely invests the underlying muscles and sends intermuscular septa in to attach to the spine and borders of the scapula. Within the superficial fascia over the lateral aspect of the shoulder and arm, the cutaneous omobrachialis muscle covers the deep fascia and extends as far distad as the cubital joint (Figure 1.25). The cutaneous muscle is innervated by the intercostobrachial nerve. Cutaneous sensation in this region is also mediated by brachial branches of the axillary and radial nerves. Superficial blood vessels are branches of the caudal circumflex humeral vessels.

The cleidobrachialis muscle (of the brachiocephalicus) covers the cranio-lateral aspect of the shoulder joint on the way to its insertion on the deltoid tuberosity, humeral crest, and the fascia of the arm (Figure 1.26). When the head and neck are fixed, this muscle acts as an extensor of the shoulder joint, drawing the forelimb cranial.

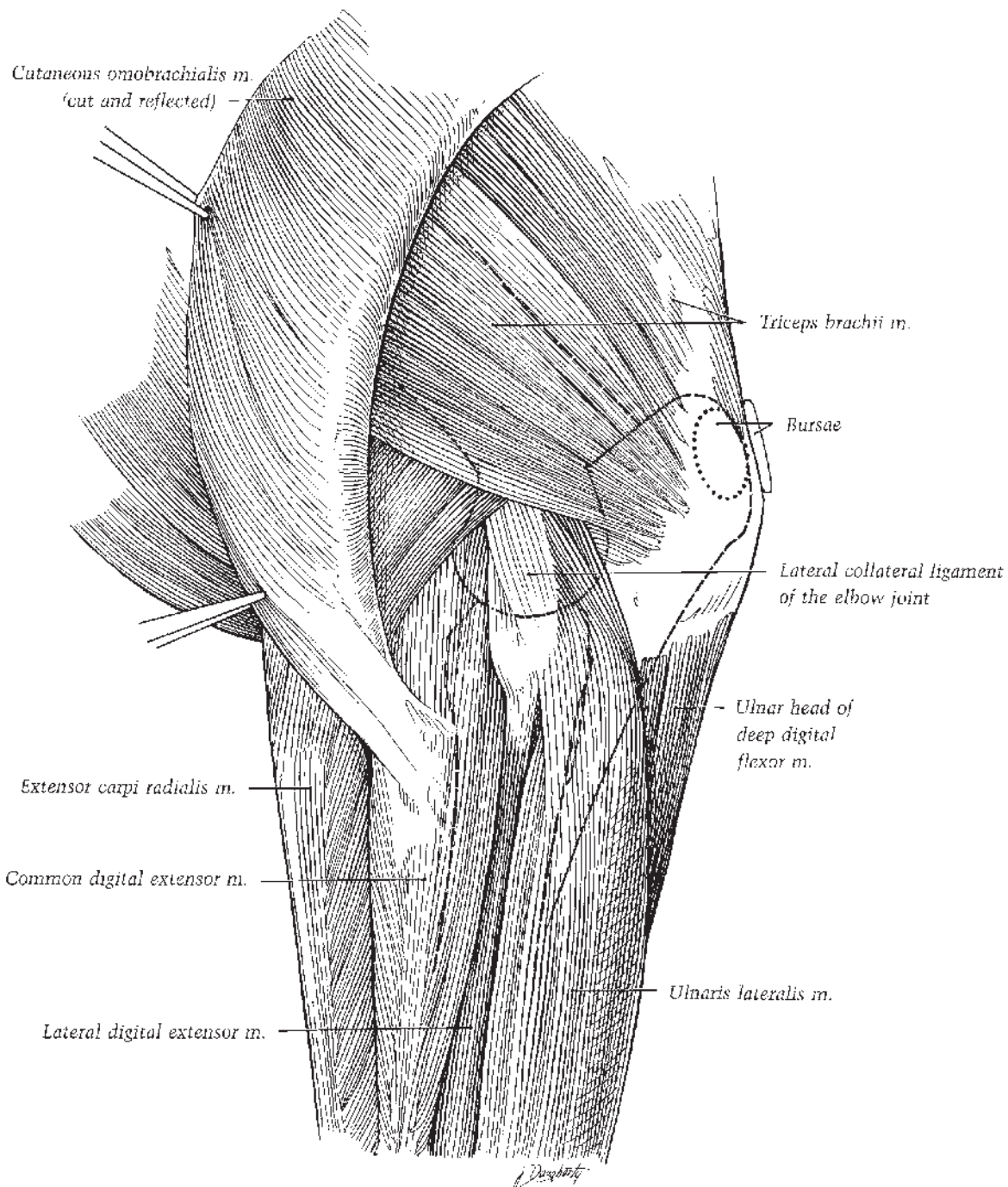
## Muscles Substituting for Shoulder Joint Ligaments

Cranially, the heavy, partly cartilaginous tendon of the biceps brachii muscle originates on the supraglenoid tubercle of the scapula and occupies the intertuberal groove of the humerus. A tendinous band from the pectoralis ascendens muscle extends from the lesser tubercle to the greater tubercle, serving to bind down the tendon of the biceps brachii. An intertuberal bursa lies under the tendon and extends around its sides. A tendinous intersection (an “internal tendon”) extends distad through the muscle. In addition to flexing the elbow, the biceps brachii fixes the

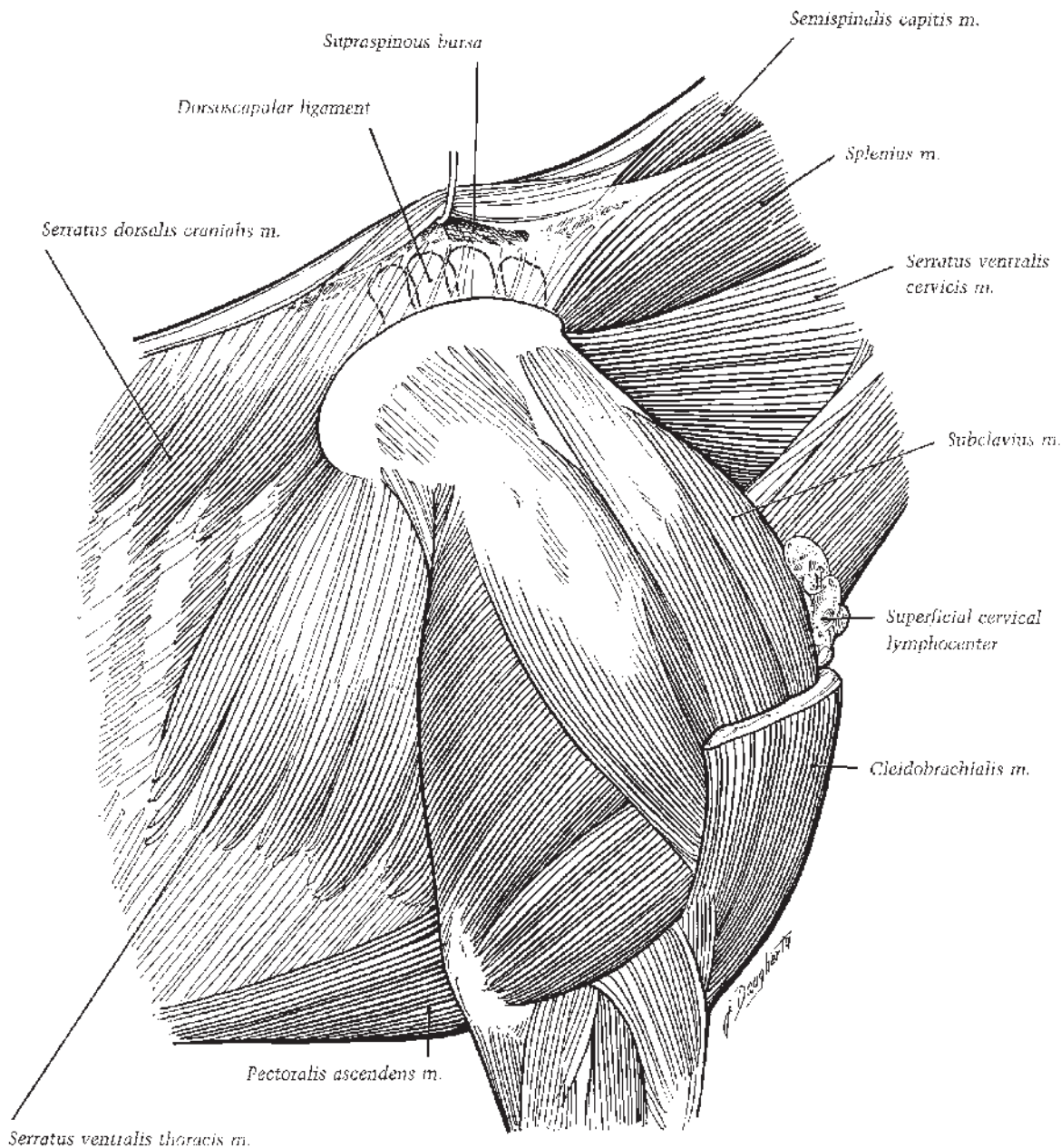


**Figure 1.24.** Medial view of the left shoulder, arm, and proximal forearm. Veins are not depicted.





**Figure 1.25.** Lateral view of the left elbow. Dashed lines represent the locations of bony elements. Note that the ulnaris lateralis is now called extensor carpi ulnaris.

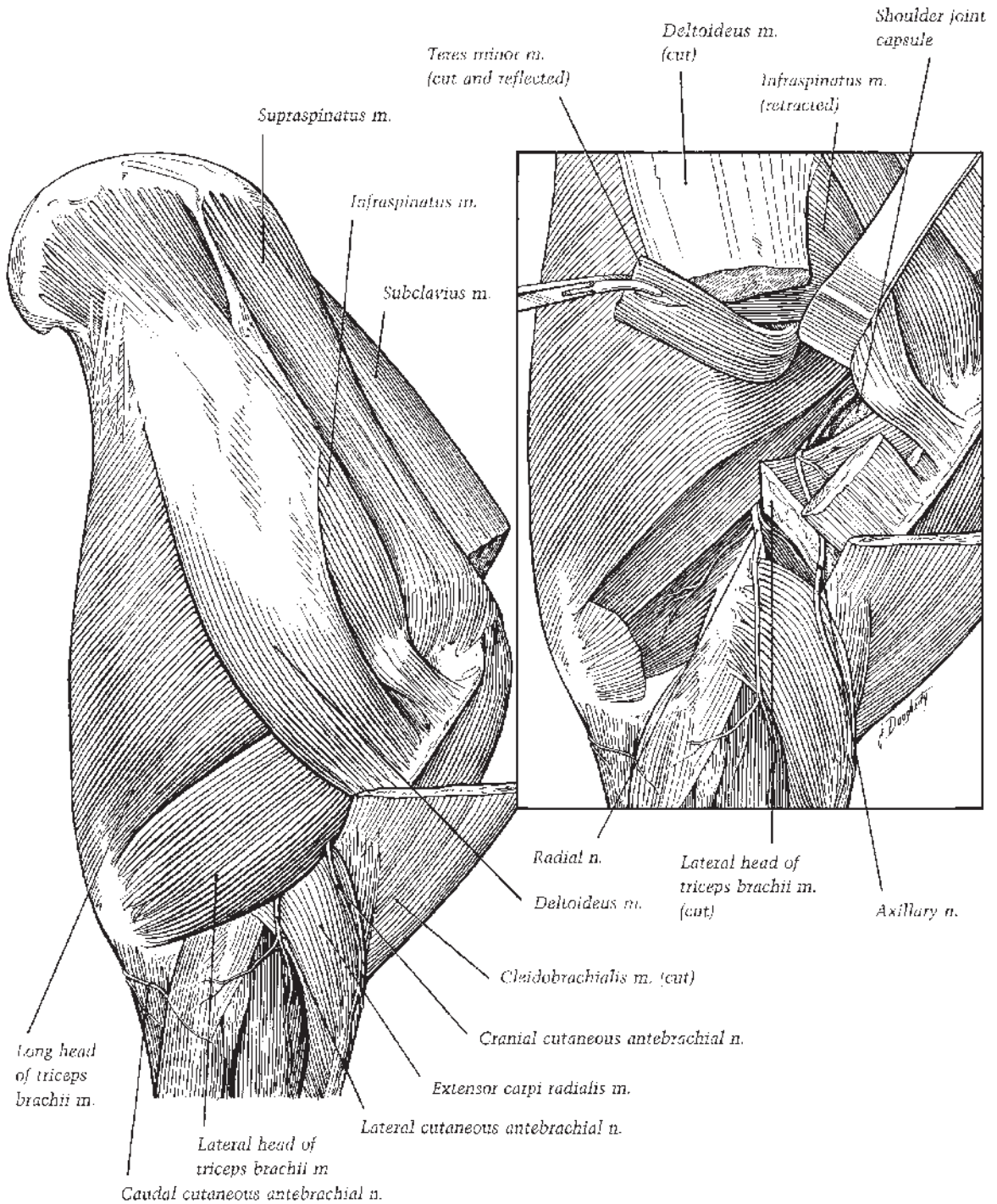


**Figure 1.26.** Right shoulder and dorsoscapular ligament. The spines of thoracic vertebrae 2 through 5 are outlined by dashed lines.

elbow and shoulder in the standing position. The musculocutaneous nerve supplies the biceps brachii. The supraspinatus muscle, which arises from the supraspinous fossa, the spine, and cartilage of the scapula, divides distally to attach to the greater and lesser tubercles of the humerus,

serving with the bicipital tendon to stabilize the shoulder joint cranially (Figure 1.27).

Laterally, the infraspinatus muscle extends from the scapular cartilage and infraspinous fossa to insert on the caudal eminence of the greater tubercle and a triangular area on the



**Figure 1.27.** Lateral aspect of the right shoulder. Inset: deeper dissection exposing the shoulder joint.

distal part of the tubercle distal to the insertion of the supraspinatus (Figure 1.27). The partly cartilaginous tendon is protected from the underlying caudal eminence by adipose tissue and a constant synovial bursa that may communicate with the shoulder joint cavity. The tendon is the main lateral support of the shoulder joint assisted by the teres minor. The lateral insertion of the supraspinatus muscle also lends some lateral support. The supraspinatus muscle extends the shoulder joint; the teres minor muscle flexes the joint and, together with the infraspinatus, abducts the arm. The infraspinatus also rotates the arm laterad. The supraspinatus and infraspinatus muscles are supplied by the suprascapular nerve that reaches the supraspinous fossa by passing out between the subscapularis and supraspinatus muscles and then going around the distal fourth of the cranial border of the scapula.

The subscapularis muscle supports the shoulder joint medially. This adductor of the arm originates in the subscapular fossa of the scapula and inserts on the caudal eminence of the lesser tubercle of the humerus. Caudal support to the joint is rendered by the long head of the triceps brachii, the only head of this muscle originating from the scapula.

### Flexor Muscles of the Shoulder Joint

In addition to the long head of the triceps brachii muscle, four muscles flex the shoulder joint: laterally, the deltoideus and teres minor (which also abduct the arm), medially, the teres major and coracobrachialis (which also adduct the arm), and the latissimus dorsi. The first three muscles are innervated by branches from the axillary nerve; the coracobrachialis, by the musculocutaneous nerve; and the latissimus dorsi, by the thoracodorsal nerve.

The deltoideus muscle originates from the proximal part of the caudal border of the scapula and the scapular spine via the aponeurosis investing the infraspinatus (Figure 1.27). The muscle lies in a groove on the lateral surface of the triceps brachii and partly on the infraspinatus and teres minor muscles as it extends distad to attach to the deltoid tuberosity of the humerus and the brachial fascia. The teres major muscle extends from the caudal angle and border of the scapula across the medial surface of the triceps brachii to the teres major tuberosity of the humerus, where it inserts with the latissimus dorsi muscle (Figure 1.24). The coracoid process of the scapula gives origin to the coracobrachialis muscle that crosses the medial aspect of the

shoulder joint and proximal arm to attach to the humerus just proximal to the teres major tuberosity and on the middle of the cranial surface of the bone.

### Shoulder Joint

The fibrous part of the joint capsule of the shoulder attaches up to 2 cm from the margins of the articular surfaces. Two elastic glenohumeral ligaments reinforce the joint capsule as they diverge from the supraglenoid tubercle to the humeral tuberosities. Within the shoulder joint the articular surface of the humeral head has approximately twice the area of the glenoid cavity of the scapula, even with the small extension afforded by the glenoid lip around the rim. The articular configuration of this ball-and-socket joint and the support of the surrounding muscles give great stability to the joint. Major movements are flexion and extension. While standing, the caudal angle of the shoulder joint is 120° to 130°. The angle increases to approximately 145° in extension and decreases to 80° in flexion. Muscles around the joint restrict abduction and adduction. Rotation is very limited.

### Muscles Overlying the Scapula

Beneath the skin over the scapular region, the broad, triangular flat trapezius muscle covers parts of eight underlying muscles. The cervical part of the trapezius arises by a thin aponeurosis from most of the funicular part of the ligamentum nuchae and inserts on the scapular spine and fascia of the shoulder and arm. The aponeurosis of the thoracic part of the trapezius takes origin from the supraspinous ligament from the third to the 10th thoracic vertebrae, and the muscle inserts on the tuber of the spine of the scapula. An aponeurosis joins the two parts of the trapezius. Innervated by the accessory nerve and dorsal branches of adjacent thoracic nerves, the trapezius muscle elevates the shoulder and draws it either cranial or caudad, depending on the activity of the cervical or thoracic parts, respectively.

Deep to the trapezius, the rhomboideus cervicis originates from the funicular part of the ligamentum nuchae, and the rhomboideus thoracis originates from the superficial surface of the dorsal part of the dorsoscapular ligament. Both parts of the rhomboideus muscle insert on the medial side of the scapular cartilage (Figure 1.24). This muscle is innervated by the sixth and

seventh cervical nerves and dorsal branches of nerves adjacent to the rhomboideus thoracis. The rhomboideus draws the scapula dorsocranial and, when the limb is stationary, the cervical part helps to raise the neck.

The widest muscle of the shoulder girdle, the latissimus dorsi, has roughly the shape of a right triangle with the origin arising through a broad aponeurosis from the thoracolumbar fascia. Thin at first, the muscle becomes thicker as it passes medial to the long head of the triceps brachii to converge on a flat, common tendon of insertion with the teres major muscle (Figure 1.24).

From deep to superficial, the muscles contributing most substantially to the attachment of the thoracic limb to the trunk and neck are the serratus ventralis, the pectoral muscles, subclavius, brachiocephalicus, and omotransversarius. The serratus ventralis cervicis extends from the transverse processes of the last four cervical vertebrae to the serrated face of the medial surface of the scapula and adjacent scapular cartilage; the serratus ventralis thoracis converges dorsad from the lateral surfaces of the first eight or nine ribs to the serrated face of the scapula and adjacent scapular cartilage. Elastic lamellae from the ventral part of the dorsoscapular ligament are interspersed through the attachments of the serratus ventralis on the scapula. The two parts of the muscle and the contralateral serratus ventralis form a support suspending the thorax between the thoracic limbs. When both muscles contract, they elevate the thorax; acting independently, each serratus ventralis shifts the trunk's weight to the ipsilateral limb. During locomotion the cervical part of the muscle draws the dorsal border of the scapula cranial; the thoracic part draws the scapula caudad. When the limb is fixed, the serratus cervicis extends the neck or pulls it laterad.

Pectoral muscles attach to the sternum. There are two superficial pectoral muscles: (1) the pectoralis descendens muscle descending from the cartilage of the manubrium sterni to the deltoid tuberosity and the crest of the humerus and the brachial fascia, and (2) the pectoralis transversus muscle extending from the ventral part of the sternum between the first to the sixth sternbrae to the superficial fascia of the medial aspect of the antebrachium and to the humeral crest. The superficial pectoral muscles adduct the thoracic limb and tense the antebrachial fascia. The largest pectoral muscle, the deep pectoral (pectoralis ascendens) muscle (Figure 1.26), ascends from its attachments on the xyphoid cartilage,

the ventral part of the sternum, the fourth to ninth costal cartilages, and the abdominal tunic to the cranial parts of the lesser and greater humeral tubercles and the tendon of origin of the coracobrachialis muscle. The subclavius has been traditionally grouped with the pectorales. It arises from the first four costal cartilages and the cranial half of the sternum and ends in an aponeurosis over the dorsal part of the supraspinatus muscle and the scapular fascia (Figures 1.26 and 1.27).

As has been noted, the cleidobrachialis part of the brachiocephalicus muscle extends from the indistinct clavicular intersection to the arm. The mastoid part of the muscle (cleidomastoides) lies between the intersection and its attachments to the mastoid process and nuchal crest, partly overlapping the omotransversarius muscle dorsally. The omotransversarius originates from the wing of the atlas and the transverse processes of the second, third, and fourth cervical vertebrae, and inserts on the humeral crest and fascia of the shoulder and arm. The dorsal branch of the accessory nerve passes through the cranial part of the omotransversarius and then between that muscle and the trapezius.

### Dorsoscapular Ligament

Further attachment of the shoulder to the trunk is afforded by a thickened, superficial lamina of the thoracolumbar fascia, the dorsoscapular ligament. It consists of two parts: a collagenous portion attaches to the third, fourth, and fifth thoracic spines under the flattened part of the nuchal ligament subjacent to the supraspinous bursa (Figure 1.26). This part of the dorsoscapular ligament passes ventrad, ultimately attaching to the medial surface of the rhomboideus thoracis muscle. As it curves under the muscle, the collagenous part changes to an elastic part. A horizontal lamina of the elastic part forms the ventral sheath of the rhomboideus thoracis muscle. Several vertical laminae project from the ventral aspect of the horizontal lamina, surrounding bundles of the serratus ventralis muscle that insert on the scapula.

The neurovascular supply to the arm and shoulder is illustrated in Figures 1.24 and 1.27.

### Stay Apparatus of the Thoracic Limb

In the standing position, interacting muscles, tendons, and ligaments constituting the stay apparatus of the thoracic limb fix the alignment of the bones of the manus, suspend the fetlock,

lock the carpus, and stabilize the elbow and shoulder joints. This complex of structures functions almost entirely as a passive, force-resisting system. It permits the horse to stand (and sleep) with a minimum of muscular activity (Figure 1.28).

The suspensory apparatus of the fetlock is a ligamentous continuum extending from the proximal end of the third metacarpal bone to the proximal and middle phalanges. It consists of the suspensory ligament, metacarpointersesamoidean ligament with its embedded proximal sesamoid bones, and distal sesamoidean ligaments. The SDFT and the DDFT and their accessory (check) ligaments assist the suspensory apparatus of the fetlock in suspending the fetlock and preventing excessive overextension of the joint and collapse of the fetlock during weight bearing, especially on striking the ground. Disruption of the suspensory ligament alters its support of the fetlock, resulting in “sinking” or hyperextension of the fetlock.

A certain amount of muscle tone prevails in all “resting” muscles of the limb, even during most stages of sleep. Tension exerted by the long head of the triceps brachii muscle is essential to prevent flexion of the elbow joint and collapse of the forelimb. The elbow’s eccentrically placed collateral ligaments allow it to exhibit considerable stability in the extended position, a stability enhanced by the triceps’ tone. Flexion of the joint is further limited by the muscle belly and fibrous components of the superficial digital flexor muscle descending from its attachment of the medial epicondyle of the humerus.

A tendinous continuum extending from the supraglenoid tubercle to the metacarpal tuberosity is formed by the main tendon of the biceps brachii muscle, its fibrous “internal tendon,” and its superficial tendon (lacertus fibrosus) that blends into the fascia of the extensor carpi radialis muscle and via it to the tendon of insertion of this muscle. This complex prevents flexion of the shoulder joint caused by the weight of the trunk via the scapular attachments of the serratus ventralis muscle and the dorsoscapular ligament. Additionally, the tendon of the extensor carpi radialis opposes flexion of the carpus.

## HINDLIMB

### *Digit and Fetlock*

The hind foot is somewhat smaller and more elongate than the fore foot. It has been commonly reported that, compared to the fore hoof,

the angle of the toe of the hind hoof is slightly greater. Within the hind pastern the middle phalanx is narrower and longer and the proximal phalanx somewhat shorter than their counterparts in the thoracic limb (Figure 1.29).

The long digital extensor muscle’s tendon attaches to the dorsal surfaces of the proximal and middle phalanges and the extensor process of the distal phalanx, but the tendon of the lateral digital extensor usually does not attach to the proximal phalanx as it does in the thoracic limb. Digital flexor tendons, tendon sheaths, and bursae of the hind digit are not remarkably different. The suspensory apparatus of the fetlock and the configuration of the fetlock (metatarsophalangeal) joint are much the same as in the thoracic limb except that the dorsal articular angle of the fetlock is approximately 5° greater (i.e., is slightly more “upright”).

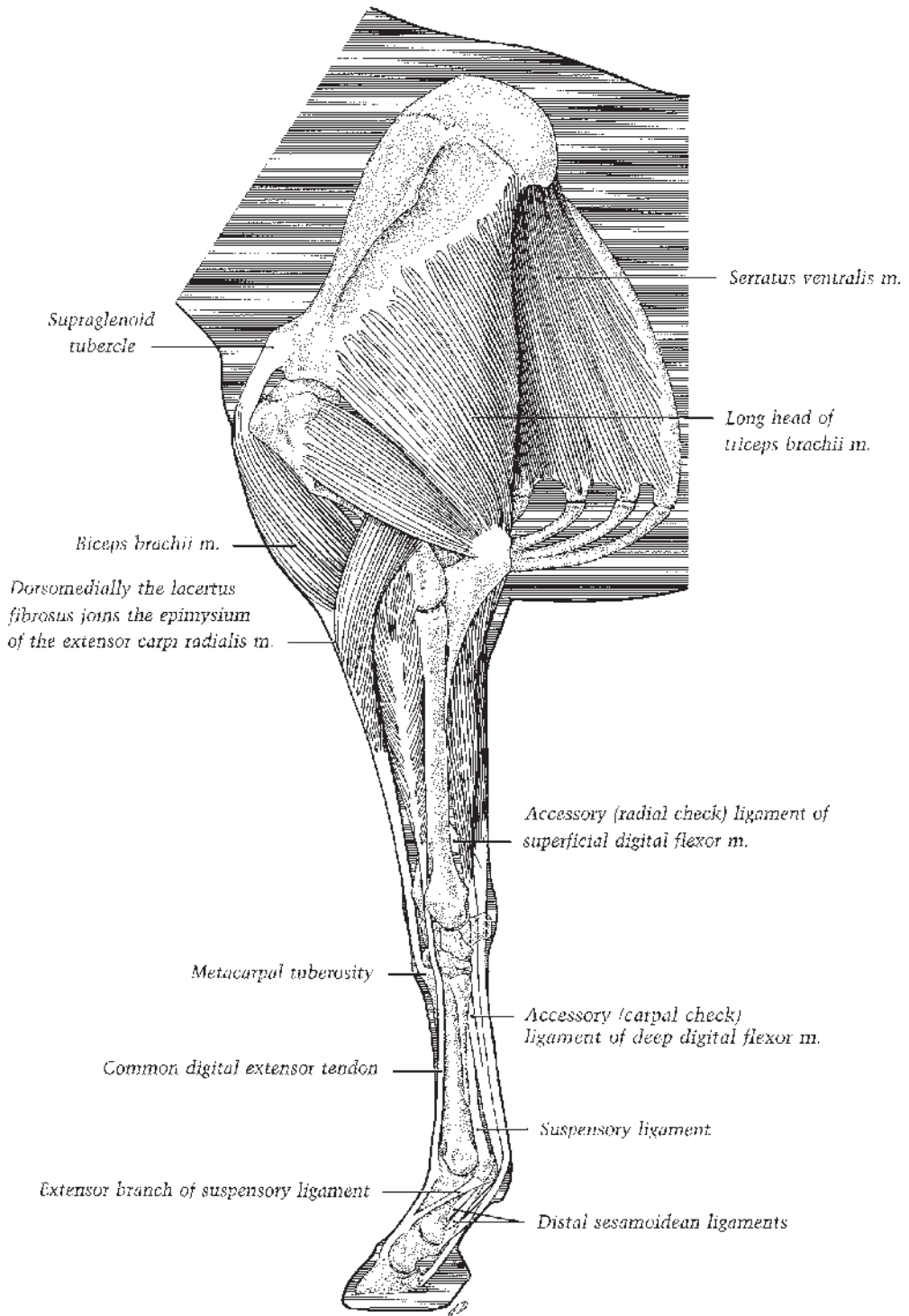
The neurovascular supply to the hind digit and fetlock is illustrated in Figures 1.30 and 1.31

### *Metatarsus*

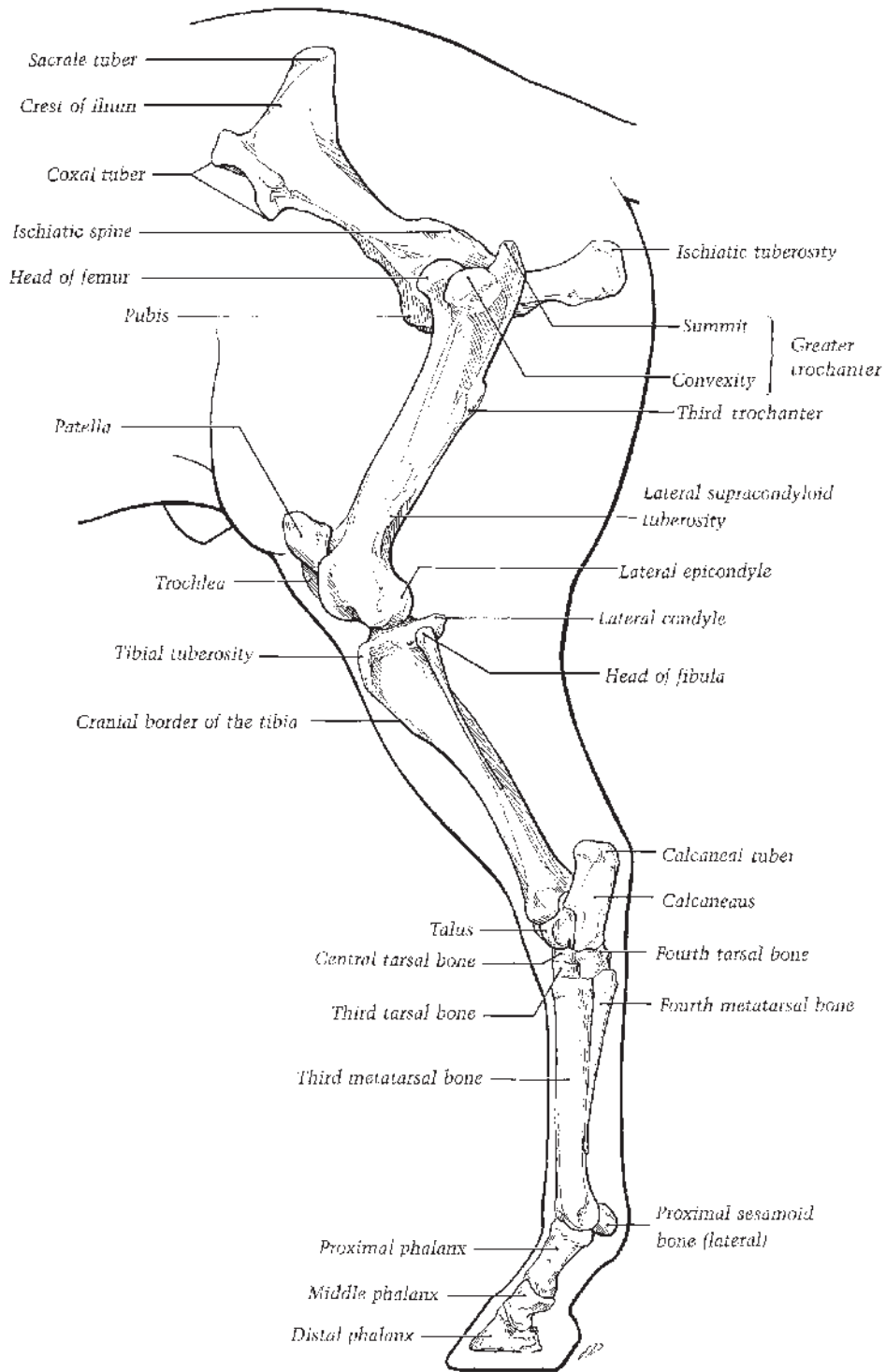
The equine metatarsus is about 16% longer than the corresponding metacarpus, and the third metatarsal bone is more rounded than the third metacarpal bone. The fourth metatarsal bone, particularly its proximal extremity, is larger than the second metatarsal bone.

Dorsally, the tendon of the long digital extensor muscle extends the length of the metatarsus beneath the skin and fascia. At the proximal third of the metatarsus, the long digital extensor tendon is joined by the tendon of the lateral digital extensor muscle. The angle formed by the conjoined long and lateral digital extensor tendons is occupied by the thin, triangular short digital extensor muscle. The short digital extensor originates on the lateral collateral ligament of the hock, the lateral tendon of the fibularis tertius muscle (most commonly called the peroneus tertius), and the middle extensor retinaculum, and inserts on the two large digital extensor tendons. All digital extensor muscles are bound down by the distal extensor retinaculum in the proximal third of the metatarsus (Figure 1.30).

Plantarily, the SDFT is similar to the corresponding tendon in the metacarpus. The deep digital flexor muscle’s principal tendon is intimately related to the dorsomedial aspect of the SDFT. In the proximal third of the metatarsus, the principal tendon is joined by the tendon of the medial digital flexor muscle (the medial head of the deep digital flexor muscle). A weakly developed, slender accessory ligament (tarsal or

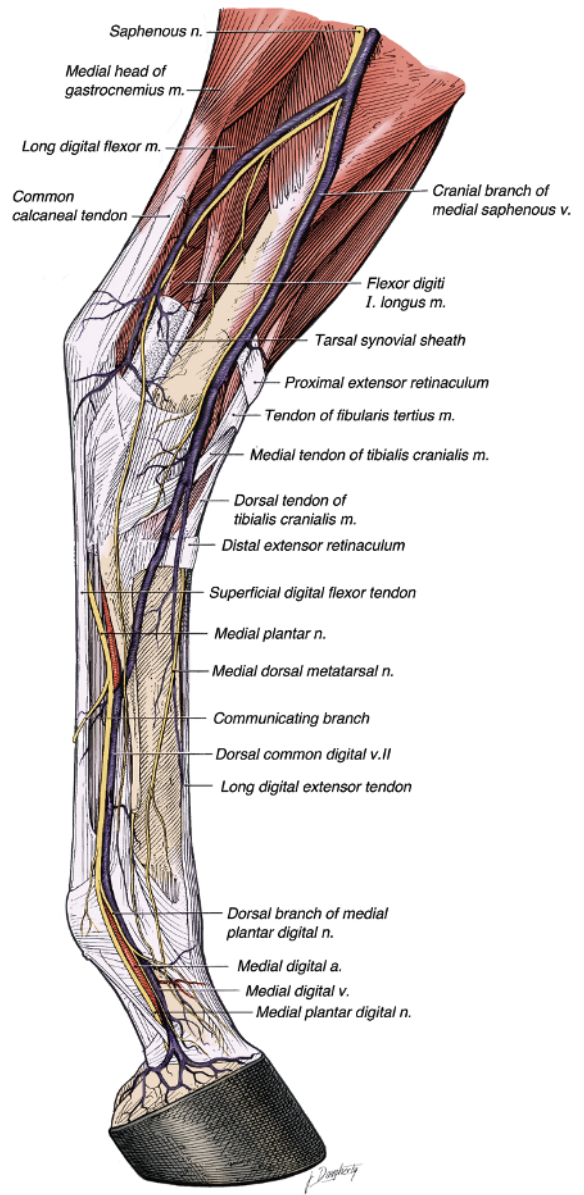
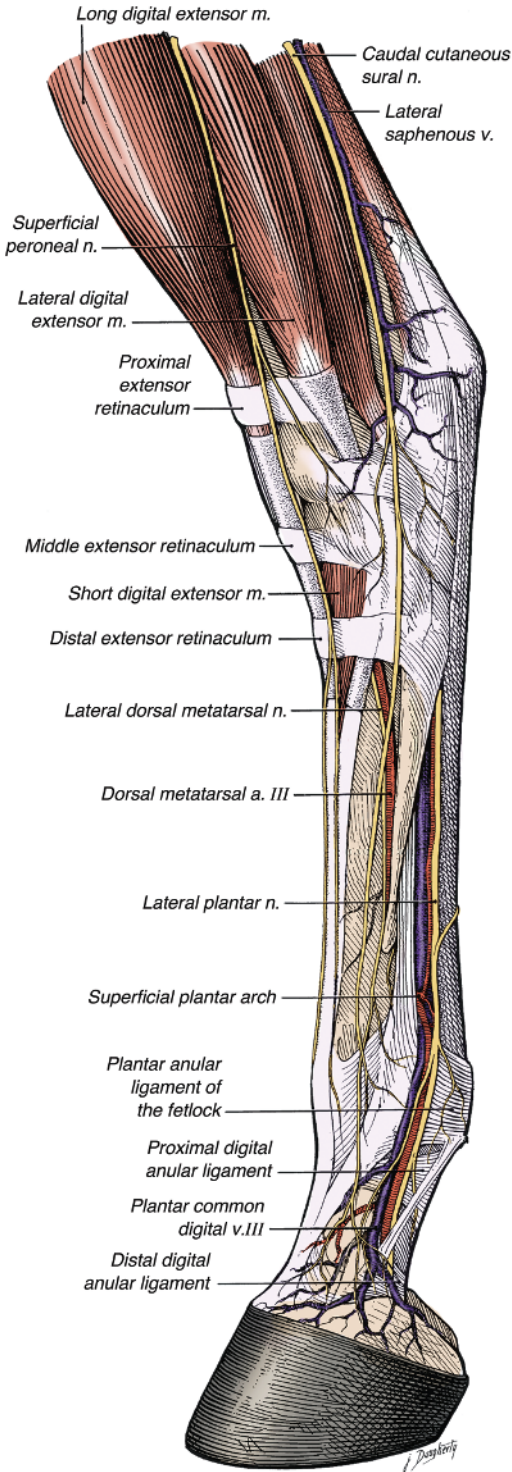


**Figure 1.28.** Stay apparatus of the left thoracic limb.



**Figure 1.29.** Bones of the left pelvic limb, lateral view.





**Figure 1.31.** Medial view of the left distal crus and pes. Please note that the term “fibularis” is currently preferred over “peroneus” (fibular rather than peroneal), although both are widely used.

**Figure 1.30.** Lateral view of the left distal crus and pes. Please note that the term “fibularis” is currently preferred over “peroneus” (fibular rather than peroneal), although both are widely used.

“inferior” check ligament) arises from the plantar aspect of the fibrous joint capsule of the hock. Longer than its counterpart in the forelimb, it joins the DDFT near the middle of the metatarsus. This slender accessory ligament may be absent in horses, and it is usually absent in mules and ponies.

The suspensory ligament (middle or third interosseous muscle) takes origin from a large area on the proximal aspect of the third metatarsal bone and a smaller attachment on the distal row of tarsal bones. Lying within the metatarsal groove deep to the DDFT, the suspensory ligament of the hindlimb is relatively thinner, more rounded, and longer than the ligament of the forelimb. In some horses, e.g., Standardbreds, the suspensory ligament of the hindlimb contains more muscle than the suspensory ligament of the forelimb. The two extensor branches pursue courses similar to those in the forelimb.

The neurovascular supply to the metatarsus is illustrated in [Figures 1.30 and 1.31](#)

### *Tarsus (Hock)*

The bones of the tarsus include the talus; calcaneus; and the central, first and second (fused), and third and fourth tarsal bones ([Figure 1.29](#)). Proximally, the trochlea of the talus articulates with the cochlear surface of the tibia in the tarsocrural joint; distally, the distal row of tarsal bones and the three metatarsal bones articulate in the tarsometatarsal joint. Extensive collateral ligaments span the latter two joints and the intertarsal joints. In the horse, nearly all of the movement of the hock arises from the tarsocrural joint.

### **Dorsal Aspect**

The long digital extensor tendon’s synovial sheath extends from the level of the lateral malleolus distad nearly to the junction of the tendon with the tendon of the lateral digital extensor muscle ([Figure 1.30](#)). The long digital extensor tendon is located just lateral to the palpable medial ridge of the trochlea of the talus. The proximal part of the short digital extensor muscle covers the tarsal joint capsule ([Figure 1.30](#)). As it crosses the dorsal surface of the tarsocrural joint, the tendon of the fibularis (peroneus) tertius muscle is superficial to the tendon of the tibialis cranialis muscle ([Figures 1.31, 1.32](#)). Then the tendon of the fibularis tertius forms a sleeve-like cleft through which the tendon of the tibialis cranialis and its synovial sheath pass. The latter tendon then bifurcates into a dorsal tendon,

which inserts on the large metatarsal bone, and a medial (“cunean”) tendon, which angles mediolateral under the superficial layer of the long medial collateral ligament, to insert on the first tarsal bone. A bursa is interposed between the cunean tendon and the long medial collateral ligament ([Figure 1.33](#)).

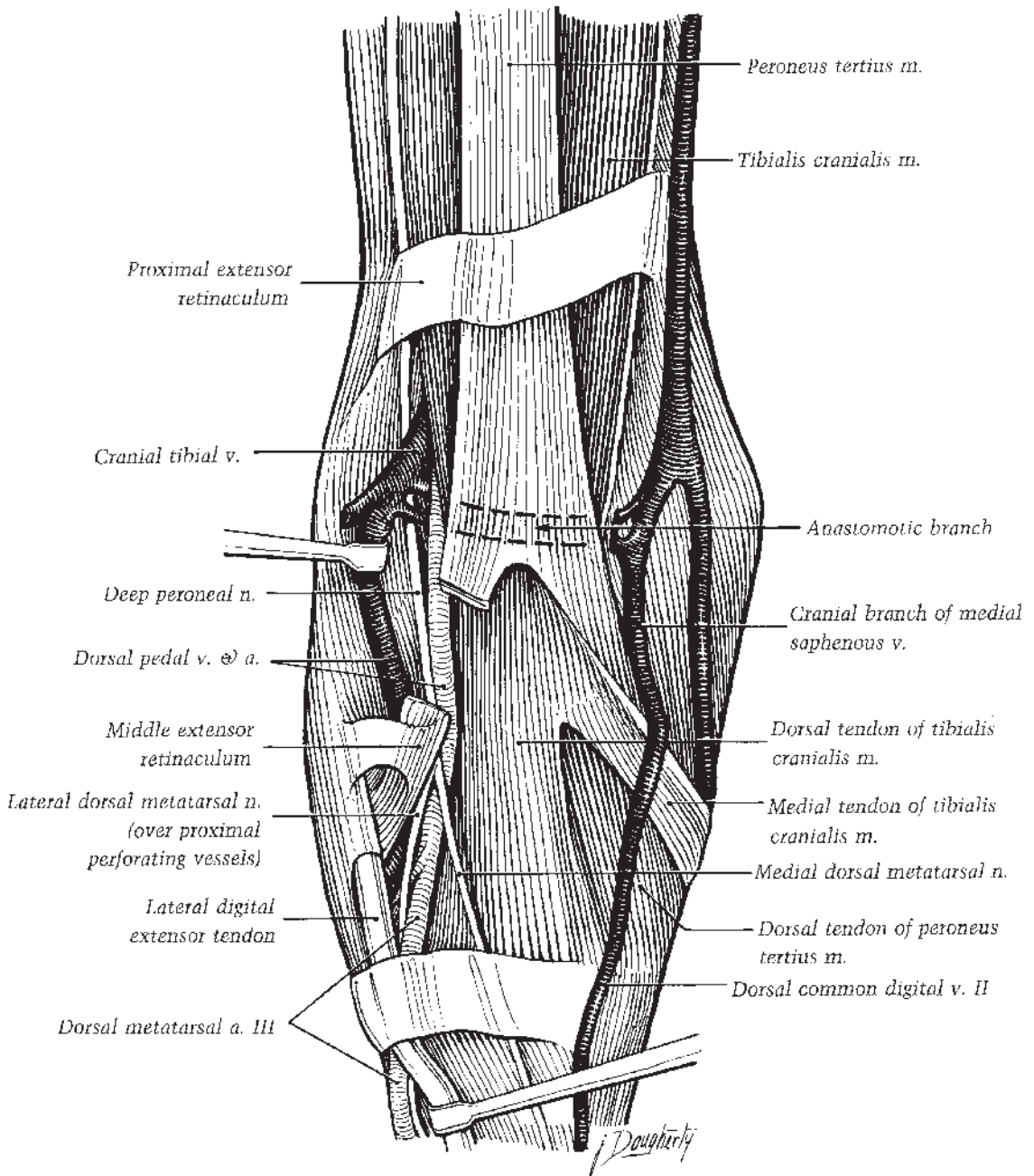
After forming the cleft that admits passage of the tibialis cranialis tendon, the fibularis tertius divides into two tendons. The dorsal tendon passes under the cunean tendon and inserts on the third tarsal and metatarsal bones, medial to the dorsal tendon of the cranial tibial muscle ([Figure 1.33](#)). The lateral tendon of the fibularis tertius extends distad deep to the long digital extensor tendon and continues laterad distal to the lateral ridge of the trochlea of the talus. The lateral tendon then bifurcates and inserts on the calcaneus and the fourth tarsal bone.

### **Lateral Aspect**

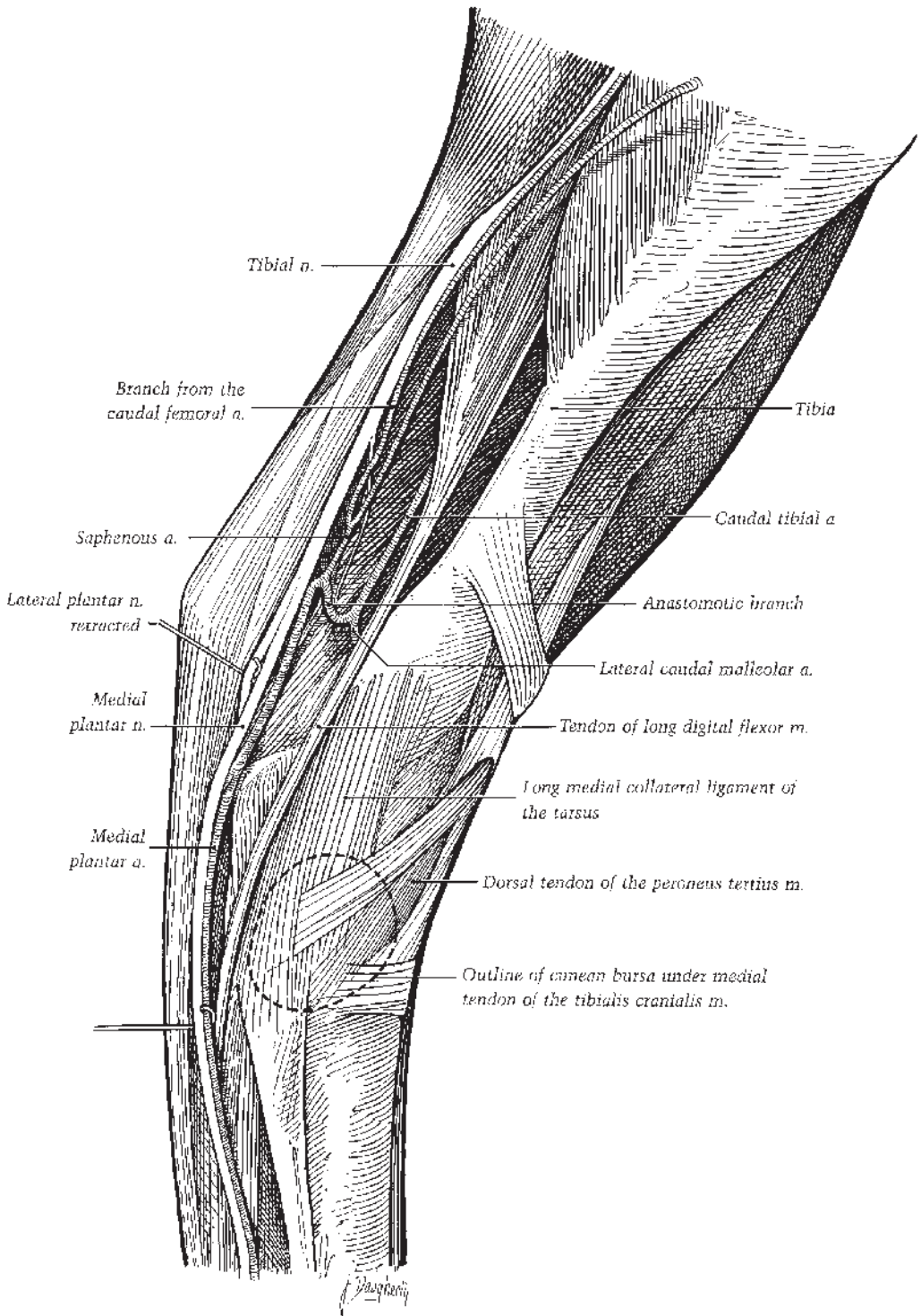
The tendon of the lateral digital extensor muscle is bound by a fibrous band in a groove in the lateral malleolus of the tibia and then traverses a passage through the long lateral collateral ligament of the tarsus as the tendon angles dorsolateral. A synovial sheath enfolds the tendon from just proximal to the lateral malleolus to a point just proximal to the tendon’s junction with the long digital extensor tendon. Plantar to the lateral extensor tendon, the lateroplantar pouch of the tarsocrural joint capsule protrudes between the lateral malleolus and the calcaneus.

### **Medial Aspect**

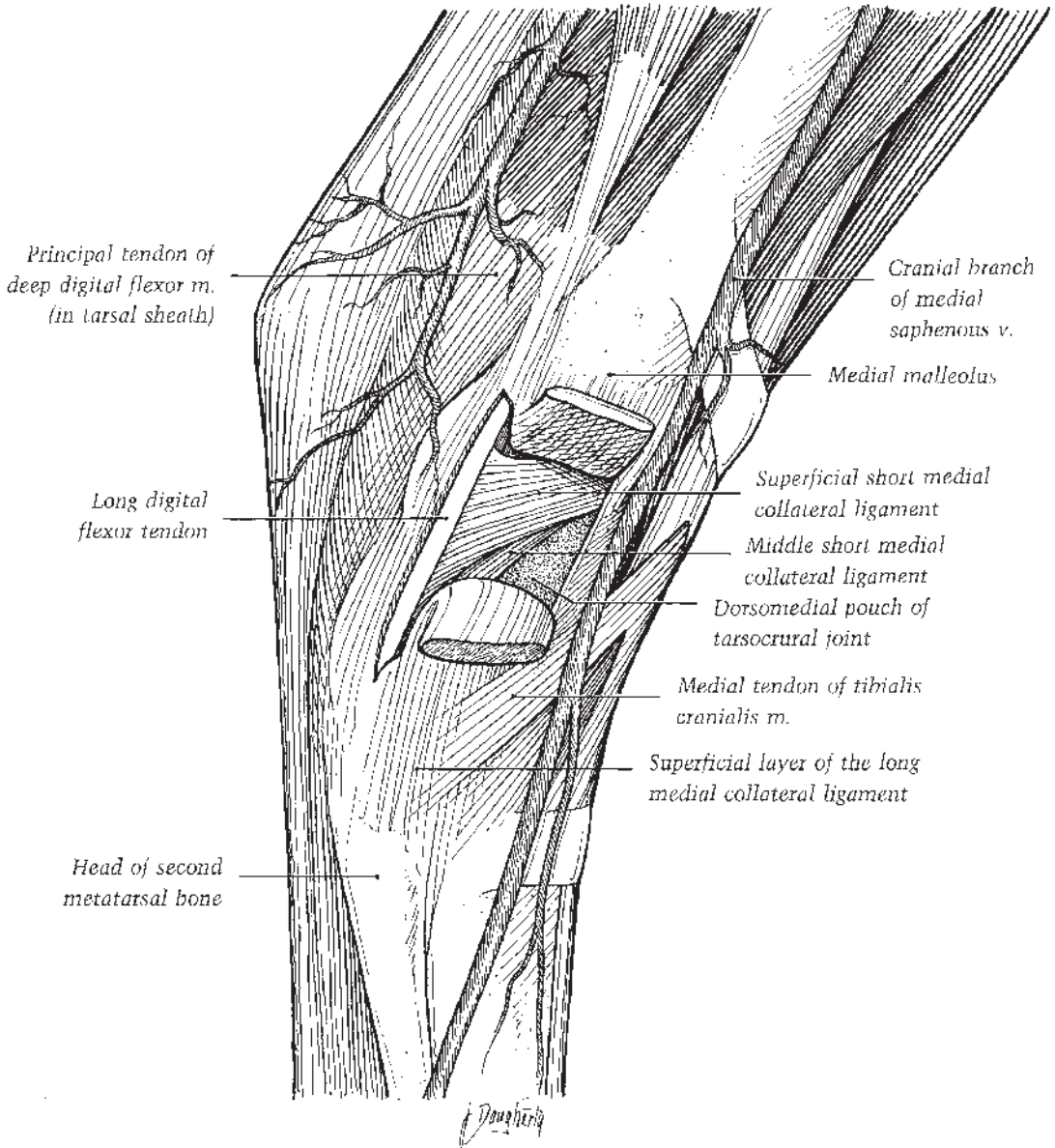
A palpable feature of the medial aspect of the hock is the medial tendon of the tibialis cranialis muscle (colloquially called the “cunean tendon”) as it inserts on the first tarsal bone. The bursa between the cunean tendon and the distal part of the long medial collateral ligament of the tarsus is not normally palpable ([Figure 1.33](#)). The tendon of the medial digital flexor (medial head of the deep digital flexor muscle, sometimes called long digital flexor muscle) passes through a fascial tunnel plantar to the medial collateral ligament ([Figure 1.34](#)). A compartment of the tarsocrural joint capsule, the medioplantar pouch, is located a short distance plantar to the medial digital flexor tendon and proximal to the sustentaculum tail of the calcaneus at the level of the medial malleolus. The tarsal fascia thickens into a flexor retinaculum, bridging the groove



**Figure 1.32.** Dorsal dissection of the right tarsus. The long digital extensor and short digital extensor muscles have been removed. The lateral tendon of the fibularis (peroneus) tertius is sectioned. Please note that the term “fibularis” is currently preferred over “peroneus” (fibular rather than peroneal), although both are widely used.



**Figure 1.33.** Medial dissection of the left distal crus, tarsus, and metatarsus, medial view. Please note that the term “fibularis” is currently preferred over “peroneus” (fibular rather than peroneal), although both are widely used.



**Figure 1.34.** Medial view of the left tarsus. The long medial collateral ligament has been cut and reflected. The tendon sheath of the long digital flexor tendon has been opened. Please note that “long digital flexor” is an older term for the medial head of the deep digital flexor muscle.

on the sustentaculum tail of the calcaneus to form the tarsal canal containing the principal tendon of the deep digital flexor muscle. The tendon’s synovial sheath, the tarsal sheath, extends from a level proximal to the medial malleolus to the proximal fourth of the metatarsus (Figure 1.31).

### Plantar Aspect

In the distal third of the crus, the tendon of the superficial digital flexor muscle curls around the medial side of the tendon of the gastrocnemius muscle to become superficial as the tendons approach the calcaneal tuber. The SDFT flattens

and is joined by aponeurotic connections of the biceps femoris and semitendinosus muscles. This tendinous complex attaches to the point and sides of the calcaneal tuber. The tendon proper of the superficial digital flexor then narrows and continues distad superficial to the long plantar ligament. The calcaneal tendon of the gastrocnemius lies deep to the superficial digital flexor at the hock and inserts on the plantar surface of the calcaneal tuber. An elongated bursa is interposed between the two tendons just above the tarsus. A smaller bursa is present between the SDFT and the calcaneal tuber. These two bursae usually communicate across the lateral surface of the gastrocnemius tendon. An inconstant subcutaneous bursa may develop over the superficial digital flexor at the level of the calcaneal tuber. Dorsolateral to the superficial digital flexor, the long plantar ligament is attached to the plantar surface of the calcaneus, terminating distally on the fourth tarsal and metatarsal bones.

### *Tarsal Joint (Hock Joint)*

The principal component of the composite tarsal joint is the tarsocrural joint. Deep grooves of the cochlear articular surface of the distal end of the tibia articulate with the surface of the trochlea of the talus at an angle of 12° to 15° dorsolateral to the limb's sagittal plane. The interarticular and tarsometatarsal joints are plane joints capable of only a small amount of gliding movement. In the standing position, the dorsal articular angle of the hock is around 150°. During flexion of the tarsocrural joint, the pes is directed slightly laterad due to the configuration of the joint.

A long collateral ligament and three short collateral ligaments bind each side of the equine tarsus (Figures 1.34 and 1.35). The long lateral collateral ligament extends from the lateral malleolus caudal to the groove for the tendon of the lateral digital extensor, attaching distally to the calcaneus, fourth tarsal bone, talus, and the third and fourth metatarsal bones. The three short lateral collateral ligaments are fused proximally where they attach to the lateral malleolus cranial to the groove for the lateral digital extensor tendon. The superficial component, its fibers spiraling 180°, attaches distoplantarly to both the talus and calcaneus, whereas the middle and deep short lateral collateral ligaments attach solely on the lateral surface of the talus.

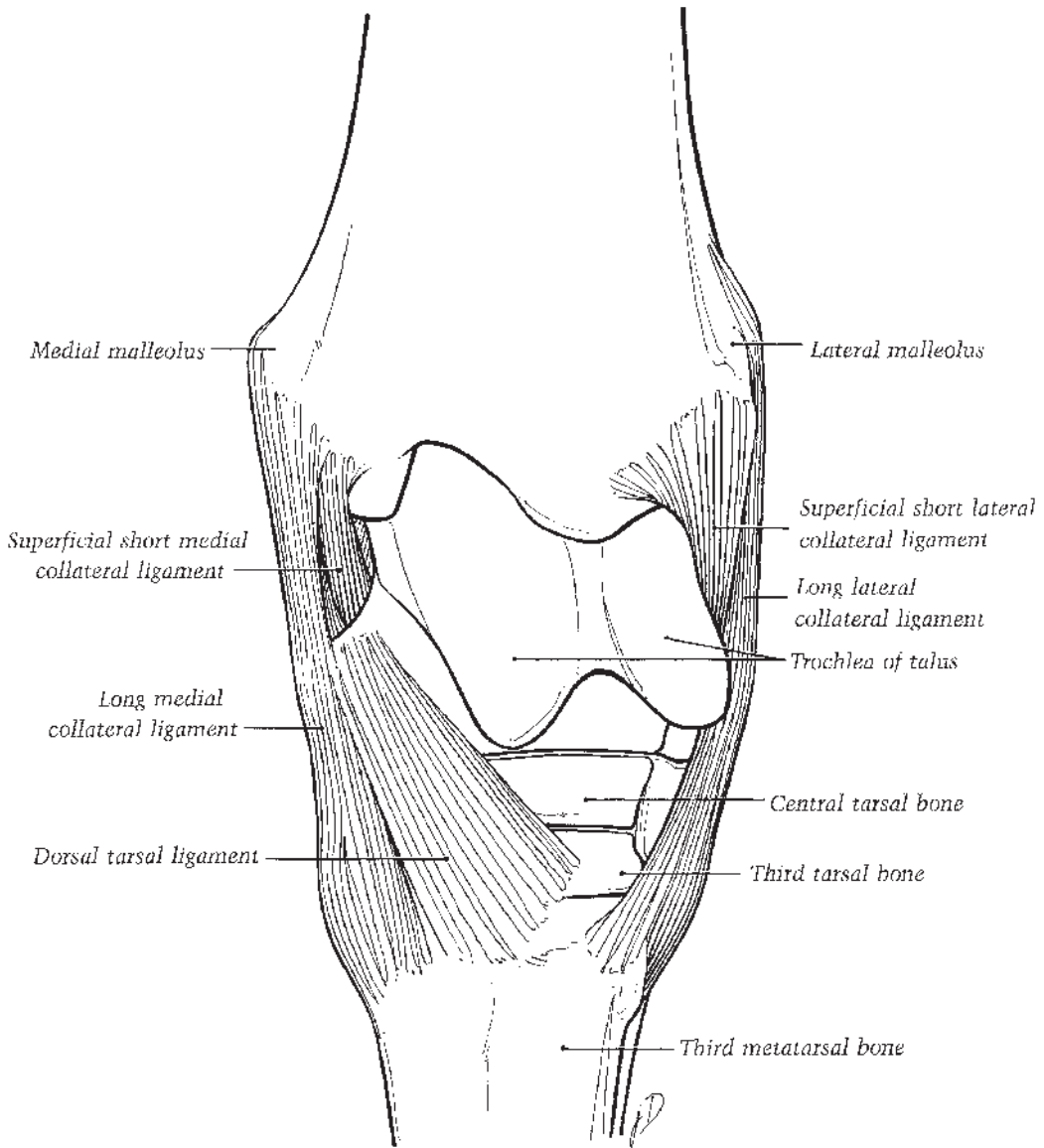
The long medial collateral ligament of the hock has less well-defined borders than its lateral

counterpart. From its proximal attachment on the medial malleolus cranial to the groove for the long digital flexor muscle, the long medial collateral ligament extends distad and divides into two layers along its dorsal border. The superficial layer goes over the cunean tendon of the tibialis cranialis muscle and attaches to the fused first and second tarsal bones and the second and third metatarsal bones just distal to the distal edge of the cunean bursa. The deep layer attaches distally to the distal tuberosity of the talus and the central and third tarsal bones. The plantar edge of the ligament attaches to the deep fascia over the sustentaculum tali and the interosseous ligament between the second and third metatarsal bones.

The flat superficial short medial collateral ligament extends from the medial malleolus to the tuberosities of the talus and the ridge between them (Figure 1.34). The middle short medial collateral ligament extends obliquely from the medial tibial malleolus to the sustentaculum tali and central tarsal bone. It lies on the medial surface of the talus between the two tuberosities, varying in position during movement of the joints. The smallest component, the deep short medial collateral ligament, courses from the distal edge of the medial tibial malleolus obliquely to the ridge between the two tuberosities of the talus.

A dorsal tarsal ligament fans out distad from the distal tuberosity of the talus and attaches to the central and third tarsal bones and the proximal extremities of the second and third metatarsal bones (Figure 1.35). A plantar tarsal ligament attaches to the plantar surface of the calcaneus and fourth tarsal bone and the fourth metatarsal bone. Smaller, less distinct ligaments join contiguous tarsal bones.

The tarsal joint capsule is thinnest dorsally and thickest in its plantar and distal parts. Three pouches can protrude (most notably with joint effusion) from the large tarsocrural synovial sac where it is not bound down by ligaments: the dorsomedial (largest), medioplantar, and lateroplantar pouches. This large synovial space consistently communicates with the synovial sac associated with the proximal intertarsal joint formed by the talus and calcaneus proximally and the central and fourth tarsal bones distally. The distal intertarsal sac, between the central tarsal and contiguous bones and the distal tarsal row, typically does not communicate with the proximal intertarsal sac, but may communicate with the synovial sac of the tarsometatarsal joint.

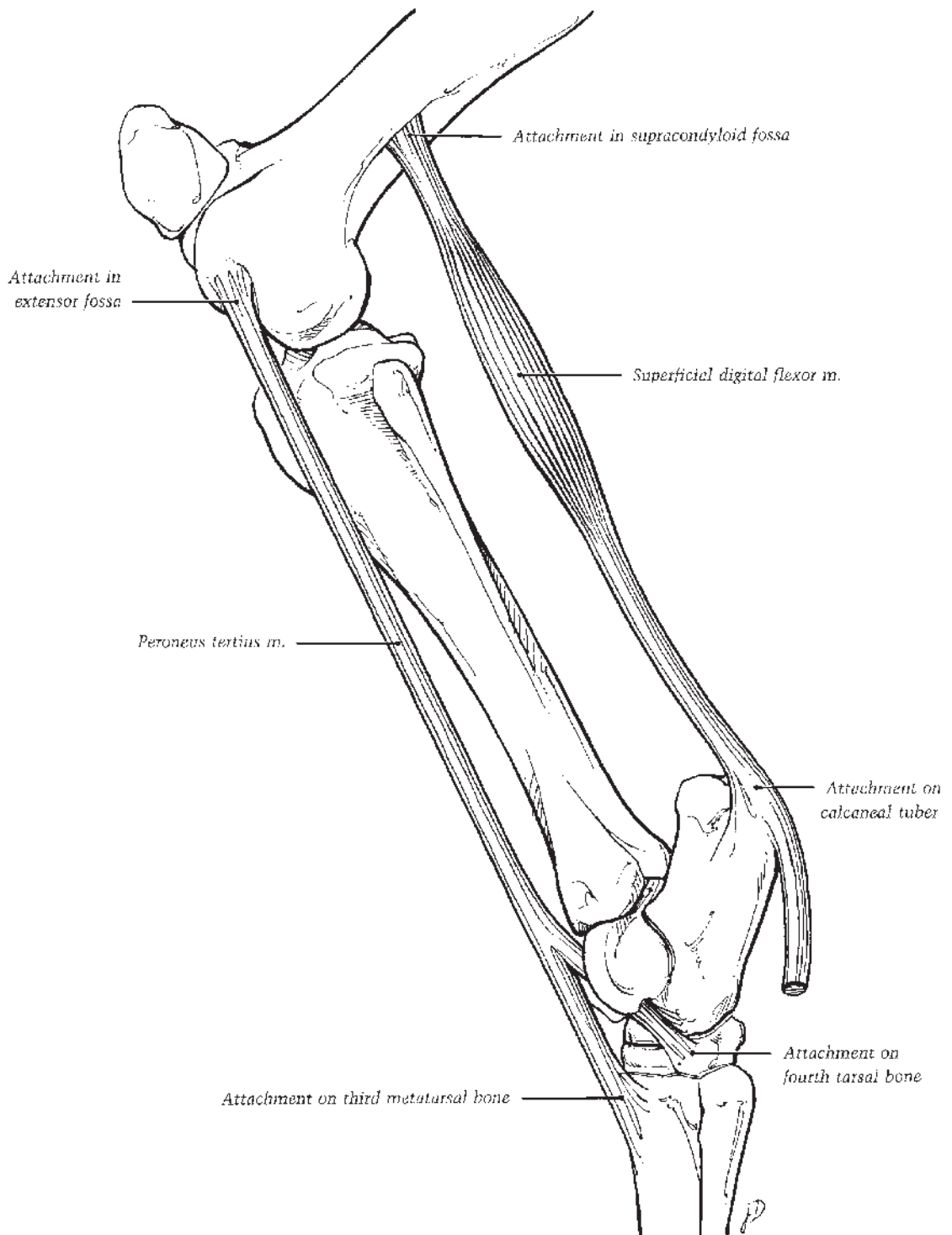


**Figure 1.35.** Dorsal view of the right tarsus.

### Movements of the Tarsocrural Joint

The tarsocrural joint is flexed by contraction of the tibialis cranialis muscle and the passive pull of the tendinous fibularis (peroneus) tertius muscle. Contraction of the gastrocnemius, biceps femoris, and semitendinosus muscles and the passive pull of the tendinous superficial digital flexor muscle extends the joint. By virtue of its attachments in the extensor fossa of the femur proximally, and on the lateral aspect of the tarsus

and dorsal surface of the third metatarsal bone distally, the fibularis tertius passively flexes the tarsocrural joint when the stifle joint is flexed. The superficial digital flexor muscle originates in the supracondyloid fossa of the femur and attaches to the calcaneal tuber. This part of the superficial digital flexor serves to passively extend the tarsocrural joint when the femoro-tibial joint is extended. The two tendinous, passively functioning muscles constitute the reciprocal apparatus (Figure 1.36).



**Figure 1.36.** Reciprocal apparatus, lateral view of left hindlimb. Please note that the term “fibularis” is currently preferred over “peroneus” (fibular rather than peroneal), although both are widely used.



The neurovascular supply to the tarsus is illustrated in [Figures 1.30, 1.31 and 1.32](#).

### Crus (Leg or Gaskin)

The crus or true leg is the region of the hindlimb containing the tibia and fibula. Thus, it extends from the tarsocrural joint to the femorotibial joints. The transversely flattened proximal end of the fibula articulates with the lateral condyle of the tibia. Distally, the fibula narrows to a free end, terminating in the distal one-half to two-thirds of the crus as a thin ligament. An interosseous ligament occupies the space between the two bones. The cranial tibial vessels pass through the proximal part of the ligament. It should be noted that the current preference among anatomists is to replace the Greek word “peroneus” with its Latin equivalent “fibularis” in the naming of crural structures.

Beneath the skin and superficial fascia a heavy crural fascia invests the entire crural region. The superficial layer of the deep crural fascia is continuous with the femoral fascia; the middle layer is continuous with tendons descending from the thigh. The two layers are inseparable in several places. The crural fascia blends with the medial and lateral patellar ligaments and attaches to the medial tibia in the middle of the leg. Caudally, the crural fascia forms the combined aponeuroses of the biceps femoris and semitendinosus muscles that attach with the SDFT to the calcaneal tuber. Under the two common fasciae a deeper layer covers the muscles of the leg.

### Cranial Aspect

The belly of the long digital extensor muscle is prominent beneath the skin on the craniolateral aspect of the crus. It originates in common with the fibularis tertius from the extensor fossa of the femur, the common tendon descending through the extensor sulcus of the tibia ([Figure 1.37](#)). The long digital extensor muscle is related deeply to the tendinous fibularis tertius and the fleshy cranial tibial muscles, and caudally to the lateral digital extensor muscle from which it is separated by a distinct intermuscular septum. Deep to and intimately associated with the fibularis tertius, the cranial tibial muscle covers the craniolateral surface of the tibia, originating from the tibial tuberosity, lateral condyle, and lateral border, and from the crural fascia ([Figure 1.37](#)). The superficial fibular nerve courses distad in the groove between the digital extensor muscles and angles cranial toward the hock.

The deep fibular nerve courses distad between the two muscles on the cranial surface of the intermuscular septum. At its origin, this nerve sends branches to the digital extensor muscles and the fibularis tertius and tibialis cranialis muscles.

### Lateral Aspect

The tibial attachment of the biceps femoris muscle, a broad aponeurosis, sweeps across the proximal third of the lateral aspect of the crus to attach to the cranial border of the tibia. Deep to the belly of the biceps femoris, the common fibular nerve crosses the lateral surface of the lateral head of the gastrocnemius muscle and divides into superficial and deep fibular nerves ([Figure 1.38](#)). Caudal to these, the lateral digital extensor muscle extends distad from its origins on the fibula, interosseous ligament, lateral surface of the tibia, and lateral collateral ligament of the femorotibial joint. The lateral head of the deep digital flexor muscle lies caudal to the belly of the lateral digital extensor.

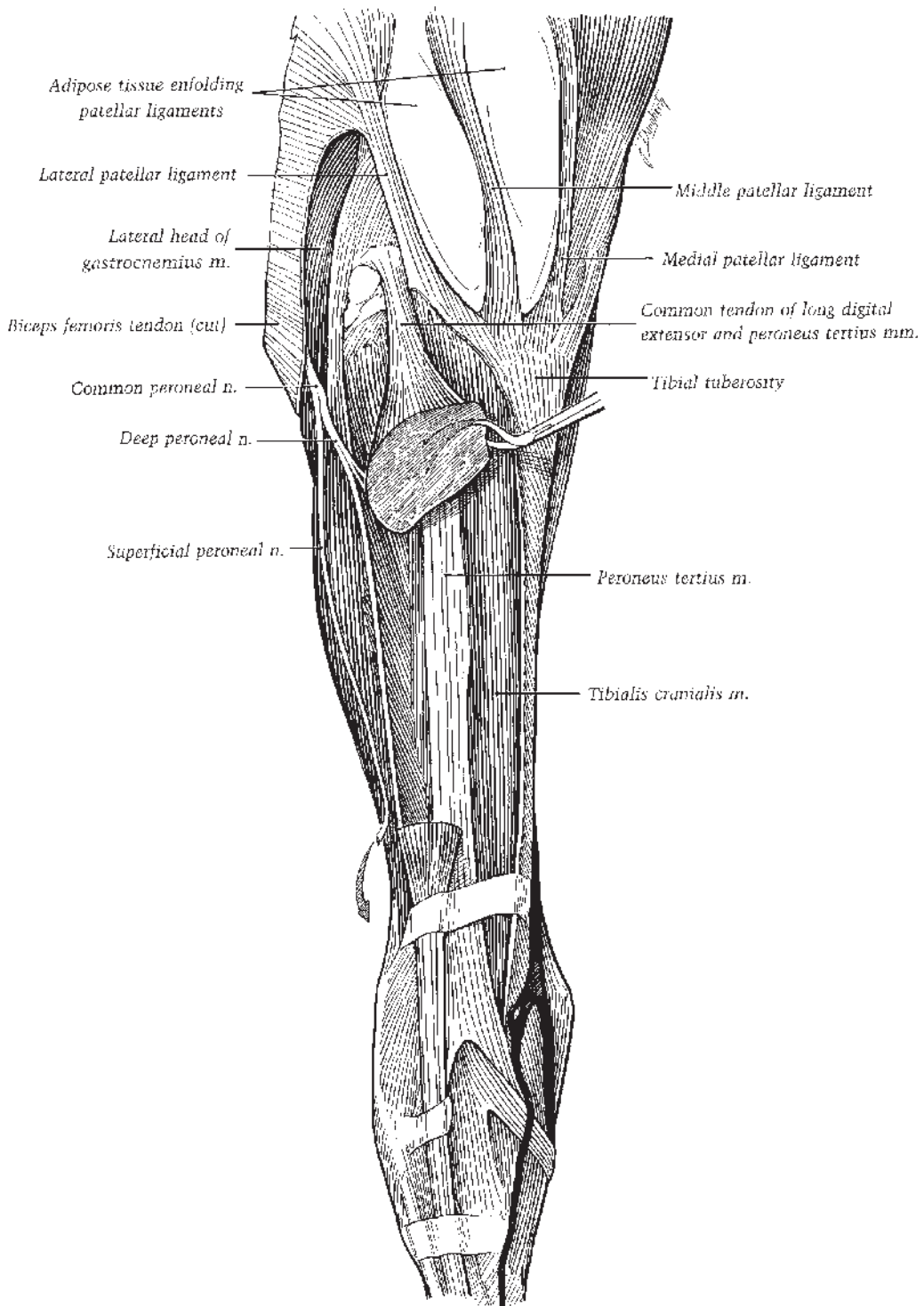
The lateral head of the gastrocnemius originates on the lateral supracondyloid tuberosity of the femur. Under the crural fascia in the proximal half of the crus, the small soleus muscle extends from its origin on the fibula along the lateral aspect of the gastrocnemius muscle to join the gastrocnemius tendon ([Figure 1.38](#)).

### Caudal Aspect

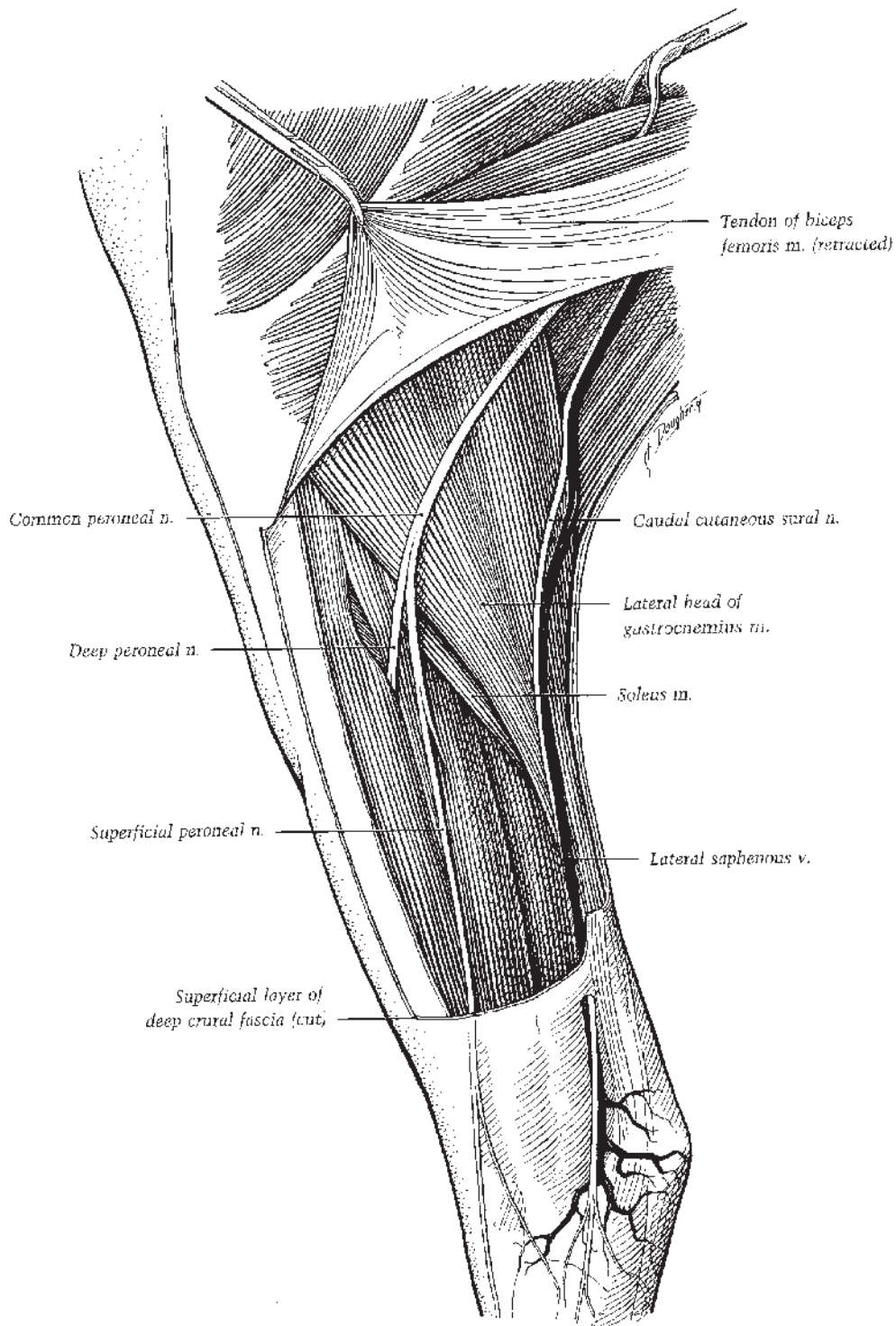
Descending from their origins on the supracondyloid tuberosities of the femur, the two heads of the gastrocnemius enclose the round, mostly tendinous superficial digital flexor. The tendon of the latter wraps medially from deep to superficial around the gastrocnemius tendon in the distal third of the crus. The deep digital flexor muscle possesses three heads with a variety of names that appear in anatomical texts ([Figure 1.38](#)). In the horse, the tendons of all three heads unite with the main deep digital flexor tendon. In the distal third of the crus, the flat tendon of the caudal tibial (the superficial head) joins the larger tendon of the lateral head, whereas the tendon of the medial head (medial digital flexor muscle) pursues its course over the medial aspect of the hock to join the principal tendon in the metatarsus ([Figure 1.34](#)).

### Stifle (Genu)

The stifle is the region including the stifle joint (femorotibial joints plus the femoropatellar joint) and surrounding structures.



**Figure 1.37.** Dorsal view of the right stifle, crus, and tarsus. The long digital extensor muscle belly has been removed, along with the terminal parts of the superficial fibular (peroneal) nerve (arrow). Please note that the term “fibularis” is currently preferred over “peroneus” (fibular rather than peroneal), although both are widely used.



**Figure 1.38.** Superficial dissection of lateral aspect of left stifle, crus, and tarsus. Please note that the term “fibularis” is currently preferred over “peroneus” (fibular rather than peroneal), although both are widely used.

## Cranial Aspect

Deep to the skin, three patellar ligaments descend from the patella, converging to their attachments on the tibial tuberosity. An extensive pad of adipose tissue is interposed between the ligaments and the joint capsule of the femoropatellar joint (Figure 1.37). The adipose tissue enfolds the ligaments, wrapping around their sides. The space between the medial and middle patellar ligaments is greater than the space between the middle and lateral ligaments. This difference reflects the origin of the medial patellar ligament from the parapatellar fibrocartilage. This is a large mass extending mediad from the patella in such a manner that its continuation, the medial patellar ligament, courses proximal and then medial to the medial ridge of the trochlea on the femur. The medial patellar ligament attaches to the medial side of the tibial tuberosity. As it descends from the patella to its insertion, two bursae lie under the middle patellar ligament, one between the proximal part of the ligament and the apex of the patella, and the other between the ligament and the proximal part of the groove. Inclining mediad from the lateral aspect of the cranial surface of the patella, the lateral patellar ligament serves as an attachment for a tendon from the biceps femoris muscle and then for the fascia lata just before the ligament attaches to the lateral aspect of the tibial tuberosity. The tendon from the biceps femoris continues on to the cranial surface of the patella.

The base, cranial surface, and medial border of the patella, and the parapatellar fibrocartilage and femoropatellar joint capsule, serve as attachments for the insertions of the quadriceps femoris muscle.

## Lateral Aspect

The insertional parts of the biceps femoris muscle and, caudally, the semitendinosus muscle, dominate the lateral aspect of the stifle region. The tendon from the cranial division of the biceps femoris inserts on the lateral patellar ligament and the patella, and the tendon from the middle division of the muscle sweeps craniodistad to the cranial border of the tibia.

Reflection of the distal part of the biceps femoris muscle reveals the following (Figure 1.39): The lateral femoropatellar ligament extends obliquely from the lateral epicondyle of the femur to the lateral border of the patella. The lateral surface of the lateral head of the gastrocnemius muscle is crossed by the common fibular

nerve and, further caudad, by the caudal cutaneous sural nerve and the lateral saphenous vein carrying blood to the caudal femoral vein. As it extends from the lateral epicondyle of the femur to the head of the fibula, the thick lateral collateral ligament of the femorotibial joint covers the tendon of origin of the popliteus muscle that also originates from the lateral epicondyle. A pouch from the lateral femorotibial joint capsule lies beneath the tendon. A common tendon of the long digital extensor and fibularis (peroneus) tertius takes origin from the extensor fossa in the distal surface of the lateral epicondyle of the femur. The tendon is cushioned as it extends distad by an elongated pouch from the lateral femorotibial joint capsule.

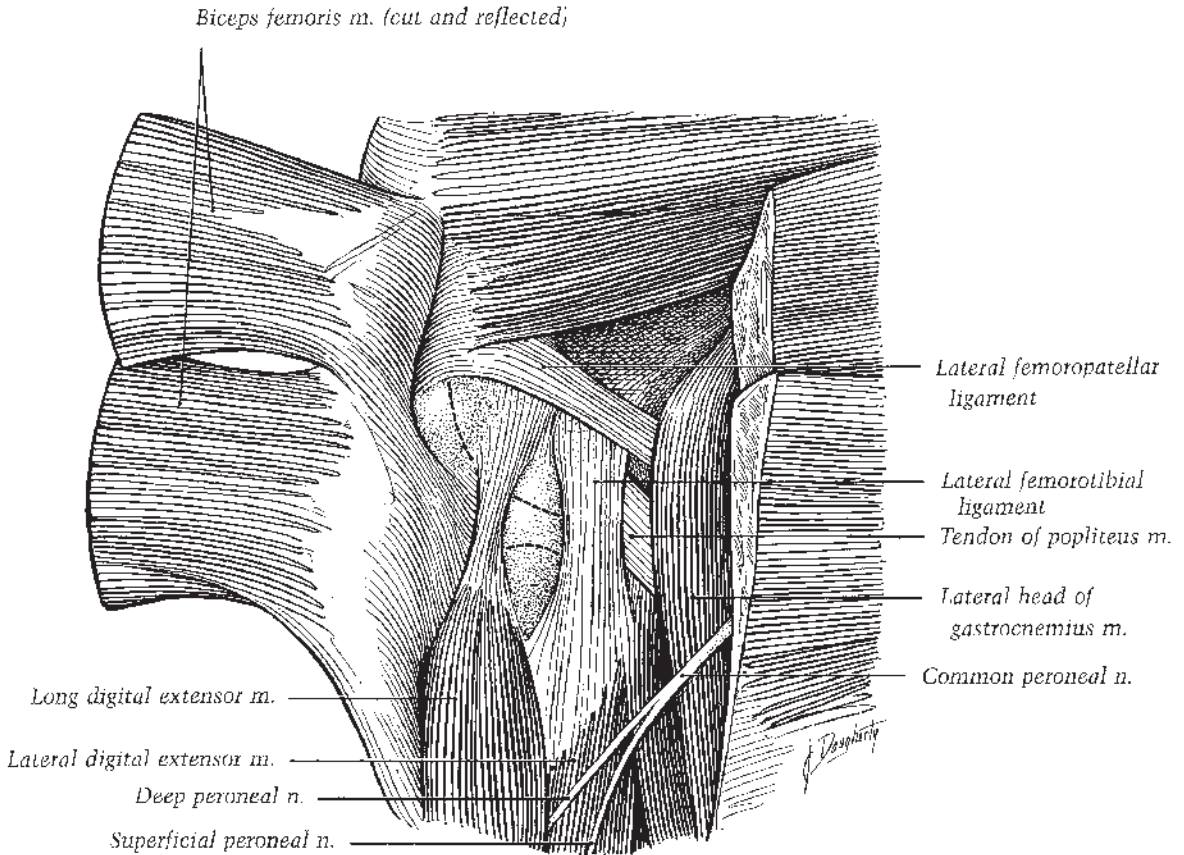
## Caudal Aspect

Under the skin and fascia on the caudal aspect of the stifle (supplied by branches of the caudal femoral nerve) the caudal part of the biceps femoris muscle covers the lateral head of the gastrocnemius, the tibial tendon of the biceps femoris going to the cranial border of the tibia, its tarsal tendon continuing distad. The semitendinosus muscle sweeps to its insertion on the cranial border of the tibia and distad toward its tarsal insertion, covering the medial head of the gastrocnemius. The tendons of the smaller medial head and larger lateral head of the gastrocnemius combine and, at first, the tendon lies superficial to the tendon of the superficial digital flexor muscle. Separation of the two heads of the gastrocnemius muscle reveals the tendinous superficial digital flexor muscle that arises in the supracondyloid fossa of the femur between the two heads, its initial part embedded in the lateral head (Figure 1.40).

The triangular popliteus muscle extends mediolateral from its origin on the lateral epicondyle of the femur (Figure 1.39). The tendon of origin passes deep to the lateral collateral ligament of the stifle joint, cushioned by an extension of the lateral pouch of the femorotibial joint capsule. The popliteus spreads out and inserts on the medial part of the caudal surface of the tibia proximal to the popliteal line, contacting the medial head of the deep digital flexor (Figure 1.40, 1.41).

## Medial Aspect

Cranially, the vastus medialis of the quadriceps femoris muscle attaches to the parapatellar



**Figure 1.39.** Deep dissection of the lateral aspect of the left stifle with femoral and tibial condylar surfaces indicated by dashed lines. Please note that the term “fibularis” is currently preferred over “peroneus” (fibular rather than peroneal), although both are widely used.

fibrocartilage, medial border of the patella, and medial patellar ligament. The straplike sartorius muscle attaches to the medial patellar ligament and the tibial tuberosity. Caudal to the sartorius, the gracilis muscle also attaches to the medial patellar ligament and to the medial collateral ligament of the femorotibial joint and the crural fascia (Figure 1.42).

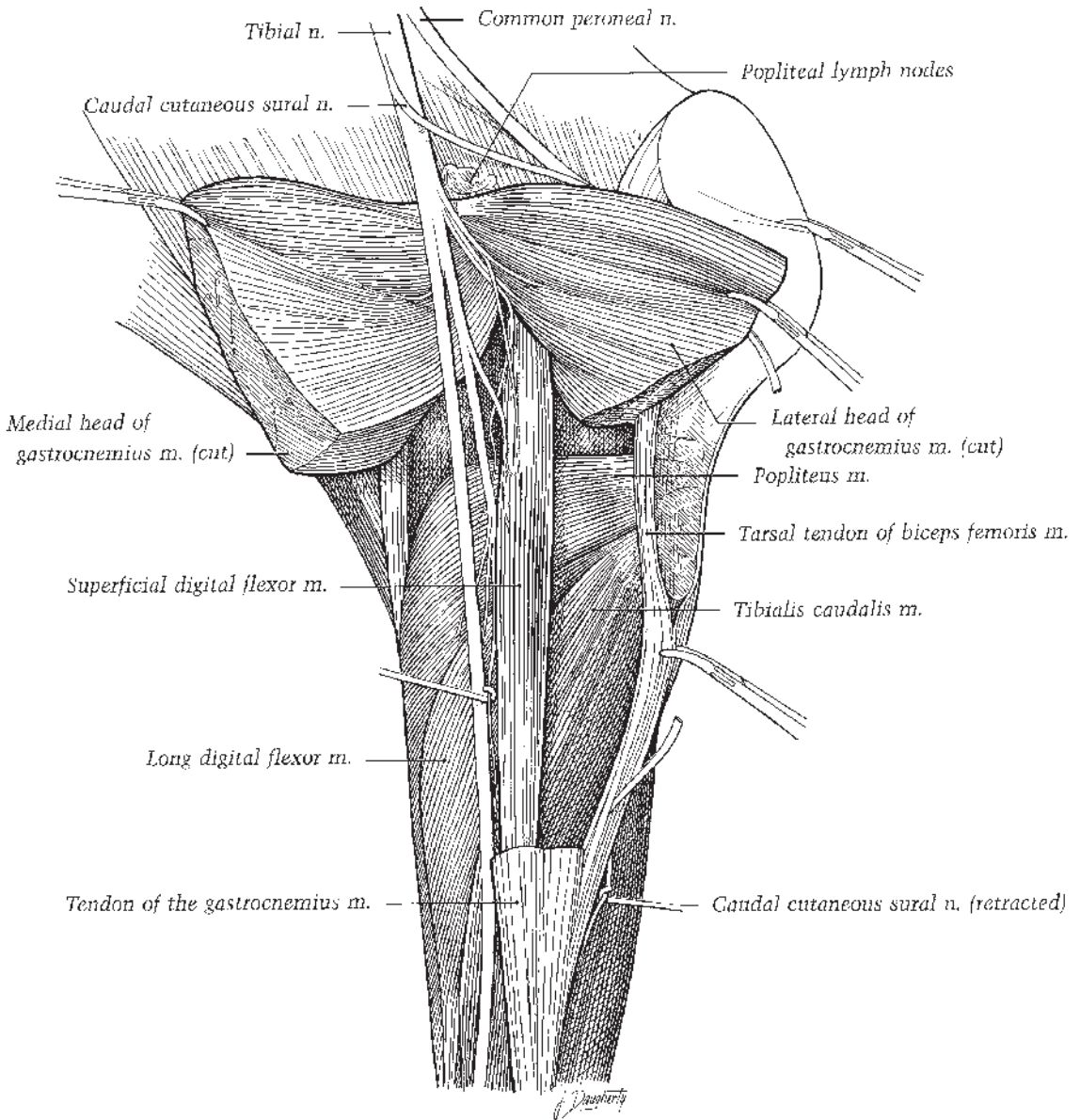
A thinner medial collateral ligament of the femorotibial joint reaches from the medial epicondyle of the femur to just distal to the margin of the medial tibial condyle, detaching fibers to the medial meniscus (Figure 1.42). The adductor muscle inserts on the ligament and the medial epicondyle. The medial femoropatellar ligament is also thinner than its lateral counterpart, blending with the femoropatellar joint capsule as the ligament extends from the femur proximal to the medial epicondyle to the parapatellar fibrocartilage.

## Stifle Joint

The stifle is the “true knee.” It comprises two joints, the femoropatellar and femorotibial joints, which together form a hinge joint. The synovial space of the stifle is significantly partitioned into three distinct sacs: the femoropatellar sac and the right and left femorotibial joint sacs.

### Femoropatellar Joint

The patella is a sesamoid bone intercalated in the termination of the quadriceps femoris muscle with the three patellar ligaments, constituting the tendon of insertion. A thin, voluminous joint capsule attaches peripheral to the edge of the femoral trochlea, with its patellar attachment close to the edge of the patellar articular surface. A large pouch from the joint capsule protrudes proximad under a mass of adipose tissue and the

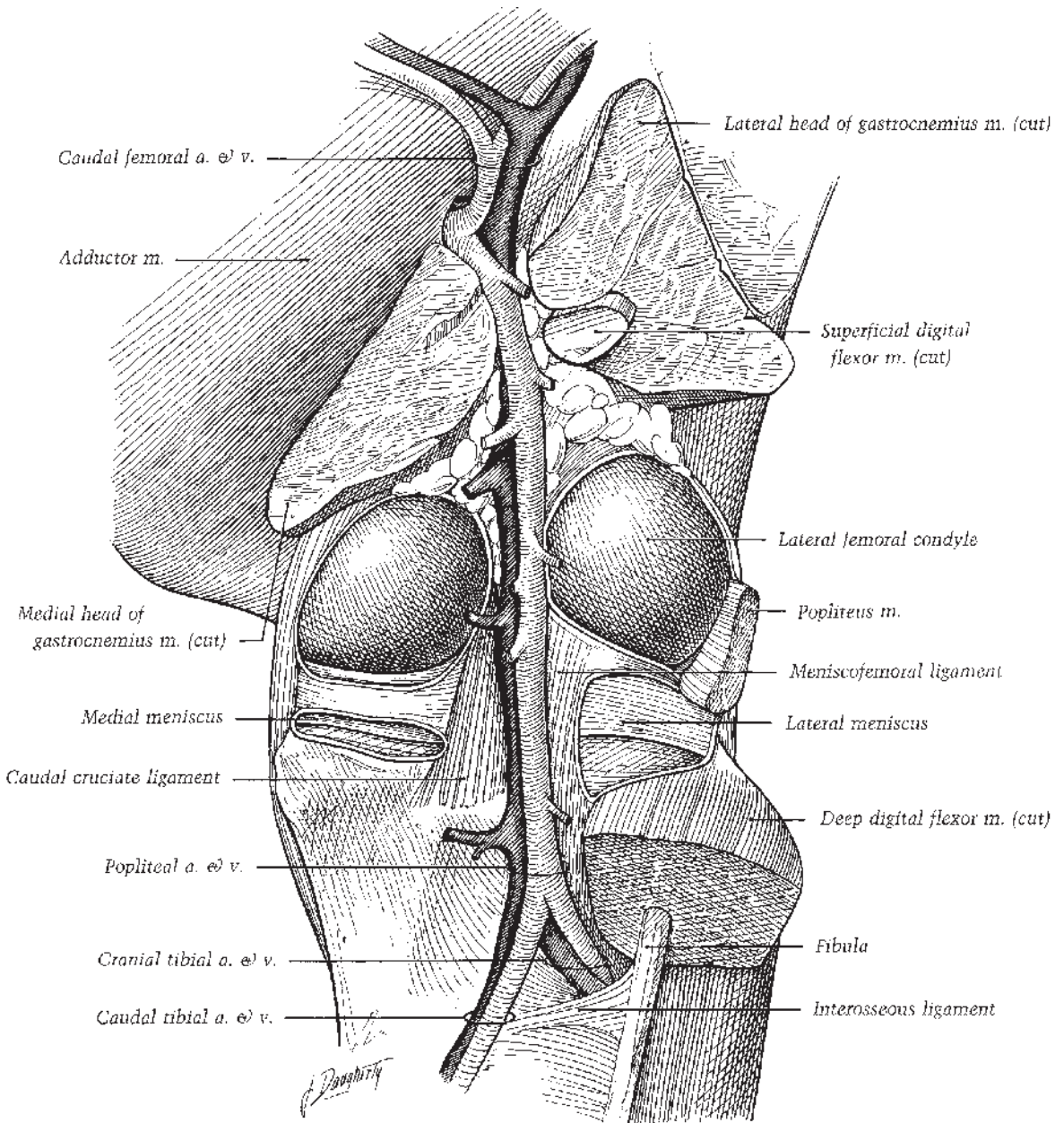


**Figure 1.40.** Dissection of the caudal aspect of the right stifle and crus. Please note that the term “fibularis” is currently preferred over “peroneus” (fibular rather than peroneal), although both are widely used.

distal part of the quadriceps femoris muscle. The distal extremity of the femoropatellar joint capsule contacts the femorotibial joint capsule. The vastus intermedius of the quadriceps femoris attaches, in part, to the femoropatellar joint capsule, acting to tense the capsule during extension of the femoropatellar joint.

The articular surface of the patella is much smaller than the trochlear surface of the femur;

the larger gliding surface of the trochlea accommodates the proximal-distal movements of the patella. A wide groove separates the substantially larger medial ridge of the trochlea from the smaller, slightly more distal lateral ridge. Articular cartilage covers the entire large, rounded medial ridge; the cartilage covering the more regularly rounded lateral ridge extends only part way over the lateral surface. Contact between the patella



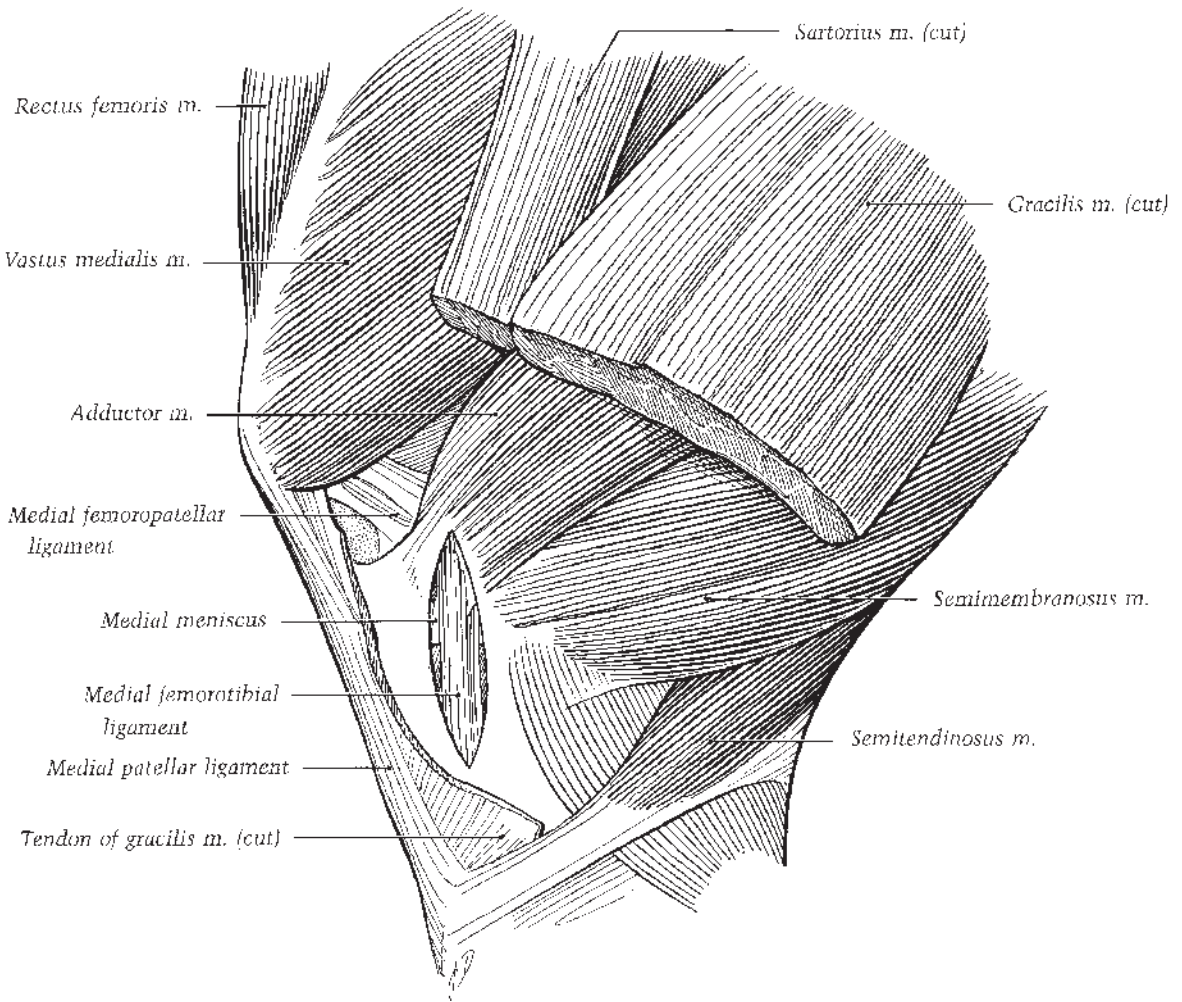
**Figure 1.41.** Deep dissection of the caudal aspect of the right stifle. The joint capsule of the femorotibial joint has been opened.

and trochlea changes as the patella moves on its larger gliding surface during flexion of the stifle joint. The patella rolls on to its narrow distal articular surface (resting surface) as the parapatellar fibrocartilage maintains its tight relationship over the trochlea's medial ridge due to tension exerted by the medial patellar ligament. The

narrow craniodorsal surface of the proximal part of the trochlea may be termed its resting surface.

### Femorotibial Joint

The fibrous part of the joint capsule is thick caudally, thin cranially. The cranial and caudal



**Figure 1.42.** Deep dissection of the medial aspect of the left stifle. The tendon of the adductor muscle is incised to reveal the medial collateral ligament of the stifle.

cruciate ligaments of the femorotibial joint lie between the joint capsule's medial and lateral synovial sacs. Two fibrocartilaginous menisci intervene between the femoral and tibial articular surfaces, thus partially subdividing each sac. An extension of the lateral synovial sac encloses the tendon of origin of the popliteus muscle and another protrudes distad under the common tendon of origin of the long digital extensor and fibularis tertius muscles.

The two fibrocartilaginous menisci are crescent-shaped, being thicker peripherally and thinner along the concave edge. Their proximal surfaces are concave to accommodate the convexity of the femoral condyles. Distally they conform to the peripheral parts of the articular

surfaces of the tibial condyles. Cranial and caudal ligaments anchor each meniscus to the tibia, and a meniscofemoral ligament attaches the caudal aspect of the lateral meniscus to the caudal surface of the intercondyloid fossa of the femur.

In addition to the support rendered by medial and lateral collateral ligaments, the femur and tibia are joined by the two cruciate ligaments that cross one another in the intercondyloid space between the two synovial sacs of the femorotibial joint. The caudal cruciate ligament, the more substantial of the two, extends from the cranial surface of the intercondyloid fossa of the femur to the popliteal notch of the tibia, crossing the medial aspect of the cranial (or



lateral) cruciate ligament. From its attachment on the lateral wall of the intercondyloid fossa, the cranial cruciate ligament attaches to a central fossa between the articular surfaces of the condyles.

### Movements of the Stifle Joint

In the standing position, the caudal angle of the stifle joint is around 150°. The quadriceps femoris muscle is relatively relaxed in this position. Extension of the stifle joint through action of the quadriceps femoris, tensor fasciae lata, and cranial division of the biceps femoris muscles plus passive traction exerted by the fibularis tertius is limited by tension from the collateral and cruciate ligaments. Flexion of the joint by the semitendinosus, middle division of the biceps femoris, popliteus, and gastrocnemius muscles, plus passive traction exerted by the superficial digital flexor, is limited only by the caudal muscle masses. During flexion the crus is rotated slightly medially, and the femoral condyles and menisci move slightly caudad on the tibial condyles with somewhat more movement on the lateral surfaces.

When a horse shifts its weight to rest on one hindlimb, the supportive limb flexes slightly as the contralateral relaxed limb is brought to rest on the toe. The pelvis is tilted so that the hip of the supporting limb is higher. The stifle on the supporting limb is locked in position due to a slight medial rotation of the patella as the medial patellar ligament and parapatellar cartilage slip farther caudad on the proximal part of the medial trochlear ridge. The loop created by the parapatellar cartilage and medial patellar ligament is pulled proximad and medially to engage the medial ridge of the femoral trochlea. The locked position achieved by this configuration together with the support rendered by the other components of the stay apparatus minimizes muscular activity in the supporting limb while the relaxed contralateral hindlimb is resting. A very small amount of muscle tone, confined to the vastus medialis, is necessary to stabilize the stifle in the locked position.

The neurovascular supply to the stifle region is illustrated in Figures 1.38, 1.39, 1.40, 1.41.

## Thigh and Hip

### Lateral Aspect

From caudal to cranial, the superficial muscles of the lateral thigh and hip are the semitendinosus, biceps femoris, gluteus superficialis, gluteus

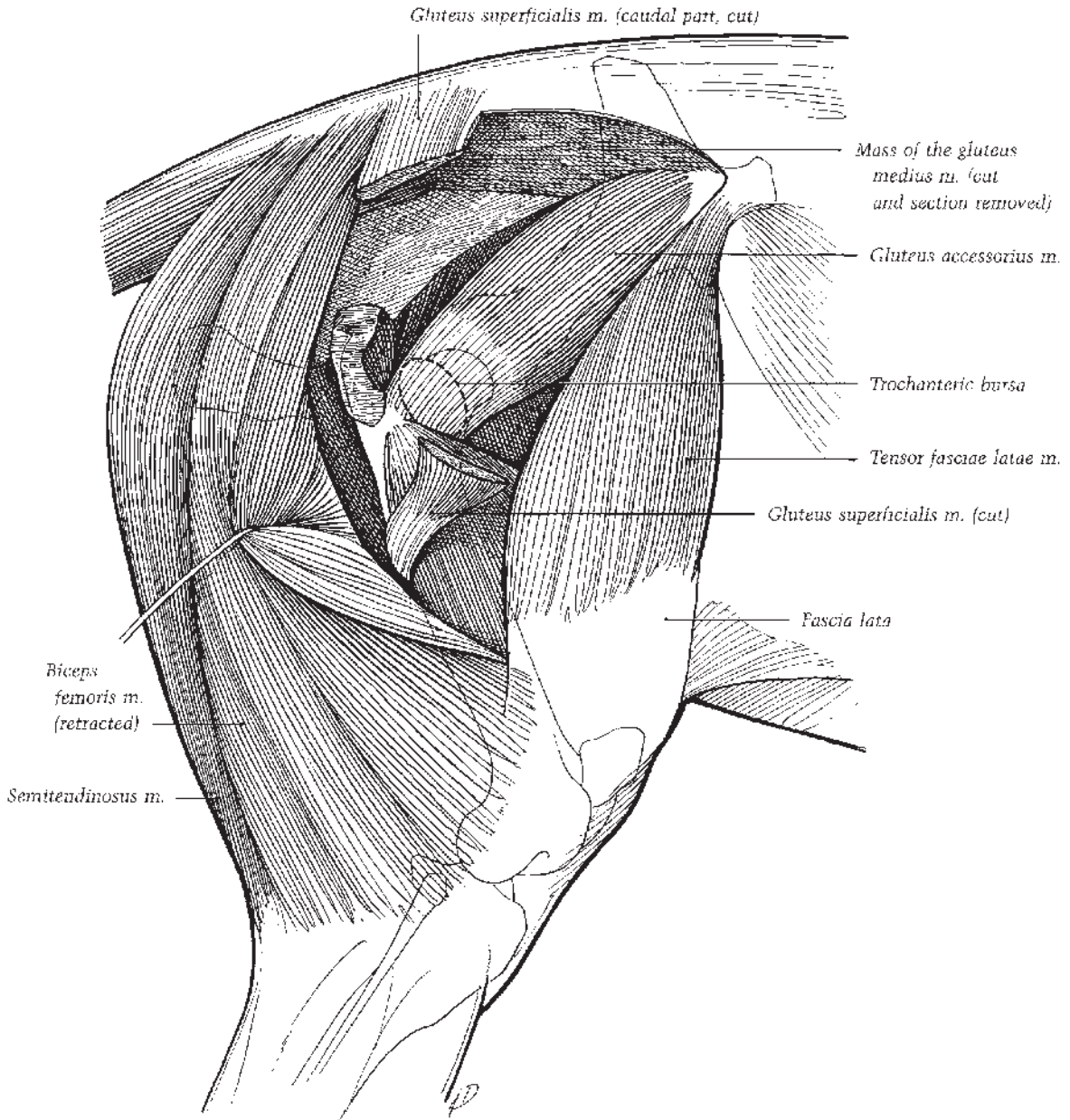
medius, and tensor fasciae lata. Both the semitendinosus and biceps femoris have ischiatic and vertebral origins. The semitendinosus attaches to the first and second caudal vertebrae and fascia of the tail and the biceps femoris attaches to the dorsal sacroiliac ligament and the gluteal and tail fasciae. A prominent longitudinal groove marks the site of the intermuscular septum between the semitendinosus and the biceps femoris muscles.

The strong gluteal fascia gives origin to and unites the long caudal head and the cranial head of the gluteus superficialis (superficial gluteal) muscle. The two heads of the superficial gluteal muscle unite in a flat tendon that attaches to the trochanter tertius of the femur. Extending caudad from the aponeurosis of the longissimus lumborum muscle, the large gluteus medius (middle gluteal) muscle forms most of the mass of the rump. The middle gluteal muscle also takes origin from the gluteal surface of the ilium, the coxal tuber and sacral tuber, the sacrotuberal and dorsal sacroiliac ligaments, and the gluteal fascia. Distally the muscle attaches to the greater trochanter, a crest distal to the greater trochanter and the lateral surface of the intertrochanteric crest.

The tensor fasciae latae muscle arises from the coxal tuber and fans out distally to insert into the fascia lata. An intermuscular septum attaches the caudal part of the muscle to the cranial head of the superficial gluteal. The fascia lata attaches to the patella and the lateral and middle patellar ligaments (Figure 1.43). The intermuscular septum between the biceps femoris and semitendinosus, the septa between the three divisions of the biceps femoris, and a septum between the biceps femoris and vastus lateralis all arise from the fascia lata (Figures 1.43).

Deeply on the lateral aspect of the hip, the smaller deep part of the gluteus medius, the gluteus accessorius, has a distinct flat tendon that plays over the convexity of the greater trochanter on its way to attach on the crest distal to the trochanter. The large trochanteric bursa lies between the tendon and the cartilage covering the convexity (Figure 1.43). The small gluteus profundus muscle is deep to the caudal part of the gluteus medius, arising from the ischiatic spine and body of the ilium and attaching on the medial edge of the convexity of the greater trochanter (Figure 1.44). This muscle covers the hip joint and parts of the articularis coxae and rectus femoris muscles. A bursa is commonly present under the tendon of insertion of the gluteus profundus.

On the caudal side of the proximal part of the femur, the gemelli, external obturator, and

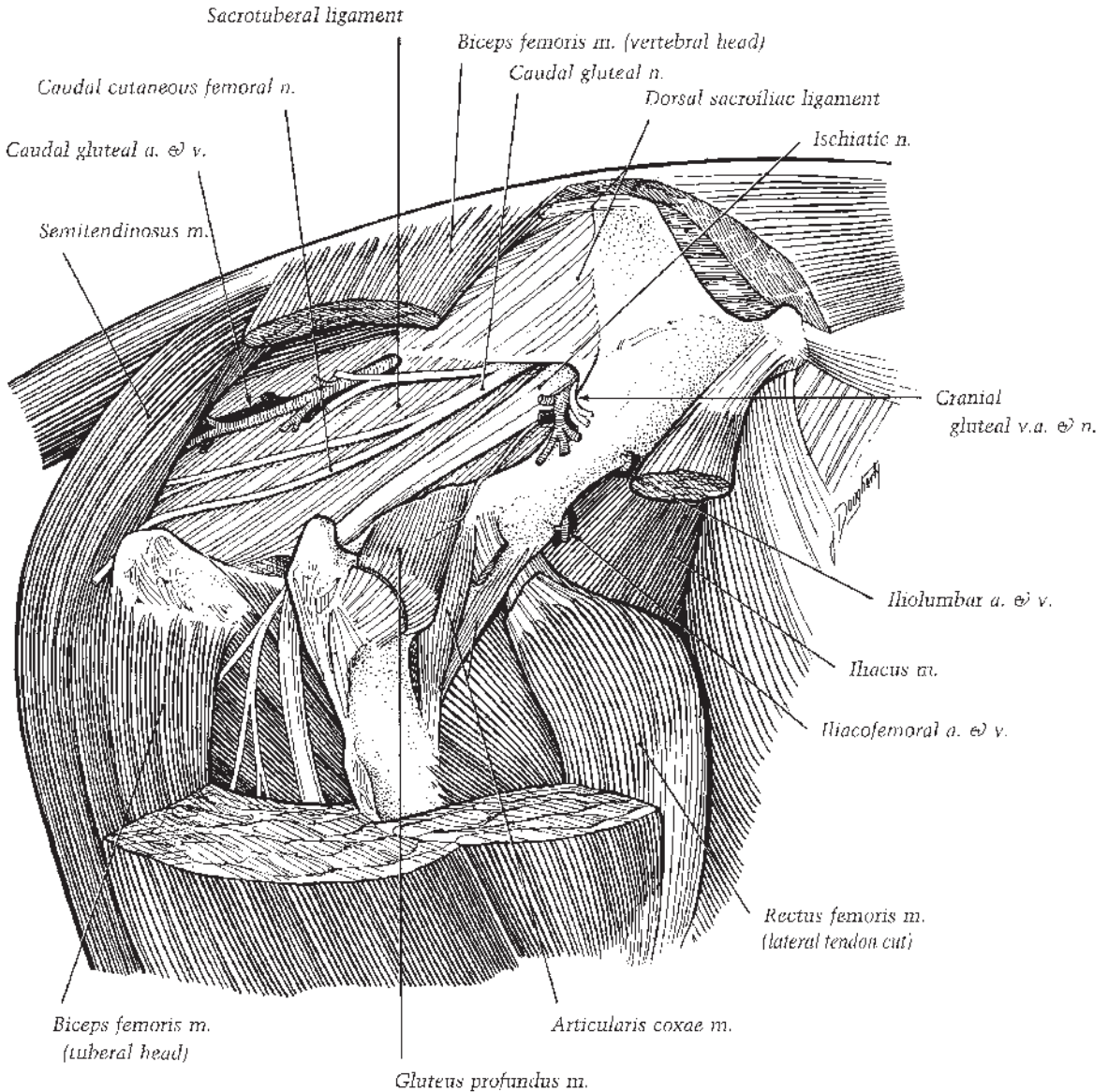


**Figure 1.43.** Lateral dissection of the right thigh and hip. Most of the superficial and middle gluteal muscles have been removed.

internal obturator muscles come from their respective origins on the ischium, pubis, ilium, and wing of the sacrum to insert in the trochanteric fossa. The quadratus femoris muscle extends from the ventral aspect of the ischium to a line on the femur near the distal part of the lesser trochanter.

A broad sheet of dense white fibrous connective tissue, the sacrotuberous (sacrotuberous) ligament, forms most of the lateral wall of the pelvic

cavity, attaching dorsally to the sacrum and first two caudal vertebrae and ventrally to the ischiatic spine and ischiatic tuber (Figure 1.44). The ventral edge of the sacrotuberous ligament completes two openings along the dorsal edge of the ischium: the lesser and greater ischiadic foramina, which allow passage of neurovascular bundles from the lumbosacral region to the muscle of the rump.



**Figure 1.44.** Deep dissection of the right hip, lateral view.

The large, flat sciatic nerve passes through the greater ischiatic foramen and courses ventrocaudad on the sacrotuberale ligament and then on to the origin of the gluteus profundus (deep gluteal). Turning distad, the ischiadic nerve passes over the gemelli, the tendon of the internal obturator, and the quadratus femoris, supplying branches to these muscles. A large branch is detached from the deep side of the nerve. This branch supplies branches to the semimembranosus, the biceps femoris and semitendinosus, and

adductor medially and the biceps femoris laterally. The sciatic nerve terminates by dividing into common fibular and tibial nerves.

### Medial Aspect

The broad gracilis muscle covers most of the medial aspect of the thigh, attaching proximally to the prepubic tendon, adjacent surface of the pubis, accessory femoral ligament, and middle of the pelvic symphysis. The muscle belly ends

distally by joining a wide thin aponeurosis of insertion. The narrow sartorius muscle takes origin from the tendon of the psoas minor and ilial fascia and descends toward its insertion in the stifle, which blends with the tendon of the gracilis. Deep to the gracilis lies the pectineus muscle. It attaches proximally to the cranial border of the pubis, the prepubic tendon, and accessory femoral ligament. Distally, the pectineus attaches to the medial border of the femur. The femoral canal, containing the neurovascular bundle supplying the pelvic limb, is delimited caudally by the pectineus, cranially by the sartorius, laterally by the vastus medialis and iliopsoas, and medially by the femoral fascia and cranial edge of the gracilis. The canal contains the femoral artery and vein, the saphenous nerve, and an elongated group of several lymph nodes of the deep inguinal lymphocenter embedded in adipose tissue (Figure 1.45).

Caudal to the pectineus and vastus medialis, the thick adductor muscle extends from the ventral surface of the ischium and pubis and the origin of the gracilis muscle to the caudal surface of the femur, the medial femoral epicondyle, and the medial collateral ligament of the femorotibial joint. The obturator nerve passes through the cranial part of the obturator foramen and external obturator muscle and branches to supply the external obturator, adductor, pectineus, and gracilis muscles (Figure 1.45).

### Cranial Aspect

The quadriceps femoris, articularis coxae, and sartorius muscles lie in the cranial part of the thigh and hip. In addition, the iliacus muscle crosses the cranial aspect of the hip where the muscle encloses the psoas major, creating the conjoined iliopsoas muscle. Their common tendon inserts on the lesser trochanter. The psoas major arises from the last two ribs and the lumbar transverse processes; the iliacus comes from the wing of the sacrum, ventral sacroiliac ligaments, sacropelvic surface of the ilium, and tendon of the psoas minor muscle.

Three heads of the quadriceps femoris muscles (the vastus lateralis, vastus intermedius, and vastus medialis) take origin from the shaft of the femur. The fourth head, the rectus femoris, originates from two tendons, one arising from a medial depression on the ilium craniodorsal to the acetabulum, and one from a lateral depression (Figure 1.44). All four heads of the quadriceps femoris attach to the patella.

### Caudal Aspect

The main muscle mass is that of the semimembranosus with the semitendinosus, with the caudal division of the biceps femoris related to it laterally and the gracilis medially. The long head of the semimembranosus attaches to the caudal border of the sacrotuberous ligament. The thicker short head attaches to the ventral part of the ischiatic tuber. The thick, roughly three-sided belly of the semimembranosus ends on a flat tendon that attaches to the medial femoral epicondyle.

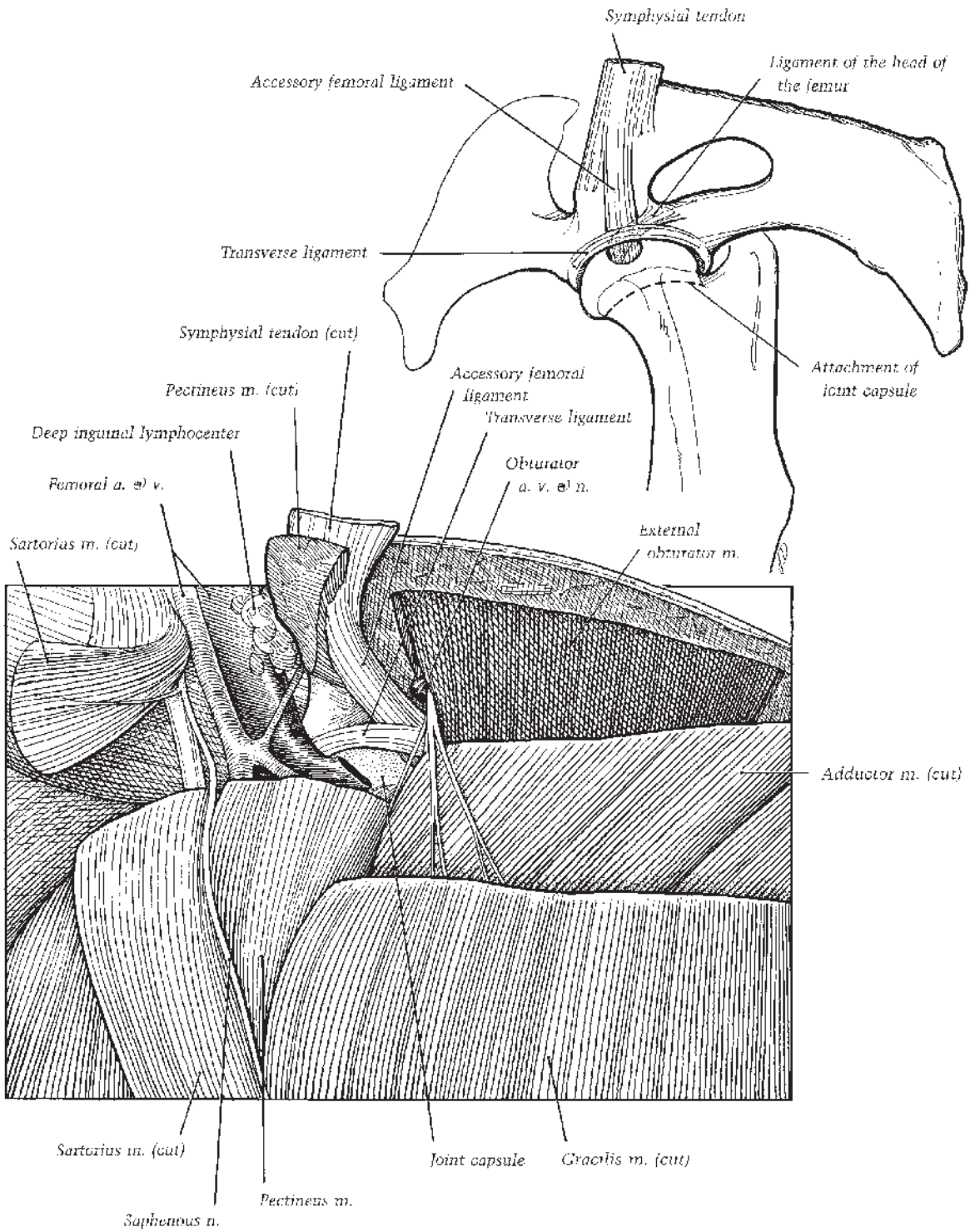
The neurovascular supply to the thigh region is illustrated in Figures 1.40, 1.41, 1.44.

### Hip (Coxofemoral) Joint

The acetabulum of the os coxae is formed where the ilium, ischium, and pubis meet. The lunate surface of the acetabulum, a cup-shaped cavity arcing around a deep nonarticular fossa, articulates with the head of the femur. A fibrocartilaginous rim, the acetabular labrum, increases the articular surface of the acetabulum. The transverse acetabular ligament bridges the labrum across the medially located acetabular notch, binding two ligaments as they emerge from the fovea capitis of the femoral head (Figure 1.45). The shorter ligament of the head of the femur comes from the narrow apex of the fovea and attaches in the pubic groove. The thick accessory femoral ligament arises from the wider, peripheral part of the fovea and passes out through the acetabular notch to lie in the pubic groove. After giving partial origin to the gracilis and pectineus muscles, the accessory femoral ligament blends into the prepubic tendon.

The capacious joint capsule of the hip attaches to the acetabular labrum and on the neck of the femur a few millimeters from the margin of the femoral head (Figure 1.45). Within the joint the synovial membrane wraps around the ligaments. An outpocketing of the synovial membrane passes out through the acetabular notch to lie between the accessory femoral ligament and the pubic groove. A small pouch also lies under the ligament of the head of the femur. The articularis coxae muscle is related to the lateral aspect of the hip joint, detaching some fibers to the joint capsule. During flexion of the hip joint, the articularis coxae can serve to tense the joint capsule.

While the hip joint is a ball-and-socket joint, capable only of very limited rotation, its principal movements are flexion and extension. Abduction of the thigh is restricted by the



**Figure 1.45.** Deep dissection of the right hip, ventromedial view.

ligament of the head of the femur and the accessory femoral ligament. Adduction is checked by the attachments of the gluteal muscles on the femur. In the normal standing position, the caudolateral part of the head of the femur lies outside the acetabulum. The hip joint is slightly flexed in this position, the cranial angle being around 115°.

## Pelvis

The equine pelvis, like that of other animals, comprises the ilium, ischium, and pubis; these bones are individually identifiable in the young but have fused by 10 to 12 months of age.

The wing-shaped ilium presents two prominences, visible landmarks on the horse. The dorsally directed tuber sacrale inclines medially toward its fellow, so that the two sacral tubers come within 2 to 3 cm over the first sacral spinous process. The ilial wing projects ventrolaterad in a bulky tuber coxae, creating the point of the hip.

Caudally, the ischial tuberosity presents as a laterally directed ridge to which muscles of the thigh attach. The acetabulum is formed through contributions from all three bones of the pelvis.

The pubis and ischium from each side meet ventrally at the symphysis pelvis. In the young animal fibrocartilage joins the bones. Later in life, a synostosis is formed as the cartilage ossifies in a cranial to caudal sequence.

## Stay Apparatus of the Pelvic Limb

The quadriceps femoris muscle and the tensor fasciae latae act to pull the patella, parapatellar cartilage, and medial patellar ligament proximad to the locked position over the medial trochlear ridge of the femur when the limb is positioned to bear weight at rest (Figure 1.46). Through the components of the reciprocal apparatus (cranially, the fibularis tertius from the femur to the lateral tarsus and proximal metatarsus and, caudally, the superficial digital flexor from the femur to the calcaneal tuber) the tarsus is correspondingly locked in extension. A small amount muscular activity in the quadriceps muscle assures continuation of this locked configuration, preventing flexion of the stifle and tarsocrural joints. Distal to the hock the digital flexor tendons support the plantar pes, the SDFT extending distad from its connection to the calcaneal tuber and the DDFT usually receiving the accessory (tarsal check) ligament from the thick plantar part of the tarsal fibrous joint capsule. Prevention

of overextension of the fetlock joint during the fixed, resting position is accomplished through the support rendered by the digital flexor tendons and the suspensory apparatus (suspensory ligament, proximal sesamoid bones, and their ligaments).

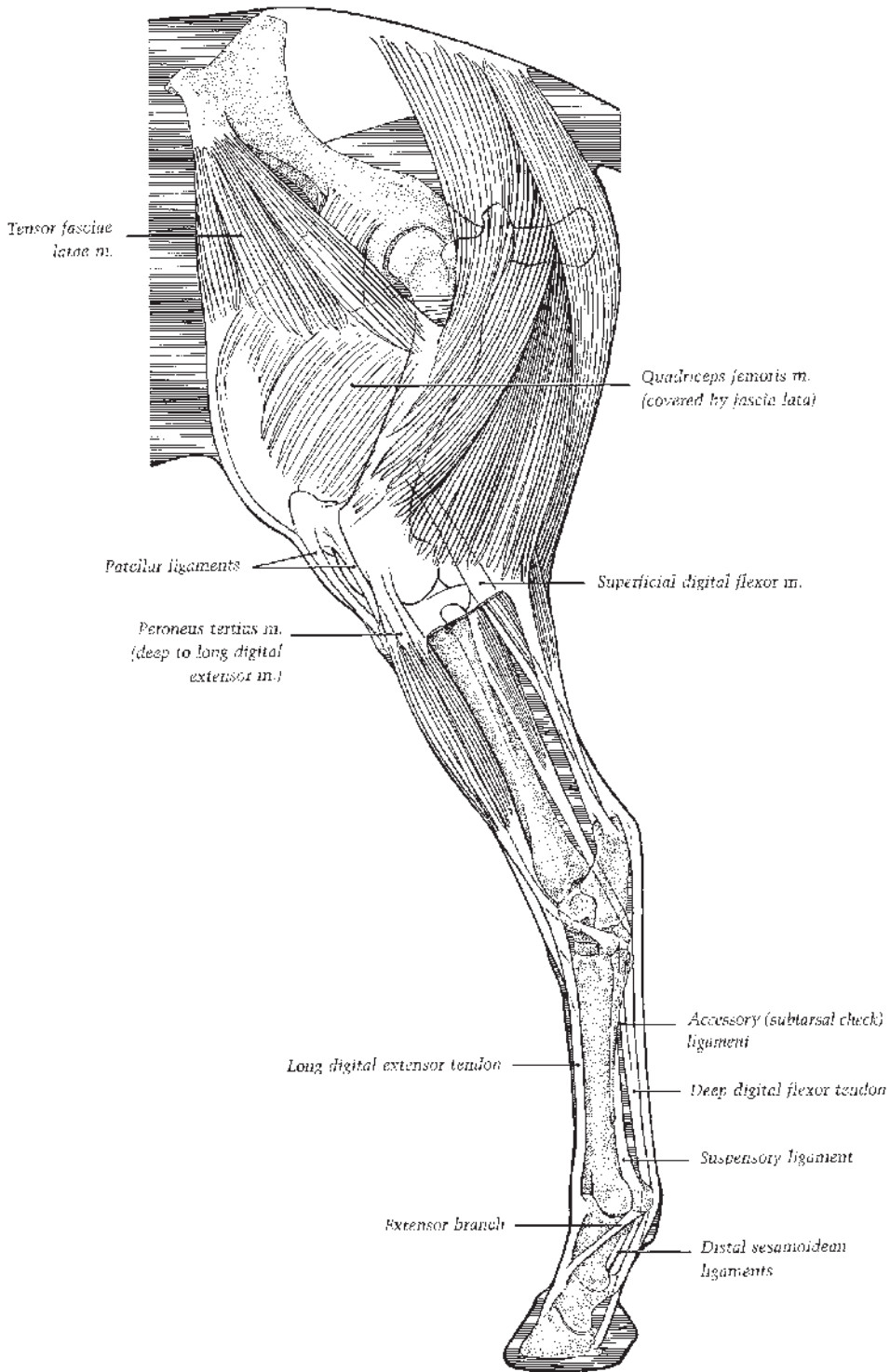
## AXIAL COMPONENTS

### Vertebral Column

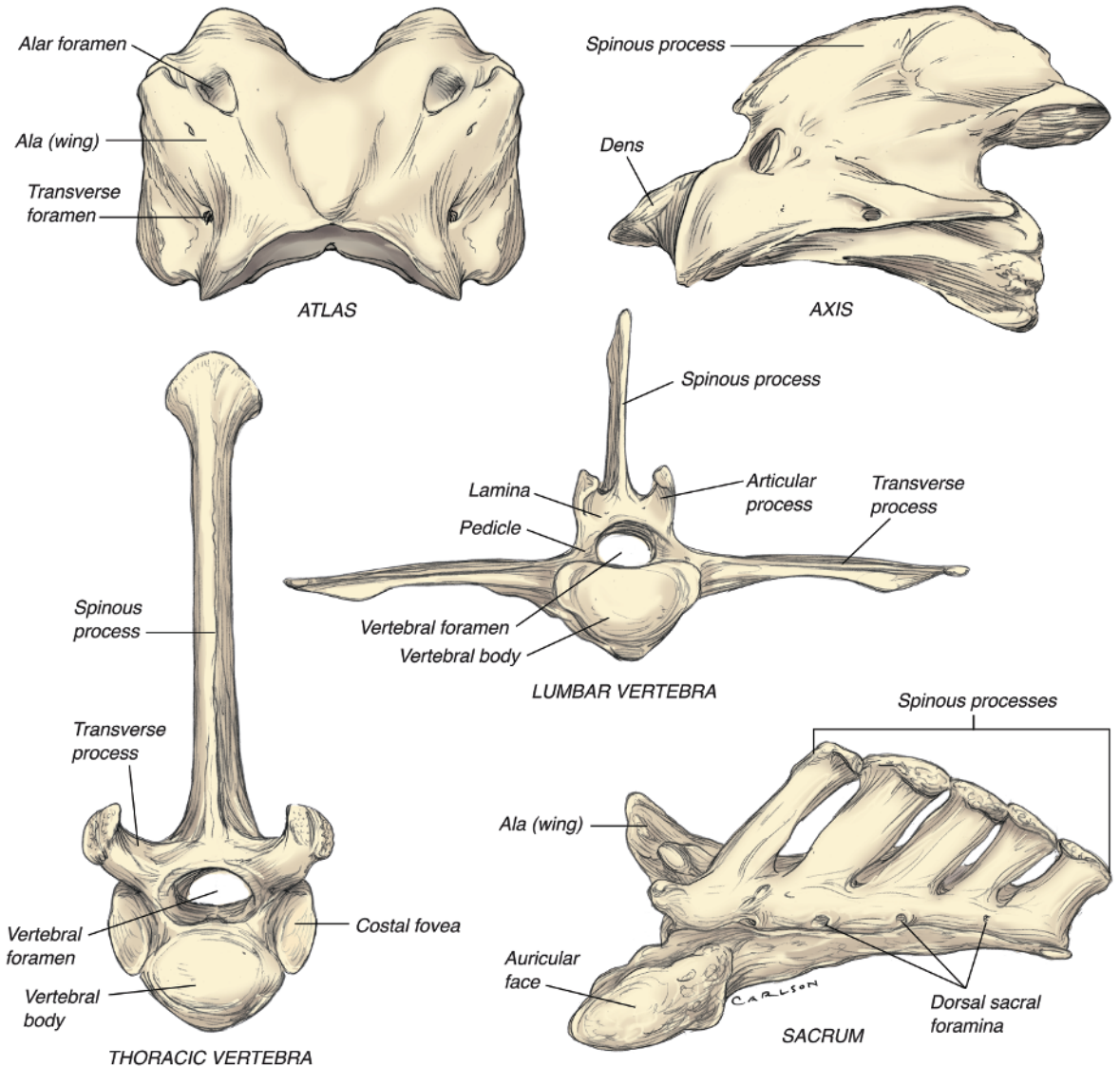
The vertebral formula of the horse is 7 cervical, 18 thoracic, 6 lumbar, 5 sacral, and an inconsistent number of caudal vertebrae (ranging from 15 to 21). There is some individual variation in numbers of other vertebrae, most commonly in the number of lumbar vertebrae, where 5 or 7 are sometimes seen (there is an increased incidence of 5 lumbar vertebrae in Arabian horses). The typical vertebra possesses a ventrally placed, roughly cylindrical body whose cranial and caudal ends articulate with adjacent vertebrae at the intervertebral disc (Figure 1.47). A bony vertebral arch attaches to the body and surrounds the spinal cord. The aperture created within a given vertebrae by the dorsal aspect of the body and the medial and ventral parts of the arch is the vertebral foramen; where vertebral foramina of adjacent vertebrae are aligned to admit the spinal cord, the resulting passageway is called the vertebral canal. The vertebral canal is widest in the caudal cervical-cranial thoracic region, where it accommodates the cervical enlargement of the spinal cord; a second dilation of the canal occurs in the lumbar region where the lumbosacral enlargement of the cord resides.

The vertebral arch comprises the pedicles and laminae, which together create the “roof” over the spinal cord. The pedicles are the vertical bony attachments to the vertebral body. The dorsal part of the arch is created by the right and left laminae. The pedicles are characterized by vertebral notches, indentations on the cranial and caudal aspects of the pedicle. When individual vertebrae are articulated, the cranial vertebral notch of one vertebra abuts the caudal vertebral notch of another, creating an intervertebral foramen through which the spinal nerve emerges from the vertebral canal.

The vertebral arch features other bony processes that bear synovial joints between adjacent vertebrae and which serve as sites of attachment for epaxial muscles. Each vertebra has a single dorsal midline spinous process and two transverse processes that arise near the point at which the pedicle attaches to the body. The dorsal



**Figure 1.46.** Stay apparatus of the pelvic limb.



**Figure 1.47.** Vertebrae.

contour of the equine thorax and loin is largely determined by the relative size and prominence of the spinous processes of thoracic and lumbar vertebrae. Arising adjacent to the spinous process are a pair of cranial articular processes and a pair of caudal articular processes.

**Cervical Vertebrae**

The first two cervical vertebrae are highly modified to meet their specialized function in permitting movement of the head. The first ver-

tebra is the atlas. It lacks the cylindrical body characteristic of other vertebrae, instead taking the form of a bony ring comprising dorsal and ventral arches. The spinous process is likewise absent. The transverse processes are modified into the wings of the atlas. These are robust, bent in a ventrolateral direction, and strongly concave ventrally. Their craniolateral edges form a prominent palpable ridge caudal to the ramus of the mandible. The dorsal aspect of the wing of the atlas bears three foramina: the transverse foramen, the alar foramen, and the lateral verte-



bral foramen. The cranial aspect of the atlas possesses two deeply concave cranial articular foveae which form a synovial joint (the atlanto-occipital joint) with the occipital condyles. The caudal articular foveae are also concave and participate in the synovial atlantoaxial joint.

The second cervical vertebra is the axis. The body of the axis is long; its cranial extremity is modified into a scoop-like projection called the dens, which features a rounded ventral articular surface that articulates with the floor of the atlas. The caudal extremity of the axis' body is deeply concave where it articulates with the body of the third cervical vertebra. The spinous process of the axis is tall and long, modified into a thick midline sail. The transverse processes are small and caudally directed.

The third through seventh vertebrae are similar to one another and follow the basic pattern of most vertebrae. They are progressively shorter from cranial to caudal. Cervical vertebrae three, four, and five bear a distinct ventral crest on their bodies. This crest is diminished in size on the sixth and absent from the seventh cervical vertebra. Articular processes on these cervical vertebrae are large, with prominent oval fovea for articulation between vertebral arches. Transverse processes are broad, each with two thick tubercles for muscular attachment. The spinous process of the seventh cervical vertebra is tall compared to other cervical vertebrae.

### Thoracic Vertebrae

There are usually 18 thoracic vertebrae in the horse, although there may on occasion be one more or one less than typical. The bodies of the thoracic vertebrae tend to be short with a small vertebral arch dorsally. The spinous processes are relatively tall, with the first four or five increasing in height and more caudal spinous processes gradually decreasing in height until at the level of the twelfth thoracic vertebra, after which they are the same height as those of the lumbar vertebrae.

The tall spinous processes of those first twelve vertebrae constitute the withers. The dorsal apex of the spines is somewhat expanded and in young horses surmounted by cartilage. The cartilage is replaced by bone as the horse ages, with the cartilages associated with the prominence of the withers persisting the longest at ten years or more. The anticlinal vertebra is defined as the one whose spinous process is perpendicular to the long axis of the vertebral column; the spinous processes of more cranial vertebrae incline

caudad, while those of more caudal vertebrae incline craniad. In the horse, the anticlinal vertebra is usually the 16th, and occasionally the 14th.

The vertebral bodies possess cranial and caudal costal foveae for articulation with the heads of ribs, except for the last thoracic vertebra which features only cranial costal foveae. Transverse processes are irregular, largest in the cranial thoracic vertebrae, and gradually decreasing in size toward the lumbar region.

### Lumbar Vertebrae

There are usually six lumbar vertebrae, although five and seven also have been reported. The cylindrical bodies of the lumbar vertebrae are somewhat flattened dorsoventrally, especially the last three; except for the seventh and sometimes the sixth lumbar vertebrae, a ventral crest is prominent. The spinous processes project slightly craniad. The vertebral arches tend to overlap dorsally, except at the L5-L6 and L6-S1 interspaces, where the larger interarcuate spaces are much larger and clinically accessible. The cranial and caudal articular processes articulate in an approximation of the sagittal plane, an orientation which allows for a very slight degree of flexion and extension of the vertebral column but prevents lateral flexion. The transverse processes of the lumbar vertebrae are large and blade-like. They project laterad. The caudal aspect of the fifth transverse process articulates with the cranial aspect of the sixth. The caudal aspect of the sixth transverse process features a large concave facet through which it articulates with the sacrum.

### Sacrum

The equine sacrum is a single bone formed through fusion of embryologically distinct sacral vertebrae, generally five of these, with four, six, and seven sacral vertebrae also being reported. Fusion is usually complete by five years of age. The sacrum is triangular and gently curving so as to present a slightly concave ventral aspect. Intervertebral foramina are transformed by the fusion of adjacent vertebrae into a row of four dorsal sacral foramina and four ventral sacral foramina, through which pass dorsal and ventral branches, respectively, of the sacral spinal nerves. The spinous processes remain individually distinct and incline slightly caudad, and the second through fifth end in slight enlargements that are not uncommonly bifid.

The first sacral vertebra gives rise to the wings of the sacrum. Their articular surfaces face dorsolateral to articulate with the auricular surface of the ilium. The ventral aspect of the first sacral vertebra is slightly rounded, forming the promontory of the sacrum, the point from which the conjugate diameter of the pelvis is measured.

### Caudal Vertebrae

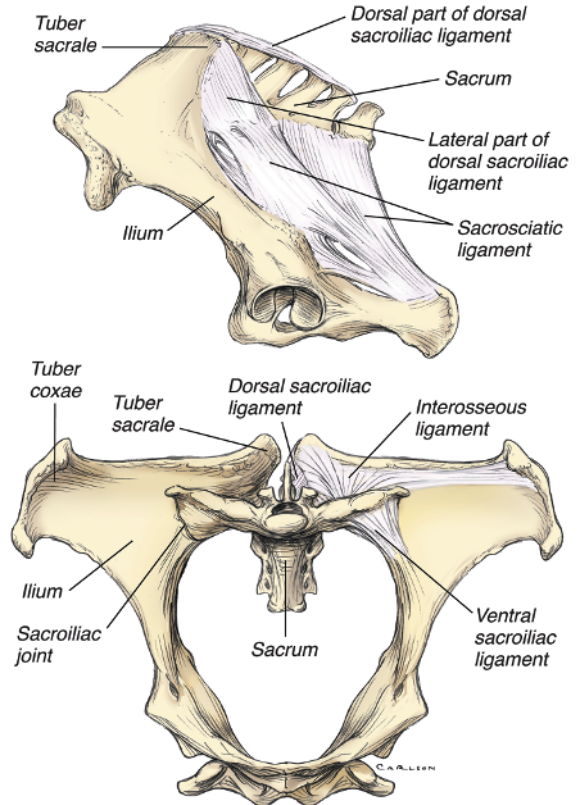
Although there is considerable individual variation, the average horse has 18 caudal vertebrae. Only the first three or so have vertebral arches, the remaining being represented by cylindrical bodies only. The first caudal vertebra is not uncommonly fused with the sacrum, especially in old horses.

### Vertebral Articulations

Excluding the atlantoaxial joint (a pivot joint), the joints of the vertebral column all permit flexion, extension, lateral flexion, and limited rotation. These movements are fairly limited through the thoracic and lumbar regions, but the cervical vertebral column is capable of extensive movement. Intervertebral discs of fibrocartilage are interposed between adjacent vertebral bodies. Further stabilization is provided to the vertebral column by (1) the continuous dorsal and ventral longitudinal ligaments on their respective surfaces of the vertebral bodies; (2) a supraspinous ligament that passes along the dorsal aspect of the spinous processes of the thoracic, lumbar, and sacral vertebrae; and (3) interspinous ligaments that pass between adjacent spinous processes. In the thoracic region, intercapital ligaments pass transversely between the heads of contralateral ribs over the dorsal aspects of the intervertebral disks. Articulations between articular processes on vertebral arches are true synovial joints. In the cervical region, these constitute broad plates, oriented in a nearly horizontal plane so as to permit significant lateral bending. Articular facets on the cranial articular processes face dorsomedial, whereas the complementary facets on the caudal articular processes face ventrolateral. True joints also exist between the transverse processes of the fifth and sixth lumbar vertebrae and between the transverse processes of the sixth lumbar vertebra and the wings of the sacrum.

### Sacroiliac Region

The axial skeleton and appendicular skeleton of the hindlimb are united at the sacroiliac joint



**Figure 1.48.** Sacroiliac joint, lateral (top) and cranial (bottom) views.

(Figure 1.48). This planar joint is created by the auricular face of the wings of the sacrum, which face dorsolaterad, and the auricular face of the wings of the ilia, which face ventromedial. This joint is histologically synovial, but is capable of only extremely limited gliding movement; its principle purpose is most likely absorption of concussive forces transmitted through the appendicular skeleton to the vertebral column. The joint capsule is close-fitting and is substantially reinforced by a series of sacroiliac ligaments that contribute markedly to the overall stability of the joint and probably act to transfer most of the weight of the trunk to the pelvic limbs. These ligaments can be summarized as comprising the ventral sacroiliac ligament, the dorsal sacroiliac ligament, and the interosseous ligament.

The ventral sacroiliac ligament surrounds the joint and fills the space between the ilium and the wing of the sacrum. The dorsal sacroiliac ligament presents two distinct portions. One arises from the tuber sacrale and inserts on the spinous processes of the sacral vertebrae. The

other, a more laterally placed sheet, arises from the tuber sacrale and the caudal edge of the ilial wing and inserts along the lateral aspect of the sacrum. From here it blends ventrad into the broad sacrosciatic ligament that fills the space between the pelvis and sacrum. The interosseous ligament consists of strong, vertically oriented fibers between the ventral part of the wing of the ilium and the dorsal aspect of the wing of the sacrum.

### Ligamentum Nuchae

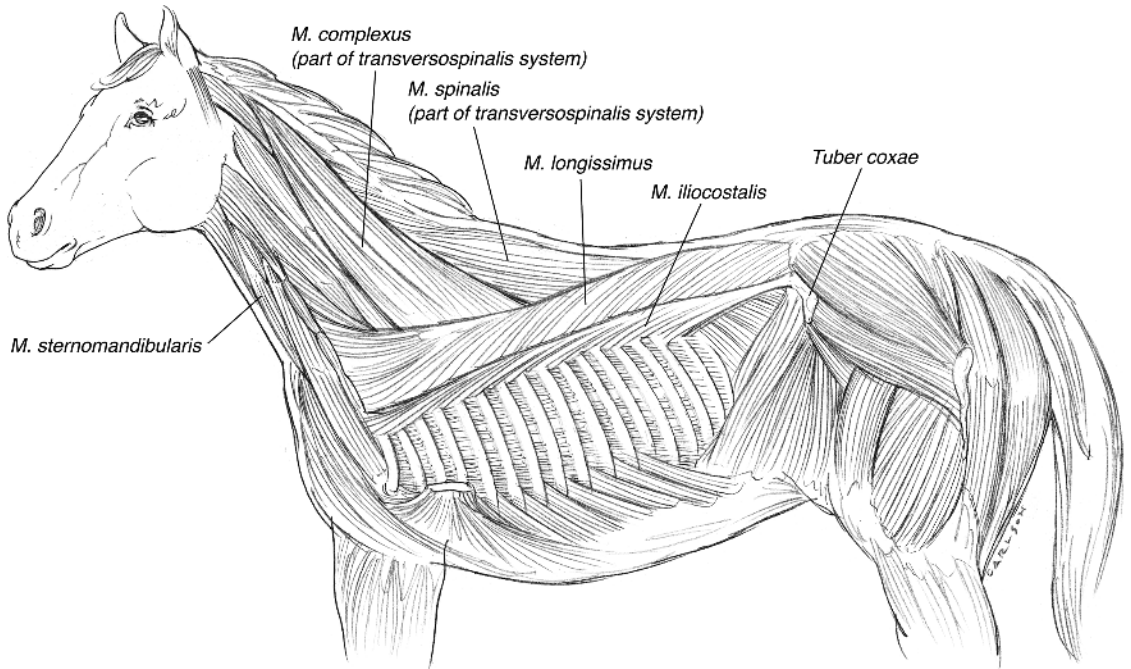
The topline of the neck is in part determined by the presence of the ligamentum nuchae (nuchal ligament), which in horses extends from its cranial attachments on the external occipital protuberance to the spinous process of the third or fourth thoracic vertebra. Both parts of the nuchal ligament (funicular and laminar) are paired. The rope-like funicular part is connected to sheets which comprise the laminar portions. These midline elastic sheets arise from the second through seventh cervical vertebrae and insert on the spines of the second and third thoracic vertebrae. Bursae are consistently found between the funicular part of the nuchal ligament and the atlas (bursa subligamentosa nuchalis cranialis)

and between the nuchal ligament and the second thoracic spine (bursa subligamentosa suprascapularis). A third bursa (bursa subligamentosa nuchalis caudalis) is inconsistently found between the nuchal ligament and the spine of the axis.

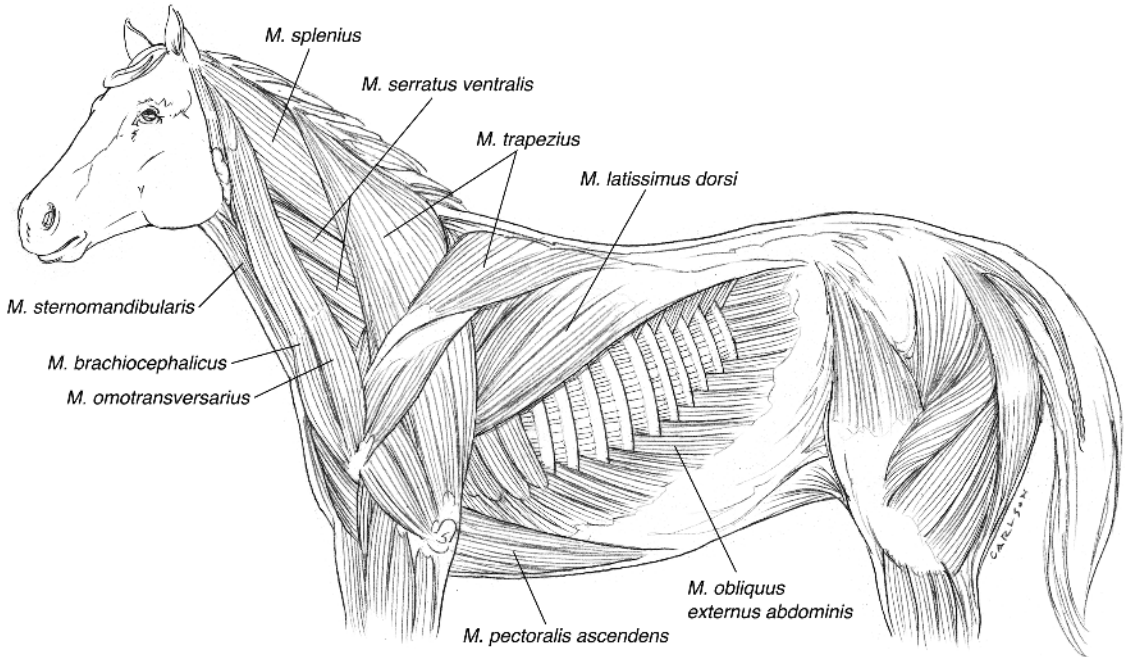
### Muscles of the Trunk and Neck

Muscles of the torso (neck, trunk, and tail) are roughly divided into those dorsal to the transverse processes (i.e., epaxial muscles) and those ventral to the transverse processes (i.e., hypaxial muscles). The epaxial muscles are innervated by dorsal branches of the spinal nerves, while hypaxial muscles receive their innervation from ventral branches.

The epaxial muscles are extensors of the vertebral column and are roughly divided into three parallel bundles of fascicles: from lateral to medial these are the iliocostalis system, the longissimus system, and the transversospinalis system (Figure 1.49). The iliocostalis system (named for its attachments to the ilium and ribs) does not extend into the neck; the others continue into the cervical region and are associated with additional distinct muscles. Of these, the splenius muscle is most superficial (Figure 1.50). The splenius possesses capital and cervical parts.



**Figure 1.49.** Deep muscles of the trunk.



**Figure 1.50.** Superficial muscles of the trunk. The cutaneous muscles have been removed.

Both arise from the third, fourth, and fifth thoracic spines and from the funicular part of the nuchal ligament, and they insert on the nuchal crest of the skull, the wing of the atlas, and the transverse processes of the third, fourth, and fifth cervical vertebrae. The splenius extends the neck and elevates the head, and it is largely the rhythmic contraction of this powerful muscle that creates the thrusting movements of the neck during the gallop.

The longissimus group is described as having lumbar, thoracic, cervical, atlantal, and capital portions. It is most robust in the lumbar region, where it gives a well-conditioned horse's back its typical rounded appearance.

Hypaxial muscles of the trunk (the psoas minor, quadratus lumborum, and the four abdominal muscles on each side) act to flex the vertebral column during the gallop. Epaxial muscles extend the vertebral column. When they contract unilaterally, both hypaxial and epaxial muscles create lateral movement of the trunk and neck.

In the ventral neck, the equine longus colli muscle is particularly well developed relative to other domestic species. The cervical portion of this muscle arises from the transverse processes and bodies of the third through sixth cervical

vertebrae in paired bundles that converge to an insertion on the preceding vertebral bodies, sometimes bridging more than one intervertebral space. The most cranial attachment is on the ventral aspect of the atlas. The thoracic portion of the longus colli arises on the lateral vertebral bodies of thoracic vertebrae one through six, passing cranial to insert on the transverse processes of cervical vertebrae six and seven.

The omohyoideus muscle is well-developed in the horse. It arises from an aponeurosis in the fascia near the shoulder joint; its muscle belly is closely attached to the deep side of the brachiocephalicus until the neck's midpoint, where the omohyoideus becomes evident as a distinct muscle as it passes cranial deep to the sternoccephalicus muscle. The right and left sternomandibularis muscles of the horse are fused on midline near their origin on the manubrium. Near mid-neck, the two halves separate, moving from their position ventral to the trachea to a more lateral location. As the muscle approaches its insertion on the sternomandibular tuberosity on the ramus of the mandible, it narrows to a distinct tendon that is visible in the cranial neck just caudal to the caudal border of the mandible. The tendon of insertion is classically considered one side of Viborg's triangle.

## Bibliography

1. Banks WJ: 1993. *Applied Veterinary Histology, 3rd ed.* St. Louis, MO, Mosby-Yearbook, Inc.
2. Bertram JEA, Gosline JM: 1987. Functional design of horse hoof keratin: The modulation of mechanical properties through hydration effects. *J Exper Biol* 130:121.
3. Bowker RM, Linder K, Van Wulfen KK, et al.: 1997. An anatomical study of the distal interphalangeal joint in the horse: Its relationship to the navicular suspensory ligaments, sensory nerves and neurovascular bundle. *Eq Vet J* 29:126.
4. Bowker RM, Rockershouser SJ, Vex KB, et al.: 1993. Immunocytochemical and dye distribution studies of nerves potentially desensitized by injections into the distal interphalangeal joint or navicular bursa of horses. *J Am Vet Med Assoc* 203:1708.
5. Bowker RM, Van Wulfen KK: 1996. Microanatomy of the intersection of the distal sesamoidean impar ligament and the deep digital flexor tendon: A preliminary report. *Pferdheilkunde* 12:623.
6. Denoix JM: 1994. Functional anatomy of tendons and ligaments in the distal limbs (manus and pes). *Vet Clinics of North Am* 10:273.
7. Dyce KM, Sack WO, Wensing CJG: 2002. *Textbook of Veterinary Anatomy.* Philadelphia, Elsevier Science.
8. Garret PD: 1990. Anatomy of the dorsoscapular ligament of horses. *J Am Vet Med Assoc* 196:446.
9. Getty R: 1975. *Sisson and Grossman's The Anatomy of the Domestic Animals, 5th ed. Vol 1.* Philadelphia, WB Saunders Co.
10. James PT, Kemler AG, Smallwood JE: 1983. The arterial supply to the distal sesamoid bones of the equine thoracic and pelvic limbs. *J Vert Orthoped* 2:38.
11. Landeau LJ, Barnett DJ, Batterman SC: 1983. Mechanical properties of equine hooves. *Am J Vet Res* 44:100.
12. Leach DH, Oliphant LW: 1983. Ultrastructure of equine hoof wall secondary epidermal lamellae. *Am J Vet Res* 44:1561.
13. Mishra PC, Leach DH: 1983. Extrinsic and intrinsic veins of the equine hoof wall. *J Anat* 136:543.
14. Nickel R, Schummer A, Seiferle E, et al.: 1986. The locomotor system of the domestic mammals. *In: The Anatomy of the Domestic Animals.* New York, Springer-Verlag.
15. Nomina Anatomica Veterinaria: World Association of Vet Anatomists. 5th ed. 2005.
16. Ottaway CA, Worden AN.: 1940. Bursae and tendon sheaths of the horse. *Vet Rec* 52:477.
17. Reeves MJ, Trotter GW, Kainer RA: 1991. Anatomical and functional communications between synovial sacs of the equine stifle joint. *Eq Vet J* 23:215.
18. Rooney JR, Quddus MA, Kingsbury HB: 1978. A laboratory investigation of the function of the stay apparatus of the equine foreleg. *J Em Med Surg* 2:173.
19. Sack WO: 1976. Subtendinous bursa on the medial aspect of the equine carpus. *J Am Vet Med Assoc* 165:315.
20. Sack WO: 1975. Nerve distribution in the metacarpus and front digit of the horse. *J Am Vet Med Assoc* 167: 298.
21. Sack WO, Habel RE: 1977. *Rooney's Guide to the Dissection of the Horse.* Ithaca, NY, Veterinary Textbooks.
22. Sack WO, Orsini PG: 1981. Distal intertarsal and tarsometatarsal joints in the horse: Communication and injection sites. *J Am Vet Med Assoc* 179:3555.
23. Schummer A, Wilkens H, Vollmerhaus B, et al.: 1981. *Schummer and Seiferle's The Anatomy of the Domestic Animals. Vol 3.* New York, Heidelberg, Berlin, Springer-Verlag.
24. Schuurman SO, Kersten W, Weijs WA: 2003. The equine hind limb is actively stabilized during standing. *J Anat* 202:355.
25. Southwood LL, Stashak TS, Kainer RA: 1997. Tenoscopic anatomy of the equine carpal flexor synovial sheath. *Vet Surg* 27:150.
26. Stecher RM: 1962. Anatomical variations of the spine in the horse. *J Mam* 43:205.
27. Stump JE: 1967. Anatomy of the normal equine foot, including microscopic features of the laminar region. *J Am Vet Med Assoc* 151:1588.
28. Talukdar AJ, Calhoun ML, Stinson AW: 1970. Sweat glands of the horse: A histologic study. *Am J Vet Res* 31:2179.
29. Updike SJ: 1984. Functional anatomy of the equine tarsocrural collateral ligaments. *Am J Vet Res* 45:867.
30. Weaver JC, Stover SM, O'Brien TR: 1992. Radiographic anatomy of soft tissue attachments in the equine metacarpophalangeal and proximal phalangeal region. *Equine Vet J* 24:310.
31. Wilson DA, Baker GJ, Pijanowski GJ, et al.: 1991. Composition and morphologic features of the interosseous muscle in Standardbreds and Thoroughbreds. *Am J Vet Res* 52:133.

