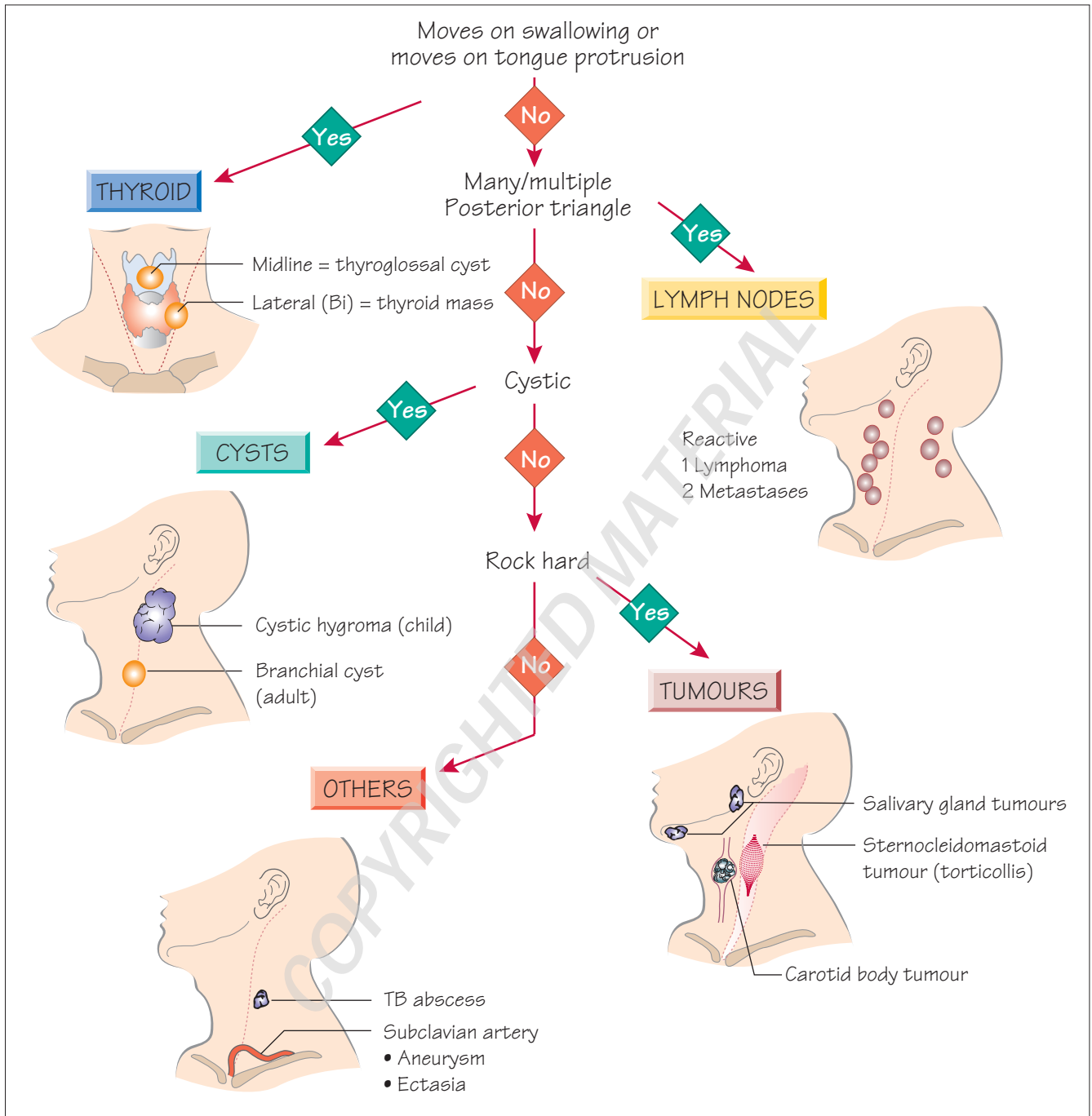


1 Neck lump



Definition

A *neck lump* is any congenital or acquired mass arising in the anterior or posterior triangles of the neck between the clavicles inferiorly and the mandible and base of the skull superiorly.

Key points

- Thyroid swellings move upwards (with the trachea) on swallowing.
- Most abnormalities of the neck are visible as swellings.
- Ventral lumps attached to the hyoid bone, such as thyroglossal cysts, move upwards with both swallowing and protrusion of the tongue.
- Multiple lumps are almost always lymph nodes.
- In all cases of lymphadenopathy a full head and neck examination, including the oral cavity is mandatory.

Differential diagnosis

- 50% of neck lumps are thyroid in origin.
- 40% of neck lumps are caused by malignancy (80% metastatic usually from primary lesion above the clavicle; 20% primary neoplasms: lymphomas, salivary gland tumours).
- 10% of neck lumps are inflammatory or congenital in origin.

Thyroid

- Goitre, cyst, neoplasm.

Neoplasm

- Metastatic carcinoma.
- Primary lymphoma.
- Salivary gland tumour.
- Sternocleidomastoid tumour.
- Carotid body tumour (rare).

Inflammatory

- Acute infective adenopathy.
- Collar stud abscess.
- Parotitis.

Congenital

- Thyroglossal duct cyst.
- Dermoid cyst.
- Torticollis.
- Branchial cyst.
- Cystic hygroma.

Vascular

- Subclavian or brachiocephalic ectasia (common).
- Subclavian aneurysm (rare).

Important diagnostic features

Children

- Congenital and inflammatory lesions are common.
- Cystic hygroma: in infants, base of the neck, brilliant transillumination, 'come and go'.

- Thyroglossal or dermoid cyst: midline, discrete, elevates with tongue protrusion.
- Torticollis: rock hard mass, more prominent with head flexed, associated with fixed rotation (a fibrous mass in the sternocleidomastoid muscle).
- Branchial cyst (also fistulae or sinus): anterior to the upper third of the sternocleidomastoid.
- Viral/bacterial adenitis: usually affects jugular nodes, multiple, tender masses.
- Neoplasms are unusual in children (lymphoma most common).

Young adults

Inflammatory neck masses and thyroid malignancy are common.

- Viral (e.g. infectious mononucleosis) or bacterial (tonsillitis/pharyngitis) adenitis.
- Papillary thyroid cancer: isolated, non-tender, thyroid mass, possible lymphadenopathy.

Over-40s

Neck lumps are malignant until proven otherwise.

- Metastatic lymphadenopathy: multiple, rock hard, non-tender, tendency to be fixed.
- 75% in primary head and neck (thyroid, nasopharynx, tonsils, larynx, pharynx), 25% from infraclavicular primary (stomach, pancreas, lung).
- Primary lymphadenopathy (thyroid, lymphoma): fleshy, matted, rubbery, large size.
- Primary neoplasm (thyroid, salivary tumour): firm, non-tender, fixed to tissue of origin.

Key investigations

