

1 • What is an ECG?

An **electrocardiograph** (ECG), in its simplest form, is a voltmeter (or galvanometer) that records the changing electrical activity in the heart by means of positive (+ve) and negative (–ve) electrodes (Fig. 1.1). **Electrocardiography** is the process of recording these changing potential differences.

A +ve and a –ve electrode can be placed almost anywhere on, or in, the body to record electrical changes. One of the most common and simplest methods is to place these electrodes on the limbs of animals – referred to as a **body surface limb ECG recording**. However, if monitoring an ECG during anaesthesia or echocardiography, for example, it is sufficient to place the –ve electrode anywhere cranial to the heart (e.g. the forelimb or neck) and the +ve electrode caudal to the heart (e.g. the hind limb, abdomen or flank). Electrodes can also be placed on the chest (precordial chest ECG recording – commonly used in humans) or inside the cardiac chambers (used in electrophysiological studies). This book focuses on the conventional limb ECG recording, which is the method most commonly used in veterinary medicine for clinical diagnosis of arrhythmias.

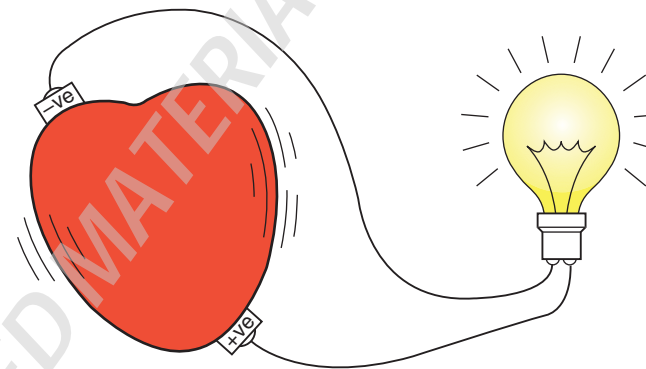


Figure 1.1 An ECG records the 'electricity of the heart'.