

About X-rays

What are X-rays?

X-rays are a form of **ionising radiation**. They are part of the electromagnetic spectrum and have sufficient energy to cause ionisations. They contain more energy than ultraviolet (UV) waves but less energy than gamma rays.

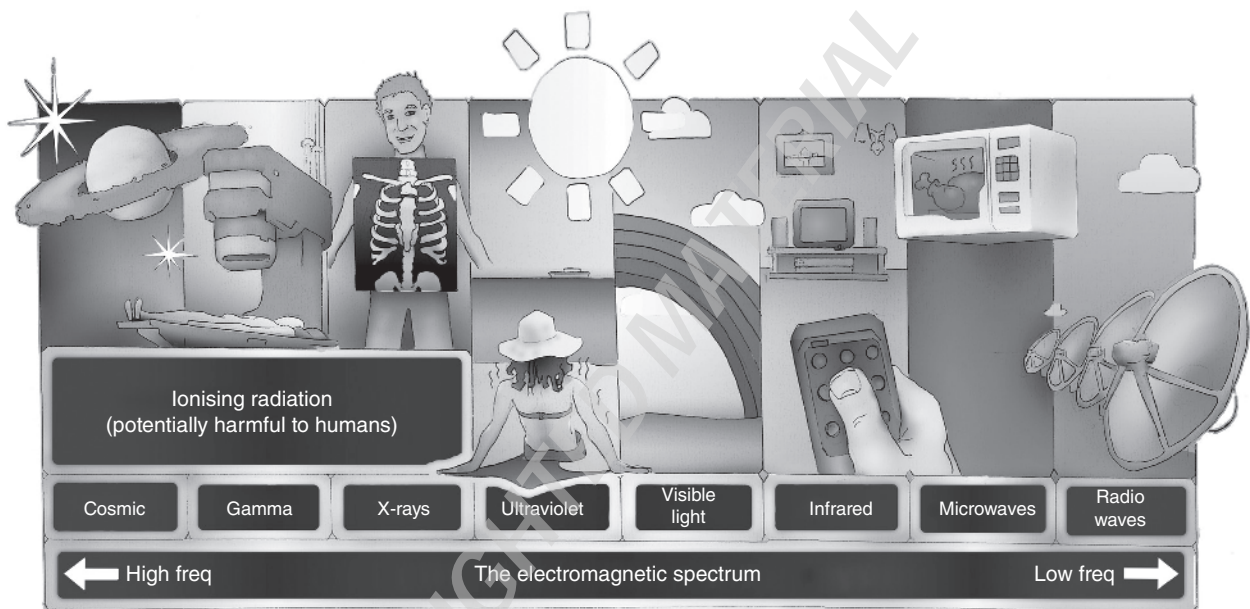


Figure 1: The electromagnetic spectrum (Freq is short for frequency).

Radiation is the transfer of energy in the form of particles or waves.

Ionising radiation is the radiation with sufficient energy to cause ionisations, which is a process whereby radiation removes an outer shell electron from an atom. Thus ionising radiation is able to cause changes on a molecular level in biologically important molecules (e.g. DNA).

Uses of ionising radiation include conventional X-rays (plain radiographs), contrast studies, computed tomography (CT), nuclear medicine and positron emission tomography (PET).

How are X-rays produced?

X-rays are produced by focusing a high-energy beam of electrons onto a metal target (e.g. tungsten). The electrons hit the metal target and some will have enough energy to knock out another electron from the inner shell of one of the metal atoms. As a result, electrons from higher energy levels then fill up this vacancy and

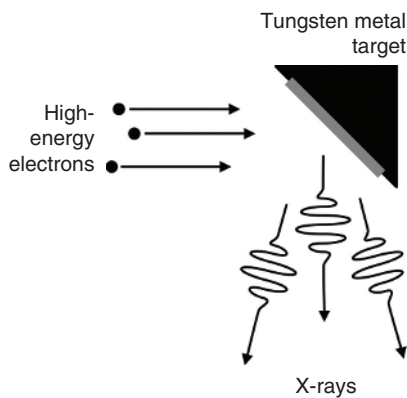


Figure 2: X-ray production.

X-rays are emitted in the process. Producing X-rays this way is extremely inefficient (~0.1%), so most of the energy is wasted as heat. This is why X-ray tubes need to have advanced cooling mechanisms. The X-rays produced then pass through the patient and onto a detector mechanism which produces an image.

How do X-rays make an image?

Main points include the following:

1. The resulting image on the X-ray detector is a **two-dimensional (2D) representation of a three-dimensional (3D) structure**.
2. While passing through a patient the X-ray beam is absorbed in proportion to the cube of the atomic number of the various tissues through which it passes. By convention, the greater the amount of radiation hitting a detector, the darker the image will be. Therefore, the less "dense" a material is, the more X-rays get through and the darker the image. Conversely the more "dense" a material is, the more X-rays are absorbed and the image appears whiter. Materials of low "density" appear darker than those of high "density".
3. **Structures can only be seen if there is sufficient contrast with surrounding tissues** (contrast is the difference in absorption between one tissue and another).

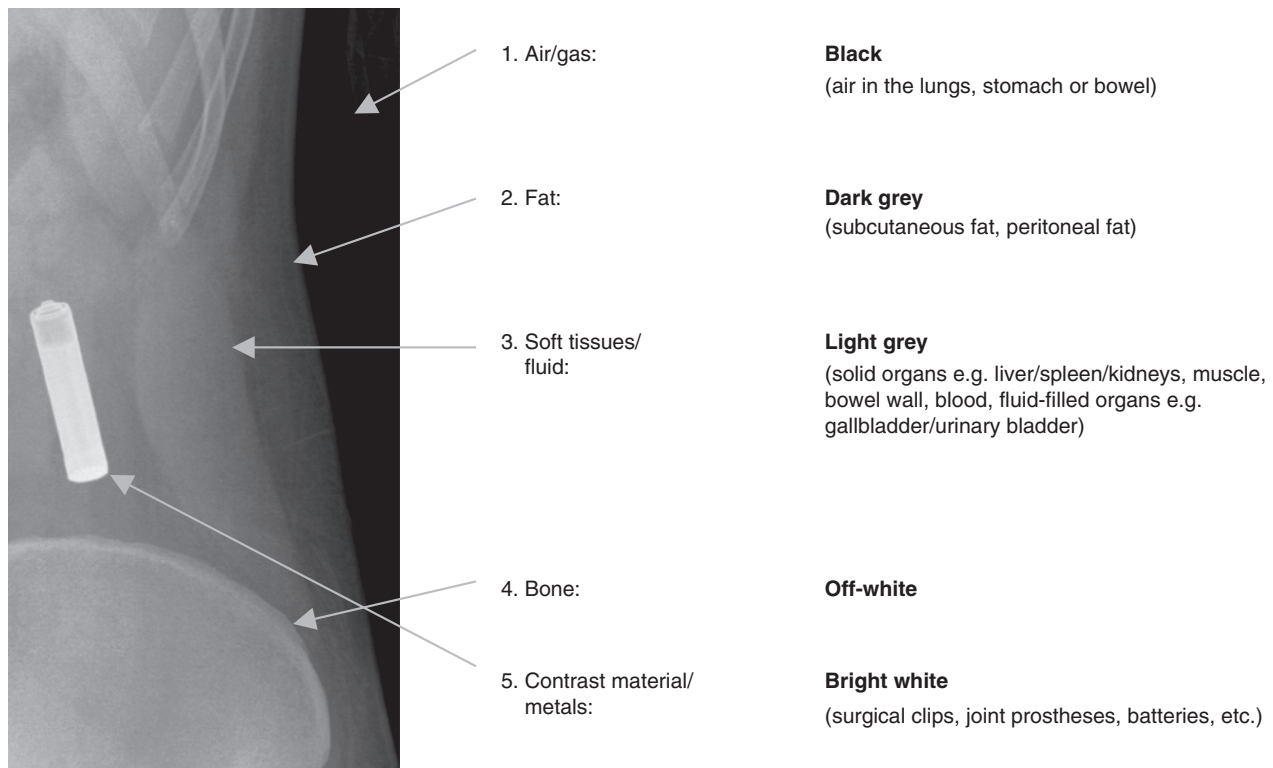


Figure 3: The spectrum of tissues of different densities as seen on a conventional radiograph. The radiograph example shows the left lumbar region of a patient who swallowed a battery.

How are X-ray images (radiographs) stored?

In some hospitals radiographs are printed onto X-ray film, but most places now use a computer-based digital radiograph storage system for storing X-ray images, thereby eliminating the need for film.

This system is known as **P**icture **A**rchiving and **C**ommunication **S**ystem (**PACS**). Doctors and other healthcare professionals are able to view the images (radiographs) on a computer screen, making it easy to manipulate the image (e.g. changing the contrast, zooming in/out, etc).

The advantages are ease of access, both locally and internationally, cost saving and no more lost films. The disadvantages are the initial cost and the risk of a system failure, which could be potentially catastrophic.

Radiation hazards

Radiation hazards occur as a result of damage to cells by radiation. Actively dividing cells are particularly sensitive (e.g. bone marrow, lymph glands and gonads). Damage takes many forms including cell death, mitotic inhibition and chromosome/genetic damage leading to mutations.

The radiation dose from an abdominal X-ray is approximately 30 times more than that of a chest X-ray and equivalent to 2 months of background radiation. It is therefore important to optimise the radiation dose to as low as reasonably achievable, while still obtaining an image of good diagnostic quality. The safety of patients and the use of ionising radiation for medical exposures are subject to specific legislation in the UK – the Ionising Radiation (Medical Exposure) Regulations or IRMER.

The Ionising Radiation (Medical Exposure) Regulations

Introduced in 2000, with a few subsequent amendments since, it lays down the basic measures for radiation protection for patients. It refers to three main people involved in protecting the patient:

1. The **Referrer** (a doctor or other accredited health professional [e.g. emergency nurse practitioner] requesting the exposure)
 - Must provide adequate and relevant clinical information to enable the practitioner to justify the exposure
2. The **Practitioner** (usually a radiologist, who justifies the exposure)
 - Decides on the appropriate imaging and justifies any exposure to radiation on a case-by-case basis.
 - **Potential benefit must outweigh the risk to the patient** (e.g. *a CT head scan on a 1-year-old adds a 1/500 lifetime risk of cancer and increases the risk of cataract formation. The benefit of this scan must therefore outweigh these risks to the child.*)
3. The **Operator** (usually a radiographer, who performs practical aspects)
 - Ensures that the above two stages have been completed appropriately
 - Keeps all justifiable exposure as low as reasonably possible by
 - i. minimising the number of X-ray radiographs taken
 - ii. focusing the X-ray beam to the area of interest
 - iii. keeping exposure as low as reasonably achievable

In women of reproductive age

- Minimise radiation exposure of abdomen and pelvis.
- Ask women of reproductive age if they could be pregnant, and avoid radiation exposure to them. The most critical periods are during the first and second trimester. From the standpoint of future development, the foetus is considered to be most radiosensitive during the second trimester when foetal organogenesis is taking place. X-rays of the abdomen and pelvis should be delayed, if possible, to a time when foetal sensitivity is reduced (i.e. post 24 weeks' gestation, or ideally until the baby is born).
- Exposure to remote areas (chest, skull and limbs) may be undertaken with minimal foetal exposure at any time during pregnancy.

Indications for an abdominal X-ray

Only request an abdominal X-ray if it is the most appropriate test to answer the clinical question. Indications for a plain abdominal X-ray are as follows:

- **Suspected bowel obstruction**
To look for dilated loops of small or large bowel or a dilated stomach.
- **Suspected perforation**
To look for evidence of pneumoperitoneum. An **erect chest X-ray** should always be requested at the same time to look for free gas under the diaphragm.
- **Moderate-to-severe undifferentiated abdominal pain**
May be useful if the provisional diagnosis includes any of the following: toxic megacolon, bowel obstruction and perforation.
- **Suspected foreign body**
To look for the presence of radiopaque foreign bodies.
- **Renal tract calculi follow-up**
To look for the presence or movement of known renal tract calculi.

For most other clinical situations, an **abdominal X-ray is not recommended** as there is a more appropriate alternative test. Common examples include:

- *Abdominal trauma*: A CT scan of the abdomen and pelvis with intravenous contrast is much more sensitive and specific at looking for evidence of solid organ, bowel or bony injury and may identify the site of significant active bleeding.
- *Right upper quadrant abdominal pain*: An ultrasound scan of the abdomen is recommended to look for evidence of gallstones, inflamed gallbladder or an obstructed common bile duct.
- *Suspected intra-abdominal collection*: A CT scan of the abdomen and pelvis is recommended to look for a source of infection (collection of pus or fluid).
- *Acute upper gastrointestinal bleeding*: Endoscopy is indicated and enables diagnosis in most cases and can be used to deliver haemostatic therapy. If initial endoscopy is negative, then angiography or CT angiography may be useful to identify the source of the bleeding.
- *Suspected intra-abdominal malignancy*: A CT scan of the abdomen and pelvis is recommended to look for a malignancy and can be used to help stage the malignancy if found.
- *Constipation*: This is usually a clinical diagnosis without the need for any imaging tests. There is no evidence correlating abdominal X-ray findings with constipation. The only exception is in elderly patients where an abdominal X-ray may be useful to show the extent of faecal impaction, but does not diagnose constipation.

Abdominal X-ray views

The standard view is an **anterior–posterior (AP) supine abdominal X-ray (AXR)**. Almost all AXRs are taken AP supine. In general, you should assume that an abdominal radiograph is taken AP supine unless otherwise stated.

AP Supine abdominal X-ray

The patient lies supine (on their back). The X-ray tube is positioned overhead in front of the patient, so the X-rays pass in the AP direction. The patient is asked to hold their breath (so that breathing movement will not make the image blurry) and the X-ray is taken.

The abdominal radiographs are performed in the supine position as it is generally easier for patients to lie on their back, especially if they are unwell or post-operative.

The average detector used to image the abdomen is 35 × 43 cm, which is slightly smaller than the normal average adult abdomen. This means that two or more radiographs are sometimes needed to image the entire abdomen. It is therefore important to check whether a second radiograph has been taken before reporting an abdominal X-ray.

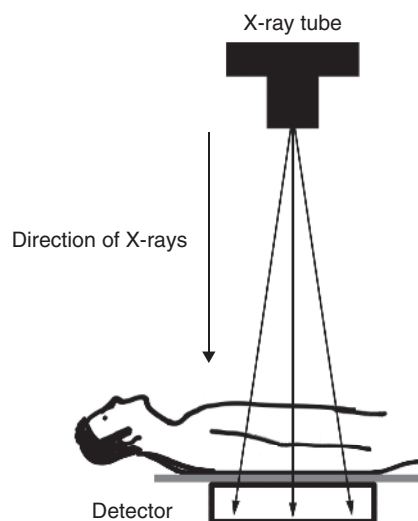


Figure 4: Anterior–posterior (AP) supine abdominal X-ray.

Other views

- **Erect AXR** (patient upright): It is very rarely performed nowadays as it has little diagnostic value when compared to a CT scan of the abdomen and pelvis. The erect AXR may demonstrate gas–fluid levels (gas rises, fluid sinks) and in the past was useful in suspected bowel obstruction.
- **Left lateral decubitus AXR** (patient lying on their left side): It is very rarely performed nowadays although is sometimes used in children to avoid high-dose CT when trying to diagnose suspected bowel perforation. The patient usually lies on their left side (as opposed to the right side) so any free intra-peritoneal gas is seen outlined against the liver edge (see Figure 28).
- **Erect chest X-ray:** It is very sensitive at identifying free sub-diaphragmatic gas (pneumoperitoneum) and has a much lower radiation dose than an abdominal radiograph. Erect chest X-ray should always be requested alongside a supine AXR in case of suspected perforation.

Radiograph quality

The quality of abdominal radiographs can vary widely. Before you think about the possible abnormalities on an abdominal radiograph, you must first assess the technical quality to ensure the image is adequate. The main questions to ask yourself are 'has everything been included on the radiograph?' and 'is the exposure adequate?'

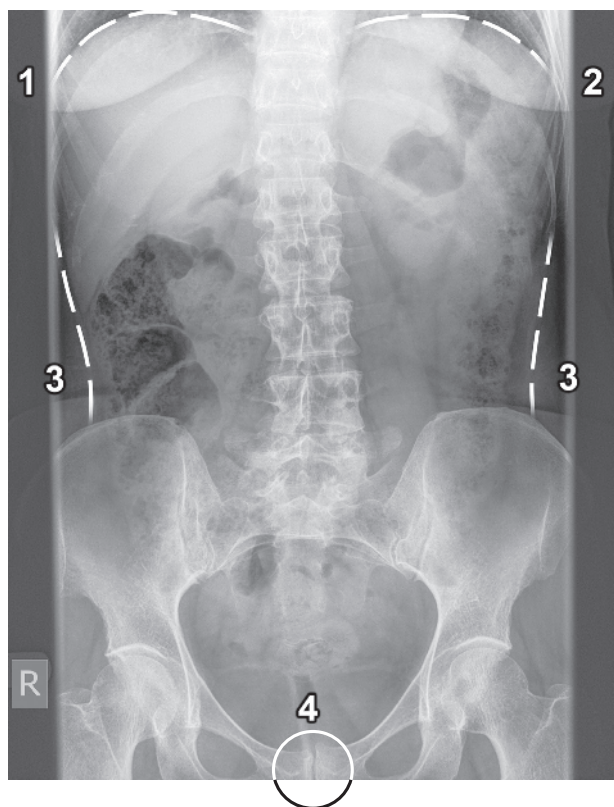


Figure 5: A normal abdominal radiograph showing the superior aspect of the liver (1), superior aspect of the spleen (2) and lateral abdominal walls (3) marked with dashed white lines. The pubic symphysis (4) is marked with a white circle (although ideally I would also like to see the inferior aspect of the pubic symphysis).

Inclusion

The entire anatomy should be included from the hemi-diaphragms to the symphysis pubis.

- The superior aspect of the liver (1) and spleen (2) should be included at the top of the radiograph.
- The lateral abdominal walls (3) should be seen on either side of the radiograph.
- The pubic symphysis (4) should be clearly visualised at the bottom of the radiograph.

Note: The average detector used to image the abdomen is slightly smaller than the average normal adult abdomen. Often two radiographs are needed to image the entire abdomen. In obese patients, sometimes the radiographs have to be used in the 'landscape' orientation rather than the traditional 'portrait' orientation to include everything.

Exposure

Exposure refers to the number of X-rays that reach the detector and make the image. An underexposed radiograph has not received enough X-rays and appears white/lighter. An overexposed radiograph has received too many X-rays and appears darker.

Exposure is less of a problem nowadays as inadequate images are usually terminated by the radiographer and repeated. Also, when viewing the radiograph, the contrast and brightness can be changed to compensate for poor exposure. However, under-exposure in obese patients can remain a problem and may limit the diagnostic value of the radiograph. To check the exposure is adequate, ensure the spine can be clearly visualised. Over-exposure is rarely an issue.

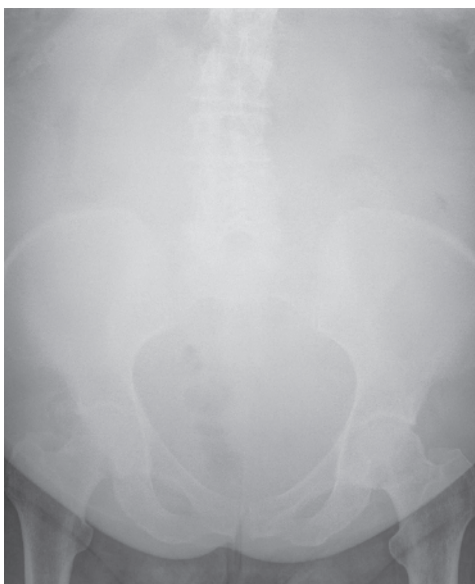
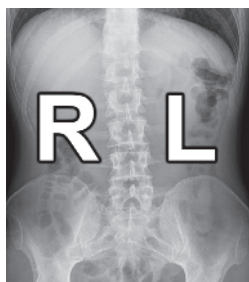
Figure 6: An underexposed abdominal radiograph demonstrating poor visualisation of the spine. It is more difficult to make out the bowel gas and the diagnostic value of this radiograph may be somewhat limited.

Normal anatomy on an abdominal X-ray

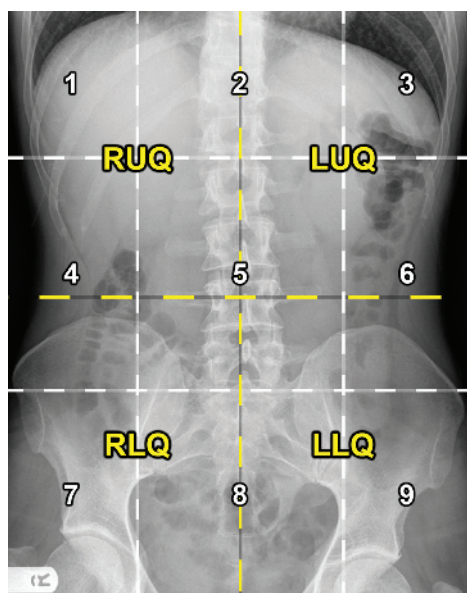
The following normal abdominal radiographs show the normal abdominal anatomy.



Right and left (Figure 7)

Remember, as you look at an abdominal radiograph the left side of the image is the patient's right side, and the right side of the image is the patient's left side. Always describe findings according to the patient's side.

Figure 7



Quadrants and regions (Figure 8)

The abdomen can be divided into four quadrants or nine regions.

The four quadrants (yellow dashed lines) are as follows:

Right upper quadrant (RUQ); left upper quadrant (LUQ); right lower quadrant (RLQ); left lower quadrant (LLQ).

The nine regions (white dashed lines) are as follows:

1. **Right hypochondriac**
2. **Epigastric**
3. **Left hypochondriac**
4. **Right lumbar**
5. **Umbilical**
6. **Left lumbar**
7. **Right iliac**
8. **Suprapubic**
9. **Left iliac**

Figure 8

Abdominal viscera 1 (Figure 9)

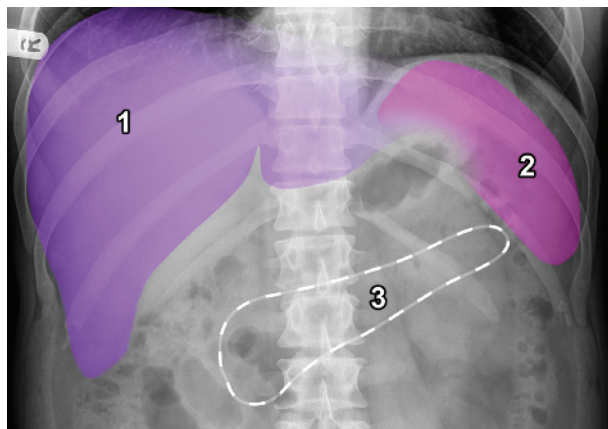
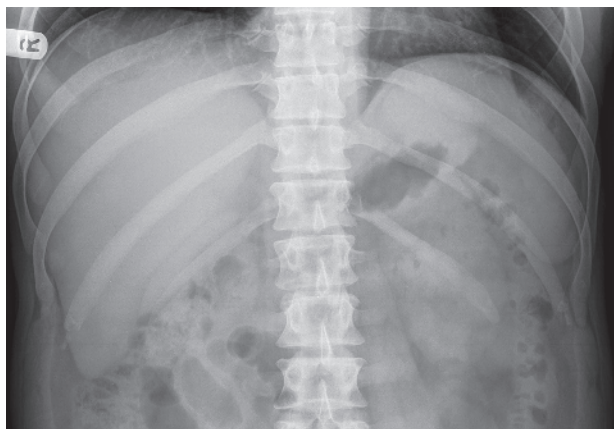


Figure 9

1. **Liver** (purple)
2. **Spleen** (pink)
3. **Location of the pancreas** (white outline) – not normally visualised

Abdominal viscera 2 (Figure 10)

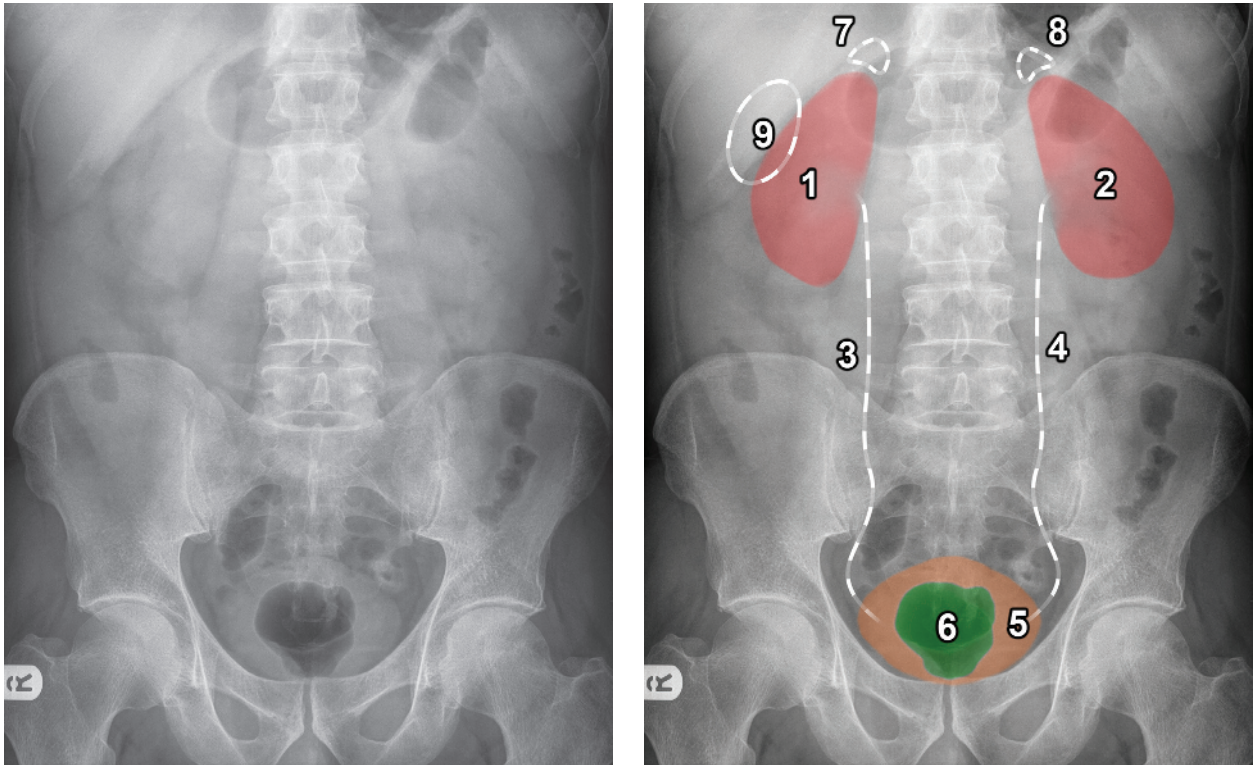


Figure 10

1. **Right kidney** (red)
2. **Left kidney** (red)
3. **Location of right ureter** (white outline) – not normally visualised
4. **Location of left ureter** (white outline) – not normally visualised
5. **Urinary bladder** (orange)
6. **Gas in the rectum** (green)
7. **Location of right adrenal gland** (white outline) – not normally visualised
8. **Location of left adrenal gland** (white outline) – not normally visualised
9. **Location of the gallbladder** (white outline) – not normally visualised

Note: The position of the gallbladder can be very variable. It can appear anywhere in the region of the right upper quadrant. The most common position (at the lower border of the liver) is shown in the earlier example.

Skeletal structures (Figure 11)

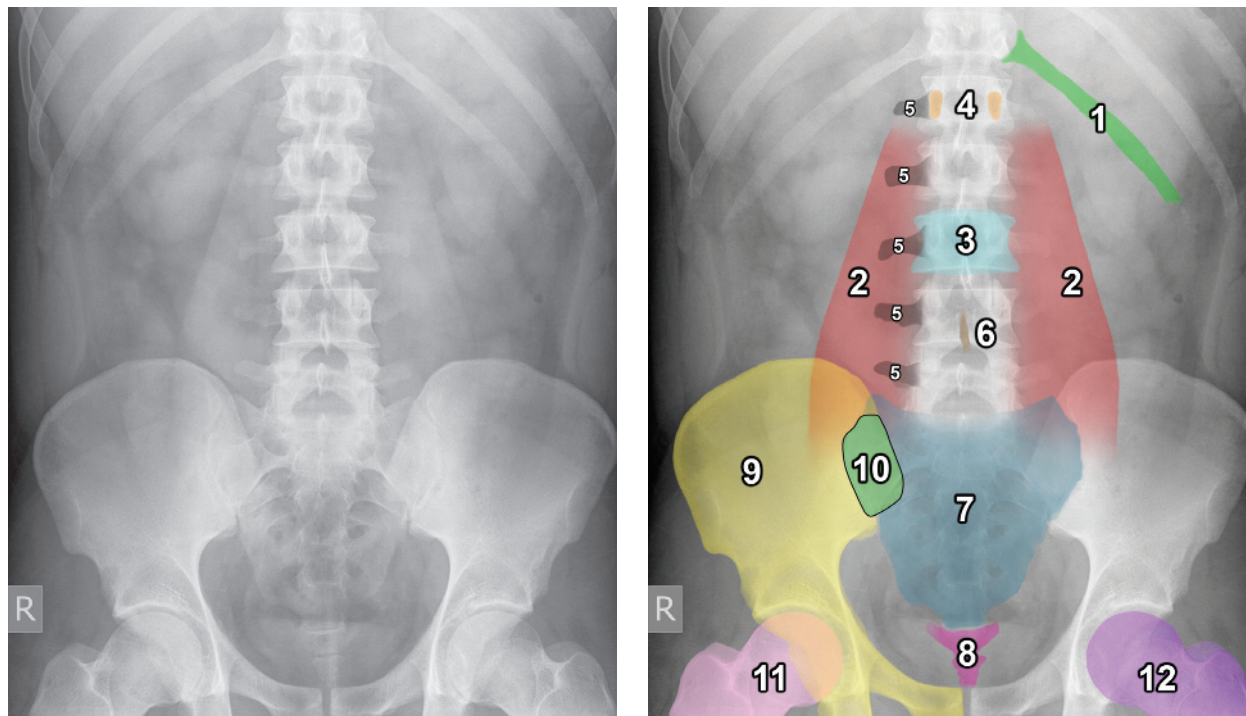


Figure 11

1. Left 12th rib (light green)
2. Psoas outline – left and right (red)
3. Vertebral body of L3 (light blue)
4. Pedicles of L1 vertebra (orange)
5. Right transverse processes of L1–L5 (black)
6. Spinous process of L4 (brown)
7. Sacrum (blue)

8. Coccyx (rose)
9. Right hemi-pelvis (yellow)
10. Right sacroiliac joint (green)
11. Right femur (pink)
12. Left femur (purple)

Pelvis (Figure 12)

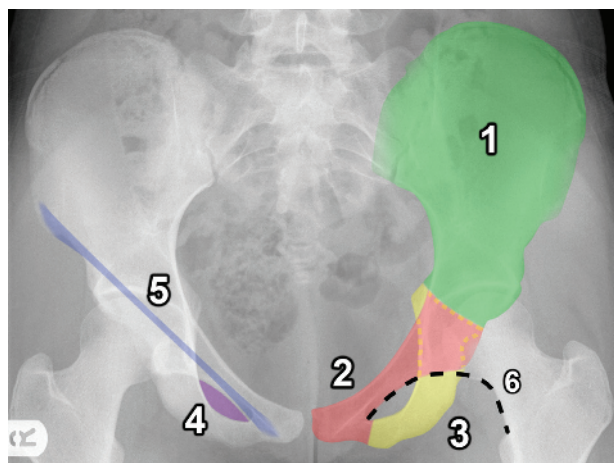


Figure 12

1. Ilium (green)
2. Pubis (red)
3. Ischium (yellow)
4. Obturator foramen (purple)
5. Location of right inguinal ligament (blue) – not normally visualised. The inguinal ligament runs between the anterior superior iliac spine and pubic tubercle
6. Shenton's line (black outline) – imaginary line along the inferior border of the superior pubic ramus and inferomedial border of the neck of femur

Lung bases (may be visualised at the top of the abdomen) (Figure 13)

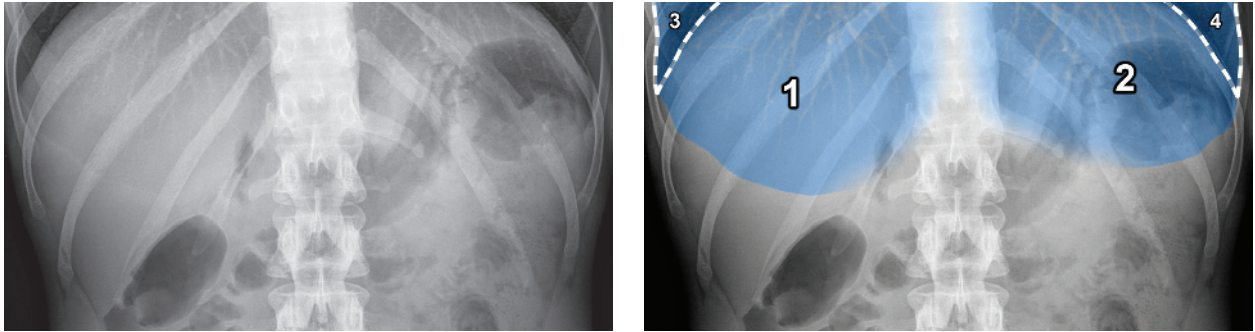


Figure 13

1. **Right lung base** (blue) – seen projected behind the liver
2. **Left lung base** (blue) – seen projected behind the stomach/spleen
3. **Right costophrenic angle** (white outline)
4. **Left costophrenic angle** (white outline)

Note: If you look carefully at the lung bases, you can often see the pulmonary vasculature as branching linear opacities (as seen in the earlier example).

Bowel 1 (Figure 14)

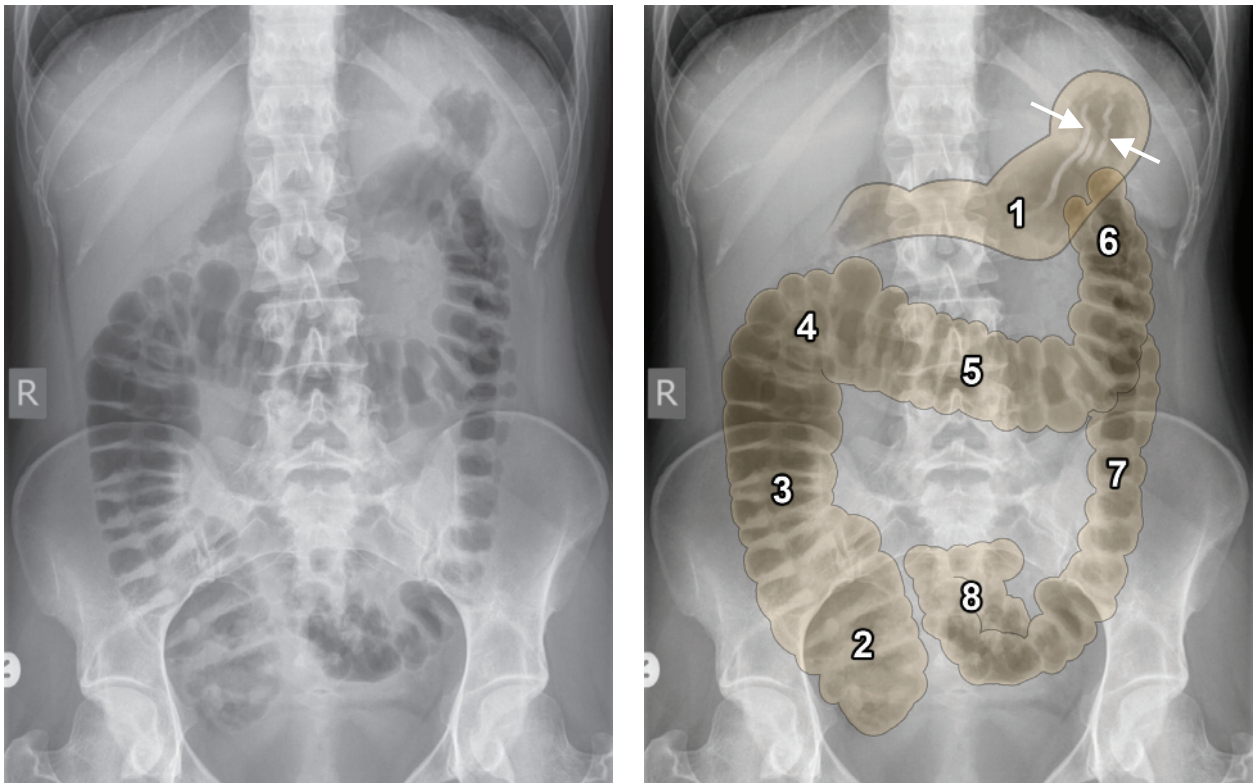


Figure 14

1. **Stomach** – note the stomach wall rugae (highlighted between the white arrows)
2. **Caecum**
3. **Ascending colon**
4. **Hepatic flexure**
5. **Transverse colon**
6. **Splenic flexure**
7. **Descending colon**
8. **Sigmoid colon**

Bowel 2 (Figure 15)

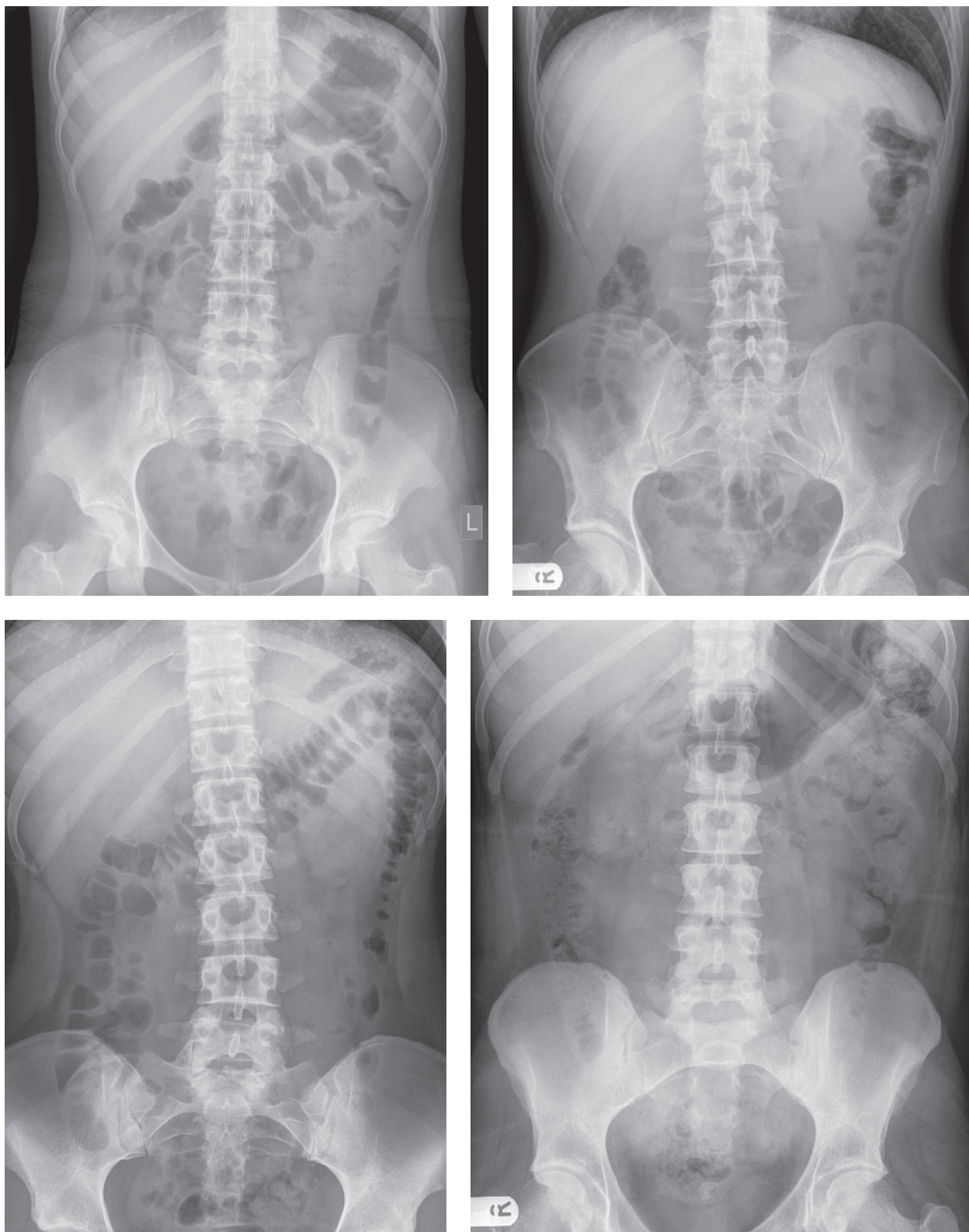


Figure 15

Four different normal abdominal radiographs showing examples of the normal variation in bowel gas pattern. Normally most of the bowel contains fluid/faeces (light grey) and therefore is not visualised on the radiograph. It is only the segments of bowel containing pockets of gas (black) that are visualised. The colon is more likely to contain gas than the small bowel and is therefore easier to visualise, as shown in the earlier examples.

The stomach is visible if it contains air; however, it may not be visible if it contains fluid or is empty. The small bowel air content is very variable depending on when the patient last ate, and can be pronounced when the patient is in pain due to air swallowing.

Presenting an abdominal radiograph

Be systematic!

You should present an abdominal radiograph in a systematic way to ensure you cover all areas and do not miss anything important. This is how you should present:

- | | | |
|---|---|---|
| <ol style="list-style-type: none">1. Give the type of radiograph.2. Give the patient's name.3. Give the date the radiograph was taken. | } | e.g. "This is an AP supine abdominal radiograph of John Smith, taken on the 1st of January, 2015." |
| <ol style="list-style-type: none">4. Briefly assess the radiograph quality (<i>see pages 6–7</i>) to ensure it is adequate.5. Run through the ABCDE of abdominal radiographs (<i>see page 15</i>).6. Give a short summary at the end. | | |

Always remember to describe what you are seeing. A good way to think about this is to **imagine you are describing the X-ray to a colleague over the phone**. If you see something, you must say **where it is anatomically** and **what it looks like**.

There are 16 examples of describing an abdominal radiograph on pages 94–106.