

1

Orbit

Please see Chapter 10 for more information about diseases, diagnostic testing, and treatment plans related to the orbit.

Figure 1.1 Orbital adenocarcinoma in a 14-year-old, castrated male Pomeranian. Left-sided abnormalities, which developed slowly, include exophthalmos, lateral and dorsal displacement of the eye, third eyelid elevation, and conjunctival vascular engorgement. Retropulsion of the left globe was reduced. Discussion of orbital neoplasia can be found on pages 67 and 68.

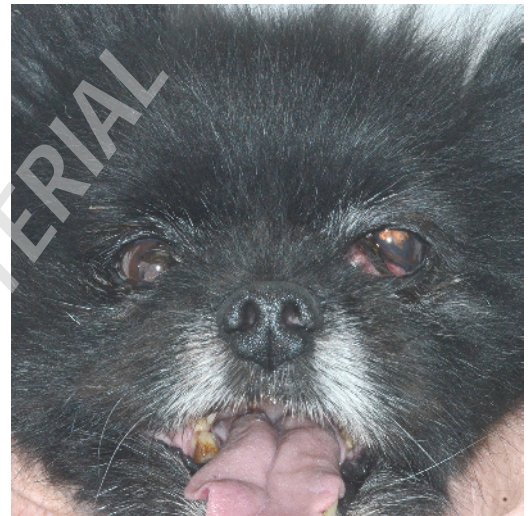


Figure 1.2 Orbital cellulitis in a 1-year-old, castrated male English springer spaniel. Left-sided abnormalities, which developed overnight, include exophthalmos, third eyelid elevation, chemosis and hyperemia of the conjunctiva overlying the third eyelid, and swelling of soft tissues around the left eye. This patient had stopped chewing on toys and had difficulty eating. *Enterococcus faecalis* was cultured from the left orbit. Clinical signs resolved with oral antibiotic therapy. Discussion of orbital cellulitis/abscess can be found on pages 65 to 67.

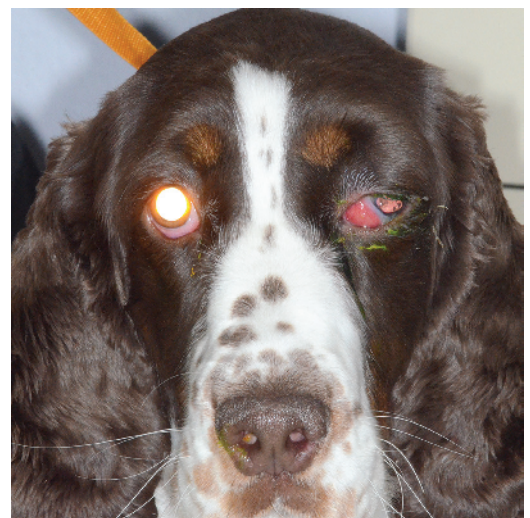

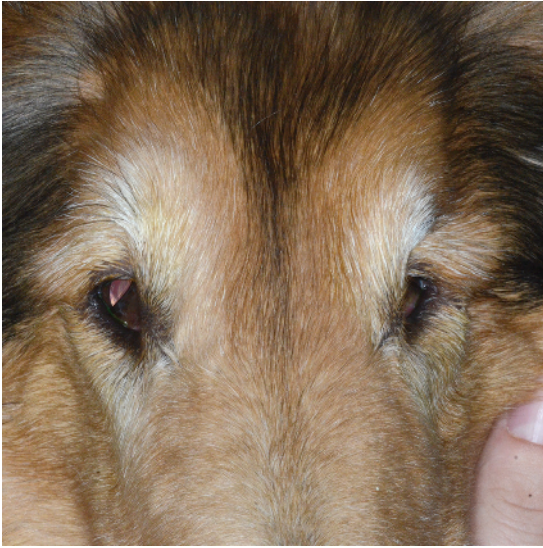


Figure 1.3 Bilateral enophthalmos, more pronounced in the left eye, in an elderly collie. Both third eyelids are raised secondary to enophthalmos, and the left third eyelid almost completely obscures the globe. This patient had a recent history of weight loss; therefore, the enophthalmos was presumed to be due to atrophy of the orbital fat pads. Discussion of orbital disease begins on page 61.



Figure 1.4 Brachycephalic ocular syndrome in a shih tzu. Note the excessive scleral show resulting from breed-related exophthalmos and enlarged palpebral fissures. Brachycephalic ocular syndrome is discussed on pages 62 and 63.

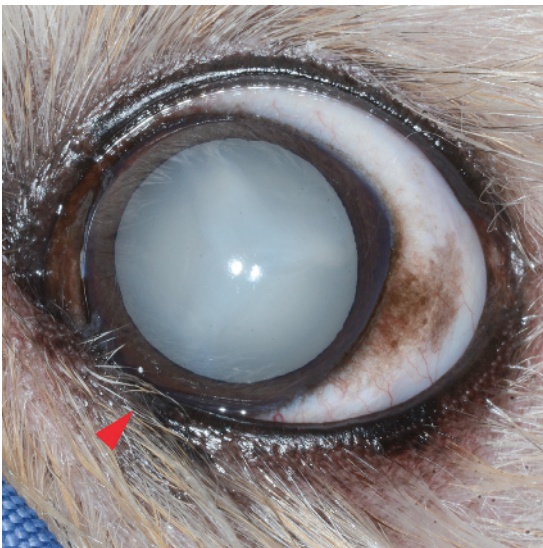


Figure 1.5 Left eye of a lhasa apso with brachycephalic ocular syndrome. Entropion affects the ventral eyelid between the medial canthus and the red arrowhead. Entropion is recognized by the inability to see the black eyelid margin medial to the red arrowhead (the margin is rolled under the haired skin.) Instead, haired eyelid skin contacts the globe. Note the excessive scleral show resulting from enlarged palpebral fissures. This dog also has a complete cataract. Brachycephalic ocular syndrome is discussed on pages 62 and 63.

Figure 1.6 Idiopathic, postganglionic Horner's syndrome. There is right-sided enophthalmos, miosis, third eyelid elevation, and ptosis. Horner's syndrome is discussed on pages 63 to 65.



Figure 1.7a Left-sided, idiopathic, postganglionic Horner's syndrome. Ptosis and third eyelid elevation completely obscure the eye. Horner's syndrome is discussed on pages 63 to 65.

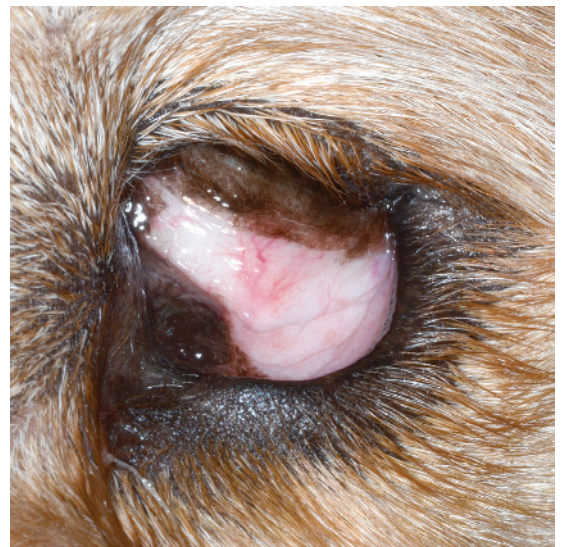
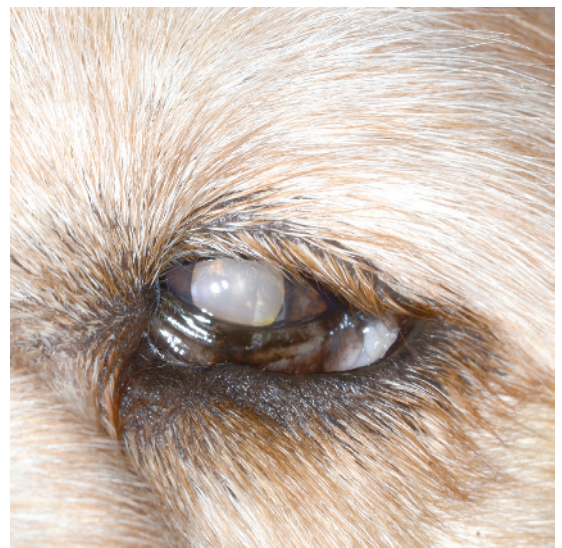
Figure 1.7b The same eye as in the previous figure, less than 20 minutes after instillation of phenylephrine into the conjunctival sac. Ptosis and third eyelid elevation are still present, but improved when compared with the previous figure. The speed of clinical improvement led to a diagnosis of postganglionic Horner's syndrome. Horner's syndrome is discussed on pages 63 to 65.



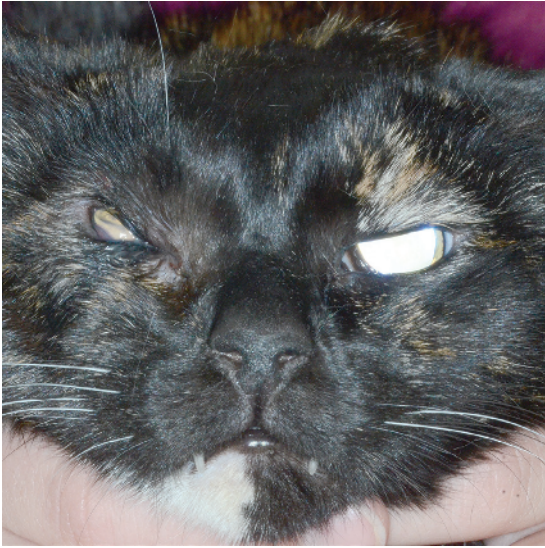

Figure 1.8 Orbital squamous cell carcinoma in a 12-year-old, spayed female DSH. The right eye is enophthalmic. The right palpebral fissure is distorted and the eyelids thickened and immobile. As a result of exposure, the cornea became ulcerated. Orbital neoplasia is discussed on pages 67 and 68.

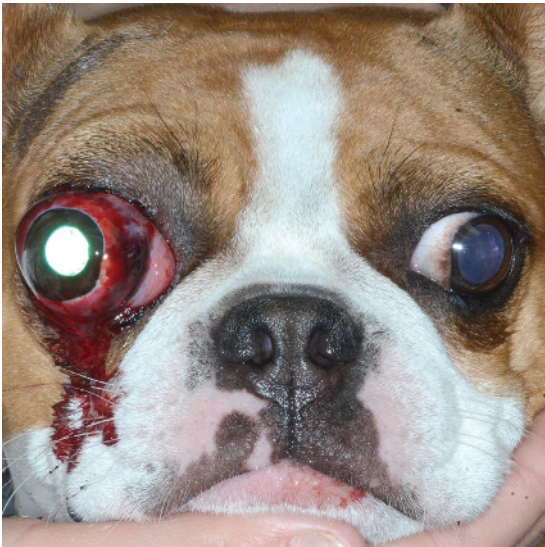

Figure 1.9 Proptosis in a 4-year-old, spayed female Boston terrier cross. The right eyelid margins are partially visible. Along with anterior displacement of the right eye, there is marked subconjunctival hemorrhage. The right pupil is miotic compared with the left pupil. Proptosis is discussed on pages 68 to 70.