

# 1

# Introduction to ECG monitoring

## Conduction system of the heart (figure 1.1)

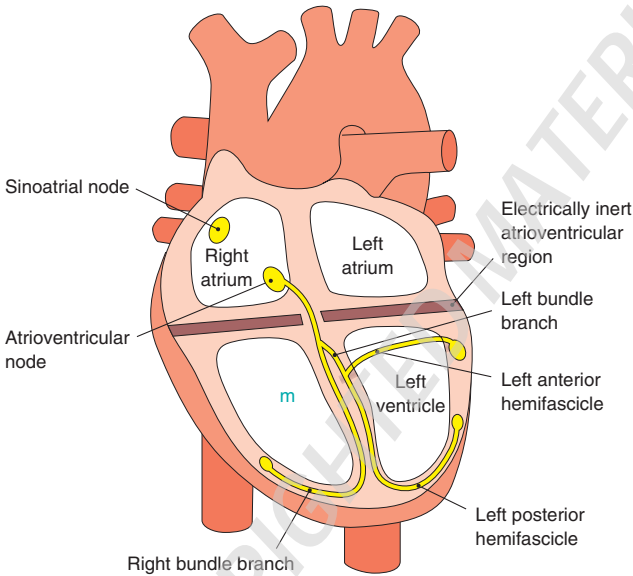


Figure 1.1 Conduction system of the heart.

## PQRST complex (figure 1.2)

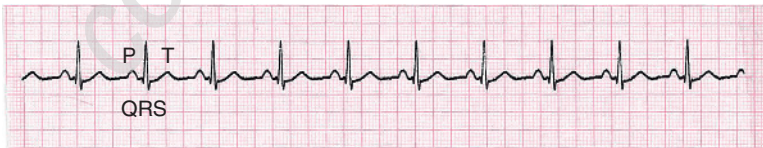

Figure 1.2 PQRST complex.

- *P wave*: atrial depolarisation
- *PR interval*: atrial depolarisation and the impulse delay in the atrioventricular (AV) node prior to ventricular depolarisation
- *QRS complex*: ventricular depolarisation
- *T wave*: ventricular repolarisation

## Sinus rhythm (figure 1.3)

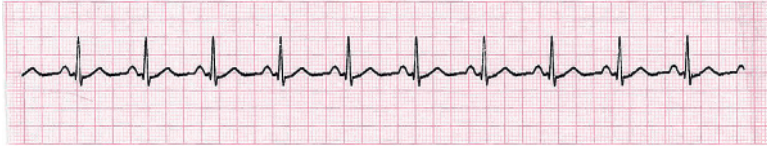

Figure 1.3 Sinus rhythm.

- Normal rhythm of the heart
- Impulse originates in the sinoatrial (SA) node (i.e. 'sinus'), regular rate of 60–100 beats per minute (bpm)
- No abnormal conduction delays

### *Sinus rhythm: Identifying ECG features*

- *Electrical activity*: present
- *QRS rate*: 60–100 bpm
- *QRS rhythm*: regular
- *QRS width*: normal width and morphology
- *P waves*: present and of constant morphology
- *Relationship between P waves and QRS complexes*: P waves associated to QRS complexes; PR interval normal and constant



**NB** Sinus rhythm can occasionally be seen in a cardiac arrest: pulseless electrical activity (PEA).