

## CHAPTER 1

# NORMAL OCULAR ANATOMY

Normal canine and feline orbital anatomy comprises the following:

The orbit, made up of bones, connective tissue, lacrimal and salivary glandular tissue, adipose tissue, blood vessels, and nerves.

The eyelids, comprising skin, orbicularis oculi muscles, deep tarsal, and superficial conjunctival tissue. These tissues also contain mucus-producing goblet cells, lipid-producing meibomian glands, and the openings of the nasolacrimal drainage system.

The third eyelid, comprising a T-shaped cartilaginous structure, which surrounds the lacrimal gland of the third eyelid and is covered with conjunctival tissue.

The external shell of the eye, comprising the cornea anteriorly and the episcleral and scleral tissues posteriorly. The cornea is composed of an outer epithelium (with its basement membrane), central stroma, and underlying endothelial layer (with its basement or "Descemet's" membrane).

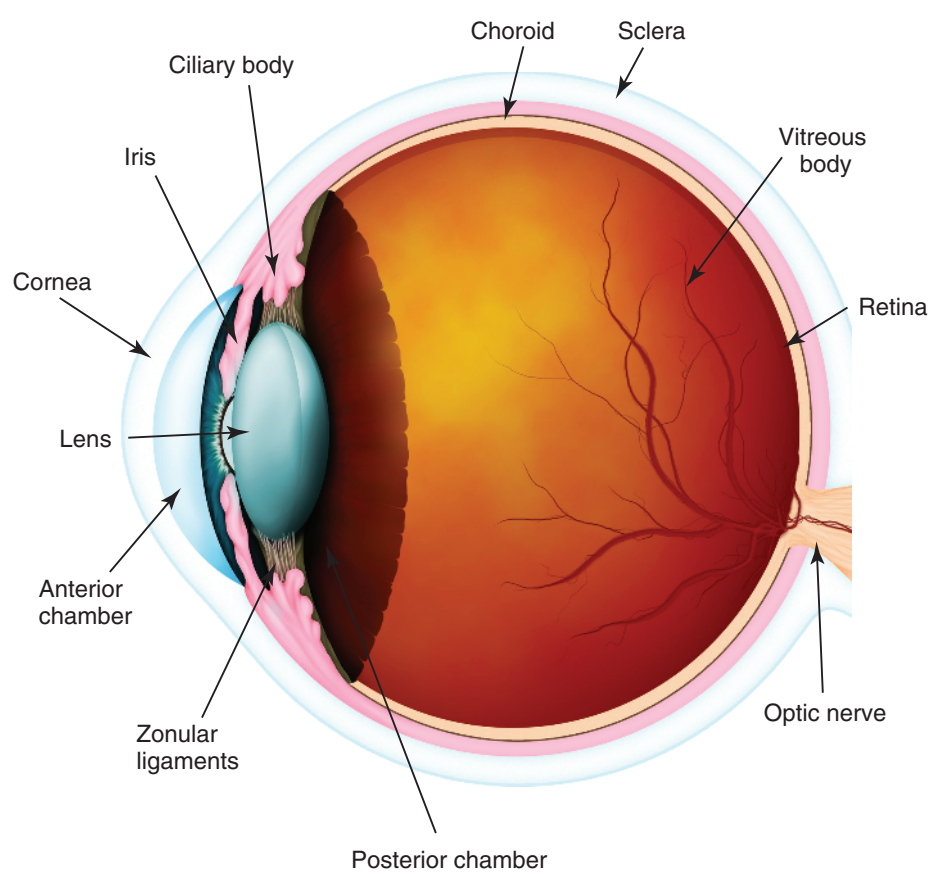
The uveal tract, composed of the anterior iris and ciliary body and the posterior choroid, which is the vascular supply to the retina.

The lens, which is suspended from the ciliary body by zonular ligaments and surrounded by the lens capsule.

The neuroretina which comprises;

- Nerve fiber layer and inner limiting membrane
- Ganglion cell layer
- Inner nuclear and inner plexiform layers
- Outer nuclear and outer plexiform layers
- Photoreceptors (rods & cones) and outer limiting membrane
- Retinal pigment epithelium.

Retinal ganglion cells coalesce to form the optic nerve which exits the globe posteriorly, through the porous lamina cribrosa.



**Figure 1.1** Normal ocular anatomy.