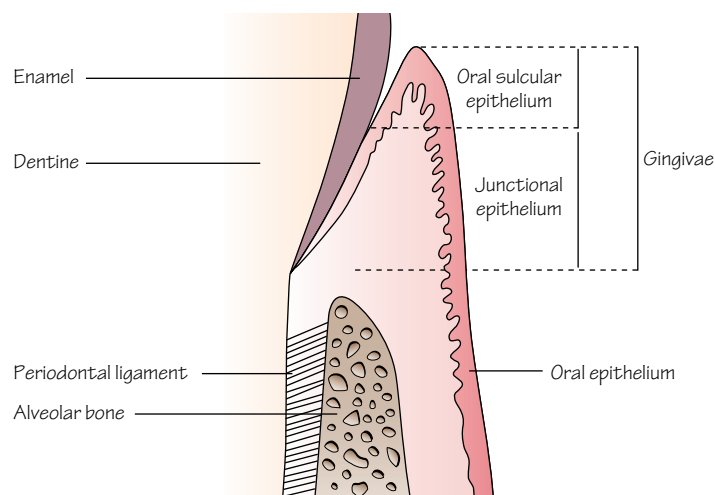


1 Anatomy of the periodontium

Figure 1.1 Longitudinal section through part of a tooth showing healthy periodontal tissues.



The gingiva is made up of the gingival epithelium and connective tissue. The gingival epithelium comprises oral epithelium, oral sulcular epithelium and junctional epithelium.

Figure 1.2 Dentogingival fibres, alveolar crest fibres and circular fibres in the gingival connective tissue.

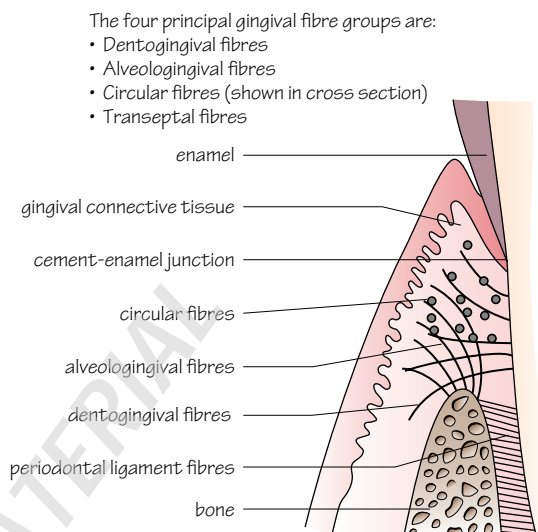


Figure 1.3 Interdental area showing transeptal and circular fibre groups in the gingival connective tissue.

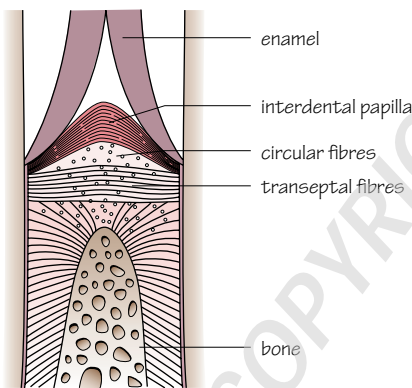
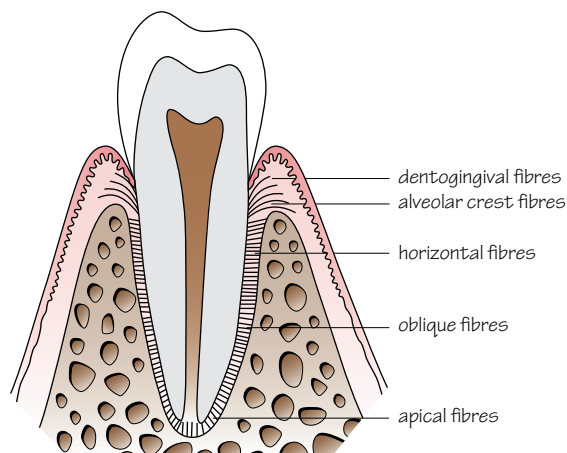


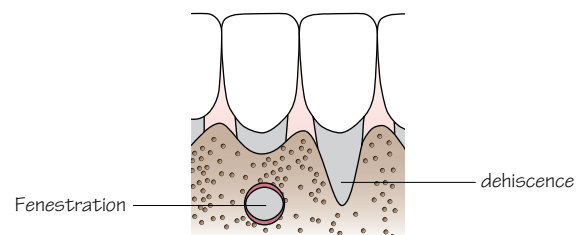
Figure 1.4 The periodontal ligament.



The four periodontal ligament fibre groups are:

- Alveolar crest fibres
- Horizontal fibres
- Oblique fibres
- Apical fibres

Figure 1.5 Bony fenestration and dehiscence.



In most situations these areas of missing bone remain undetected as they are covered with soft tissue. They may be clinically significant if associated with loss of soft tissue resulting in gingival recession (Chapter 32).

The periodontal tissues form the supporting structures of the teeth. The principal components of the periodontium are shown in Fig. 1.1:

- Gingivae (including epithelium and connective tissue).
- Periodontal ligament.
- Cementum.
- Alveolar bone.

Gingivae

The gingivae in health are pink and firm with a knife-edge appearance, scalloped around the teeth. In certain ethnic groups the gingivae may be pigmented. In health, the gingival margin is a few millimetres coronal to the cement–enamel junction. The gingival sulcus (or crevice) is a shallow groove which may be between 0.5 and 3 mm in depth around a fully erupted tooth. The gingival tissues are keratinised and appear paler pink than sites of non-keratinised oral epithelium.

Gingival epithelium

The gingival epithelium comprises (Fig. 1.1):

- Oral epithelium (OE).
- Oral sulcular epithelium (SE).
- Junctional epithelium (JE).

The gingival sulcus is lined by SE and JE.

Oral epithelium

- The OE is an orthokeratinised, stratified, squamous epithelium.
- Surface cells lose their nuclei and are packed with the protein keratin.
- It presents an impermeable physical barrier to oral bacteria.

The basal layer of epithelial cells is thrown up into folds overlying the supporting connective tissue. These folds increase the surface area of contact between the epithelium and connective tissue and are known as rete ridges or rete pegs.

Oral sulcular epithelium

- There are no rete ridges.
- Cells are keratinised but still have nuclei (parakeratinised).

Junctional epithelium

- The JE forms a specialised attachment to the tooth via:
 - a hemidesmosomal layer within the JE cells;
 - a basal lamina produced by the epithelial cells.
- The JE is non-keratinised and has a very fast turnover of cells (2–6 days compared to 1 month for OE).
- The most apical part of the JE lies at the cement–enamel junction in health.
- The JE at its widest point is 20–30 cells thick coronally.
- The JE tapers until it is only one cell in width apically.
- The JE is permeable with wide intercellular spaces through which cells and substances can migrate (such as bacterial toxins or host defence cells).
- Migration of the JE from its position in health apically onto the root cementum indicates a loss of periodontal attachment and progression to the disease state of periodontitis.

Gingival connective tissue

The gingival connective tissue (or lamina propria) is made up of collagen fibre bundles called gingival fibres, around which lie ground substance, fibroblasts, blood and lymph vessels and neural tissues. The four fibre groups are shown in Figs 1.2 and 1.3.

Periodontal ligament

The periodontal ligament forms the attachment between the cementum and alveolar bone. It is a richly vascular connective tissue within which lie bundles of collagen fibres; these are divided into four groups based on their position (Fig. 1.4).

Within the ligament are mechanoreceptors that provide sensory input for jaw reflexes. Cells from the periodontal ligament are involved in the formation and remodelling of alveolar bone and cementum. The periodontal ligament acts to dissipate masticatory forces to the supporting alveolar bone and its width, height and quality determine a tooth's mobility.

Cementum

Cementum is a mineralised tissue overlying the root dentine. It does not undergo physiological remodelling but is continuously deposited throughout life. Cementum is classified into two types:

- Acellular.
- Cellular.

Acellular cementum

Acellular cementum forms on root dentine during root formation and tooth eruption. Fibres inserted from the periodontal ligament are mineralized within the cementum and are known as Sharpey's fibres and are abundant in acellular cementum.

Cellular cementum

Cellular cementum lies over the acellular cementum. It contains cells called cementocytes which lie in lacunae. The cellular cementum layer is thicker in the apical region of the root where it is between 0.2 and 1 mm thick.

Alveolar bone

- The walls of the sockets are lined with a layer of dense bone called compact bone, which also forms the buccal and lingual/palatal plates of the jaw bones.
- In between the sockets and the compact jaw bone walls lies cancellous bone that is made up of bony trabeculae.
- The compact bone plates of the jaws are thicker on the buccal aspect of the mandibular molars and thinnest on the labial surface of the mandibular incisors.

The thickness of the compact bone layer is relevant to the choice of local analgesia techniques as the anaesthetic solution passes through bone to reach the nerve supply. The thin bone, particularly in the lower incisor region, can manifest as incomplete bony coverage in the form of fenestrations and dehiscences (Fig. 1.5).

The tooth sockets are lined with compact bone within which the principal fibres of the periodontal ligament are inserted. This area of bone can appear as a dense white line called the lamina dura on a radiograph.

Key points

- Gingivae
 - JE forms the specialised attachment to the tooth
 - The most apical part of JE lies at the cement–enamel junction in health
 - Supported by connective tissue containing collagen fibre bundles
- Periodontal ligament
 - Forms attachment between the cementum and bone
- Cementum
 - Mineralised and deposited continuously
- Alveolar bone
 - Compact and cancellous bone
 - Periodontal ligament fibres inserted into compact bone lining the tooth sockets