

CHAPTER 1

Female infertility

The normal female goat

In temperate regions, female goats are seasonally poly-oestrus. Most goats are totally anoestrus in the northern hemisphere between March and August, although fertile matings have been recorded in all months of the year. Anglo-Nubian and pygmy goats in particular have extremely long breeding seasons. Recently imported goats from the southern hemisphere may take time to adjust to a new seasonality. The breeding season is initiated largely in response to decreasing day length, but is also dependent on temperature, the environment (particularly nutrition) and the presence of a male. Decreasing day length also stimulates reproductive activity in the buck. Table 1.1 details the reproductive aspects of the goat.

Investigation of female infertility

Because of the seasonal pattern of breeding, infertility must be investigated as early as possible in the breeding season.

The investigation of female infertility in the goat presents major difficulties when compared with the cow because of the inability to palpate the ovaries and because of the seasonal pattern of breeding – does are often presented towards the end of the season, limiting the time available for remedial measures. Figure 1.1 lists possible causes of infertility in the doe.

Table 1.1 Reproduction in the goat.

Breeding season	September to March (northern hemisphere)
Puberty	5 months
Age at first service	4 to 6 months (male) 7 to 18 months (female)
Oestrus cycle	19 to 21 days (dairy goats) 18 to 24 days (Pygmy goats)
Duration of oestrus	24 to 96 hours (usually 36 to 40 hours)
Ovulation	24 to 48 hours after start of oestrus
Gestation length	150 days (145 to 156 days)
Weight at first mating	60–70% of predicted adult weight ~30 kg for meat goats 30–40 kg for dairy goats

Initial assessment

The preliminary history should consider:

- Individual or herd/flock problem.
- Feeding, including mineral supplementation.
- Management practices – hand-mating, artificial insemination (AI), buck running with does.
- Disease status of herd/flock.

If there is a *herd problem*, investigate:

- Male infertility (Chapter 3).
- Intercurrent disease – parasitism, footrot, etc.
- Nutritional status – energy or protein deficit, mineral deficiency (phosphorus, copper, iodine, manganese).
- Stress – overcrowding, recent grouping of goats.
- Poor heat detection.
- Services at incorrect time.

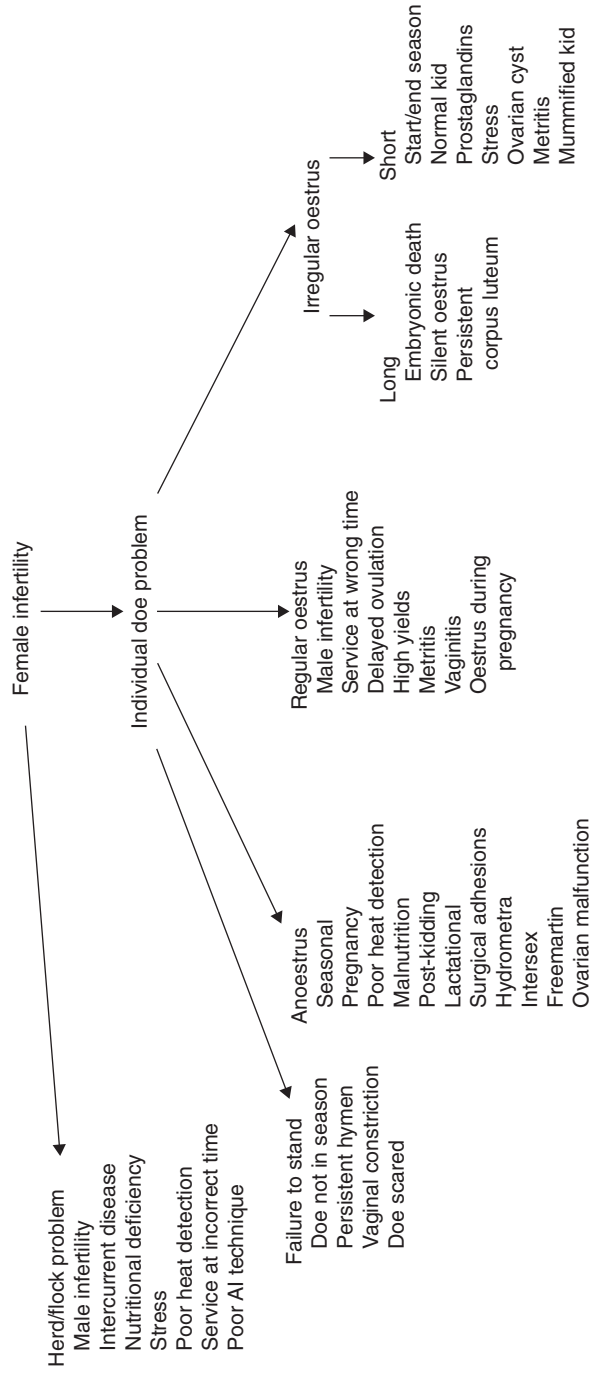

Figure 1.1 Causes of female infertility.

Assessment of individual doe

General assessment

- Conformation.
- Body condition.
- Dentition.
- Clinical examination.

Any obvious clinical signs such as debility, anaemia or lameness should be investigated and corrected where possible before commencing specific therapy aimed at correcting a reproductive disorder.

In the UK overfeeding is probably a greater cause of infertility than poor condition.

Specific examination

- Specific examination of the reproductive and mammary systems. Include, where necessary, examination of the vagina and cervix with a speculum to identify anatomical abnormalities.

Specific history

- Date of last kidding/stage of lactation.
- Daily milk yield.
- Presence or absence of obvious oestrus signs.
- Length of oestrus cycles.
- Date of last service.
- Willingness to stand for male.
- Kidding difficulties last time – malpresentation/manipulation, metritis, retained placenta, abortion, mummified fetus, stillbirths.

Further investigations

- Specific laboratory tests:
 - Progesterone assay
 - Oestrone sulphate assay
- Bacteriological examination of vaginal or uterine samples
- Feed analysis
- Real-time ultrasound scanning
- Laparoscopy or laparotomy.

Individual infertility problems

Individual infertility problems will generally fall into one of four categories:

- 1 **Difficulty at service.**
- 2 **Anoestrus.**

3 **Irregular oestrus cycles.**

4 **Regular oestrus cycles.**

Difficulty at service

- Doe not in season.
- Doe scared – common with maiden animals, particularly if a large buck is used on a small doe.
- Persistent hymen or vaginal constriction.

Anoestrus

Always consider the possibility of an undetected pregnancy (even if the owner insists that no mating has occurred) before attempting treatment, particularly with prostaglandins.

The causes of anoestrus are listed in Table 1.2 and discussed below.

- *Seasonal.* Most goats are totally anoestrus between March and August.
- *Pregnancy.*
- *Poor heat detection.*

Although some dairy goats show only minor behavioural changes during oestrus, oestrus detection is generally easier than in Angora goats, with most does showing obvious signs of tail wagging, frequent bleating, urination near the buck, swelling of the vulva and a mucous vaginal discharge. The signs are generally accentuated in the presence of a male or even a 'billy rag', that is a cloth that has been rubbed on the head of a buck and stored in a sealed jar.

Oestrus can be determined visually by means of a speculum. At the onset of heat, the cervix changes from

Table 1.2 Causes of anoestrus.

Seasonal
Pregnancy
Poor heat detection
Malnutrition
Post-kidding anoestrus
Lactational anoestrus
Adhesions following surgery
Hydrometra
Intersex
Freemartin
Ovarian malfunction

its normal white colour, becoming hyperaemic, and the cervical secretions are thin and clear. The secretions rapidly thicken, becoming grey/white and collecting on the floor of the vagina. Conception is best when mating occurs at the stage at which the cervical mucus is cloudy and the cervix is relaxed.

Unlike cows, most does will not stand to be ridden by other females even when in oestrus. Riding behaviour is sometimes seen as an expression of dominance in the herd or as part of the nymphomaniac behaviour of goats with cystic ovaries. Many young bucks will mount and serve females that are not in true standing oestrus if the female is restrained, although older bucks are more discriminating. The doe will stand to be mated only when she is in oestrus.

In the milking doe, a rise in milk production may occur 8 to 12 hours before the start of oestrus and milk production may fall below normal during oestrus.

When the buck is running with the flock or herd, sire harnesses with raddles or marker paste will aid oestrus detection. A marked vasectomised ('teaser') buck can be used to detect (and help initiate) the start of oestrus in a group of does.

- **Malnutrition.** An energy or protein deficit due either to poor nutrition or intercurrent disease may cause anoestrus. Deficiencies of minerals such as cobalt, selenium, manganese, zinc, phosphorus, iodine and copper and deficiencies of vitamins B12 and D are all reported to cause infertility.
- **Post-kidding anoestrus.** Many does will not show signs of oestrus for 3 months or more after kidding, even if kidding takes place during the normal breeding season.
- **Lactational anoestrus.** Some high yielding does do not exhibit marked signs of oestrus. These animals may respond to prostaglandin injections with careful observation for oestrus 24 to 48 hours later. Animals that do not respond may need a further injection 11 days later.
- **Adhesions following surgery.** The goat's reproductive tract is sensitive to handling and adhesions will occur unless very high standards of surgery are maintained during embryo transplant or other surgical procedures. Talc from surgical gloves will produce a marked tissue reaction.

False pregnancy (hydrometra, cloudburst)

False pregnancy occurs when aseptic fluid accumulates in the uterus in the absence of pregnancy, but in the presence of a persistent corpus luteum, which continues to secrete progesterone. The incidence of false pregnancies is fairly high, particularly in some strains of dairy goats and incidences of between 3 and 30% have been reported in commercial herds.

Aetiology

- A persistent corpus luteum following an oestrus cycle in which pregnancy did not occur. This may occur in any sexually mature female but is particularly common in goats in their second year of a lactation ('running through') without being mated. Certain families seem prone to develop the condition.
- A persistent corpus luteum following embryonic death with resorption of the embryo.
- Occurrence is increased following use of progestagen sponges and treatment with equine chorionic gonadotrophin (eCG).

Clinical signs

- The doe acts as if pregnant, with enlargement of the abdomen and a degree of udder development if not milking (Plate 1.1). Milking does may show a sharp drop in yield and this may result in a significant economic loss if the condition is not corrected.
- Fetal fluids collect in the abdomen (*hydrometra*) and the doe may become enormously distended, although the amount of fluid varies from 1 to 7 litres or more.
- When the hydrometra occurs following embryonic death, the false pregnancy generally persists for the full gestational length, or longer, before luteolysis occurs, progesterone secretion ceases and the fetal fluids are released (*cloudburst*). Some does milk adequately following a natural cloudburst.
- When the false pregnancy occurs in a doe which has not been mated, the release of fluid often occurs in less than the normal gestation period, the doe may cycle again and a further false pregnancy may occur if she is not mated. Subsequent pregnancies are not generally affected, but the doe is likely to develop the condition again the following year. The expelled fluid is generally clear and mucoid. The vulva and perineum become moist and the tail sticky (Plate

1.2). Some goats that spontaneously cloudburst early, before a large amount of fluid has accumulated, have a bloody discharge. The abdomen decreases to a normal non-pregnant size and bedding appears wet. Some does continue to squirt small amounts of fluid for a couple of days and in fact this could be confused with cystitis.

- If the false pregnancy follows fetal death, fetal membranes and possibly a decomposed fetus are present; otherwise no fetal membranes are formed.

Diagnosis

- Realtime ultrasound scanning of the right ventrolateral abdominal wall in early false pregnancy, or of either flank later, shows large fluid-filled hyperechoic compartments with the absence of fetuses or caruncles (Plate 1.3). The uterus is separated into compartments with thin tissue walls, which undulate when balloted. White flecks may be seen in the fluid. Scanning should take place at least 40 days after mating to avoid confusion with early pregnancy and is easier before 70 days. *Pyometras* (rare) also present as fluid filled uteri but are more hyperechoic.
- Elevated milk or plasma progesterone levels are consistent with pregnancy, but with low milk or plasma oestrone sulphate levels at >45 days.
- X-ray at 70–80 + days fails to show fetal skeletons in an anoestrus doe with a distended abdomen.
- Pregnancy specific protein is negative in pseudopregnancy.

Treatment

- As pseudopregnancy is maintained by the presence of a corpus luteum, treatment is by prostaglandin injection:
Dinaprost, 5–10 mg i.m. or s.c. or Clorprostenol, 62.5–125 µg i.m. or s.c.
Dinaprost has a direct effect on uterine muscle and may be preferable to clorprostenol. A second injection of prostaglandin 12 days after the first may cause evacuation of further uterine fluid and, it is suggested, may make the condition less likely to recur.
- An oxytocin injection a few days after treatment with prostaglandin stimulates uterine contractions and aids involution:
Oxytocin, 2–10 units, 0.2–1.0 ml i.m. or s.c..

Pituitary extract (posterior lobe), 20–50 units, 2–5 ml i.m. or s.c. or 2–10 units, 0.2–1.0 ml i.m. (preferred) or s.c.

- The prognosis for future fertility is good, with 85% of goats becoming pregnant if mated during the same breeding season.

Other conditions causing anoestrus

- *Hydrops uteri*. A false pregnancy may need to be distinguished from hydrops uteri. Hydrops uteri is an unusual condition of pregnant goats caused by an abnormal accumulation of fluid in either the amniotic (hydramnios) or allantoic (hydrallantois) sacs. Distension of the uterus is caused by accumulation of fluid, which may be greater than 10 litres, leading to bilateral, rapidly progressive abdominal distension. Other clinical signs, similar to those of pregnancy toxæmia, are a result of compression of other organs by the fluid – lethargy, inappetence, decreased defaecation, recumbency, tachycardia and dyspnoea.

Ultrasonography can be used to distinguish between false pregnancy (hydrometra), where the uterus is distended with fluid but no fetuses, membranes or cotyledons are present, and hydrops uteri, where fluid, fetuses, membranes and cotyledons are present. Most fetuses of animals with hydrops uteri have congenital defects and are underdeveloped, but may appear normal although not viable.

Treatment is by caesarian section or by induction of parturition with prostaglandins, but cardiovascular support with intravenous fluids should be provided because of the danger of hypotension from the sudden loss of large volumes of fluid.

- *Intersex (pseudohermaphrodite)*. An intersex is an animal that shows both male and female characteristics. In goats the dominant gene for absence of horns (polled condition) is associated with a recessive gene for intersex. Thus an intersex is normally polled with two polled parents. Intersex is a recessive sex-linked incompletely penetrant trait resulting from the breeding of two polled goats – intersex goats are homozygous for the polled (hornless) gene and homozygous for the intersex gene.

A mating between a homozygous (PP) polled male and a heterozygous (Pp) polled female will produce 50% intersexes; a mating between a heterozygous (Pp) polled male and a heterozygous (Pp) polled female will produce

25% intersexes. In theory, mating two homozygous (PP) polled animals should produce 100% intersexes, but the gene has incomplete penetrance.

Affected animals are genetically female with a normal female chromosome complement (60 XX), but phenotypically show great variation from phenotypic male (Plate 1.4) to phenotypic female (Plate 1.5). Some animals are obviously abnormal at birth with a normal vulva but enlarged clitoris or a penile clitoris. The gonads are generally testes or ovotestes, which may be abdominal or scrotal and phenotypic males may have a shortened penis (hypospadias), hypoplastic testes or sperm granuloma in the head of the epididymis. Other animals may reach maturity before being detected and may present as being anoestrus. A phenotypically female animal may have male characteristics due to internal testes.

Intersexes with female appearance are sometimes presented as kids or goatlings with a history of anoestrus. Although the vulva is normal, there is no true vagina or cervix, the clitoris may be enlarged and the anogenital distance may be > 3 cm. The presence or absence of a vagina of proper length should always be investigated in anoestrus kids. The absence of a vagina can be demonstrated by gently inserting a lubricated plastic rod, for example a ballpoint pen, into the vulva (Plates 1.6 and 1.7) or endoscopically. Care should be taken not to mistake a persistent hymen for a shortened vagina.

Intersexes with male appearance may have a penis or penis-like structure just below the anus. These animals may have urine scalding down their hind legs or have dysuria. Urine may accumulate in the perineal area causing dermatitis. In some cases, the urethra does not pass through the vestigial penis/clitoris and surgery may be required to establish an effective urethral opening. Localised hypospadias has been described in some cases.

- *Freemartins (XX/XY chimeras)*. Most female kids born co-twin to males are normal females, because placental fusion is much less common than in cattle. A freemartin is a female rendered sterile in utero when her placenta and that of her twin male fuses in early gestation, allowing vascular anastomosis between the allantoic membranes, exchange of cells and hormones between the two fetuses and XX/XY chimaerism. The developing genital tract of the female is influenced by the male and results in hypoplasia of the female gonads. A freemartin may be polled or horned. There is some evidence that the

condition is slightly more common when the female shares the uterus with two or more male fetuses. Externally freemartins appear female but internally show a variable degree of masculinisation:

- Heavy masculinisation, Gonads resemble testes and may contain tubules and interstitial tissue.
- Light masculinisation. Oocytes have been found in the gonads.

- *Whole body chimera*. The rarest type of caprine intersex, which arises from the fusion of two embryos, produces a true hermaphrodite with an XX/XY karyotype and gonads of both sexes.

- *Ovarian malfunction*. Ovarian inactivity is poorly understood in the goat, but some anoestrus goats will respond to treatment with gonadotrophin releasing hormone [GnRH]:

Buserelin, 0.020 mg i.m., s.c. or i.v. or Gonadorellin, 0.5 mg i.m.

Other goats will respond to treatment with prostaglandins, suggesting a *persistent corpus luteum* or *luteinised cystic ovaries*.

Ultrasound scanning can be used to examine the ovaries but is not as easy as in cattle, because the reproductive tract cannot be manipulated manually so it is impossible to scan all the surfaces of the ovary. Both transrectal (using a lubricated 5 or 7.5 MHz linear transducer) or transabdominal (using a 5 MHz transducer) scanning can be carried out with the goat in a standing position. The bladder is located as a landmark and the transducer rotated to the left or right until the ovary is visualised. The ovary appears as a tissue-dense, circular to oblong structure cranial to the bladder. Follicles are non-echogenic fluid-filled structures that appear as black circular sacs.

Increased use of laparoscopic techniques may aid the diagnosis of these conditions.

Irregular oestrus cycles (see Table 1.3)

Long oestrus cycles

- *Embryonic death*. Early embryonic death with loss of the corpus luteum will produce a subsequent return to oestrus following resorption of the embryonic material. Following embryonic death, a percentage of does will not return to oestrus but develop hydrometra.
- *Silent oestrus*. Some does will exhibit oestrus early in the season and then show no further oestrus signs for

Table 1.3 Irregular oestrus cycles.

Long	Short
Embryonic death	Start/end of season
Silent oestrus	Normal kid behaviour
Persistent corpus luteum	Prostaglandins
	Premature regression of the corpus luteum
	Stress
	Ovarian follicular cyst
	Metritis
	Mummified kid
	Ovarian tumour

some months. These goats may be cycling silently and will respond to treatment with prostaglandins.

- *Persistent corpus luteum*. Failure of the corpus luteum to undergo luteolysis at the correct time will delay the return to oestrus. Treat with prostaglandins (see this chapter).

Short oestrus cycles (<18 to 21 days)

- Short anovulatory cycles of about 7 days are common at the *start of the breeding season* and occasionally occur at the end of the breeding season.
- *Kids* commonly show short cycles during their first breeding season.
- Very short oestrus cycles have been recorded following administration of *prostaglandins* to abort does. A normal oestrus pattern returns after 3 to 4 weeks.
- *Premature regression of the corpus luteum* is recognised as a problem in goats undergoing oestrus synchronisation for embryo transplant. In some cases this will be a result of stress (see below). In other cases, the cause is unknown.
- *Stress* will often cause groups of goats to show short cycles of around 7 days, presumably because of premature regression of the corpus luteum. For this reason goats being brought together for a breeding programme, for example for embryo transplant, should be grouped at least 3 months before the start of the programme.
- *Ovarian follicular cysts* produce oestrogens, which result in a shortened oestrus cycle of between 3 and 7 days or continuous heat. Eventually the oestrogenic effects produce relaxed pelvic ligaments and the goat displays male-like mounting behaviour. The diagnosis can be confirmed by laparoscopy or laparotomy.

Treatment is exceptionally difficult in goats because the relatively short breeding season means that by the time treatment is completed the doe has already entered seasonal anoestrus. Medical treatment is only successful if commenced early:

Chorionic gonadotrophin 1000 U, i.m. or i.v. or Gonadotrophin releasing hormone (GnRH): buserelin, 0.020 mg i.m., s.c. or i.v. or gonadorellin, 0.5 mg i.m.

Surgical treatment to exteriorise and rupture the thick wall of the cyst should be considered in valuable animals.

- Ovarian tumours are rare in goats, with granulosa theca cell tumours being the most common type. Clinical signs include short cycles, nymphomania and male behaviour. Examination of the ovary laparoscopically or with rectal or transabdominal ultrasound usually shows an enlarged ovary that may be cystic.
- *Endometritis* may cause short cycling or return to oestrus at the normal time.
- *Vaginitis*: see 'Regular oestrus cycles'.
- The presence of fetal bone remaining from a *mummified kid*, which is not expelled at parturition, will act as a constant source of stimulation and result in short oestrus cycles. There may be a history of bones and fetal material being expelled at kidding or subsequently.

Regular oestrus cycles (see Table 1.4)

- *Male infertility* (Chapter 3).
- *Service at the wrong time*.
- *Delayed ovulation/follicular atresia*. There is little scientific evidence describing these conditions in goats, but in practice a 'holding' injection given at the time of

Table 1.4 Regular oestrus cycles.

Male infertility
Service at the wrong time
Delayed ovulation
High yielders
Metritis
Vaginitis
Oestrus during pregnancy

service or AI will aid fertility in some animals by stimulating ovulation on the day of service:

Chorionic gonadotrophin, 500 U i.m. or i.v.

Gonadotrophin releasing hormone (GnRH): busere-
lin, 0.010 mg i.m., s.c. or i.v.

Gonadorellin, 0.25 mg i.m.

- *High yielding females.* Some high yielding females may have suboptimum fertility, possibly due to a pituitary dysfunction resulting from the heavy lactation. Maturation of follicles, ovulation and formation of the corpus luteum may be promoted by chorionic gonadotrophin, 500 U i.m. or i.v.
- *Metritis.* A low-grade metritis may result in the failure of the embryo to implant and subsequent return to service at the normal time.
- *Vaginitis.* Vaginitis occasionally occurs, particularly after the removal of vaginal sponges, and may result in short oestrus cycles or repeated return to service at a normal cycle length. In New Zealand, Australia and the United States, *caprine herpesvirus 1 (CpHV-1)* causes vulvovaginitis with short oestrus cycles and resulting infertility. Initial clinical signs are oedema and hyperaemia of the vulva with a slight discharge, which becomes more copious over the next few days. Multiple, shallow erosions with yellow to red-brown scabs develop on the vulvar and vaginal mucosa. Lesions heal spontaneously in about two weeks but may recur. Infection may be subclinical.

The virus is transmitted venereally and in the male produces penile hyperaemia and erosions of the preputial and penile epithelium. There is prolonged shedding of the virus by the preputial route.

CpHV-1 is also responsible for lethal systemic infections in one to two week old kids and for subclinical infections of the respiratory tract in adults.

- *Oestrus during pregnancy.* A few goats exhibit regular oestrus signs during pregnancy although this is less common than in cattle. Ovulation does not occur and the signs of oestrus are usually rather weak. Accurate pregnancy diagnosis is important before attempting treatment, particularly with prostaglandins.

Pregnancy diagnosis

Non-return to service is not a reliable method of pregnancy diagnosis. Many does do not outwardly cycle throughout the breeding season and the non-return may be due to seasonal anoestrus or false pregnancy. Neither is mammary development in primiparous goats a reliable method of pregnancy diagnosis as maiden milkers are common. Nor is abdominal distension.

Although animals may have behavioural changes during late pregnancy (for example, a 'dog sitting' position is normal for some pregnant goats (Plate 1.8), these are very variable. Accurate pregnancy diagnosis is essential to distinguish between pregnant goats, those with false pregnancies and those that are not cycling.

A vasectomised and harnessed teaser male running with the does will detect return to service, that is non-pregnancy, but should not be relied upon as some males will mount females that are not cycling. *Always* undertake an accurate pregnancy diagnosis before using prostaglandins to induce oestrus. Table 1.5 lists the methods available.

Table 1.5 Techniques available for pregnancy diagnosis in the doe.

	Days	Fetal numbers	Accuracy (%)	Usefulness
Vasectomised male	>20	No	65–90	Moderate
Abdominal palpation	60–115	No	60–90	Moderate
Progesterone assay	18–22	No	90–95	Moderate
Oestrone sulphate assay	>50	No	>95	High
Pregnancy specific protein B	>26	No	>95	High
Realtime ultrasound	28–100	Yes	95–100	High
Doppler ultrasound	60–90	No	85–90	Moderate
Radiography	>70	Yes	>90	Low

Oestrone sulphate assay

Oestrone sulphate concentrations in milk and plasma increase steadily during pregnancy and can be used to diagnose pregnancy 50 days post-service. This test will distinguish between true pregnancy and hydrometra, but occasional false negatives do occur, particularly if the sampling is close to 50 days, and repeat sampling may be indicated before the induction of oestrus with prostaglandins to avoid the possibility of aborting a pregnant doe.

Ultrasonographic scanning

Realtime ultrasonographic scanning has the added advantage of giving some indication of the number of kids being carried, thus enabling a better estimate of the nutritional requirements of the doe during pregnancy. The technique is virtually 100% accurate in determining pregnancy and 96 to 97% accurate in determining twins and triplets. Good operators can distinguish hydrometra, resorbed fetuses and other abnormalities as well as live kids (Table 1.6). Goats can be scanned transabdominally or transrectally. Sector scanners are best for transabdominal scanning but linear scanners can be used and are better for transrectal scanning. Transrectal ultrasound techniques are preferred for very early pregnancies and permit diagnosis 4 to 5 days earlier than transabdominal techniques.

Transabdominal scanning is usually carried out with the goat standing. A 3.5 or 5 MHz transducer is suitable for most of the pregnancy, but may not penetrate

as far as the foetus in late gestation, although caruncles will be visible. Before about 90 days a 5 MHz transducer gives the best results; in later pregnancy, a 3.5 MHz probe is preferable. Scanning can be used from 28 days post-service when a fluid-filled uterus can be identified, but is best used between 50 and 100 days of pregnancy. Cotyledons can be distinguished from about 40 days and individual foetuses by 45 to 50 days. By 100 days individual fetuses more than fill the entire screen, making accurate determination of numbers difficult (Table 1.7). The most common error is to underestimate the number of fetuses.

The transducer is placed on the right side of the restrained standing doe in the relatively hairless area

Table 1.7 Transabdominal ultrasound scanning for pregnancy diagnosis.

Day of gestation	Ultrasound findings
28	Fluid-filled uterus
30–35	Fetal heart beats detectable
40	Cotyledons visible (doughnuts or c-shaped structures)
45–50	Individual fetuses first identifiable
45–90	Accurate determination of multiple kids Gestational age corresponds to crown rump length, biparietal diameter and chest diameter
>100	Identification of number of fetuses becomes difficult because individual kids fill the screen; fluid and fetuses shift cranially

Table 1.6 Abnormal finding on ultrasonographic examination of the uterus.

Abnormality	Ultrasound findings
Recent abortion	Margins of the enlarged uterus observable, with caruncles often visible but with no fetus or fluid
Hydrometra	Anechoic or hypoechoic fluid-filled uterus, often with membranous strands visualized in the lumen of the uterus or apparent septae within the lumen of the uterine horn
Pyometra	Fluid-filled uterus; fluid more hyperechoic than hydrometra, often has a swirling appearance
Retained mummified foetus	Hyperechoic bone shadows in the absence of fluid contrast Lack of fluid contrast, dense bony shadows, or cranium or ribs in an organized foetal mass Usually smaller than expected foetal mass No sign of viability of fetus
Macerated foetus	Hyperechoic bone shadows in the absence of fluid contrast Overriding bony densities, usually linear or curvilinear images, with no sign of normal fetal architecture

just cranial and dorsal to the udder, with the transducer beam aimed towards the opposite brim of the pelvis (towards the pelvic inlet) and the abdomen scanned by slowly sweeping cranially. The uterus is normally dorsal or cranial to the bladder. Early in pregnancy (30 to 45 days), the uterus lies towards the pelvic inlet, but later is usually against the right abdominal wall. Clipping the area helps in fibre or long-coated goats. The area should be as clean as possible and large amounts of ultrasound gel used.

Transrectal scanning can be carried out from 25 days. Faeces are removed from the rectum and the lubricated 5 or 7.5 MHz linear transducer is advanced gently until it is adjacent to the reproductive tract. Initially the animal should be examined in a standing position, which is generally less stressful for the animal, but if the uterus is not identifiable the doe can be placed in dorsal recumbency.

Foetal viability can be evaluated during ultrasonographic examination, the presence of fetal movement or heartbeat indicating a live fetus. The fetal heart beat can be detected 35 days into the pregnancy by transabdominal ultrasonography (earlier by transrectal ultrasonography). Lack of echogenicity of amniotic fluid, the proper amount of fluid for the gestational stage and normal foetal posture and movement are signs of a healthy fetus. Fetal size incompatible with the expected gestational age may indicate earlier fetal death, as may increased fluid echogenicity, 'floating' membranes, collapsed fetal posture and failure to detect a heartbeat or fetal movement. Hyperechogenicity of the cotyledons is a common finding in a non-viable pregnancy.

Age determination is most accurately carried out early in gestation. Gestational age can be subjectively assessed based on size of the fetus and cotyledons, or the size of the amniotic vesicle in early gestation. Between 40 and 100 days, the length of the fetuses and the fetal head width or biparietal diameter (BPD) correlate closely with gestational age (see Table 1.8 and Figure 1.2). Later in pregnancy, the variation in size of fetuses is too great to permit accurate age determination.

Determination of fetal gender is by visualisation of the male/female genital tubercle or male scrotum. Best results are obtained between 55 and 75 days. Accuracy is decreased when multiple kids are present, because the spontaneous movement and repositioning of the foetuses during the examination makes visualising individual foetuses difficult.

Table 1.8 Correlation of fetal length with age of fetus.

Gestation (days)	Fetal length (mm)
45	40
60	100
90	250

Pre-breeding examination is important, especially in herds with out-of-season breeding programmes, for routine examination of does before assignment to breeding groups will allow detection of animals that would not respond to synchronisation, treatment of abnormal does and identification of does for potential culling. Abnormal findings by ultrasound can be followed by a vaginal speculum exam or other diagnostic procedures.

Doppler ultrasound techniques

Doppler ultrasound techniques can detect the fetal pulse after about 2 months' gestation, using either an intrapelvic probe or an external probe placed on a clipped site immediately in from the right udder or lateral to the left udder using ultrasound gel or vegetable oil to improve contact. Between 60 and 120 days' gestation the accuracy in detecting non-pregnancy is more than 90%, but the method is unreliable in detecting multiple fetuses.

Pregnancy specific protein B

Pregnancy specific protein B (PSPB) is produced by the placenta and is identifiable in plasma or serum, using an ELISA test, from 26 days after mating and then throughout pregnancy, dropping rapidly after parturition, but still detectable for several weeks. It has an accuracy rate of >95% – false positives are likely to be caused by loss of the embryo, rather than inaccuracy of the test. A positive result therefore means that the animal is pregnant or has recently been pregnant (or aborted or resorbed). If it is suspected that a doe has or may have resorbed or aborted, a second blood sample several weeks later would distinguish between pregnancy (continuing high protein level) or non-pregnancy (precipitous drop in protein level). Goats carrying multiple fetuses have higher PSPB concentrations than those carrying singles but there is sufficient overlap to prevent accurate identification of

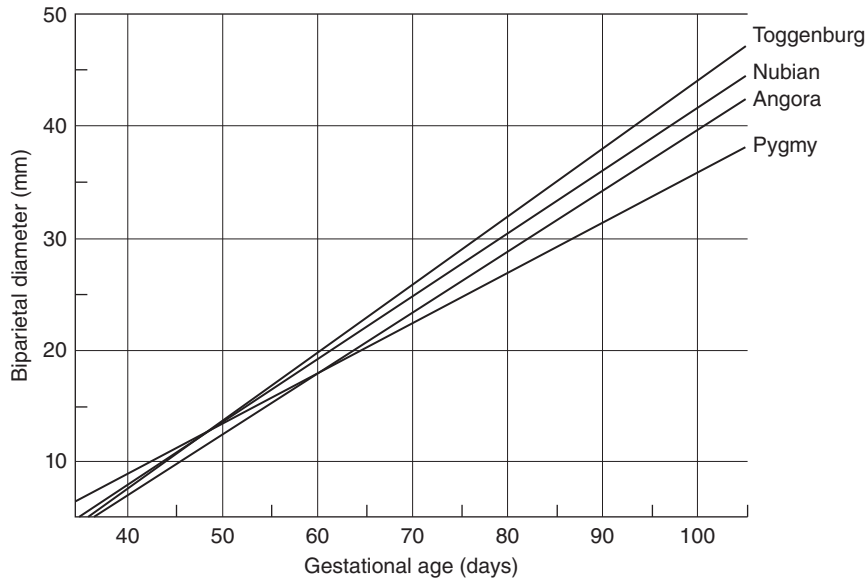


Figure 1.2 Biparietal diameter and gestational age of goats (from Haibel *et al.*, 1989).

single from multiple fetuses. The test is marketed in the United States by BioTracking, Moscow, ID.

Progesterone assay

Progesterone secreted by the corpus luteum of a pregnant goat can be detected by radioimmunoassay or by ELISA methods in milk or in plasma. Progesterone levels remain high throughout pregnancy.

Random sampling will not lead to accurate pregnancy diagnosis because the corpus luteum of the normal oestrus cycle and that of hydrometra also produce progesterone. A sample taken 24 days after mating will give nearly 100% accuracy in determining non-pregnancy but only about 85 to 90% accuracy in determining pregnancy because of factors such as early embryonic death and hydrometra. *A low progesterone level always indicates non-pregnancy.*

Radiography

Fetal skeletons are detectable by radiography between 70 and 80 days, although the technique is more useful after 90 days. An enlarged uterus may be detected at 38 days and over.

Rectoabdominal palpation

In the non-pregnant goat a plastic rod inserted in the rectum can be palpated at the body wall. Between 70

and 100 days post-service, the pregnant uterus prevents palpation of the rod. However, the technique produces unacceptably high levels of fetal mortality and risk of rectal perforation.

Ballotment

Ballotment of the right flank or ventrally is a time-honoured goatkeepers' technique for pregnancy diagnosis, but in the author's experience it is extremely unreliable. Fetal movements can often be observed in the right flank of the doe during the last 30 days of gestation.

Use of prostaglandins

Unlike other ruminants where placenta-derived progesterone becomes significant, the goat depends on corpus-luteum-derived progesterone throughout pregnancy, and is thus susceptible to luteolytic agents, including prostaglandins, throughout the whole of the pregnancy. Prostaglandins can be used for:

- Timing of oestrus.
- Synchronization of oestrus.
- Misalliance.
- Abortion.
- Timing and synchronization of parturition.

- Treatment of hydrometra.
- Treatment of persistent corpus luteum.

Prostaglandins can be used to terminate pregnancy throughout the whole gestation period.

Suggested doses of prostaglandins in dairy goats are:

Dinaprost, 5–10 mg i.m. or s.c. or Clorprostenol, 62.5–125 µg i.m. or s.c.

Smaller doses will produce luteolysis in Angora goats.

The effect of prostaglandin administration is seen between 24 and 48 hours (generally around 36 hours) post-injection, provided the animal being injected has an active corpus luteum, that is between days 4 and 17 of the normal oestrus cycle or during pregnancy. For induction of parturition where live kids are required, prostaglandins should not be used alone before day 144 of gestation, because prostaglandins bypass the steps involved in producing fetal lung surfactant. Before day 144, dexamethasone should be used and will produce parturition in about 48 to 96 hours (Figure 1.3).

Where rapid termination is required and the viability of the kids is not critical, for example when the doe is collapsed, prostaglandins can be used at any stage of gestation. There is generally no problem with retained fetal membranes following induction with prostaglandins or dexamethasone.

Table 1.9 Methods for controlling oestrus cycles.

Transitory Period	Breeding season	Out of breeding season
Buck effect	Prostaglandin injection(s)	Lighting regimes
Progestagen sponge or CIDR + PMSG	Progestagen sponge or CIDR + PMSG	Progestagen sponge or CIDR + PMSG Lighting regime + Melatonin

Control of the breeding season

Out-of-season breeding is being increasingly used to enable milk producers to maintain regular supplies of fresh milk and to produce three kid crops in 2 years from fibre goats. Best results are obtained when the techniques are used to extend the breeding season, that is by early or late season breeding, rather than in deep anoestrus. Table 1.9 shows methods available for controlling oestrus cycles.

Introduction of a buck or teaser male (buck effect)

Introduction of a buck or teaser male produces oestrus before the start of the breeding season, with loose synchronisation of oestrus. The introduction of a teaser or entire male into a group of does, which have been deprived of the sound, sight and smell of a male for at least 4 to 6 weeks during the transitional period before

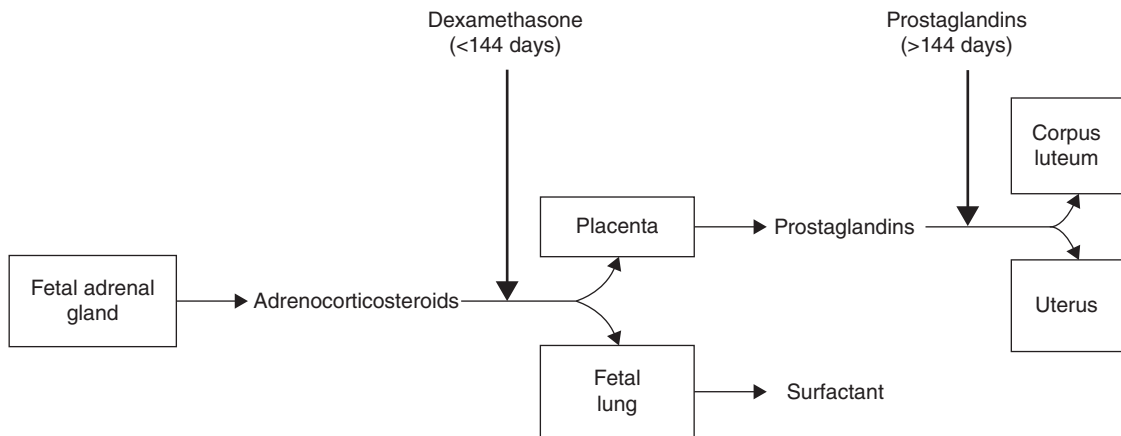


Figure 1.3 Induction of parturition.

the start of the normal breeding season, will produce oestrus cycles within 3 to 10 days, but the first one or two oestruses may be silent, without any sign of behavioural oestrus. A silent oestrus may be followed by a fertile oestrus 21 days later or the first silent oestrus may be followed by a short cycle and a second silent oestrus or fertile oestrus after about 5 days, following premature regression of the corpus luteum.

The fertility of the females after exposure is variable – the closer to the breeding season, the higher the fertility.

Prostaglandin injections

During the normal breeding season, the luteolytic effect of prostaglandins can be used to induce oestrus in animals with a corpus luteum, that is between days 4 and 17 of a normal oestrus cycle. Return to oestrus occurs between 24 to 48 hours post-injection, generally about 36 hours; 60–70% of the herd should respond to a single injection.

Dinaprost, 5–10 mg i.m. or s.c. or Clorprostenol, 62.5–125 µg i.m. or s.c.

For synchronisation of oestrus, two injections should be given 9 to 11 days apart.

Lighting regimes

Lighting extends the breeding season into the spring, with synchronisation of oestrus. Does respond to a shortening daylength by ovulation and oestrus. Keeping goats under an artificially long daylight regime during the winter months, followed by a sudden change to normal daylength in the spring, enables out-of-season breeding to be achieved from April to June during the normal anoestrus period.

From 1 January, 20 hours of artificial light are given daily for 60 days. After 60 days, the goats are returned to normal lighting. Oestrus occurs 7 to 10 weeks later. The oestrus period may be shorter than normal (often only 8 to 10 hours compared to the normal 24 to 96 hours) and the signs of oestrus are not very obvious, so best results are obtained if the males are run with the females. Sudden introduction of the male to the females after their return to normal daylength increases the percentage of successful matings.

The lights must be of sufficient number and intensity to simulate daylight and suppress melatonin – 200 lux

is provided by one 36 watt fluorescent light per 18 m² of floor space with lights at a height of about 2.75 m. The males should undergo light treatment at the same time as the females. With this regime, kidding rates of 50 to 60% can be expected, although up to 90% has been obtained.

Theoretically, it is not necessary to provide continuous lighting for the extended long day period. In sheep, a long day effect can be obtained by providing one extra hour of light during the night, provided it is given 7 to 8 hours before dawn. However, equivocal results have been obtained with goats, so the practical application of short light pulses remains to be established. One regime is to provide additional light between 6 a.m. and 9 a.m. (fixed dawn) and between 10 p.m. and midnight.

Progestagen-impregnated intravaginal sponges

Progestagen-impregnated intravaginal sponges enable:

- Oestrus synchronisation within the breeding season.
- Extension of the breeding season.
- Out-of-season breeding.

Two types of impregnated sponge are currently available in the UK:

Medroxyprogesterone, 60 mg (Veramix Sheep Sponge, Zoetis) and Flugestone acetate, 20 mg (Chronogest, MSD)

Applicators are available for insertion of the sponges, but because the goat's vagina is more delicate than that of sheep, it is generally better to insert the sponges manually with a gloved hand using a small amount of antiseptic cream. If the animals are handled gently, the incidence of vaginitis or vaginal adhesions is low, but oxytetracycline powder may be used at insertion.

The principal of progestagen synchronisation is that:

- Gonadotrophin releasing hormone (GnRH) and gonadotrophin release is inhibited because of the negative feedback of the progestagen on the hypothalamus/pituitary.
- When the progestagen is suddenly withdrawn, there is a rebound effect with the sudden release of GnRH, and thus gonadotrophin, provided that there is no residual luteal function, which is itself secreting progesterone.
- Thus the progestagen must be administered for at least 12 days, but preferably longer (up to 20 days),

or used in conjunction with prostaglandins given 48 hours before sponge removal.

Improved pregnancy rates are generally obtained with shorter periods of progestagen treatment, particularly in large goats, as the hormonal levels in the sponges are designed for sheep. Progestagens are used for 9–12 days with prostaglandin treatment 48 hours before removal of the sponges (see Table 1.10). Removal of the sponges promotes oestrus in 95 to 100% of animals in the transitional and normal breeding periods, but in only about 70% of animals outside these periods.

Two days before sponge removal, or at sponge removal if during the breeding season, a dose of follicle stimulating hormone, that is serum gonadotrophin (PMSG), is administered s.c. or i.m. to ensure optimum ovulation. The dose depends on the size of the goat, its yield and the season when the sponges are being used (Table 1.11). If

high doses of serum gonadotrophin are used, superovulation may occur, with resultant multiple births.

There are usually very strong signs of oestrus following sponging. The presence of a male improves the response. Oestrus occurs 24 to 72 hours after sponge removal (generally 30–36 hours). This is dependent upon several factors, which include:

- Social cues.
- Day length and ambient temperature.
- Whether the goat has been routinely cycling and producing regular pulsatile amounts of LH.
- Age of animal.
- Amount and type of chorionic gonadotrophin or follicle stimulating hormone given before or at sponge or CIDR removal.

Table 1.10 Regimes for sponging goats.

Breeding season			
Day 0 Sponge inserted	Day 9 Prostaglandin injection	Day 11 Sponge removed + serum gonadotrophin injection	Day 12–13 Onset of oestrus
Out of breeding season			
Day 0 Sponge inserted	Day 9 Serum gonadotrophin injection	Day 11 Sponge removed	Day 12–13 Onset of oestrus
Transitory period			
Day 0 Sponge inserted	Day 9 Prostaglandin injection + serum gonadotrophin injection	Day 11 Sponge removed	Day 12–13 Onset of oestrus

Table 1.11 Serum gonadotrophin treatments for sponged goats.

	Time of injection of serum gonadotrophin	Dose of serum gonadotrophin (i.u.) (PMSG)	
		Production of milk/day <3.5 kg	> 3.5 kg
Out of season (March–June)	48 hours before sponge removal	600	700
Transitory period	48 hours before sponge removal	500	600
Breeding season (September–February)	At sponge removal	400	500

Table 1.12 Optimum time for artificial insemination following sponge removal.

Fixed time (once)	Between 43 and 46 hours after sponge removal
Fixed time (twice)	30 and 50 hours after sponge removal
Fixed time (laparoscopically)	48 to 52 hours after sponge removal
After oestrus detection	12 to 24 hours after the onset of oestrus

- Whether the doe can smell a buck or is being physically teased with a vasectomized or epididymectomised buck.

Although there is some breed variation, the doe typically ovulates between 19 and 23 hours after going out of heat. The optimum times for artificial insemination using frozen semen are shown in Table 1.12. Fixed time AI results in pregnancies but the rate is reduced when compared to insemination based on oestrus detection. Sufficient males should be available if natural mating is used in a synchronised herd, for example 1 male to 10 females during the breeding season and more for out-of-season breeding.

Conception rates during the transitory period or out-of-season will be lower than for mating within the breeding season. Fertility will improve closer to the start or end of the breeding season. Many factors can influence fertility including breed, age and weight of the doe, month of treatment, buck selection and management.

Because the sponges are not licensed for goats, there is no defined milk withhold period but synthetic progesterones like medroxyprogesterone are known to be excreted into the milk in large quantities whilst the sponge is in place and for at least 3 days afterwards.

Controlled internal drug release

Suitable progesterone-impregnated intravaginal controlled internal drug-releasing devices (CIDRs) are available in many countries, although at present not the UK, for oestrus synchronisation in goats. CIDRs, silicon rubber elastomers moulded over a nylon spine, are inserted into the vagina like a sponge and similarly

release a controlled amount of progesterone into the bloodstream, placing the treated does in the luteal phase of the oestrous cycle. The level of progesterone in milk from healthy goats after CIDR insertion for 19 days is similar to or less than those endogenously produced during dioestrus or pregnancy.

CIDRs available in the United States, Australia and New Zealand (Eazi-Breed CIDR, Zoetis) contain 0.3 g of a natural progesterone and similar timing and hormone regimes to sponges are used.

During the breeding season they are inserted and left in place for 14 to 18 days. The majority of does will be in oestrus approximately 48 hours after device removal. For AI using frozen semen, it is recommended that pregnant mare serum gonadotrophin (PMSG) 200 to 400 IU is given 48 hours before device removal. The use of vasectomised bucks is recommended prior to insemination. Insemination using a laparoscopic or cervical technique should be performed within 48 hours after device removal.

During the transitional periods, at the start and end of the breeding season, PMSG injections should be given at CIDR removal to help promote ovulation.

Out of season, if the does are not cycling, only a short period of progesterone is required to initiate follicle production. CIDRs are inserted for 7–9 days, followed by PMSG when the CIDR is removed. Breeding behaviour will likely occur without the PMSG, but the does do not ovulate and therefore the conception rate is very poor.

Outside the normal breeding season, buck fertility is usually much reduced. When using sponges and CIDRs, it is important to recognise this limitation and to use an increased male to female ratio, possibly with hand mating, or use AI. Reduced numbers of pregnancies and decreased numbers of feti/doe are common at this time. Does generally only cycle once, so failure to exhibit oestrus should not be used as an indicator of pregnancy.

Good record keeping will help improve conception rates using natural service and AI:

- Season of year/doe already cycling or not.
- Amount and type of chorionic gonadotropin given.
- Time of sponge or CIDR removal.
- Time to first signs of oestrus (hours).
- Time to end of oestrus; doe will no longer stand for buck (hours).
- Natural service or AI; fresh or frozen semen.
- Time AI carried out after sponge or CIDR removal (hours).

- Number of does confirmed pregnant.
- Number of progeny produced.

Melatonin

Animals measure day length using melatonin secreted during the hours of darkness by the pineal gland. In sheep, treatment with melatonin provides a short day/long night signal that will advance the breeding season. Goats appear to need exposure to long days, provided by artificial light, before they will respond to melatonin. Twenty hours of artificial light from 1 January for 60 days followed by a return to natural light, combined with melatonin treatment by subcutaneous implant, will advance the breeding season by 2 to 3 months. Males should be light-treated under the same regime as the females and their fertility may be further increased by melatonin treatment. The males should be removed from the herd at the start of the melatonin treatment and kept apart (out of sight, sound and smell) until they are reintroduced 35 to 40 days later. Fertile oestrus will occur from 2 to 6 weeks after the introduction of the males (i.e. from late April to June), with peak mating activity occurring 3 to 4 weeks after introduction (during May) and peak kidding during November.

If light treatment is not used, it is recommended that does should not be implanted before mid-May.

Melatonin can also be used in cashmere goats to delay the shedding of fleece, so obviating the need for winter shearing when weather conditions require goats to be housed and there is increased risk of post-shearing deaths.

Melatonin, 18 mg implant, s.c. behind ear

Further reading

General

- Bretzlaff, K.N. and Romano, J.E. (2001) Advanced reproductive techniques in goats. *Vet. Clin. North Amer., Food Anim. Pract.*, **17**, 421–434.
- Evans, G. and Maxwell, W.M.C. (1987) *Salomon's Artificial Insemination of Sheep and Goats*. Butterworths, London.
- Howe, P.A. (1984) Breeding problems in goats. *Proc. Univ. Sydney Post Grad. Comm. Vet. Sci.*, **73**, 511–514.
- Jackson, P. (2004) Aspects of reproduction in the doe goat. *Goat Vet. Soc. J.*, **20**, 9–12.
- Johnson, B.M., Nuti, L.C. and Wiltz, D. (1994) Ultrasonic examination of the caprine ovary. *Vet. Med., Food Anim. Pract.*, May, 477–480.
- Mews, A. (1981) Breeding and fertility in goats. *Goat Vet. Soc. J.*, **2** (2), 2–11.
- Noakes, D. (2003) Some aspects of normal and abnormal reproduction in goats. *Goat Vet. Soc. J.*, **19**, 14–22.
- Peaker, M. (1978) Gestation period and litter size in the goat. *Br. Vet. J.*, **134**, 379–383.
- Skelton, M. (1978) Reproduction and breeding of goats. *J. Dairy Sci.*, **61**, 994–1010.
- Ward, W.R. (1980) Some aspects of infertility in the goat. *Goat Vet. Soc. J.*, **1** (2), 2–5.

Caprine herpes virus

- Camero, M. *et al.* (2015) Caprine herpesvirus type 1 infection in goat: not just a problem for females. *Small Ruminant Res.*, **128**, 59–62.

Control of the breeding season

- Abecia, J.A., Forcada, F. and González-Bulnes, A. (2011) Pharmaceutical control of reproduction in sheep and goats. *Vet. Clin. North Am. Food Anim. Pract.*, **27** (1), 67–79.
- Abecia, J.A., Forcada, F. and González-Bulnes, A. (2012) Hormonal control of reproduction in small ruminants. *Anim. Reprod. Sci.*, **130**, 173–179.
- Corteel, J.M. *et al.* (1982) Research and development in the control of reproduction. In: *Proc. III Int. Conf. Goat Prod. and Dis.*, Arizona, **1982**, pp. 584–591.
- Evans, G., Holt, N., Pedrana, R.G. and Pemberton, D.H. (1987) Artificial breeding in sheep and goats. *Proc. Univ. Sydney Post Grad. Comm. Vet. Sci.*, **96**.
- Geary, M.R. (1982) Use of Chronogest sponges and PMSG. *Goat Vet. Soc. J.*, **3** (2), 5–6.
- Haibel, G.K. (1990) Out-of-season breeding in goats. *Vet. Clin. North Amer.: Food Anim. Pract.*, **6** (3), 577–583.
- Henderson, D.C. (1985) Control of the breeding season in sheep and goats. *In Practice*, **7**, 118–123.
- Henderson, D.C. (1987) Manipulation of the breeding season in goats – a review. *Goat Vet. Soc. J.*, **8** (1), 7–16.
- Leboeuf, B. *et al.* (2003) Efficacy of two types of vaginal sponges to control onset of oestrus, time of preovulatory LH peak and kidding rate in goats inseminated with variable numbers of spermatozoa. *Theriogenology*, **60** (7), 1371–1378.
- Rowe, J.D. *et al.* (2010) Progesterone milk residues in goats treated with CIDR-G(®) inserts. *J. Vet. Pharmacol. Ther.*, **33** (6), 605–609.

Fetal age determination and sexing

- Amer, H.A. (2010) Ultrasonographic assessment of early pregnancy diagnosis, fetometry and sex determination in goats. *Anim. Reprod. Sci.*, **117** (3–4), 226–231.

Haibel, G.K., Perkins, N.R. and Lidi, G.M. (1989) Breed differences in biparietal diameters of second trimester Toggenburg, Nubian and Angora goat fetuses. *Theriogenology*, **32** (5), 827–834.

Santos, M.H.B *et al.* (2007) Early fetal sexing of Saanen goats by use of transrectal ultrasonography to identify the genital tubercle and external genitalia. *AJVR*, **68**, 561–564.

Hydrometra

Hesselink, J.W. (1993) Incidence of hydrometra in dairy goats. *Vet. Rec.*, **132**, 110–112.

Hesselink, J.W. (1993) Hydrometra in dairy goats: reproductive performance after treatment with prostaglandins. *Vet. Rec.*, **133**, 186–187.

Pieterse, M.C. and Taverne, M.A.M. (1986) Hydrometra in goats: diagnosis with realtime ultrasound and treatment with prostaglandins or oxytocin. *Theriogenology*, **26**, 813–821.

Souza, J.M.G. *et al.* (2013) Hormonal treatment of dairy goats affected by hydrometra associated or not with ovarian follicular cyst. *Small Ruminant Res.*, **111** (1–3), 104–109.

Hydrops uteri

Jones, S.L. and Fecteau, G. (1995) Hydrops uteri in a caprine doe pregnant with Goat–sheep hybrid fetuses. *JAVMA*, **206** (12), 1920–1922.

Morin, D.E., Hornbuckle, T., Rowan, L.L. and Whiteley, H.E. (1994) Hydrallantois in a caprine doe. *JAVMA*, **204** (1), 108–111.

Intersexes

Hamerton, J.L., Dickson, J.M., Pollard, C.E., Grieves, S.A. and Short, R.V. (1969) Genetic intersexuality in goats. *J. Reprod. Fert. Suppl.*, **7**, 25–51.

Laparoscopy

Van Reven, G. (1988) Laparoscopy in goats. *Goat Vet. Soc. J.*, **9** (1/2), 24–32.

Ultrasonography

DesCôteaux, L. (ed.) (2010) *Practical Atlas of Ruminant and Camelid Reproductive Ultrasonography*, pp. 181–199. Wiley-Blackwell, Iowa.

Erdogan, G. (2012) Ultrasonic assessment during pregnancy in goats – a review. *Reprod. Domestic Animals*, **47**, 157–163.

Rowe, J.D. (2014) Use of reproductive ultrasound for goat herd management. *AABP Proceedings*, **47**, 104–107.