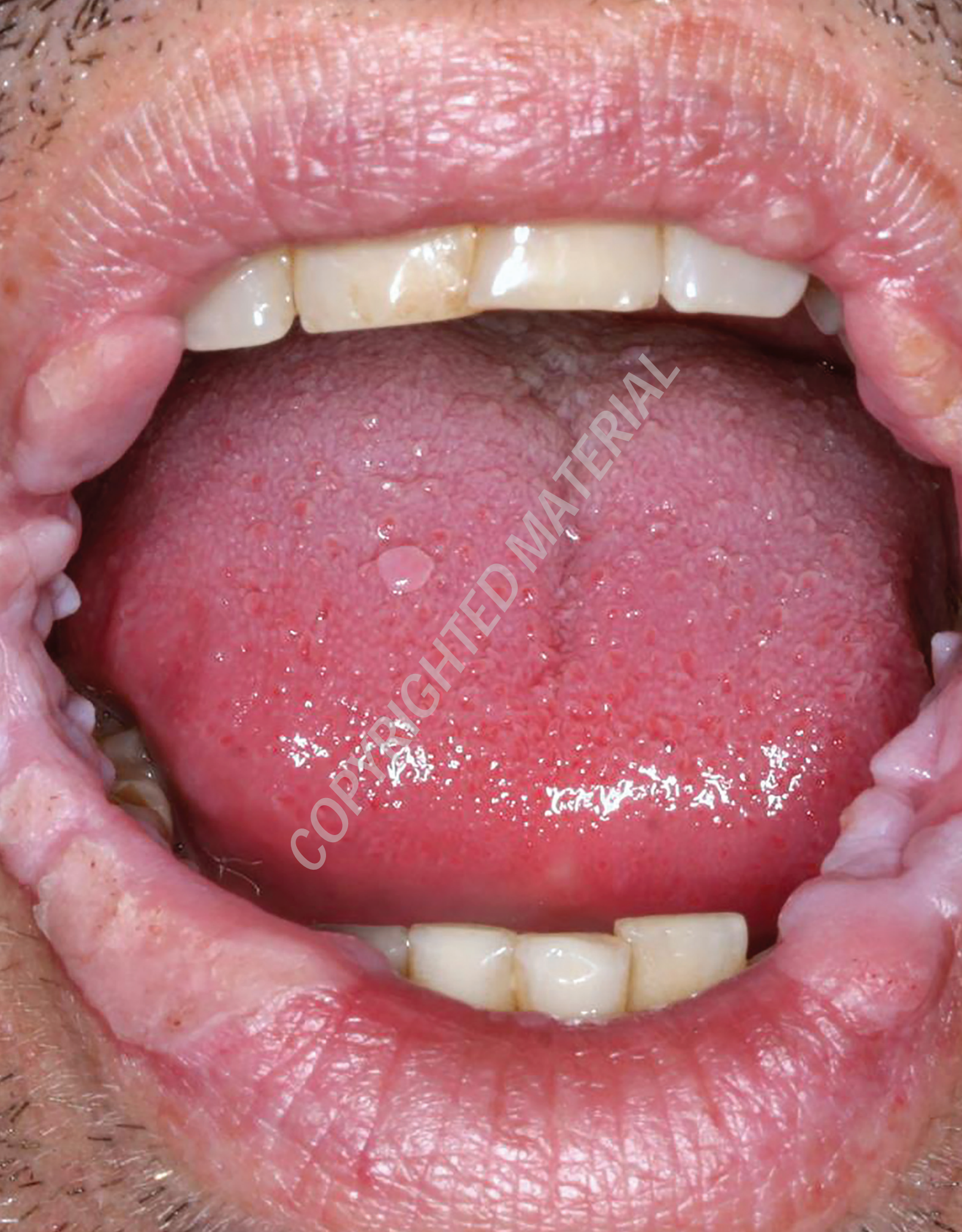



1

Examination of extraoral tissues

Figure 1.1 Cerebral palsy head.

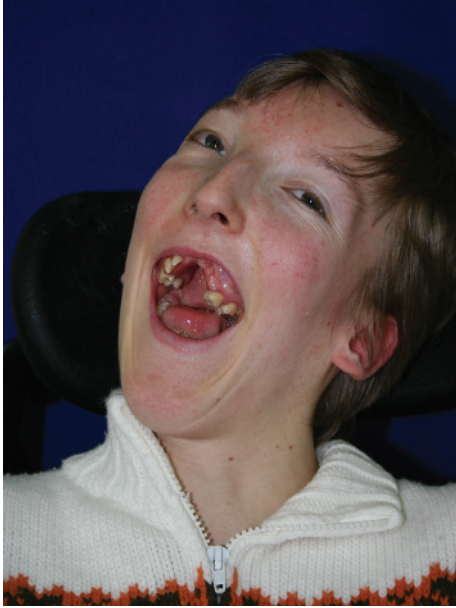

Figure 1.2 Hereditary hemorrhagic telangiectasia.

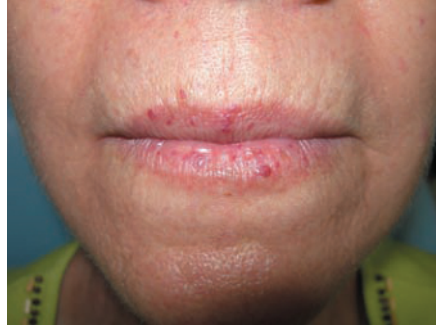

Figure 1.3 Cutaneous odontogenic fistula.

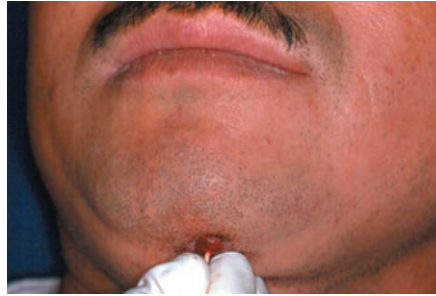

Figure 1.4a Lipoma.

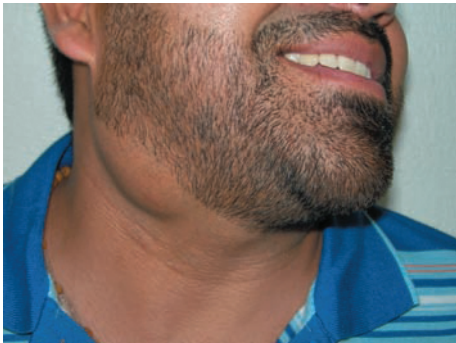

Figure 1.4b Scan of lipoma (arrow on lesion).

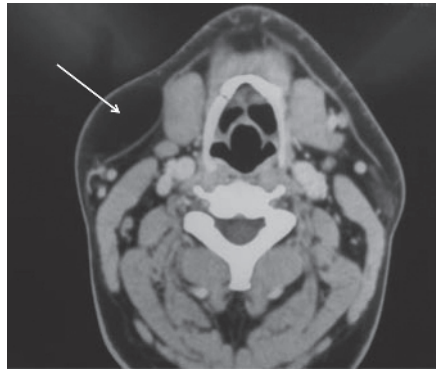


Figure 1.5 Hereditary hemorrhagic telangiectasia (same patient as in Figure 1.2).

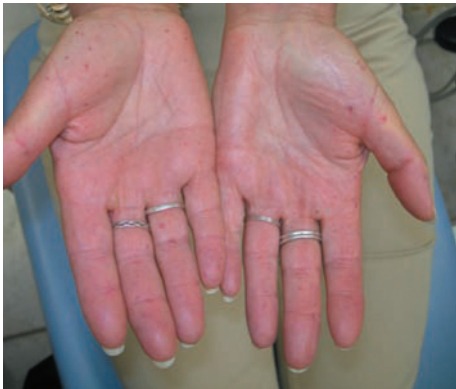
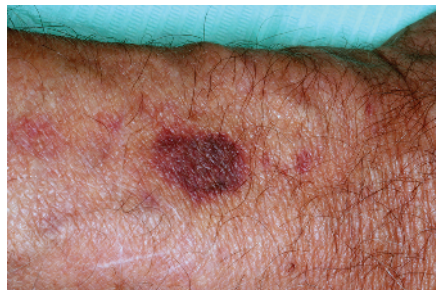
Figure 1.6 Purpura on arm.



This book does not include the basics of history taking, only specific relevant points in the text. *Bear in mind that the history gives the diagnosis in about 80% of cases.*

Following the history, during which the clinician will note the patient's conscious level, any anxiety, appearance, communication, posture, breathing, movements, behavior, sweating, weight loss or wasting (Figure 1.1), physical examination is indicated. This necessitates touching the patient; therefore, informed consent and confidentiality are required, a chaperone available, and religious and cultural aspects should be borne in mind (see Scully and Wilson).

Relevant medical problems may even be manifest in the fully clothed patient – where changes affect the head and neck, cranial nerves, or limbs. Therefore, while there is no rigid system for examination, the clinician should ensure that these areas are checked.

Head and neck

Pupil size should be noted (e.g. dilated in anxiety or cocaine abuse, constricted in heroin abuse).

Facial color should be noted:

- pallor (e.g. anemia)
- rashes (e.g. viral infections, lupus) (Figure 1.2)
- erythema (e.g. anxiety, alcoholism, polycythemia)

Swellings, sinuses or fistulas should be noted (Figure 1.3).

Facial symmetry is examined for evidence of enlarged masseter muscles (masseteric hypertrophy) suggestive of clenching or bruxism.

Neck swellings should be elicited, followed by careful palpation of lymph nodes (and salivary and thyroid glands), searching for swelling and/or tenderness, by observing the patient from in front, noting any obvious asymmetry or swelling (Figure 1.4a and b), then standing behind the seated patient to palpate the nodes. Systematically, each region needs to be examined lightly with the pulps of the fingers, trying to roll the nodes against harder underlying structures.

Some information can be gained by the texture and nature of the lymphadenopathy; nodes that are tender may be inflammatory (lymphadenitis), while those that are increasing in size and are hard, or fixed to adjacent tissues, may be malignant.

Cranial nerves

The cranial nerves should be examined, in particular facial movement and corneal reflex should be tested and facial sensation determined (Table 1.1). Movement of the mouth as the patient speaks is important, especially when they allow themselves the luxury of some emotional expression.

Facial movement is tested out by asking the patient to:

- close their eyes; any palsy may become obvious, with the affected eyelid failing to close and the globe turning up so that only the white of the eye shows (Bell sign)
- close their eyes tightly against your attempts to open them, and note the degree of force required to part the eyelids
- wrinkle their forehead, and check any difference between the two sides
- smile
- bare the teeth or purse the lips
- blow out the cheeks
- whistle

The muscles of the upper face (around the eyes and forehead) are bilaterally innervated and thus loss of wrinkles on one-half of the forehead or absence of blinking suggests a lesion in the lower motor neurone.

Table 1.1 Cranial nerve examination.

Cranial nerve	Examination
I Olfactory	Sense of smell for common odors
II Optic	Visual acuity (Snellen types ± ophthalmoscopy); nystagmus Visual fields (by confrontation) Pupil responses to light and accommodation
III Oculomotor	Eye movements Pupil responses
IV Trochlear	Eye movements
V Trigeminal	Sensation over face ± corneal reflex ± taste sensation Motor power of masticatory muscles; jaw jerk
VI Abducens	Eye movements
VII Facial	Motor power of facial muscles Corneal reflex ± taste sensation
VIII Vestibulocochlear	Hearing (tuning fork at 256 Hz) Balance
IX Glossopharyngeal	Gag reflex Taste sensation
X Vagus	Gag reflex
XI Accessory	Motor power of trapezius and sternomastoid
XII Hypoglossal	Motor power of tongue

Corneal reflex depends on the integrity both of the trigeminal and facial nerves – a defect of either will give a negative response. This is tested by gently touching the cornea with a wisp of cotton wool twisted to a point. Normally, this procedure causes a blink but, provided that the patient does not actually see the cotton wool, no blink follows if the cornea is anesthetic from a lesion involving the ophthalmic division of the trigeminal nerve, or if there is facial palsy.

Facial sensation is tested by determining the response to light touch (cotton wool) and pin-prick (gently pricking the skin with a sterile pin, probe or needle without drawing blood). It is important to test sensation in all parts of the facial skin but the most common defect is numb chin, due to a lesion affecting the mandibular division of the trigeminal.

Occasionally, a patient complains of hemifacial or complete facial hypoesthesia (reduced sensation) or anesthesia (complete loss of sensation). If the corneal reflex is retained or there is apparent anesthesia over the angle of the mandible (an area not innervated by the trigeminal nerve), then the symptoms are probably functional (non-organic, i.e. psychogenic).

Limbs

Hands may reveal rashes (Figure 1.5), purpura (Figure 1.6), pigmentation or conditions such as arthritis and Raynaud phenomenon. Finger clubbing may reveal systemic disease. Nail changes may reveal anxiety (nail biting), or disease such as koilonychia (spoon-shaped nails), in iron deficiency.

The operator should then ensure that all relevant oral areas are examined, in a systematic fashion.

Reference

Scully C and Wilson N (2006). *Culturally Sensitive Oral Healthcare*. Quintessence, London.