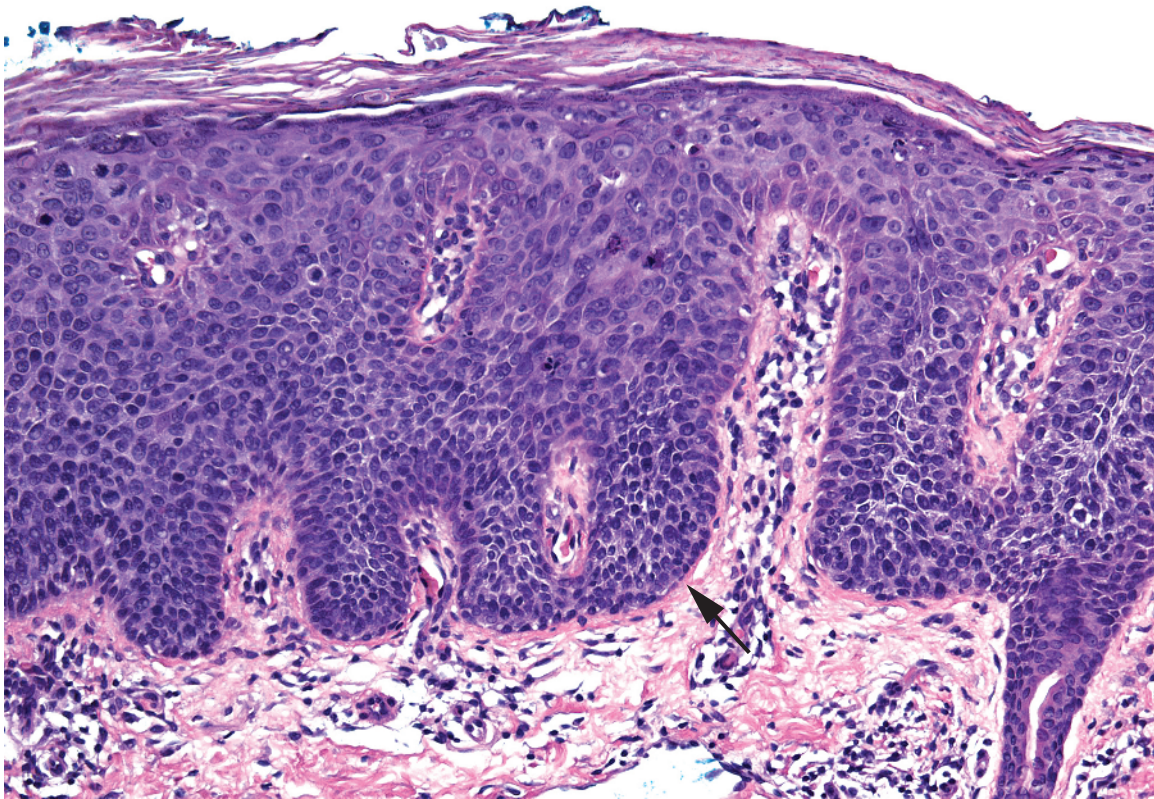
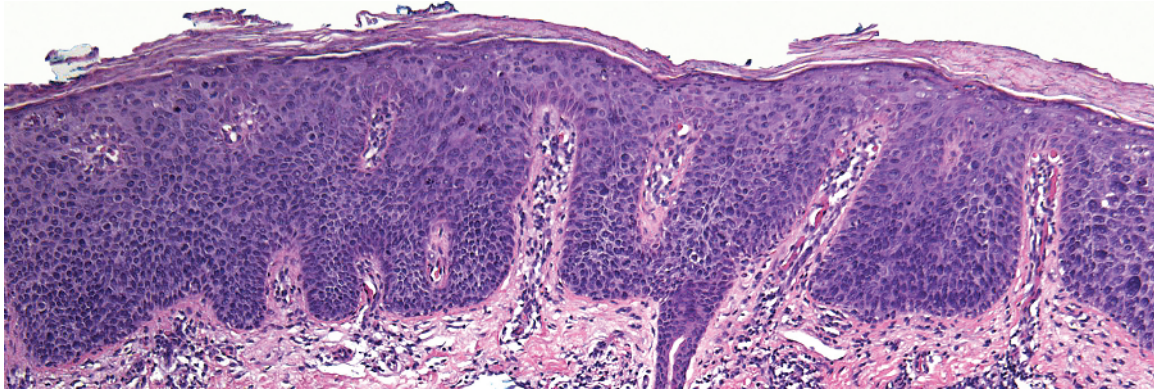

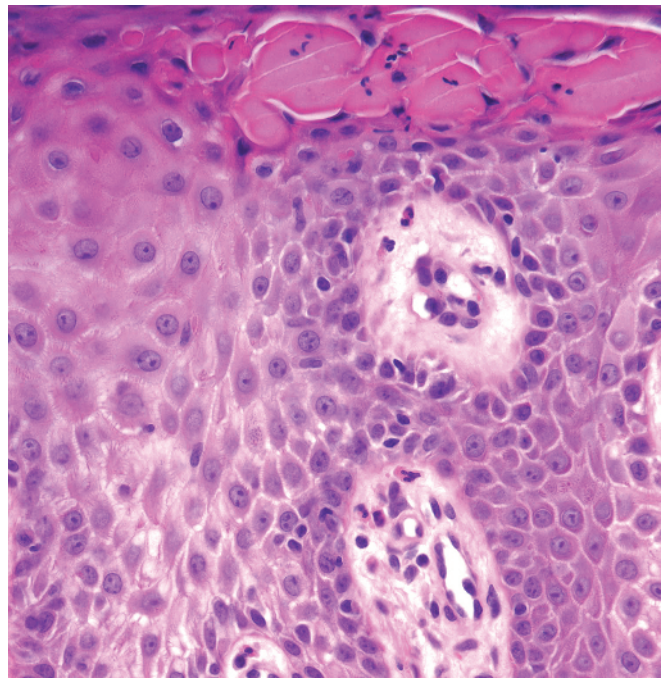
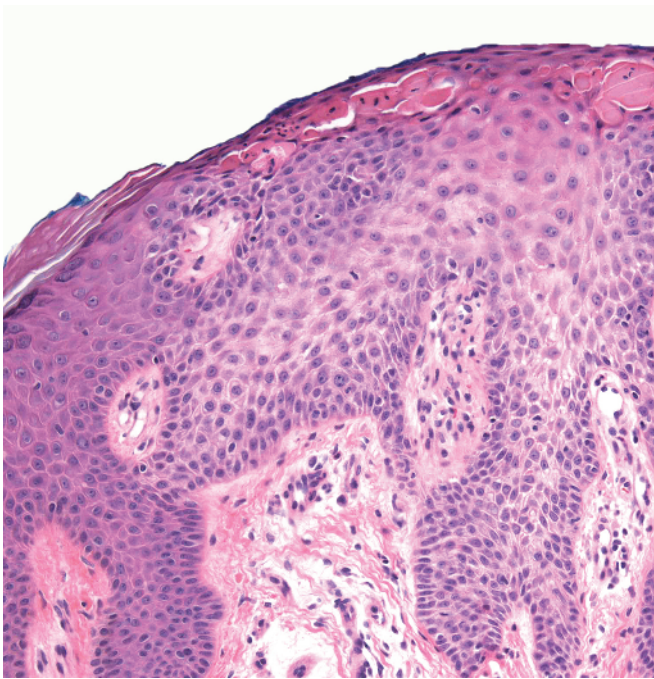
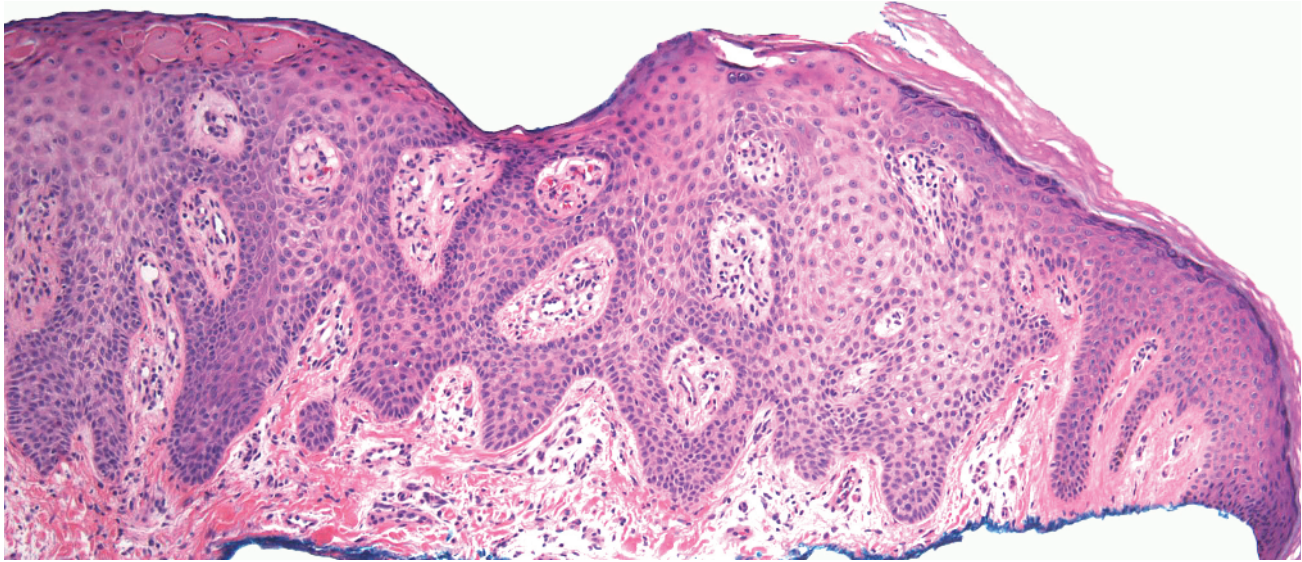
1

Shape on Low Power

- Epidermis
 - Regular acanthosis, 25
 - Lobular proliferation, 29
 - Reticulated proliferation, 35
 - Central pore, 42
 - Epidermal perforation, 46
- Dermis
 - Circular islands, 49
 - Cords/tubules and comma shapes, 53
 - Space with a lining, 59
 - Papillations, 70
 - Polypoid (dome-shaped), 77
 - Square/rectangular, 82
 - Palisading reactions, 88
 - Pseudoepitheliomatous hyperplasia above abscesses, 93
 - Pink ball (see Chapter 6)

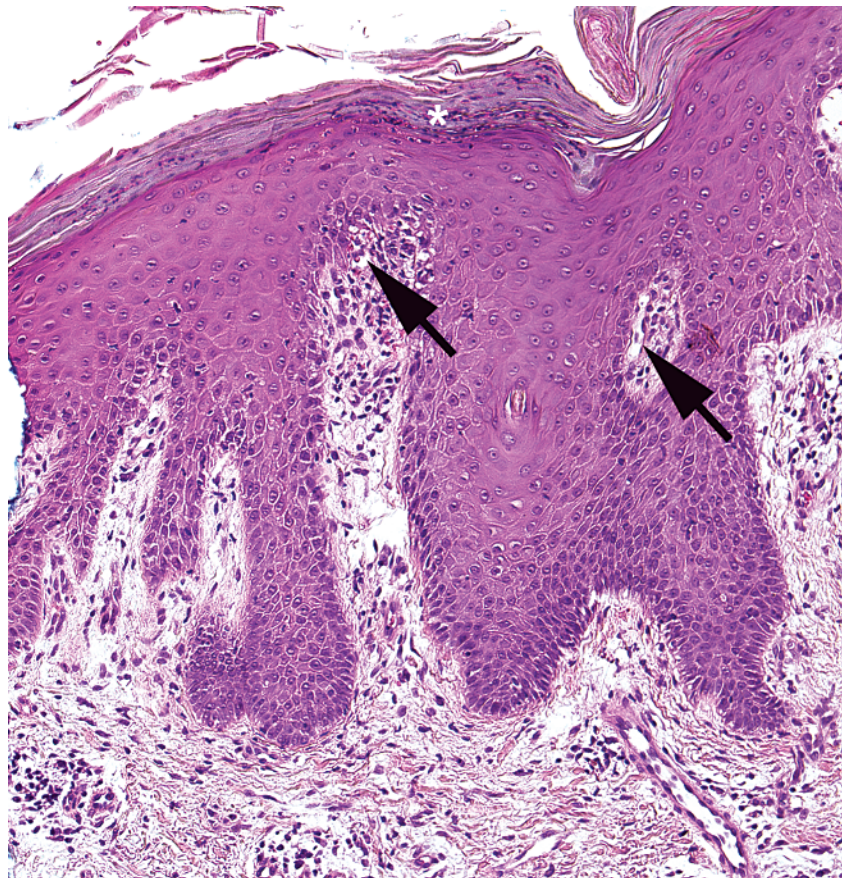
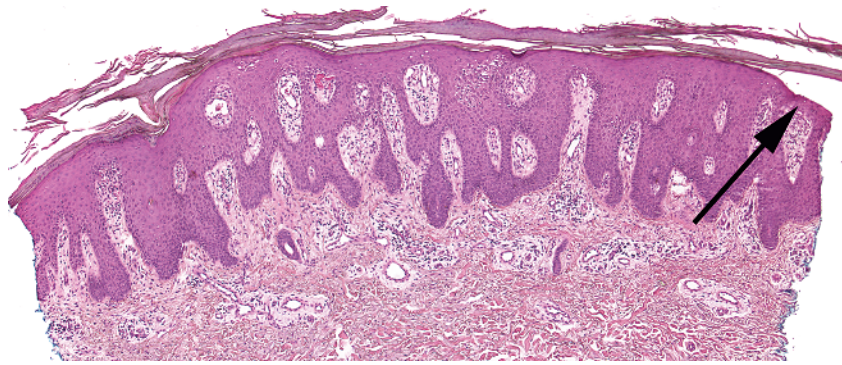


-
- Epidermal acanthosis
 - Parakeratosis
 - Full-thickness disorder of keratinocytes with atypical cells and mitoses
 - Basal layer may focally appear normal ("eyeliner" sign) (arrow)

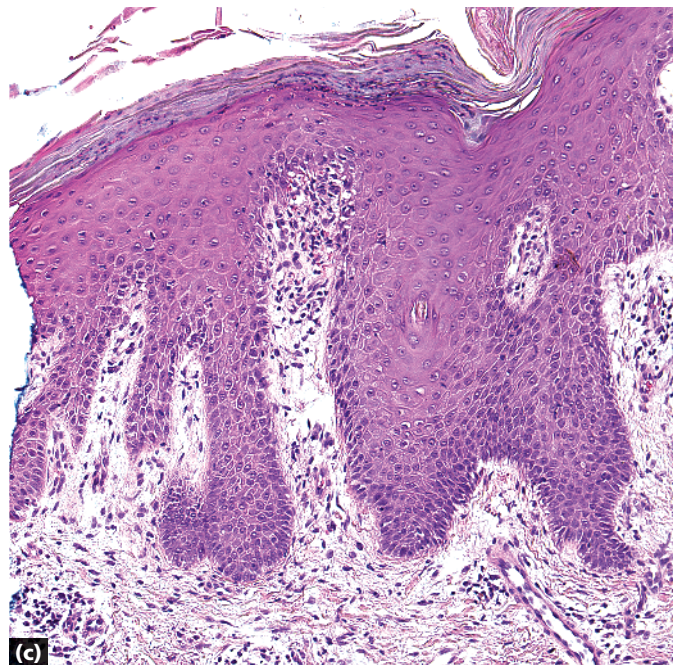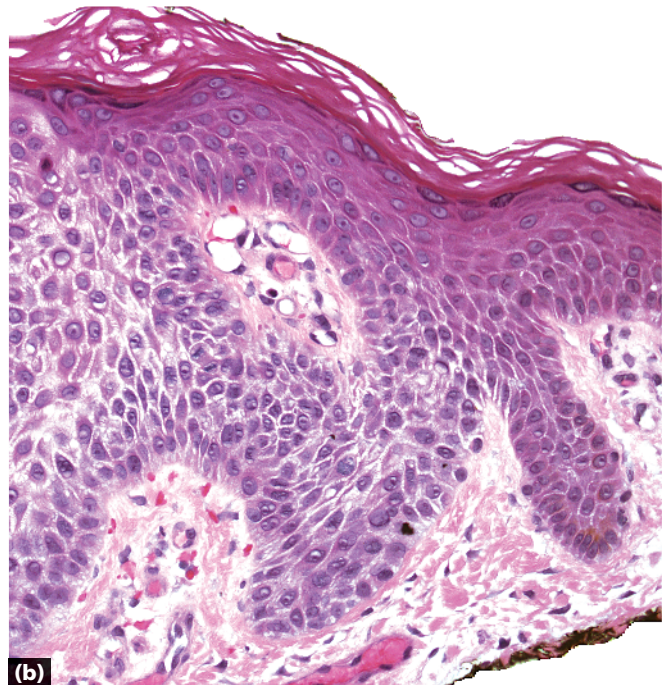
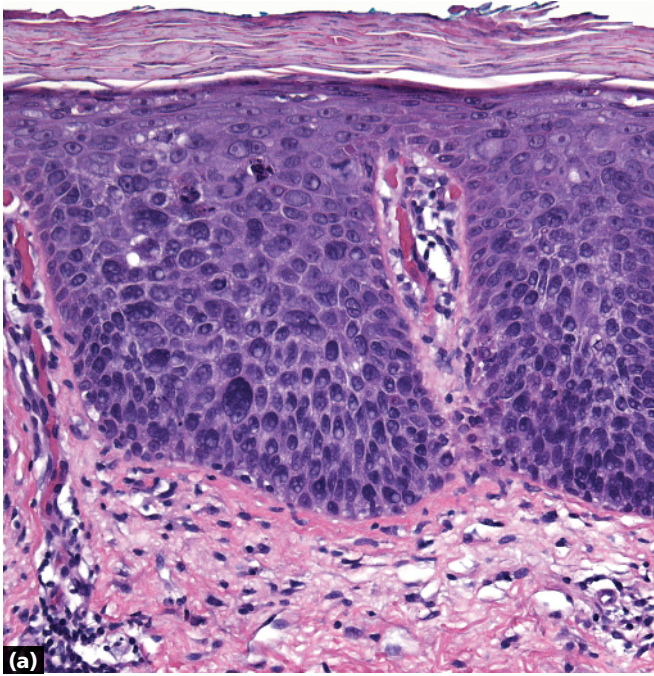


-
- Epidermal acanthosis
 - Clear cells well-demarcated from the normal epidermis and adnexal keratinocytes
 - Parakeratosis above clear cells

Clear cell acanthoma

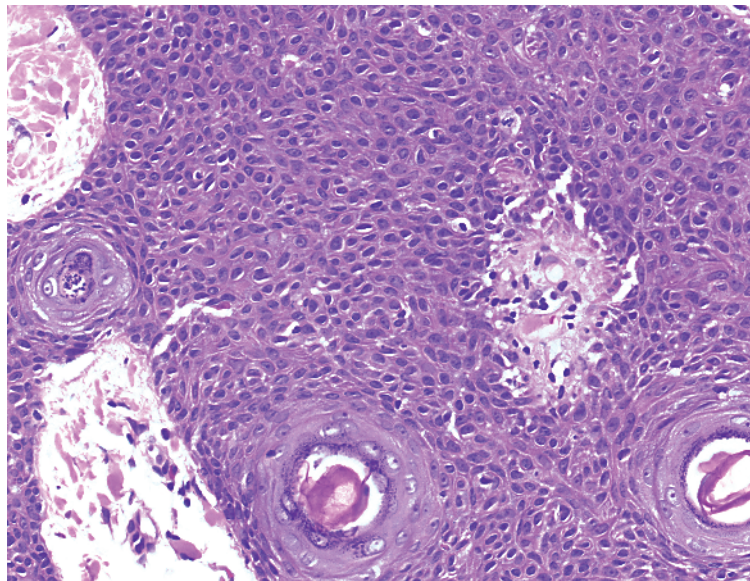
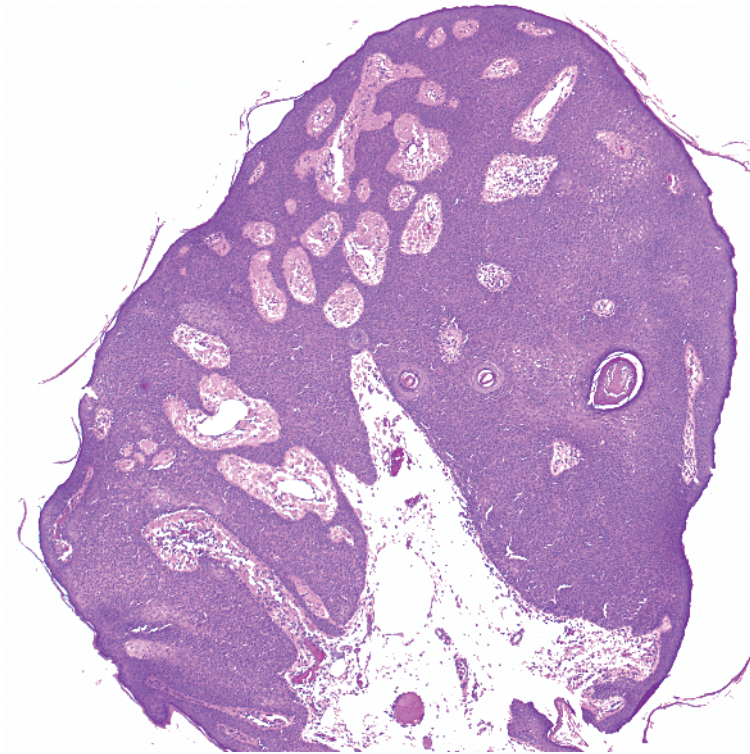


-
- Epidermal acanthosis
 - Parakeratosis
 - Neutrophils in stratum corneum (asterisk)
 - Hypogranulosis
 - Thinned suprapapillary plates (long arrow)
 - Dilated vessels in papillary dermis (short arrows)

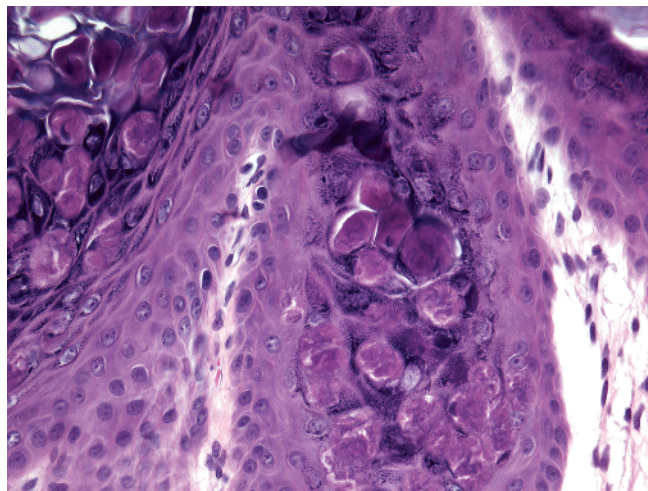
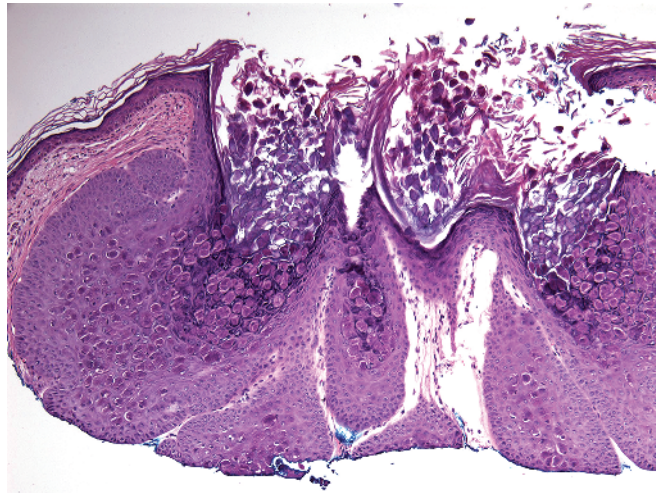
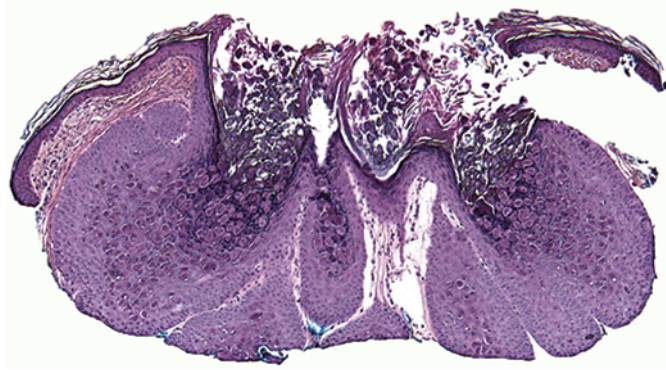


- a** Bowen disease: disordered keratinocytes and atypical mitoses
- b** Clear cell acanthoma: pale/clear keratinocytes well-demarcated from normal epidermis
- c** Psoriasis: confluent parakeratosis above thickened epidermis, neutrophils in stratum corneum, normal keratinocytes, thin suprapapillary plates, dilated vessels

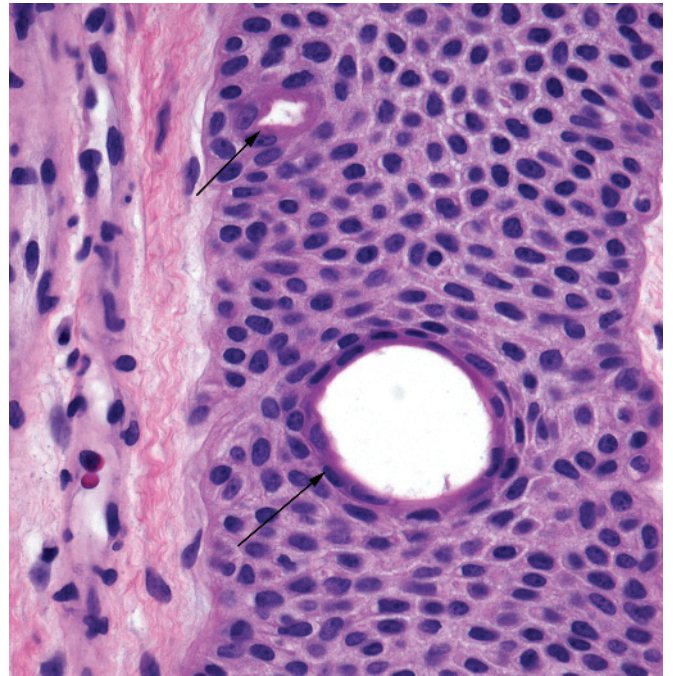
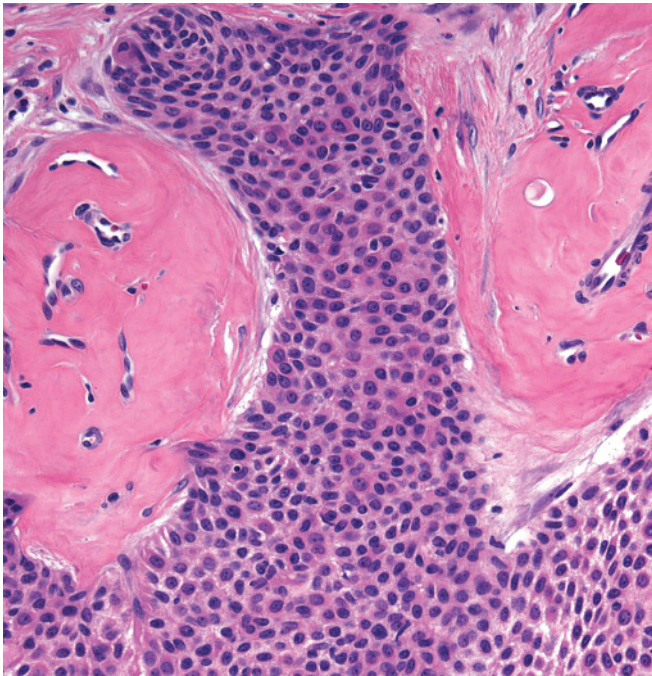
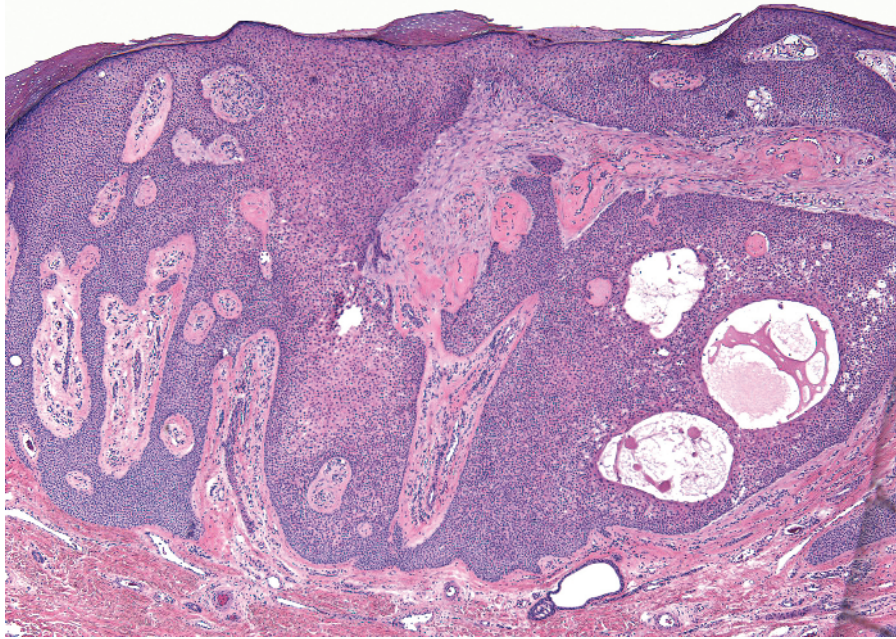
Key differences



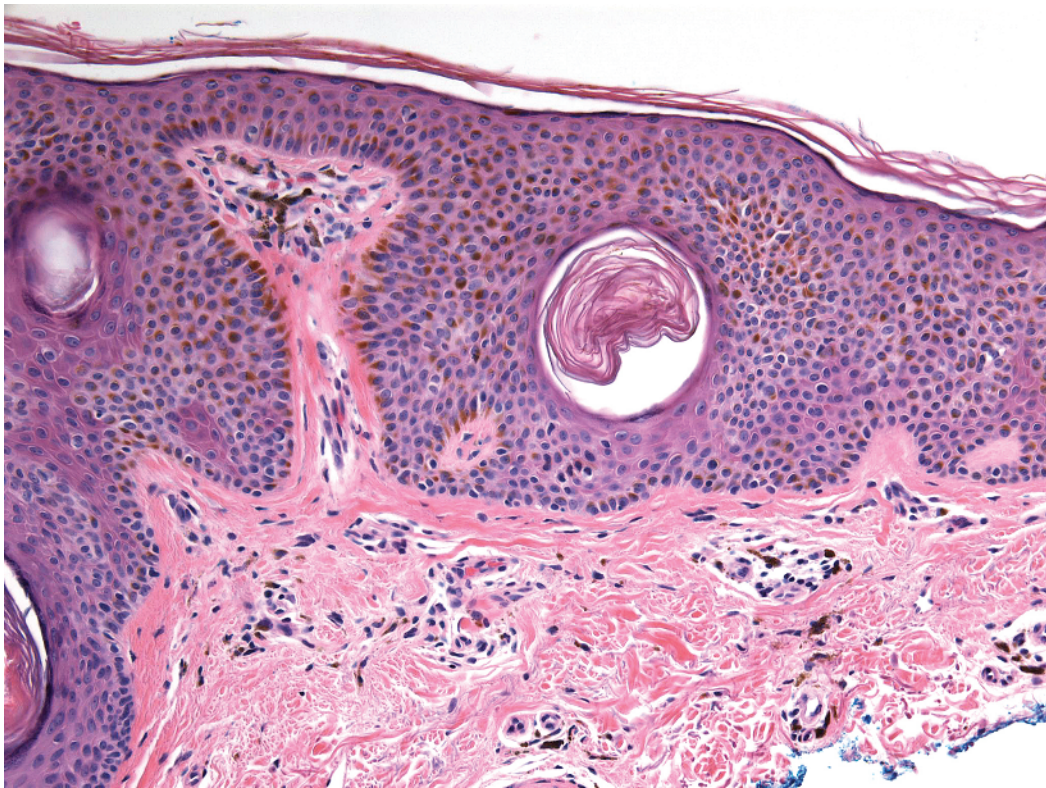
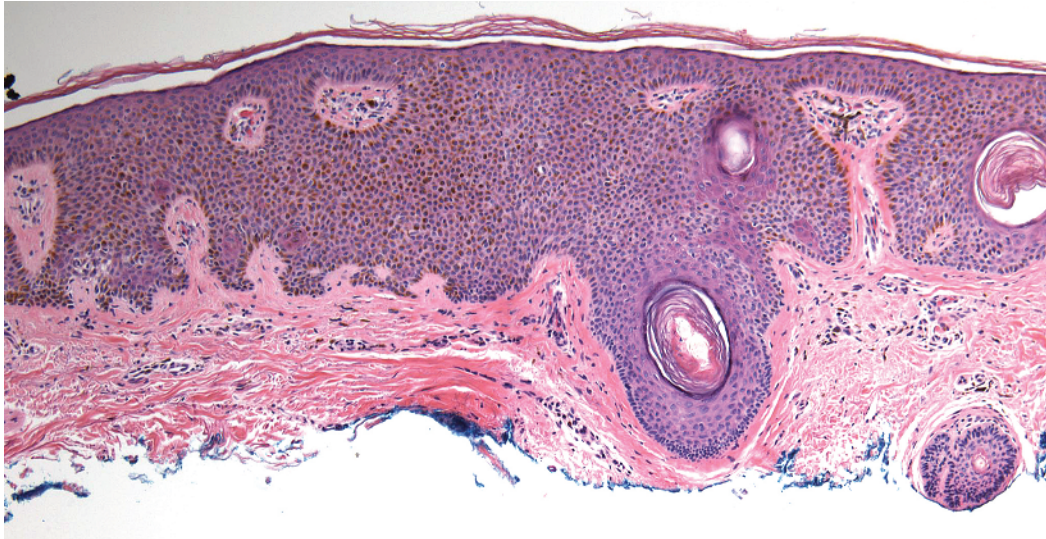
-
- Lobular proliferation
 - Normal-appearing keratinocytes with some arranged in squamous eddies



-
- Lobular proliferation
 - Blue-gray hue to some of the keratinocytes
 - Large, pink cytoplasmic inclusions (Henderson-Paterson bodies)

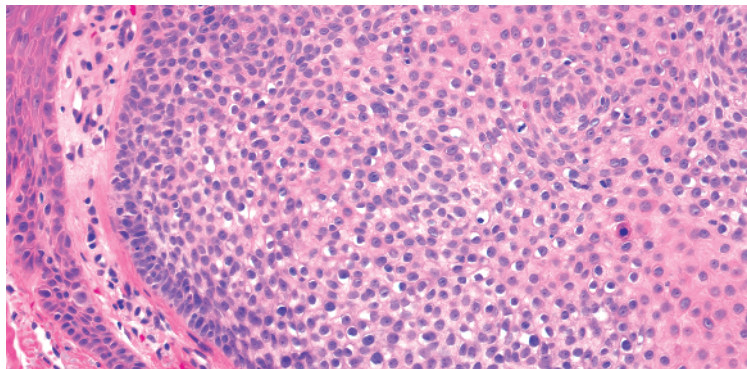
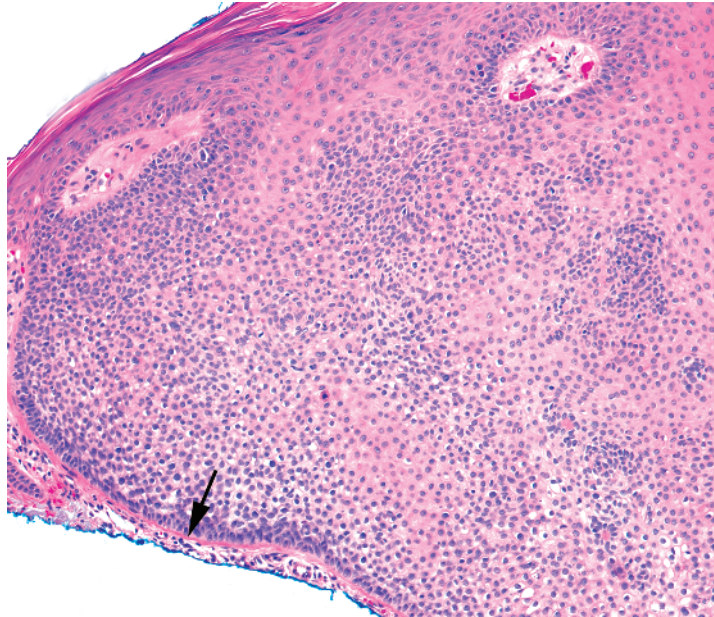
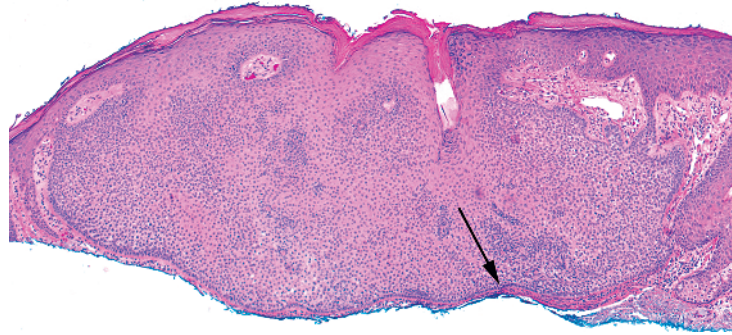


- Lobular proliferation (can be reticulated)
- Uniform blue cells with interspersed ducts (arrows)
- Fibrotic or hyalinized stroma with dilated vessels

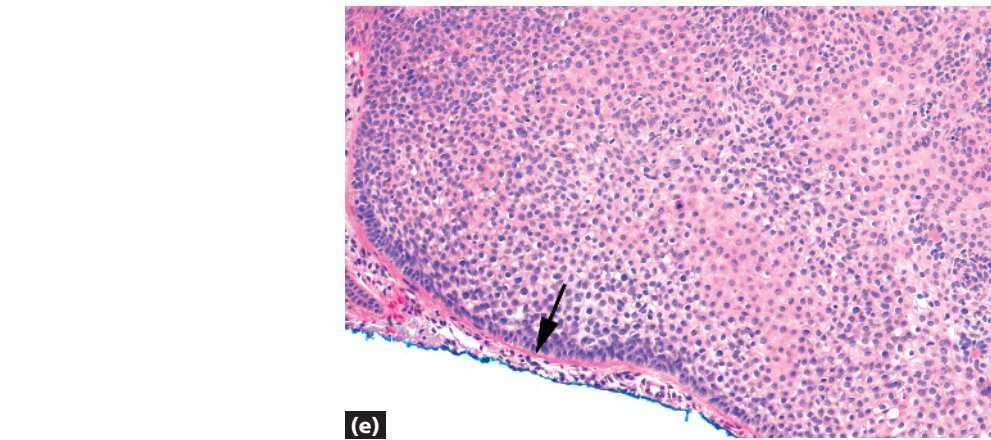
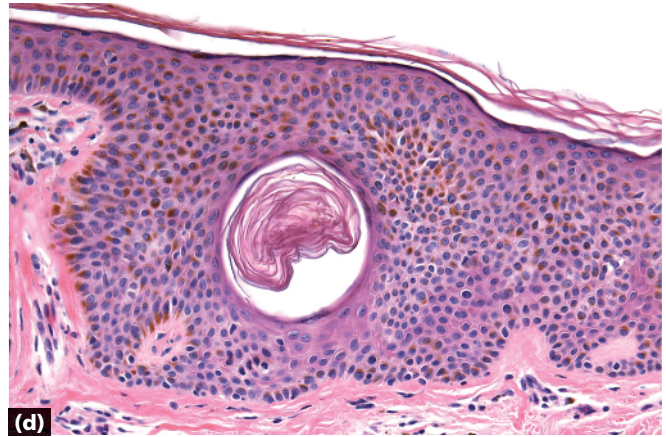
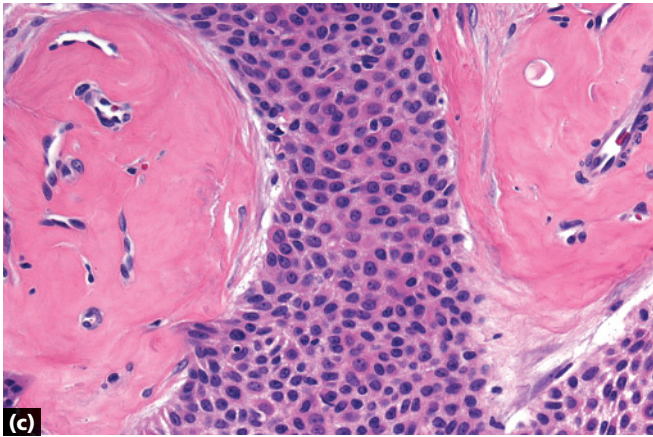
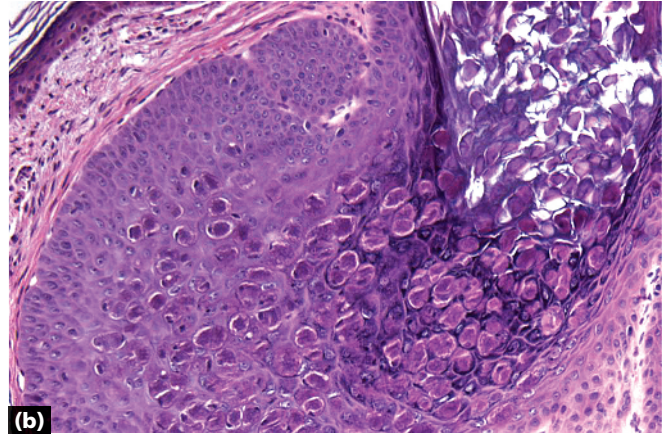
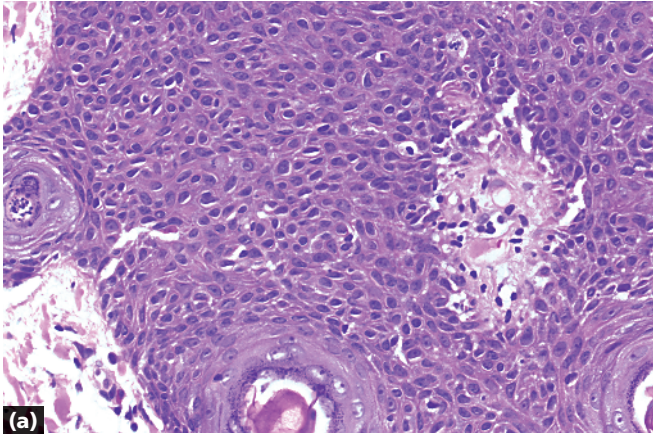


-
- Lobular proliferation
 - Acanthosis of epidermis
 - Pseudohorn cysts
 - No ducts

Seborrheic keratosis, acanthotic



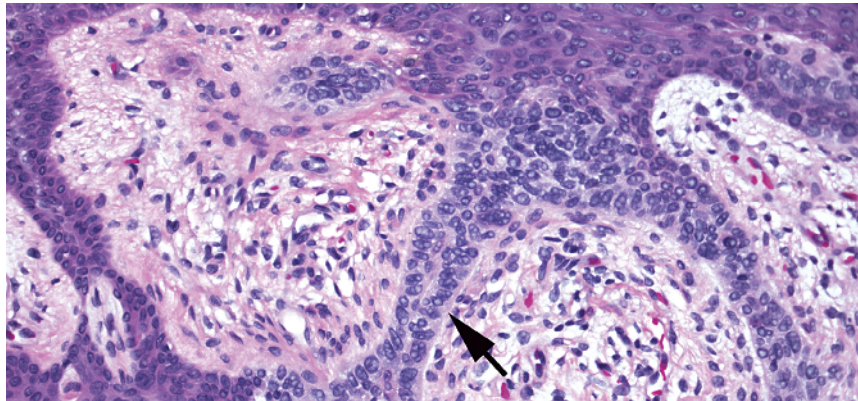
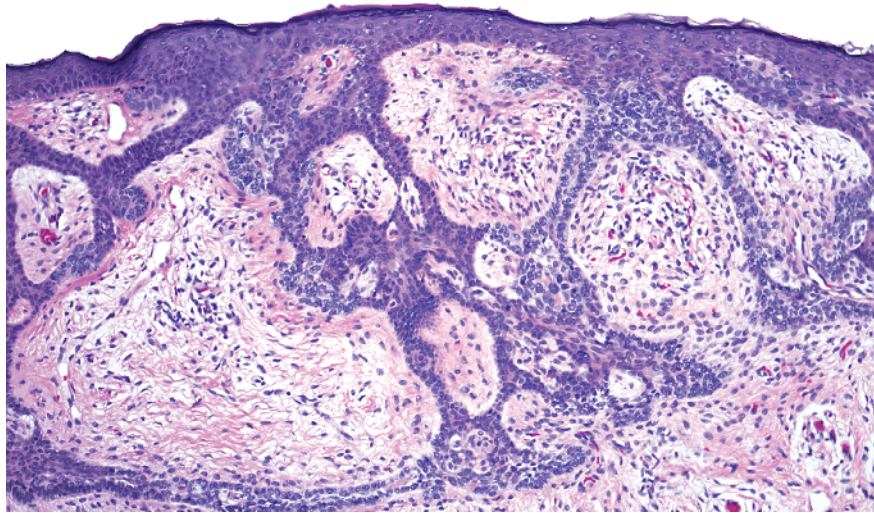
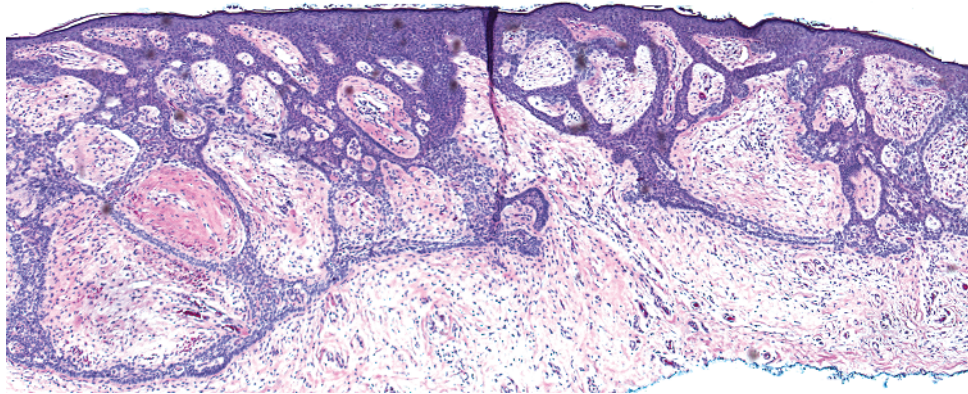
- Lobular proliferation
- Proliferation composed of pale/clear cells
- Peripheral palisading (long arrow) with thickened basement membrane (short arrow)



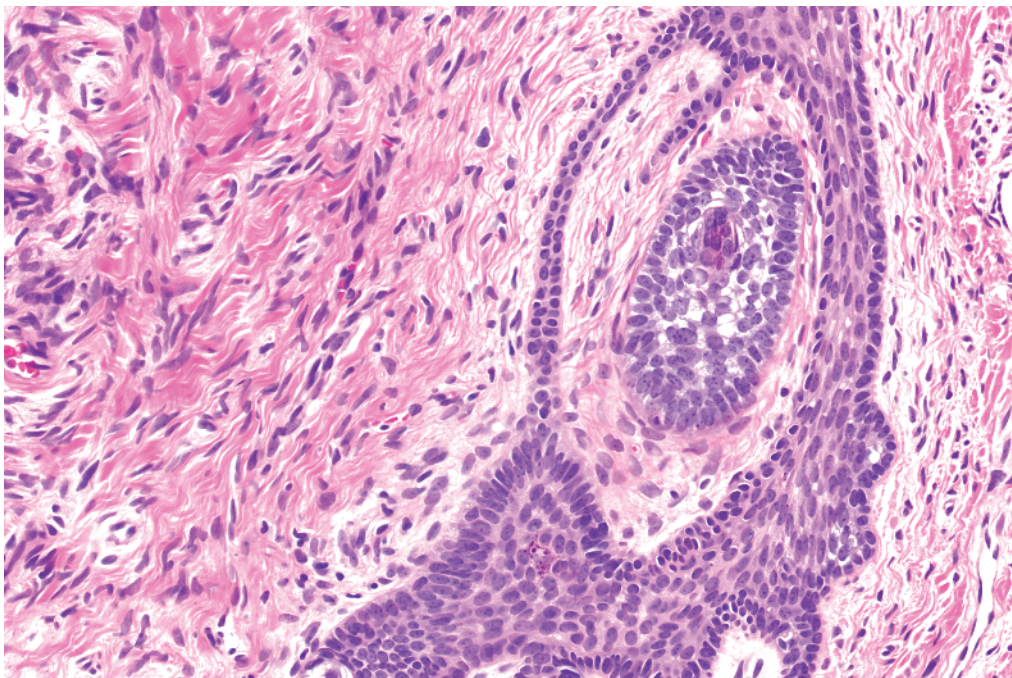
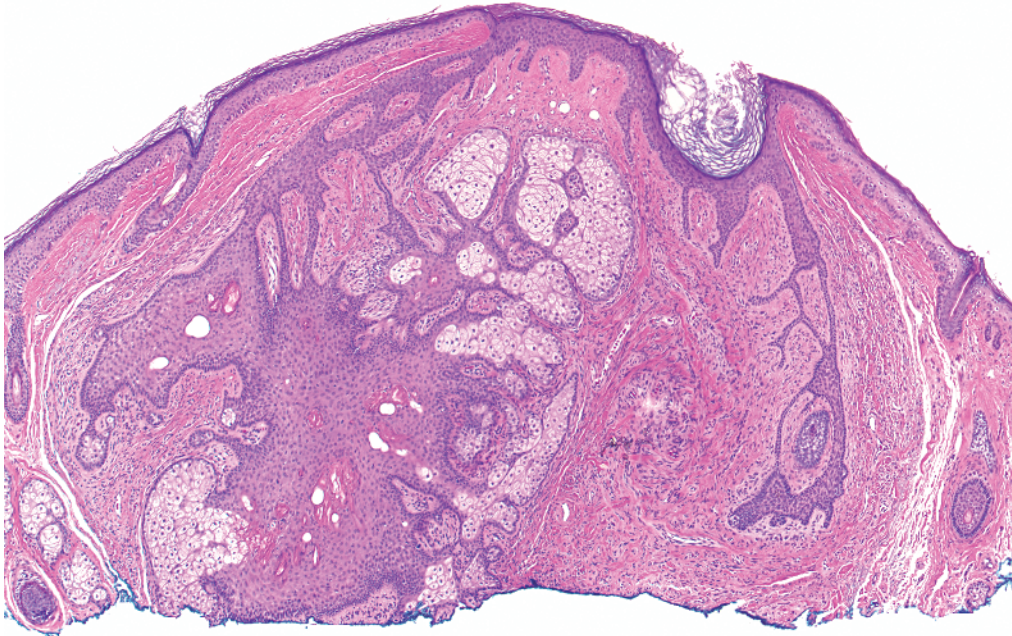
- a** Inverted follicular keratosis: squamous eddies of normal keratinocytes
- b** Molluscum contagiosum: intracytoplasmic pink inclusions (Henderson-Paterson bodies)
- c** Poroma: uniform blue cells with interspersed ducts, hyalinized stroma

- d** Seborrheic keratosis: pseudohorn cysts
- e** Trichilemmoma: pale/clear keratinocytes with peripheral palisading and thickened basement membrane

Key differences

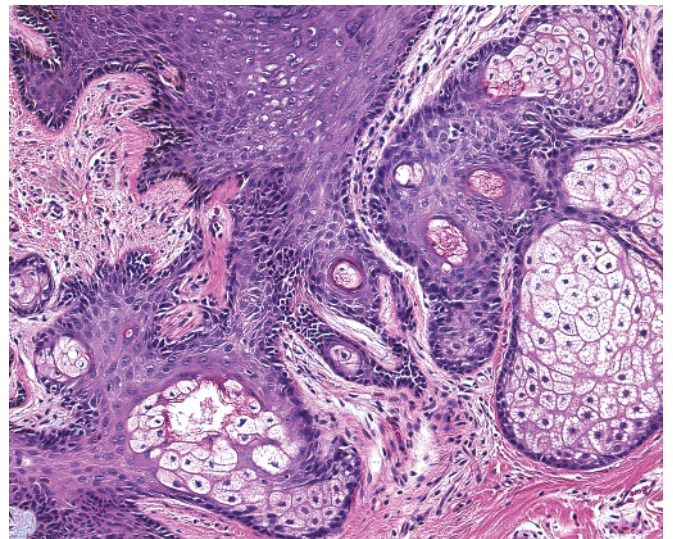
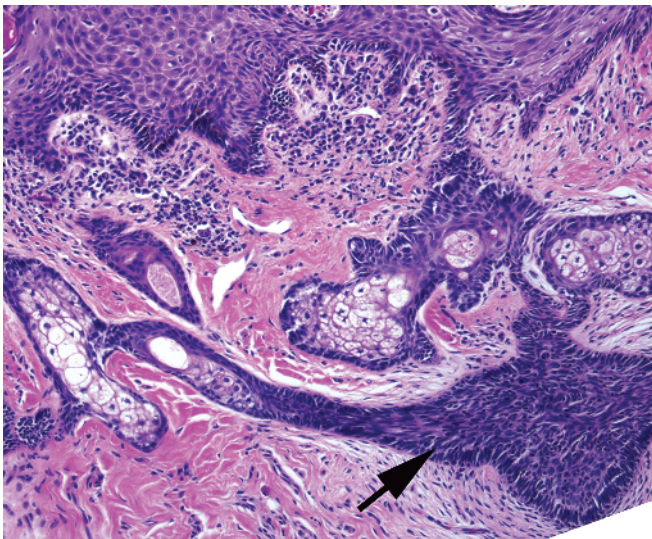
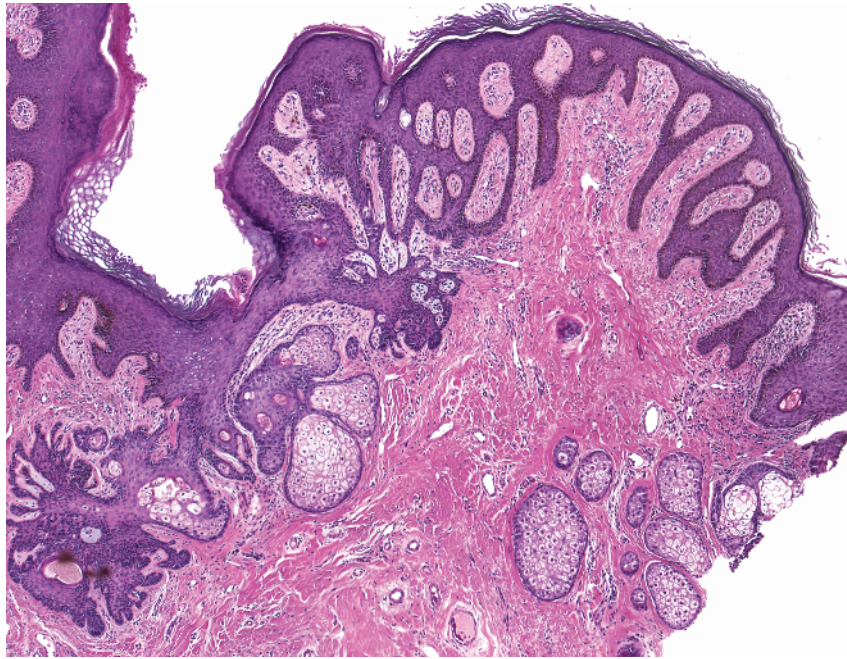


-
- Reticulated proliferation
 - Strands of basaloid cells in a fibrovascular stroma
 - Some hints of palisading of cells (arrow)

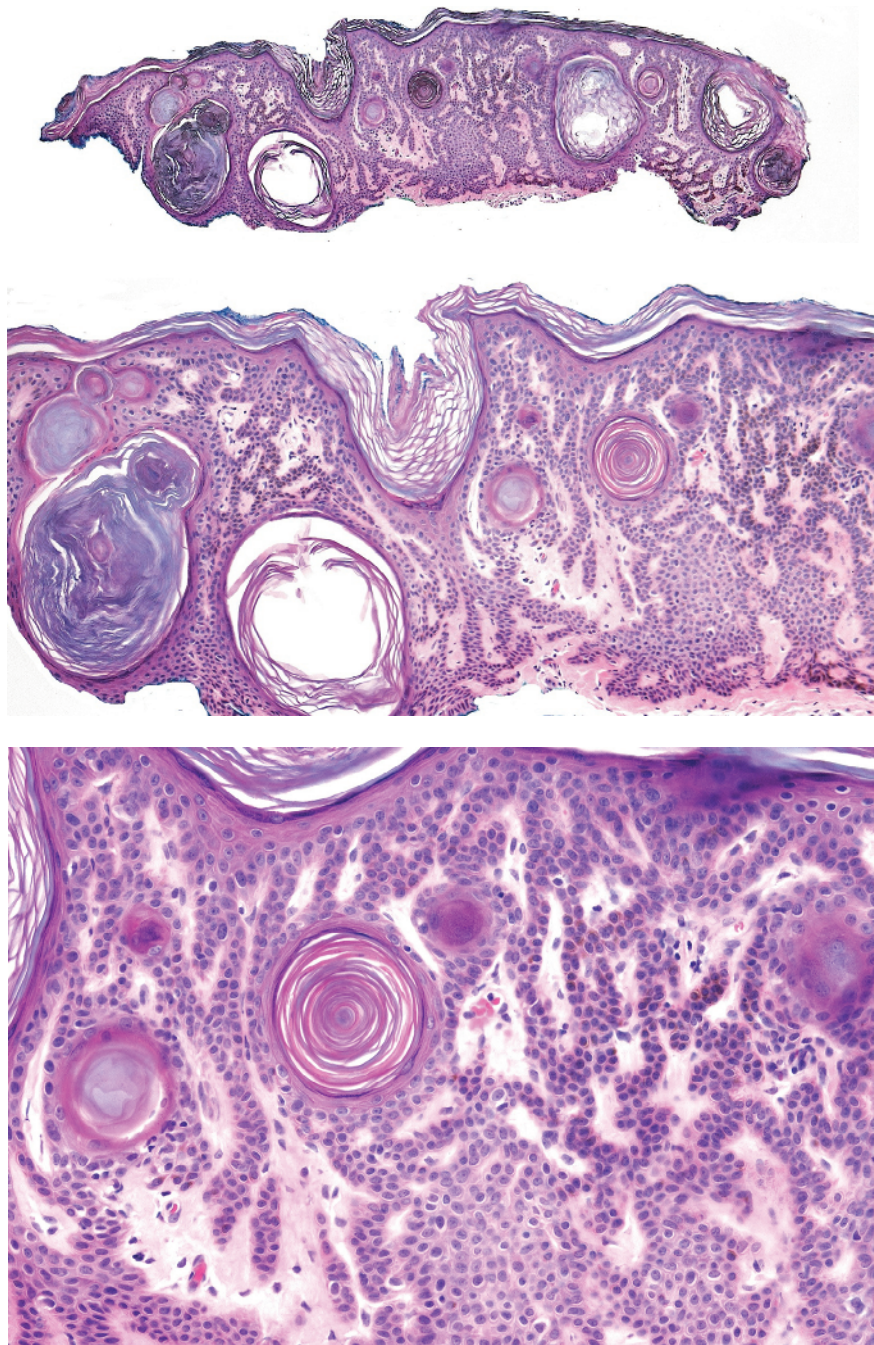


-
- Reticulated proliferation
 - Fibrotic stroma adjacent to the hair follicle has reticulated strands of epithelium
 - This entity has overlap with trichodiscoma (most consider these a spectrum of the same entity)

Fibrofolliculoma

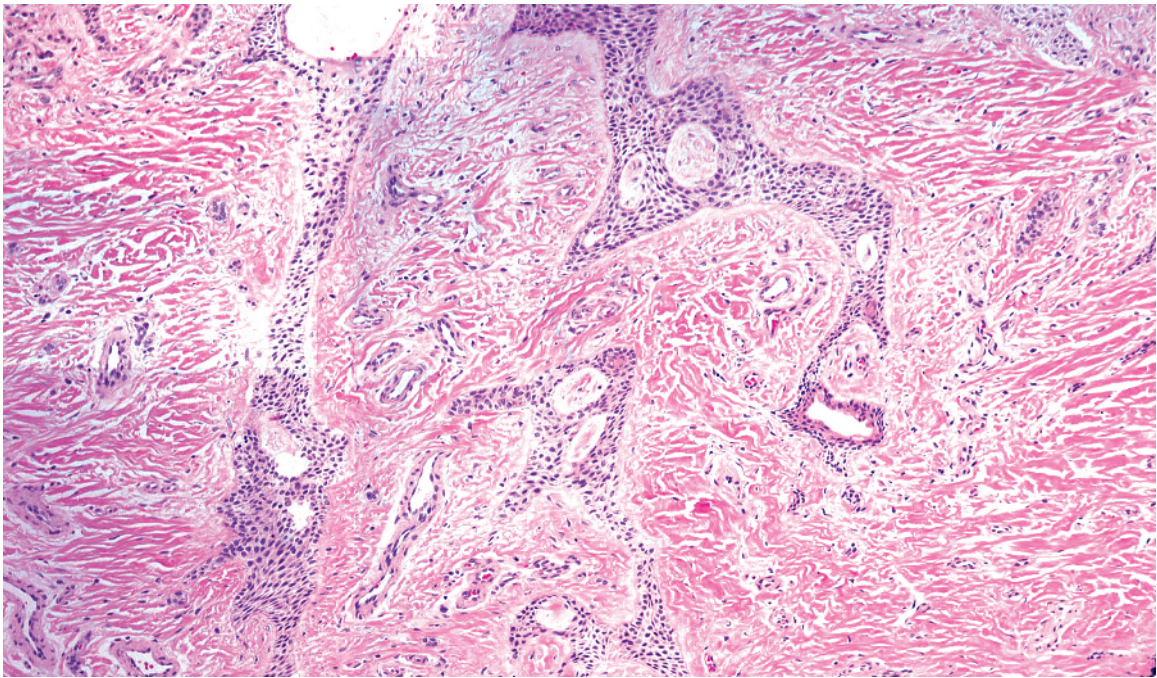
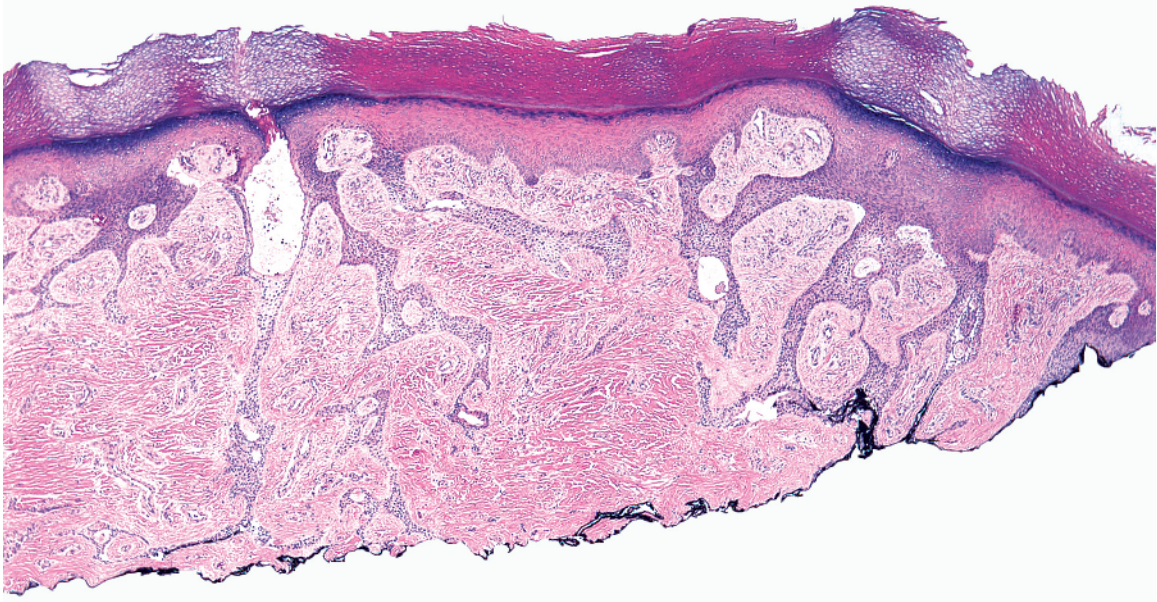


- Reticulated proliferation
- Sebaceous glands, basaloid proliferations (arrow) connect to the epidermis
- Apocrine glands may be seen deep
- Absent terminal hairs in mature stage

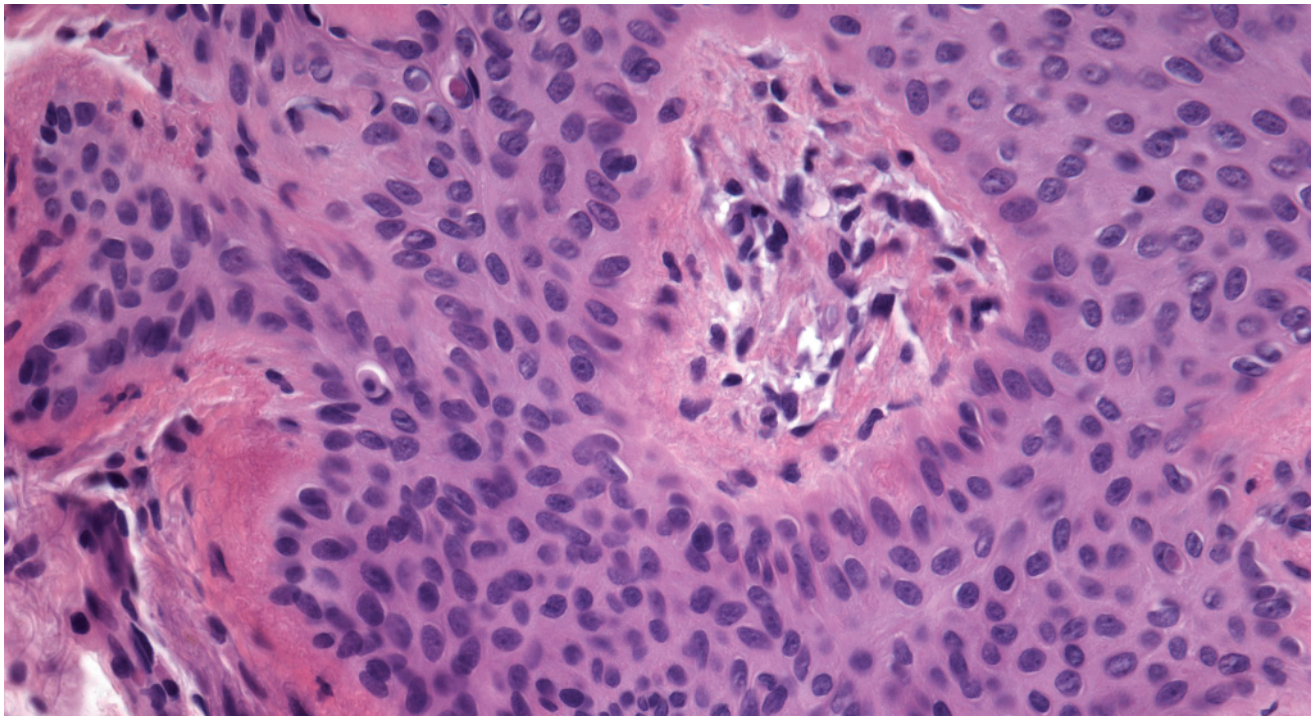
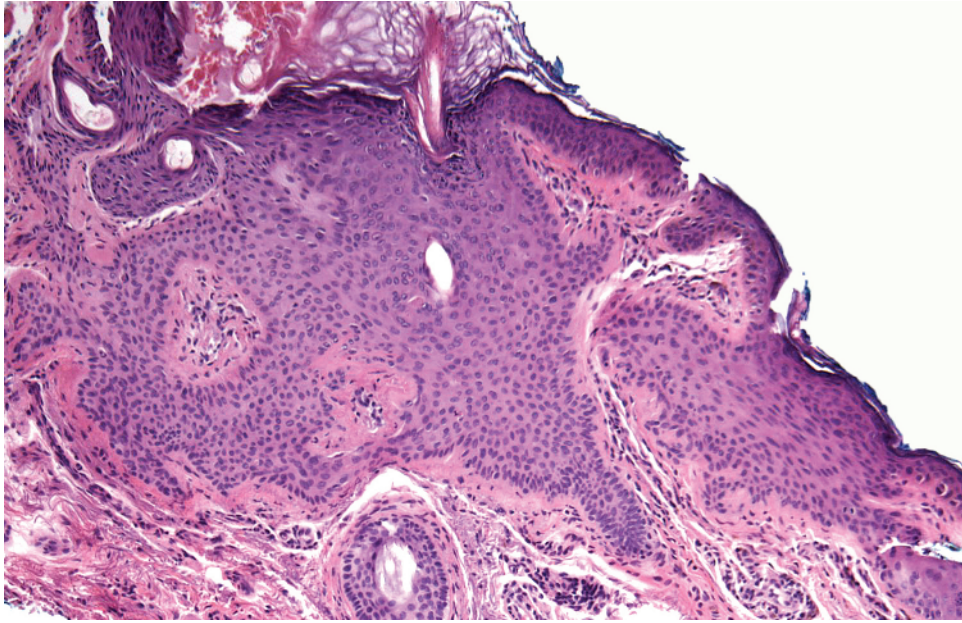


-
- Reticulated proliferation
 - Strands of banal keratinocytes, often pigmented
 - Interspersed pseudohorn cysts

Seborrheic keratosis, reticulated

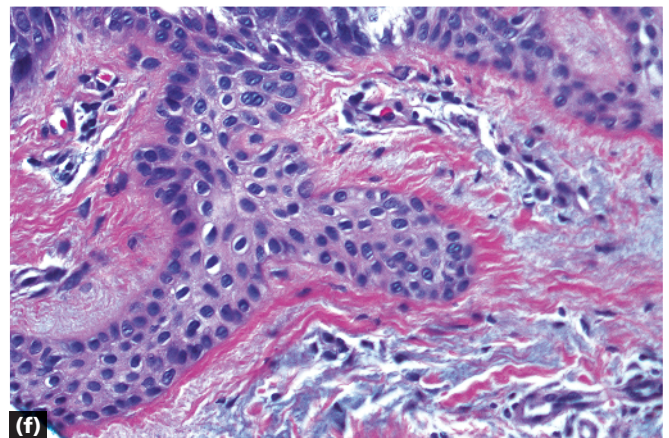
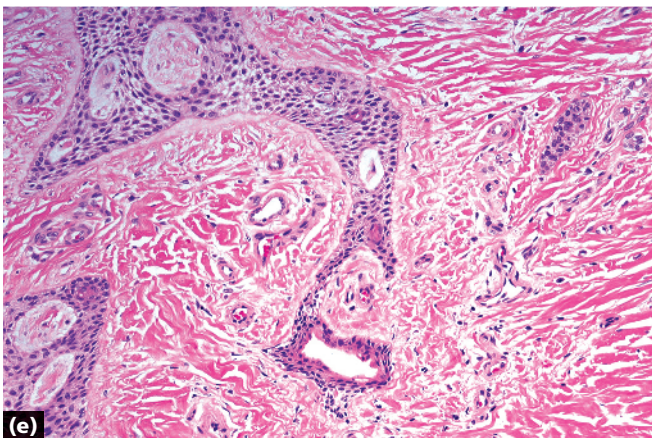
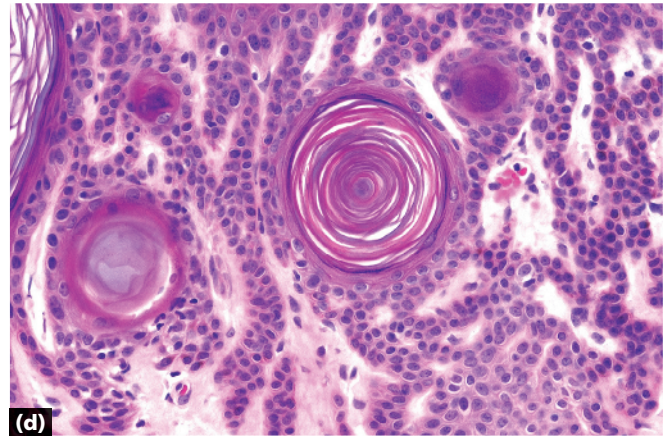
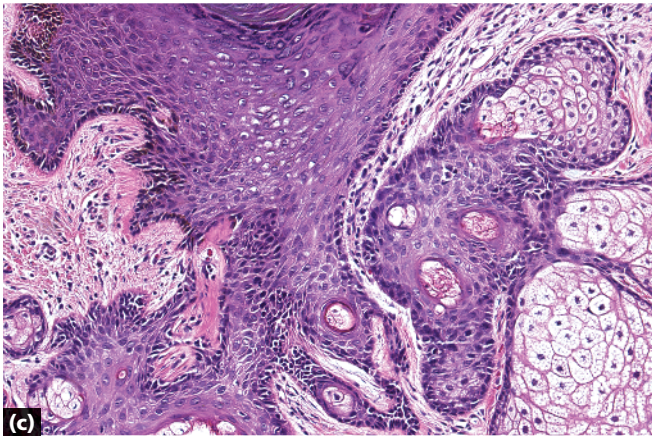
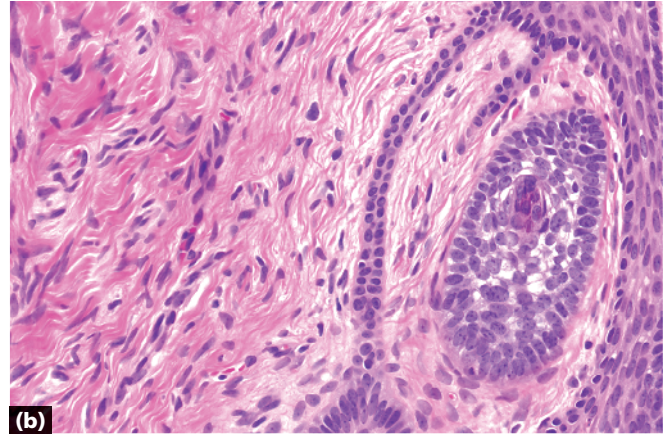
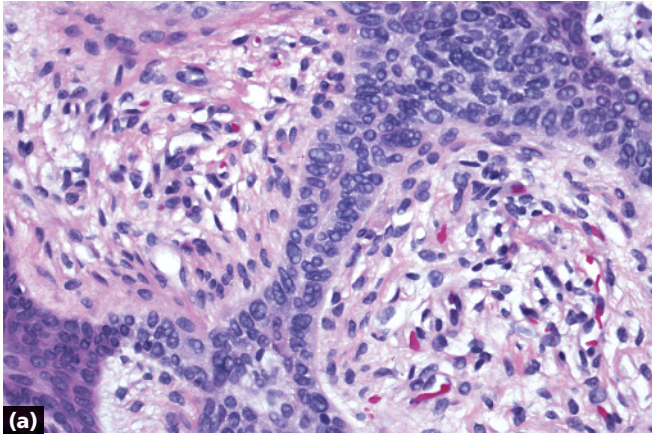


-
- Reticulated proliferation
 - Strands of banal, round cells
 - Interspersed ducts



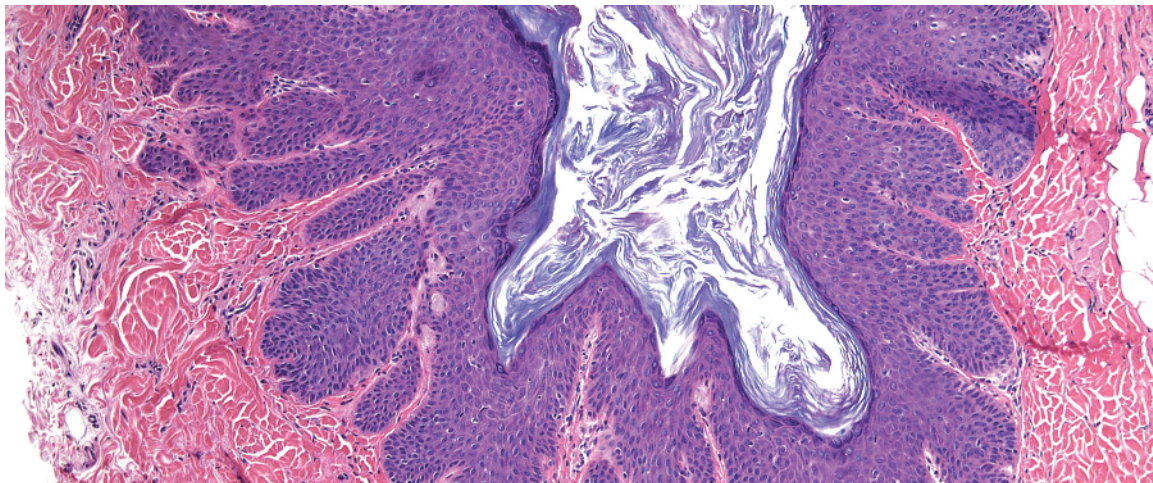
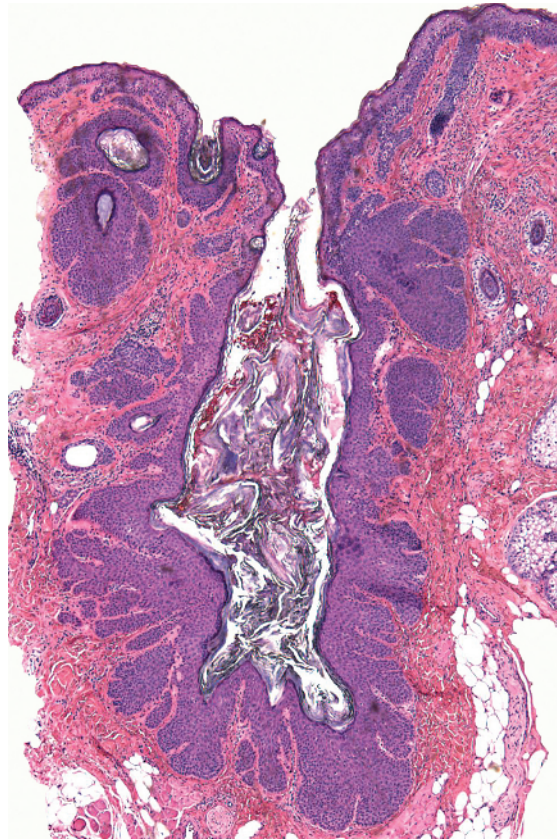
-
- Reticulated proliferation
 - Pale cells in columns with "windows" of dermis in between
 - Peripheral palisading

Tumor of the follicular infundibulum

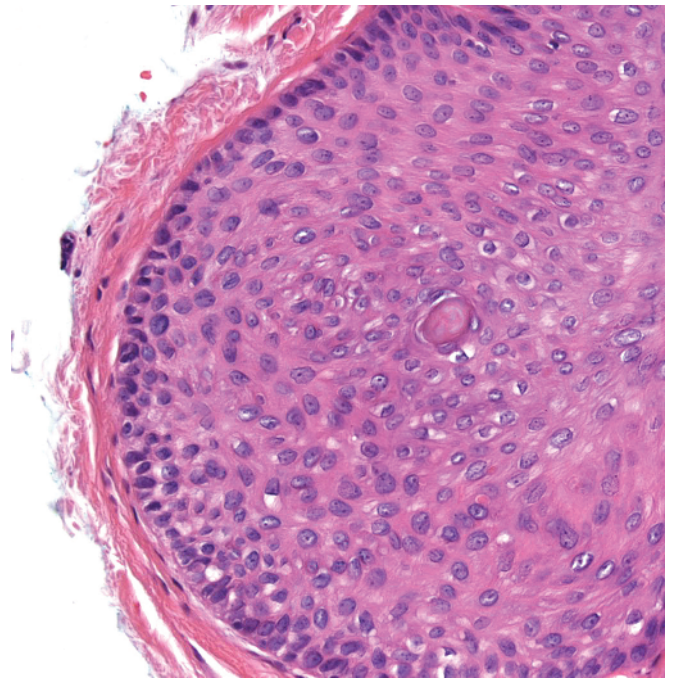
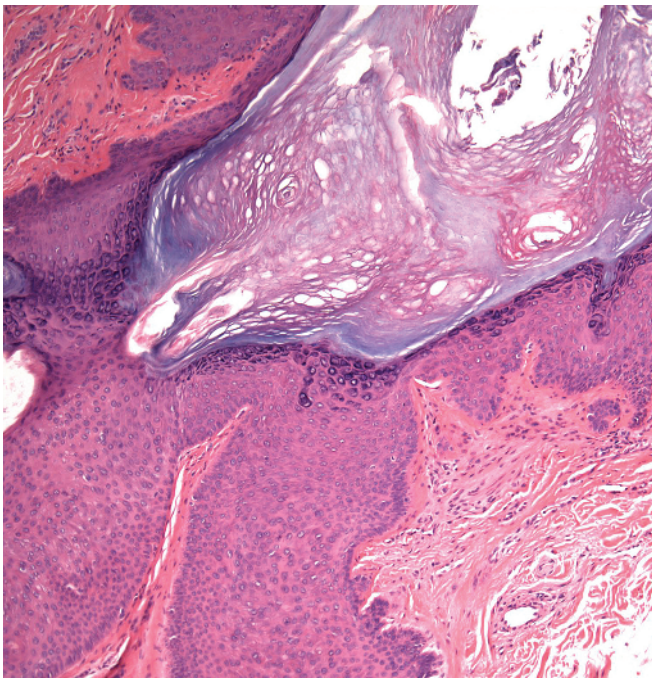
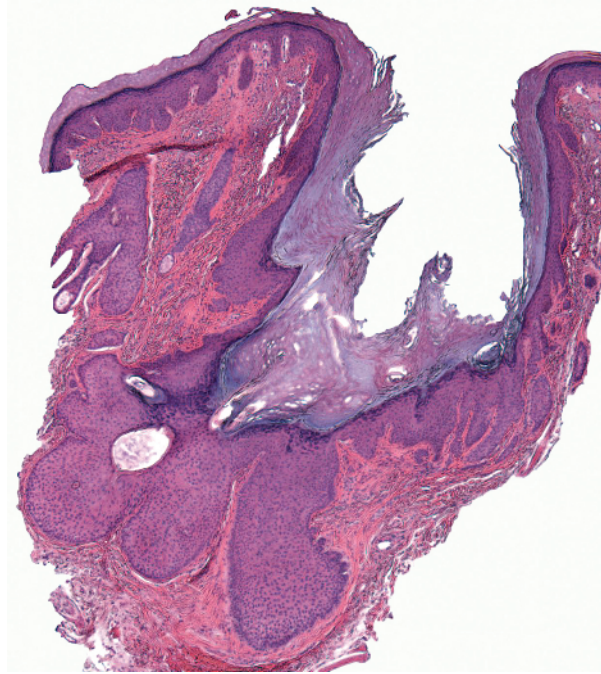


- a** Fibroepithelioma of Pinkus: strands of basaloid epithelium in fibrovascular stroma
- b** Fibrofolliculoma: hair follicle with adjacent fibrotic stroma and reticulated epithelium
- c** Nevus sebaceus: proliferation of epidermis connecting to sebaceous lobules and basaloid proliferations
- d** Seborrheic keratosis, reticulated: reticulated strands of banal keratinocytes, often pigmented; interspersed pseudohorn cysts

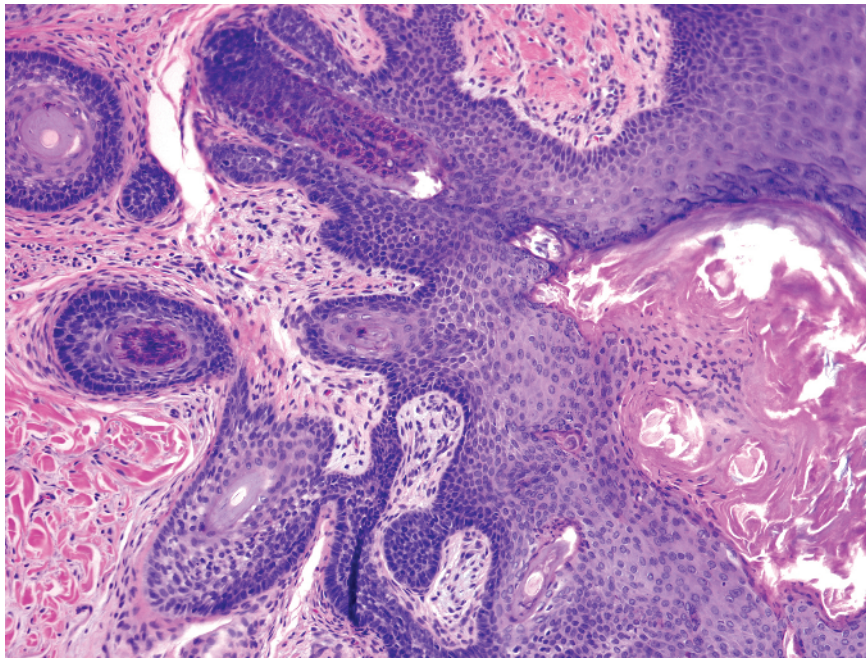
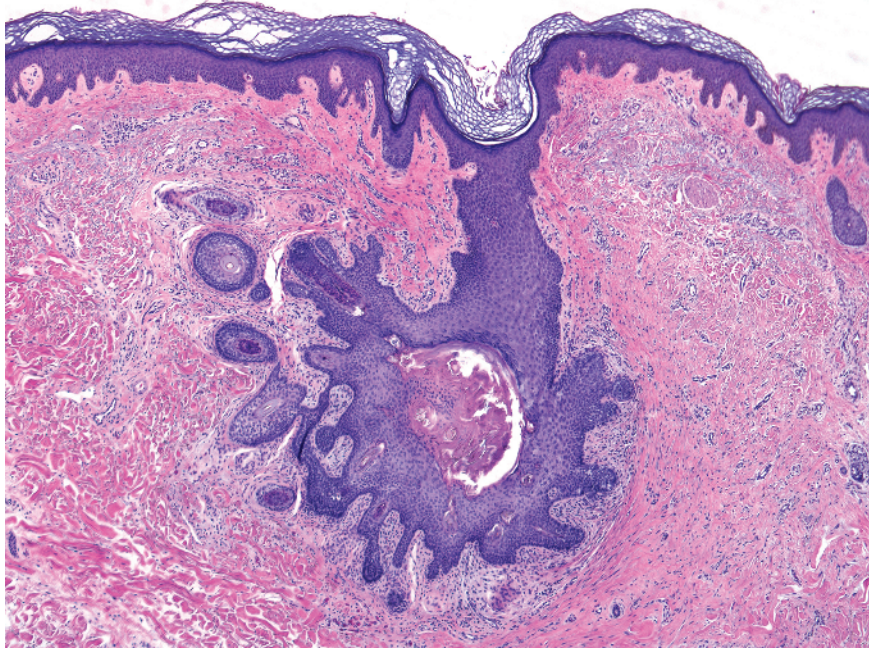
- e** Syringofibroadenoma: strands of uniform, round cells with interspersed ducts
- f** Tumor of the follicular infundibulum: pale cells in columns with "windows" of dermis in between



-
- Central pore
 - Invaginated epidermis is acanthotic

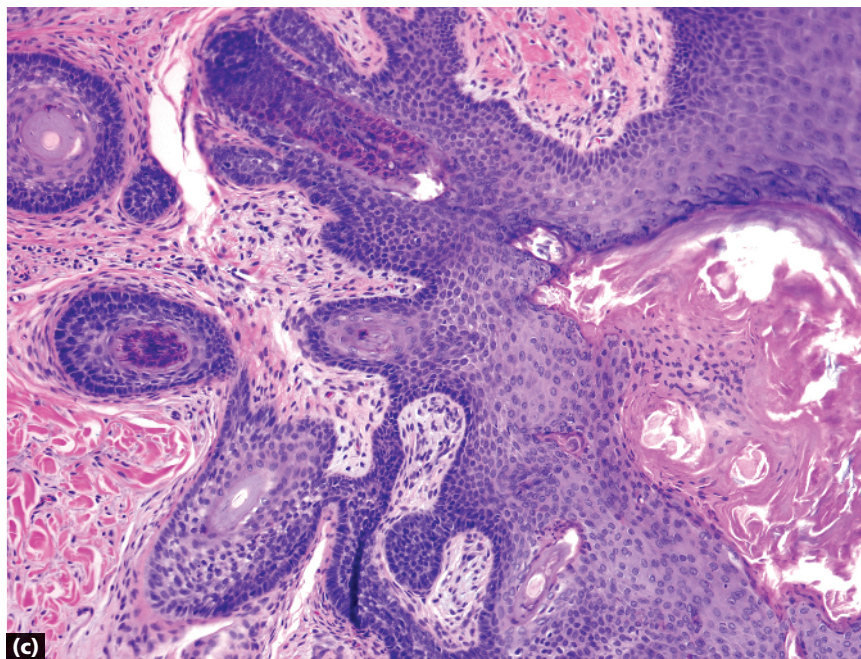
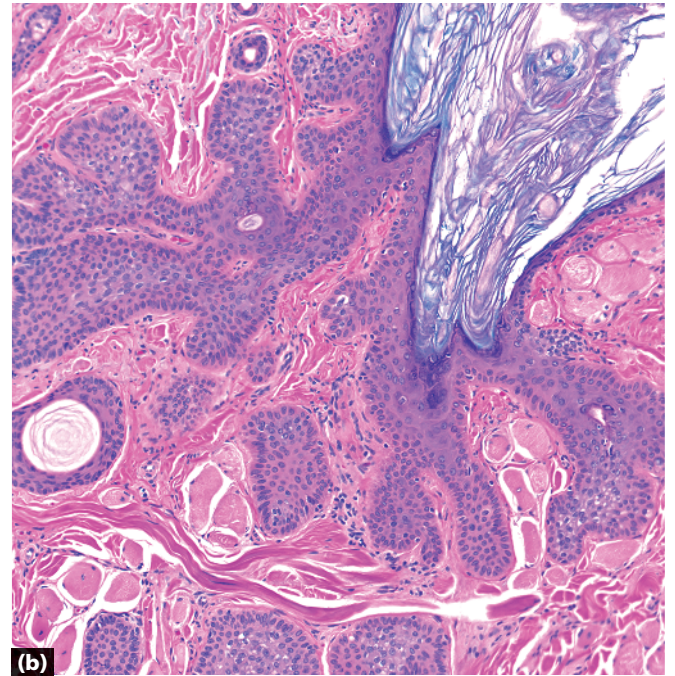
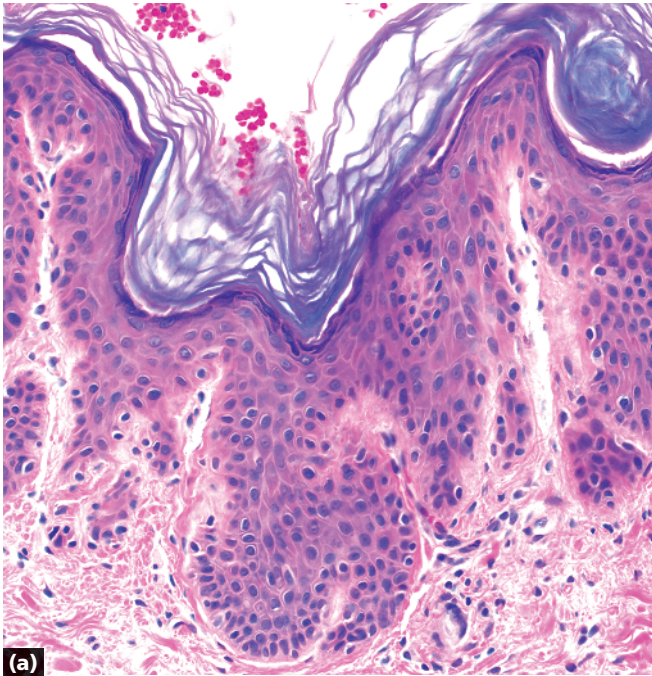

- Central pore
- Invaginated epidermis is acanthotic and has areas resembling outer root sheath with peripheral palisading around slightly pale cells

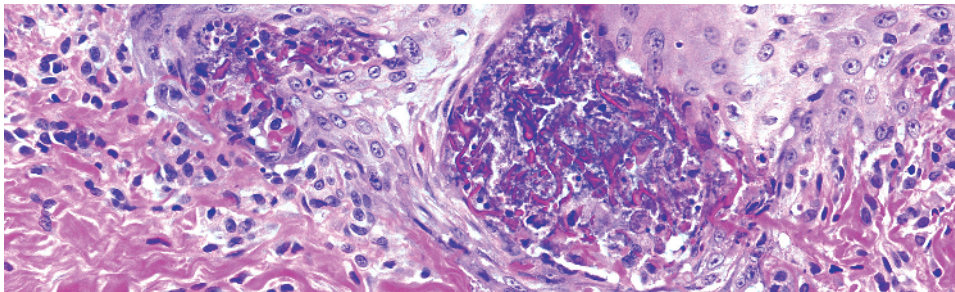
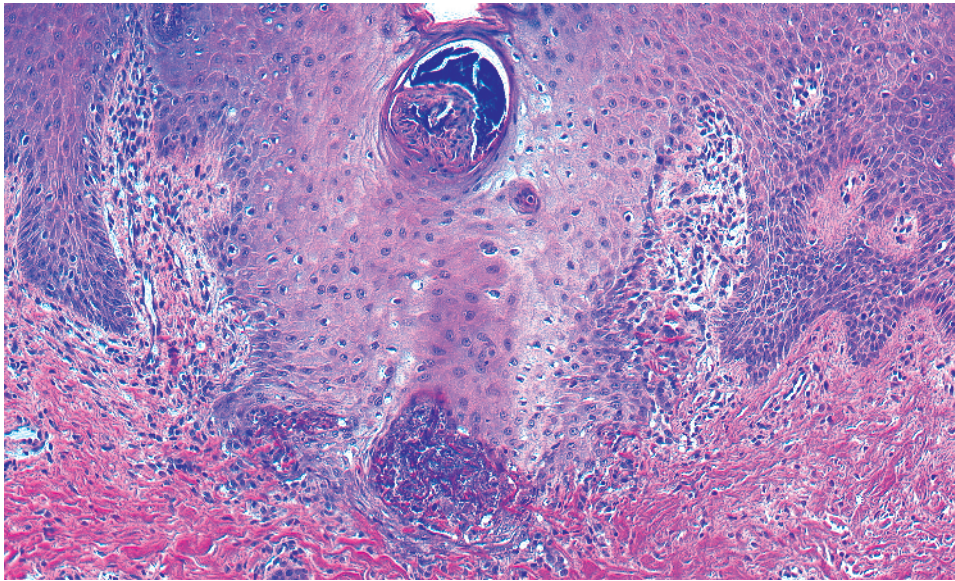
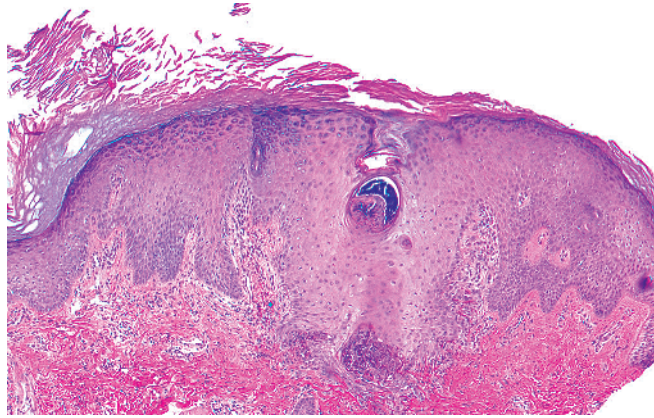


-
- Central pore
 - Invaginated epidermis connects to a primary hair follicle
 - Multiple secondary hair follicles radiating away from the central follicle

Trichofolliculoma

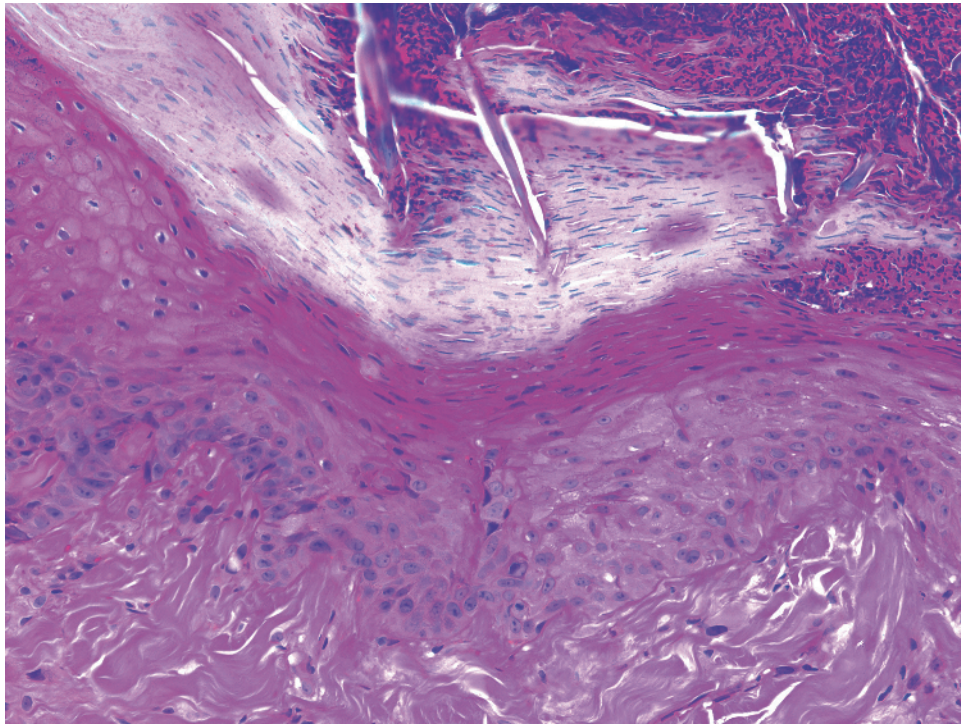
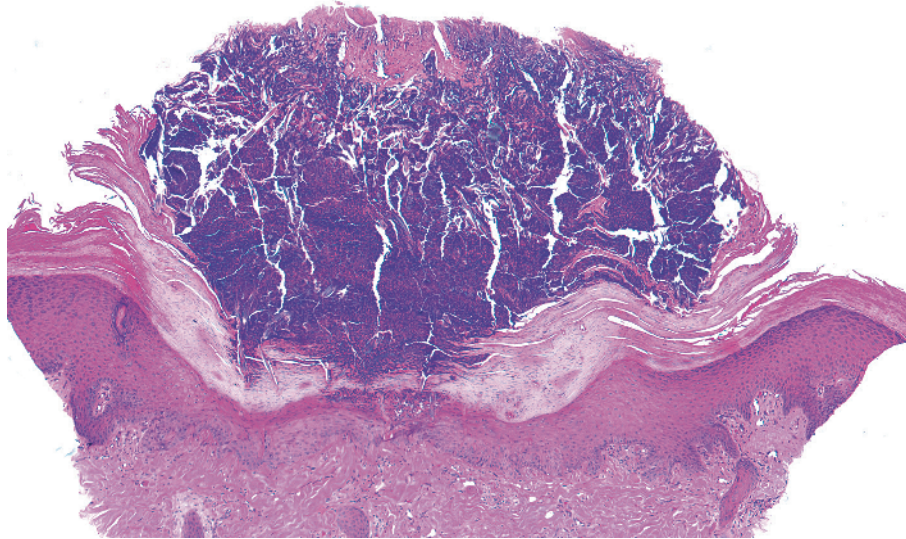


- a Dilated pore of Winer: acanthotic epidermis
- b Pilar sheath acanthoma: epidermal acanthosis and areas resembling outer root sheath
- c Trichofolliculoma: primary follicle and surrounding secondary follicles

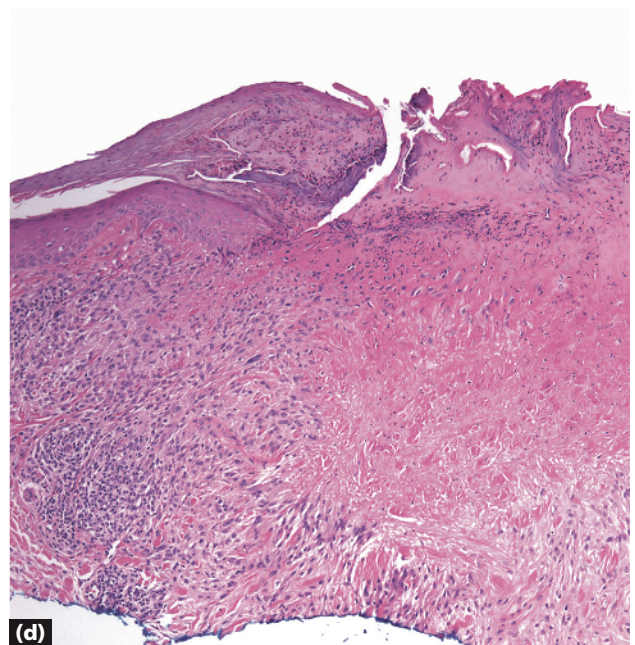
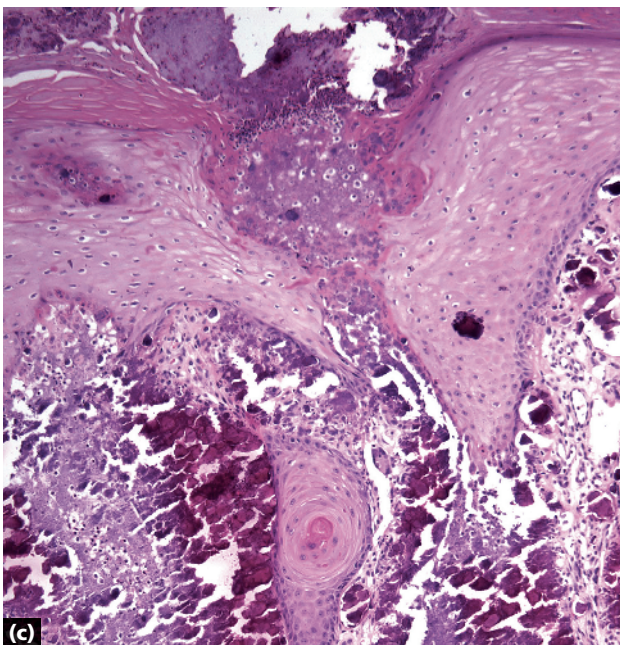
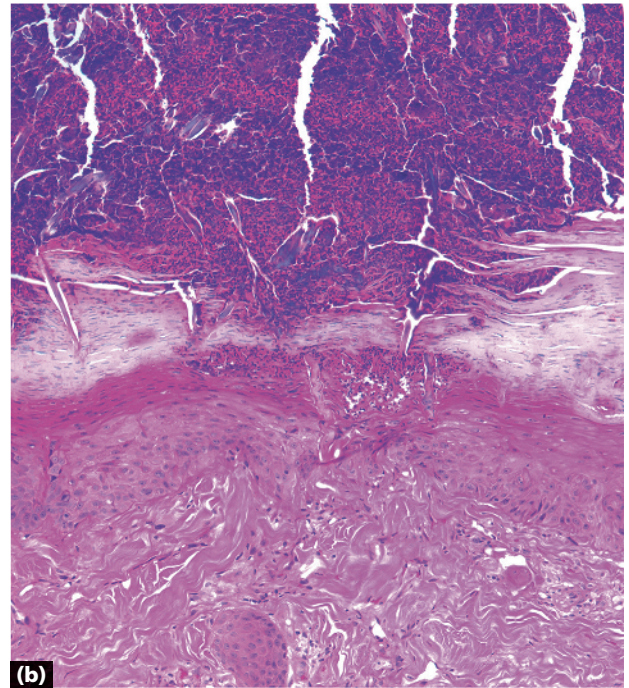
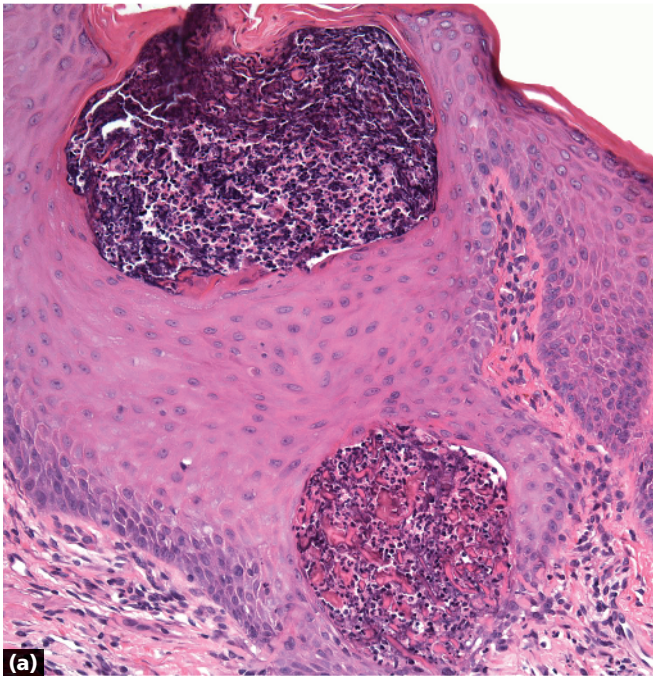


-
- Epidermal perforation
 - Elongated claw (epidermal rete) gripping thin, glassy, eosinophilic elastic fibers and debris
 - Altered elastic fibers are thinner than the collagen fibers in the dermis

Elastosis perforans serpiginosa



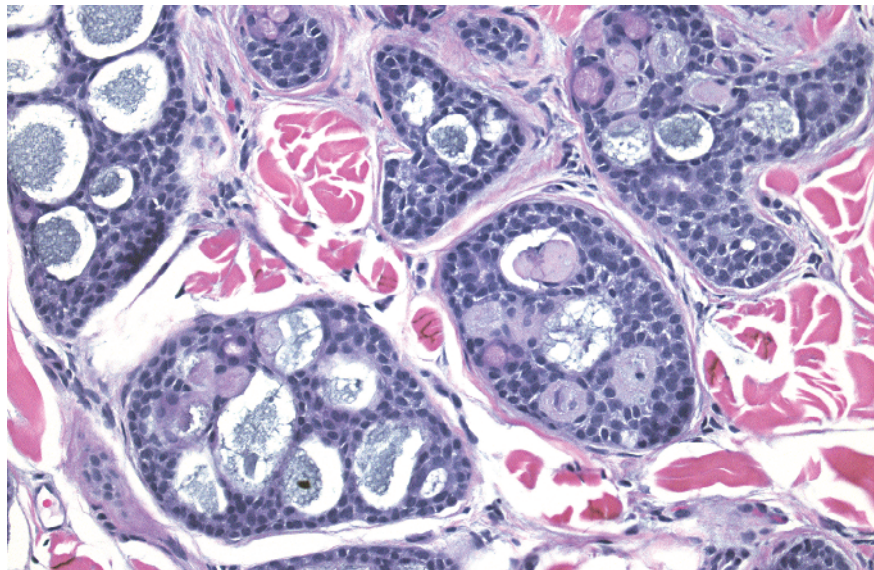
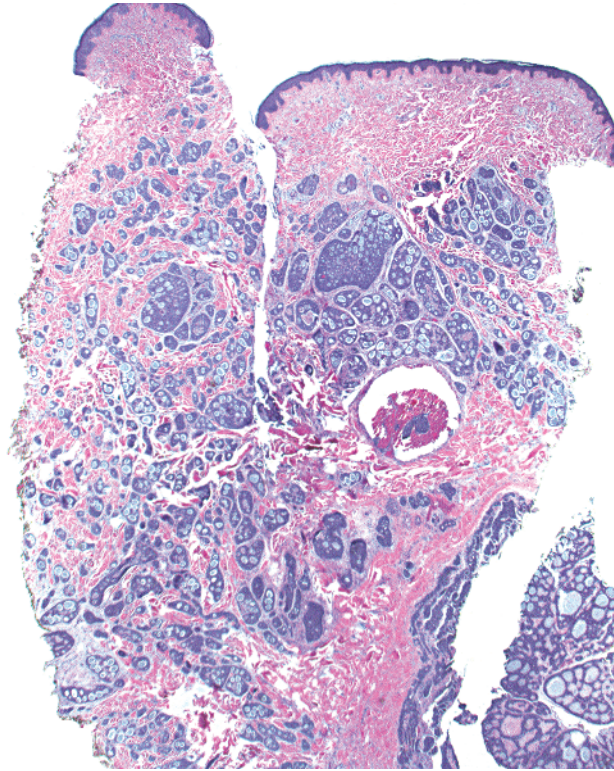
-
- Epidermal perforation
 - Shallow cup-shaped architecture
 - Pink collagen fibers extend vertically through epidermis



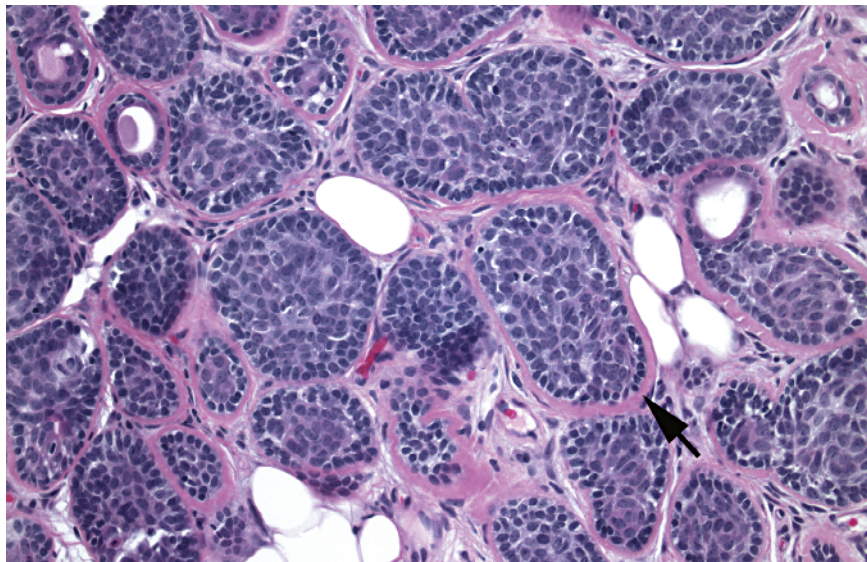
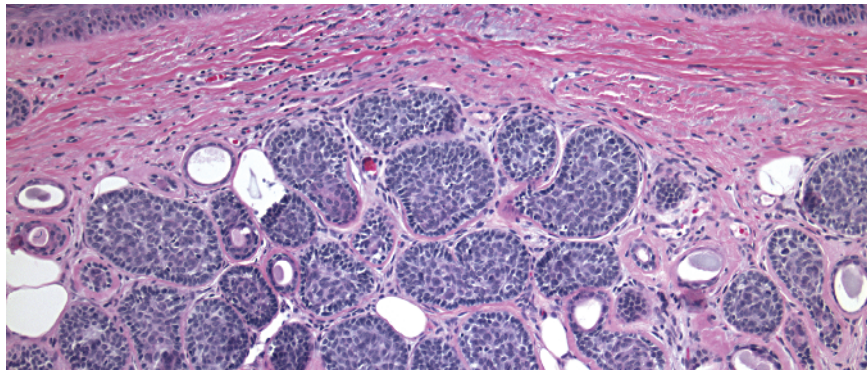
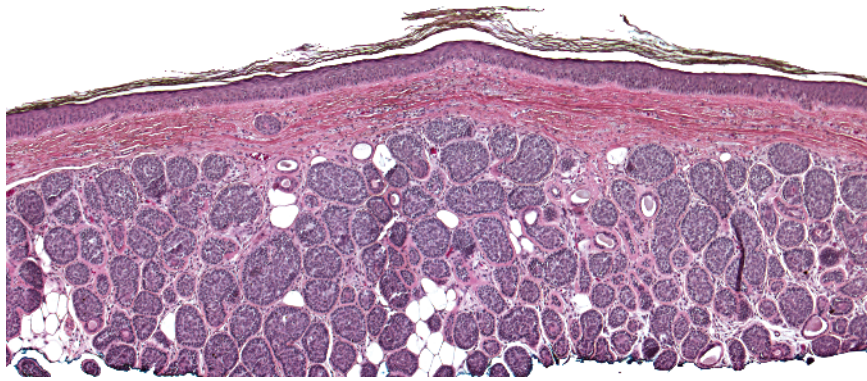
- a** Elastosis perforans serpiginosa: elongated rete forming a claw (tortuous channel); case courtesy of Whitney High, MD, JD
- b** Reactive perforating collagenosis: shallow, broad cup-shaped architecture
- c** Calcinosis cutis, perforating: chunky, bluish material (see page 264) at the base of an ulcer

- d** Granuloma annulare, perforating: palisading histiocytes around collagen with mucin (see page 89)
- Note** Other entities may also perforate the epidermis, for example, chondrodermatitis nodularis helicis, pseudoxanthoma elasticum.

Key differences

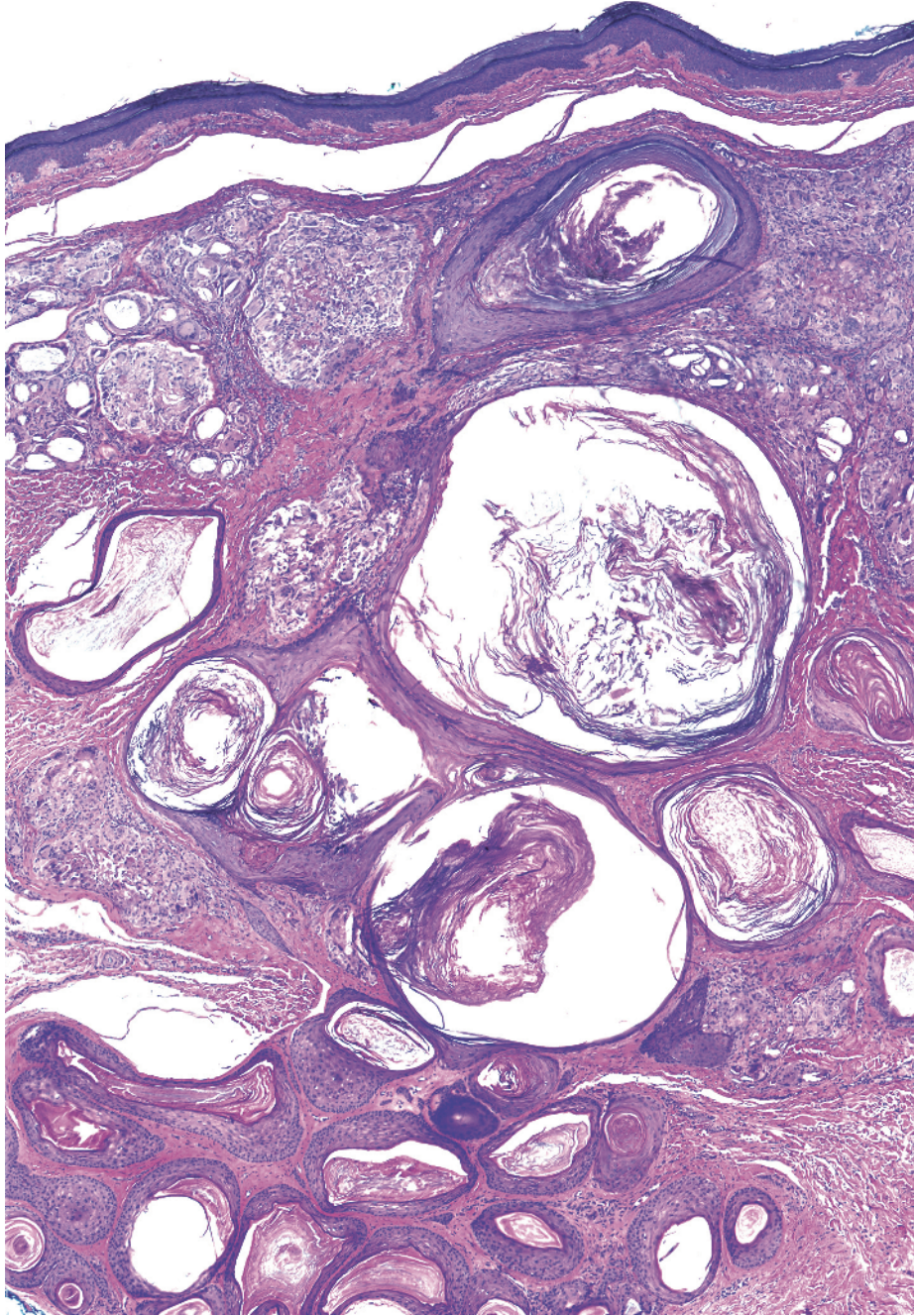


-
- Circular dermal islands
 - Islands contain basaloid cells with a cribriform pattern of duct-like spaces filled with amorphous material

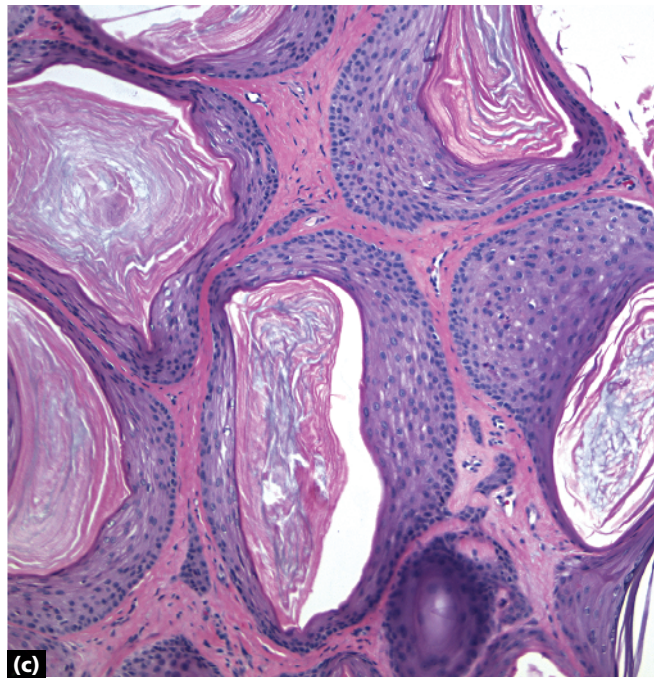
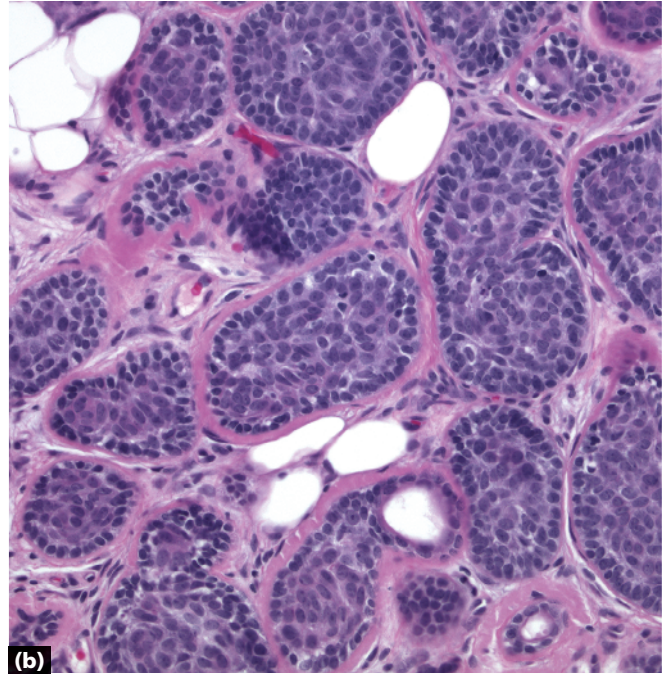
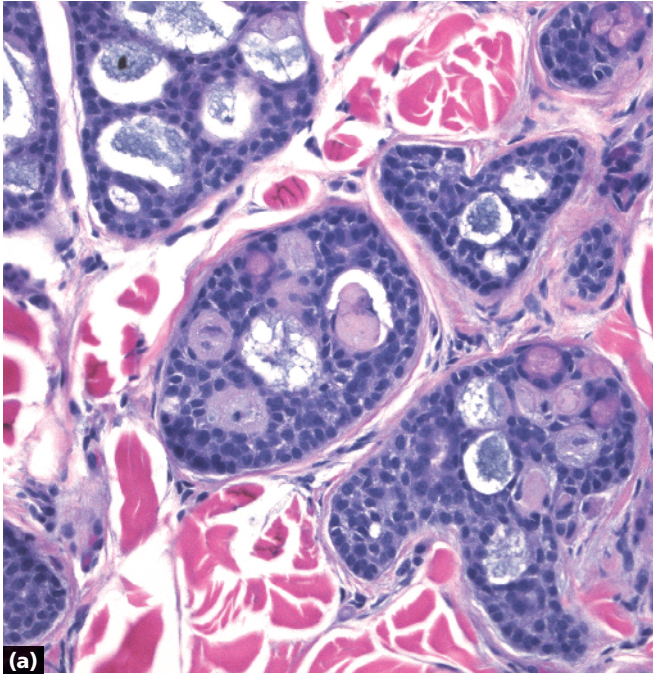


-
- Circular dermal islands
 - Islands contain basaloid cells surrounded by a thick pink basement membrane (arrow)
 - Islands arranged like a "jigsaw puzzle"

Cylindroma

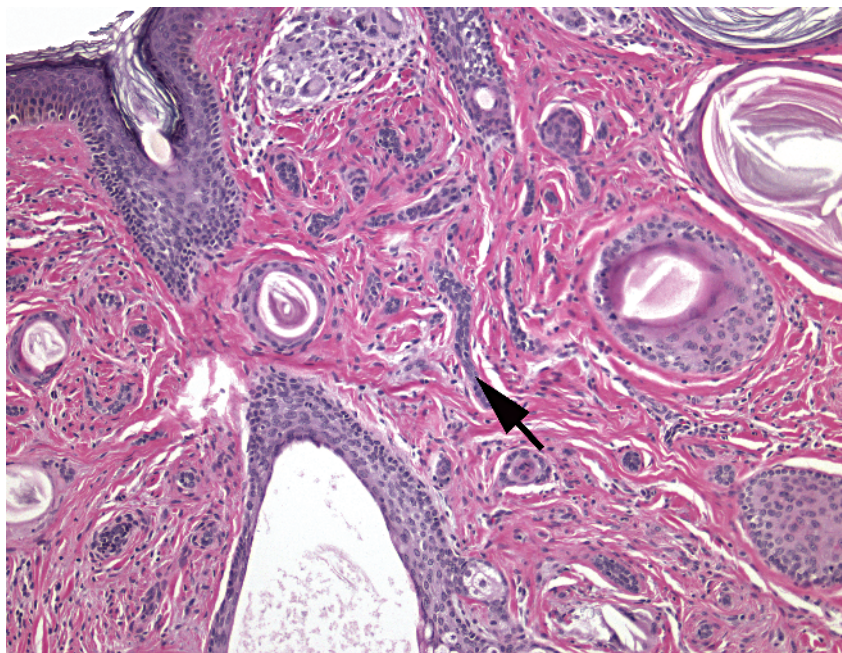
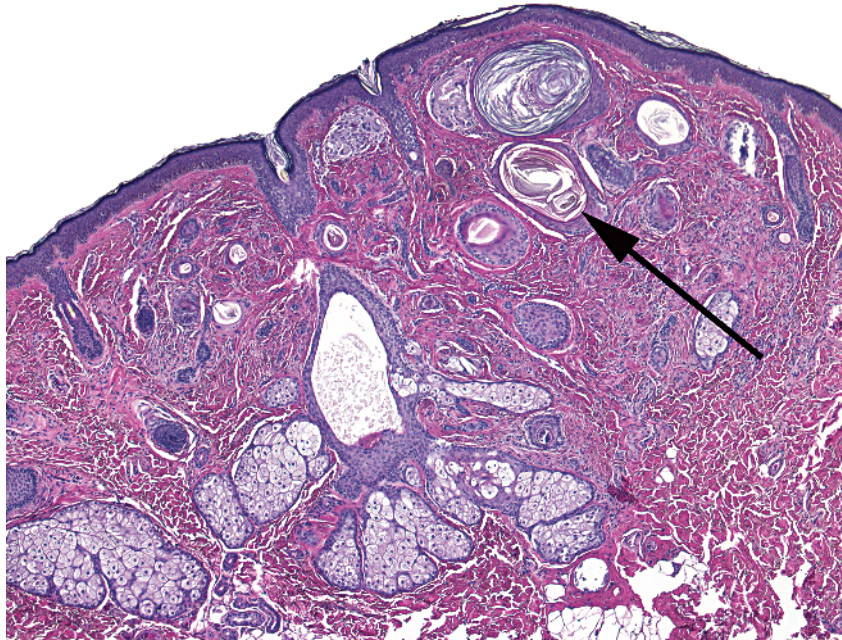


-
- Circular dermal islands
 - Islands of epithelium with central flaky keratin (horn cysts)
 - Interspersed basaloid cords

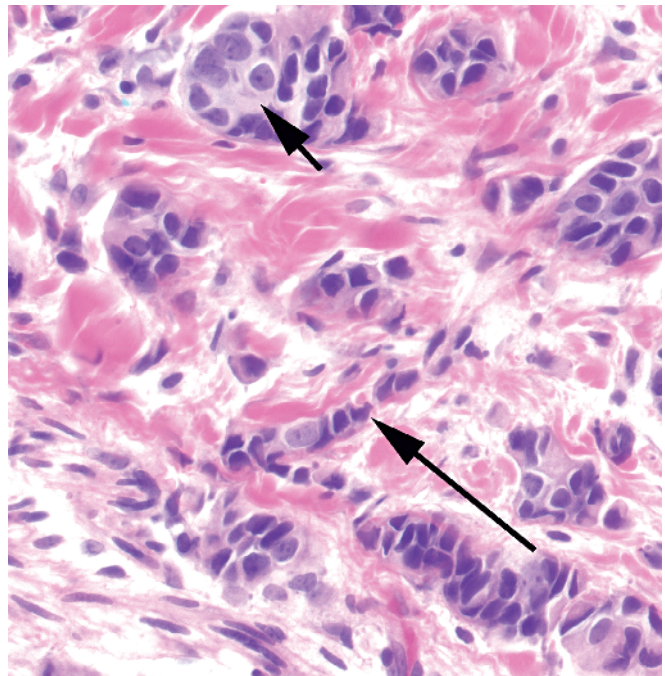
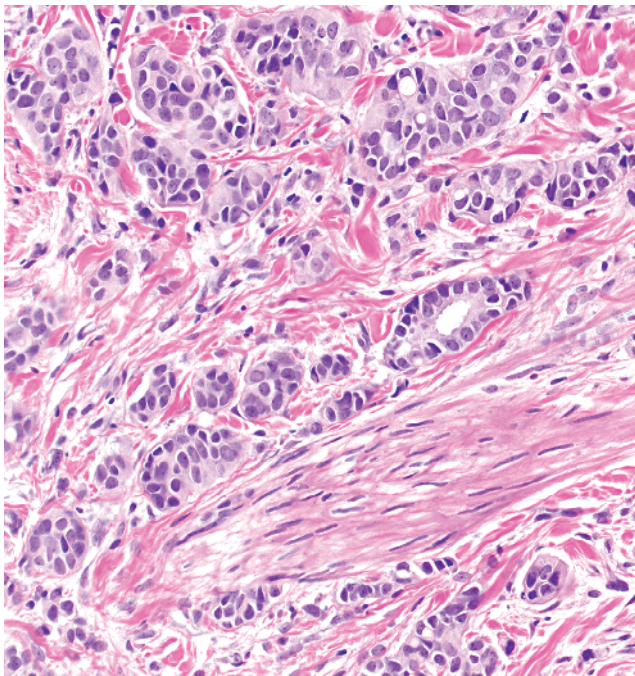
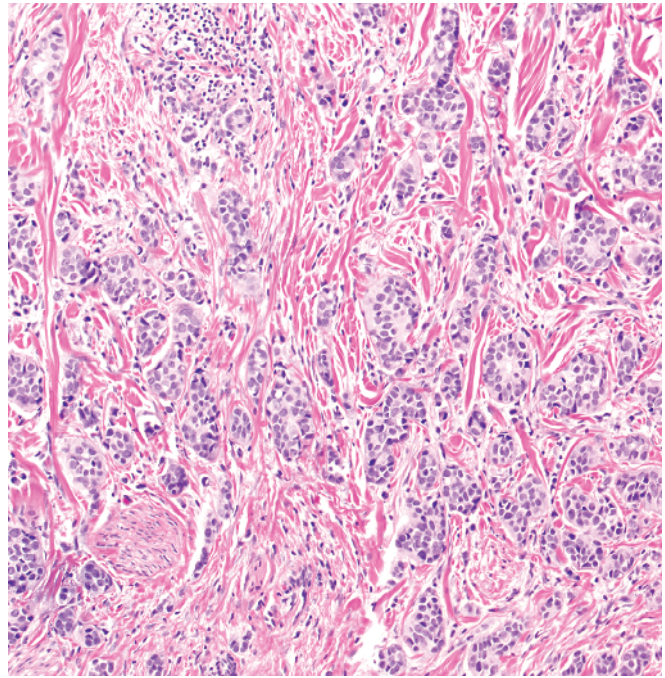
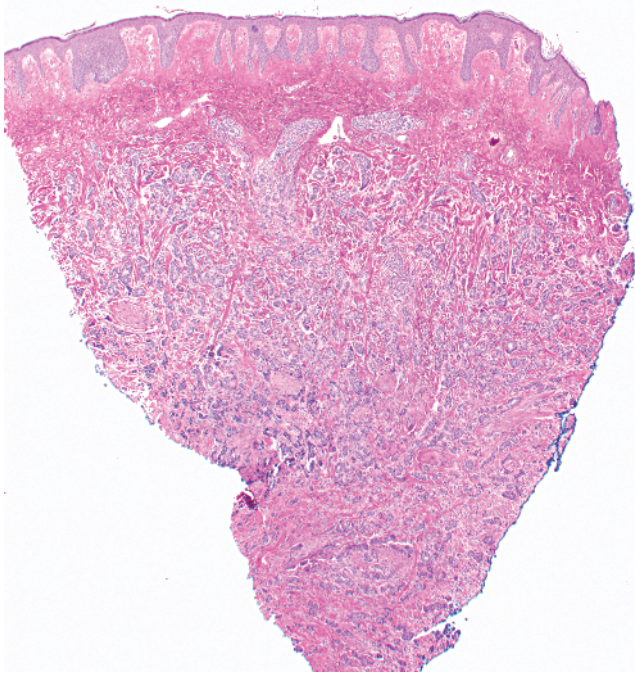


- a** Adenoid cystic carcinoma: cribriform pattern of duct-like structures
- b** Cylindroma: puzzle-like arrangement, thick/pink basement membrane
- c** Trichoadenoma: numerous horn cysts

Key differences

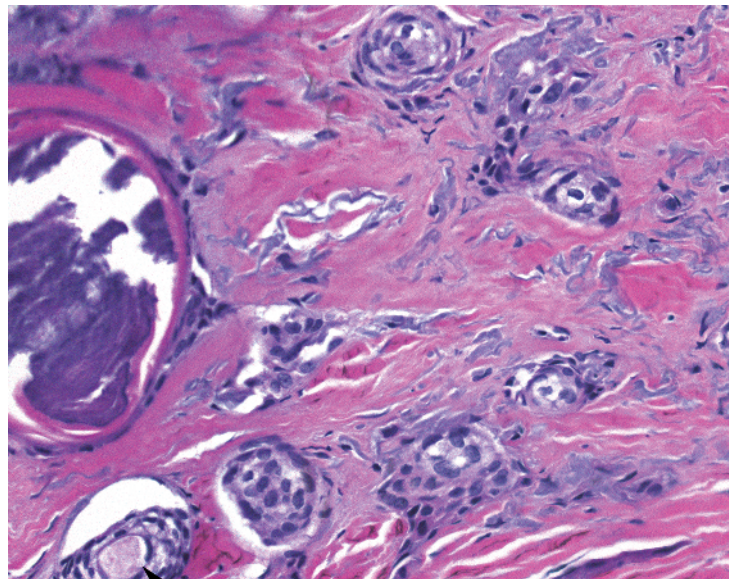
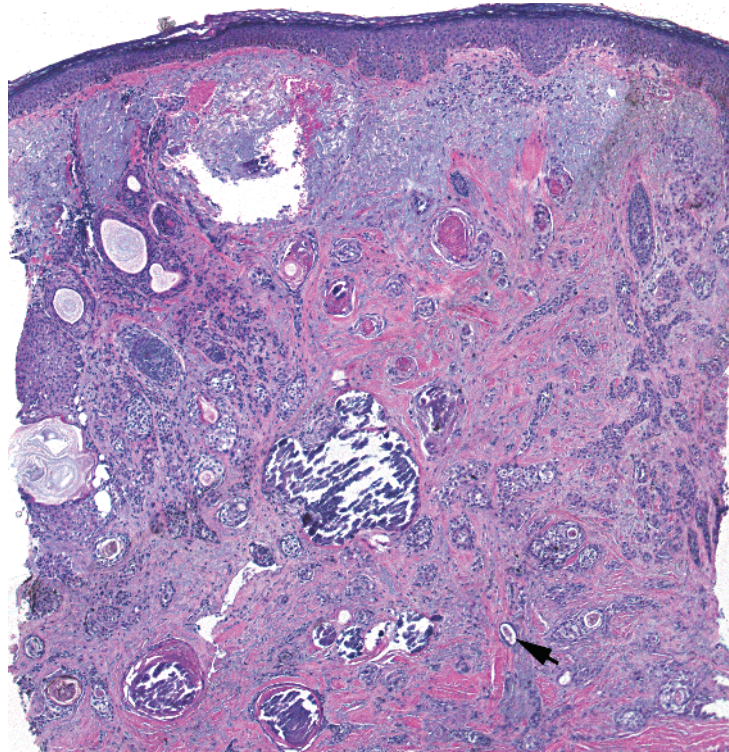


- Cords/tubules and comma shapes in dermis
- Numerous horn cysts (long arrow) in fibrotic stroma
- Tubules of two-layered epithelium (short arrow)
- Calcification often present
- Confined to dermis

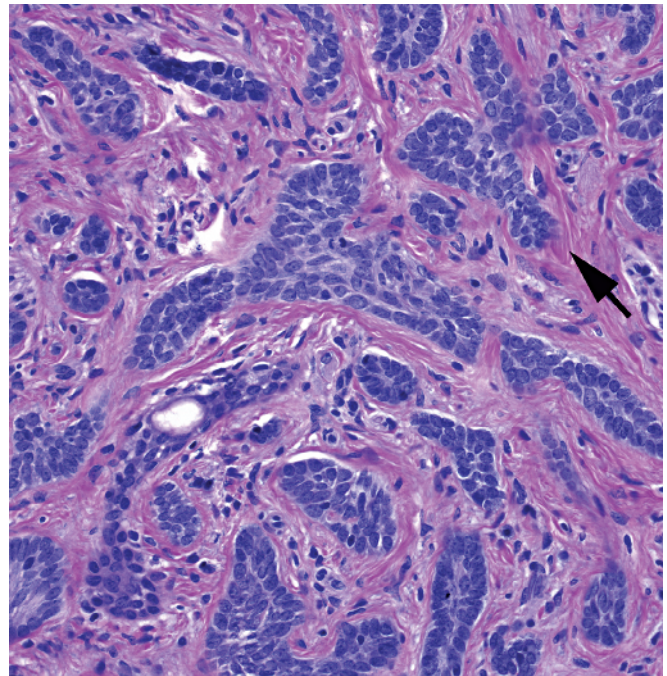
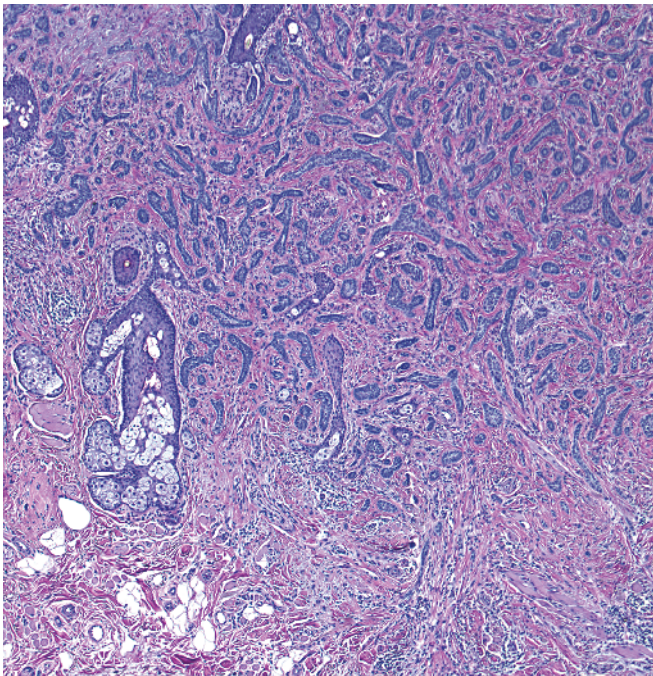
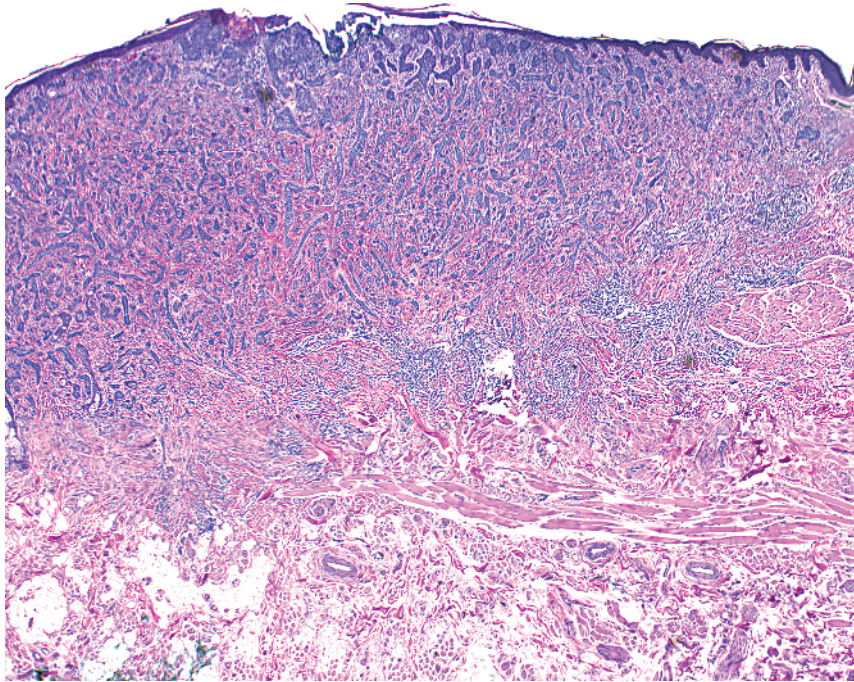


- Cords/tubules and comma shapes in dermis and below
- Tubules of single-layered ("Indian filing" – long arrow) and multi-layered epithelium
- Some cells forming gland-like structures (short arrow)
- Other metastatic carcinomas may look like this – need clinical history; immunohistochemistry may be helpful

Metastatic breast carcinoma

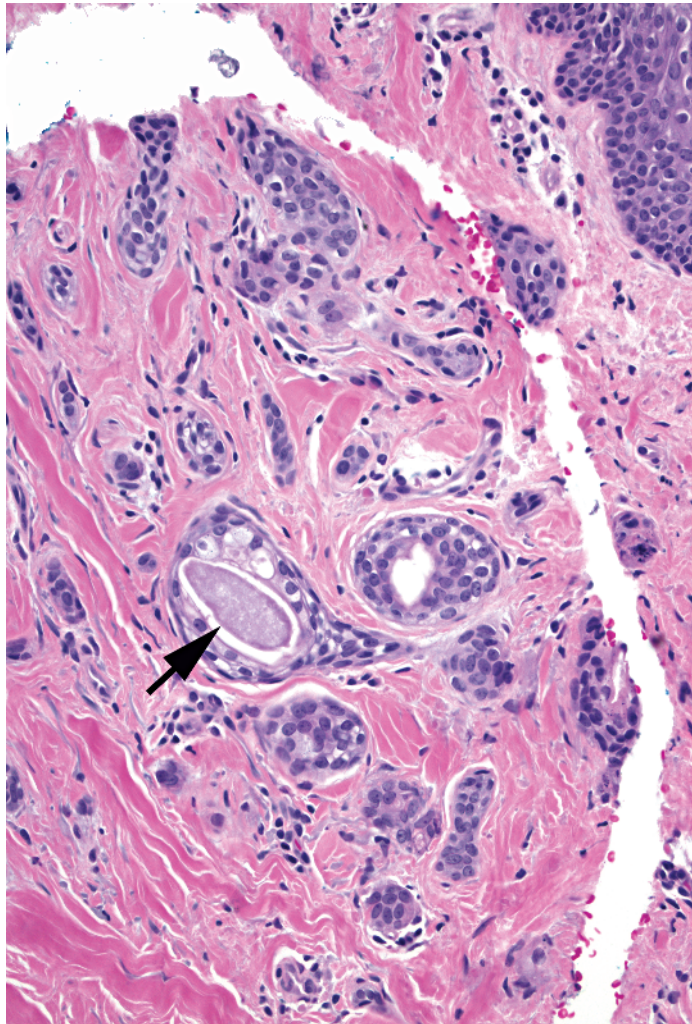
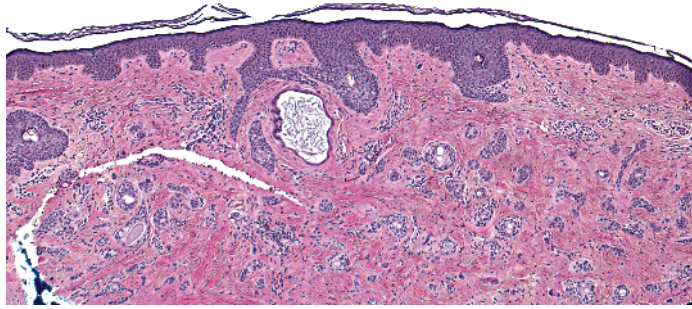


-
- Cords/tubules and comma shapes in dermis
 - Comma shapes with duct-like spaces
 - Deeply infiltrative (fills dermis)
 - Perineural involvement

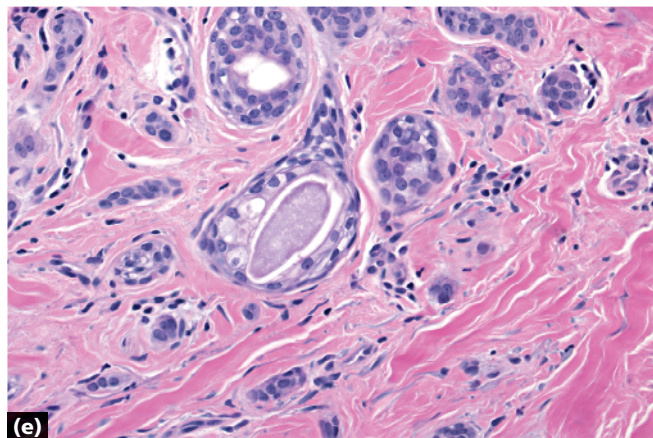
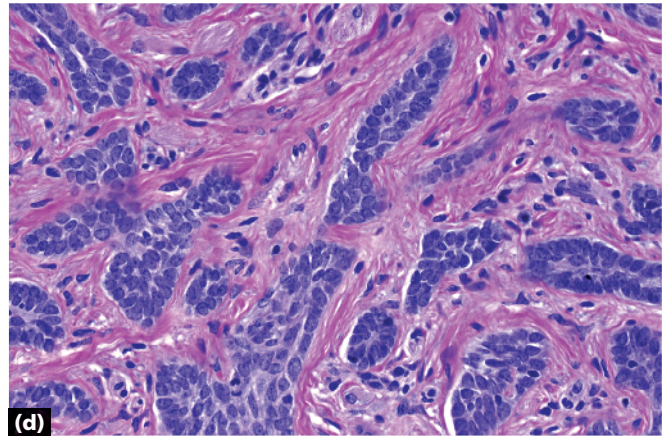
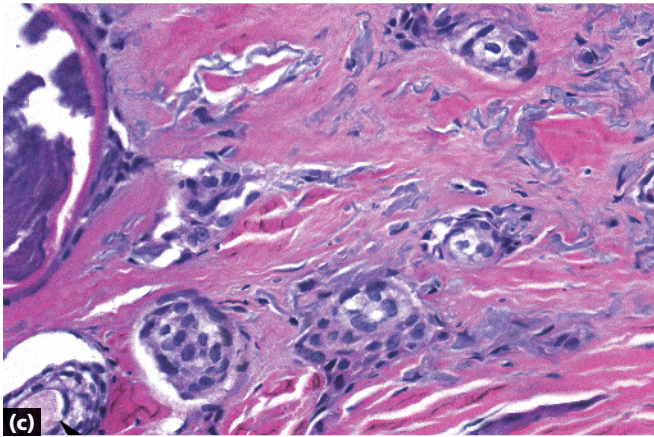
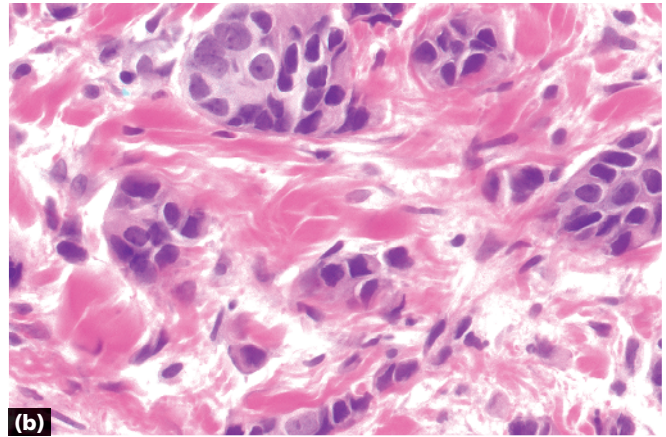
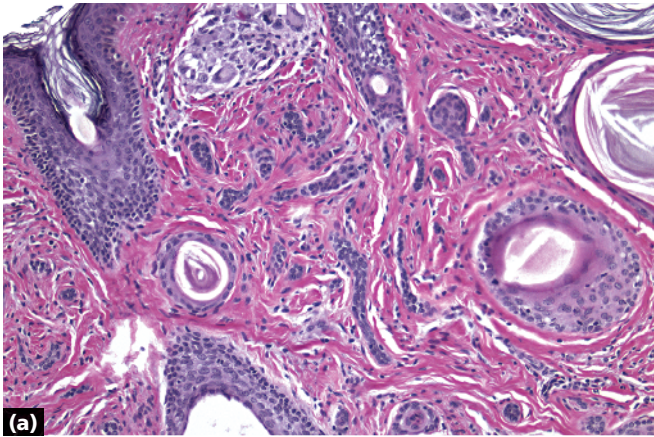


- Cords/tubules and comma shapes in dermis
- Tubules of epithelium composed of basaloid cells with hints of peripheral palisading
- New collagen forming around islands (arrow)
- Deeply infiltrative

Morpheaform basal cell carcinoma



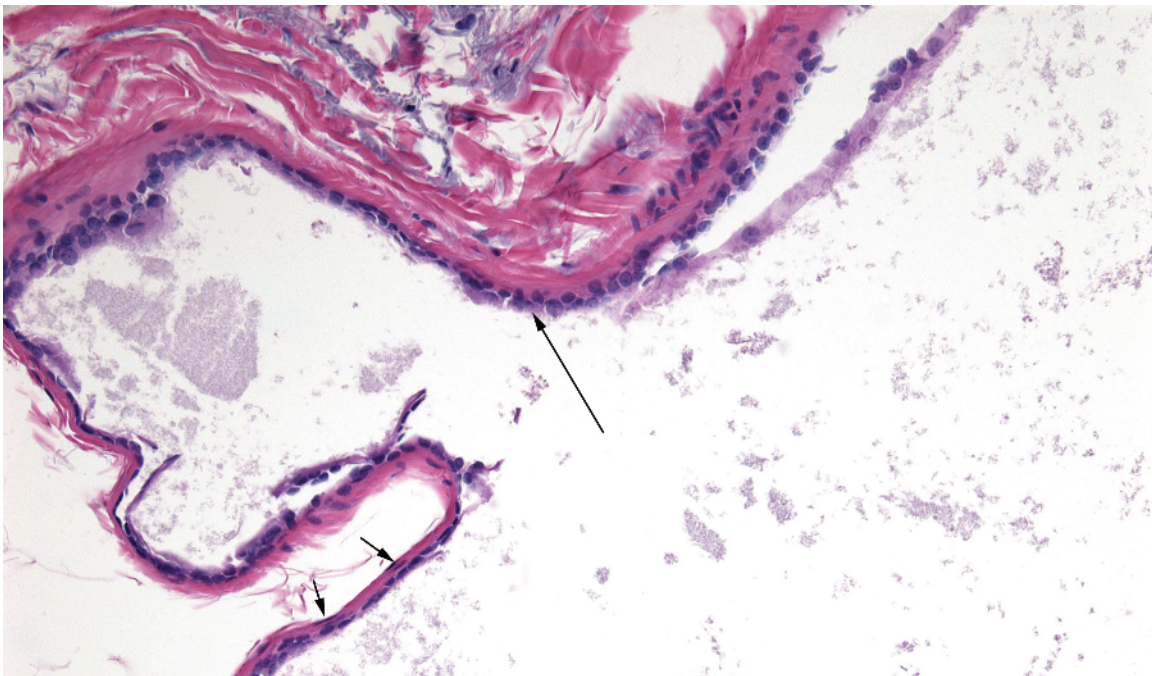
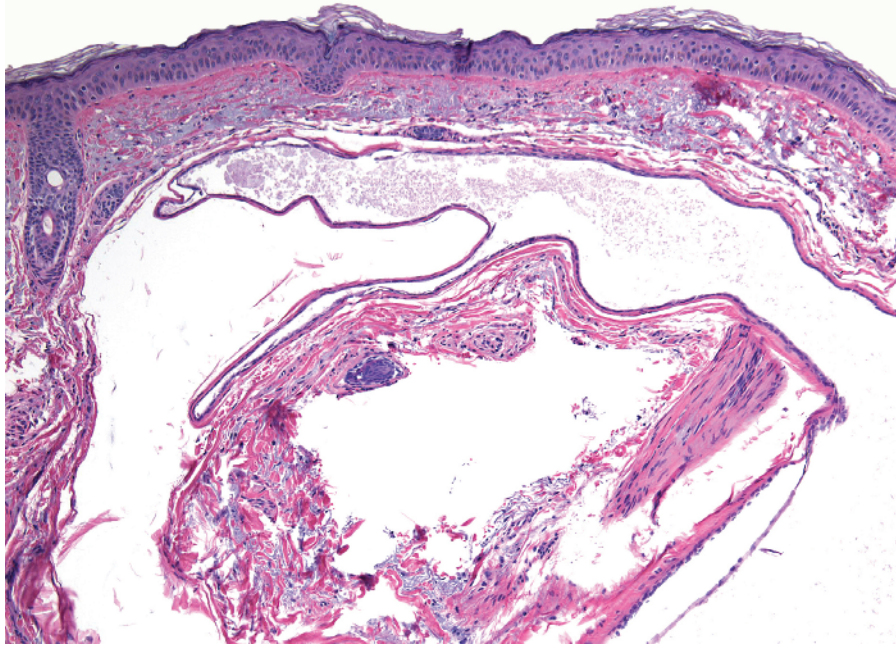
-
- Cords/tubules and comma shapes in dermis
 - Restricted to upper dermis
 - "Tadpoles" of epithelium with duct-like structures in heads (arrow)
 - Darker cells at periphery, clear cells in center
 - Eosinophilic cuticle lining lumina
 - No horn cysts



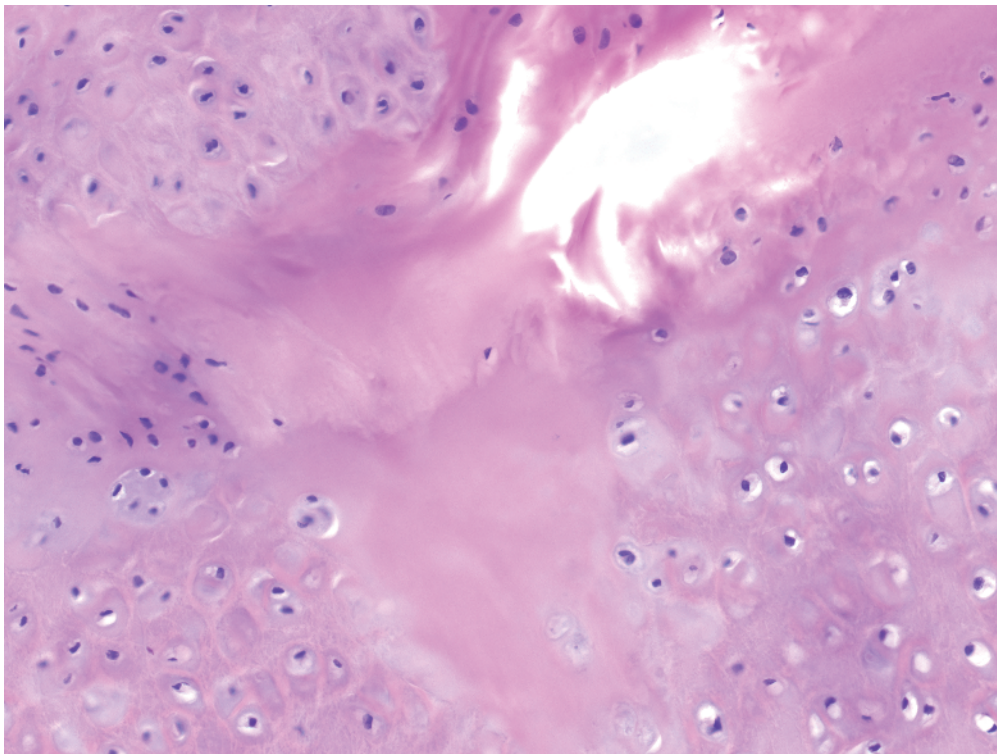
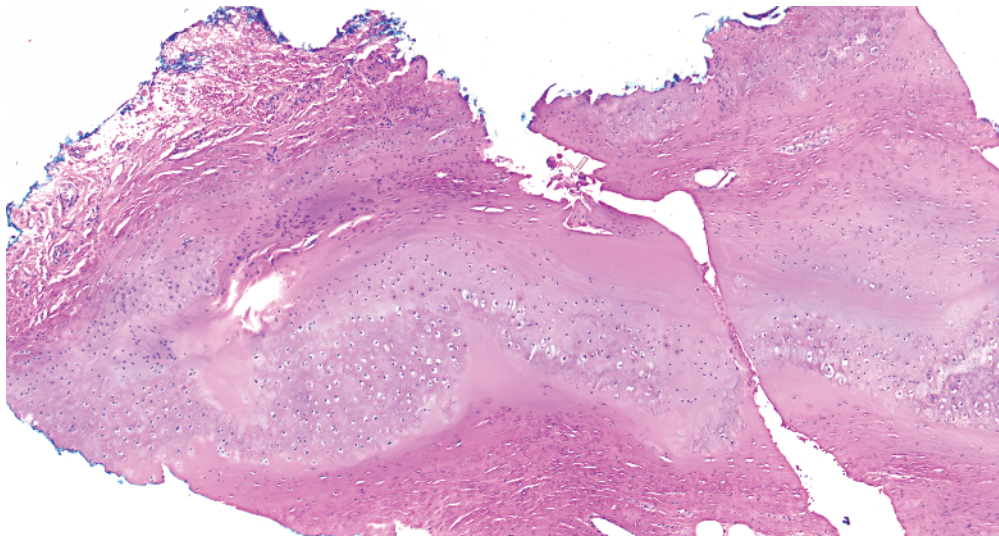
- a** Desmoplastic trichoepithelioma: horn cysts, no clear cells, circular areas of epithelium surround keratin
- b** Metastatic breast carcinoma: single filing of atypical cells, deeply infiltrative
- c** Microcystic adnexal carcinoma: like syringoma with tadpole-like structures but deeply infiltrative, perineural involvement

- d** Morpheaform basal cell carcinoma: infiltrative cords of basaloid cells with hints of peripheral palisading; may have some duct-like structures (but less than **c**)
- e** Syringoma: superficial tadpoles with clear cells

Key differences

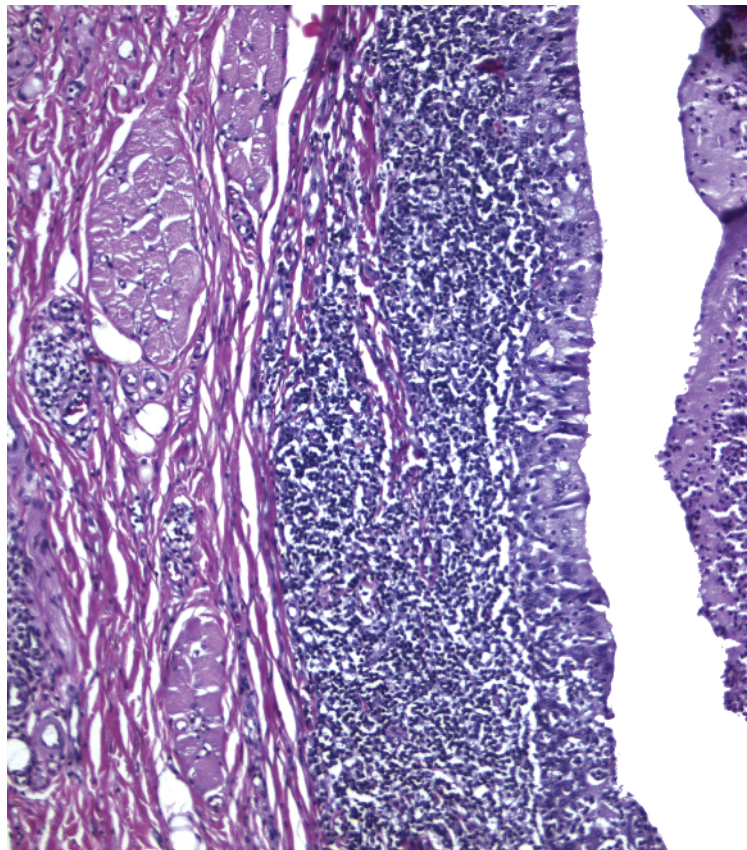
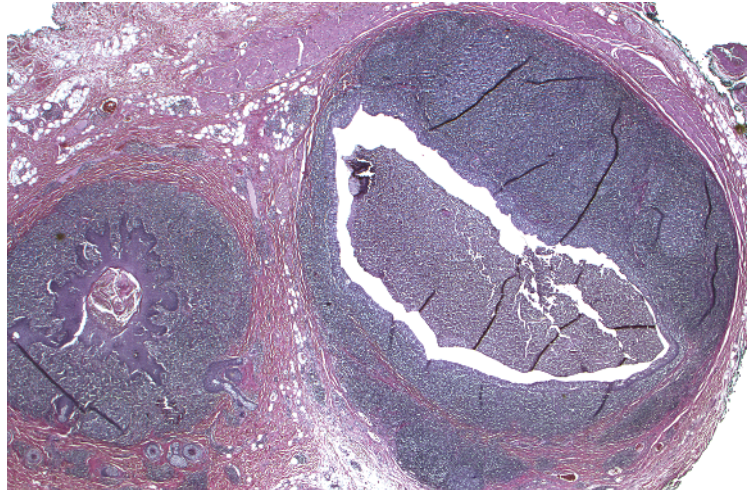


- Space with a lining
- Lining composed of an inner layer of cells with decapitation secretion (long arrow) and a compressed layer of myoepithelial cells (short arrow)

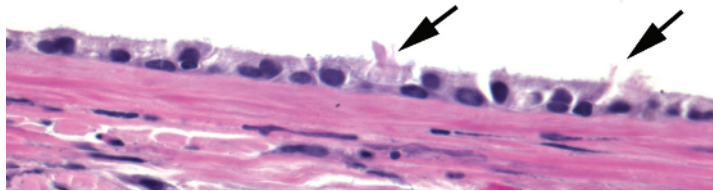
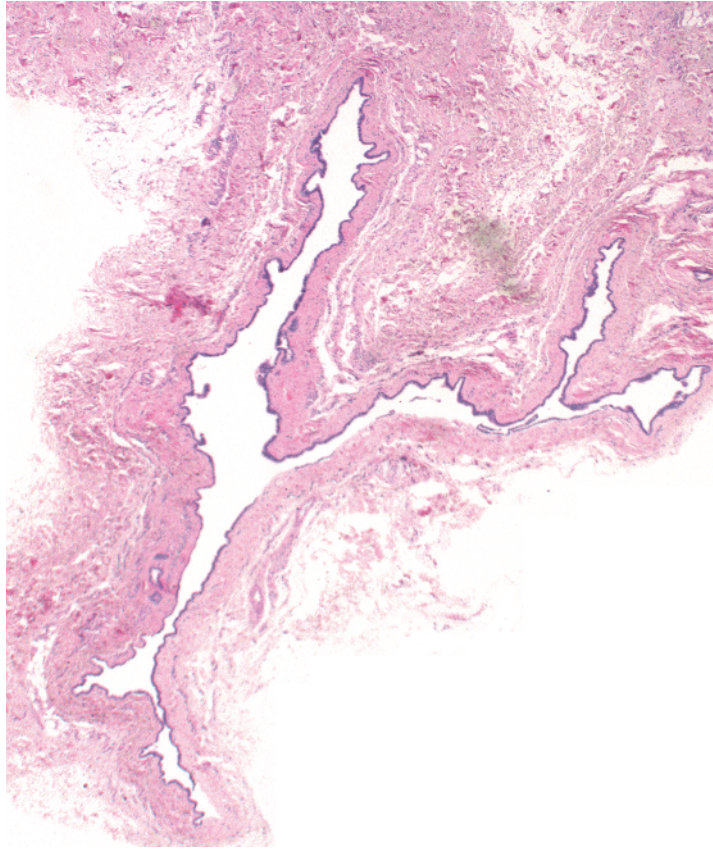


-
- Space with a lining
 - “Lining” is not a true epithelial layer but is cartilage
 - Centrally, there is degeneration of cartilage

Auricular pseudocyst

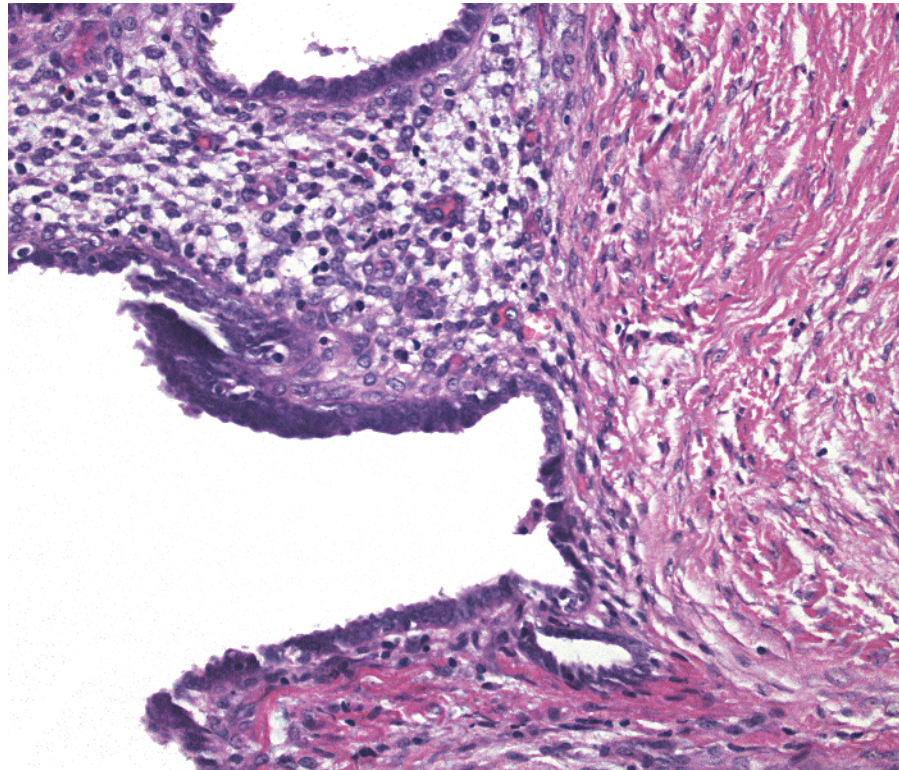
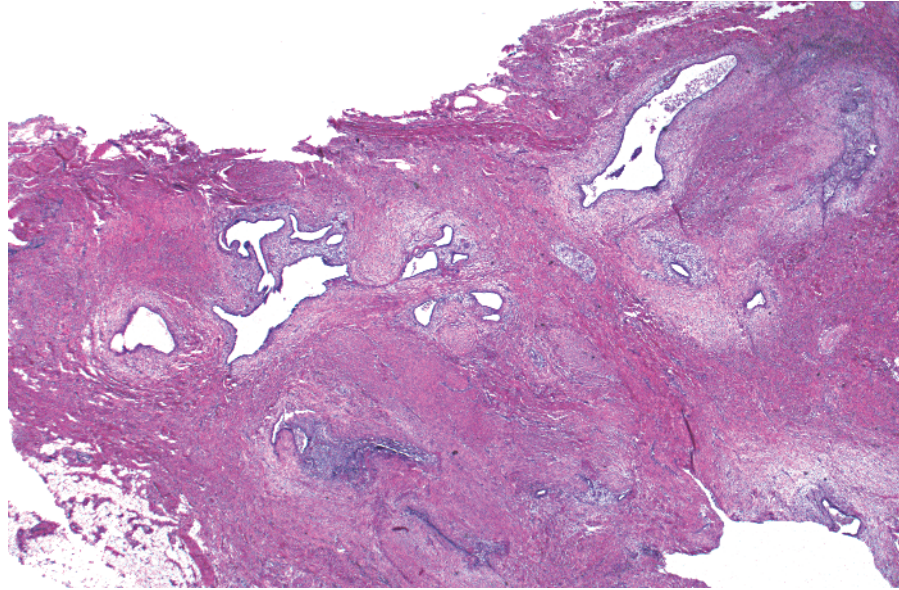


-
- Space with a lining
 - Lining composed of squamous or sometimes cuboidal/columnar epithelium often with squamous metaplasia
 - Prominent lymphoid follicles in wall

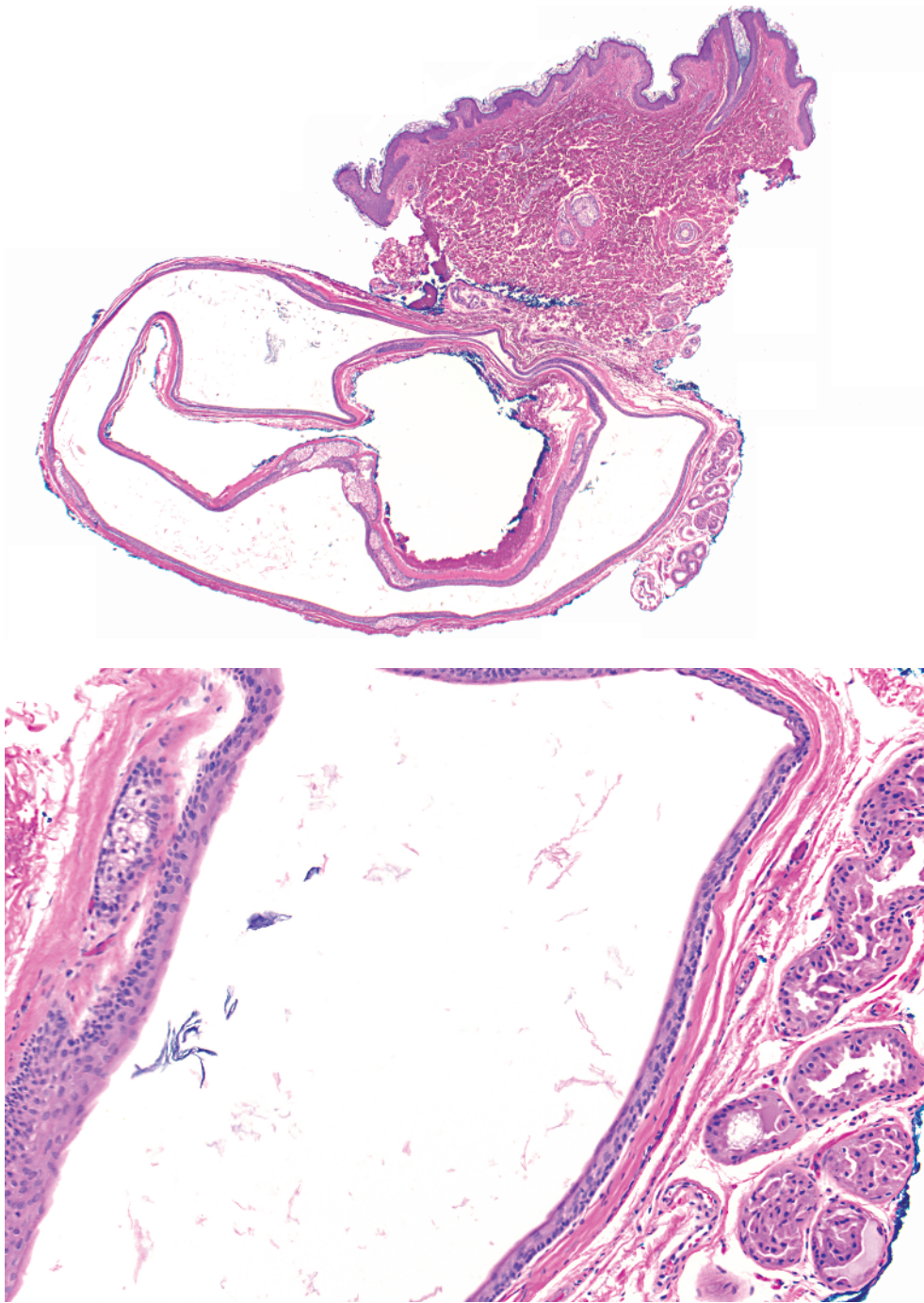


-
- Space with a lining
 - Lining composed of cuboidal/columnar epithelium with cilia (arrows)

Cutaneous ciliated cyst

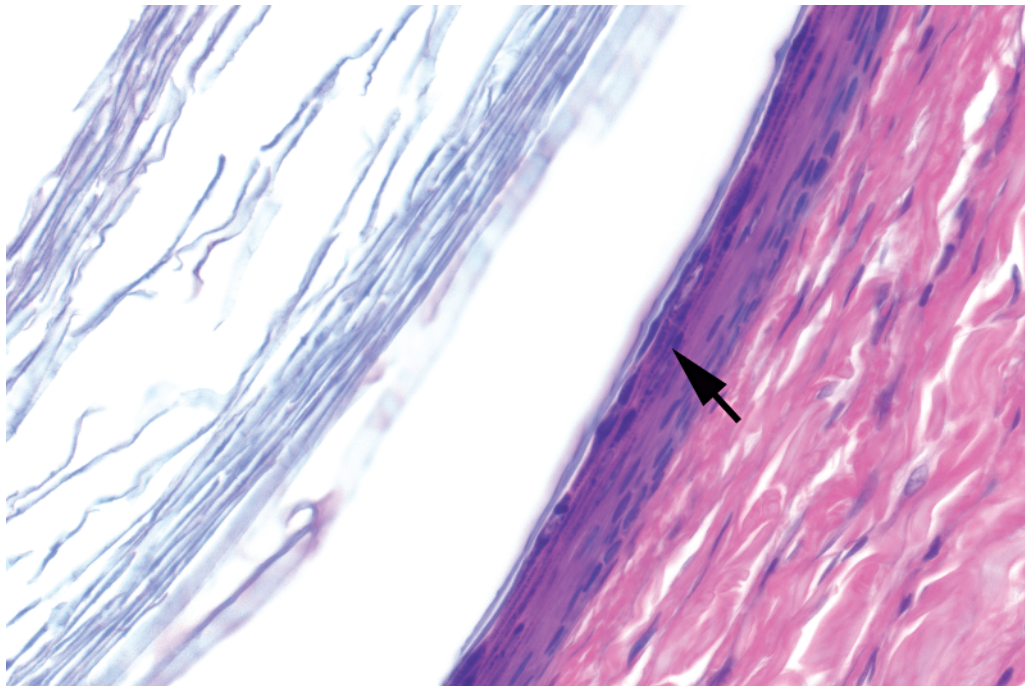
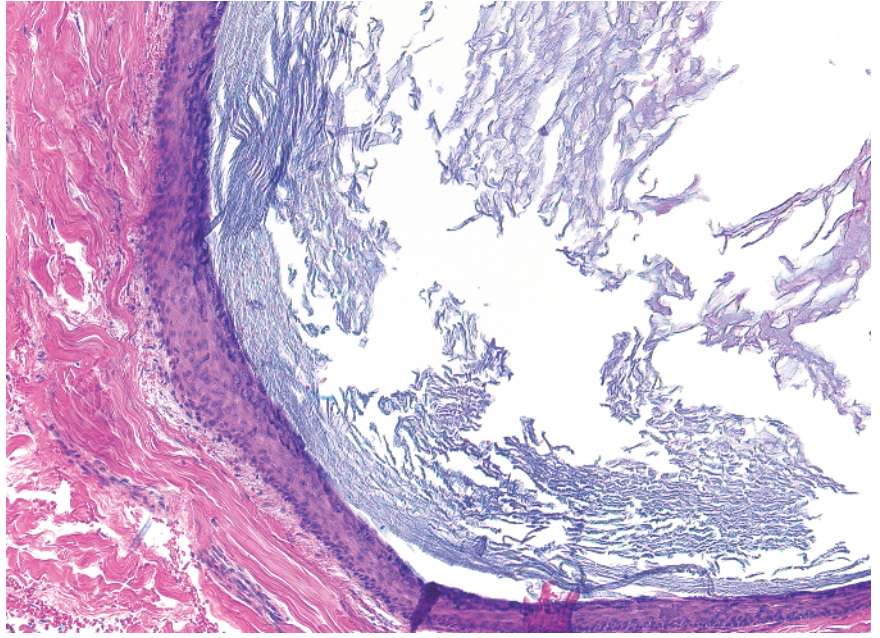
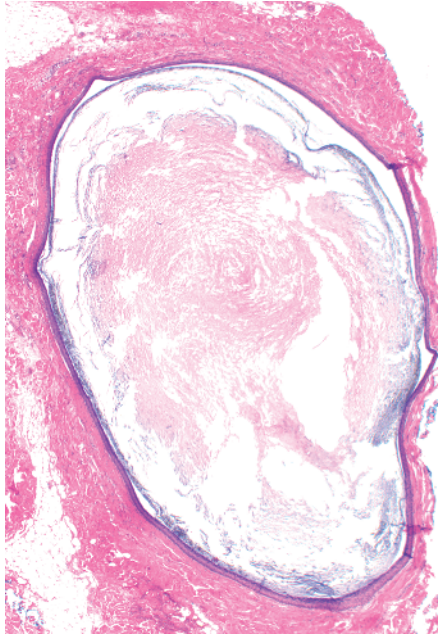


-
- Space with a lining
 - Spaces embedded in a fibrovascular stroma (endometrial stroma)
 - Lining composed of crowded blue cells
 - Hemosiderin deposits common in stroma

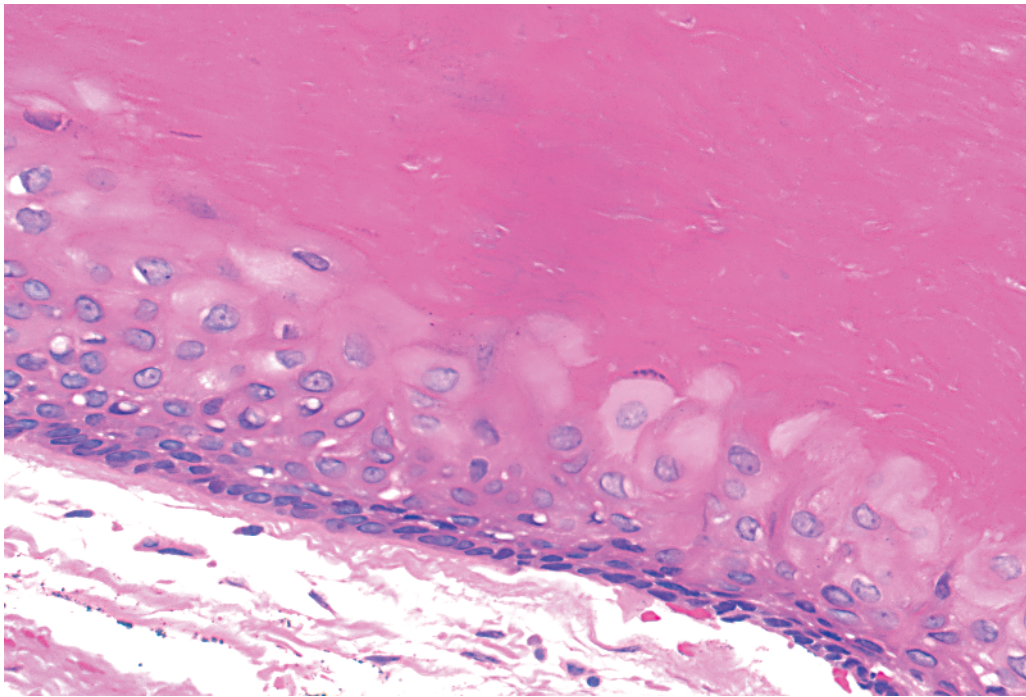
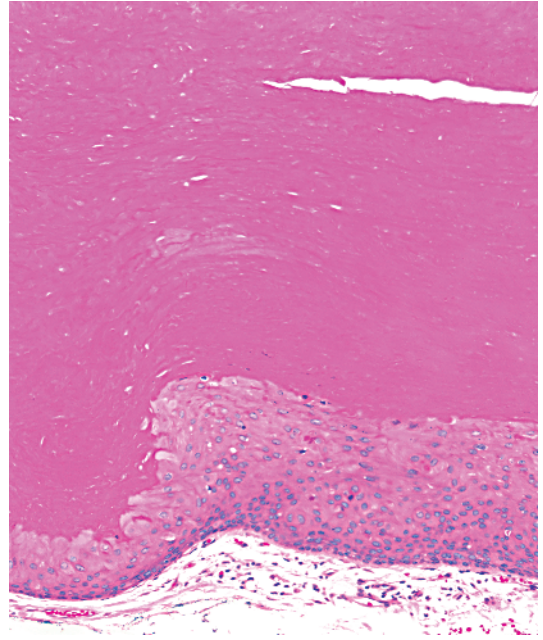
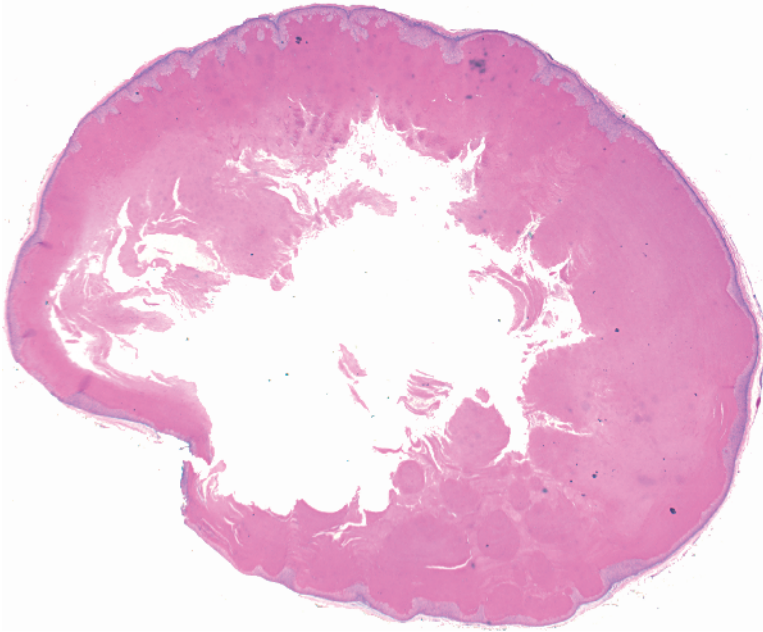


- Space with a lining
- Lining composed of squamous epithelium
- Walls contain adnexal structures

Dermoid cyst

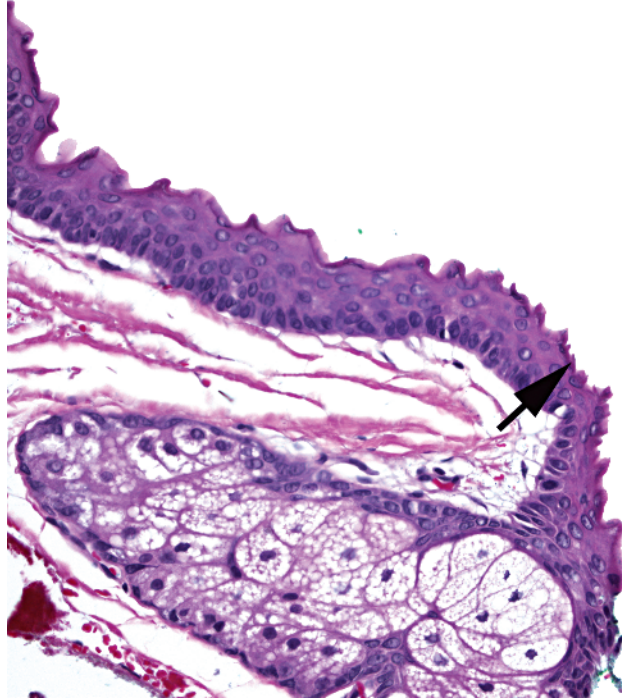
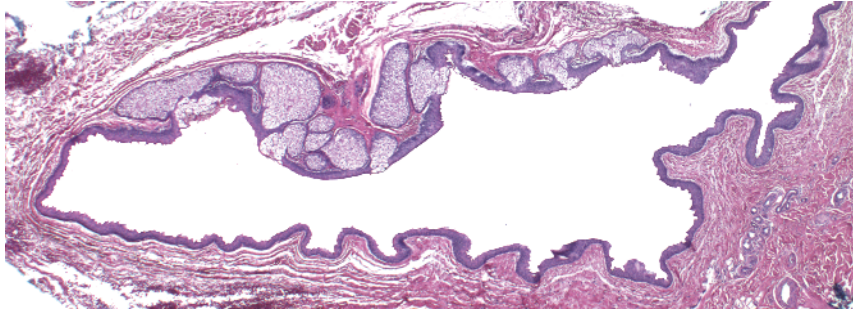


- Space with a lining
- Lining composed of squamous epithelium with a granular layer (arrow)
- Cyst contents composed of flakes of keratin

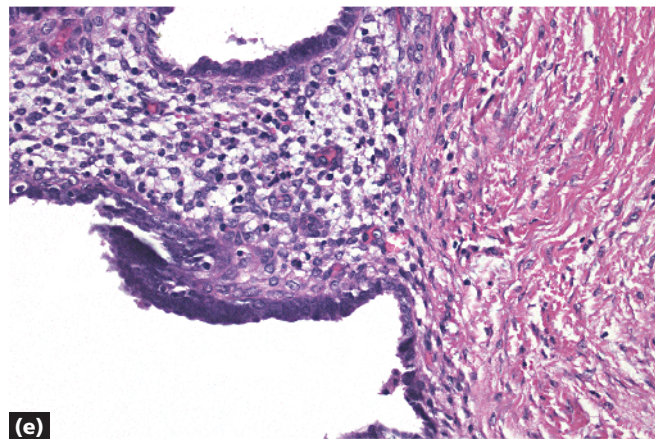
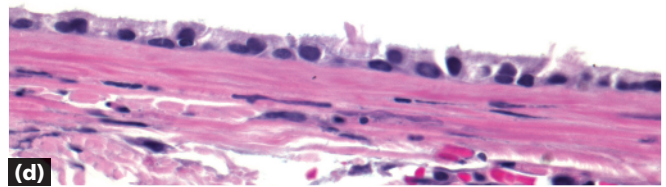
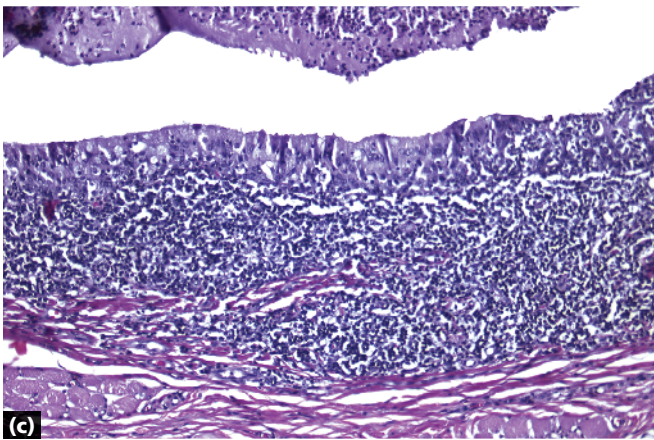
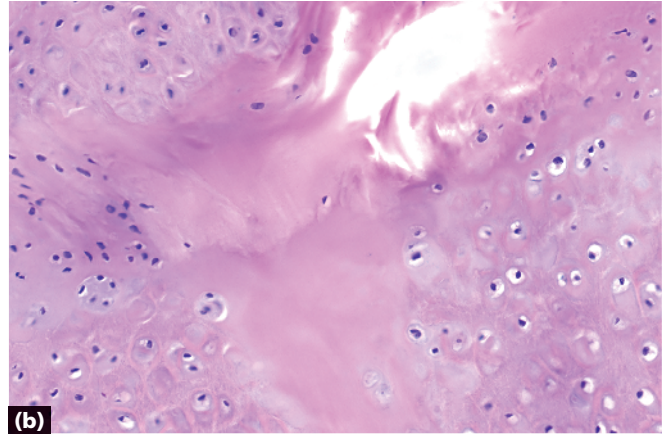
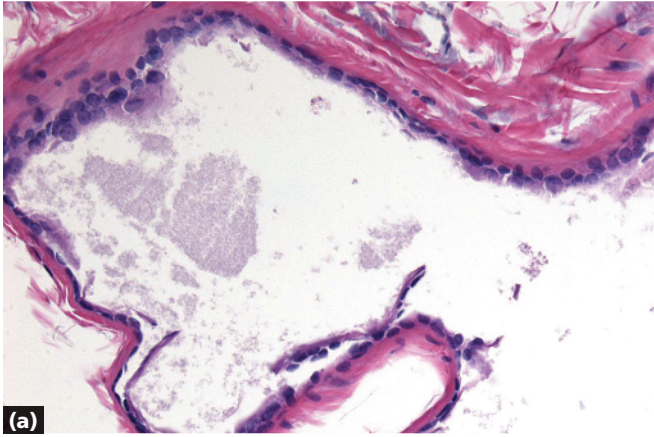


- Space with a lining
- Lining composed of squamous epithelium without a granular layer
- Cyst contents composed of dense pink keratin

Pilar cyst



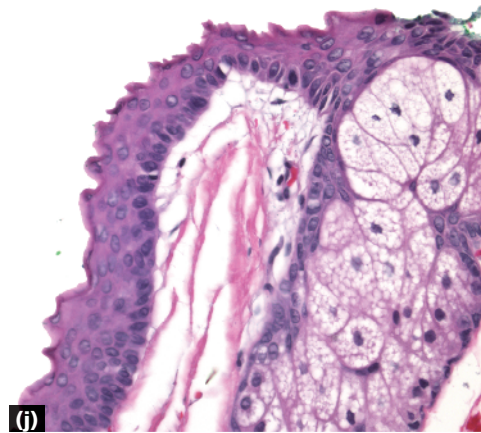
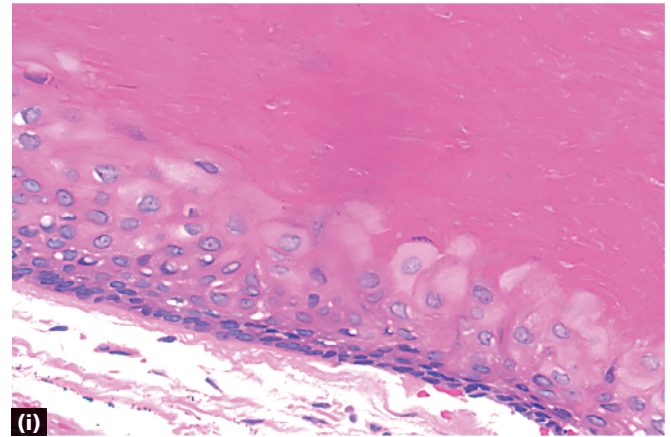
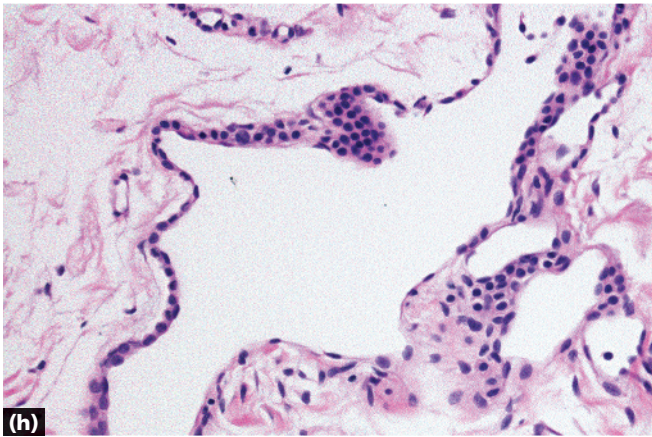
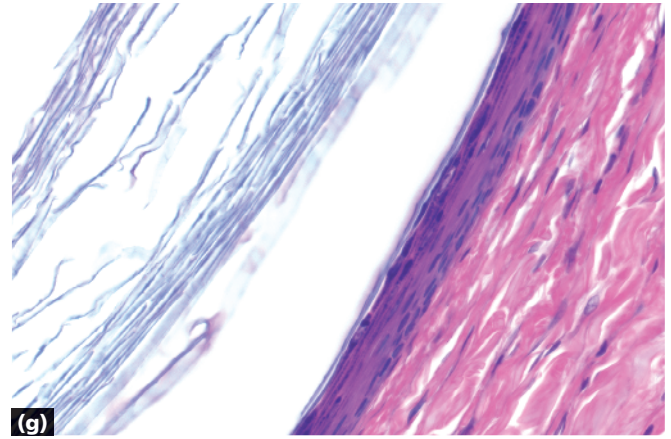
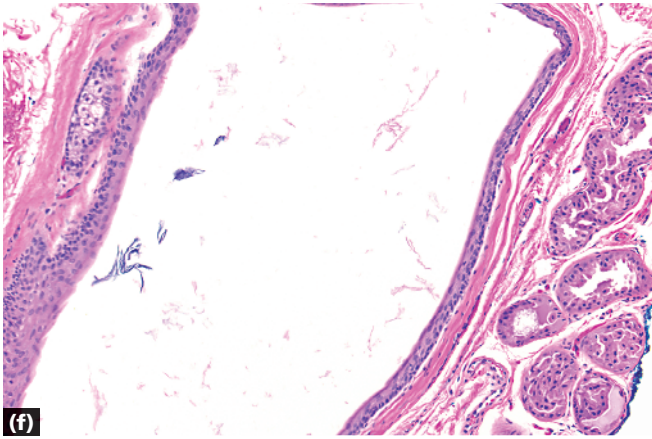
-
- Space with a lining
 - Lining composed of layered epithelium with a bright pink crenulated keratin (arrow)
 - Sebaceous glands in wall



- a** Apocrine hidrocystoma: decapitation secretion
- b** Auricular pseudocyst: degeneration surrounded by cartilage
- c** Branchial cleft cyst: prominent lymphoid follicles in wall

- d** Cutaneous ciliated cyst: columnar epithelium with cilia; no structures in wall
- e** Cutaneous endometriosis: fibrovascular stroma with glands

Key differences



f Dermoid cyst: sebaceous glands and other adnexal structures in wall

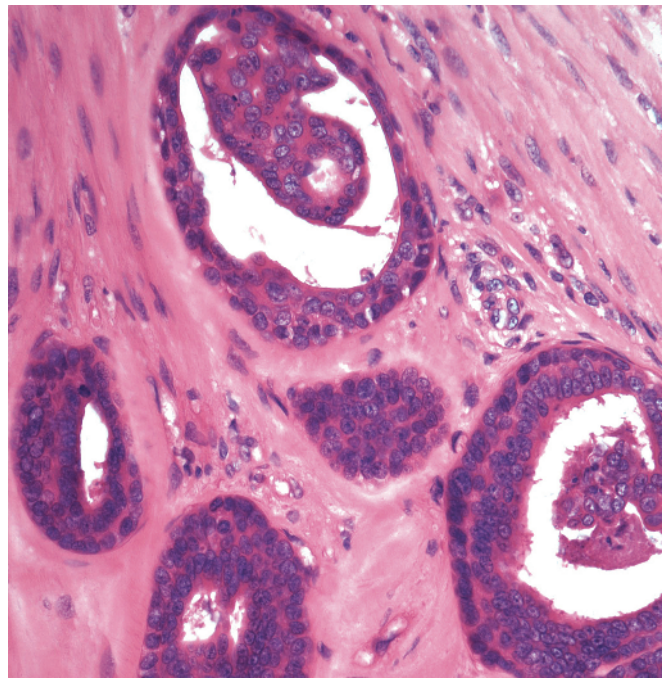
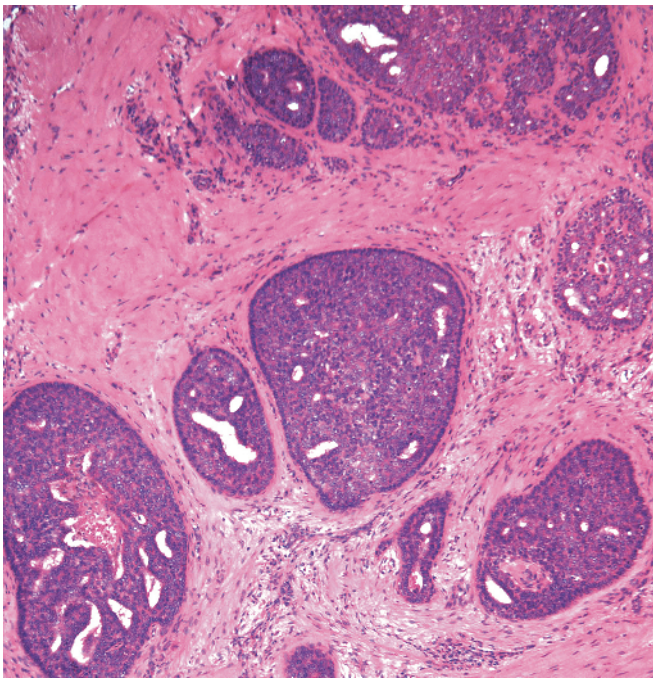
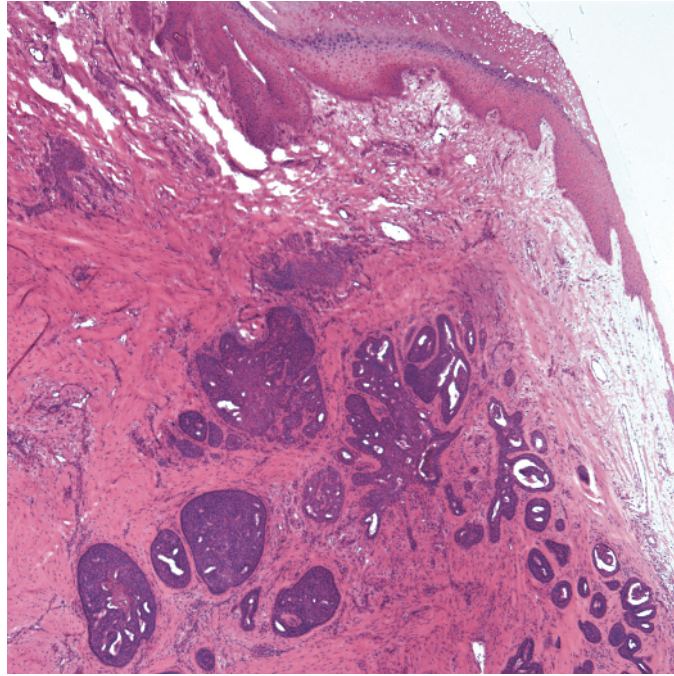
g Epidermal inclusion cyst: epithelium with granular layer, flakes of keratin in center

h Glomovenous malformation (glomangioma): monomorphic, cuboidal blue cells (see also glomus tumor on page 282)

i Pilar cyst: epithelium without granular layer, dense keratin in center

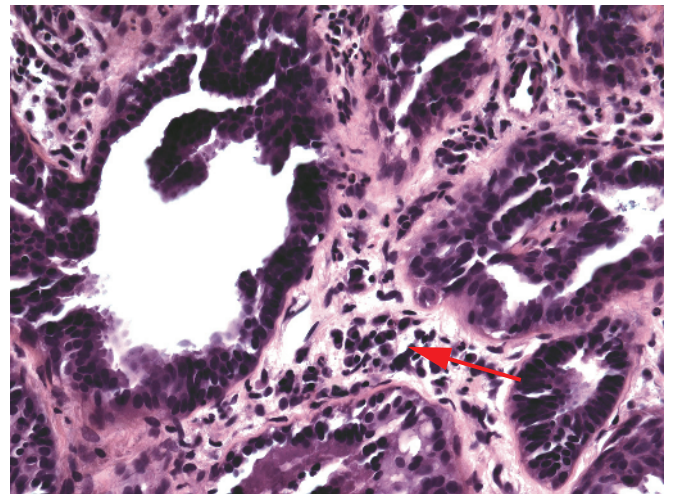
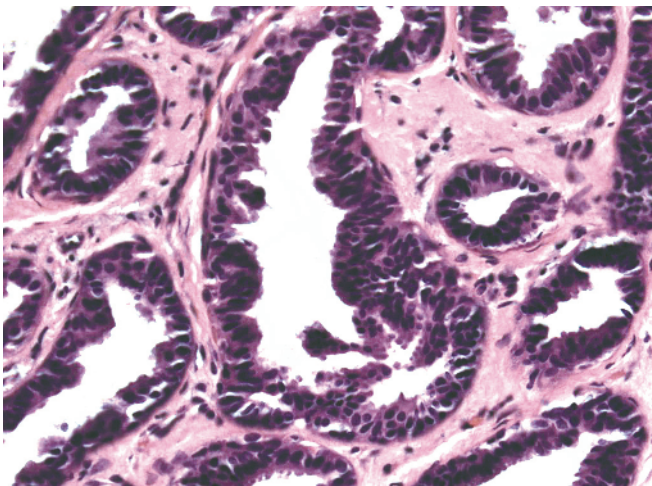
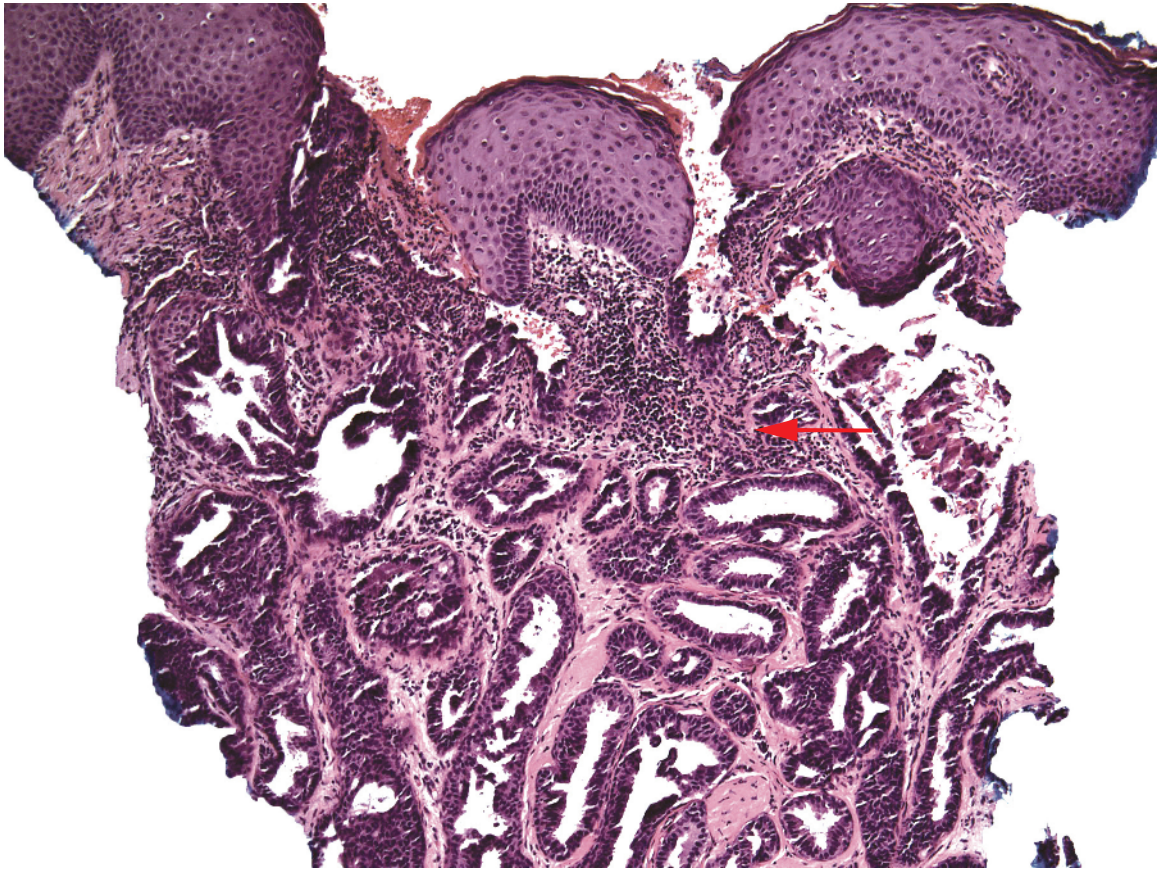
j Steatocystoma: crenulated keratin lining the cyst; sebaceous glands in wall

Note Bronchogenic cysts are uncommon, and are diagnosed by clinical history and the presence of columnar epithelium +/- cilia, +/- cartilage in wall; venous lakes are common and are composed of flattened endothelial cells with erythrocytes in the space.



- Papillated dermal tumor
- Disordered layers of epithelium in large papillations with some tubules
- Variable cytological atypia and mitotic figures
- Acral location

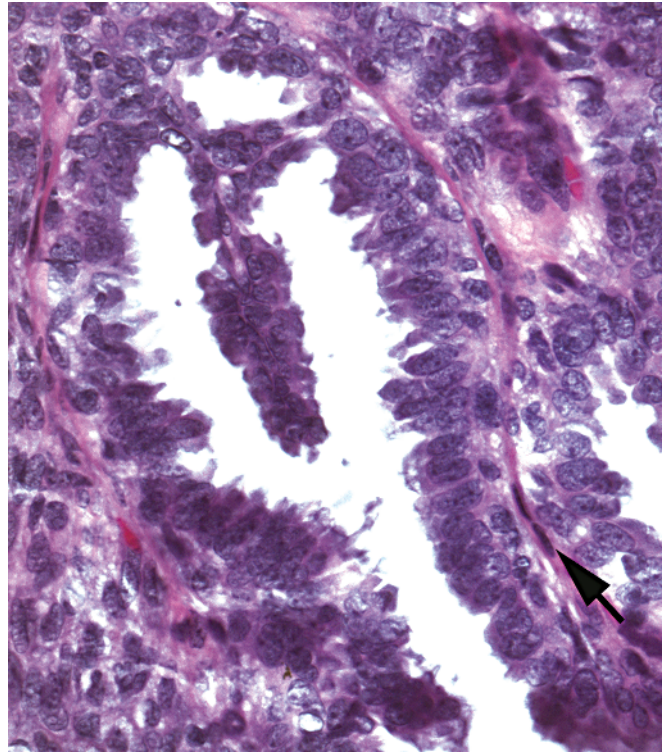
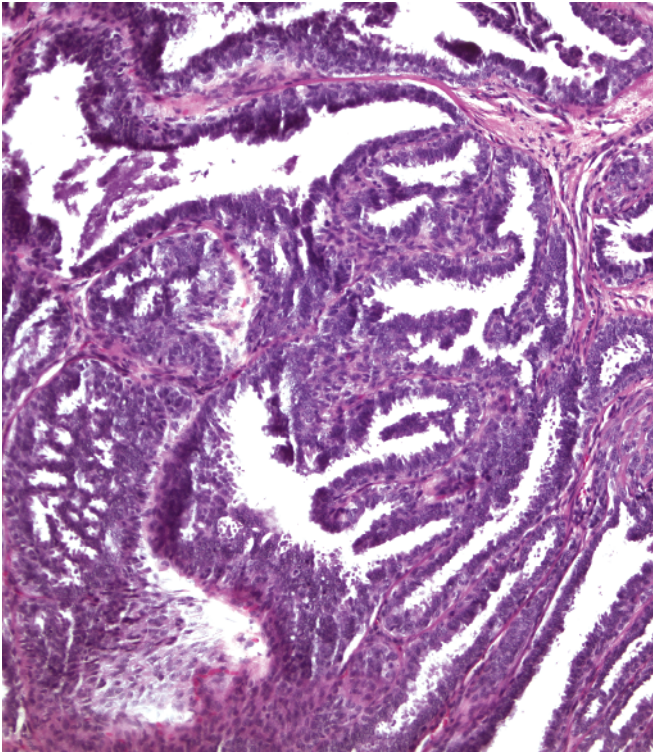
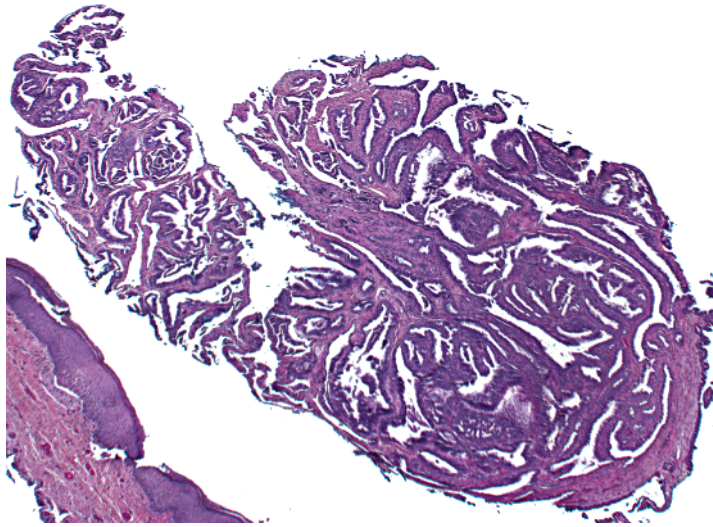
Aggressive digital papillary adenocarcinoma



- Papillated dermal tumor
- Nipple can sometimes be identified by fascicles of smooth muscle in dermis
- Circular islands, some cystic, and tubules
- Compressed myoepithelial cells at periphery of islands/ tubules

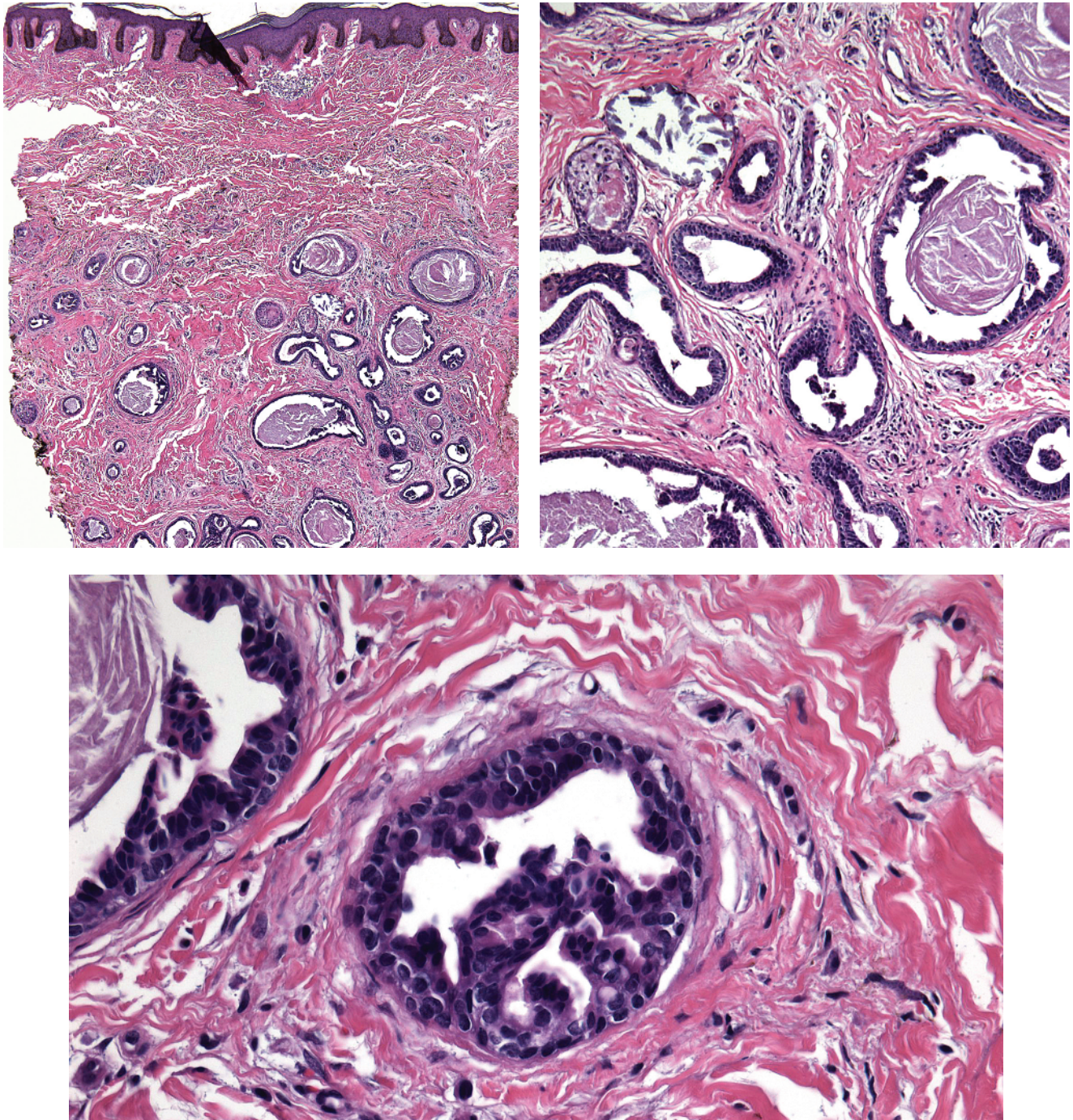
- Decapitation secretion often evident
- Resembles syringocystadenoma papilliferum (stromal plasma cells [arrows]) or tubular apocrine adenoma

Erosive adenomatosis of the nipple (nipple adenoma)

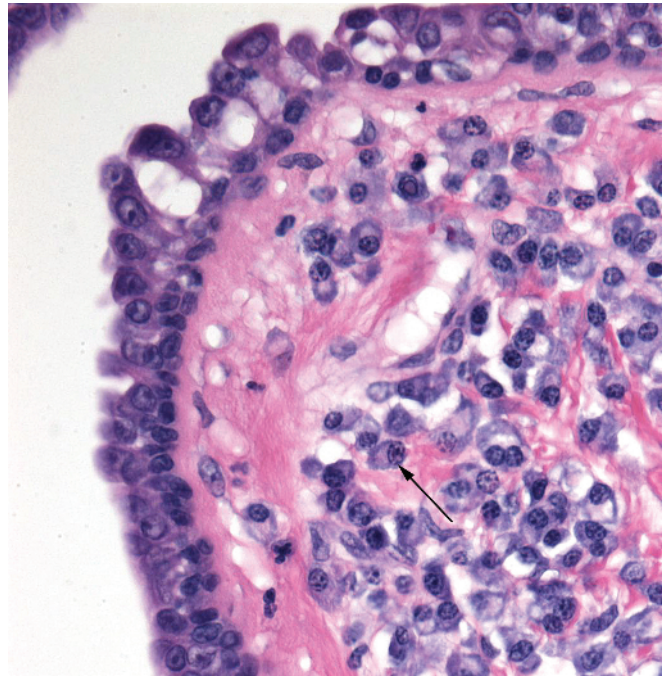
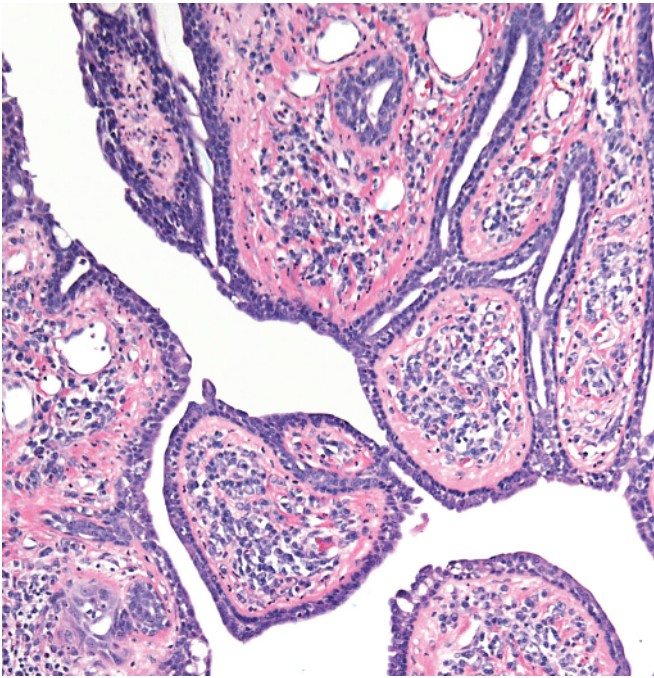
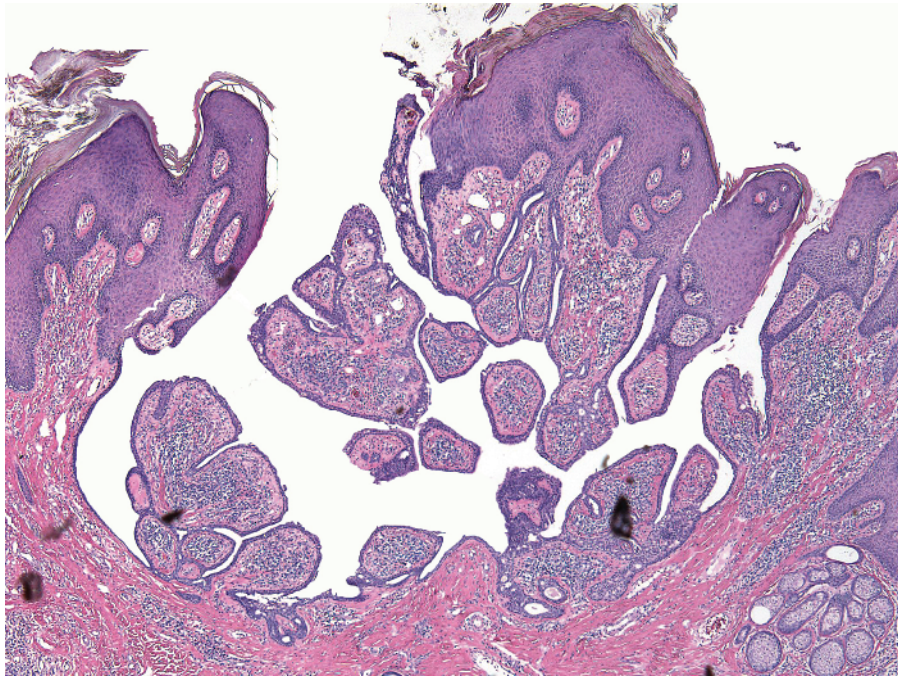


- Papillated dermal tumor
- Finger-like projections have cores of collagen/fibroblasts (arrow)
- No connection to epidermis

Hidradenoma papilliferum

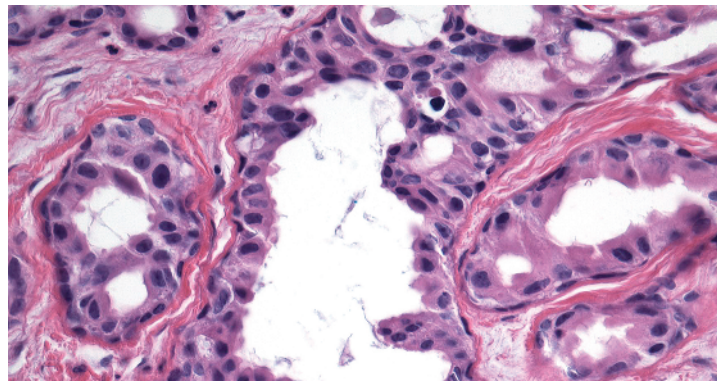
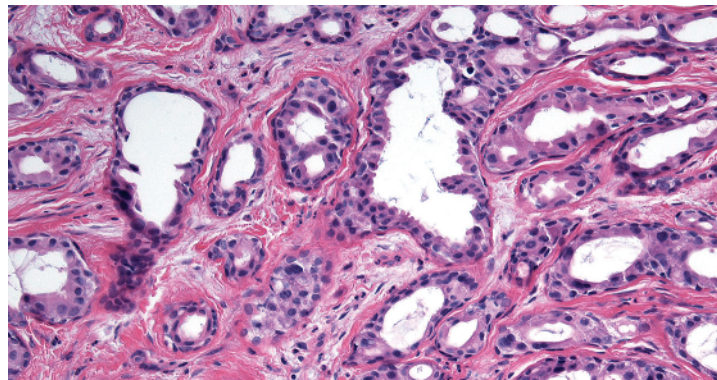
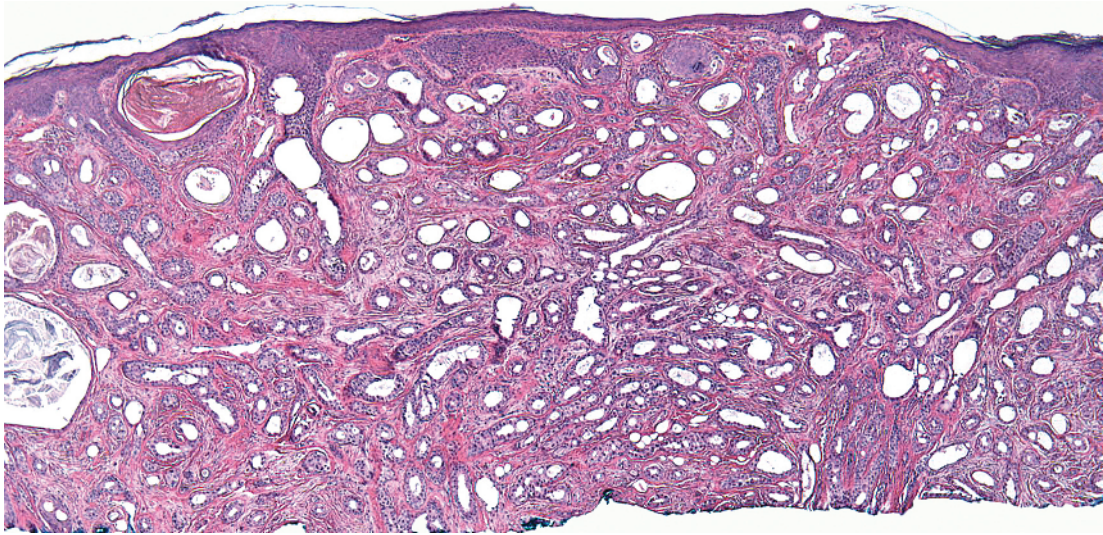


- Islands of epithelium with papillated projections
- With or without epidermal connection
- Duct-like spaces lined by eosinophilic cuticle
- Overlaps with tubular apocrine adenoma

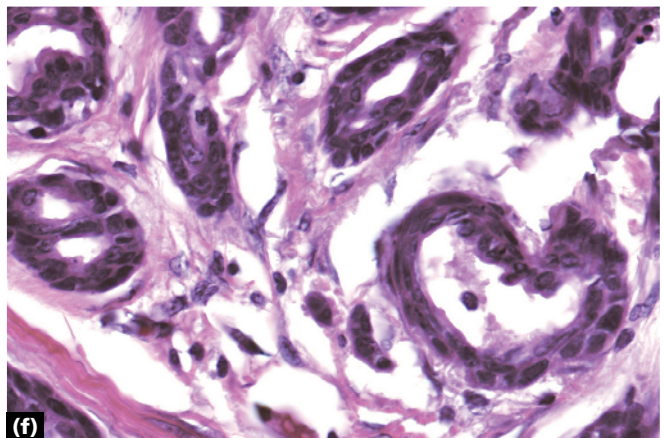
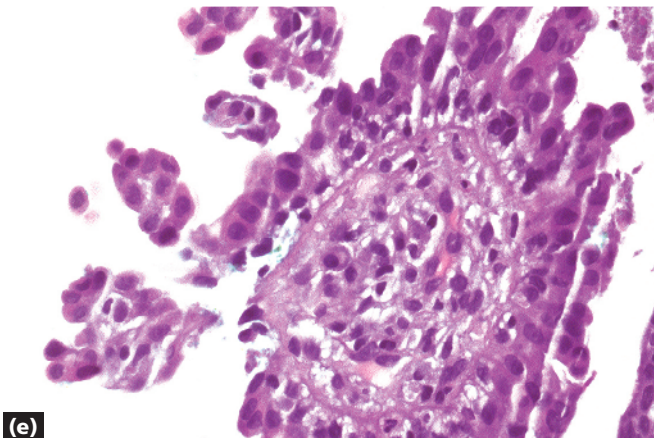
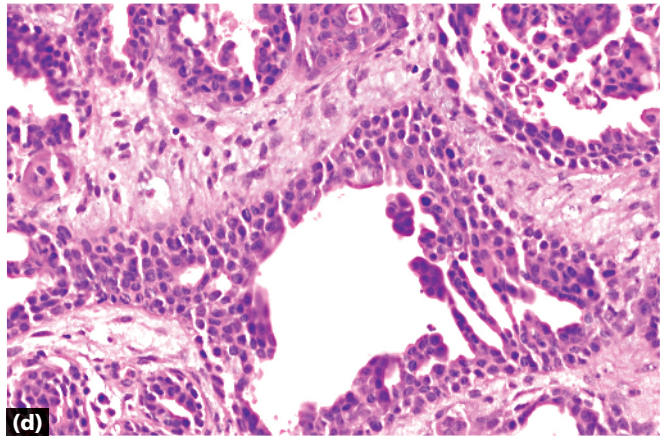
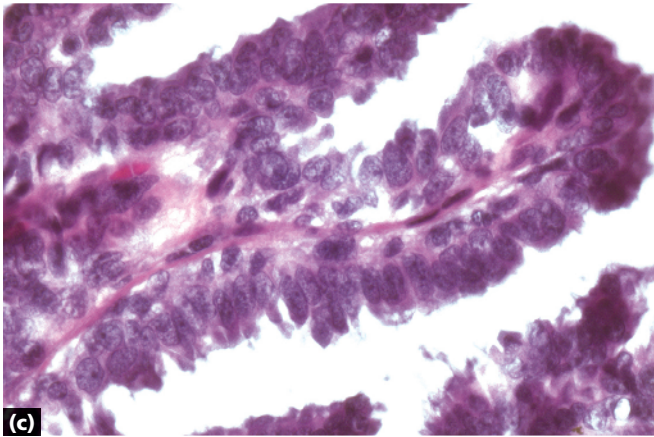
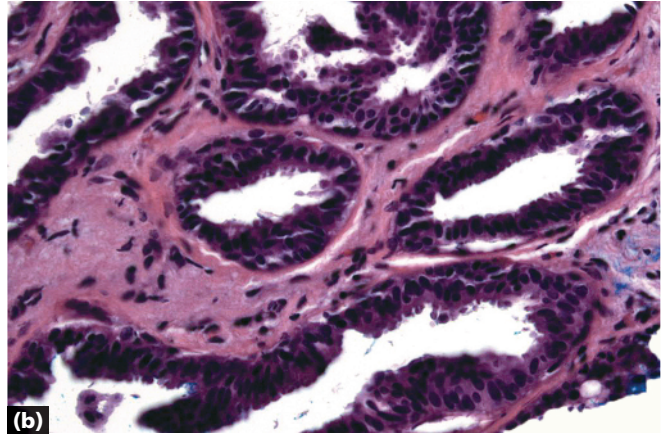
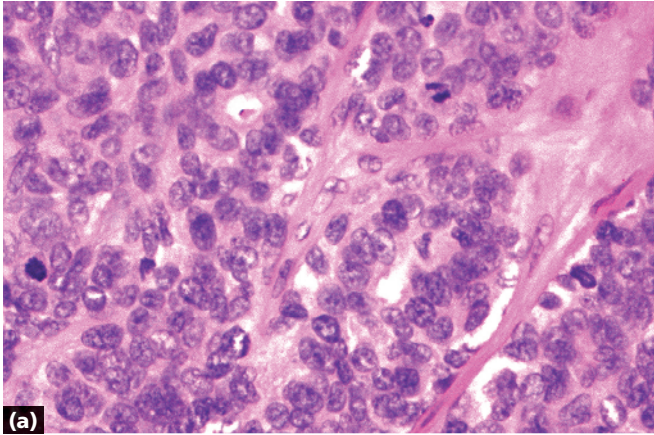


- Papillated dermal tumor
- Papillations contain numerous plasma cells (arrow)
- Tumor often connected to epidermis

Syringocystadenoma papilliferum



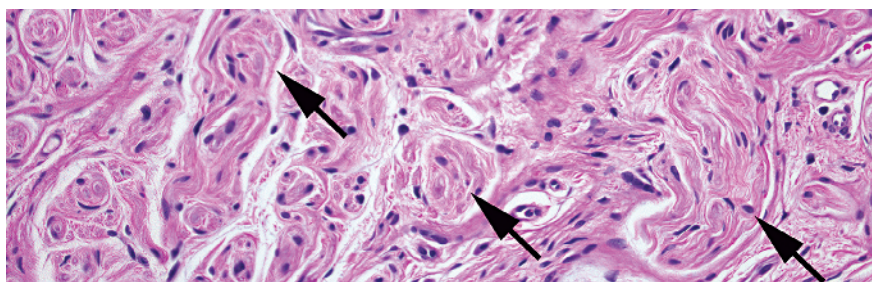
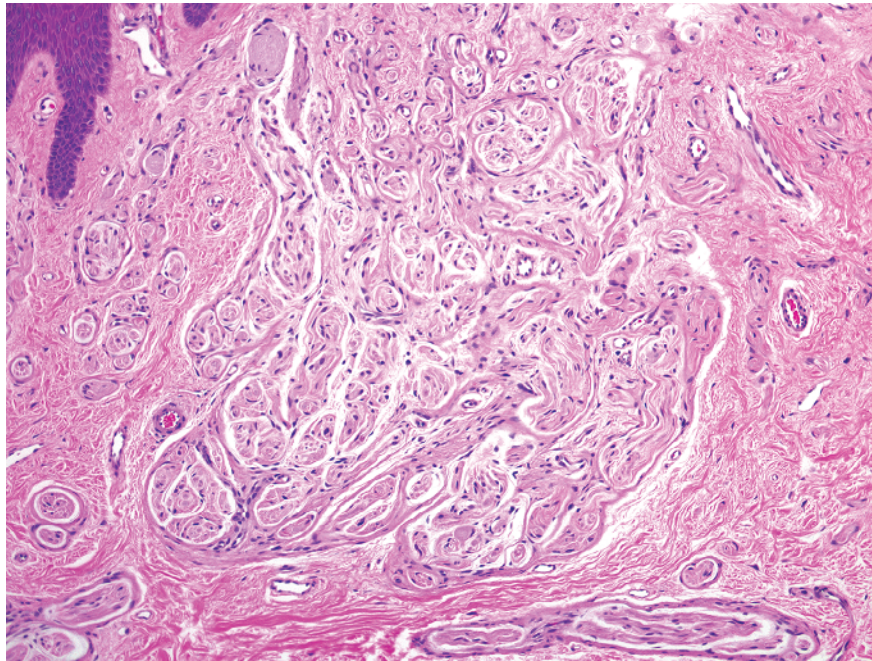
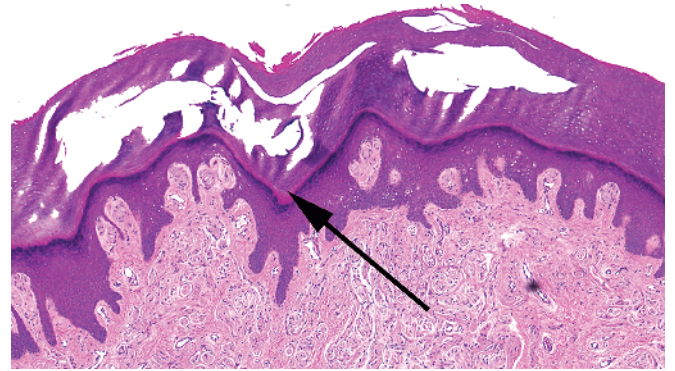
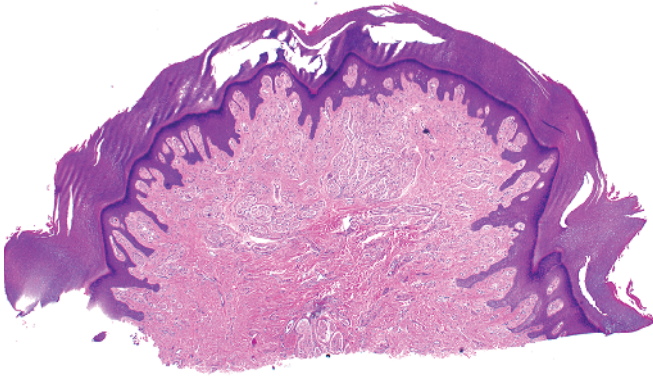
-
- Papillated dermal tumor
 - Evidence of decapitation secretion
 - Overlaps with papillary eccrine adenoma



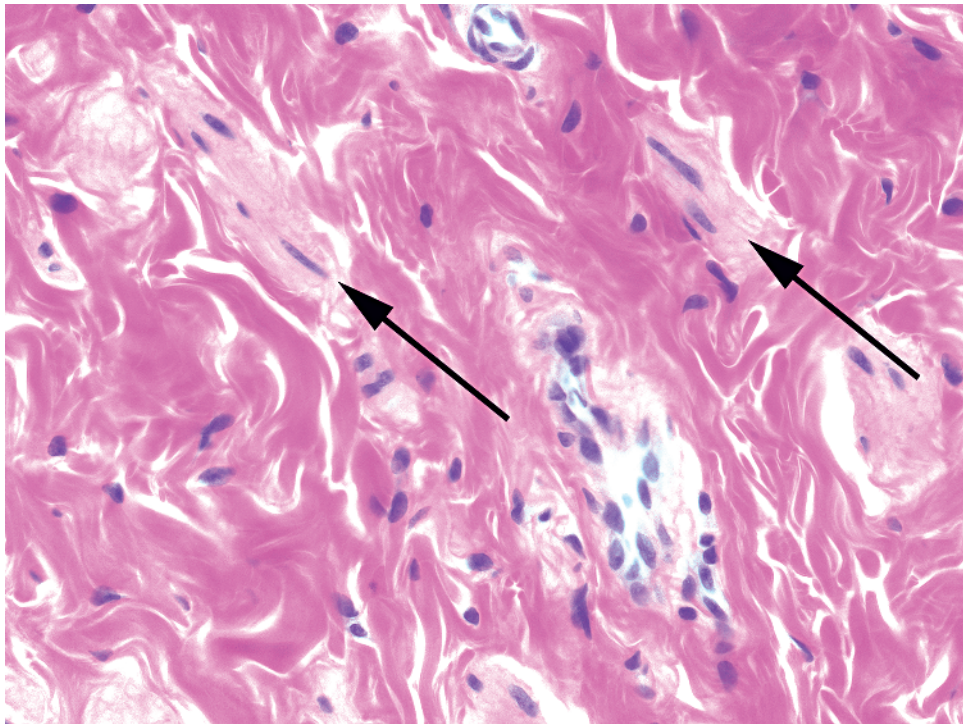
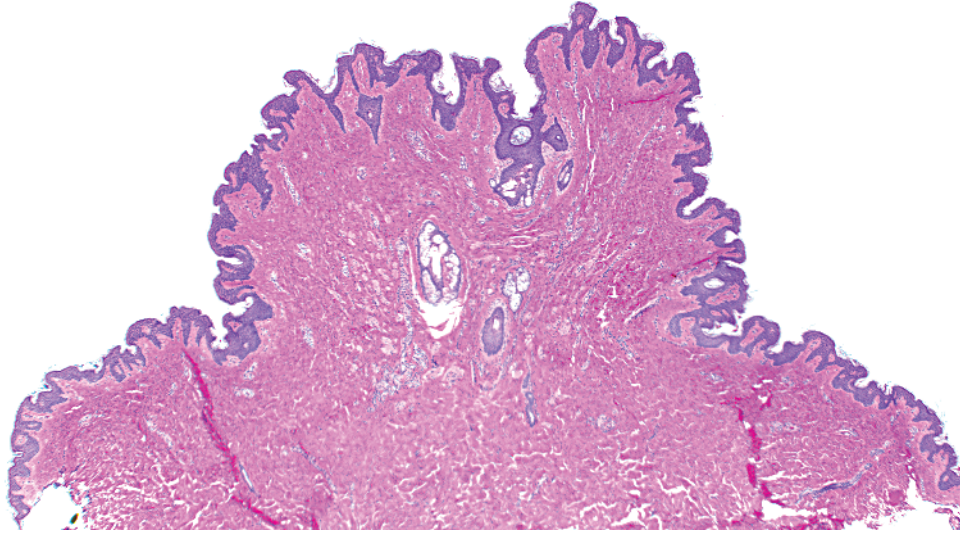
- a** Aggressive digital papillary adenocarcinoma: large tumor, atypical cells and mitoses piled up
- b** Florid papillomatosis (erosive adenomatosis) of the nipple (nipple adenoma): resembles syringocystadenoma papilliferum but fewer plasma cells; nipple may be identified by smooth muscle bundles in dermis
- c** Hidradenoma papilliferum: thin papillations with fibrovascular cores

- d** Papillary eccrine adenoma: islands of epithelium with papillated areas
- e** Syringocystadenoma papilliferum: fat papillations with plasma cells in cores
- f** Tubular apocrine adenoma: decapitation secretion and papillations within islands

Key differences

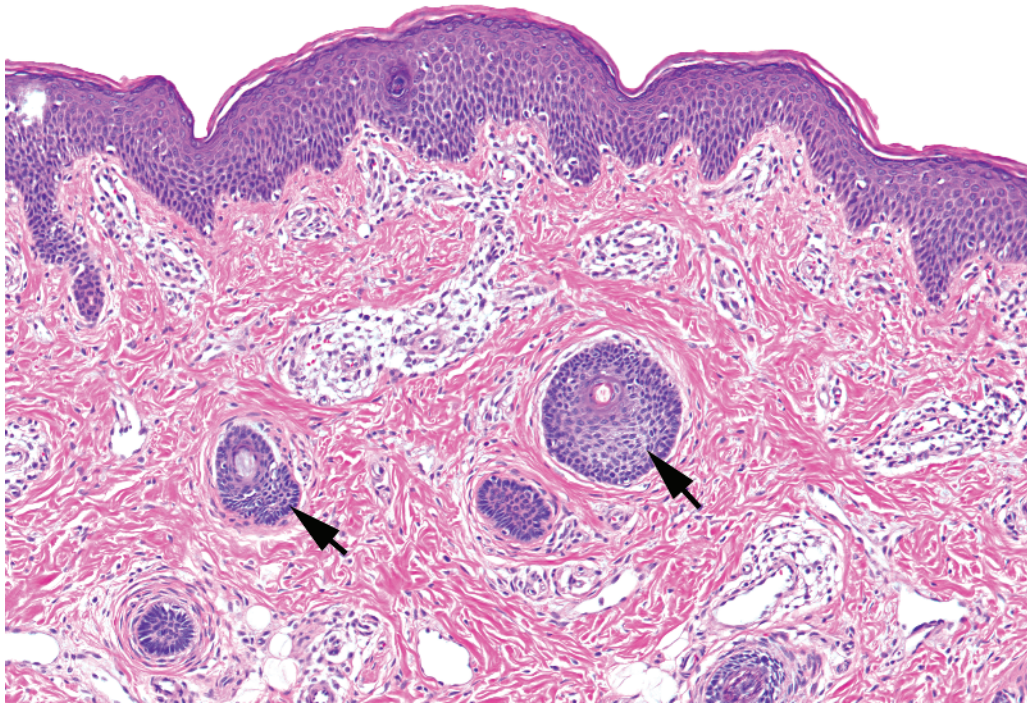
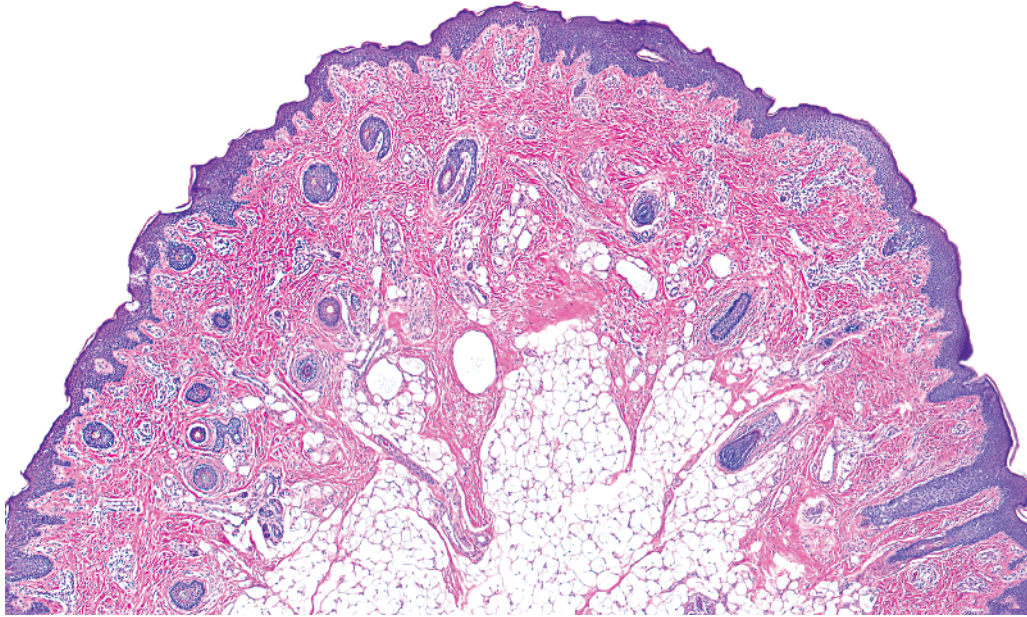


- Polypoid shape
- Acral skin (thick stratum corneum with stratum lucidum [long arrow])
- Dermal nerve bundles (short arrows)

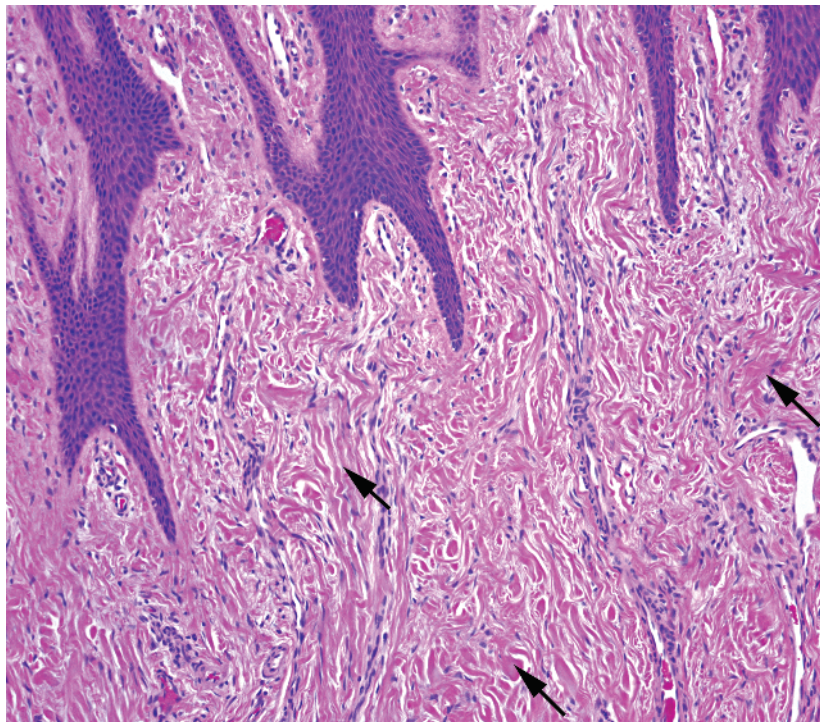
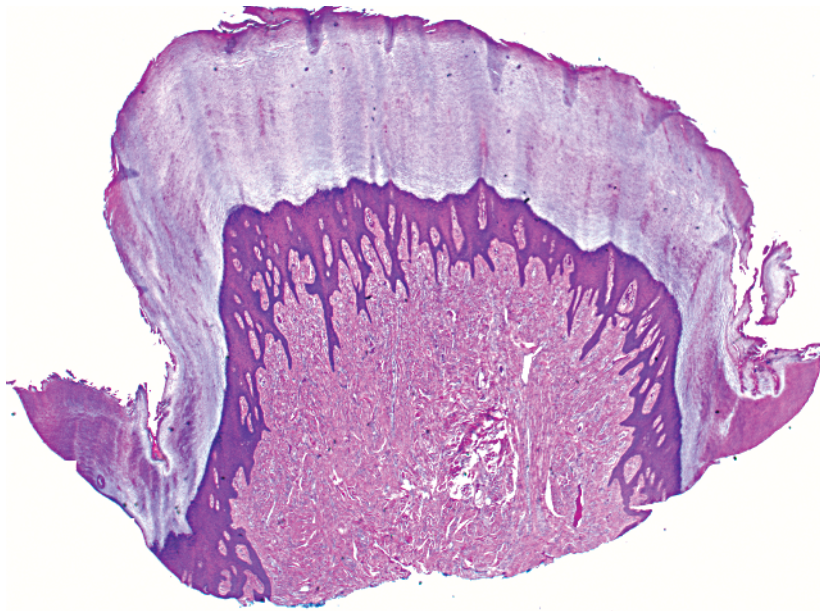


-
- Polypoid shape
 - May see a slight invagination of surface epidermis with underlying sebaceous glands
 - Surface epidermis often slightly acanthotic and hyperpigmented
 - May see mammary ducts or apocrine glands deep
 - Dermis with numerous smooth muscle bundles (arrows)

Accessory nipple

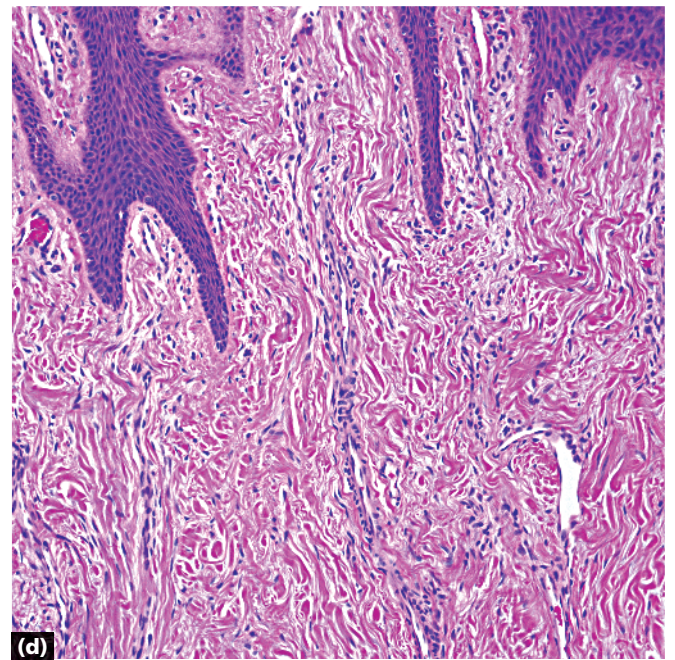
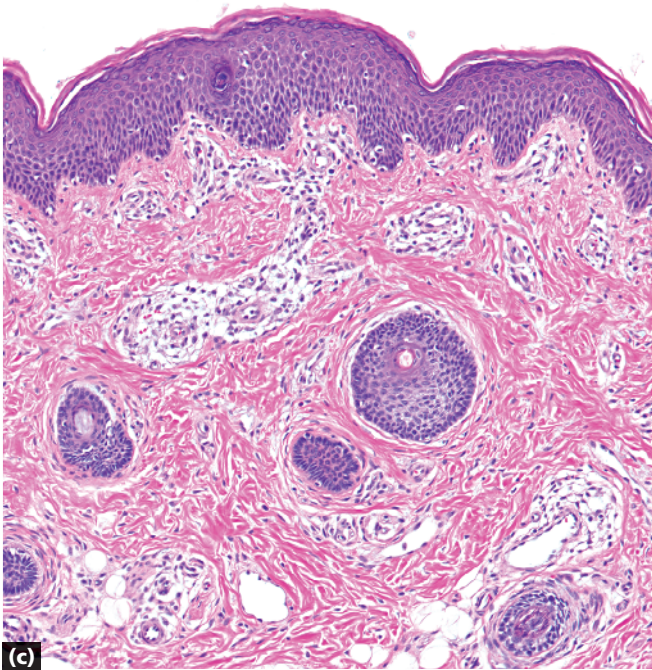
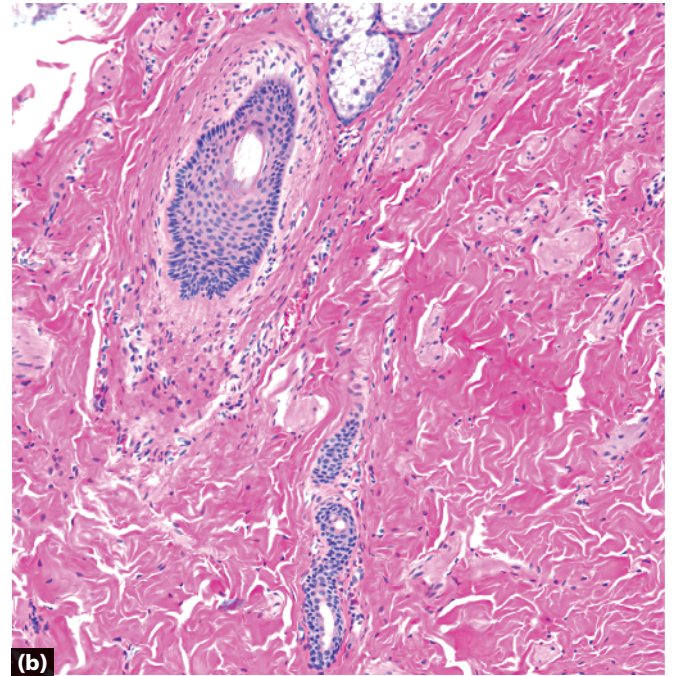
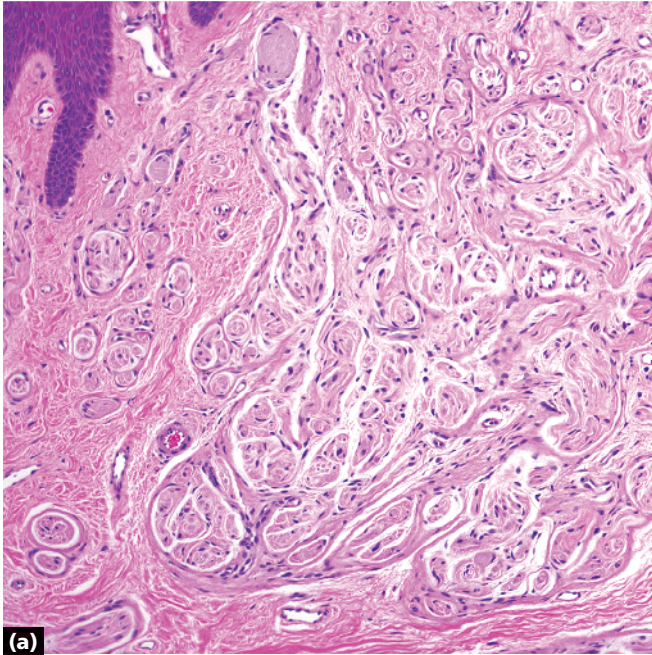


- Polypoid shape
- Thin epidermis
- Vellus hairs (arrows)
- Cartilage not always present
- Differential diagnosis of numerous vellus hairs
 - Eyelid/earlobe/sometimes facial skin
 - Vellus hair nevus



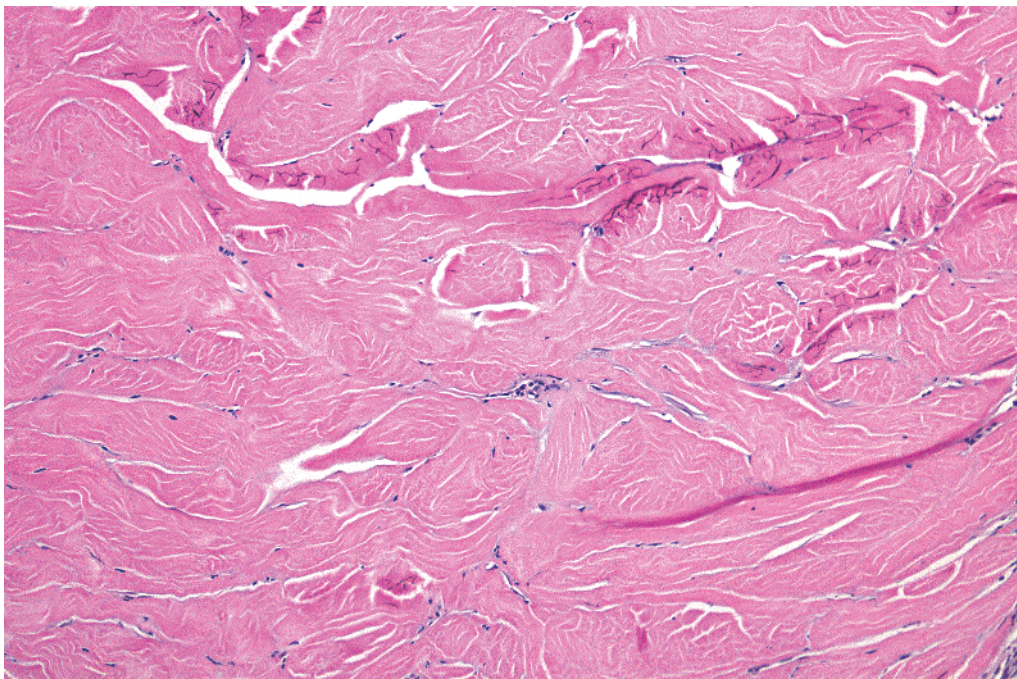
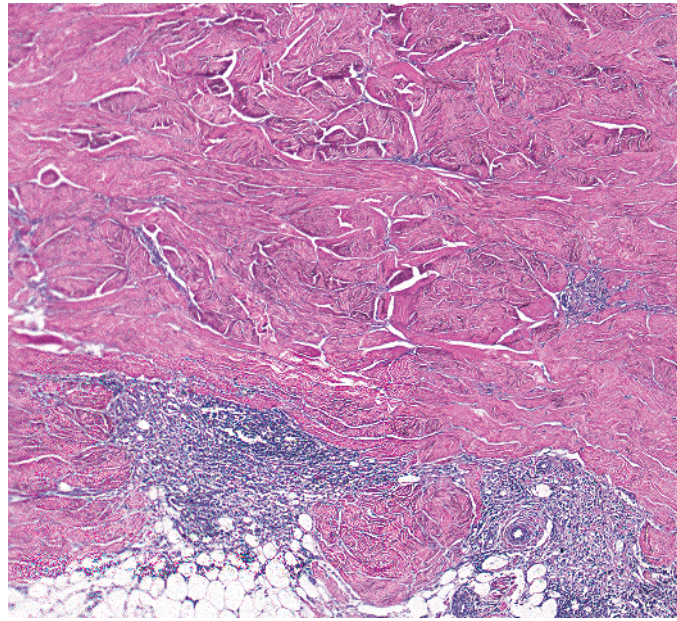
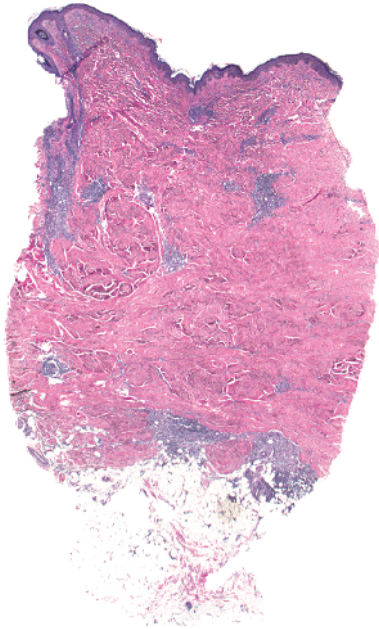
-
- Polypoid shape
 - Acral skin
 - Fibrovascular stroma (thick collagen [arrows])

Digital fibrokeratoma

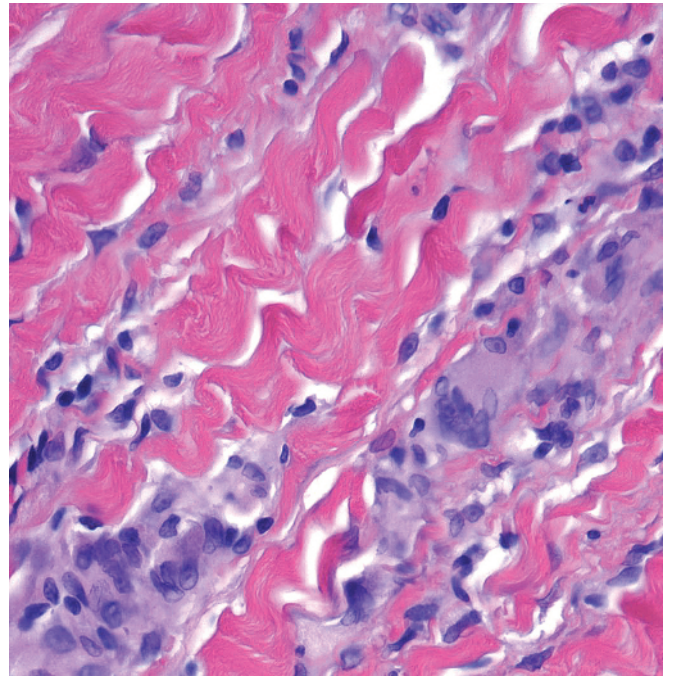
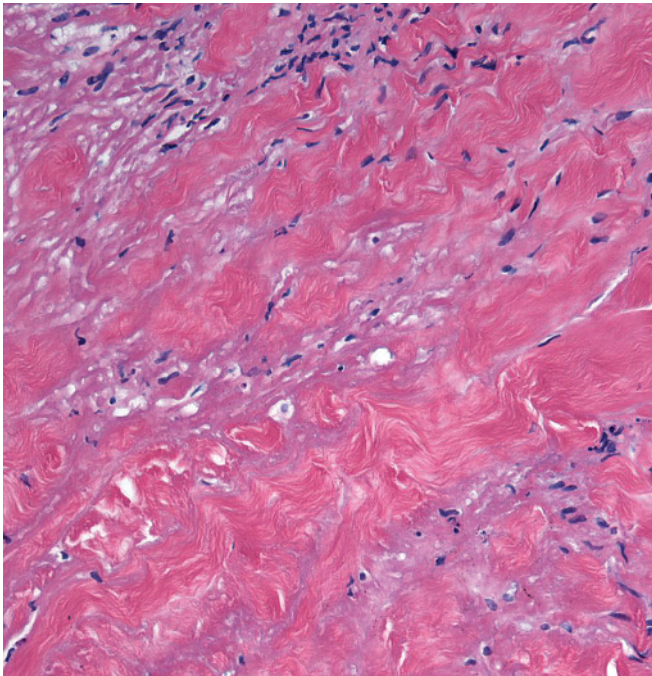
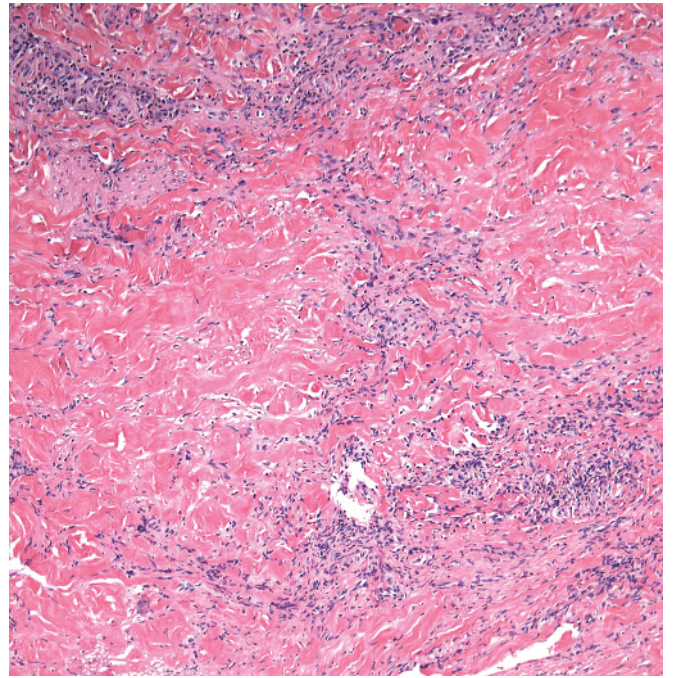
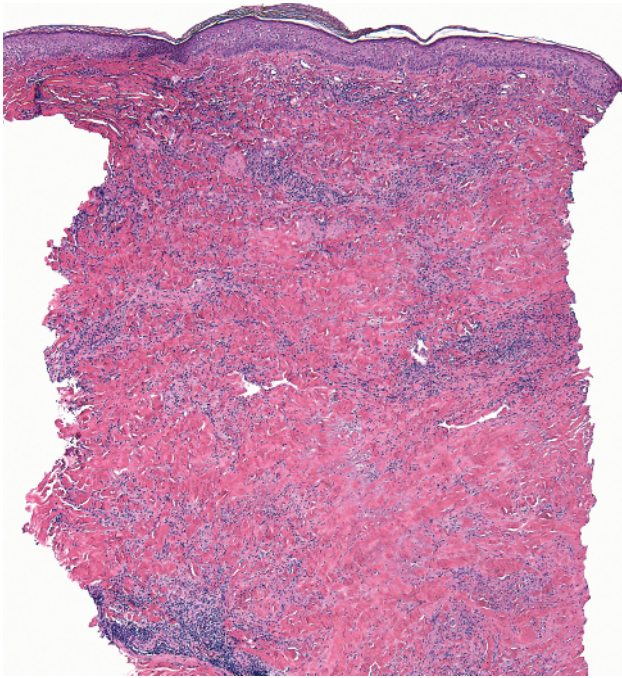


- a Accessory digit: nerve bundles in the dermis
- b Accessory nipple: sebaceous glands, mammary ducts or apocrine glands, smooth muscle bundles in the dermis
- c Accessory tragus: vellus hairs in the dermis


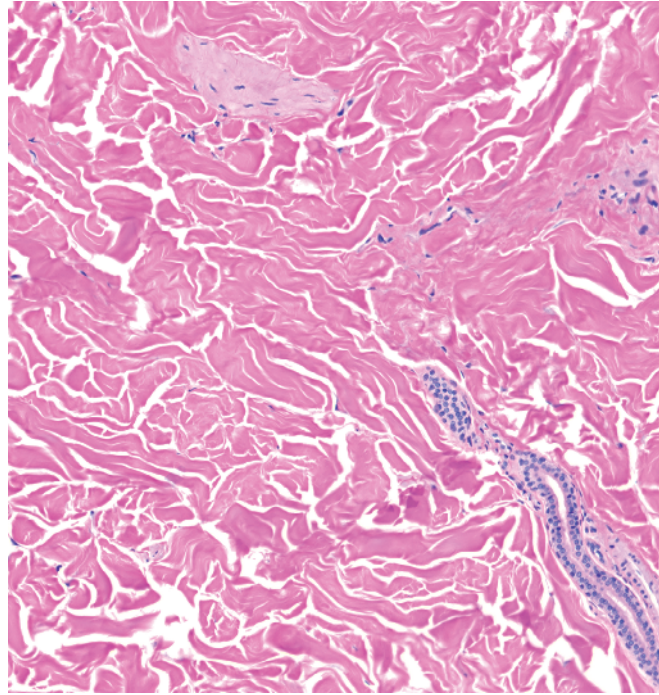
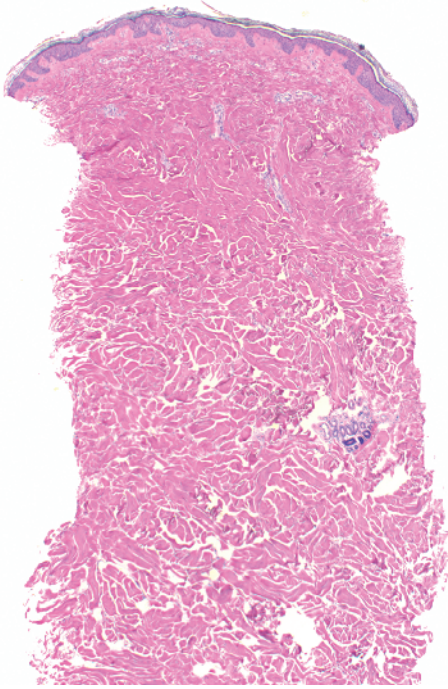
- d Digital fibrokeratoma: collagen in the dermis
- Note** Other entities may also be polypoid; for example, intradermal nevus, neurofibroma, fibrous papule, etc.



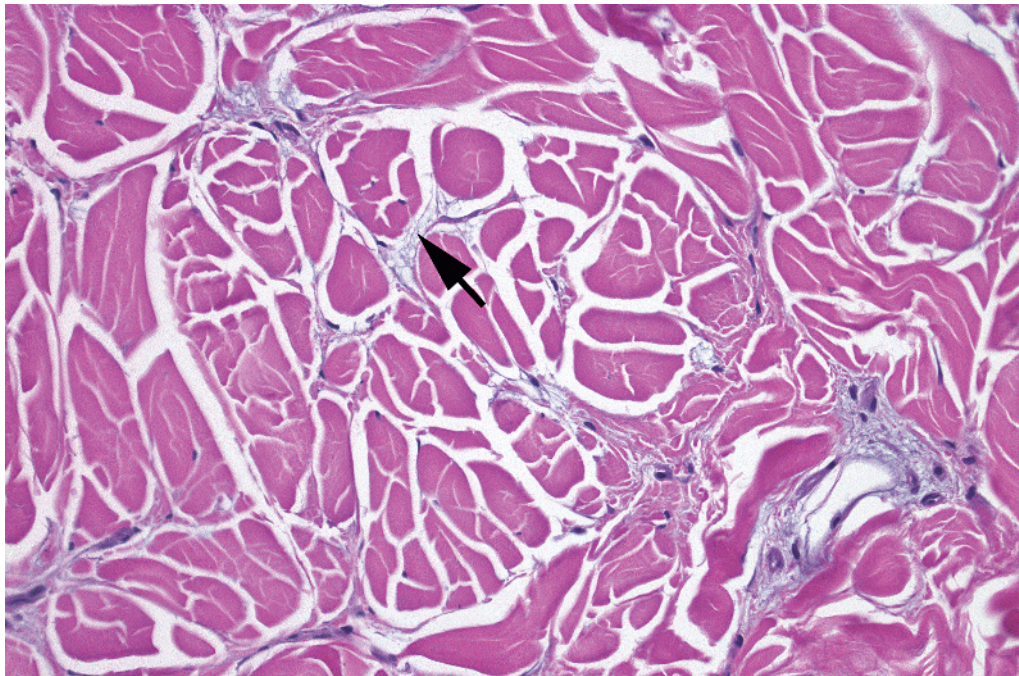
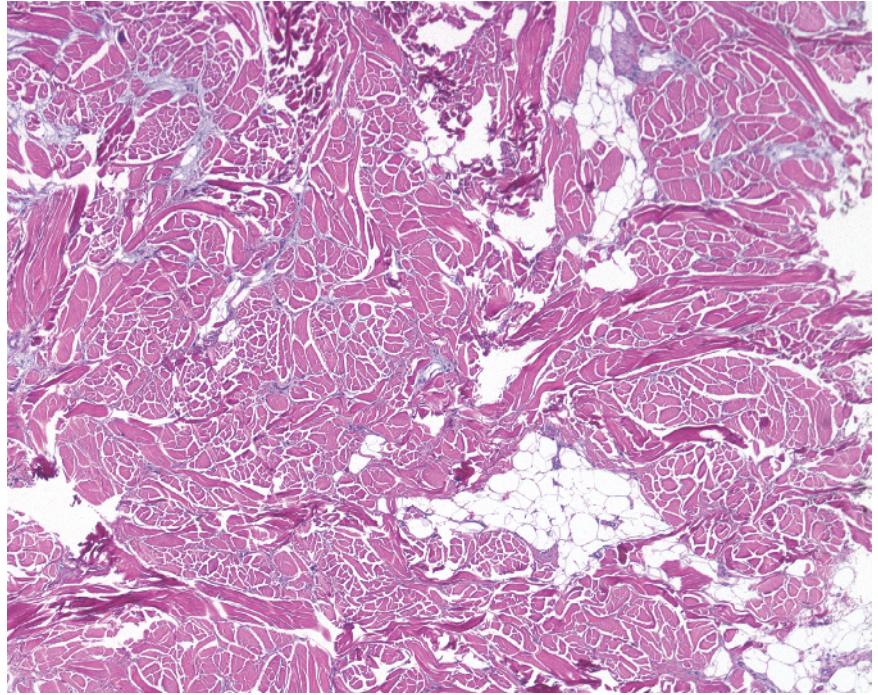
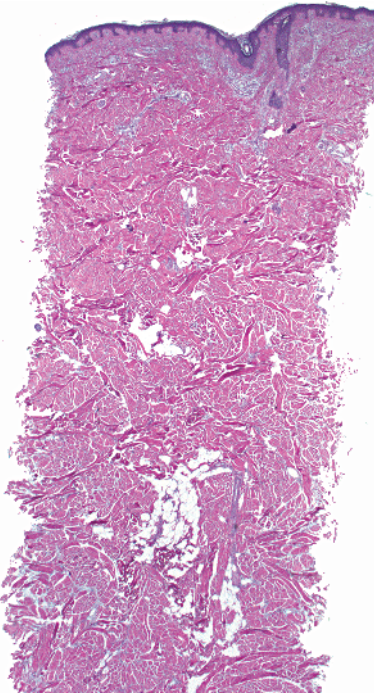
-
- Square/rectangular shape
 - Thick, pink smudgy collagen in dermis
 - Plasma cells around vessels
 - Atrophic or absent adnexal structures



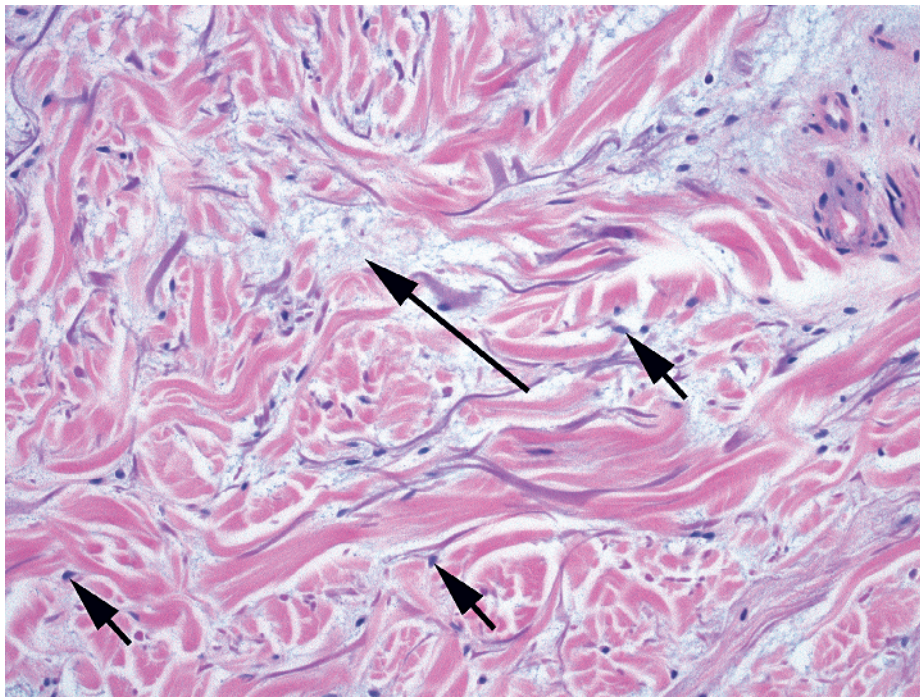
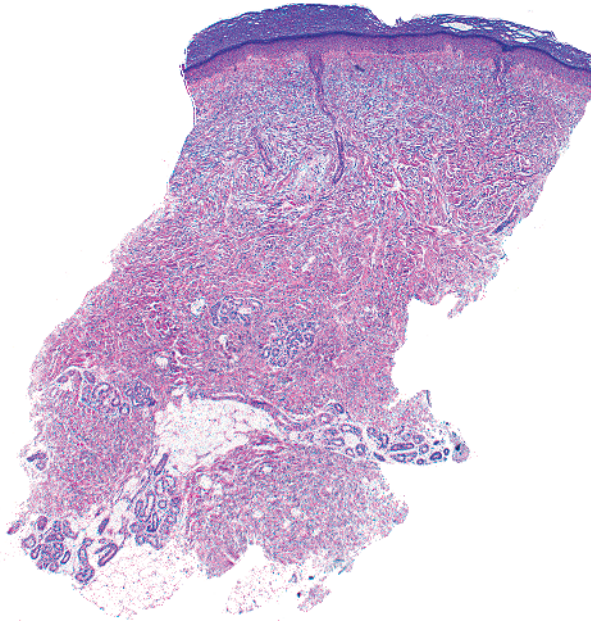
- Square/rectangular shape
- Altered, reddened collagen (necrobiosis) layered with inflammation
- Giant cells and plasma cells are prominent



-
- Square/rectangular shape
 - Normal-appearing collagen bundles in dermis
 - No increased mucin



- Square/rectangular shape
- Slight widening of space between collagen due to mucin (arrow)
- No increase in fibroblasts

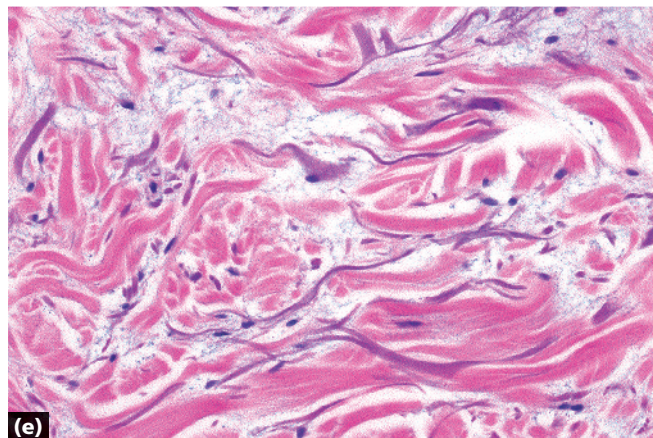
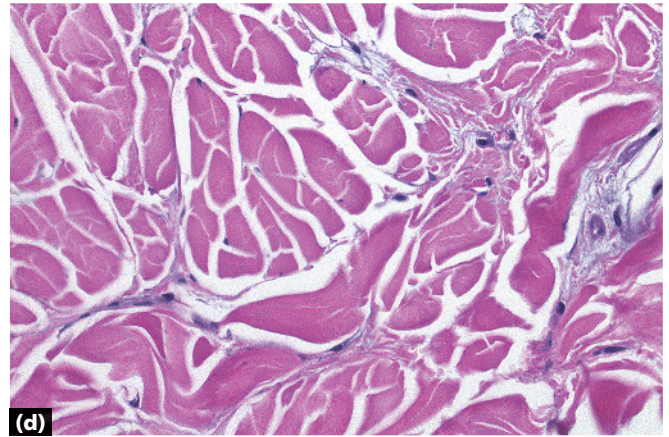
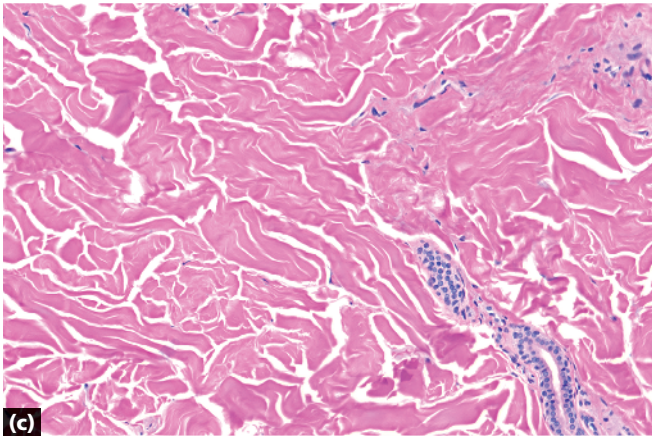
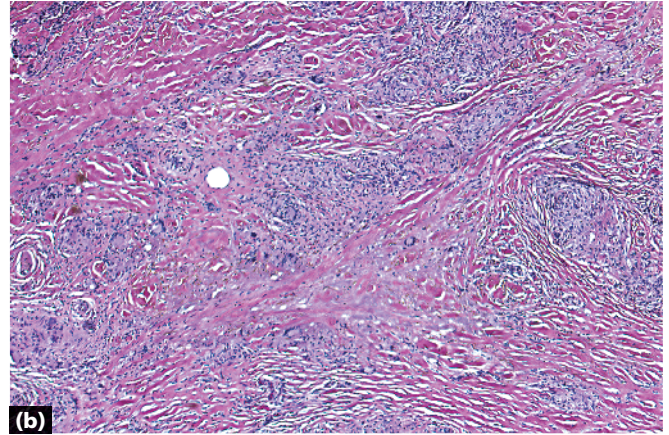
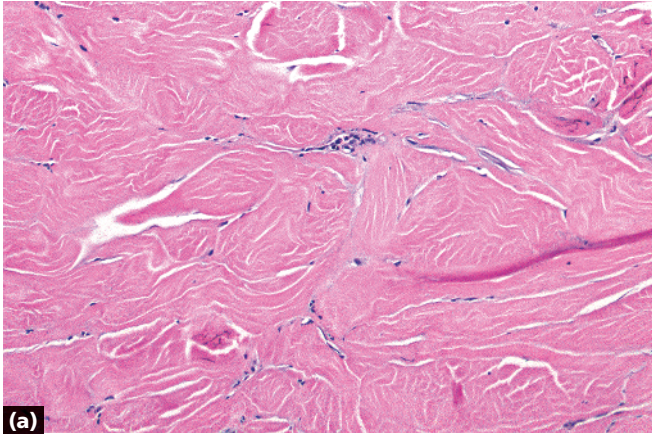


- Square/rectangular shape
- Slight widening of space between collagen due to mucin (long arrow)
- Increased fibroblasts (short arrows)

Note Lichen myxedematosus is histologically similar but clinically different.

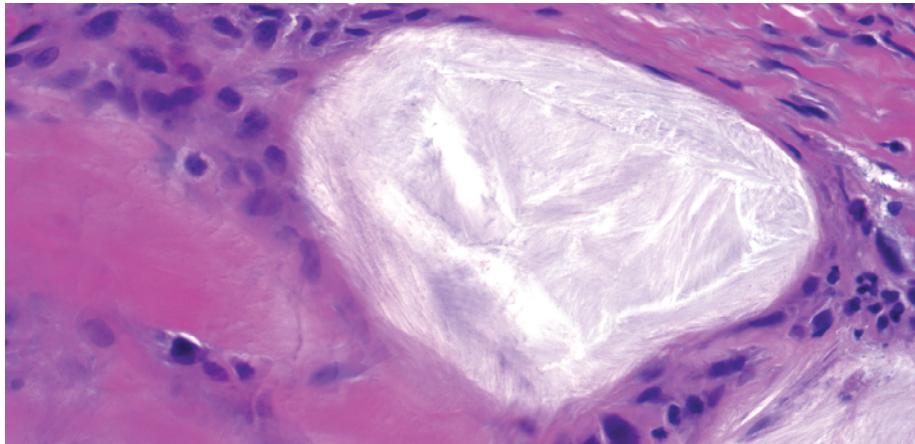
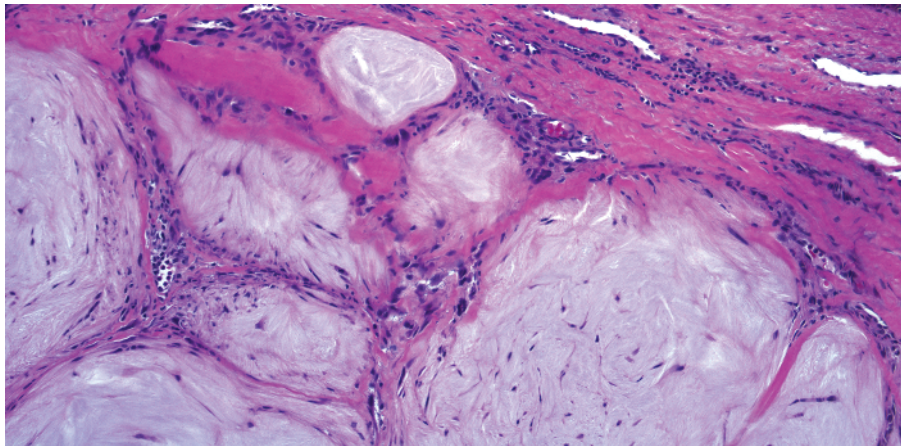
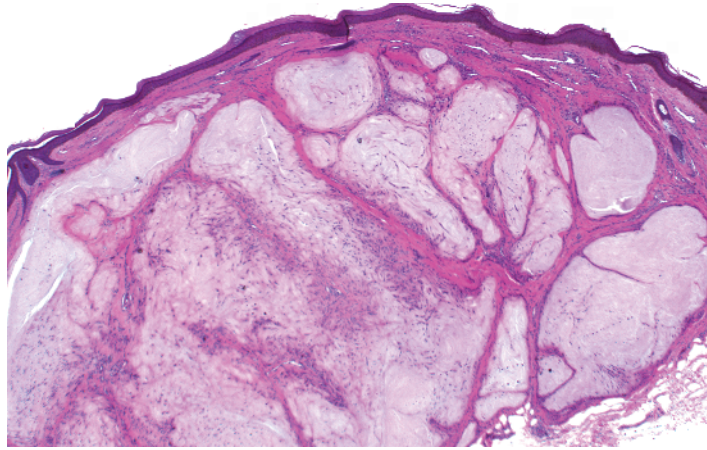
Note Nephrogenic systemic fibrosis may show similar findings but may have deeper involvement.

Scleromyxedema

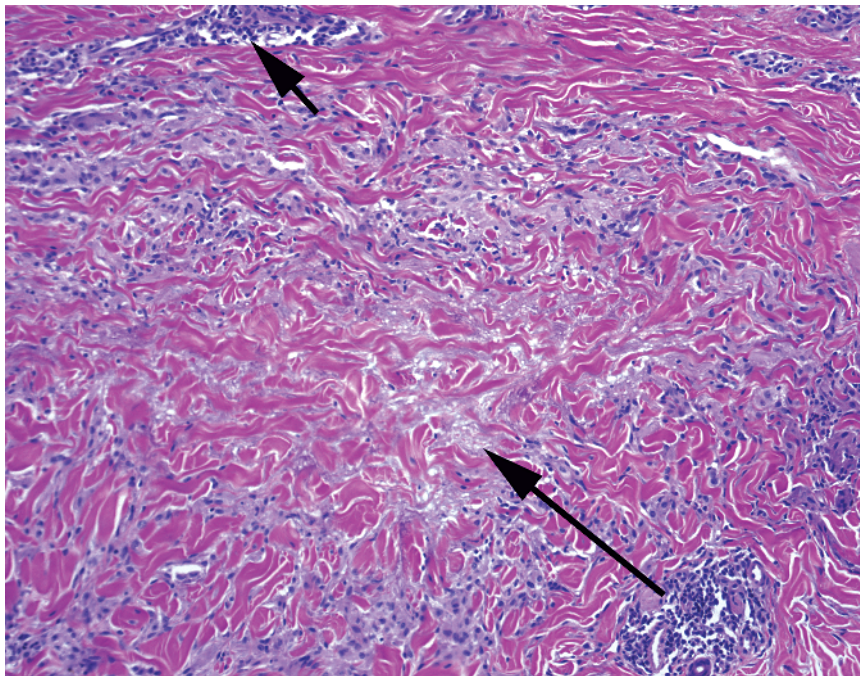
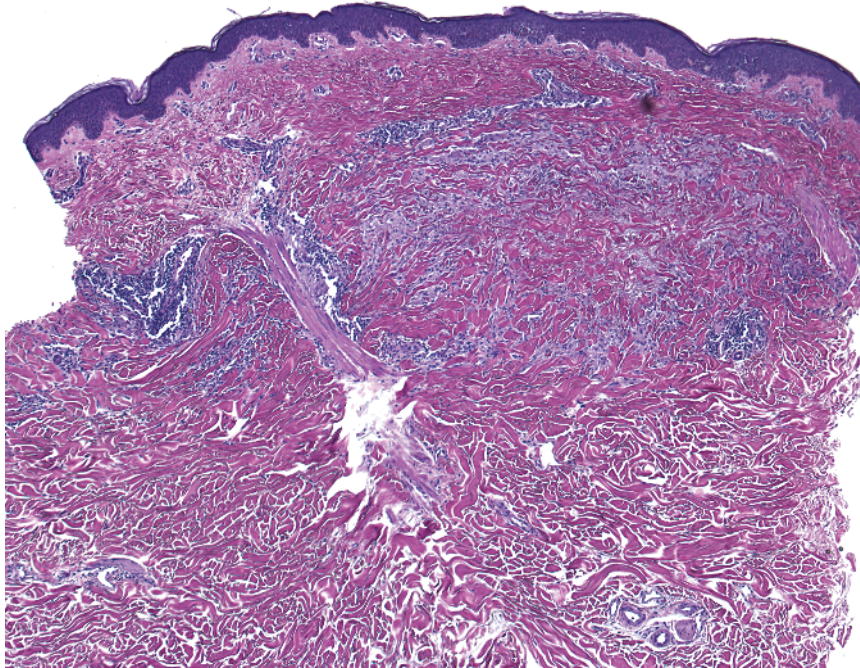


- a** Morphea: thickened bundles of collagen with loss of fenestrations between collagen bundles
- b** Necrobiosis lipidica: reddened collagen sandwiched between layers of inflammatory cells (giant cells, plasma cells)

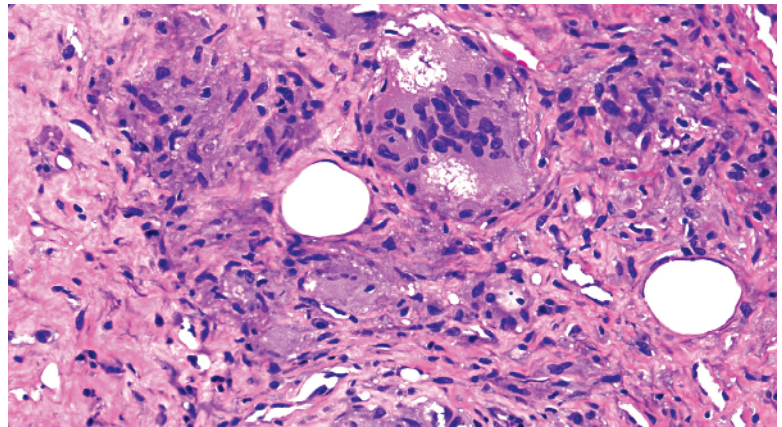
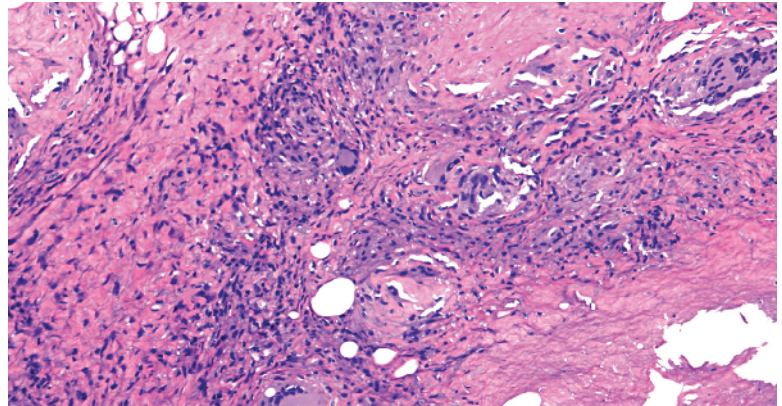
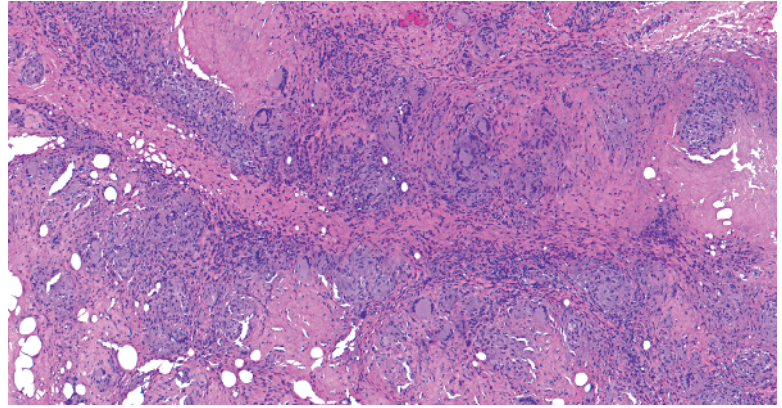
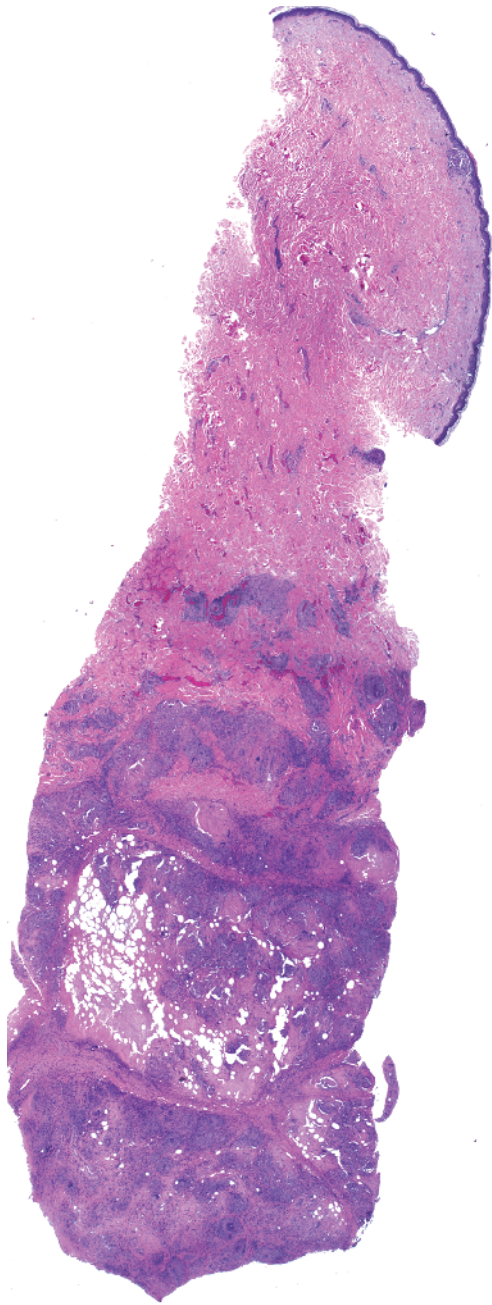
- c** Normal back: normal-sized collagen bundles, no increased mucin
- d** Scleredema: mucin between collagen
- e** Scleromyxedema: mucin and increased fibroblasts



-
- Palisading of histiocytes around amorphous white-gray substance with a feathery edge

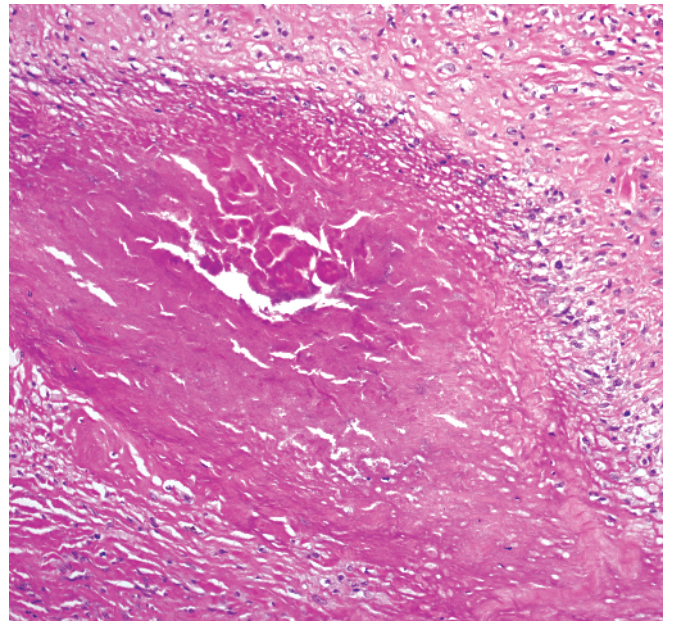
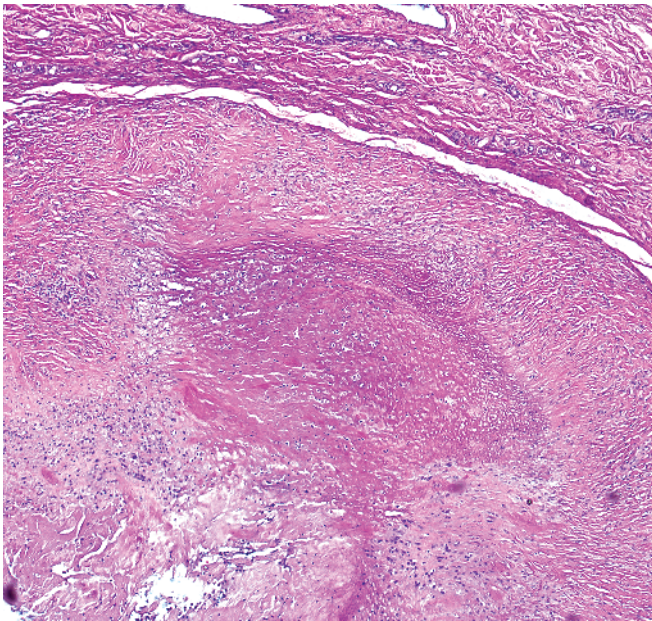
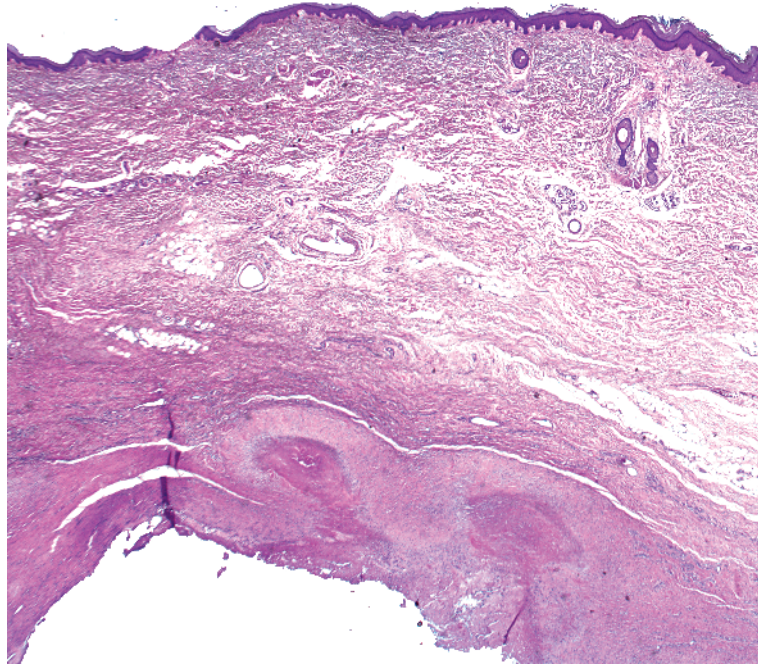


-
- Palisading of histiocytes around altered collagen, basophilic mucin (long arrow)
 - Lymphocytes around vessels (short arrow)

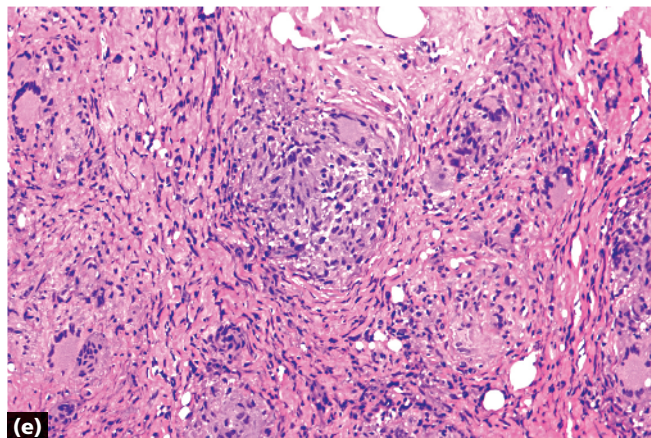
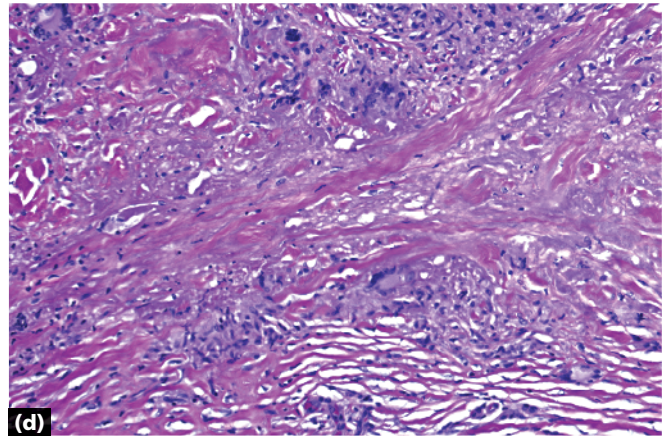
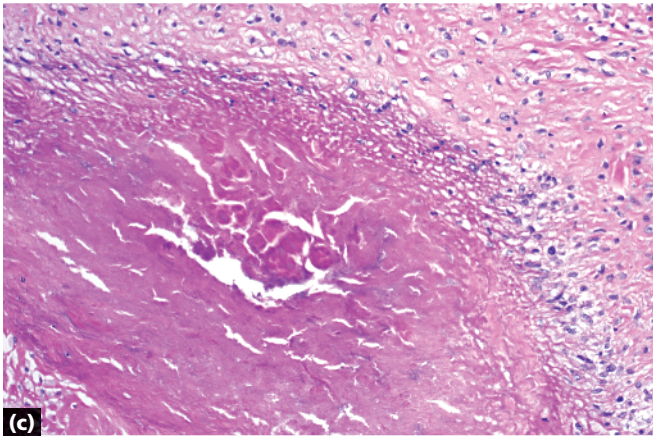
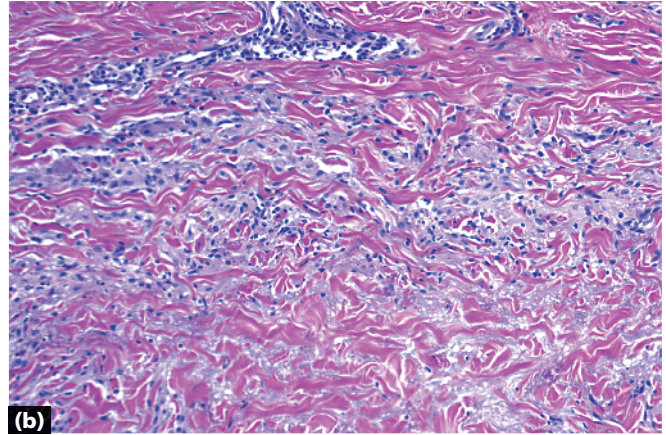
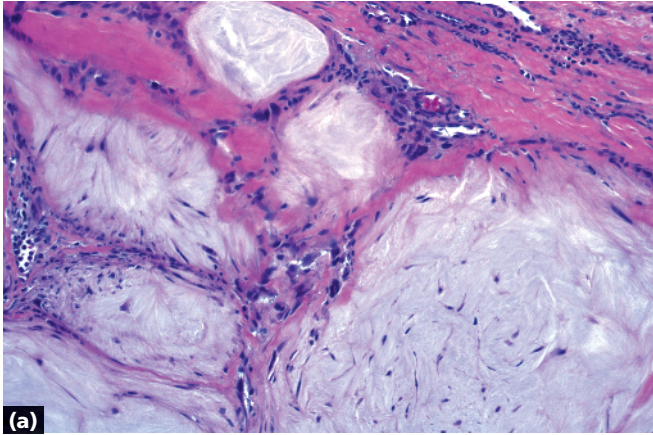


- Palisading of histiocytes and bizarre, multinucleated giant cells around foci of necrosis
- Scattered Touton giant cells
- Cholesterol clefts, plasma cells, and/or lymphoid follicles may be present

Necrobiotic xanthogranuloma



- Palisading of histiocytes around central pink fibrin
- The reaction is often deep



a Gout: central white-gray feathery material

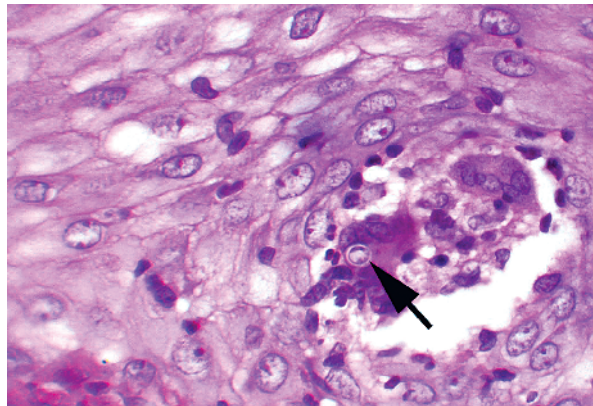
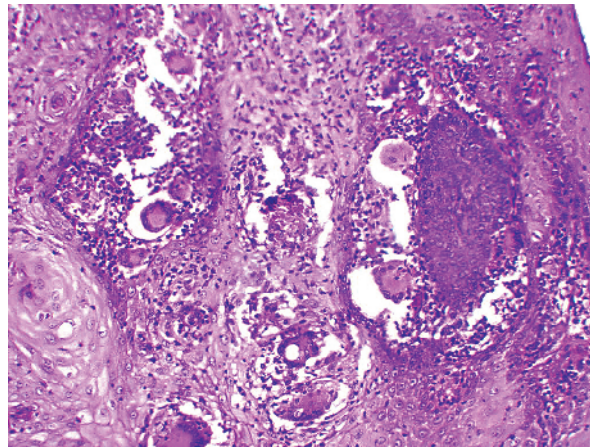
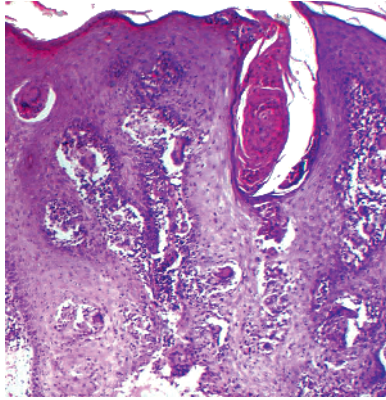
b Granuloma annulare: central altered collagen interspersed with blue mucin

c Rheumatoid nodule: central pink fibrin

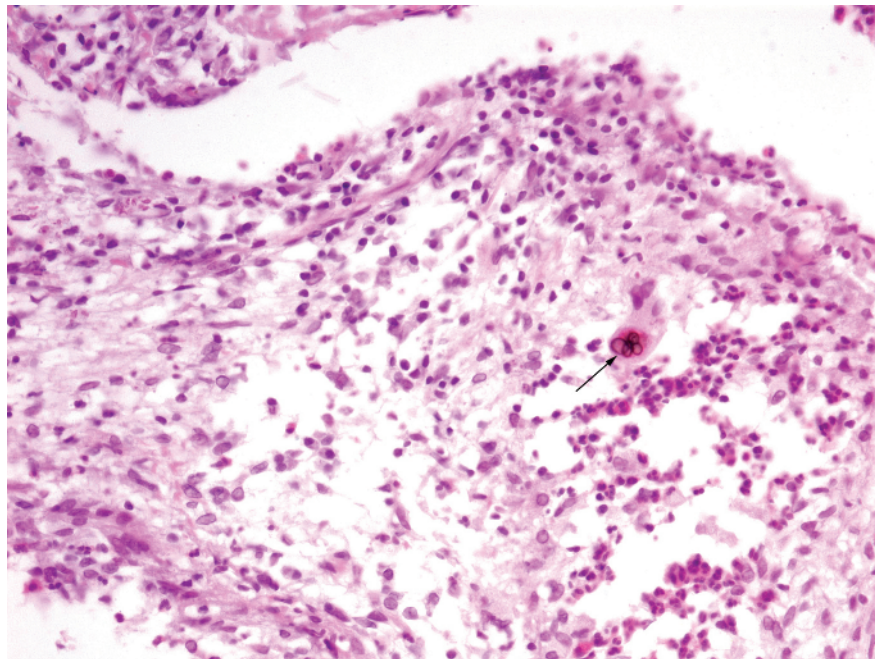
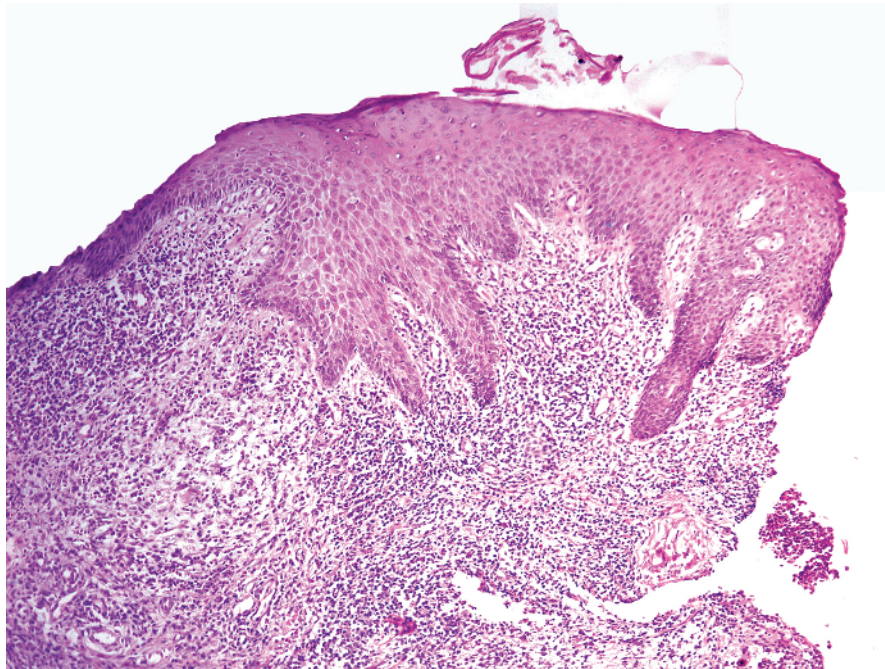
d Necrobiosis lipoidica: altered "red" collagen surrounded by giant cells, plasma cells (see page 83)

e Necrobiotic xanthogranuloma: bizarre, multinucleated giant cells; Touton giant cells

Key differences

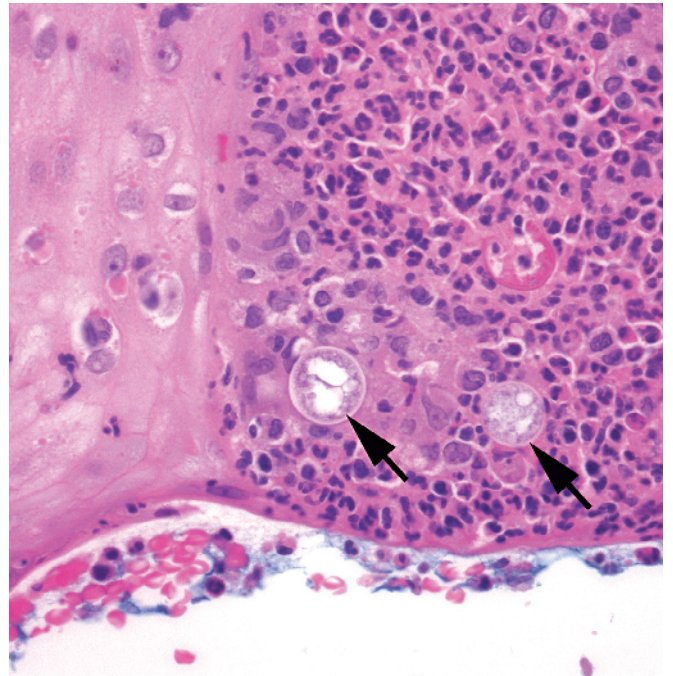
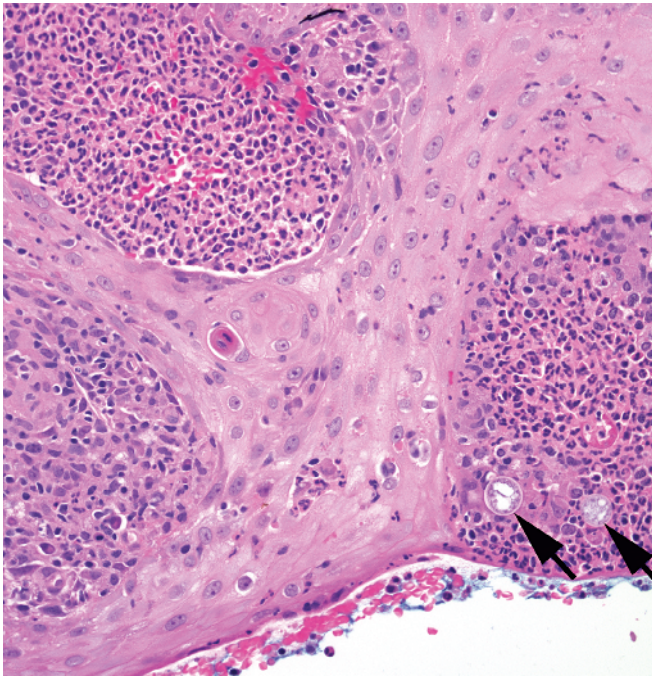
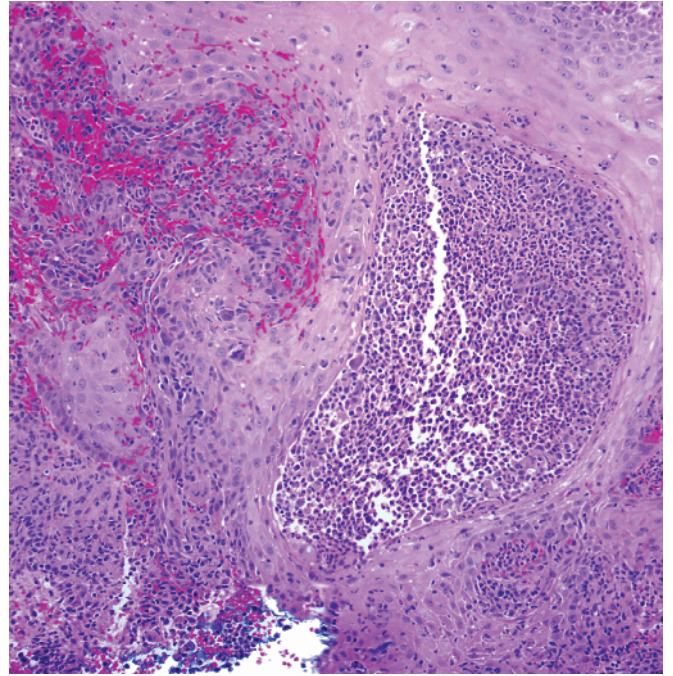
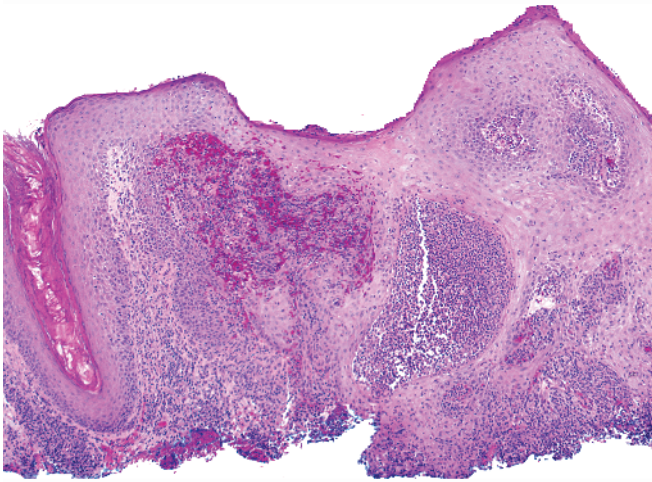


-
- Pseudoepitheliomatous hyperplasia above abscesses
 - Yeast forms (arrow) that classically show broad-based budding

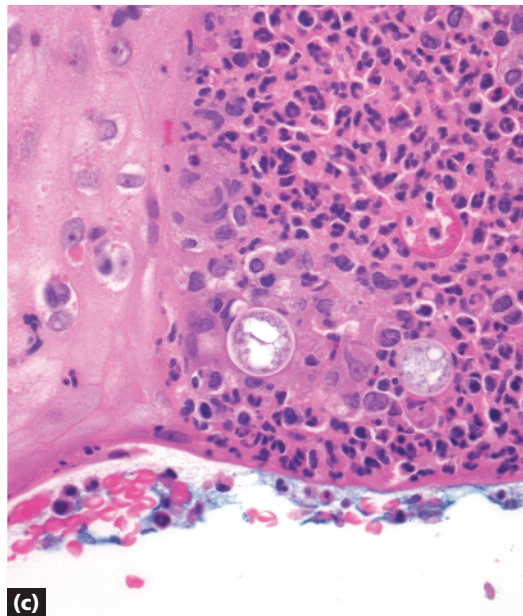
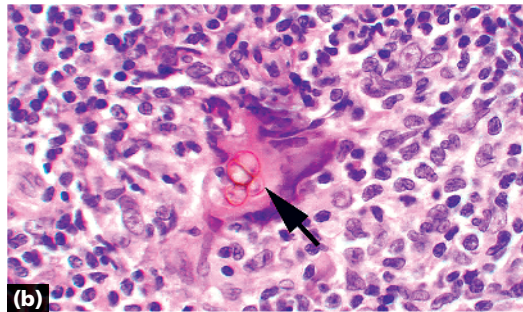
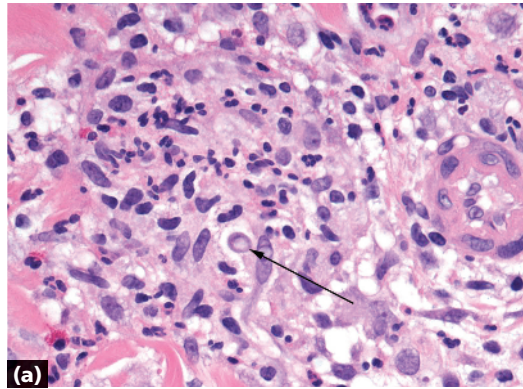


-
- Pseudoepitheliomatous hyperplasia above abscesses
 - Brown-colored septate rounded "hot cross buns" (Medlar bodies, sclerotic bodies, copper pennies) (arrow)

Chromomycosis



- Pseudoepitheliomatous hyperplasia above abscesses
- Large (~80-200 micron) spherules containing endospores (arrows)



- a** Blastomycosis: ~8–30 micron yeast form (arrow)
- b** Chromomycosis: ~5–12 micron Medlar bodies
- c** Coccidioidomycosis: ~80-200 micron spherules with endospores

Note Paracoccidioidomycosis (~6–60 micron Mariner’s wheel; an uncommon infection in the United States), sporotrichosis (organisms usually not evident in biopsies), and tuberculosis verrucosa cutis may also show this pattern.

Key differences