

Current Status of Clinical Practice with Dental Implants: An Evidence-Based Decision Making Overview

Osseointegration and its application to the treatment of completely or partially edentulous patients in clinical practice

Since the first experimental study from the end of 1960s [1], the titanium implant has been used as a biocompatible feasible alternative in the treatment of completely or partially edentulous patients. Basically, the systematic use of dental implants in dentistry as a scientifically proven therapeutic approach occurred in the 1980s, while in the 1990s it strongly grew in terms of potential clinical applications (Figure 1.1 and 1.2).

Currently, titanium implant-based procedures are seen as the gold standard for the replacement of teeth lost as a consequence of periodontitis, caries, endodontic pathology, and trauma. As a result, it can be argued with a high degree of certainty that implant-based therapies alone or in association with hard- and soft-tissue reconstructive procedures (most of them developed during the same period) are essential for the achievement of excellent clinical treatment in dentistry. These principles are grounded in the accomplishment of so-called osseointegration between the implant surface and living alveolar bone, (i.e. a direct bone deposition on implant surfaces at the light microscopic level) [2]. Additionally, others factors have influenced implant therapy among professionals over the last 20 years: the high success rates and the clinical/functional predictability of prosthetic restorations examined by long-term periodontal and implant dentistry research (Figure 1.3 and 1.4) [3–8].

Anatomical implications to implant therapy and the current impact of guided bone regeneration

The success rate of this treatment modality has been influenced by many elements, such as the successful osseointegration of the dental implants, smoking, the relationship between the final restoration(s) and the adjacent teeth, occlusal loading, and the health of the surrounding soft and hard tissue [9–18]. However, and apart from them, the initial anatomical conditions of the site intended to receive an implant merit close attention as they will drive the initial treatment path.

The bone defects in the alveolar ridge have always been considered a major obstacle to clinical therapy with osseointegrated dental implants, especially in partially edentulous patients. Tooth loss leads to changes of the alveolar ridge anatomy (i.e. bone resorption

in both height and thickness) and to the development of bone defects: (a) limited bone thickness, (b) reduced bone height, (c) vertical bone defects, (d) bone defects' combined height and thickness, (e) periodontal attachment loss of the teeth adjacent to the edentulous area, and (f) large bone loss resulting from infections/dentoalveolar trauma or previous surgical procedures (Figure 1.5 and 1.6) [19–24]. These features may not only significantly hinder the placement of implants but also affect the proposed restorative therapy in terms of function and aesthetics.

From the late 1980s and early 1990s, the introduction of the principles of guided bone regeneration (GBR) in implantology dramatically changed the treatment of the areas presenting anatomical limitations [19,21–23]. This therapy involves the application of bone-filling materials (in particles or blocks) covered by barrier membranes isolating the overlying soft tissue in order to allow cells to populate the bone defect area. As a result, areas previously contraindicated for implant therapy could be treated with bone augmentation techniques, prior to or simultaneously with implant placement [24].

Biomaterials for bone filling, or bone substitutes, have shown significant progress over the past two decades. Currently, there are options of biomaterials with osteoconductive properties that can be effectively and safely used in clinical practice [25]. It is noteworthy that these materials are responsible for maintaining the space at the defect area (i.e. the three-dimensional configuration of the future regenerated bone), providing support for the membrane. It is well known that membranes are essential for the application of GBR techniques, as is that absorbable materials are currently the most widely used membranes, owing to their user-friendliness compared to traditional, non-absorbable materials (i.e. expanded polytetrafluoroethylene (e-PTFE)) (Figure 1.7 and 1.8).

Furthermore, several implant surfaces, designs, and materials have been settled to increase bone-implant contact (BIC) and primary implant stability. These advances promote substantial improvements in success rates for dental implants in posterior intraoral regions and low-density bone sites. Initial enhancements on surface roughness leading to more effective microtextures have been followed by chemical modifications to speed up the initial bone apposition process, as well as to optimize BIC and the osseointegration interface. These developments have significantly increased the predictability of implant therapy, and at the same time decreased periods of wound healing/bone repair (i.e. osseointegration period). Likewise, such innovations have allowed the

consolidation of the clinical use of shorter implants (<8 mm in length), a condition that considerably increases the treatment options of sites with bone height limitation [26,27].

In addition, experimental research conducted on the dynamics of alveolar bone repair has proven what many periodontists had already perceived by clinical experience: fresh post-extraction alveolus/sockets heal differently from edentulous alveolar ridges following the installation of a dental implant [28,29]. Consequently, different approaches advocating the use of bone substitutes used to

fill the residual space between the implant surface and the fresh socket walls have been proposed as a way of counterbalancing future alveolar ridge dimensional changes/remodeling following tooth extraction. Comparably, the use of soft-tissue grafts has been expanded beyond the “conventional keratinized tissue gain” to promote the maintenance the alveolar ridge contours, particularly in areas with esthetic demands. Nowadays, there is a great deal of evidence to support clinical treatment protocols for immediate implant placement in esthetic sites (Figure 1.9).

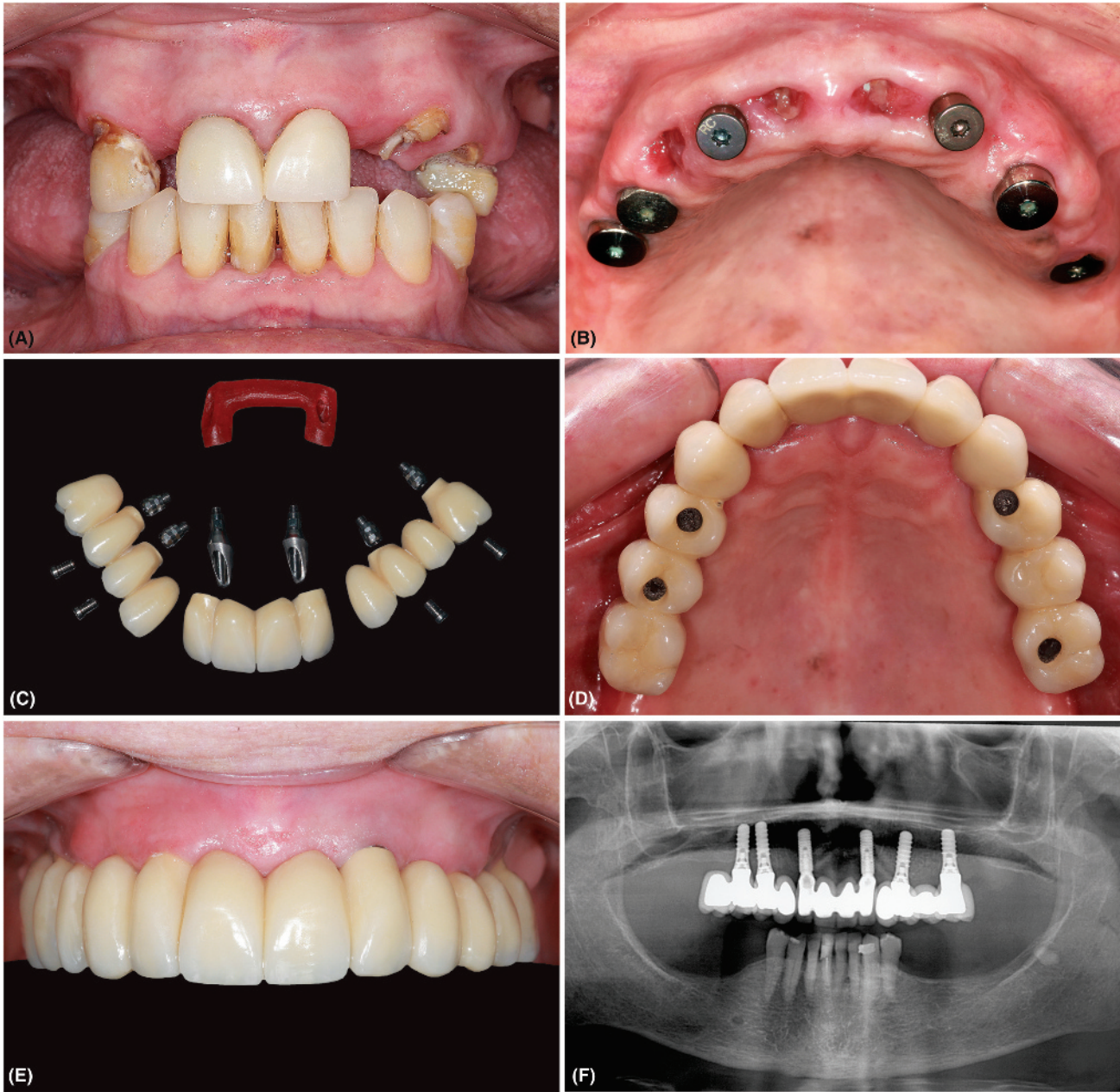


Figure 1.1 (A) Initial clinical status with several missing teeth before the full-mouth reconstruction. (B) After osseointegration around six implants in the maxilla the remaining teeth were extracted. (C) The abutments and the three four-unit porcelain-fused-to-metal restorations: two posterior screw-retained restorations and one anterior cemented restoration. (D, E) Clinical view of the final rehabilitation in position – occlusal and buccal views. (F) Panoramic radiograph.

Implant: Abutment connections

The connections between the implants and abutments can basically be divided into two groups: external connections and internal connections. External connections provide a less stable, small area of overlap between the parts (implant/abutment) that can lead to loosening of the fixing screw. Currently, these are indicated for prosthetic rehabilitations containing several connected implants.

It is important to note that the greater the overlap of the internal surfaces of the implant/abutment, the greater its resistance to

horizontal loads. Implants with internal connections present more overlap at the implant/abutment connection, a condition that provides greater stability, and this makes them better indicated for cases involving single crown restorations. It should be noted that the implant systems that have conical internal connections (i.e. fitting joint) have demonstrated the best mechanical results – for this reason they are also called “high-stability systems.” Another condition that should be highlighted in the implant/abutment connection is the concept of reduced platform (i.e. prosthetic abutment with a diameter smaller than the implant shoulder

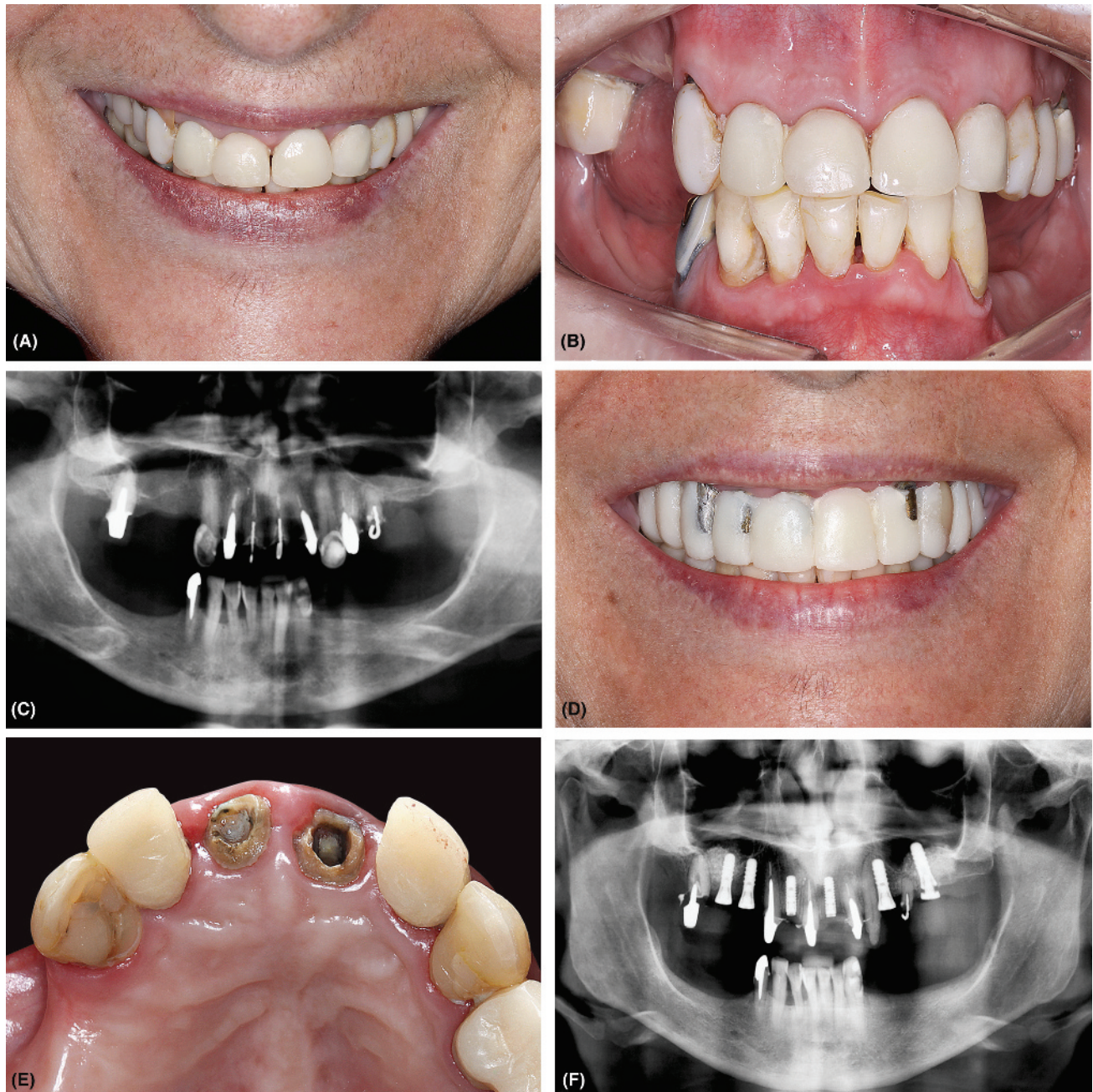

Figure 1.2 (A) Patient smile before treatment. (B) Initial clinical status with several missing teeth before the full-mouth reconstruction. (C) Initial panoramic radiograph. (D) First mockup shows the unfavorable position of teeth #6, 7, and 11 regarding the planning for restorative treatment. (E) Occlusal view of the anterior teeth. (F) Panoramic radiograph after the placement of six implants in the maxilla.

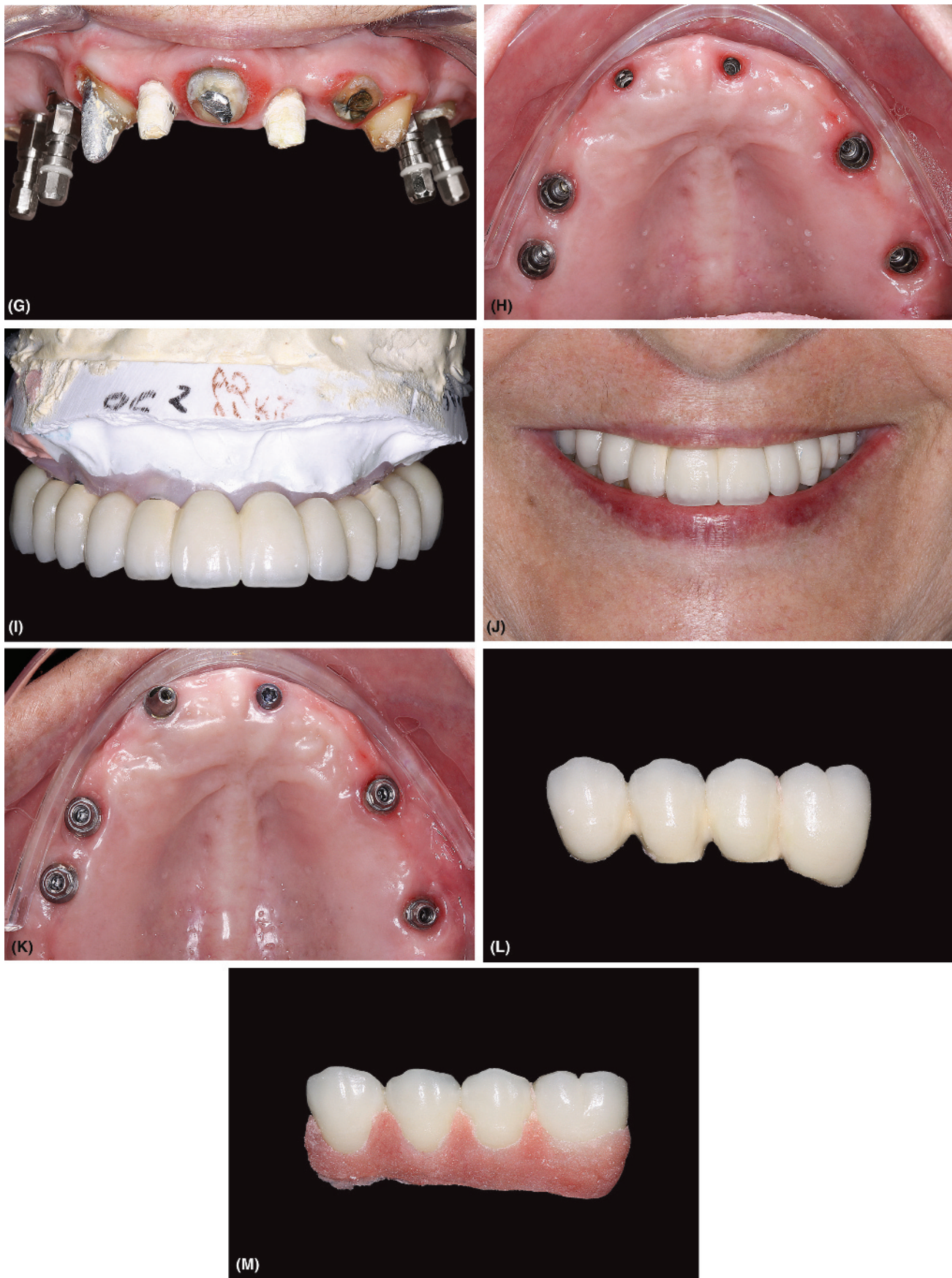

Figure 1.2 (G, H) Clinical views after implant placement before and after teeth extraction. (I) The three four-unit porcelain-fused-to-metal restorations prior to installation. (J) Clinical try-in of the three four-unit screw-retained porcelain-fused-to-metal restorations. (K) Occlusal view of the abutments. (L) Right-side partial fixed restoration before the pink gingival application. (M) Pink gingival simulation with acrylic resin.

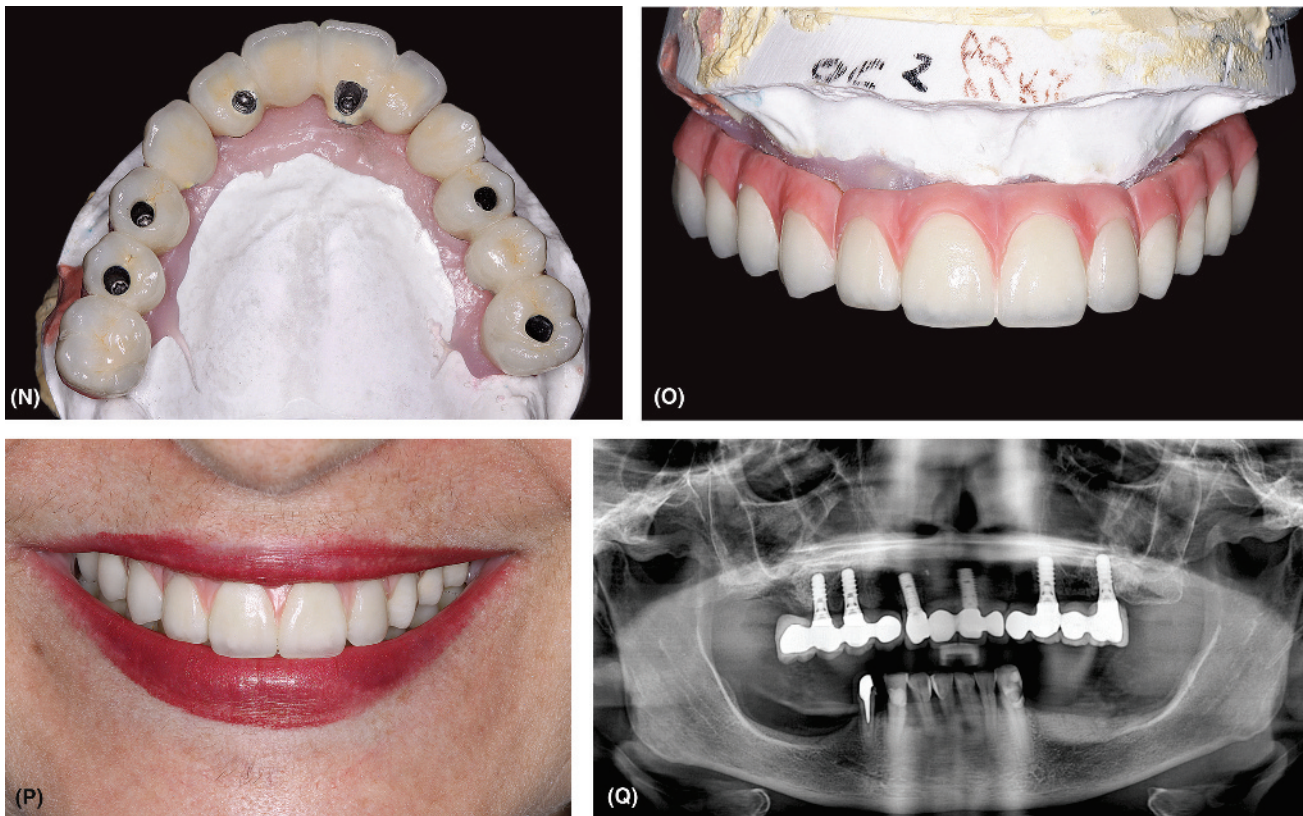


Figure 1.2 (N, O) Restorations completed – occlusal and buccal views. (P) Patient smile after treatment. (Q) Panoramic radiograph.

diameter - platform switching) - which is considered an excellent choice for areas with higher esthetic requirements, given that the success of treatment of these sites seems to be associated with the stability of the peri-implant bone crests and the greater thickness of soft tissue around the joint implant/abutment (Figure 1.10) [30–32].

Evolution of imaging diagnosis methods

CBCT has greatly improved the diagnosis and, consequently, the treatment plan in contemporary dentistry. Currently, high-resolution scanners acquire far superior images over the three spatial planes with lower exposure doses. This apparatus can provide high-definition images from teeth, edentulous areas, soft-tissue thickness of donor/recipient sites, and other important facial structures. It is important to consider that modern implantology/implant dentistry no longer support surgical procedures (i.e. implant placement and GBR) being performed without the assistance of proper high-quality diagnostic images (Figure 1.11) [33, 34].

Root-treated teeth: Decision making for implant placement

Controversy still surrounds the need for replacing teeth with questionable prognosis by implants. Meticulous clinical and radiographic evaluation (e.g. visual inspection assisted by optical microscope, periodontal probing, exploratory surgical procedures, use of

CBCT imaging) is important before condemning any tooth. The clinical decision making process can be influenced by several factors, such as tooth root fragility (by considering its role in future restorations), occlusal pattern, masticatory forces, and the patient's age and ability to chew. A frequent scenario found in clinical practice regards vertical root fractures (VRF), a condition of difficult diagnosis, especially in cases where the root fragments are not separated. At this stage, conventional and/or digital periapical radiographs are unlikely to be able to show the presence of VRF, because of the limitation of two-dimensional imaging. To be radiographically visible, the X-ray beam should be positioned in the same focal plane as the fracture, because small changes in the horizontal angle may not allow the detection of the line of the fracture. The vertical fracture may show clinical signs (e.g. presence of fistula or swelling of the gingival tissues at the level of root fracture) and symptoms such as discomfort or pain during chewing or after a percussion test (Figure 1.12 and 1.13) [33].

Evidence-based decision making in implant dentistry: "What is the importance of founding a treatment plan on evidence-based clinical approaches?"

While it is true that there are many treatment modalities discussed and promoted in dentistry literature, the validity of dental implants for modern practice is supported by evidence-based clinical results.

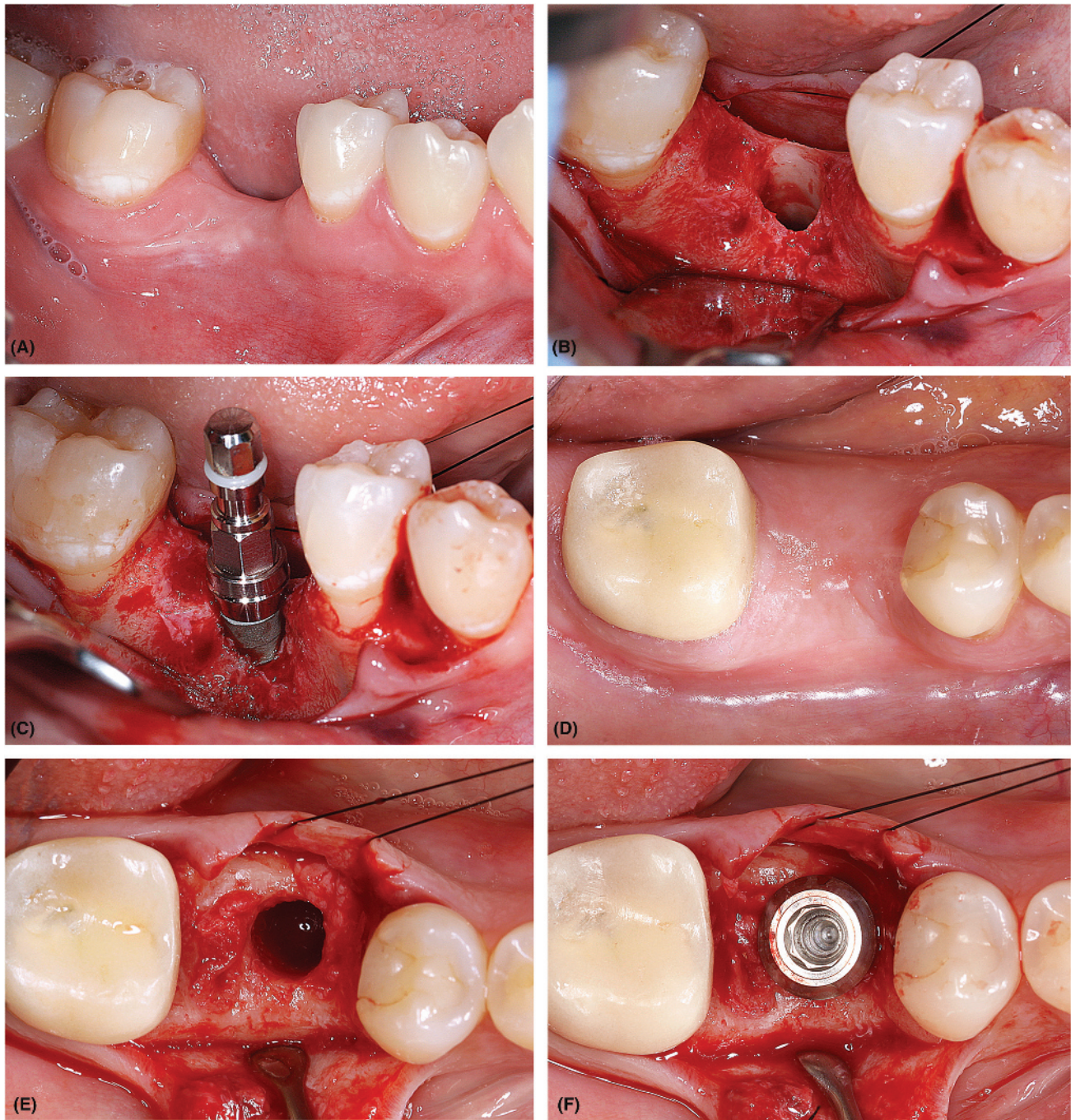


Figure 1.3 Two implant sites in tooth #30 with different characteristics. (A) Tooth #30 is missing and a bone defect is present at the alveolar ridge. (B) Implant site with thin bone walls. (C) Implant in position (4.1 mm diameter). A dehiscence-type defect is present at the buccal aspect. (D) Tooth #30 is missing and the alveolar ridge contour is well preserved. (E) Implant site with thick bone walls (more than 2 mm of width). (F) A wide-diameter implant (4.8 mm diameter) in position.

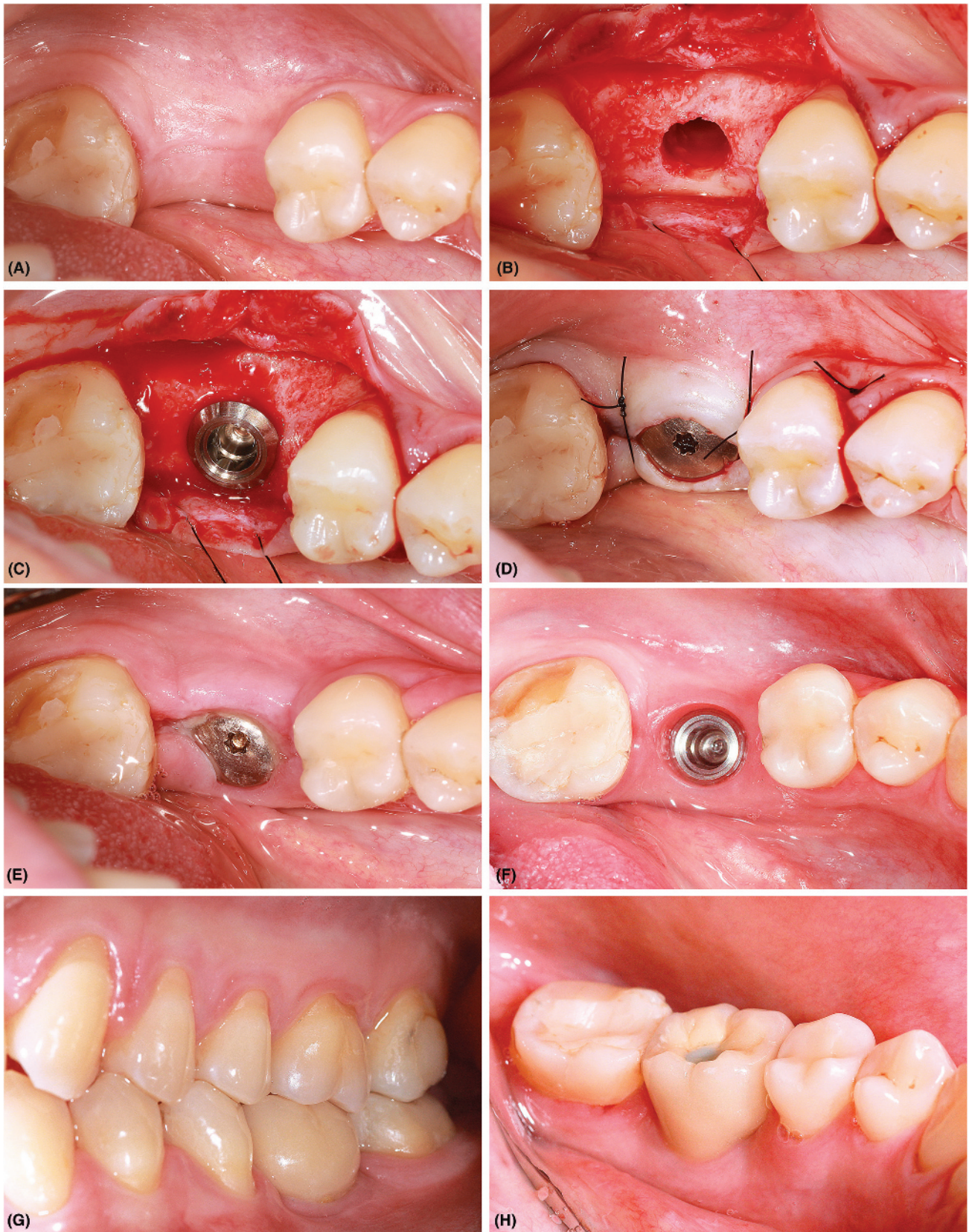


Figure 1.4 (A) Tooth #19 is missing. (B) Implant bed. (C) A wide-diameter implant (4.8 mm diameter) was placed. (D) Wound closure. Non-submerged healing. (E) Aspect one week after operation. (F) Aspect eight weeks after operation. (G, H) Porcelain-fused-to-metal screw-retained restoration in occlusion and lingual views.

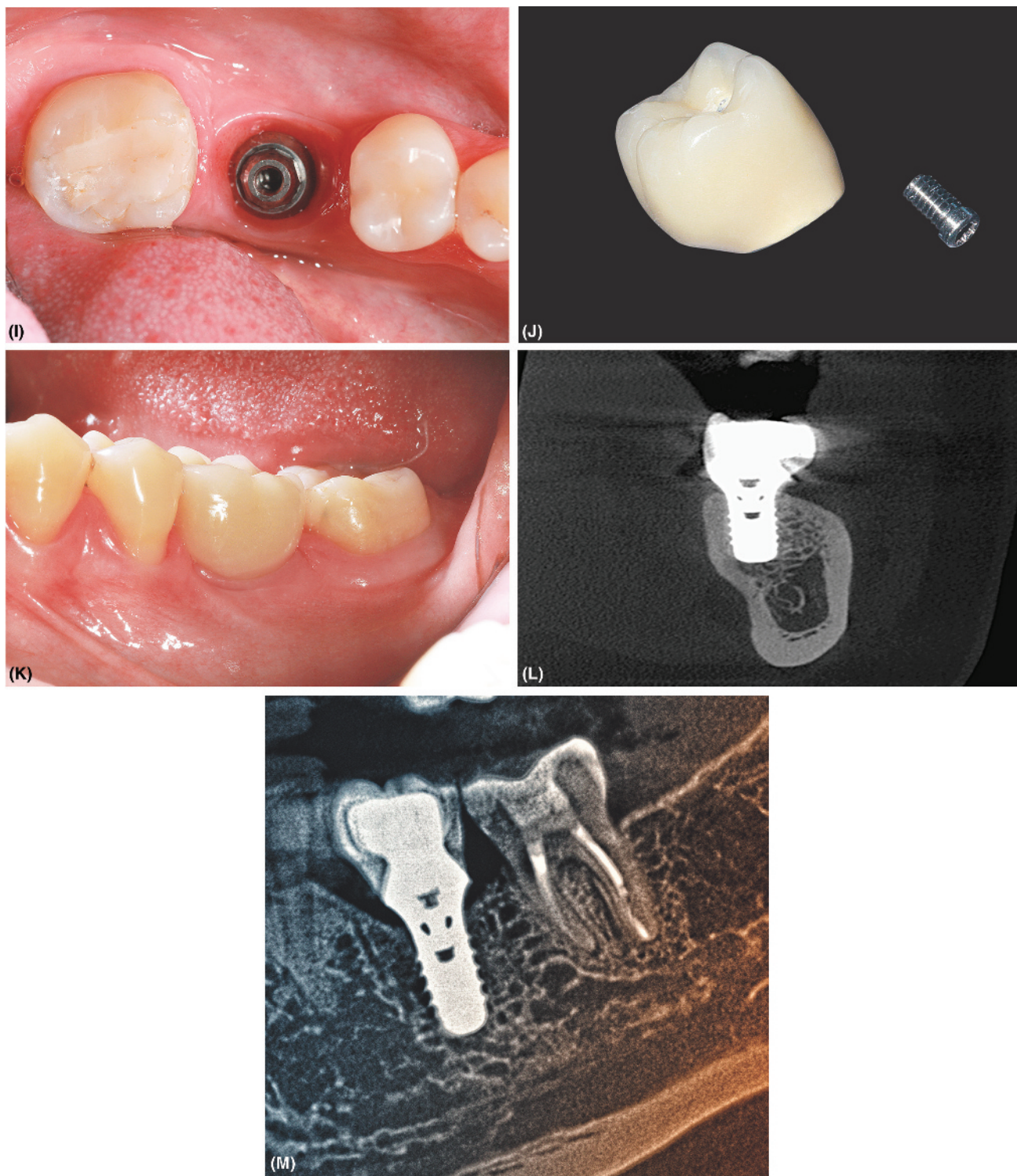


Figure 1.4 (I) Eight-year follow-up shows healthy peri-implant soft tissue. (J) Screw-retained restoration. (K) Restoration replaced in position. (L, M) Eight-year follow-up cone beam computerized tomography (CBCT) image shows excellent bone levels around the implant.

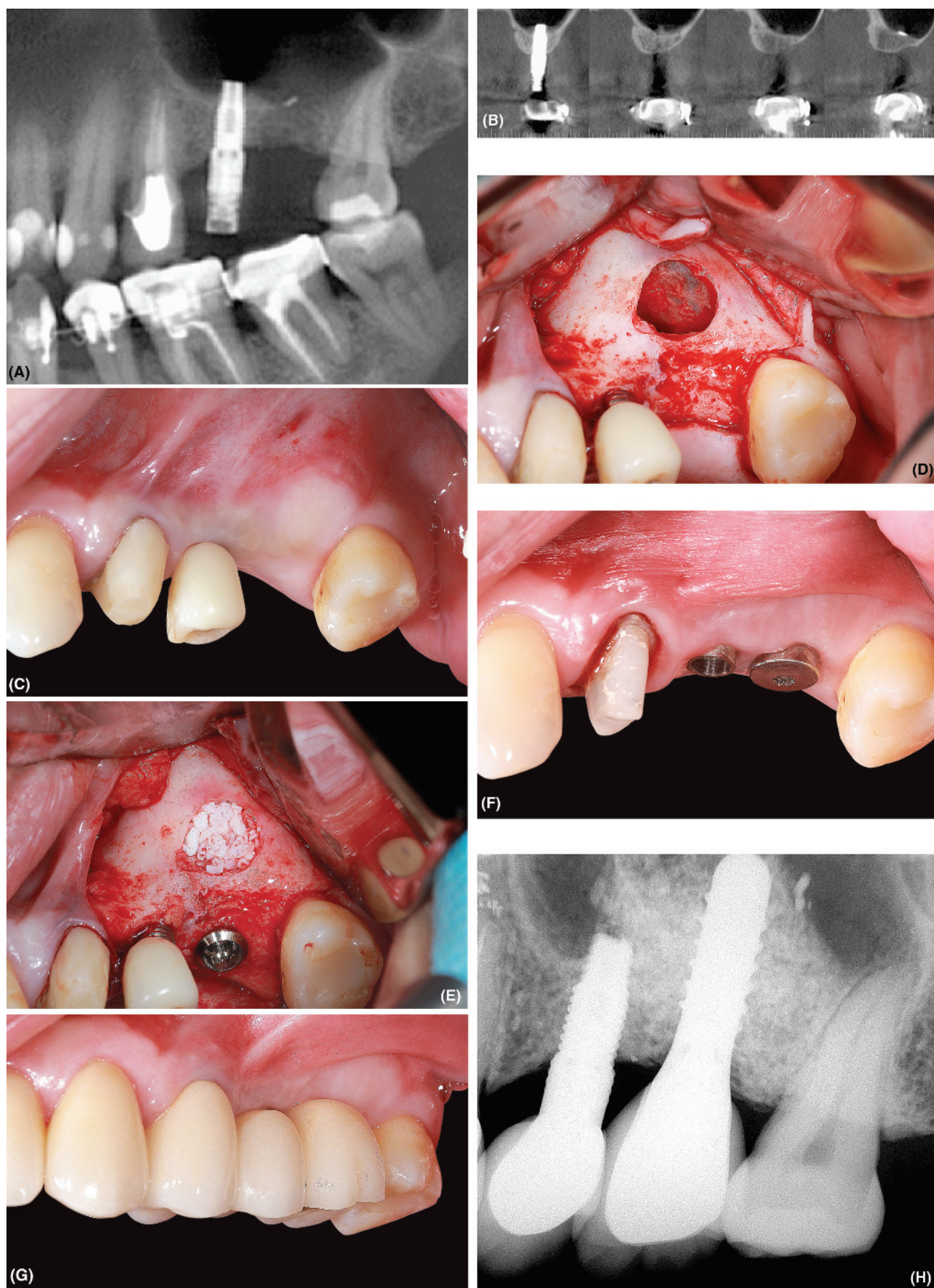


Figure 1.5 (A, B) Tooth #14 is missing. CBCT shows limited bone height because of the sinus floor presence. (C) Initial clinical aspect. (D) Sinus grafting using the lateral window technique (sinus lifting procedure). (E) Bone substitute filling the sinus followed by implant placement (simultaneous approach). (F) Healing aspect six months after procedure. (G) Buccal view of the final restorations. (H) One-year follow-up periapical radiograph.

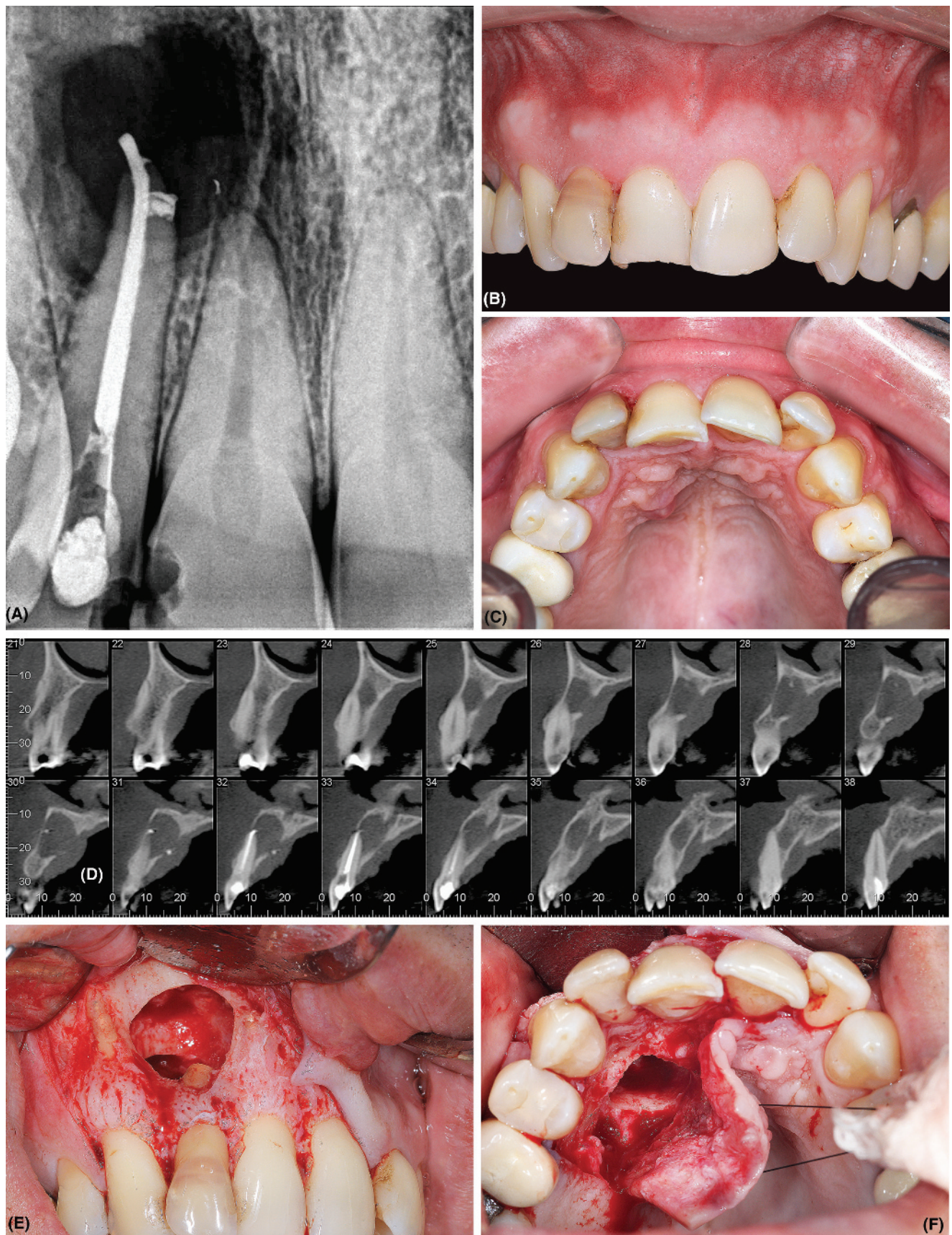


Figure 1.6 (A–D) Extended periapical lesion associated with teeth #7 and 8 compromising direct implant placement. (E, F) Surgical treatment – buccal and palatal views – after apicoectomy of tooth #7 and extensive bone defect cleaning.

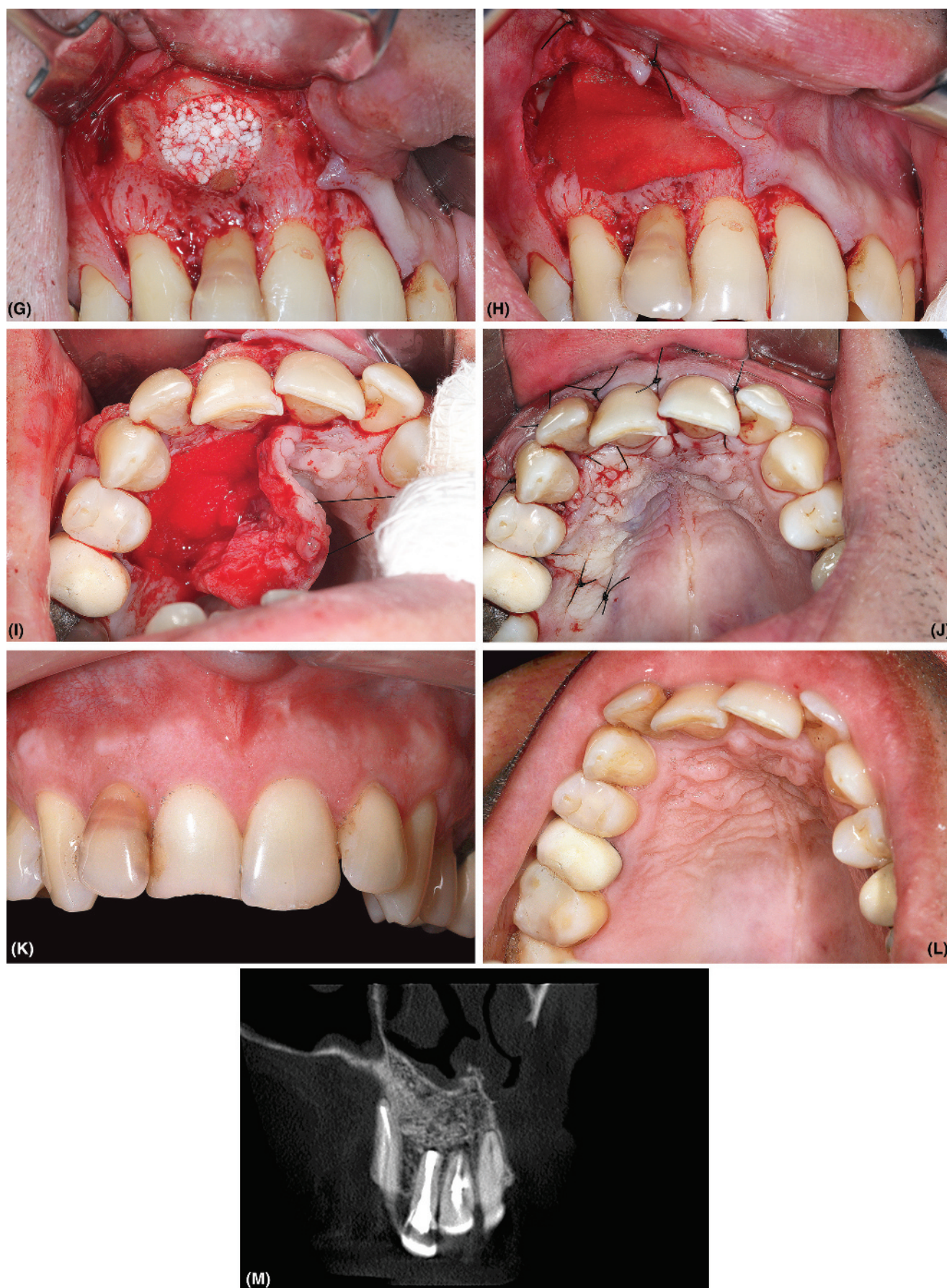


Figure 1.6 (G) Deproteinized bovine bone matrix (DBBM (Bio-Oss® collagen)) filling the transmaxillary defect. (H, I) Collagen membrane covering the defect – buccal and palatal aspects. (J) Wound closure with interrupted sutures. (K, L) Two-year clinical follow-up after surgery – buccal and palatal views. (M) CBCT control two years after surgery shows no residual bone defect.

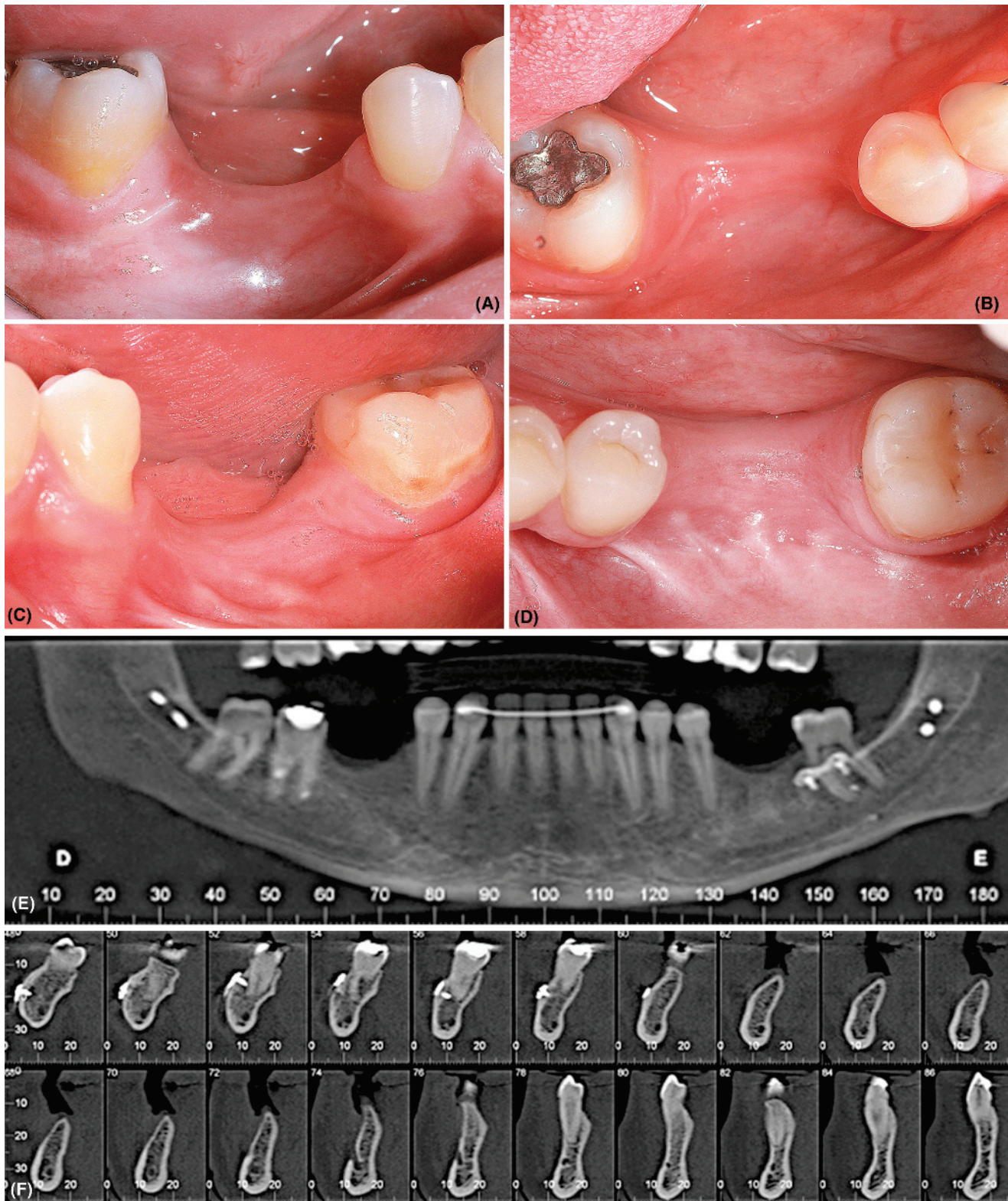


Figure 1.7 (A–D) Adult female with several missing lower posterior teeth. Localized alveolar ridge defects are present both sides. (E, F) CBCT images.

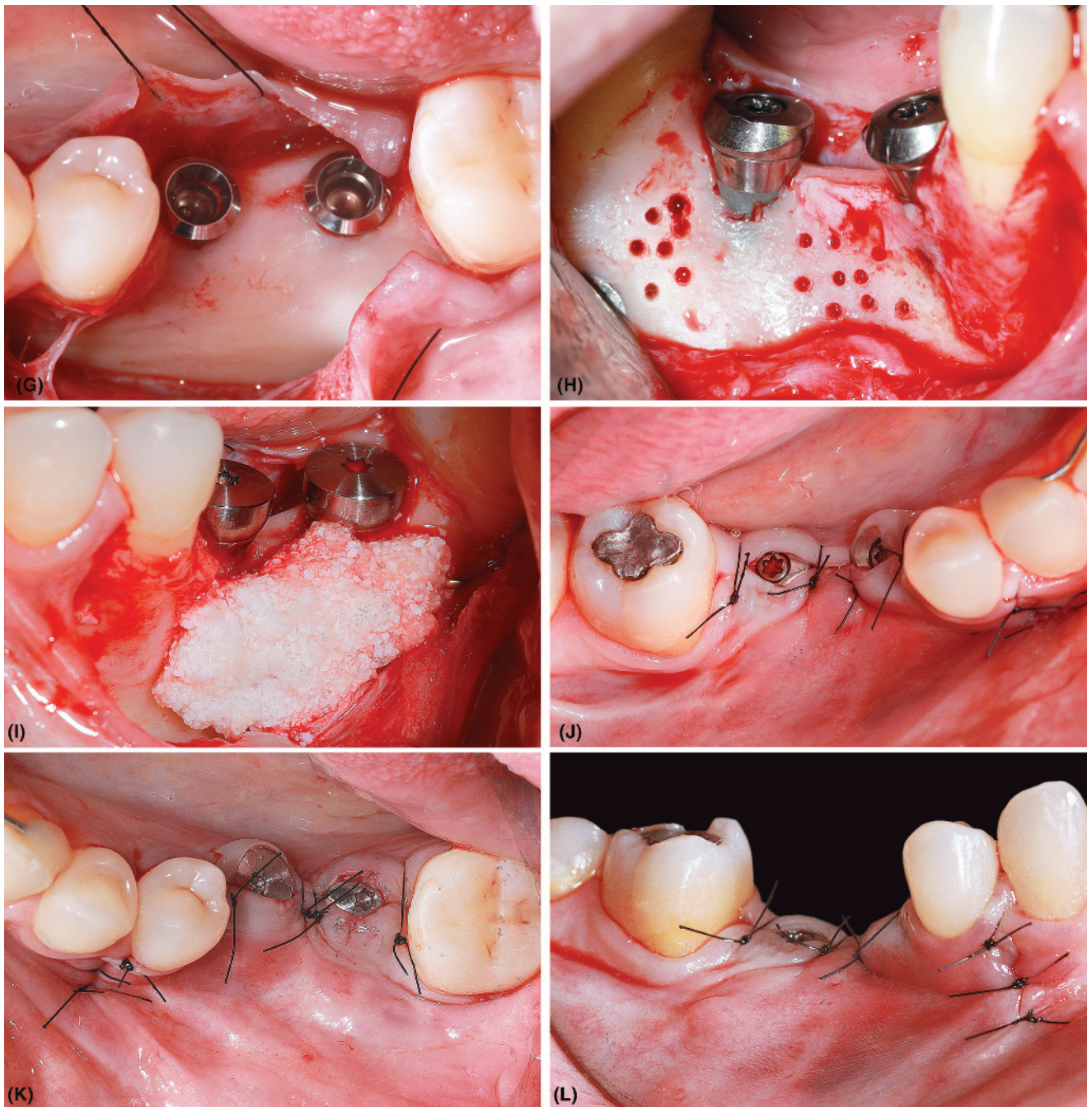


Figure 1.7 (G) Implant placement – left side. (H) Buccal cortical perforation for blood supply at the defect site – right side (I) Bone substitute DBBM (Bio-Oss collagen) filling the bone defect area – right side (J–L) Wound closure bilaterally (nylon 5-0).

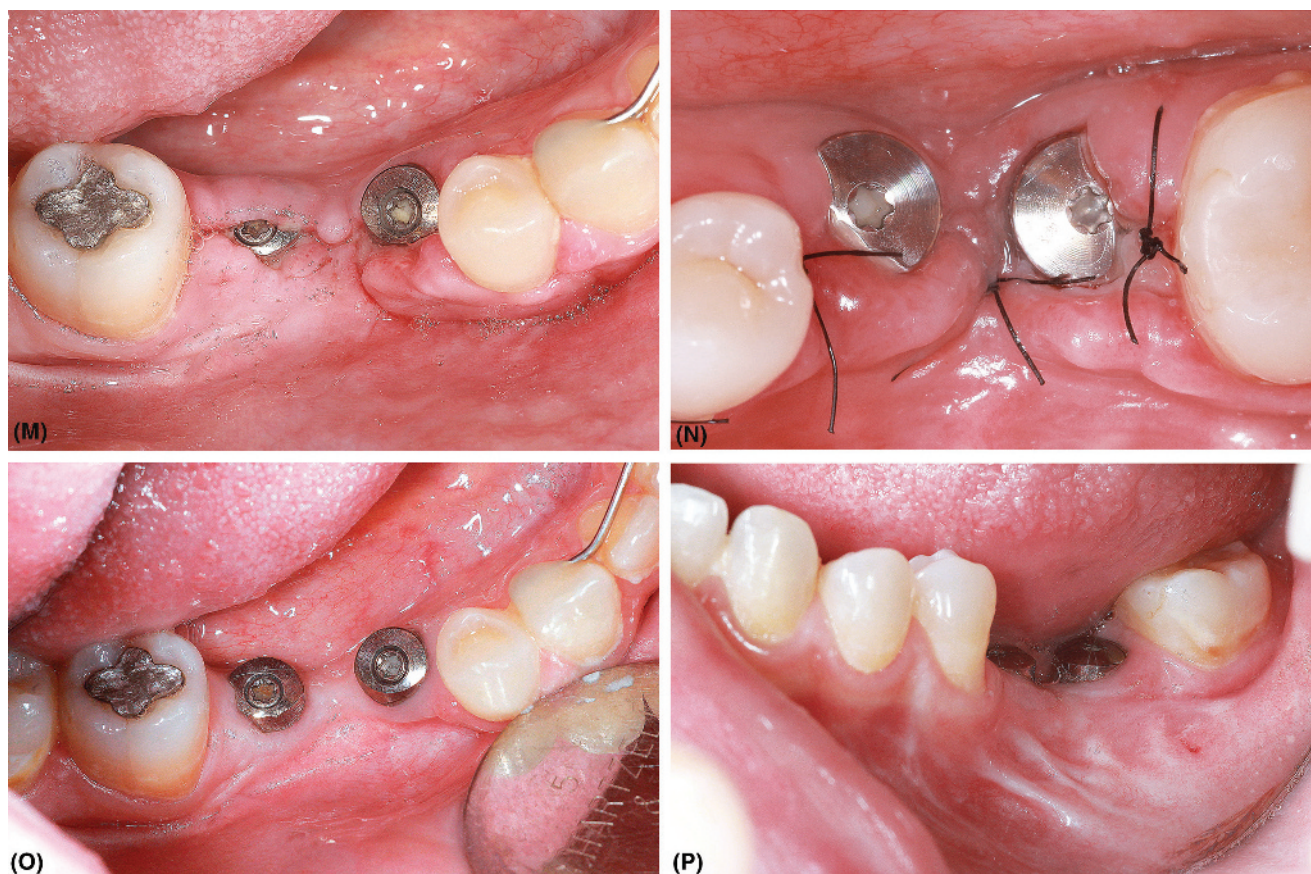


Figure 1.7 (M, N) Healing aspect one week after operation. (O, P) Healing aspect 16 weeks after operation.

This assumption implies that health promotion must be derived from the best source of information available in order “to translate the outcomes of efficacy research into clinical effectiveness” [18], in other words to adapt the findings of university research to clinical practice.

To achieve this objective, outcomes gathered from systematic reviews (SRs) are used throughout this book to recognize and provide evidence-based solutions to and options for the most common clinical scenarios found in clinical practice. As an instrument used by researchers and clinicians to establish the decision making process, an SR is considered the best type of study to appraise the cost and impact of treatment approaches. Conversely, many clinicians have not judiciously managed the information (i.e. its key findings) of an SR. Thus, it is important to provide them with a way of navigating understanding and those research findings that can (or cannot) be applied to clinical practice

Given the importance of applying research recommendations to practice, this book uses SR summaries and evidence-based ratings when discussing the strength and reliability of various implant procedures, and supports this with evidence from the literature. The aim of this is to assign various treatment modalities discussed in this book a level of validity (i.e. high, moderate, or low), based on the criteria defined by the US Preventive Services Task Force (USPSTF) and adapted by the American Dental Association (Table 1.1 and 1.2) [35]. Consequently, “Clinical Recommendation Summaries” summarizing “the strengths and weaknesses of the

evidence in terms of benefits and harms” have been generated [35]. These aim to give accurate and explicit rationale for clinical practice, as well as the reasons for the recommendations. As a result, once the balance between benefits and downsides is decided, the following *Strength and direction of recommendation regarding the need for therapy and procedures* are applied [35]:

- Strongly in favor: Evidence strongly supports the intervention/procedure.
- In favor: Evidence supports the intervention/procedure.
- Weakly in favor: Evidence suggests implementing the intervention/procedure after alternatives have been considered.
- Expert opinion for: Evidence is lacking; the level of certainty is low. Expert opinion guides this recommendation.
- Expert opinion against: Evidence is lacking; the level of certainty is low. Expert opinion suggests not implementing the intervention/procedure.
- Against: Evidence suggests not implementing the intervention/procedure or discontinuing ineffective procedures.

These recommendations aim to identify the level of evidence for –and, at the same time, offer the “scientific truth” behind – the various procedures and interventions discussed in the current dental literature on dental implants. It is important to point out here that these should not be understood as merely a “clinical guide” but as the preferred modes of treatment that could be implemented in clinical practice.

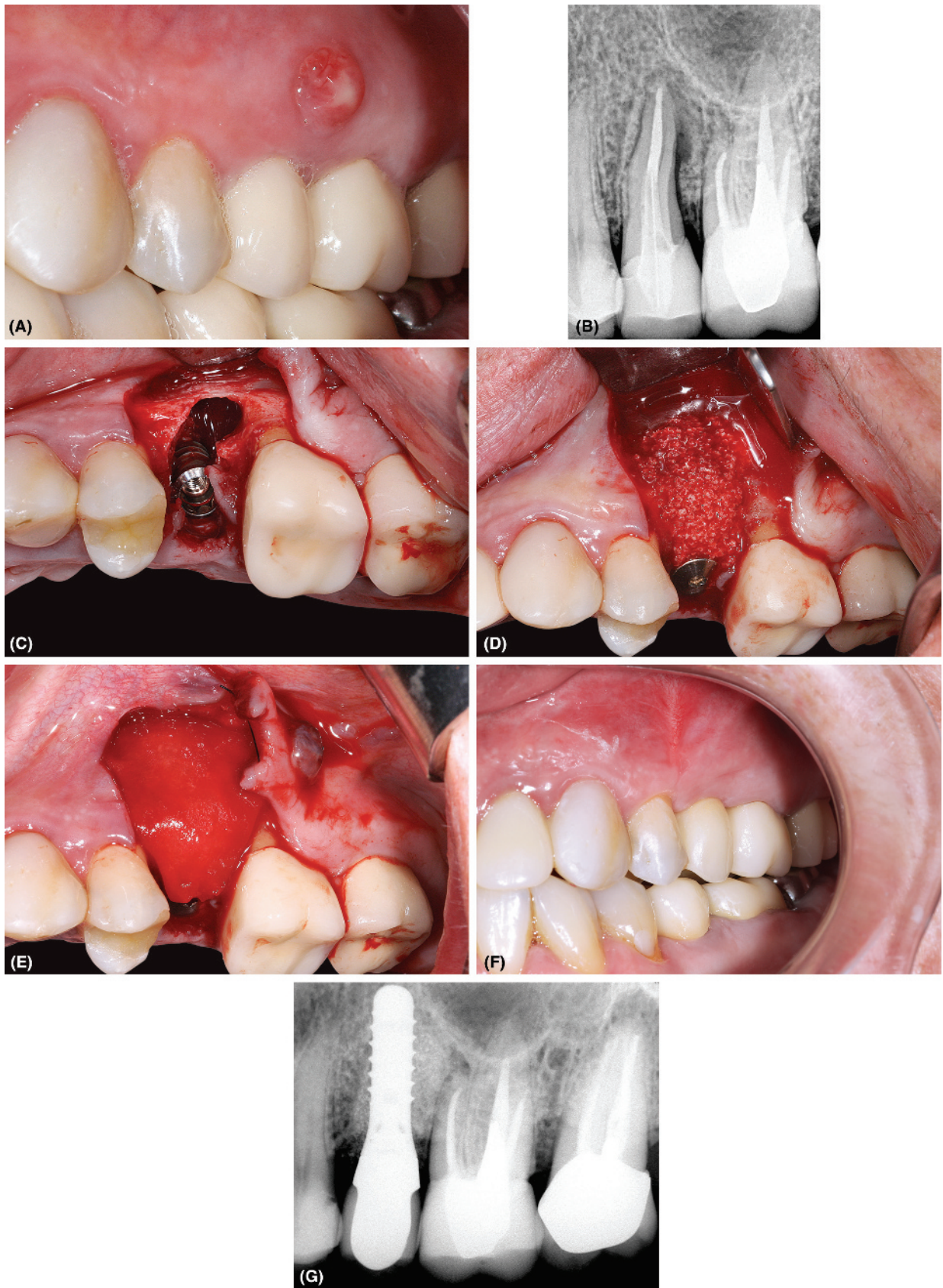


Figure 1.8 (A) Presence of infection with fistula associated with tooth #13. (B) Intraoral radiographic exam shows periapical lesion around tooth #13. (C) After remission of the acute phase, tooth #13 was extracted followed by an immediate implant placement. (D) The bone defect was filled with biphasic calcium phosphate (Straumann® BoneCeramic™). (E) Absorbable collagen membrane covering the grafted site. (F) Restorative treatment consisted of a screw-retained porcelain-fused-to-metal restoration. Healthy soft tissue with no signs of infection. (G) Three-year follow-up intraoral radiograph.

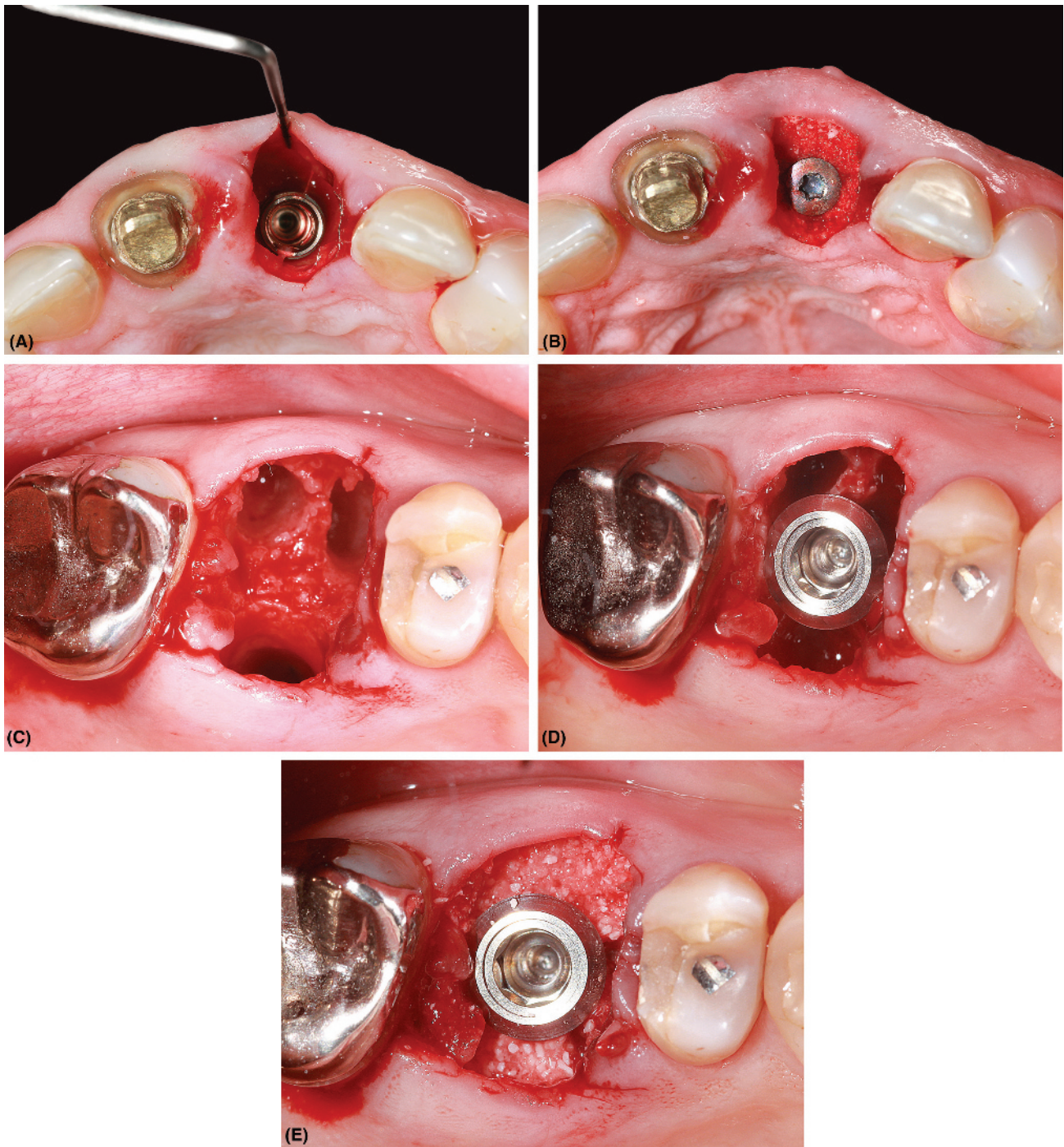


Figure 1.9 (A) Immediate implant placement at site #9. There is a bone defect at the buccal wall. (B) Defect filling with DBBM (Bio-Oss collagen). (C) Post-extraction alveolar ridge at site # 3. (D) Immediate implant in position (Straumann SLActive Wide Neck Tissue Level™). (E) Gap filling with DBBM (Bio-Oss collagen).

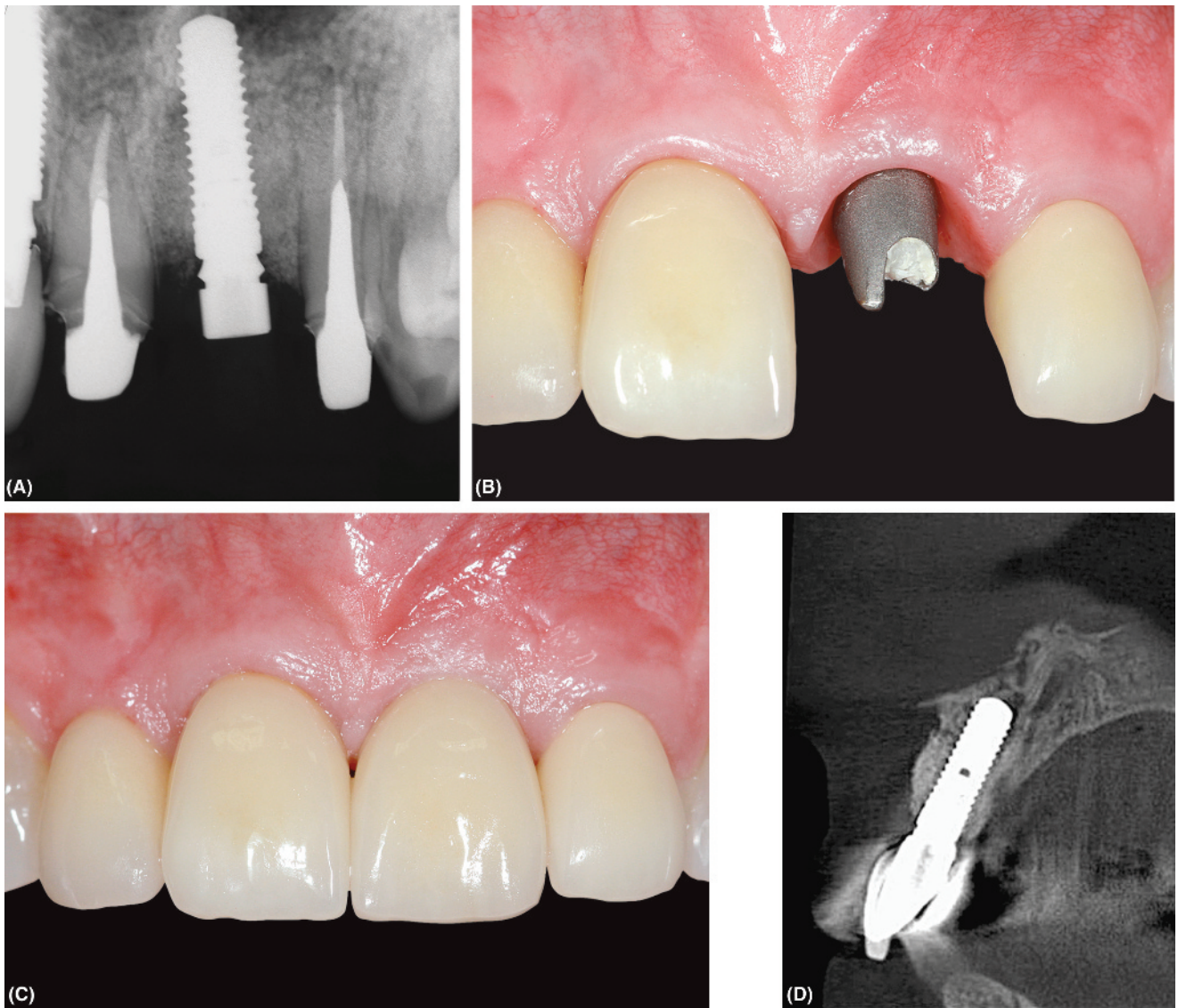


Figure 1.10 (A) Implant placed in site tooth #9 – periapical radiograph. (B) Customized cementable abutment in position. Healthy soft tissue two years post implantation. (C) e.max® cemented restoration. (D) CBCT shows thick bone walls after two years of loading. Bone substitute (DBBM (Bio-Oss collagen)) is clearly detectable at the buccal wall (arrow).

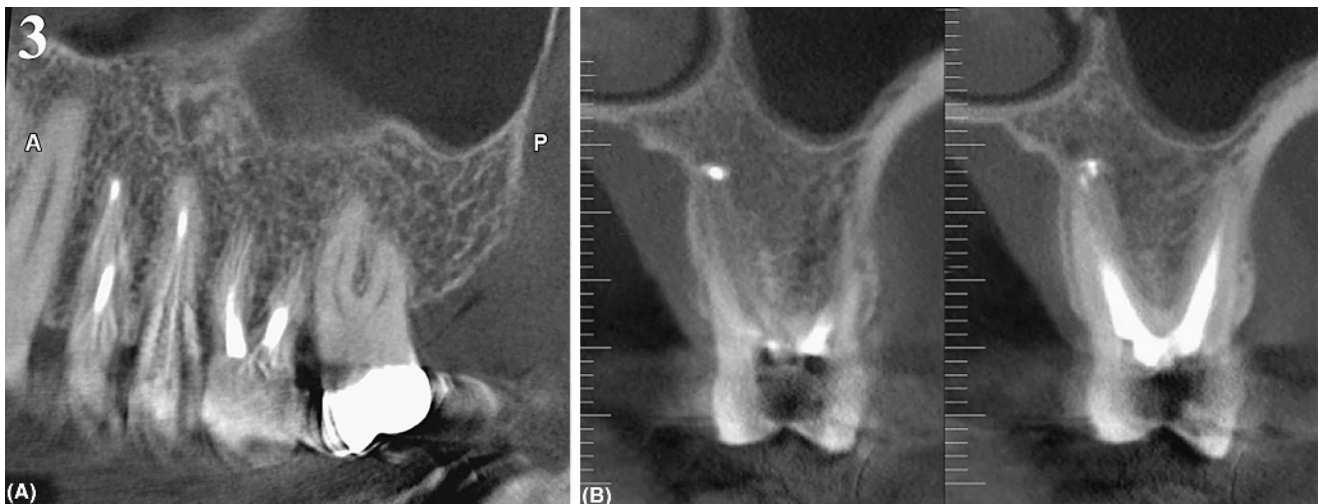


Figure 1.11 CBCT. (A) Parasagittal section. (B) Transaxial section.

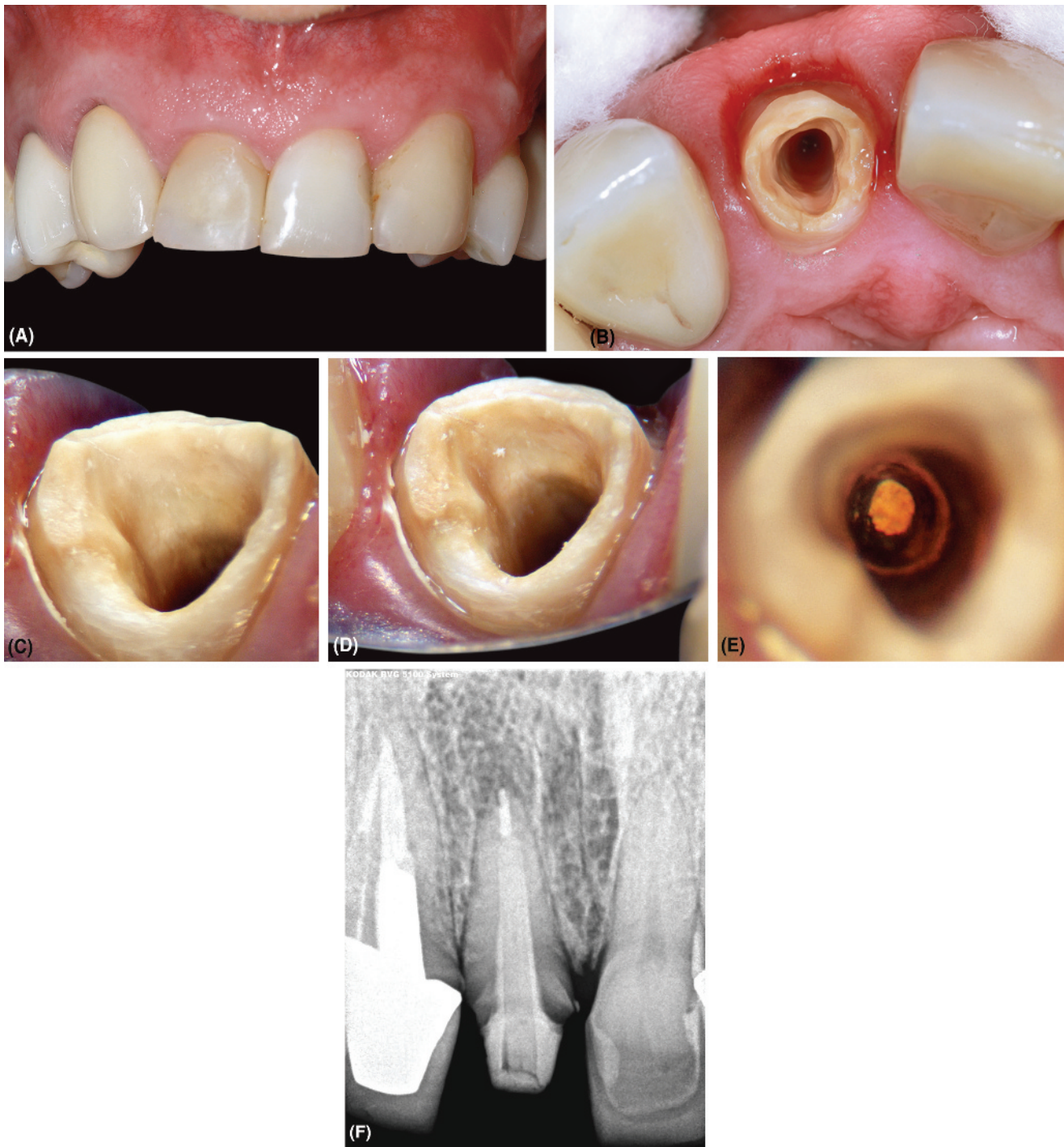


Figure 1.12 (A) Clinical restorative evaluation of tooth #8. (B) Root evaluation. (C-E) Magnification of root canal examination. (F) After careful evaluation tooth #8 it was decided not to remove the tooth and a fiberglass post was cemented inside the root canal – periapical radiograph.

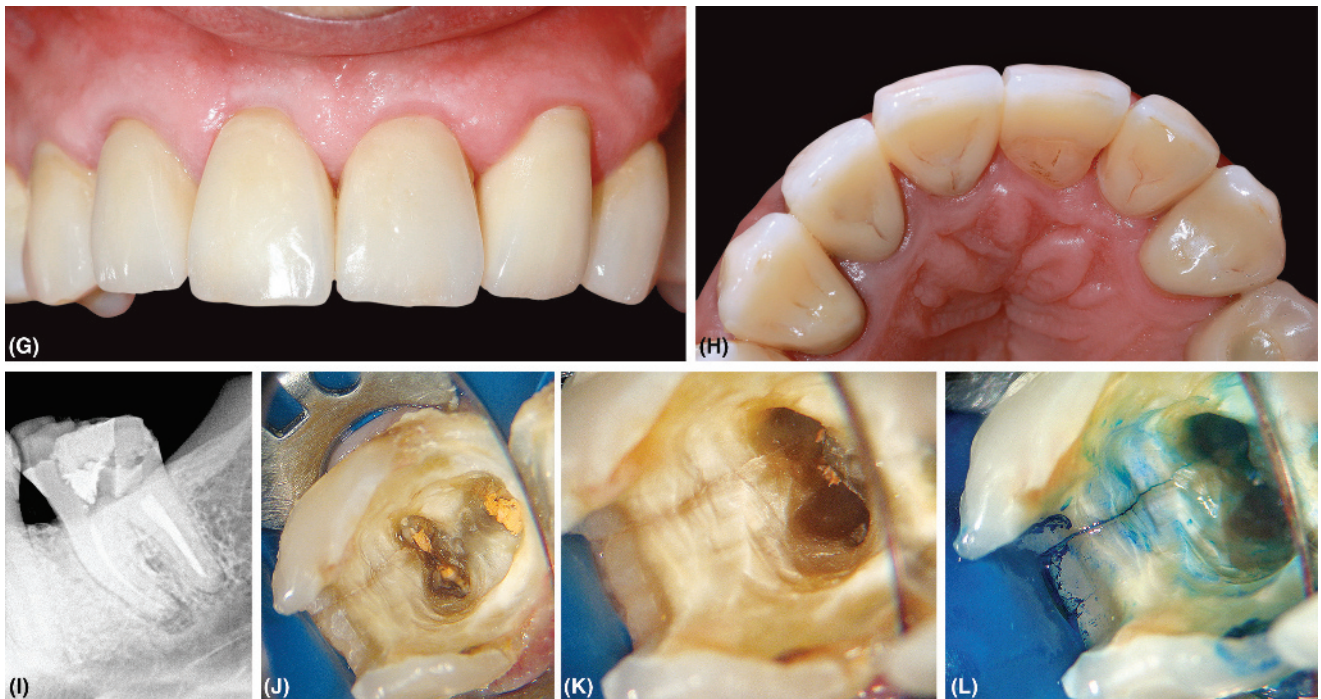


Figure 1.12 (G, H) Restorative treatment with e.max crowns and veneers – buccal and palatal views. (I) Initial X-ray shows endodontic lesion on tooth #18. (J, K) Clinical examination under microscope detected a fracture line at the mesiolingual canal. (L) Toluidine-blue staining the fracture line. Source: Courtesy of Dr. Marina Tosta – Endodontist.

Table 1.1 Level of certainty in the body of evidence included in the review

Level of certainty	Description
High	The body of evidence usually includes consistent results from well-designed, well-conducted studies in representative populations. This conclusion is unlikely to be strongly affected by the results of future studies. <i>This statement is strongly established by the best available evidence.</i>
Moderate	As more information becomes available, the magnitude or direction of the observed effect could change, and this change could be large enough to alter the conclusion. <i>This statement is based on preliminary determination from the current best available evidence, but confidence in the estimate is constrained by one or more factors, such as:</i> <ul style="list-style-type: none"> • the limited number or size of studies • plausible bias that raises some doubt about the results • inconsistency of findings across individual studies • imprecision in the summary estimate • limited applicability owing to the populations of interest • evidence of publication bias • lack of coherence in the chain of evidence.
Low	More information could allow a reliable estimation of effects on health outcomes. <i>The available evidence is insufficient to support the statement or the statement is based on extrapolation from the best available evidence. Evidence is insufficient or the reliability of estimated effects is limited by factors such as:</i> <ul style="list-style-type: none"> • the limited number or size of studies • plausible bias that seriously weakens confidence in the results • inconsistency of findings across individual studies • imprecision in the summary estimate • gaps in the chain of evidence • findings not applicable to the populations of interest • evidence of publication bias • a lack of information on important health outcomes.

Source: Adapted from [35].

Table 1.2 Balancing potential benefit and harm

Level of certainty	Net benefit rating		
	<i>Benefits outweigh potential harm</i>	<i>Benefits balanced with potential harm</i>	<i>No benefit or potential harm outweigh potential harm</i>
High	Strong	In favor	Against
Moderate	In favor	Weak	Against
Low	<i>Expert opinion for or against</i>		

Adapted from [35].

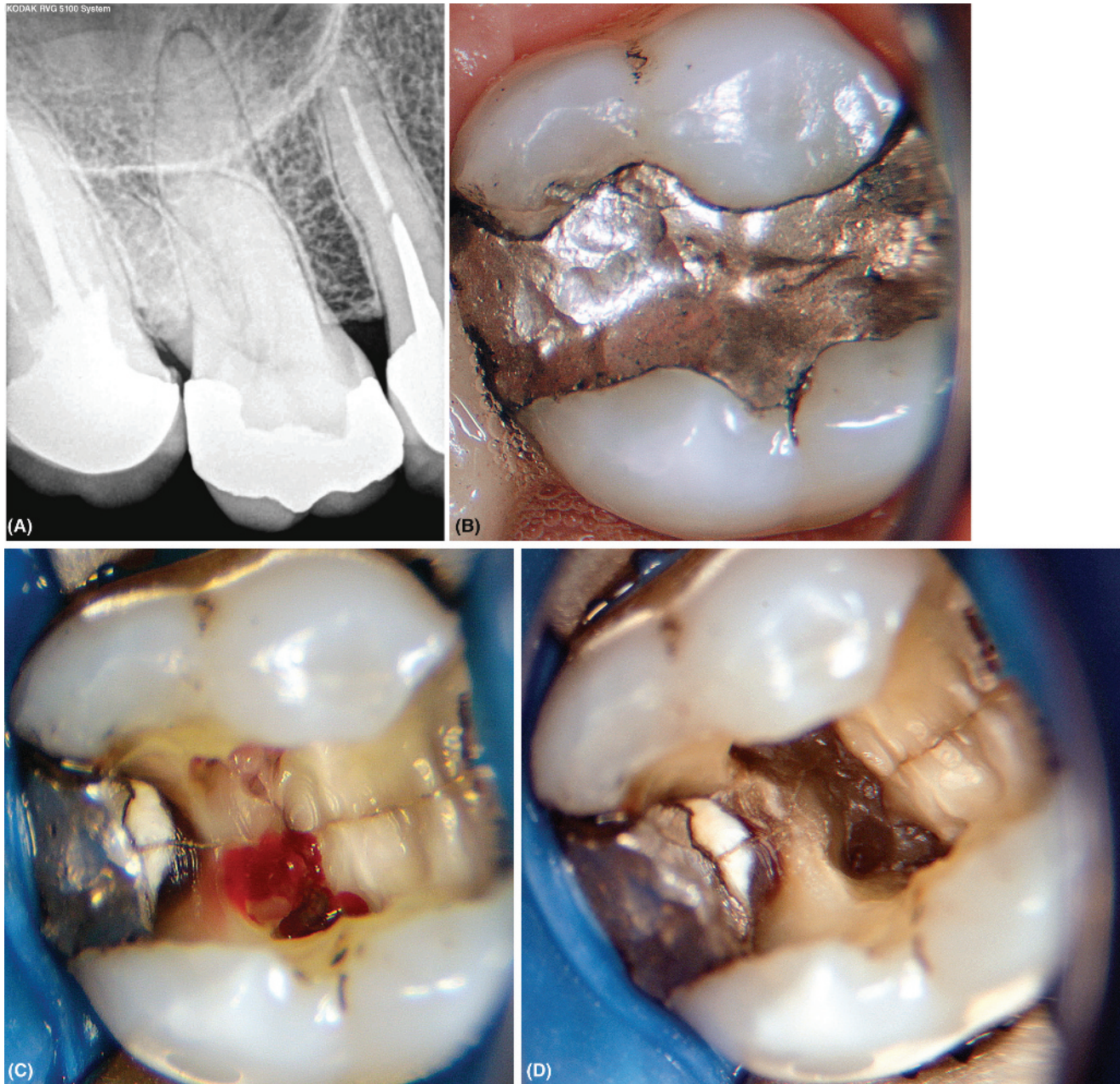


Figure 1.13 (A) Initial periapical radiograph of tooth #3. (B) Clinical evaluation of tooth #3. Patient reported pain, and temperature variation clinical tests showed compromised vitality. (C) After removal of an old amalgam filling, microscope check showed a fracture line. (D) After root canal cleaning, the diagnosis was further confirmed and tooth #3 was referred for extraction. *Source:* Courtesy of Dr. Marina Tosta – Endodontist.

References

- 1 Brånemark, P. I., Adell, R., Breine, U., *et al.* (1969) Intra-osseous anchorage of dental prostheses: I: Experimental studies. *Scand J Plast Reconstr Surg*, **3**: 81–100.
- 2 Schroeder, A., Pohler, O., and Sutter, F. (1976) Gewebsreaktion auf ein Titan-Hohlzylinderimplantat mit Titan-Spritzschichtoberfläche. *Schweiz Monatsschr Zahn-med*, **86**: 713–727.
- 3 Brånemark, P. I., Hansson, B. O., Adell, R., *et al.* (1977) Osseointegrated implants in the treatment of the edentulous jaw: Experience from a 10-year period. *Scand J Plast Reconstr Surg Suppl*, **16** (Suppl.): 1–132.
- 4 Schroeder, A., van der Zypen, E., Stich, H., and Sutter, F. (1981) The reactions of bone, connective tissue, and epithelium to endosteal implants with titanium sprayed surfaces. *J Maxillofac Surg*, **9**: 15–25.
- 5 Adell, R., Lekholm, U., Rockler, B., and Branemark, P. I. (1981) A 15-year study of osseointegrated implants in the treatment of the edentulous jaw. *Int J Oral Surgery*, **10**: 387–416.
- 6 Jemt, T., Lekholm, U., and Adell, R. (1989) Osseointegrated implants in the treatment of partially edentulous patients: A preliminary study on 876 consecutively placed fixtures. *Int J Oral Maxillofac Implants*, **4**: 211–217.
- 7 Zarb, G. A. and Schmitt, A. (1993) The longitudinal clinical effectiveness of osseointegrated dental implants in anterior partially edentulous patients. *Int J Prosthodont*, **6**: 180–188.
- 8 Zarb, G. A. and Schmitt, A. (1993) The longitudinal clinical effectiveness of osseointegrated dental implants in posterior partially edentulous patients. *Int J Prosthodont*, **6**: 189–196.
- 9 Strietzel, F. P., Reichart, P. A., Kale, A., *et al.* (2007) Smoking interferes with the prognosis of dental implant treatment: a systematic review and meta-analysis. *J Clin Periodontol*, **34**: 523–544.
- 10 Pjetursson, B. E., Tan, K., Lang, N. P., *et al.* (2004) A systematic review of the survival and complication rates of fixed partial dentures (FPDs) after an observation period of at least 5 years: I: Implant-supported FPDs. *Clin Oral Implants Res*, **15**: 625–642.
- 11 De la Rosa, G. M., Rodriguez, A., Sierra, K., *et al.* (2013) Predictors of peri-implant bone loss during long-term maintenance of patients treated with 10 mm implants and single crowns restorations. *Int J Oral Maxillofac Implants*, **28**: 798–802.
- 12 Chambrone, L., Preshaw, P. M., Ferreira, J. D., *et al.* (2014) Effects of tobacco smoking on the survival rate of dental implants placed in areas of maxillary sinus floor augmentation: A systematic review. *Clin Oral Implants Res*, **25**: 408–416.
- 13 Lang, N. P. and Zitzmann, N. U., on behalf of Working Group 3 of the VIII European Workshop on Periodontology (2012) Clinical research in implant dentistry: Evaluation of implant-supported restorations, aesthetic and patient-reported outcomes. *J Clin Periodontol*, **39** (Suppl. 12): 133–138.
- 14 Pjetursson, B. E., Bragger, U., Lang, N. P., and Zwahlen, M. (2007) Comparison of survival and complication rates of tooth-supported fixed dental prostheses (FPDs) and implant-supported FPDs and single crowns (SCs). *Clin Oral Implants Res*, **18** (Suppl. 3): 97–113.
- 15 Chambrone, L., Chambrone, L. A., and Lima, L. A. (2010) Effects of occlusal overload on periimplant tissue health: A systematic review of animal-model studies. *J Periodontol*, **81**: 1367–1378.
- 16 Esposito, M., Grusovin, M. G., Willings, M., *et al.* (2007) The effectiveness of immediate, early, and conventional loading of dental implants: A Cochrane systematic review of randomized controlled clinical trials. *Int J Oral Maxillofac Implants*, **22**: 893–904.
- 17 Faggion, C. M. Jr, Chambrone, L., Listl, S., and Tu, Y. K. (2013) Network meta-analysis for evaluating interventions in implant dentistry: The case of peri-implantitis treatment. *Clin Implant Dent Related Res*, **15**: 576–588.
- 18 Chambrone, L. (2015) Evidence-based decision-making: An overview. In: Chambrone, L. (ed.) *Evidence-based Periodontal and Peri-Implant Plastic Surgery: A clinical roadmap from function*. Basel, Switzerland: Springer International Publishing AG.
- 19 Buser, D., Bragger, U., Lang, N. P., and Nyman, S. (1990) Regeneration and enlargement of jaw bone using guided tissue regeneration. *Clin Oral Implants Res*, **1**: 22–32.
- 20 Schenk, R. (1994) Bone healing: Biologic basis. In: Buser, D., Dahlin, C., and Schenk, R. *Guided Bone Regeneration in Implant Dentistry*. Chicago: Quintessence: 49–101.
- 21 Dahlin, C. (1994) Scientific background of guided bone regeneration. In: Buser, D., Dahlin, C., and Schenk, R. *Guided Bone Regeneration in Implant Dentistry*. Chicago: Quintessence: 31–48.
- 22 Simion, M., Baldoni, M., and Zaffe, D. (1992) Jawbone enlargement using immediate implant placement associated with a split-crest technique and guided tissue regeneration. *Int J Periodontics Restorative Dent*, **12**: 463–473.
- 23 Buser, D. (2009) Implant placement with simultaneous guided bone regeneration: Selection of biomaterials and surgical principles. In: Buser, D. (ed.) *Twenty Years of Guided Bone Regeneration in Implant Dentistry*, 2nd edn. Hanover Park, IL: Quintessence: 123–152.
- 24 Bornstein, M. M., von Arx, T., and Bosshardt, D. D. (2009) Properties of barrier membranes. In: Buser, D. (ed.) *Twenty Years of Guided Bone Regeneration in Implant Dentistry*, 2nd edn. Hanover Park, IL: Quintessence: 46–70.
- 25 Jensen, S. S., Bosshardt, D. D., Buser, D. (2009) Bone grafts and bone substitute materials. In: Buser, D. (ed.) *Twenty Years of Guided Bone Regeneration in Implant Dentistry*, 2nd edn. Hanover Park, IL: Quintessence: 71–96.
- 26 Cochran, D. L., Buser, D., Bruggenkatte, C. M., *et al.* (2002) The use of reduced healing times on ITI implants with a sandblasted and acid-etched (SLA) surface: Early results from clinical trials on ITI SLA implants. *Clin Oral Implants Res*, **13**: 144–153.
- 27 Buser, D., Broggin, N., Wieland, M., *et al.* (2004) Enhanced bone apposition to a chemically modified SLA titanium surface. *J Dent Res*, **83**: 529–533.
- 28 Araújo, M. G. and Lindhe, J. (2005) Dimensional ridge alterations following tooth extraction: An experimental study in the dog. *J Clin Periodontol*, **32**: 212–218.
- 29 Botticelli, D., Perrson, L. G., Lindhe, J., and Berglundh, T. (2006) Bone tissue formation adjacent to implants placed in fresh extractions sockets: An experimental studies in dogs. *Clin Oral Implants Res*, **17**: 351–358.
- 30 Wiskott, H. W. A. and Belser, U. (1992) Mechanical resistance of cemented post and core build-ups for ITI Bonefit implants. *Clin Oral Impl Res*, **3**: 128–135.
- 31 Ateih, M. A., Ibrahim, H. M., and Atieh, A. H. (2010) Platform switching for marginal bone preservation around dental implants: A systematic review and meta-analysis. *J Periodontol*, **81** (10): 1350–1366.
- 32 Sutter, F., Weber, H. P., Sorensen, J., and Belser, U. (1993) The new restorative concept of the ITI@DENTAL IMPLANT SYSTEM: Design and engineering. *Int J Periodontics Restorative Dent*, **13**: 409–431.
- 33 Patel, S. (2009) New dimensions in endodontic imaging: Part 2: Cone beam computed tomography. *Int End J*, **42**: 463–475.
- 34 Kan, J. Y., Roe, P., Rungcharassaeng, K., *et al.* (2011) Classification of sagittal root position in relation to the anterior maxillary osseous housing for immediate implant placement: A cone beam computed tomography study. *Int J Oral Maxillofac Implants*, **26**: 873–876.
- 35 American Dental Association (2013) *ADA Clinical Practice Guidelines Handbook*, http://ebd.ada.org/~media/EBD/Files/ADA_Clinical_Practice_Guidelines_Handbook-2013.ashx, accessed April 19th, 2017.

