

SECTION



1

Diseases and Conditions

COPYRIGHTED MATERIAL



CHAPTER 1

Acetaminophen Toxicosis

Sharon Fooshee Grace

Overview

Acetaminophen toxicosis usually occurs when well-intentioned owners, unaware of the significant toxicity of this drug in cats, administer the drug for a variety of reasons. Most case reports indicate that owners give acetaminophen to individual cats as a pain reliever. Ingestion of as little as 10 mg/kg of acetaminophen may be fatal for some cats. This is less than one regular-strength tablet (325 mg) for a 4–5-kg (8.8–11-lb) cat. One case report described fatal toxicosis in a kitten that had played with an empty acetaminophen bottle. Methemoglobinemia and Heinz body hemolytic anemia are the classic hematologic findings in poisoned cats.

Acetaminophen preys upon several metabolic peculiarities of the feline species. Once the cat's limited ability to produce nontoxic drug metabolites via sulfate and glucuronide conjugation has been exceeded, toxic metabolites accumulate. The hepatic cytochrome P450 oxidase system converts acetaminophen to the reactive electrophilic intermediate N-acetyl-para-benzoquinoneimine (NAPQ1). This compound is believed to be responsible for cell injury, such as can occur in the liver, but is no longer thought to be the cause of methemoglobinemia. Recent research has indicated that para-aminophenol (PAP) is the likely metabolite leading to development of methemoglobinemia in cats ingesting acetaminophen.

As hemoglobin is oxidized from its normal ferrous state (+2) to a ferric state (methemoglobin, +3), it becomes unable to effectively deliver oxygen to tissues, with catastrophic consequences for the patient. Notably, even under normal circumstances, the feline erythrocyte is vulnerable to oxidative stress because of the relatively large number of sulfhydryl groups present in cat hemoglobin. Further, precipitation of damaged hemoglobin on the erythrocyte membrane leads to the second significant event: development of Heinz body hemolytic anemia. The feline spleen is relatively ineffective at removing Heinz bodies from erythrocyte membranes so they persist, with the net effect of increased erythrocyte membrane fragility, decreased deformability, and development of hemolytic anemia. Whereas methemoglobinemia is potentially reversible, Heinz body formation and damage to the red blood cell membrane is not. Finally, acetaminophen toxicosis may uncommonly cause feline liver necrosis via NAPQ1-mediated damage to hepatocyte membranes and reaction with hepatocellular proteins. However, hepatic damage in cats is usually minimal when compared with that typically seen in humans (and in dogs at very high doses).

Earliest signs of toxicosis include anorexia, vomiting, and ptyalism. The appearance of cyanotic or brown-colored mucous membranes may occur within a few hours of drug ingestion and heralds the onset of significant methemoglobinemia. Edema of the face and paws is common, although the precise cause for these findings remains unclear. As Heinz body hemolytic anemia develops within hours to a few days of drug ingestion, the mucous membranes become pale and sometimes icteric.

The Feline Patient, Fifth Edition. Edited by Gary D. Norsworthy.
© 2018 John Wiley & Sons, Inc. Published 2018 by John Wiley & Sons, Inc.
Companion website: www.wiley.com/go/norsworthy/feline

Diagnosis

Primary Diagnostics

- **History:** Because the clinical signs are not always distinctive, a history of acetaminophen administration or potential exposure to the drug is critical to help confirm a diagnosis.
- **Clinical Signs:** The appearance of cyanotic or brown-colored mucous membranes and facial and paw edema are noteworthy. Other findings may include vocalization, tachycardia, dyspnea, depression, and weakness. Icterus may occur 24–48 hours after drug ingestion.
- **Complete Blood Count (CBC):** Submitted blood will often have a dark brown color (see Diagnostic Notes below). Typical findings include anemia and the appearance of Heinz bodies on the red cell membrane. See Figure 1.1. Reticulocytes may appear several days later if the cat survives. Heinz bodies and reticulocytes are more easily recognized if a drop of new methylene blue stain is applied to an air-dried blood smear, which is then coverslipped and examined microscopically (see Chapter 314).
- **Chemistry Profile:** Hepatocellular leakage enzymes may be mildly to severely elevated. Since acetaminophen does not commonly cause significant hepatic necrosis in cats, these elevations could be due to hepatocyte hypoxia. Serum bilirubin is sometimes increased.
- **Urinalysis:** Chocolate- or red-colored urine may be seen due to methemoglobinuria or hematuria.

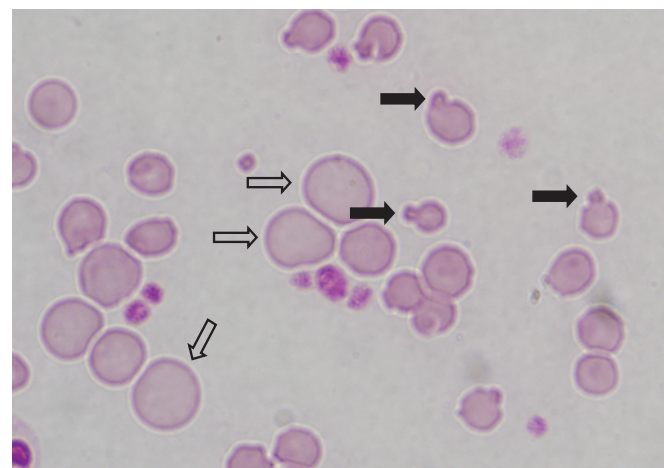



Figure 1.1 Heinz body formation (*closed arrows*) on the red blood cells is one of the diagnostic features of acetaminophen toxicity. The large, non-nucleated erythrocytes (*open arrows*) (macrocytes or reticulocytes) indicate a regenerative anemia. Image courtesy of Dr. Gary D. Norsworthy.



SECTION 1: Diseases and Conditions

Diagnostic Notes

- In healthy, nonanemic cats, up to 5% of erythrocytes may contain Heinz bodies. As such, detection of occasional Heinz bodies should be considered normal in cats.
- Methemoglobinemia is the usual cause of death. Signs of methemoglobinemia appear when more than 20–30% of hemoglobin is in the form of methemoglobin.
- Methemoglobinemia is sometimes difficult to discern in a blood sample because venous blood is normally dark. As a clinical screening test, one drop of patient blood can be placed on a white paper towel or filter paper next to a drop of normal “control” blood. If the methemoglobin content is greater than 10%, the patient’s blood is expected to be noticeably brown when compared to the brighter red of the control blood.
- Acetaminophen serum concentration may be measured and is maximally increased 2–3 hours post-ingestion. In most cases, it is unnecessary and impractical to measure blood levels of the drug.

Therapy**Primary Therapeutics**

- Removal of the Toxin: Acetaminophen is rapidly absorbed from the gastrointestinal tract so emesis should be induced only if drug ingestion has occurred within the previous 1–2 hours. Emesis may be induced by apomorphine or xylazine. Use of activated charcoal is controversial; it should be given only if acetaminophen ingestion has occurred within the preceding 2 hours. Because of the risk for aspiration pneumonia, activated charcoal should be used cautiously if the cat is vomiting or if emesis has been induced. If acetylcysteine is given orally, charcoal may bind the drug.
- Acetylcysteine (Mucomyst®): This drug is recommended as a specific antidote. It supplies precursors for replenishment of the antioxidant glutathione. Available solutions are in 10% and 20% concentrations and should be diluted in a 5% dextrose solution for both intravenous and oral routes of therapy. An initial oral or intravenous dose of 130–140 mg/kg should be followed by 70 mg/kg q6h PO or IV for five to seven treatments. It is recommended that intravenous treatments be administered through a 0.2 µm millipore filter over 30–60 minutes. Some have suggested that oral administration may be superior to the intravenous route because of the higher concentration of drug available to the liver via portal circulation. It has been shown that therapy is less effective when started more than 8 hours after ingestion of acetaminophen, though there may still be some benefit appreciated when treating up to 80 hours post-ingestion. The majority of benefit from acetylcysteine is directed toward protection of the liver against oxidative injury and not resolution of methemoglobinemia.

Secondary Therapeutics

- Ascorbic Acid (vitamin C): Vitamin C is an antioxidant which, through nonenzymatic means, is proposed to assist in reduction of methemoglobin back to hemoglobin, though the process is slow. This is an adjunctive therapy and should not be substituted for acetylcysteine administration. Give 30 mg/kg PO for six treatments. Alternatively, give 30 mg/kg q6h IV until methemoglobinemia resolves. Consult a formulary before mixing ascorbic acid with other solutions due to a high likelihood of incompatibility.
- S-Adenosylmethionine (SAME): SAME, currently marketed as Denosyl® and Denamarin® by Nutramax Laboratories, demonstrates hepatoprotective and systemic antioxidant properties. SAME has been shown to increase the cat’s resistance to oxidative stress. In one placebo-controlled feline study evaluating oxidant injury

caused by acetaminophen, SAME-treated cats had reduced Heinz body formation and erythrocyte destruction as compared to cats receiving only acetaminophen. However, additional studies need to be done, especially regarding its effect on methemoglobinemia, which did not appear to improve with SAME therapy in the aforementioned study. At this time, it should be considered an adjunctive treatment.

- Transfusion with Blood or Hemoglobin Solutions: Administration of whole blood may be useful in cats with severe hemolytic anemia and should be considered if the hematocrit falls below 20%. Signs of hypoxemia would also warrant a transfusion, even with a normal hematocrit, as the hematocrit is not a true reflection of the oxygen-carrying capacity of the blood. Oxyglobin®, a hemoglobin solution, appears unlikely to return to the market, at least for the foreseeable future.
- Supportive Therapy: This may include intravenous fluids, electrolytes, and limited handling of the patient.

Therapeutic Notes

- Cimetidine was previously recommended as ancillary therapy. Many toxicologists now consider it contraindicated as it interferes with biochemical pathways that attempt to detoxify the PAP metabolite.
- Corticosteroids are of no value.
- The literature contains varied opinions about the benefit of oxygen therapy because methemoglobin is unable to bind oxygen. However, it is reasonable to consider oxygen support, as long as oxygen administration does not further stress the patient. An oxygen cage is preferred to an oxygen mask.
- Hyperbaric oxygen therapy is efficacious in humans with acetaminophen toxicosis and should be tried if available.
- Though opinions vary, most consider that methylene blue is contraindicated in treatment of this disorder because of the potential to worsen the hemolytic anemia.
- A positive response to therapy is indicated by improvement within 48 hours.

Prognosis

A grave prognosis is indicated when methemoglobinemia and Heinz body hemolytic anemia are severe and unresponsive to appropriate therapy. For cats that recover, no long-term effects have been reported.

Suggested Readings

- Court, M.H. (2013) Feline drug metabolism and disposition: Pharmacokinetic evidence for species differences and molecular mechanisms. *Vet Clin North Am Small Anim Pract* 43(5), 1039–1054.
- McConkey, S., Grant, D., Cribb, A. (2009) The role of para-aminophenol in acetaminophen-induced methemoglobinemia in dogs and cats. *J Vet Pharm Therapeu* 32(6), 585–595.
- Webb, C.B., Twedt, D.C., Fettman, M.J., et al. (2003) S-adenosylmethionine (SAME) in a feline acetaminophen model of oxidative injury. *J Fel Med Surg* 5(2), 69–75.

Norsworthy’s Notes

Brown is the unique key to diagnosing this disease: mucous membranes, serum, and/or urine. Toxic amounts are absorbed within 2 hours after ingestion so prompt treatment is essential for a good outcome. The use of acetylcysteine greatly increases response.