

PART I

MANAGEMENT OF MAXILLOFACIAL DEFECTS USING CAD/CAM TECHNOLOGY

COPYRIGHTED MATERIAL

COMPARATIVE ACCURACY OF FACIAL MODELS FABRICATED USING TRADITIONAL AND 3D IMAGING TECHNIQUES

KETU P. LINCOLN, DMD,¹ ALBERT Y. T. SUN, PHD, CSWA,² THOMAS J. PRIHODA, PHD,³ AND
ALAN J. SUTTON, DDS, MS, FACP⁴

¹Department of Graduate Prosthodontics, USAF, Joint Base San Antonio-Lackland, San Antonio, TX

²Department of Mechanical Engineering, National Taipei University of Technology, Taipei, Taiwan

³Department of Pathology, University of Texas Health Science Center, San Antonio, TX

⁴Department of Restorative Dentistry, University of Colorado School of Dental Medicine, Aurora, CO

Keywords

Moulage; facial prosthetics; 3D imaging; 3D models; dental materials; stereolithography; rapid prototyping.

Correspondence

Alan Sutton, 13045 E. 17th Ave Ste F845, Aurora, CO 80045. E-mail: Alan.sutton@ucdenver.edu

The authors deny any conflicts of interest.

Accepted June 14, 2015

Published in *Journal of Prosthodontics* September 2015

doi: 10.1111/jopr.12358

ABSTRACT

Purpose: The purpose of this investigation was to compare the accuracy of facial models fabricated using facial moulage impression methods to the three-dimensional printed (3DP) fabrication methods using soft tissue images obtained from cone beam computed tomography (CBCT) and 3D stereophotogrammetry (3D-SPG) scans.

Materials and Methods: A reference phantom model was fabricated using a 3D-SPG image of a human control form with ten fiducial markers placed on common anthropometric landmarks. This image was converted into the investigation control phantom model (CPM) using 3DP methods. The CPM was attached to a camera tripod for ease of image capture. Three CBCT and three 3D-SPG images of the CPM were captured. The DICOM and STL files from the three 3dMD and three CBCT were imported to the 3DP, and six testing models were made. Reversible hydrocolloid and dental stone were used to make three facial moulages of the CPM, and the impressions/casts were poured in type IV gypsum dental stone. A coordinate measuring machine (CMM) was used to measure the distances between each of the ten fiducial markers. Each measurement was made using one point as a static reference to the other nine points. The same measuring procedures were accomplished on all

specimens. All measurements were compared between specimens and the control. The data were analyzed using ANOVA and Tukey pairwise comparison of the raters, methods, and fiducial markers.

Results: The ANOVA multiple comparisons showed significant difference among the three methods ($p < 0.05$). Further, the interaction of methods versus fiducial markers also showed significant difference ($p < 0.05$). The

Craniofacial dysmorphism (CD) is the study of structural defects caused by trauma, treatment of neoplasms, or congenital anomalies characterized by complex irregularities in the shape and configuration of facial soft tissue structures.¹ Patients with CD may undergo extensive surgical procedures, including the fabrication of facial prostheses to restore an extraoral maxillofacial defect.² The facial prostheses are not functional, but provide the patient with an esthetic result for psychological and social acceptance.³⁻⁶

Anthropometry is a way to assess changes in facial soft tissue over time through line measurements between two landmarks.⁷ The challenge has been to identify landmarks and plot them accurately in the three planes of space, in order to describe the dimensions of the face.⁸ Traditionally, direct anthropometry was done using calipers. This assessment was a reliable and inexpensive method for data collection of surface measurements.⁴ However, there were several limitations, including technician training, direct patient contact requiring extensive time to make multiple measurements, patient compliance to sit in one position, inability to archive information, difficulty attaining several measurements as tissue undergoes changes with time, and finally comparing tissue changes with accurate landmark location.⁹

Making a facial moulage impression was, and still is, another means for 3D facial structure capture, analysis, and documentation. This method has been used successfully for almost 100 years, dating back to World War I.¹⁰ Currently, various impression materials like alginate, poly(vinyl siloxane), and reversible hydrocolloid are used to create a facial moulage. The facial moulage method can be time consuming, and soft tissue deformation is a significant problem. Furthermore, it is difficult to obtain accurate impressions of certain defects involving the orbit where the periorbital tissue displaces easily.¹¹ The casts made from the impressions are fragile and require large physical storage space, and it is extremely difficult to communicate physical data to other providers in distant locations.¹² Also, archival preoperative casts may not be available for many patient treatments due to storage limitation.

Several types of 3D imaging systems have been created in the past three decades, including cone beam computed

CBCT and facial moulage method showed the greatest accuracy.

Conclusions: 3DP models fabricated using 3D-SPG showed statistical difference in comparison to the models fabricated using the traditional method of facial moulage and 3DP models fabricated from CBCT imaging. 3DP models fabricated using 3D-SPG were less accurate than the CPM and models fabricated using facial moulage and CBCT imaging techniques.

tomography (CBCT) and 3D stereophotogrammetry (3D-SPG). Both methods are noninvasive and allow for archival of data and virtual models that can subsequently be used for comparison purposes.

Computed tomography (CT), and more specifically CBCT, is currently used to capture soft tissue surface images because it is accurate and repeatable for anthropometric measurements.⁷ Collimating the X-ray beam decreases the radiation exposure dose, and the scan time is 10 to 70 seconds.¹³ The dose of radiation ranges between 60 and 1000 μSv versus medical grade CT of the mandible, which ranges from 1320 to 3324 μSv .¹³⁻¹⁵ More recent studies have generated 3D facial soft tissue surface computer models from image data captured by CBCT. Linear anthropometric measurements on computer models using CBCT software proved reliable and as accurate as the traditional direct method.⁷ The data and virtual models are easily archived without physical storage requirements and can provide pre- and postoperative information for skeletal or soft tissue comparisons.¹³

3D-SPG is a newer technique/method for craniofacial surface imaging that allows for the capture evaluation of the external surface of a subject. The method creates a 3D image reconstructed from multiple digital images taken at different angles simultaneously. The resultant image is a collection of points positioned along an x , y , and z coordinate system. These points can be identified as landmarks, then used for subsequent analysis.⁹ Reports indicate that 3D-SPG is reliable and accurate for determining the location of landmarks and interlandmark craniofacial distances.^{16,17} The advantages include minimal artifact production due to short image capture time (approximately 1.5 ms), ability to archive and compare subject images, three-point (x , y , z) coordinate format of locating tissue landmarks, high resolution, and no radiation. Software programs are available to identify landmarks and calculate anthropometric measurements.¹⁸ In addition, the error in the location of a landmark when using 3D-SPG is less than 1 mm.¹⁹

The use of 3D-SPG has a great potential for use in the military. During World War II, the Korean War, and the Vietnam War, the mean incidence of head, face, and neck injury (HNFI) was approximately 16%. A recent study

looked at the characteristics and causes of HFNI sustained by US military forces during the stability and support phase of Operation Iraqi Freedom (OIF-II). The number of HFNI increased to 39%, and of these injuries, 65% were injuries to the face.²⁰ A more recent study showed a comprehensive analysis of craniomaxillofacial battle injuries sustained by military members evacuated to level III-V military treatment facilities to be 42.2% HNFIs.²¹ The reason for the notable increase in the past decade is an increase in survival rate due to improvement in body armor, battlefield medicine, tactically placed medical units, and quick evacuation tactics.

Both CBCT and 3D-SPG use computer-aided design (CAD) software to facilitate the design of soft tissue surface images and virtual models. With rapid prototyping (RP), information from the CAD software can be used along with computer-aided manufacturing (CAM) to fabricate 3D physical models. Image data from CBCT and 3D-SPG scans translated into the digital imaging and communication in medicine (DICOM) file format, which are converted to a CAM file format to produce a 3D model using RP methods and equipment.

One RP method used in the medical and dental field is 3D printing (3DP). This process uses a polyjet selectively depositing fine powder polymer droplets evenly along a piston and liquid binder. Additional layers are added as the piston powder bed and cured model is lowered layer by layer. The resolution accuracy is 100 μm for one-dimensional features and 300 μm for 3D features.¹¹ The 3D printed models are accurate to 0.016 mm (Objet Eden 260V; Stratasys Ltd., Minneapolis, MN), and the build time is at a rate of 1 cm of height per hour.²²

The 3D models are useful for surgical planning, creation of surgical templates, and fabrication of craniofacial prostheses and custom implants used in craniofacial reconstruction.

The accuracy of the RP models has been measured by software calculations,^{23–25} digital calipers,¹⁸ and more recently the use of a coordinate measurement machine (CMM). The CMM can provide accurate location of x , y , and z coordinate reference points. This device is very useful in locating the same landmark on various models and therefore accurate in determining any error in model production.

RP techniques are proving beneficial in the treatment planning, diagnosis, surgical assistance, prosthesis fabrication and postassessment of patients with craniofacial anomalies, facial trauma, and structural defects caused by neoplasms; however, further studies need to be done to evaluate the precise fit of models fabricated from soft tissue imaging. The purpose of this investigation was to compare the accuracy of facial models fabricated using facial moulage impression methods to the 3DP fabrication methods using soft tissue images obtained from CBCT and 3D-SPG.

MATERIALS AND METHODS

One human form was obtained from a two-pod 3D-SPG surface imaging system and software system (3dMDface; 3dMD, Atlanta, GA). The scanned image was saved as an Standard Triangulation Language (STL) file and uploaded into the modeling software program (Geomagic Freeform Modeling Plus; Geomagic, Wilmington, MA) to create the virtual model. The virtual model was used to design the control phantom model (CPM). Five millimeter diameter spheres were built into the model to mark the following ten landmarks on the facial soft tissue: Glabella, Nasion, Pronasale, right and left Orbitale, right and left Frontale, right and left Cheilion, and Pogonion (Fig 1.1A).^{4,5,7,9,26,27} The

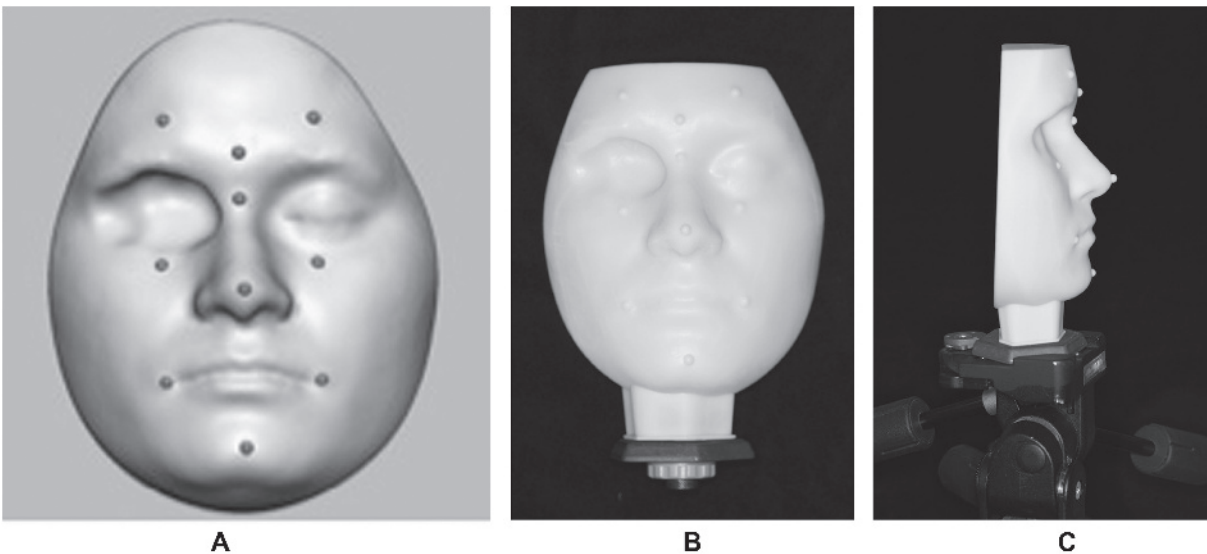


FIGURE 1.1 (A) Virtual model with landmarks. (B) Printed control phantom model (CPM) frontal view. (C) CPM lateral view.

virtual master model was processed using 3DP software (Objet Studio; Stratasys Ltd., Minneapolis, MN), and the physical CPM was created using 3DP (Objet Eden 260V; Stratasys Ltd.) (Figs 1.1B and 1.1C).

The CPM was used to create three facial moulage experimental gypsum dental stone models using reversible hydrocolloid (Polyflex Duplicating Material; Dentsply International, York, PA). Reversible hydrocolloid at room temperature was heated to its liquefaction temperature to convert the gel to the sol condition.²⁸ The reversible hydrocolloid was applied to the CPM using a synthetic brush (Synthetic brush #16; Dentsply). Cotton gauze (2 in²) was embedded in the solidifying reversible hydrocolloid to reinforce the material and allow for the attachment to dental stone. A thin consistency of dental stone (Mounting Stone ISO type 3; Whip Mix Corp., Louisville, KY) was applied over the reversible hydrocolloid and gauze in a uniform half-inch thickness to fabricate an external tray. The ratio of the dental stone to filtered water was 900 g to 170 ml. Once the stone set, the impression was removed from the master model and poured in type IV dental stone (Silky Rock, Whip Mix Corp.) (Fig 1.2A).²⁹ The ratio of type IV dental stone to filtered water was 600 g to 138 ml. Each of the resultant three stone models was labeled accordingly (Fig 1.2B).

To position the CPM for CBCT capture, a tripod measurement base assembly was fabricated using a tripod screw platform with acrylic resin (Ortho Acrylic Resin; Great Lakes Orthodontics, Tonawanda, NY) (Fig 1.3).³⁰ The CBCT system (Kodak 9500 Cone Beam 3D System; Carestream Health, Inc., Rochester, NY) was calibrated following the manufacturer's instructions. The CPM was stabilized on the tripod, and a total of three images were made individually and labeled one through three (Fig 1.4). The images were saved as DICOM files and copied onto a disc for use with the RP system.

The same tripod base assembly for the CPM was used to obtain the 3D-SPG images (3dMDface). The system was calibrated according to the manufacturer's instructions.³¹ The tripod with CPM was positioned at a 15° anterior tilt to capture an image with minimal shadowing (Fig 1.5). A total of three images were made individually and labeled one through three. These images were saved as STL files and saved onto a disc for use with the RP system.

The DICOM images and STL files from the CBCT and 3dMD, respectively, were used to create the virtual models using computer software. A DICOM segmentation program (MIMICS 12.1; Materialise Dental, Plymouth, MI) was used to identify the CPM and generate a surface model (in STL format) from the series of CBCT images (Fig 1.6). The six STL files were aligned, and a common base was designed and merged to the 3D surface of each of the scans. Then, using 3DP (Objet Eden 260V) six individual models were fabricated prior to measurement procedures (Fig 1.7).

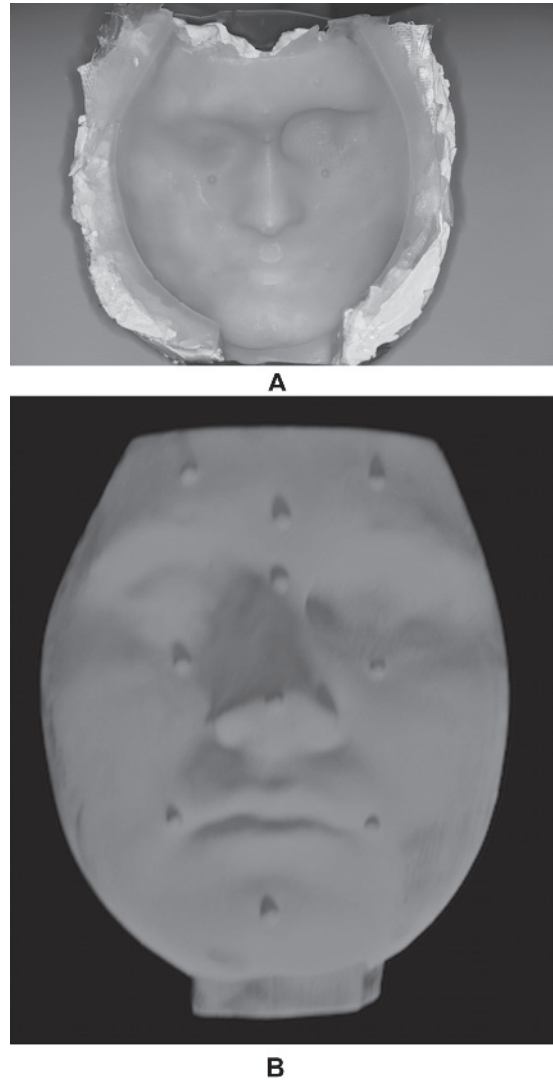


FIGURE 1.2 (A) Reversible hydrocolloid impression. (B) Stone model.

The printed RP models and gypsum stone models were measured for accuracy by three individual raters using a CMM (Faro, Lake Mary, FL). A 3 mm ball probe stylus was placed on the surface of each fiducial marker, and a discrete point cloud was recorded into Geomagic Studio as the measuring software interface. Each cloud data set was interpreted as a sphere feature on the model. The scans resulted in a collection of point cloud data representing the feature location in space relative to each of the other spheres (Figs 1.7 and 1.8).

The software was then used to calculate a best-fit sphere for each of the point cloud groups. Three sphere centers (1, 2, and 10) were used to define a reference plane. New points were defined by projecting each of the sphere centers to the reference plane in a direction normal to the plane (Fig 1.9).



FIGURE 1.3 Tripod assembly.

Nine projected points were then measured against the projected point #3 on the same model. The following 3D Distance Formula was used where $i=1, 2, 4, \dots, 10$ and $j=3$.

$$\sqrt{(x_i - x_j)^2 + (y_i - y_j)^2 + (z_i - z_j)^2}$$

This procedure was accomplished for each landmark on the CPM model and compared to the same measurements obtained on the facial moulage stone reproductions and the printed models.

Statistical Analysis

Vertical distances from point #3 were analyzed. First, the master distances were averaged over the three raters at each point. Then, for each rater on CBCT (CT), 3D-SPG (OP), and stone (ST) the vertical distance from point #3 was subtracted from the master mean of the three raters and divided by the master mean and multiplied by 100 to obtain a percent difference from the master for each rater and each point of the other three methods. The percent differences were



FIGURE 1.4 Tripod positioning for CBCT capture.

analyzed with ANOVA for repeated measures, since the raters repeatedly measured each point from each of the cast methods.

The three raters were compared, the three methods were compared, and the nine points were compared. Since all distances were relative to point #3, those values were always zero, and that point was not included in the analysis. In addition, the two-way interaction of method and points was analyzed. Interactions with the rater factor were the denominators for the F-tests in the ANOVA for repeated measures. Tukey's comparison was done for pairwise comparisons of means following the ANOVA. Residuals of the ANOVA were calculated and plotted to verify they had a near normal bell-shaped curve and that their variance was similar over the range of predicted values.

RESULTS

The percent difference of each of the three methods (CT, OP, ST) from the control mean relative to point 3 for each method is shown in Figure 1.10. The ANOVA was done and is displayed in Table 1.1. The method (meth) by point (pt)

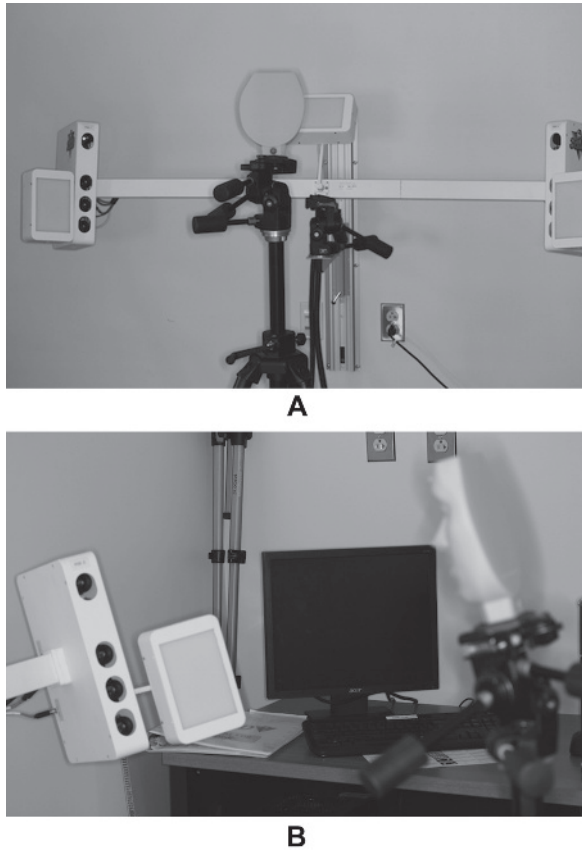


FIGURE 1.5 (A) Tripod positioning of CPM for 3dMD capture. (B) 15° anterior tilt position of CPM.

source was significant. Therefore, a comparison was done with the three methods to the control and each method to each other. Multiple comparisons showed the raters were not different. Pairwise comparisons of the methods were different with OP not having as small a percentage error as the other two methods, while the other two had similar percent error overall (Tables 1.2 and 1.3). Overall, OP showed statistically significant difference ($p < 0.05$) in comparison to the CT and ST; however, Figure 1.10 shows the greatest difference localized to points #1, 2, and 5. The OP data for the other points are similar to the CT and ST findings.

DISCUSSION

The impression technique for making facial models has been used for many years, but a major disadvantage is soft tissue deformation caused by the direct contact of the impression material to the facial soft tissue. Holberg et al reported that making an alginate impression of the face produced between 1 and 3 mm of soft tissue deformation in varying areas.³² Germec-Cakan et al found significant differences between clinical and facial plaster cast measurements explained by distortion related to the impression material.¹² In this study, the CPM was made from a rigid resin material. When a facial moulage was made of the CPM, there were no signs of deformation, which would normally be seen in a patient. Therefore, the results at each point showed very minimal percentage difference in comparison to the CPM.

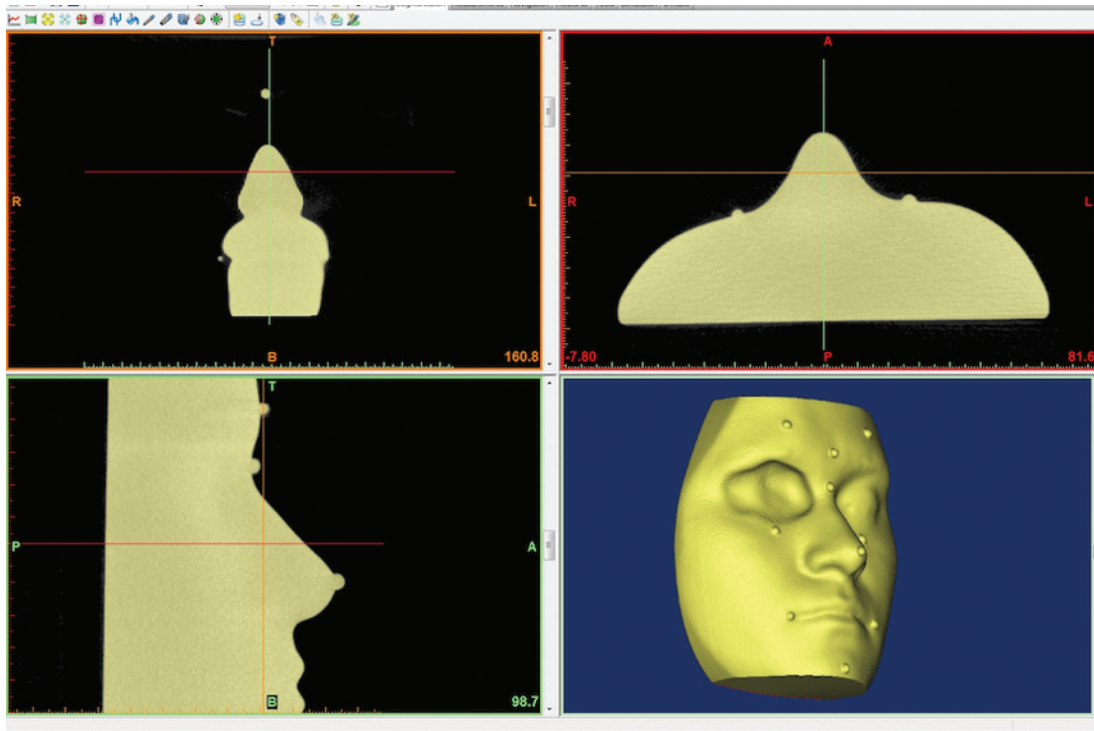


FIGURE 1.6 Mimics DICOM segmentation.



FIGURE 1.7 Point cloud data of spheres 1 to 4.

Numerous studies have shown that imaging done by CT, and more specifically CBCT, is currently used to capture hard and soft tissue surface images because of its accuracy, reliability, and repeatability for anthropometric measurements.^{33–35} Fourie et al compared linear measurements derived from 11 soft tissue landmarks on seven cadaver heads made directly using digital calipers to CBCT-based computer-generated models. Their results showed surface detail of the soft tissue images was insufficient; however, overall, the data proved to be reliable and accurate.⁷ Once again, the CPM was a rigid resin form without soft tissue-like surfaces. The results showed that CT data were not significantly different from the CPM measurements and confirmed that CT-generated models were reliable and accurate.

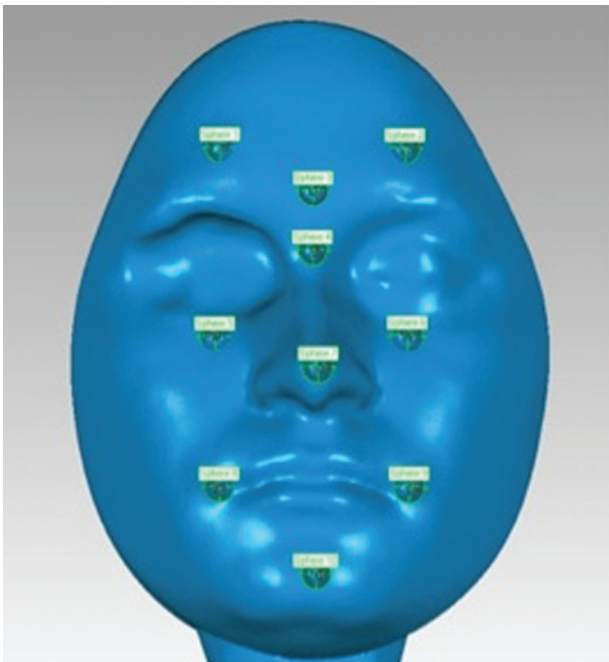


FIGURE 1.8 Point cloud data of spheres 1 to 10.

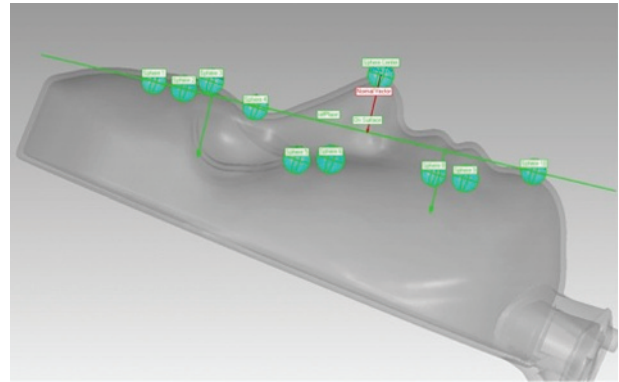


FIGURE 1.9 Defined reference plane using sphere centers of 1, 2, and 10.

3D-SPG imaging provides accurate detail of surface texture, contour, and color. Many studies have been done comparing 3D-SPG imaging to direct anthropometry resulting in repeatable, precise, and accurate measurements.^{16,36,37} Additional studies by Weinberg et al and Wong et al showed an increase in accuracy and precision of landmark location with labeling prior to image capture.^{5,9} In a study done by Plooij et al, midline landmarks were precisely generated compared to pair landmarks, especially if the interlandmark distance increased.¹⁷ In the present study, spherical landmarks were created in the CPM that were reproducible using impression material and the two imaging techniques. Capturing the landmarks was an important factor to calculate the linear measurements and make comparisons of accuracy.

In all of these studies involving CT or 3D-SPG computer-generated images, 3D imaging software was used to calculate linear measurements, which were compared to direct anthropometric measurements. Caliper measurements can be subjective and therefore the accuracy and reliability of the data may be questionable.³⁸ In the present study, a CMM was used to decrease the subjectivity found in using digital calipers. In Taft et al's study,³⁹ stainless steel spheres (5.00 ± 0.005 mm in diameter) were secured on a dry cadaver skull in seven locations. Point locations of the spheres were measured by placing the CMM ball probe on the points of interest, thus improving accuracy and reliability. Also, because the spheres were used as fiducial markers, a mean centroid location was identified for each sphere, and the distance between two points was then determined. In this study, a CMM in conjunction with computer software was used to calculate a best-fit sphere for each of the landmarks. There were three raters who collected point cloud data at each sphere, and a rater pairwise comparison showed no significant difference among the raters. The CMM proved to be reliable and accurate in this study.

Both CBCT and 3D-SPG image files can be imported into CAD/CAM software to create an RP model. The accuracy of the RP models have been studied by measuring distances

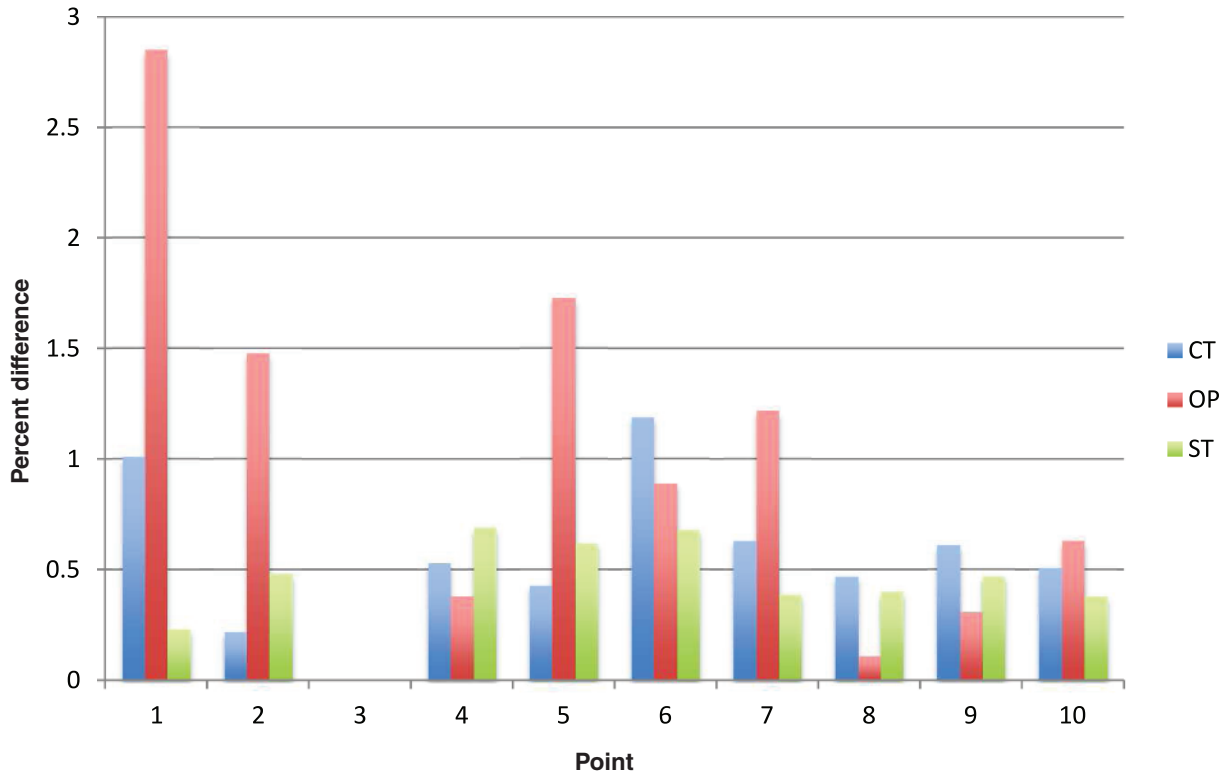


FIGURE 1.10 Percent difference from control mean relative to point 3.

between landmarks on 3D phantom models and comparing those points with measurements calculated through the CT software.²³⁻²⁵ In this study 3DP models were fabricated using the DICOM images and STL files from the CBCT and 3dMD, respectively; however, instead of using computer

software to make the measurements for the CBCT and 3DMD, the CMM was the constant measuring tool for the stone and the 3DP models.

The accuracy of RP models fabricated to replace hard tissue has been studied with skull models and is used in

TABLE 1.1 ANOVA Table for Percent Difference from Master Mean

Source	DF	Sum of Squares	Mean Square	F value	Pr > F
Rater	2	0.53050924	0.26525462	1.60	0.2169
Meth	2	5.03638366	2.51819183	59.86	0.0010
Meth × rater	4	0.16827539	0.04206885	0.25	0.9048
Pt	8	7.17435054	0.89679382	5.05	0.0029
Pt × rater	16	2.83916780	0.17744799	1.07	0.4169
Meth × pt	16	13.47849934	0.84240621	5.09	< 0.0001
Residual	32	5.29215010	0.165379691		
Corrected total	80	34.51933608			

TABLE 1.2 Rater Pairwise Comparison: Tukey Comparison

Rater	Difference Percentage Mean	p-Values	
		versus 2	versus 3
1	0.61600732	0.1984	0.4865
2	0.81106176		0.8187
3	0.74416230		

Table 1.3 Method Pairwise Comparison: Tukey Comparison

Method	Difference Percentage Mean	p-Values	
		versus OP	versus ST
CT	0.62195799	0.0030	0.1357
OP	1.06703386		0.0010
ST	0.48223953		

reconstructive craniofacial surgeries.^{33,39} However, many craniofacial anomalies also involve the facial soft tissue, requiring accurate dimensional measurements to fabricate prosthetics. Studies have been done using CT scans to create casts from the RP models for facial prosthesis engineering.⁴⁰⁻⁴³ Few studies have evaluated the precise fit of prostheses fabricated from RP models manufactured from soft tissue imaging obtained by 3D-SPG.¹⁸ This investigation was limited because a rigid resin model was used as a control.

According to this investigation, 3DP models fabricated using 3D-SPG showed statistical difference compared to the models fabricated using the traditional method of facial moulage and 3DP models fabricated from CBCT imaging. Major discrepancies stemmed from points #1 and 2 (Fig 1.10). The greater difference of the optical scan point values in comparison to those of the models made from CBCT imaging and facial moulage at the other points may be because a two-pod system was used and the 15° anterior angulation of the control during 3dMD image capture.

Percentage differences of the individual points on all three methods in comparison to the control, points #4, 8, 9, and 10 were not statistically significant differences from the CBCT and stone method. Thus, 3D-SPG is a viable option for RP production of facial models, especially in situations where it is not feasible to use CBCT imaging. Many patients with craniofacial dysmorphologies undergo numerous surgeries in a short period of time, and the 3D-SPG method would eliminate radiation exposure from CT. Additionally, the short image capture time would be extremely beneficial for patients with the inability to be still for the time it takes to make a CBCT. Comparative growth studies could be accomplished using this technology, and if necessary, RP models could be engineered to help with treatment needs. The incorporation of this technology is beneficial for the facial reconstruction process because of its high efficiency, the ability to provide accurate facial surface detail, and the overall treatment planning information obtained for patients. The ability to archive images further helps with the treatment process and analysis of any subsequent changes in the soft tissue.

The 3D-SPD method can also be used in conjunction with CBCT.⁴⁴ The accurate hard tissue image obtained from a CBCT can be referenced to a 3D-SPG scan providing detailed images relating the hard tissue with soft tissue for analysis prior to orthognathic surgery. Furthermore, it is difficult to capture an image using 3D-SPG in a defect area where undercuts are present, and the image captured through a CBCT may help define the boundaries of the defect. This merging of hard and soft tissue images can be extremely beneficial in viewing, treatment planning, and fabricating an accurate prosthesis for a craniofacial defect.

In addition, military members suffering from HFNIs present to medical and dental clinics with facial dysmorphologies, such as missing ears, requiring facial prostheses. In the past, these patients required creation of models of the

area of deformity by using previous 2D photographs, an impression of family member anatomical replicas, or a prosthesis fabricated by an anaplastologist to replicate the lost tissue. Now, with 3D-SPG and CBCT images, recreation of missing tissue can be accomplished by banked images, images of family members, or even custom-created anatomic forms. Furthermore, images of military members could be obtained and archived prior to entering a military conflict. If the military member should sustain any HFNI, then the archive image can be referenced to create a model in the fabrication of a more accurate facial prosthesis.

Future Directions

There were limitations to this study. First, the CPM was made from a rigid resin material. When a facial moulage was made of the CPM, there were no signs of deformation, which would normally be seen in a patient. Also, a CT image does capture hard tissue detail accurately but lacks in soft tissue detail. 3D-SPG imaging provides a 3D viewing ability to see soft tissue color and texture detail. Therefore, future studies should be done using a patient with a craniofacial defect, and all three methods should be reinvestigated. Also, investigation of five-pod 3D-SPG systems may provide a more accurate 3D image. Finally, it may be beneficial to investigate the accuracy of 3D-SPG in conjunction with CBCT imaging to fabricate facial models.

CONCLUSION

This investigation was based on an innovative research setting creating facial models using a two-pod 3D-SPG imaging system, and a CBCT imaging method, then comparing the accuracy of these models to the traditional facial moulage impression model fabrication technique.

Within the limitations of this investigation, the following conclusions could be made:

1. 3DP models fabricated using 3D-SPG showed statistical difference in comparison to the models fabricated using the traditional method of facial moulage and 3DP models fabricated from CBCT imaging.
2. 3DP models fabricated using 3D-SPG were less accurate in comparison to the CPM and models fabricated using facial moulage and CBCT imaging techniques.
3. Models fabricated using CBCT imaging and facial moulage showed no statistical difference and proved to be accurate in comparison to the CPM.

ACKNOWLEDGMENTS

A special thanks to Mrs. Nancy Hansen, CDT, CCA, BS, and Mr. Alain Carballeyra, BS, for their support.

REFERENCES

- Merriam-Webster Dictionary. [Internet]. Merriam-Webster, Incorporated; 2013. Dismorphology; Accurate; Precision. [cited 2013 Feb 10]. Available from: <http://www.merriam-webster.com>.
- Eckert SE, Desjardins RP: Prosthetic considerations. In Brankmark PI (ed): *Osseointegration in Craniofacial Reconstruction*, Vol 1 (ed 1). Chicago, Quintessence, 1998, pp 87–88.
- Arridge SR, Moss JP, Linney AD, et al: Three-dimensional digitization of the face and skull. *J Maxillofac Surg* 1985;13:136–143.
- Posnick JC, Farkas LG: The application of anthropometric surface measurements in craniomaxillofacial surgery. In Farkas LG (ed): *Anthropometry of the Head and Face* (ed 1). New York, Raven Press, 1994; pp 125–138.
- Weinberg SM, Scott NM, Neiswanger K, et al: Digital three-dimensional photogrammetry: evaluation of anthropometric precision and accuracy using a Genex 3D camera system. *Cleft Palate Craniofac J* 2004;41:507–518.
- Davis BK: The role of technology in facial prosthetics. *Curr Opin Otolaryngol Head Neck Surg* 2010;18:332–340.
- Fourie Z, Damstra J, Gerrits PO, et al: Accuracy and repeatability of anthropometric facial measurements using cone beam computed tomography. *Cleft Palate Craniofac J* 2011;48:623–630.
- Souccar NM, Kau CH: Methods of measuring the three-dimensional face. *Sem Orthod* 2012;18:187–192.
- Wong JY, Oh AK, Ohta E, et al: Validity and reliability of 3D craniofacial anthropometric measurements. *Cleft Palate Craniofac J* 2008;45:232–239.
- Alexander C: Faces of war: amid the horrors of World War I, a corps of artists brought hope to soldiers disfigured in the trenches. *Smithsonian Magazine* 2007;37:72.
- Beumer J, Wolfaardt J, Lee M: *Maxillofacial Rehabilitation* (ed 3). Hanover Park, IL, Quintessence, 2011, pp. 282–3, 361–3, 391–394.
- Germec-Cakan D, Canter HI, Nur B, et al: Comparison of facial soft tissue measurements on three-dimensional images and models obtained with different methods. *J Craniofacial Surg* 2010;21:1393–1399.
- Scarfe WC, Farman AG, Sukovic P: Clinical applications of cone-beam computed tomography in dental practice. *J Can Dent Assoc* 2006;72:75–80.
- Kau CH, Olim S, Nguyen JT: The future of orthodontic diagnostic records. *Seminar in Orthodontics* 2011;17:39–45.
- DeVos W, Casselman J, Swennen GR: Cone-beam computerized tomography (CBCT) imaging of the oral and maxillofacial region: a systemic review of the literature. *Int J Oral Maxillofac Surg* 2009;38:609–625.
- Heike CL, Cunningham ML, Hing AV, et al: Picture perfect? Reliability of craniofacial anthropometry using three-dimensional digital stereophotogrammetry. *Plast Reconstr Surg* 2009;124:1261–1272.
- Plooji JM, Swennen GR, Rangel FA, et al: Evaluation of reproducibility and reliability of 3D soft tissue analysis using 3D stereophotogrammetry. *Int J Oral Maxillofac Surg* 2009;38:267–273.
- Sabol JV, Grant GT, Liacouras P, et al: Digital image capture and rapid prototyping of the maxillofacial defect. *J Prosthodont* 2011;20:310–314.
- Aldridge K, Boyadjiev SA, Capone GT, et al: Precision and error of three-dimensional phenotypic measures acquired from 3dMD photographic images. *Am J Med Genet A* 2005;138A:247–253.
- Wade AL, Dye JL, Mohrle CR, et al: Head, face, and, neck injuries during Operation Iraqi Freedom II: results from the US Navy-Marine Corps combat trauma registry. *J Trauma* 2007;63:836–840.
- Chan RK, Siller-Jackson A, Verrett AJ, et al: Ten years of war: a characterization of craniomaxillofacial injuries incurred during operations Enduring Freedom and Iraqi Freedom. *J Trauma* 2012;73:453–458.
- Cohen A, Laviv A, Berman P, et al: Mandibular reconstruction using stereolithographic 3-dimensional printing modeling technology. *Oral Surg Oral Med Oral Path Oral Rad Endo* 2009;105:661–666.
- Fruhwald J, Schicho K, Figl M, et al: Accuracy of craniofacial measurements: computed tomography and three-dimensional computed tomography compared with stereolithographic models. *J Cranio Surg* 2008;19:22–26.
- Taylor JS: Influence of computerized tomography parameters on the quality of stereolithographic models. Biomedical Science [thesis]. San Antonio (TX): University of Texas; 1999.
- Bouma L: The accuracy of non-contact three-dimensional laser surface scanning in the fabrication of facial moulage. Biomedical Science [thesis]. San Antonio (TX): University of Texas; 2003.
- Jacobson A: *Radiographic Cephalometry; Basics of Video-imaging*. Chicago, Quintessence, 1995.
- Williams PL, Warwick R, Dyson M, et al: *Gray's Anatomy* (ed 37). New York, Churchill Livingstone, 1989.
- Shen, C: Impression materials. In Anusavice KJ (ed): *Phillip's Science of Dental Materials* (edn 11). St. Louis, Saunders, 2003, pp 231–248.
- Clarke CD: *Prosthetics*. Butler, MD, Standard Arts Press, 1965, Ch 3.
- Khambay B, Naim N, Bell A, et al: Validation and reproducibility of a high resolution three-dimensional facial imaging system. *Br J Oral Maxillofac Surg* 2008;40:27–32.
- Weinberg SM, Naidoo S, Govier DP, et al: Anthropometric precision and accuracy of digital three-dimensional photogrammetry: comparing the genex and 3dMD imaging systems with one another and with direct anthropometry. *J Craniofac Surg* 2006;17:477–483.
- Holberg C, Schwenzer K, Mahaini L, et al: Accuracy of facial plaster casts. *Angle Orthod* 2006;76:605–611.
- Damstra J, Fourie Z, Huddleston Slater JJR, et al: Accuracy of linear measurements from cone beam computed tomography derived surface models of different voxel sizes. *Am J Orthod Dentofacial Orthop* 2010;137:16.e1–16.e6.

34. Stratemann SA, Huang JC, Maki K, et al: Comparison of cone beam computed tomography imaging with physical measures. *Dentomaxillofac Radiol* 2008;37:80–93.
35. Mischkowski R, Reinhard P, Lutz R, et al: Geometric accuracy of a newly developed cone beam device for maxillofacial imaging. *Oral Surg Oral Med Oral Path Oral Rad Endo* 2007;104:551–559.
36. Ghoddousi H, Edler R, Haers P, et al: Comparison of three methods of facial measurement. *Int J Oral Maxillofac Surg* 2007;36:250–258.
37. Lubbers HT, Medinger L, Kruse A, et al: Precision and accuracy of the 3dMD photogrammetric system in craniomaxillofacial application. *J Craniofac Surg* 2010;21:763–767.
38. Jamali AA, Deuel C, Perreira A, et al: Linear and angular measurements of computer generated models: are they accurate, valid, and reliable? *Comput Aided Surg* 2007;12:278–285.
39. Taft RM, Kondor S, Grant GT: Accuracy of Rapid Prototype models for head and neck reconstruction. *J Prosthet Dent* 2011;106:399–408.
40. Esses SJ, Berman P, Bloom A, et al: Clinical applications of physical 3D models derived from MDCT data and created by rapid prototyping. *AJR Am J Roentgenol* 2011;196:683–688.
41. Karayazgan-Saracoglu B, Gunay Y, Atay A: Fabrication of an auricular prosthesis using computed tomography and rapid prototyping technique. *J Craniofac Surg* 2009;20:1169–1172.
42. Turgut G, Sacak, KK, et al: Use of rapid prototyping in prosthetic auricular restoration. *J Craniofac Surg* 2009;20:321–325.
43. Marafon PG, Mattos BS, Saboia AC, et al: Dimensional accuracy of computer-aided design/computer-assisted manufactured orbital prostheses. *Int J Prosthodont* 2010;23:271–276.
44. Maal TJ, Plooji JM, Rangel FA, et al: The accuracy of matching three-dimensional photographs with skin surfaces derived from cone-beam computed tomography. *Int J Oral Maxillofac Surg* 2008;37:641–646.