

1

Aggressive Periodontitis

1.1 Definition

Aggressive periodontitis can be defined based on the following primary and secondary features (Lang *et al.*, 1999).

1.1.1 Primary Features

- Non-contributory medical history; diagnosis requires the exclusion of systemic diseases.
- Rapid attachment loss and bone destruction.
- Familial aggregation of cases.

1.1.2 Secondary Features

- Amount of plaque is inconsistent with the severity of the disease.
- Elevated levels of *Actinobacillus actinomycetemcomitans* (AA) and *Porphyromonas gingivalis* (PG) in some population.
- Phagocyte abnormalities.
- Hyper-responsive macrophage phenotype, elevated prostaglandin (PG)-E₂, interleukin (IL)-1 beta in response to bacterial endotoxins.
- Progression of attachment and bone loss may be self-arresting.

1.2 Classification

Based on the 1999 International Workshop for Classification of Periodontal Diseases and Conditions, aggressive periodontitis can be classified into two main categories (Armitage, 1999): localised aggressive periodontitis (LAP) and generalised aggressive periodontitis (GAP).

Localised aggressive periodontitis is characterised by the following features.

- Circumpubertal onset.
- Localised first molar/incisor presentation with interproximal attachment loss on at least two permanent teeth, one of which is a first molar and involving no more than two teeth other than the first molars and incisors.
- Robust serum antibody response to infecting agents.

Generalised aggressive periodontitis is characterised by the following features.

- Usually affecting a person under 35 years of age but patients may be older.
- Generalised interproximal attachment loss affecting at least three permanent teeth other than the first molars and incisors.
- Pronounced episodic nature of the destruction.
- Poor serum antibody response to infecting agents.

There can be high heterogeneity in the clinical presentation of aggressive periodontitis. Some LAP cases may initially affect the primary dentition.

1.3 Prevalence

There is a wide variation in the prevalence of aggressive periodontitis between populations and differences in race/ethnicities can be a key factor (Susin *et al.*, 2014). Most studies show comparable disease prevalence in male and female subjects.

Aggressive periodontitis is most prevalent in Africa and in populations of African descent (around 1%), compared to Caucasians where the prevalence of LAP is 0.1%.

1.4 Aetiology and Pathogenesis

Aggressive periodontitis is a multifactorial disease. It shares most of the risk factors associated with chronic periodontitis, as discussed in Chapter 6. However, the

following parameters play key roles in the onset and progression of the aggressive disease.

1.4.1 Bacteria

Actinobacillus actinomycetemcomitans (mainly serotype b) has been isolated from periodontal lesions in 90% of LAP patients. It can invade the soft tissue and produces virulence factors including leucotoxins, endotoxin (LPS), bacteriocin, immunosuppressive factors and collagenase, and causes chemotactic inhibition (Kononen and Muller, 2014).

Elevated serum antibodies against AA can be detected in LAP patients and there is a correlation between treatment outcomes and levels of AA after therapy.

On the other hand, GAP is associated with PG, *Bacteroides forsythus* and AA.

1.4.2 Genetic Susceptibility

Available data suggest that aggressive periodontitis is caused by mutations in multiple genes, combined with environmental effects (Vieira and Albandar, 2014). A hereditary pattern for susceptibility to aggressive periodontitis has been reported and the most likely mode of inheritance is autosomal dominant. The percentage of the affected siblings can be 40–50%.

Disease-modifying genes that have been studied in relation to periodontitis include:

- IL-1, IL-10 and tumour necrosis factor (TNF)-alpha gene polymorphism
- Fc gamma receptor gene polymorphism
- gene polymorphism in the innate immunity receptors
- vitamin D receptor gene polymorphism.

1.4.3 Smoking

Smoking is a major risk factor for periodontal disease and it further adds to the susceptibility for severe aggressive disease. Patients with aggressive periodontitis who are smokers show poorer response to treatment compared to non-smokers (Hughes *et al.*, 2006) (see also Chapter 6).

1.5 Screening

The most sensitive screening method for aggressive periodontitis in adults is the measurement of pocket depth by probing (attachment loss measurement).

In children with primary and mixed dentition, probing may not be a reliable method due to partial eruption of teeth and the presence of pseudo-pockets. Therefore, measurement of distance between the alveolar bone

crest and the cemento-enamel junction (CEJ) using bitewing (BW) radiographs can be an appropriate screening method in children. The median distance between the alveolar bone crest and the CEJ in 7–9-year-old children is 0.8–1.4 mm in primary molars and the normal range is less than 2 mm.

1.6 Diagnosis

Aggressive periodontitis can be differentiated from chronic periodontitis based on the primary and secondary features as described above, including the criteria for the classification of localised and generalised disease (Albandar, 2014).

The diagnosis of aggressive periodontitis can be confirmed by different approaches as listed below.

- *History, clinical, and radiographic examination* (see Chapter 6).
- *Microbiological testing*: bacterial testing alone cannot distinguish between chronic and aggressive periodontitis but it can provide useful information that can improve the outcome of periodontal therapy. It can help with the choice of antibiotics so it is best to postpone microbiological testing until after the initial treatment phase. It can also help to identify the presence of transmissible AA or PG in family members so that disease can be potentially prevented by early intervention.
- *Serological testing*: serum antibody levels against AA may be useful for differential diagnosis of GAP and LAP and in the early detection of LAP cases with high risk for progression.
- *Genetic diagnosis*: pedigree plotting can be essential for the diagnosis of aggressive periodontitis due to its familial aggregation.

1.7 Prognosis

General patient-level, site-level and tooth-level prognostic factors for periodontal disease are discussed in Chapter 6.

The prognosis for aggressive periodontitis specifically depends on early diagnosis, the extent and severity of the disease, directing treatment towards elimination of infecting pathogens and long-term maintenance.

1.8 Treatment

Non-surgical and even surgical periodontal treatments alone are not sufficient for the elimination of AA in LAP and in some chronic periodontitis patients. Therefore,

oral hygiene instructions (OHI) and root surface debridement (RSD) supplemented with systemic antibiotics are recommended for the treatment of aggressive periodontitis patients.

1.8.1 Systemic Antibiotics

Systematic reviews show significantly larger adjunctive benefits of systemic antibiotics and greater clinical improvements and reduction in periodontal indices following systemic antibiotic administration upon completion of subgingival instrumentation in aggressive periodontitis cases compared to patients with chronic periodontitis (Haffajee *et al.*, 2003; Keestra *et al.*, 2015a; Rabelo *et al.*, 2015; Rajendra and Spivakovsky, 2016).

According to the American Academy of Periodontology and the British Society for Periodontology guidelines, patients who are likely to benefit from adjunctive systemic antibiotics are those diagnosed with aggressive periodontitis, those suffering from acute periodontal infections such as necrotising periodontal disease and periodontal abscesses with systemic involvement, certain medically compromised patients, and those for whom conventional mechanical treatment has proven ineffective (BSP, 2016).

Systemic antibiotics are not routinely prescribed for the treatment of chronic periodontitis due to the risk of resistance which is enhanced by the biofilm's protective nature and the risk of unwanted systemic side effects such as hypersensitivity, nausea, vomiting, gastrointestinal (GI) intolerance, and pseudomembranous colitis.

Different types and combinations of systemic antibiotics have been used for the treatment of periodontal disease (Herrera *et al.*, 2002, 2008; Keestra *et al.*, 2015b; Moreno Villagrana and Gomez Clavel, 2012; Renatus *et al.*, 2016; Santos *et al.*, 2016). Some examples of the most commonly prescribed regimens include:

- amoxicillin 500 mg, three times per day + metronidazole 500 mg, three times per day for 7 days
- metronidazole 500 mg, three times per day + ciprofloxacin 500 mg twice a day for 7 days
- clindamycin 300 mg, four times per day for 7 days
- doxycycline 200 mg, once a day for 7–14 days
- azithromycin 500 mg, once a day for 3 days.

It has been shown that metronidazole on its own does not eradicate AA but combination therapy with metronidazole and amoxicillin can be effective against AA.

There is a growing body of evidence that azithromycin used as an adjunct to RSD significantly improves the efficacy of non-surgical periodontal therapy in reducing probing pocket depth and other periodontal indices, particularly at the initially deep probing depth sites (Buset *et al.*, 2015; Renatus *et al.*, 2016; Zhang *et al.*,

2016). Azithromycin is an effective, safe and well-tolerated drug and has the advantage of a relatively short duration of therapy and therefore improved patient compliance and reduced potential side effects.

1.8.2 Local Antimicrobials

Local delivery of antibiotics can be beneficial in the control of localised ongoing periodontal disease in otherwise stable patients. It can also be useful in the management of non-responding sites following initial treatment.

The advantages of local antimicrobials include their ease of use, independence of patient co-operation, high dose at treated sites and reduced systemic adverse effects. The disadvantages include narrow distribution to other sites that may reinfect, potential washout, dilution within minutes and rapid clearance. Furthermore, local therapy may be less successful in patients with widespread lesions than those with localised lesions. It has been shown that local healing with locally delivered antibiotics is affected if the other diseased sites are left untreated (Mombelli *et al.*, 1997).

Local antimicrobial products most commonly used in the treatment of periodontal disease with the relevant studies on their efficacy are listed below.

- Minocycline ointment (Dentomycin) and microspheres (Arestin) (Williams *et al.*, 2001)
- Doxycycline hyclate in a biodegradable polymer (Atridox two-syringe system) (Wennstrom *et al.*, 2001)
- Metronidazole gel (Elyzol Dental Gel 25%) (Ainamo *et al.*, 1992)
- Tetracycline in a non-resorbable plastic co-polymer (Actisite periodontal fibre 25%) (Michalowicz *et al.*, 1995)
- Chlorhexidine in a gelatin chip (PerioChip) (Jeffcoat *et al.*, 1998)

A meta-analysis of 19 clinical trials indicated significant adjunctive pocket depth reduction for locally delivered minocycline gel, microencapsulated minocycline, chlorhexidine chip and doxycycline gel during non-surgical periodontal treatment compared to RSD alone (Hanes and Purvis, 2003).

In another systematic review, subgingival application of tetracycline fibres, sustained-release doxycycline and minocycline demonstrated a significant benefit in probing pocket depth reduction. The local application of chlorhexidine and metronidazole showed a minimal effect when compared with placebo (Matesanz-Perez *et al.*, 2013).

Locally delivered antibiotics, although extensively demonstrated to have clinical efficacy and microbiological benefits, are still debated regarding their

cost-effectiveness and adequate indications (Herrera *et al.*, 2012; Kalsi *et al.*, 2011).

Finally, it is important to emphasise that mechanical debridement before the application of antimicrobial agents and mechanical plaque control after therapy are essential for treatment success. To limit the development

of microbial antibiotic resistance in general, and to avoid the risk of unwanted systemic effects of antibiotics for the treated individual, a precautionary, restrictive attitude towards using antibiotics is recommended (Lang and Lindhe, 2015).

Case Study

A 34-year-old female patient was referred by the general dental practitioner for the management of periodontal

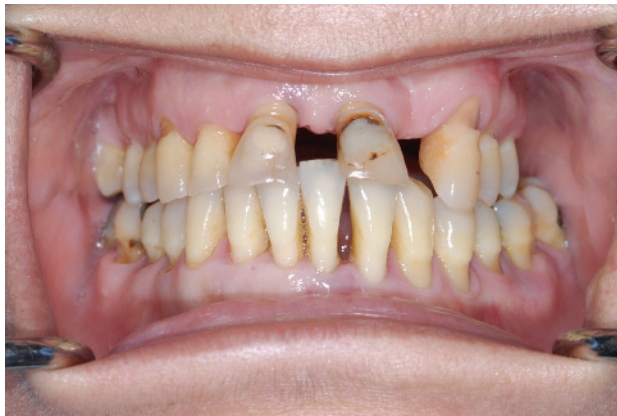

Figure 1.1 Preoperative clinical photograph.

disease and residual deep pockets despite repeated cycles of non-surgical periodontal treatment in the practice. The patient presented with painful gums, drifted upper front teeth, recurrent infections and loss of several teeth. She was a non-smoker, medically fit and well and reported a positive familial history of periodontal disease.

The patient's preoperative clinical photograph and radiographs are shown in Figures 1.1 and 1.2 respectively. Table 1.1 shows full periodontal charting at the baseline prior to any specialist treatment.

Diagnoses

- Generalised aggressive periodontitis
- Secondary occlusal trauma to the incisor teeth
- Caries
- Chronic apical periodontitis UL1, UL3, LR5, LL1
- Missing teeth
- Cervical abrasion lesions

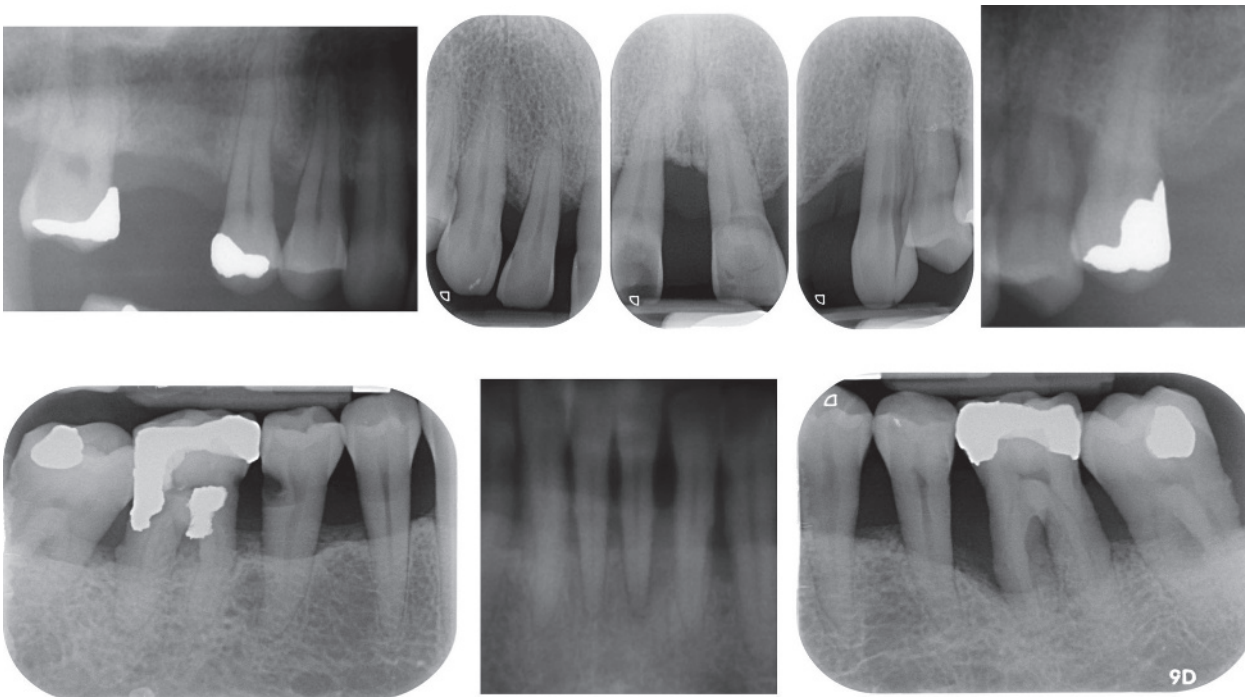


Figure 1.2 Preoperative full-mouth periapical radiographs showing the extent and severity of periodontal bone loss and presence of multiple periapical radiolucencies.

Table 1.1 Preoperative full periodontal charting.

Mobility	X		X					II	II	X	I	II	I	X	X	X
Recession	X		X		1	2		2	2	X	3	1		X	X	X
PPD (Buccal)	X	733	X	216	524	327	323	424	422	X	515	726	634	X	X	X
Upper teeth	8	7	6	5	4	3	2	1	1	2	3	4	5	6	7	8
PPD (Palatal)	X	533	X	236	535	336	433	345	522	X	656	656	543	X	X	X
Recession	X		X		1	1		2	2	X	1	1		X	X	X
Furcation	X		X							X				X	X	X

Mobility	X		I				I	I	III	I		I	II	I	I	X
Recession	X	1	1	1	2	1	2	4	5	3	2	2	1	2	1	X
PPD (Lingual)	X	455	335	534	524	355	333	233	326	423	554	636	535	943	576	X
Lower teeth	8	7	6	5	4	3	2	1	1	2	3	4	5	6	7	8
PPD (Buccal)	X	425	624	524	524	526	623	523	336	326	525	523	528	857	656	X
Recession	X	2	3	3	3	2	3	4	4	3	3	3	3	3	3	X
Furcation	X	I	II											III	I	X

Prognosis

The prognosis for LR6 and LL1 was hopeless. LR6 was non-vital as tested by the electric pulp tester and had large restoration with subgingival secondary caries and was non-restorable. This tooth also had advanced periodontal bone loss with furcation involvement.

LL1 had advanced periodontal bone loss and periapical radiolucency and was grade III mobile. The prognosis for the remaining teeth was questionable and would also depend on the patient's compliance

Treatment Strategy

- Initial non-surgical periodontal treatment supplemented with systemic antibiotics
- Extraction of non-restorable teeth with hopeless prognosis
- Restoration of caries
- Root canal treatment of teeth with apical periodontitis
- Surgical periodontal treatment in the lower left sextant
- Direct and indirect restoration of compromised teeth and replacement of missing teeth with fixed bridges
- Periodontal maintenance

Clinical Procedures Undertaken

- 1) Full periodontal assessment and recording indices.
- 2) Oral hygiene instructions including modified Bass and interdental brushing.

- 3) Full-mouth RSD under local anaesthesia (LA) in combination with systemic azithromycin 500 mg once a day for 3 days.
- 4) Extraction of LR6 and LL1.
- 5) Splinting of the extracted LL1 crown to LR1 using composite fibre splint.
- 6) Restoration of caries LR5, UR1, UL1 and cervical abrasion lesion UL3.
- 7) Root canal treatment (RCT) of UL1, UR1, UL3, LR5.
- 8) Periodontal reassessment. Significant improvement and reduction in the probing pocket depth was recorded. Deep residual pockets remained in the LL6 region.
- 9) Surgical periodontal treatment in the lower left sextant and tunnel preparation in the LL6 furcation area to facilitate cleaning of the furcation with an interdental brush.
- 10) Impressions and diagnostic wax-up of the upper anterior teeth to ideal crown position, shape and occlusion (Figure 1.3).
- 11) Preparation and fitting of porcelain fused to metal (PFM) crowns on UR1 and UR2 and a three-unit PFM bridge for UL1–UL3 to replace the missing UL2.
- 12) Three-monthly periodontal reassessment and supportive periodontal treatment.

Postoperative periodontal charting is shown in Table 1.2 and the postoperative clinical photograph and radiographs

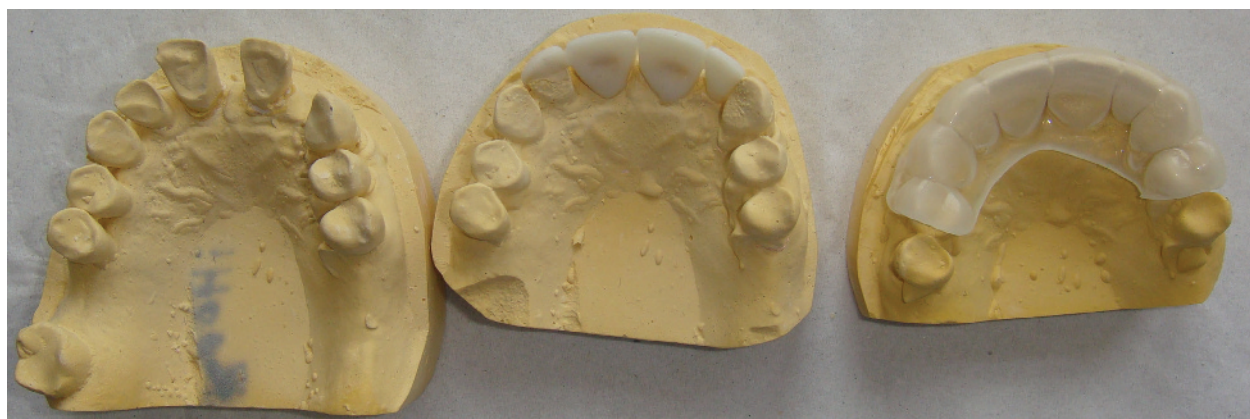

Figure 1.3 Diagnostic wax-up of the upper anterior teeth and fabrication of a clear stent to facilitate construction of provisional restorations.

of the root-treated teeth are demonstrated in Figures 1.4 and 1.5 respectively.

Discussion and Learning Points

The diagnosis of aggressive periodontitis was made for this case because of rapid disease progression in a relatively young patient, non-contributory medical history and positive familial history of periodontitis. Also, there was little plaque and calculus which was not commensurate with the severity of the disease.

The patient responded well to the RSD under LA supplemented with systemic azithromycin. She had shown a poorer response to repeated RSD alone in the dental practice previously. This shows the additional beneficial role of

adjunctive systemic antibiotics in the treatment of aggressive periodontitis.

Extraction of LL1 with hopeless prognosis and splinting the extracted tooth to the adjacent tooth with composite fibre splint was a successful attempt to eliminate the infection, alleviate the patient’s discomfort and restore function using the patient’s own extracted tooth. Optimised bonding technique with appropriate moisture control and careful occlusal adjustment of the pontic tooth were the key factors in achieving a satisfactory outcome.

LR6 was also extracted as this tooth was not restorable. However, the patient did not want to replace this tooth and was satisfied with maintaining a shortened dental arch.

Table 1.2 Postoperative full periodontal charting.

Mobility	X		X		I		I	I	I	X		I	I	X	X	X
Recession	X	4	X	4	3	4				X	1	4	2	X	X	X
PPD (Buccal)	X	323	X	223	323	223	323	223	323	X	223	223	333	X	X	X
Upper teeth	8	7	6	5	4	3	2	1	1	2	3	4	5	6	7	8
PPD (Palatal)	X	323	X	223	333	223	333	222	222	X	333	323	332	X	X	X
Recession	X	4	X	3	2	3	1	1	1	X	1	3	1	X	X	X
Furcation	X		X							X				X	X	X

Mobility	X		X	I			I	I	X	I		I	II	II	II	X
Recession	X	4	X	5	3	2	3	4	X	4	4	3	3	5	4	X
PPD (Lingual)	X	333	X	323	322	222	222	222	X	221	212	323	333	333	233	X
Lower teeth	8	7	6	5	4	3	2	1	1	2	3	4	5	6	7	8
PPD (Buccal)	X	333	X	323	323	323	212	222	X	322	222	323	333	323	333	X
Recession	X	5	X	6	4	3	4	5	X	5	5	5	5	6	5	X
Furcation	X	I	X						X					III	I	X

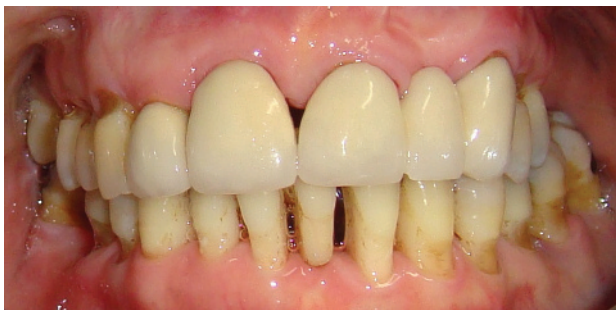

Figure 1.4 Postoperative clinical photograph.

Surgical periodontal treatment in the lower left sextant resulted in the elimination of the isolated residual deep periodontal pockets associated with LL6 which had grade III furcation involvement, and a tunnel preparation technique facilitated access for cleaning of the furcation area using an interdental brush. Management of teeth with furcation involvement is discussed in detail in Chapter 6.

The options regarding the drifted upper anterior teeth with spacing and poor aesthetics included: (a) keeping the teeth as they were with maintenance only; (b) extraction of the teeth and replacement by removable partial dentures or implant-retained prosthesis; and (c) RCT of non-vital teeth and UR1 and modification of the teeth using crowns and replacement of the spaces using fixed bridges. As the patient responded well to periodontal treatment and was well motivated to maintain her teeth, it was decided to restore the anterior teeth with crowns and bridges following root canal treatment. The use of a diagnostic wax-up (see Figure 1.3) to correct the position and alignment of the drifted teeth and recreate the ideal tooth shape, size and ratios was a very helpful approach.

The patient was very satisfied with the outcome of the treatment in terms of aesthetics, function and the resolution of symptoms associated with periodontal disease. Supportive periodontal therapy was extremely important in long-term maintenance of the patient's periodontal health.

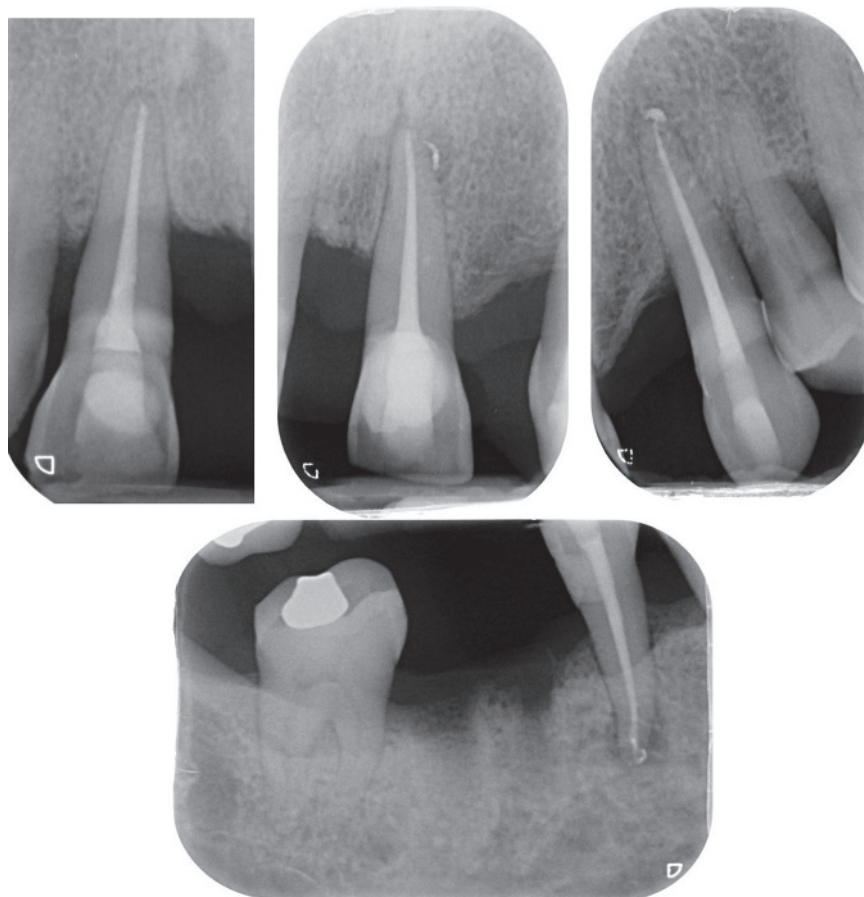


Figure 1.5 Postoperative periapical radiographs of the teeth following root canal treatment showing evidence of periapical healing.

References

- Ainamo, J., Lie, T., Ellingsen, B.H. *et al.* (1992) Clinical responses to subgingival application of a metronidazole 25% gel compared to the effect of subgingival scaling in adult periodontitis. *J Clin Periodontol*, **19**, 723–729.
- Albandar, J.M. (2014) Aggressive periodontitis: case definition and diagnostic criteria. *Periodontology 2000*, **65**, 13–26.
- Armitage, G.C. (1999) Development of a classification system for periodontal diseases and conditions. *Ann Periodontol*, **4**, 1–6.
- BSP (2016) *The Good Practitioner's Guide To Periodontology*, British Society of Periodontology, Selby.
- Buset, S.L., Zitzmann, N.U., Weiger, R. and Walter, C. (2015) Non-surgical periodontal therapy supplemented with systemically administered azithromycin: a systematic review of RCTs. *Clin Oral Invest*, **19**, 1763–1775.
- Haffajee, A.D., Socransky, S.S. and Gunsolley, J.C. (2003) Systemic anti-infective periodontal therapy. a systematic review. *Ann Periodontol*, **8**, 115–181.
- Hanes, P.J. and Purvis, J.P. (2003) Local anti-infective therapy: pharmacological agents. A systematic review. *Ann Periodontol*, **8**, 79–98.
- Herrera, D., Sanz, M., Jepsen, S., Needleman, I. and Roldan, S. (2002) A systematic review on the effect of systemic antimicrobials as an adjunct to scaling and root planing in periodontitis patients. *J Clin Periodontol*, **29**(suppl 3), 136–159; discussion 160–162.
- Herrera, D., Alonso, B., Leon, R., Roldan, S. and Sanz, M. (2008) Antimicrobial therapy in periodontitis: the use of systemic antimicrobials against the subgingival biofilm. *J Clin Periodontol*, **35**, 45–66.
- Herrera, D., Matesanz, P., Bascones-Martinez, A. and Sanz, M. (2012) Local and systemic antimicrobial therapy in periodontics. *J Evid Based Dent Pract*, **12**, 50–60.
- Hughes, F.J., Syed, M., Koshy, B. *et al.* (2006) Prognostic factors in the treatment of generalized aggressive periodontitis: II. Effects of smoking on initial outcome. *J Clin Periodontol*, **33**, 671–676.
- Jeffcoat, M.K., Bray, K.S., Ciancio, S.G. *et al.* (1998) Adjunctive use of a subgingival controlled-release chlorhexidine chip reduces probing depth and improves attachment level compared with scaling and root planing alone. *J Periodontol*, **69**, 989–997.
- Kalsi, R., Vandana, K.L. and Prakash, S. (2011) Effect of local drug delivery in chronic periodontitis patients: a meta-analysis. *J Indian Soc Periodontol*, **15**, 304–309.
- Keestra, J.A., Grosjean, I., Coucke, W., Quirynen, M. and Teughels, W. (2015a) Non-surgical periodontal therapy with systemic antibiotics in patients with untreated aggressive periodontitis: a systematic review and meta-analysis. *J Periodontol Res*, **50**, 689–706.
- Keestra, J.A., Grosjean, I., Coucke, W., Quirynen, M. and Teughels, W. (2015b) Non-surgical periodontal therapy with systemic antibiotics in patients with untreated chronic periodontitis: a systematic review and meta-analysis. *J Periodontol Res*, **50**, 294–314.
- Kononen, E. and Muller, H.P. (2014) Microbiology of aggressive periodontitis. *Periodontology 2000*, **65**, 46–78.
- Lang, N.P. and Lindhe, J. (2015) *Clinical Periodontology and Implant Dentistry*, Wiley-Blackwell, Oxford.
- Lang, N., Bartold, P.M., Cullinan, M. *et al.* (1999) Consensus report: aggressive periodontitis. *Ann Periodontol*, **4**, 53.
- Matesanz-Perez, P., Garcia-Gargallo, M., Figuero, E., Bascones-Martinez, A., Sanz, M. and Herrera, D. (2013) A systematic review on the effects of local antimicrobials as adjuncts to subgingival debridement, compared with subgingival debridement alone, in the treatment of chronic periodontitis. *J Clin Periodontol*, **40**, 227–241.
- Michalowicz, B.S., Pihlstrom, B.L., Drisko, C.L. *et al.* (1995) Evaluation of periodontal treatments using controlled-release tetracycline fibers: maintenance response. *J Periodontol*, **66**, 708–715.
- Mombelli, A., Lehmann, B., Tonetti, M. and Lang, N.P. (1997) Clinical response to local delivery of tetracycline in relation to overall and local periodontal conditions. *J Clin Periodontol*, **24**, 470–477.
- Moreno Villagrana, A.P. and Gomez Clavel, J.F. (2012) Antimicrobial or subantimicrobial antibiotic therapy as an adjunct to the nonsurgical periodontal treatment: a meta-analysis. *ISRN Dent*, **2012**, 581207.
- Rabelo, C.C., Feres, M., Goncalves, C. *et al.* (2015) Systemic antibiotics in the treatment of aggressive periodontitis. A systematic review and a Bayesian network meta-analysis. *J Clin Periodontol*, **42**, 647–657.
- Rajendra, A. and Spivakovsky, S. (2016) Antibiotics in aggressive periodontitis. Is there a clinical benefit? *Evid Based Dent*, **17**, 100.
- Renatus, A., Herrmann, J., Schonfelder, A., Schwarzenberger, F. and Jentsch, H. (2016) Clinical efficacy of azithromycin as an adjunctive therapy to non-surgical periodontal treatment of periodontitis: a systematic review and meta-analysis. *J Clin Diagn Res*, **10**, Ze01–7.
- Santos, R.S., Macedo, R.F., Souza, E.A., Soares, R.S., Feitosa, D.S. and Sarmiento, C.F. (2016) The use of systemic antibiotics in the treatment of refractory periodontitis: a systematic review. *J Am Dent Assoc*, **147**, 577–585.

- Susin, C., Haas, A.N. and Albandar, J.M. (2014) Epidemiology and demographics of aggressive periodontitis. *Periodontology* 2000, **65**, 27–45.
- Vieira, A.R. and Albandar, J.M. (2014) Role of genetic factors in the pathogenesis of aggressive periodontitis. *Periodontology* 2000, **65**, 92–106.
- Wennstrom, J.L., Newman, H.N., Macneill, S.R. *et al.* (2001) Utilisation of locally delivered doxycycline in non-surgical treatment of chronic periodontitis. A comparative multi-centre trial of 2 treatment approaches. *J Clin Periodontol*, **28**, 753–761.
- Williams, R.C., Paquette, D.W., Offenbacher, S. *et al.* (2001) Treatment of periodontitis by local administration of minocycline microspheres: a controlled trial. *J Periodontol*, **72**, 1535–1544.
- Zhang, Z., Zheng, Y. and Bian, X. (2016) Clinical effect of azithromycin as an adjunct to non-surgical treatment of chronic periodontitis: a meta-analysis of randomized controlled clinical trials. *J Periodontal Res*, **51**, 275–283.

