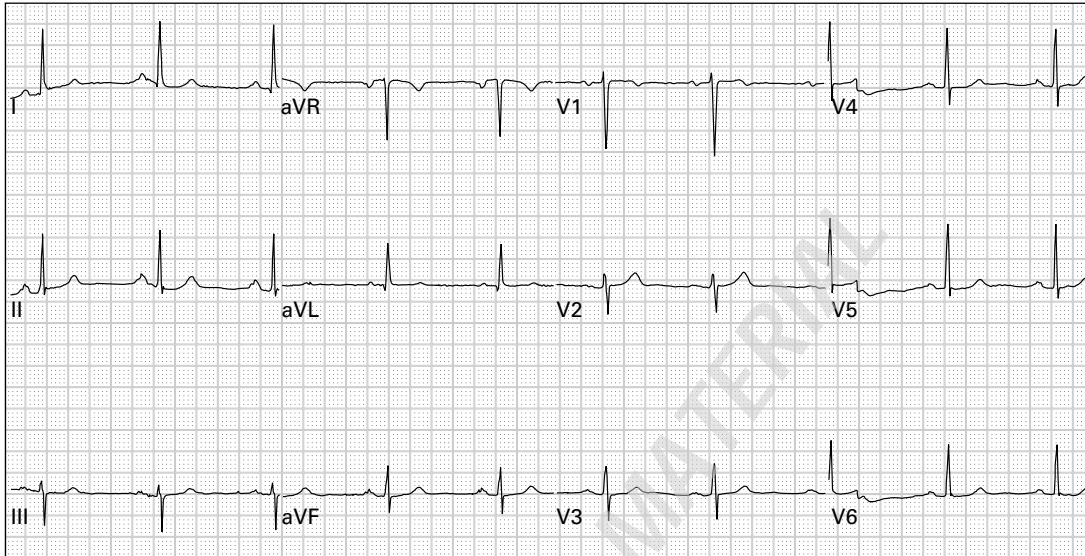
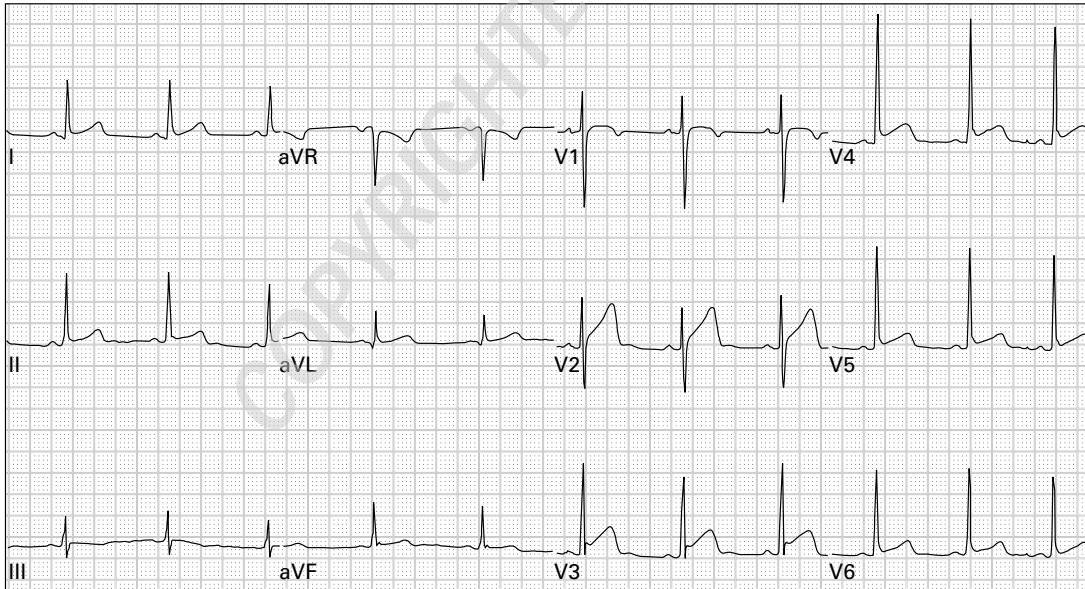


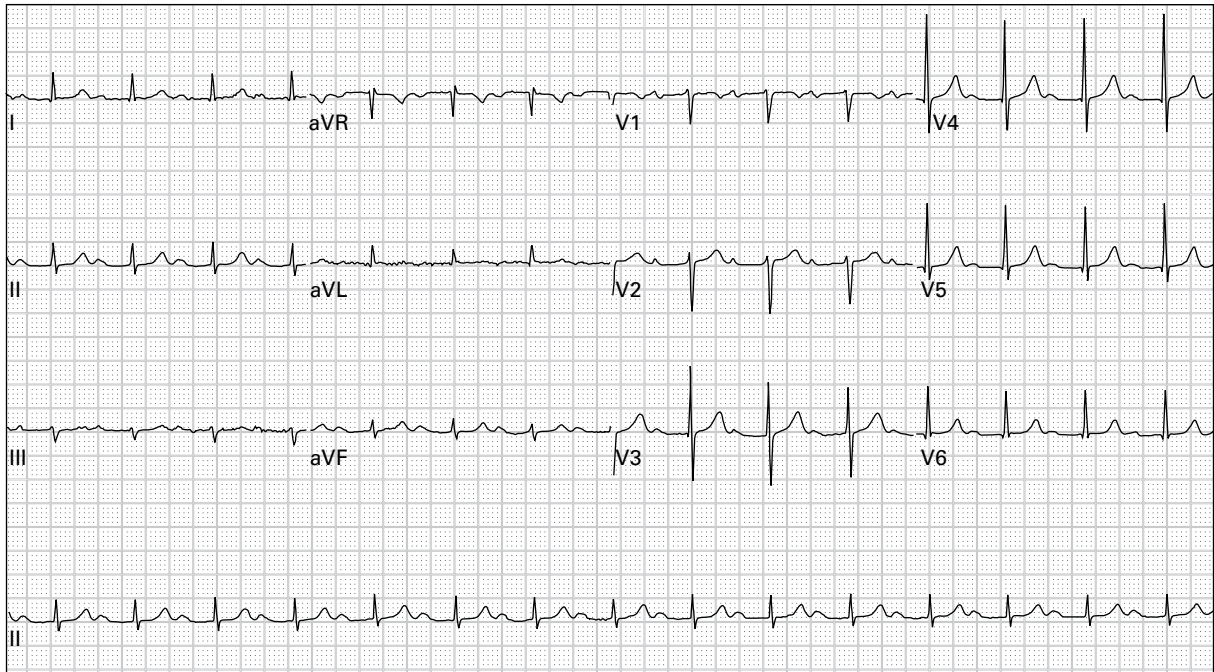
Case histories



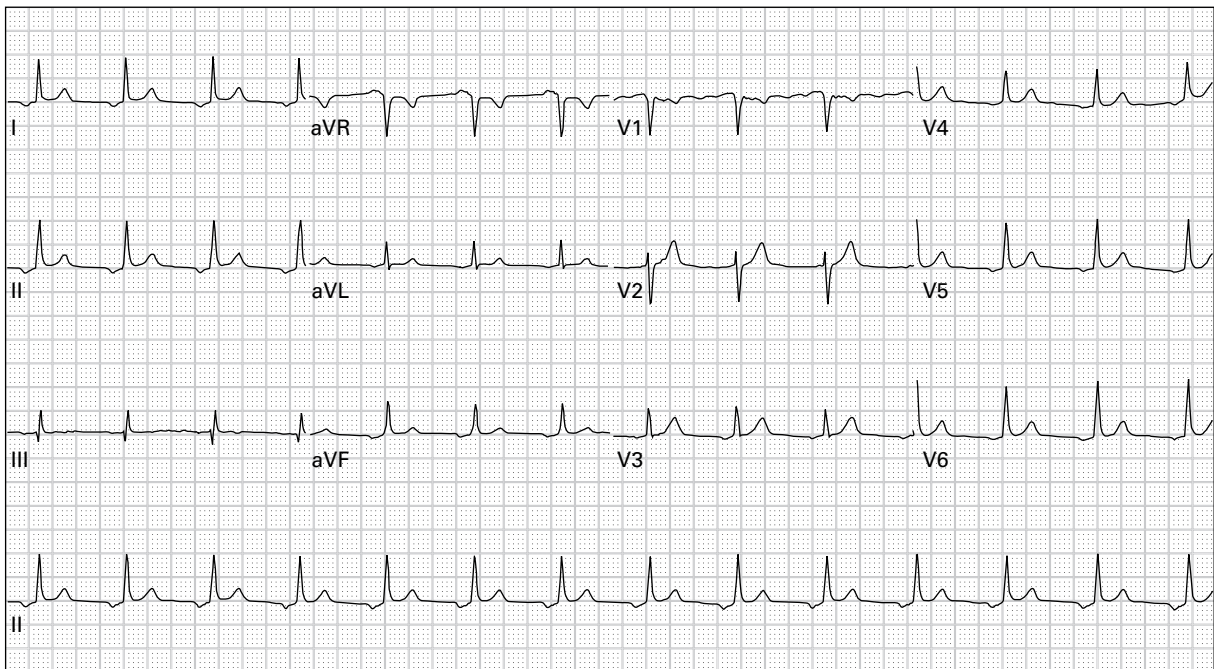
1. 45 year old woman, asymptomatic



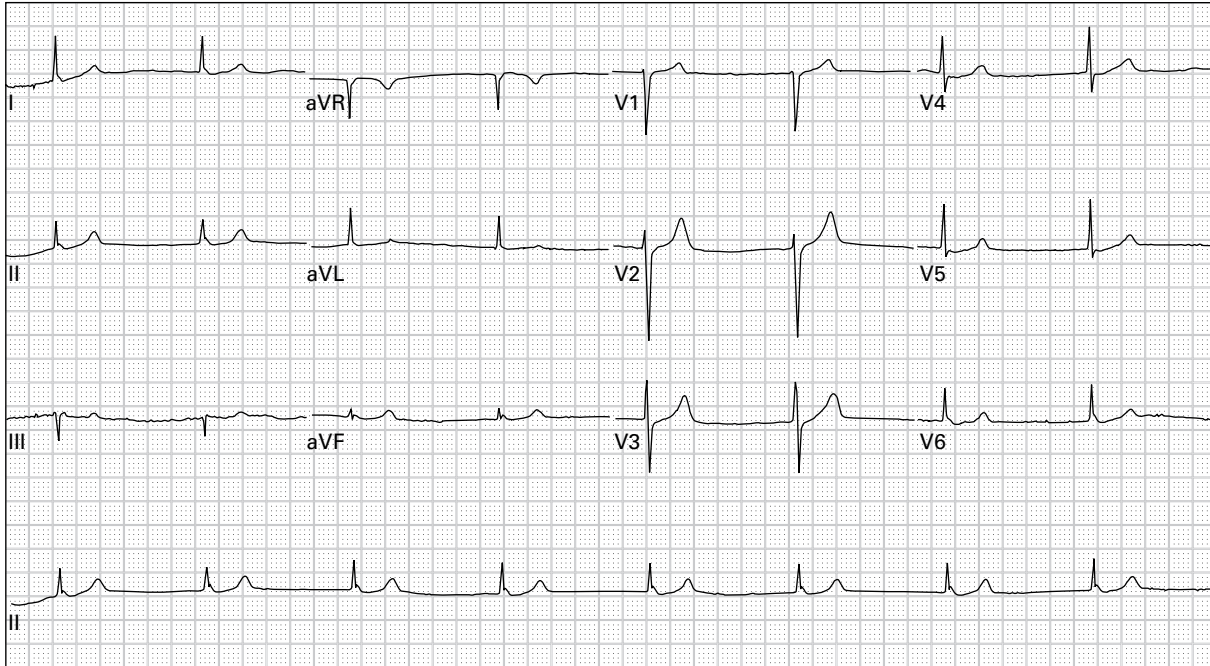
2. 24 year old man with chest ache after lifting weights



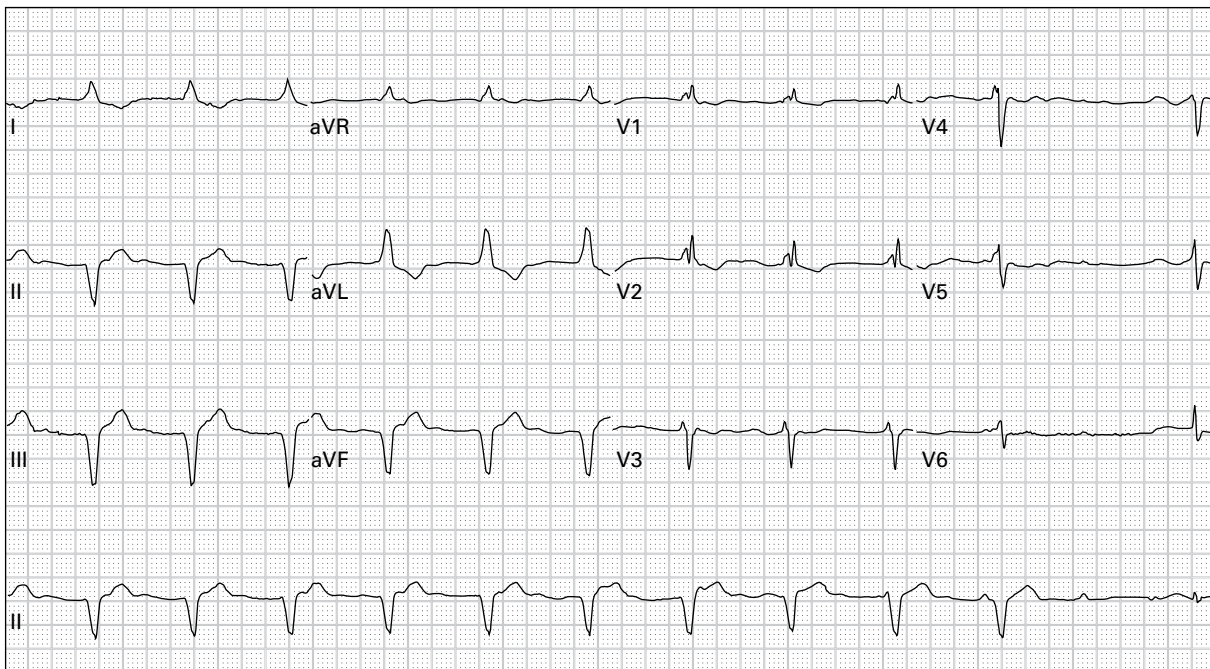
3. 76 year old man with dyspnea



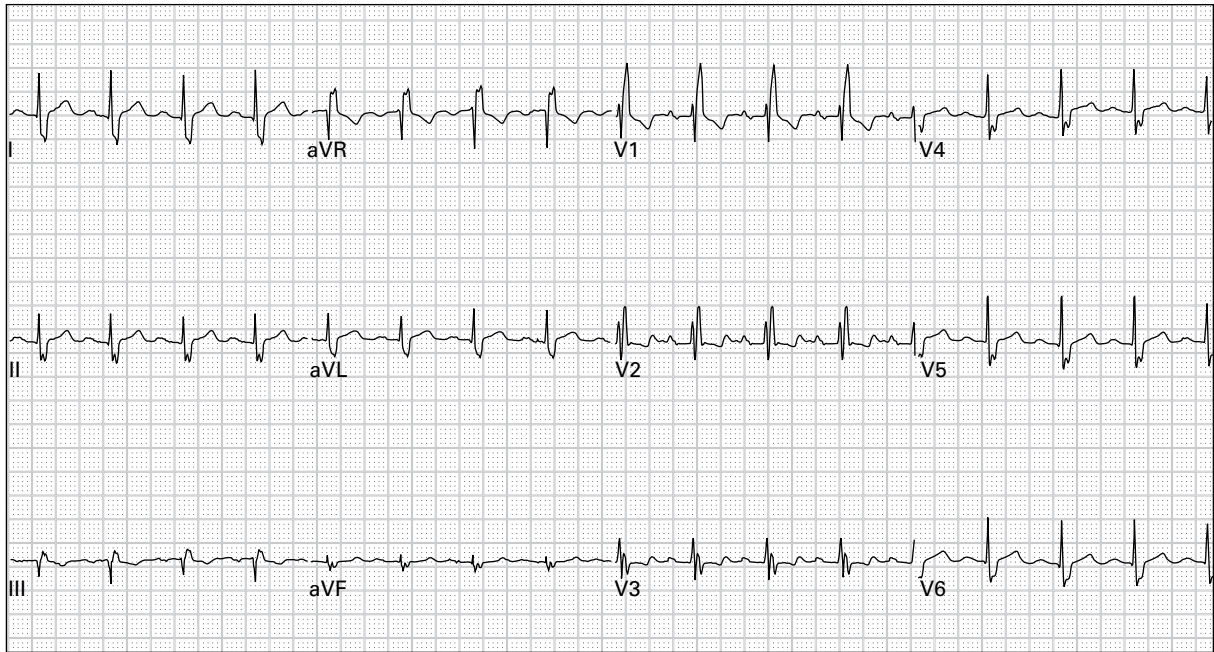
4. 64 year old man, asymptomatic



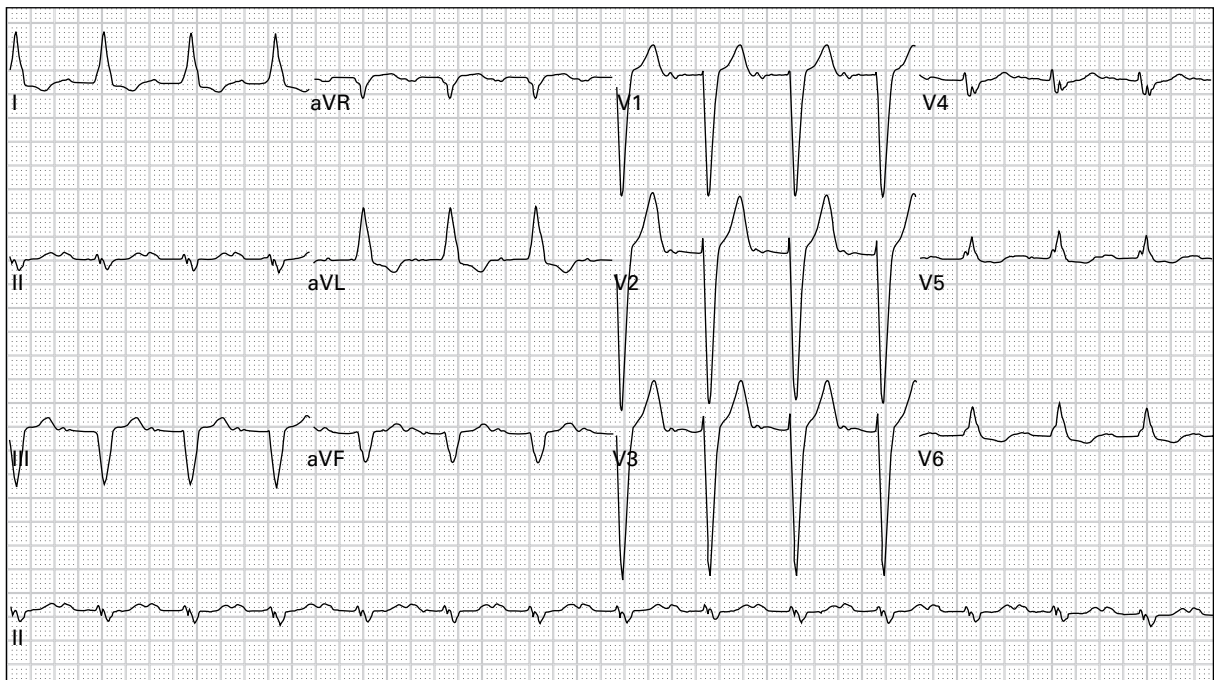
5. 48 year old woman reports severe lightheadedness with walking; she recently started a new medication for hypertension



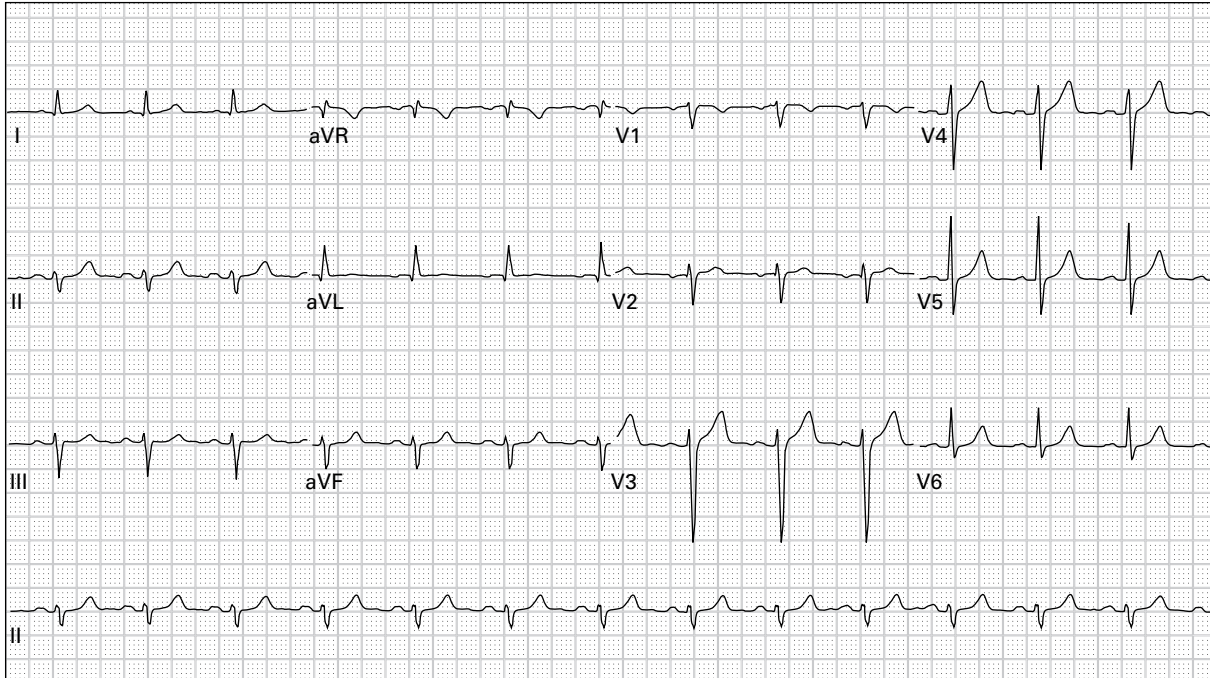
6. 79 year old man 45 minutes after receiving thrombolytic therapy for acute myocardial infarction; currently pain-free



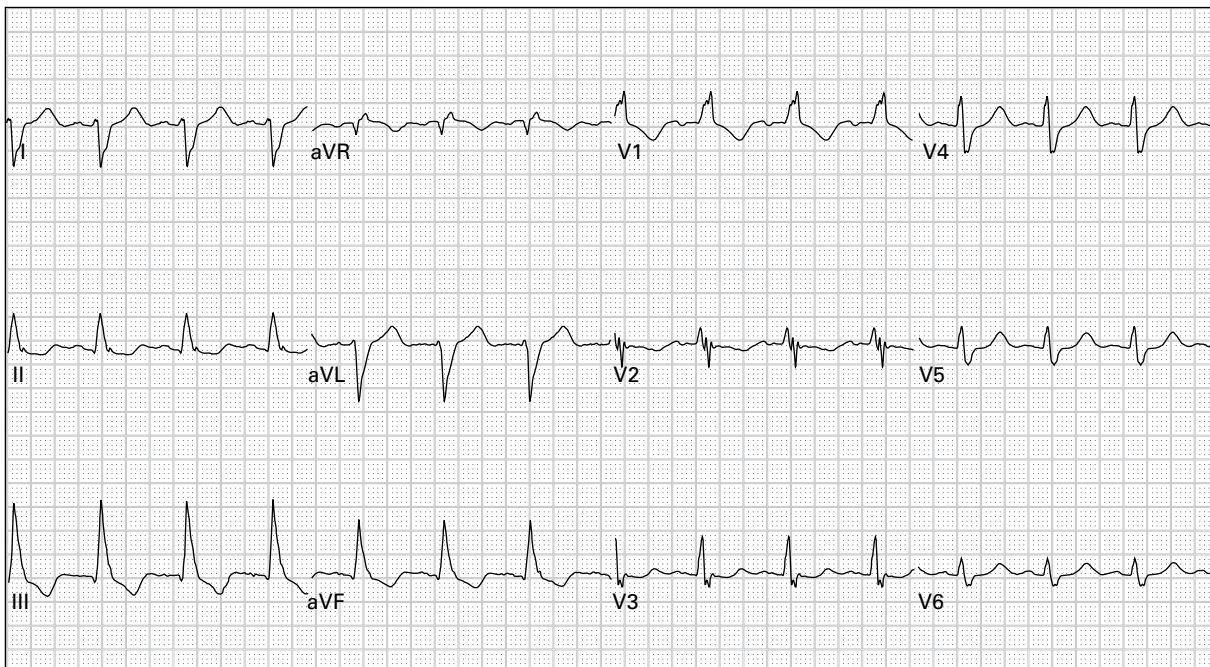
7. 43 year old man, asymptomatic



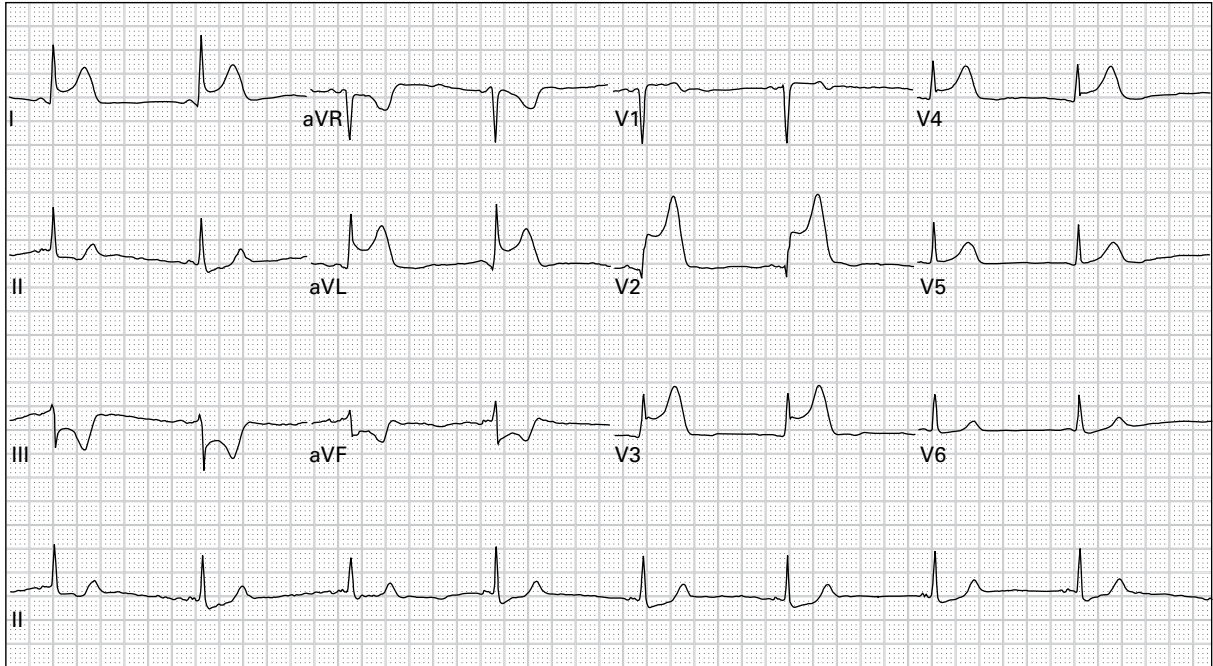
8. 82 year old man recently increased his dose of a beta-receptor-blocking medication; he now reports exertional lightheadedness



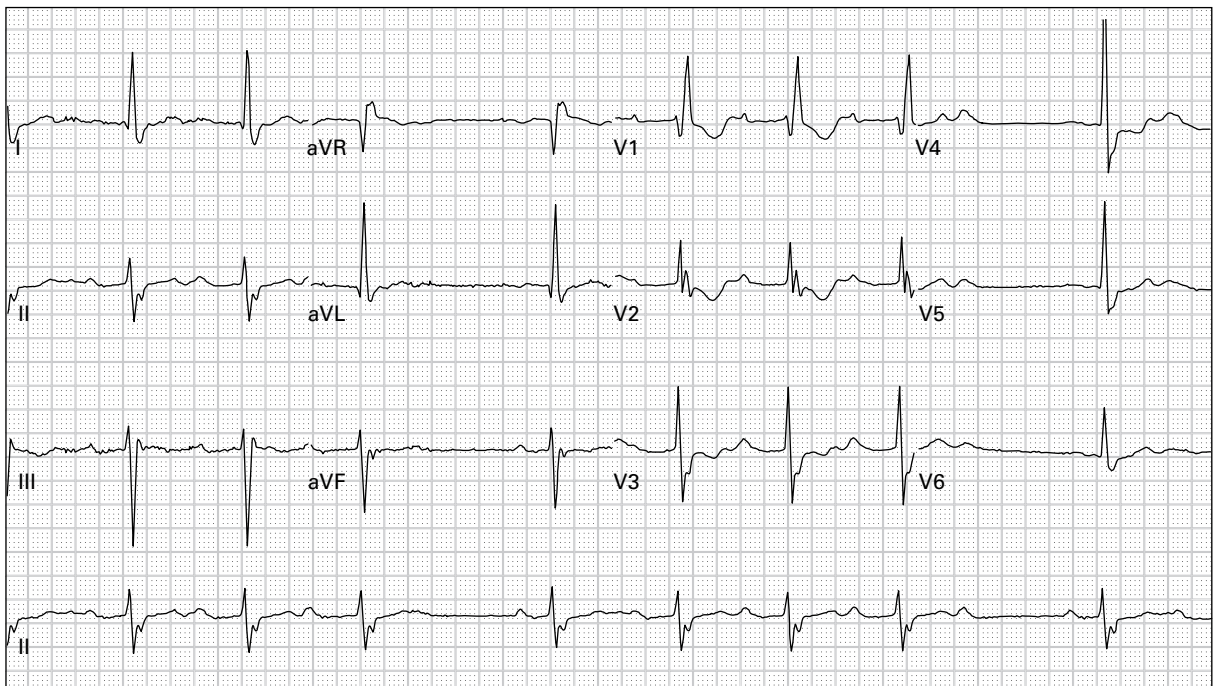
9. 49 year old man with occasional episodes of chest pain



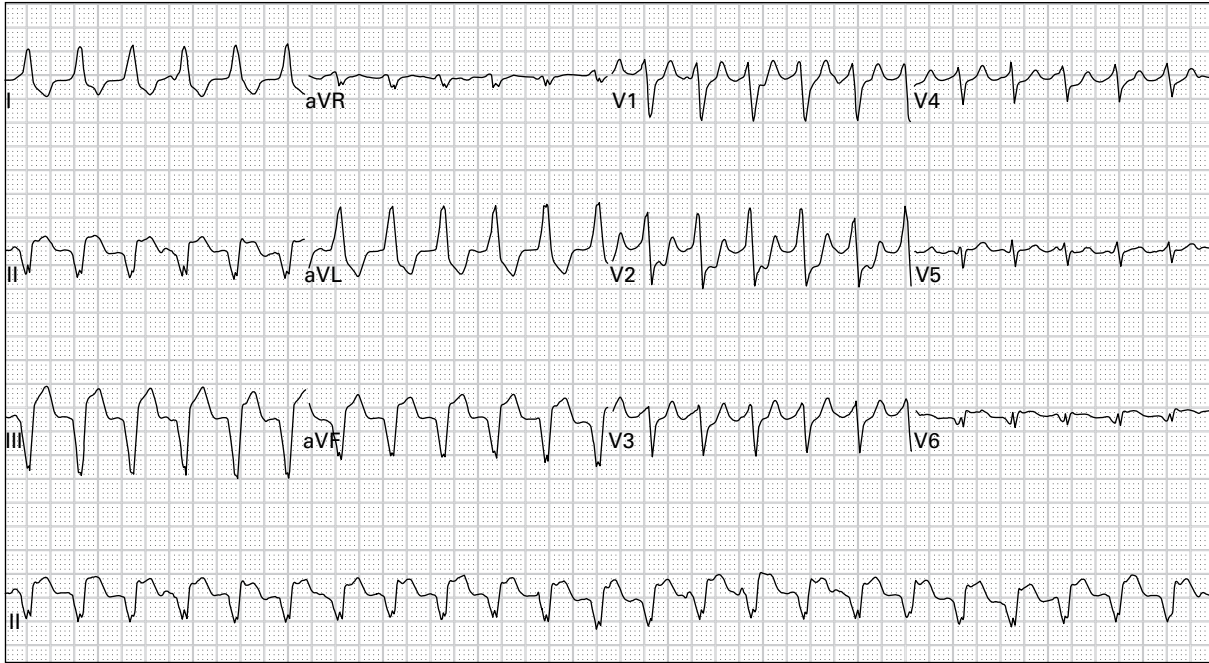
10. 65 year old woman with a long history of smoking presents for treatment of an emphysema exacerbation



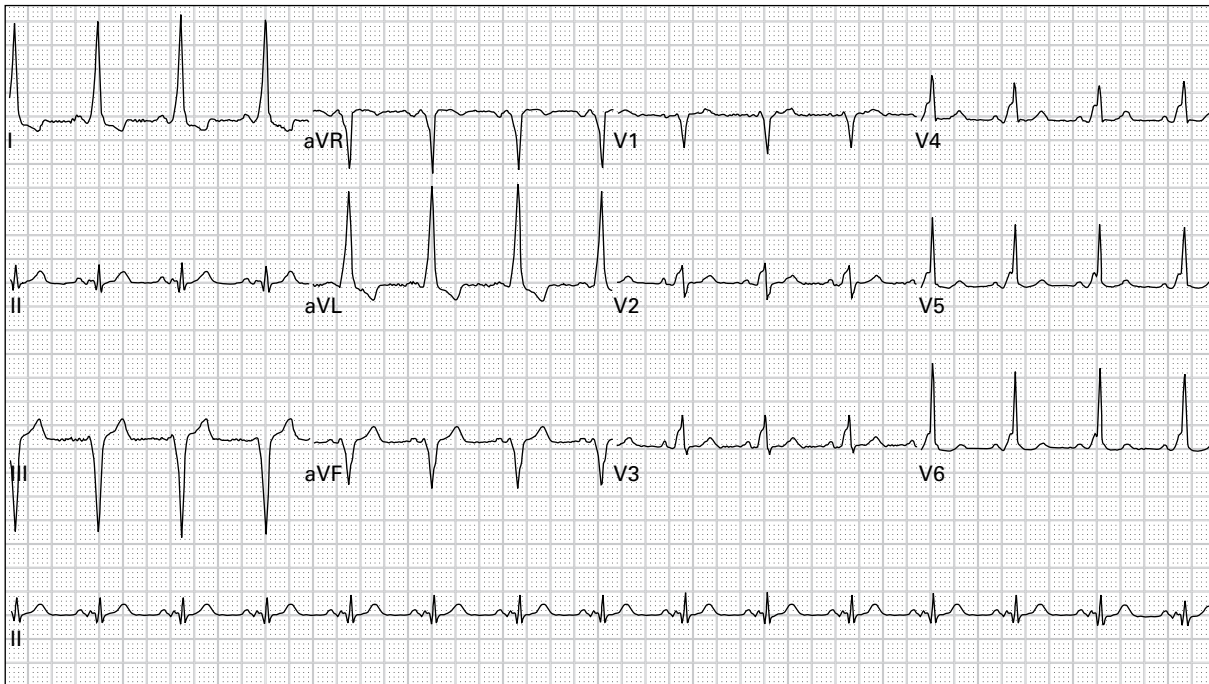
11. 54 year old woman complains of midsternal chest pain and lightheadedness



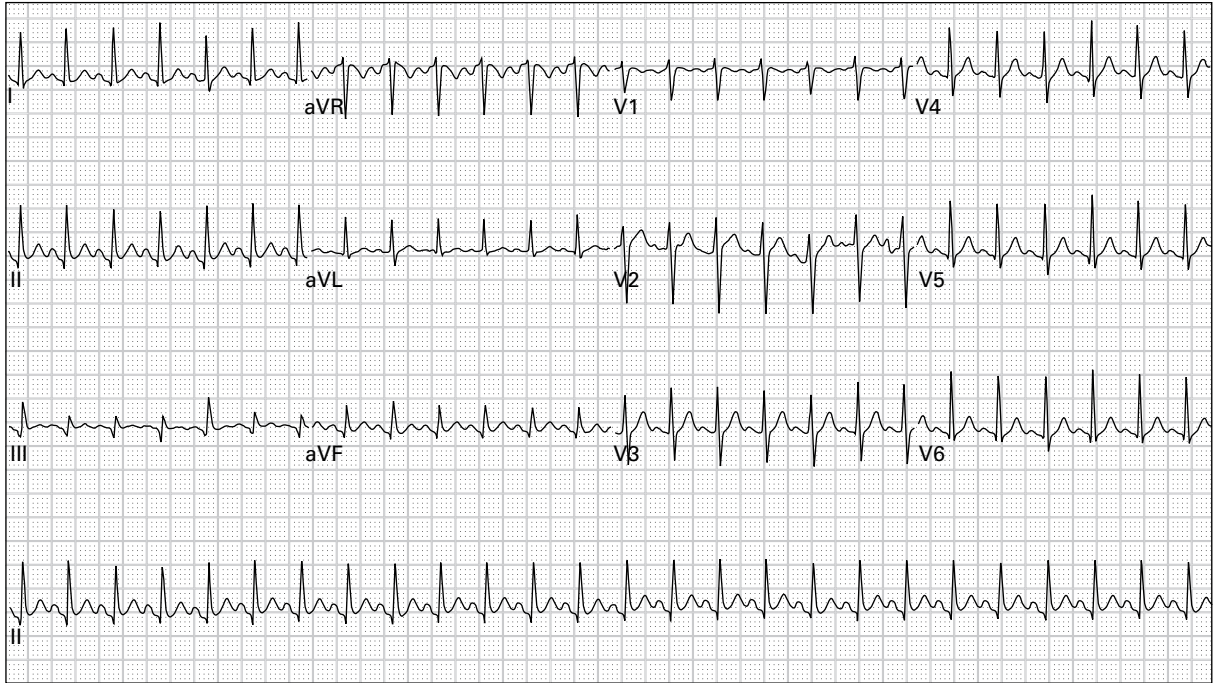
12. 86 year old woman complains of generalized weakness



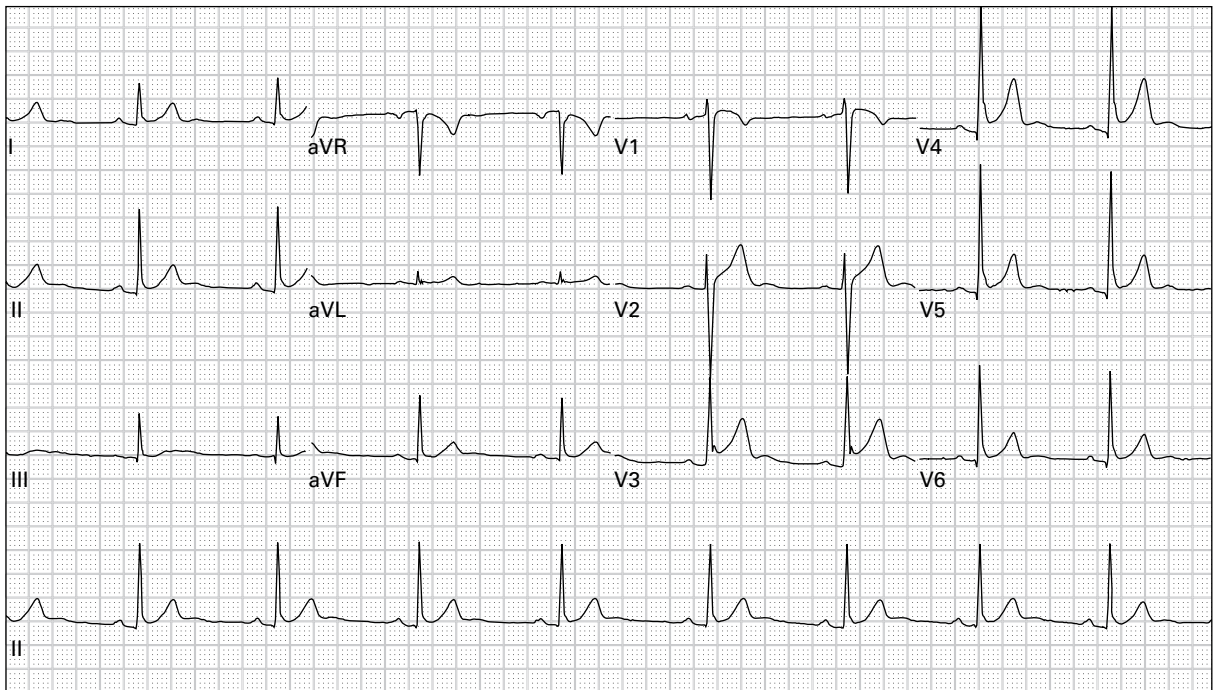
13. 61 year old man with palpitations and lightheadedness



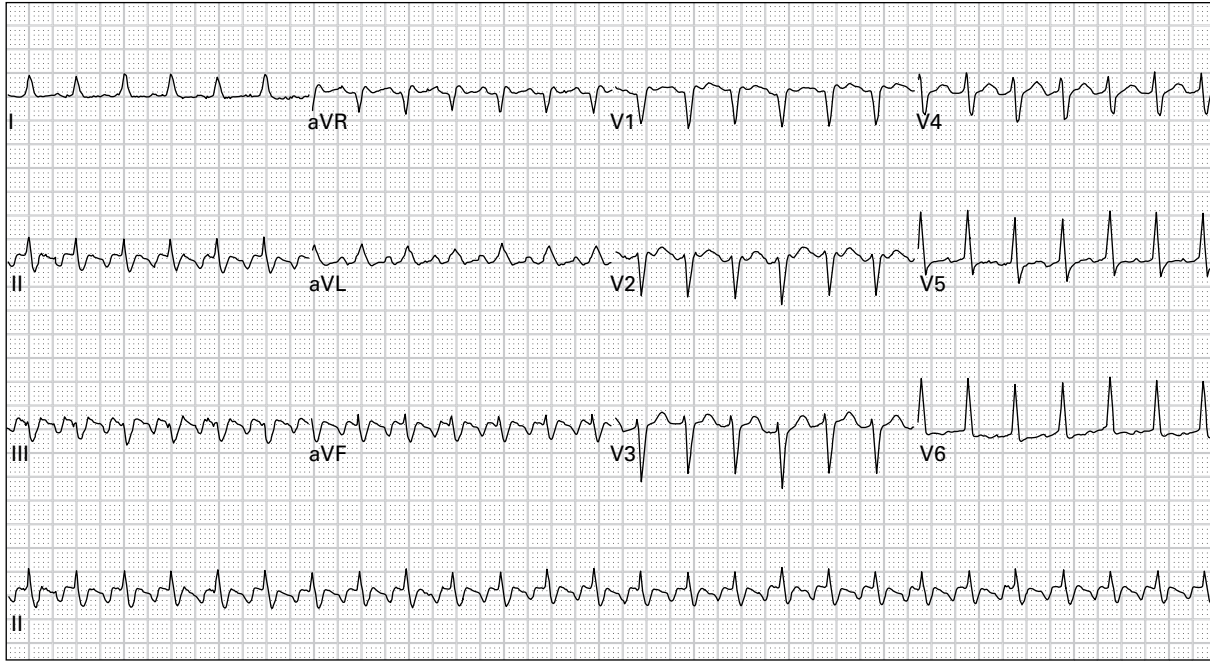
14. 44 year old woman with intermittent episodes of palpitations



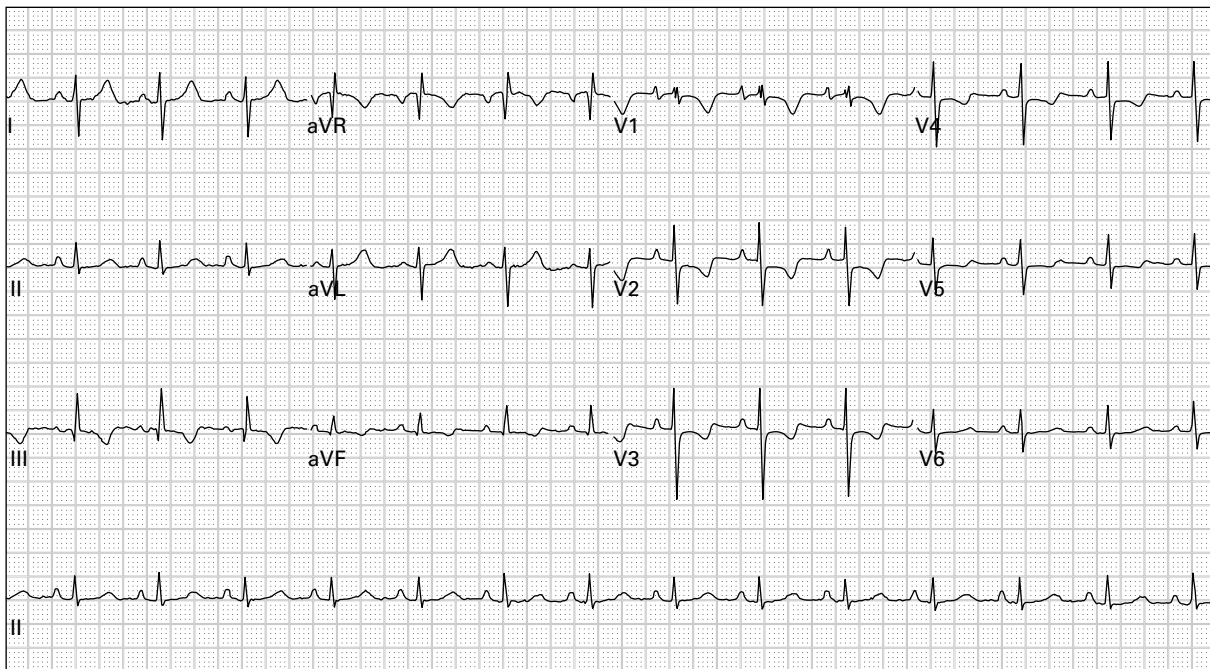
15. 24 year old pregnant woman with three days of frequent vomiting



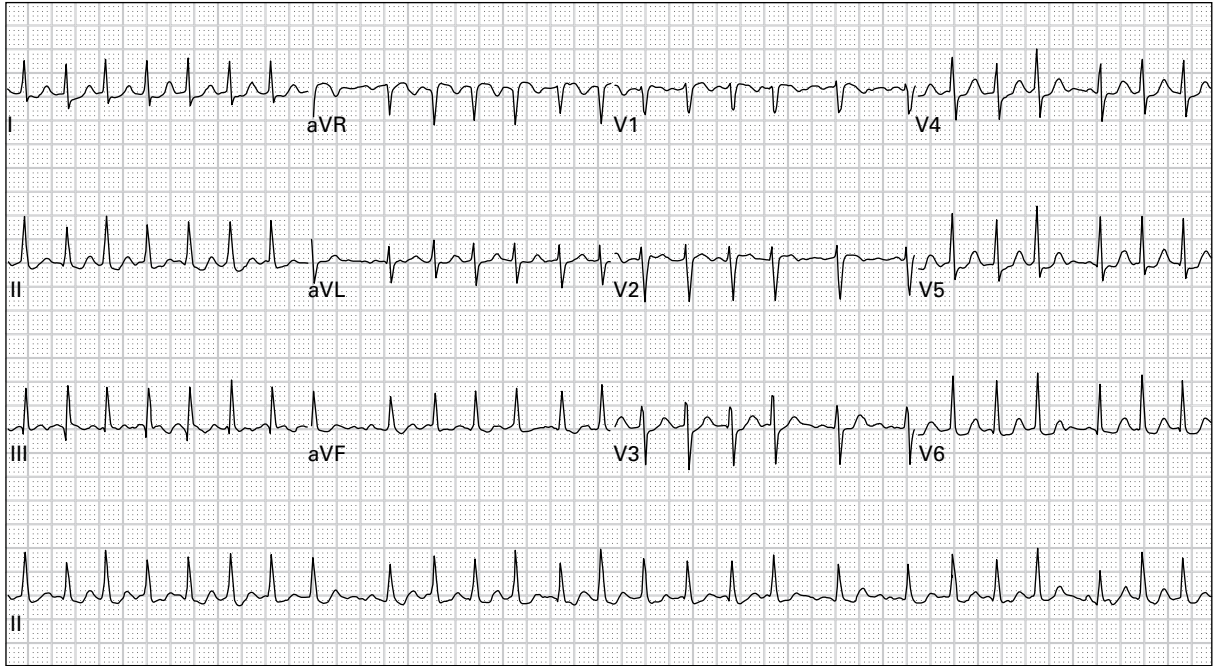
16. 37 year old man with pleuritic chest pain



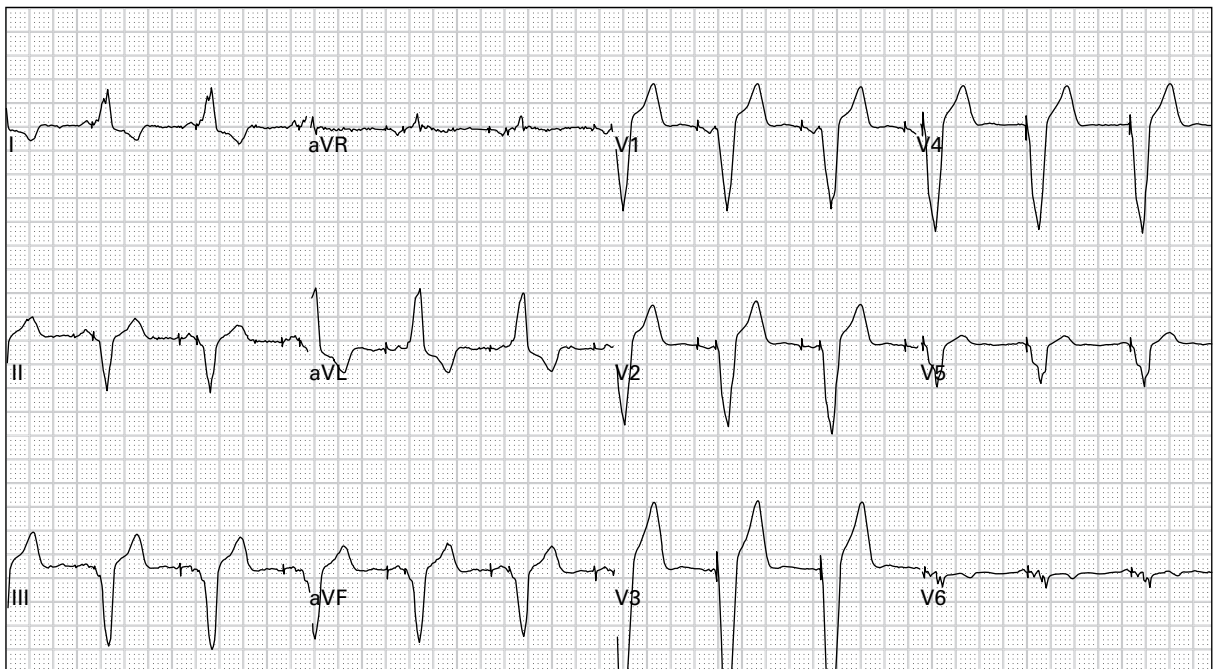
17. 63 year old man with palpitations and lightheadedness



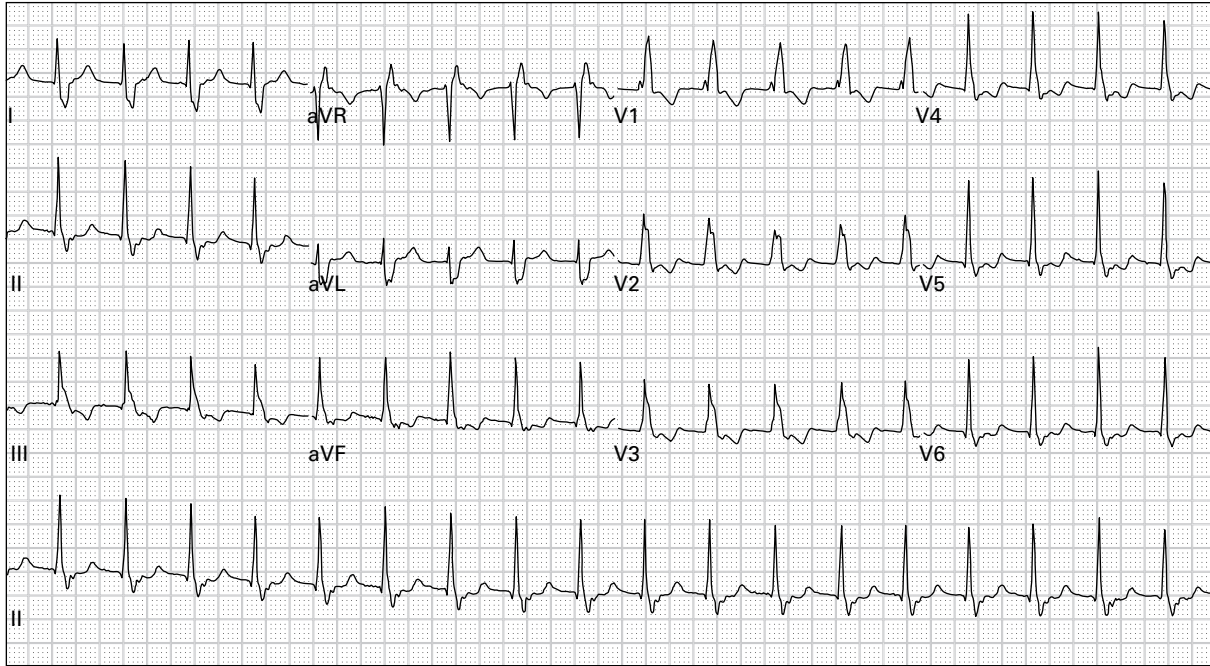
18. 33 year old obese man with sharp chest pain and dyspnea



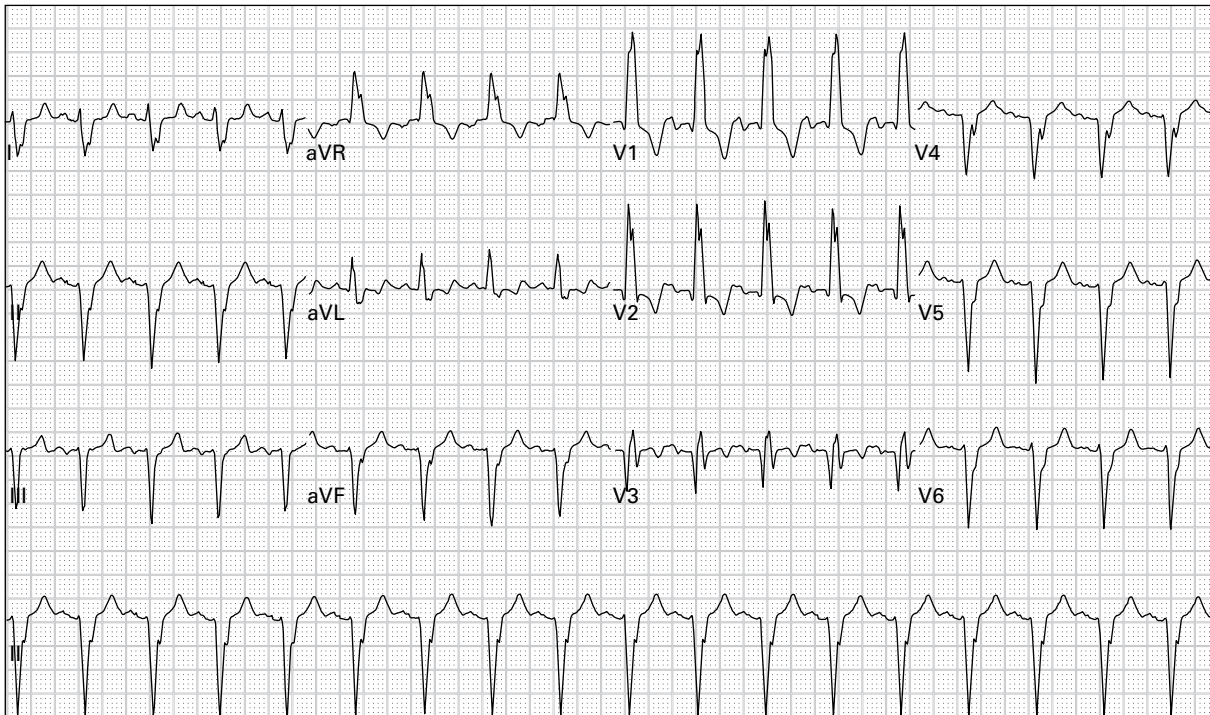
19. 81 year old woman with palpitations and generalized weakness



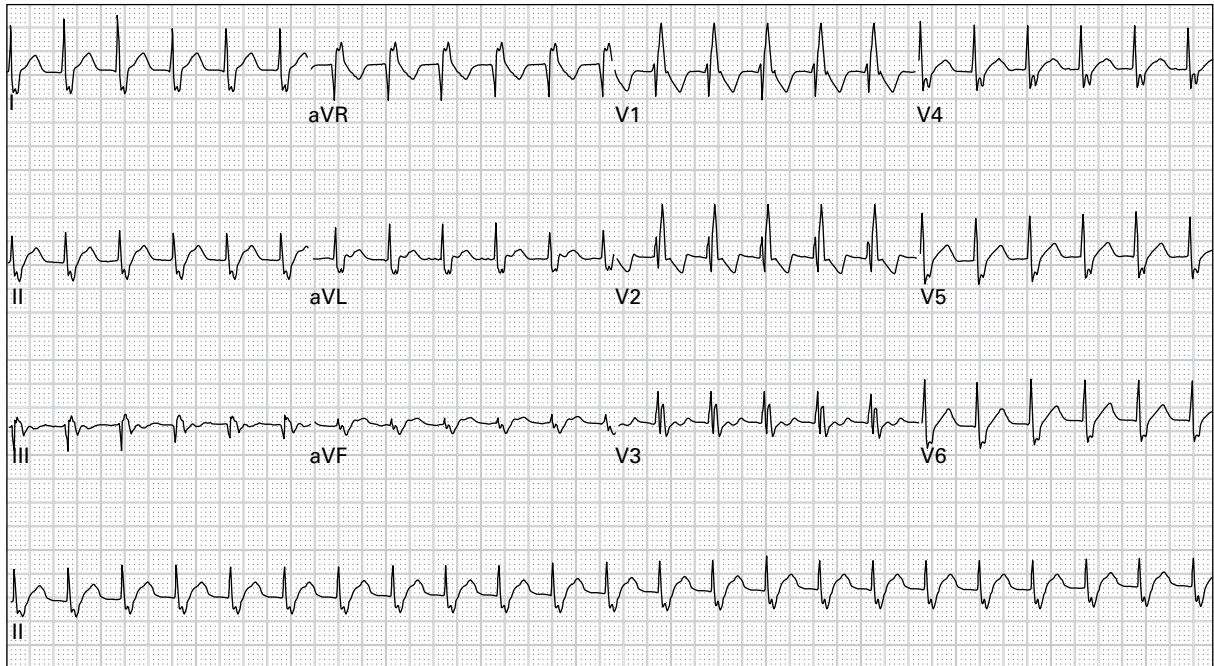
20. 61 year old man, asymptomatic



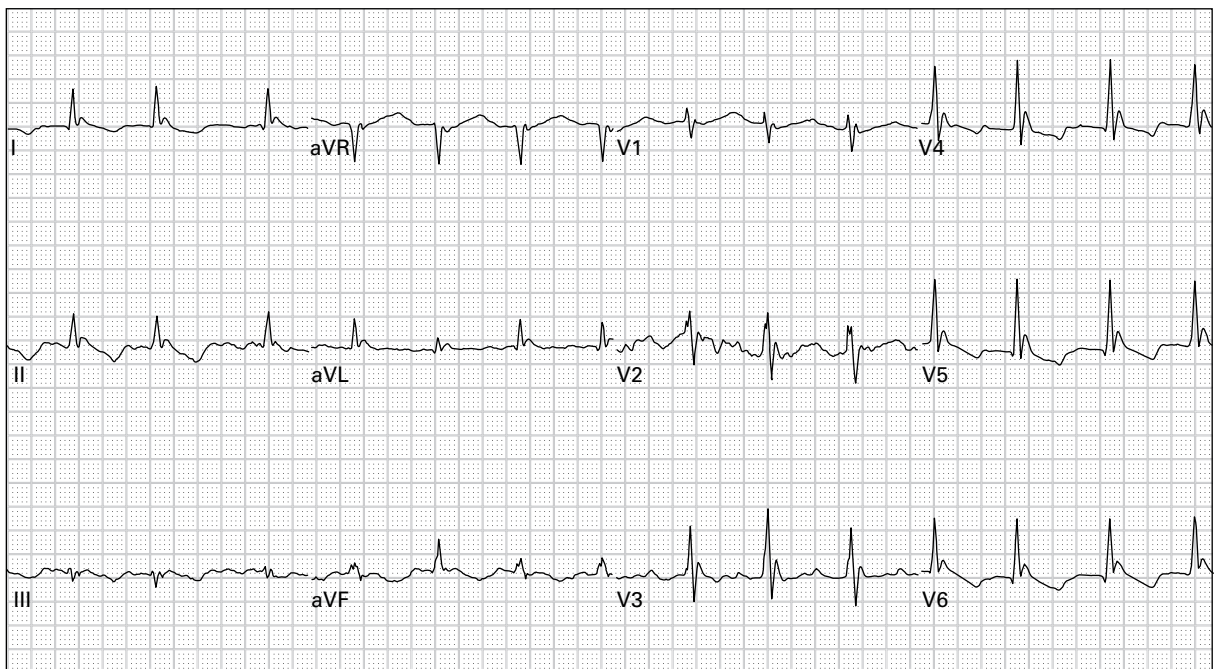
21. 57 year old woman with mild chest pain and palpitations



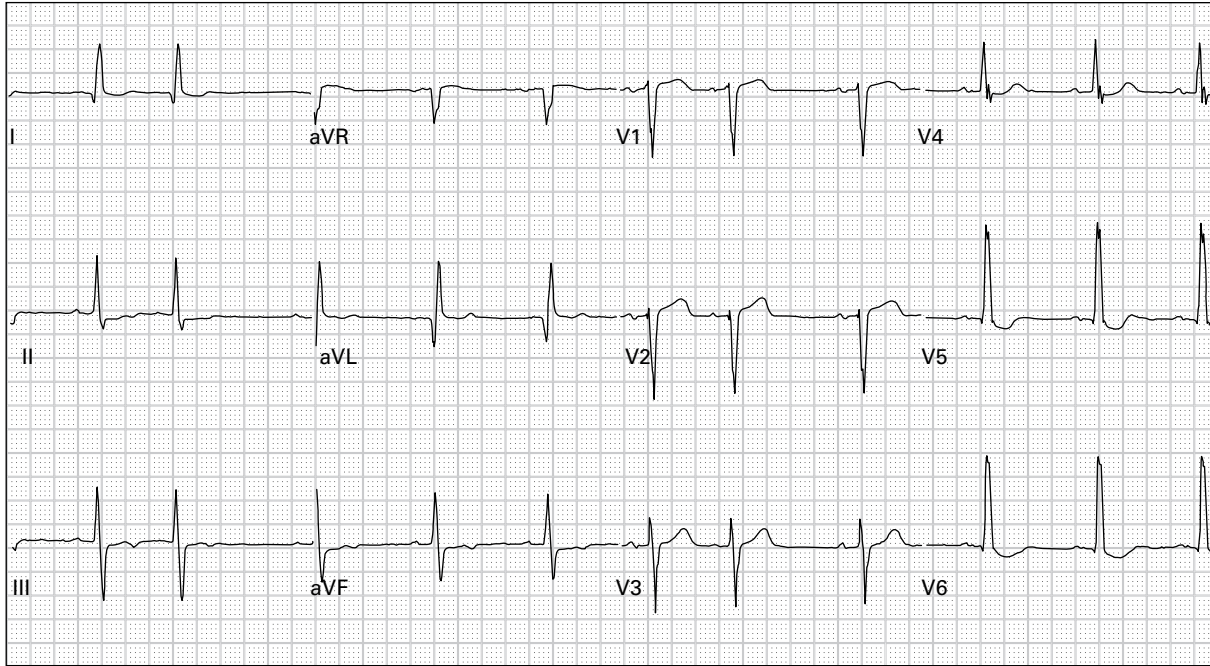
22. 75 year old man presents with cough, dyspnea, and wheezing



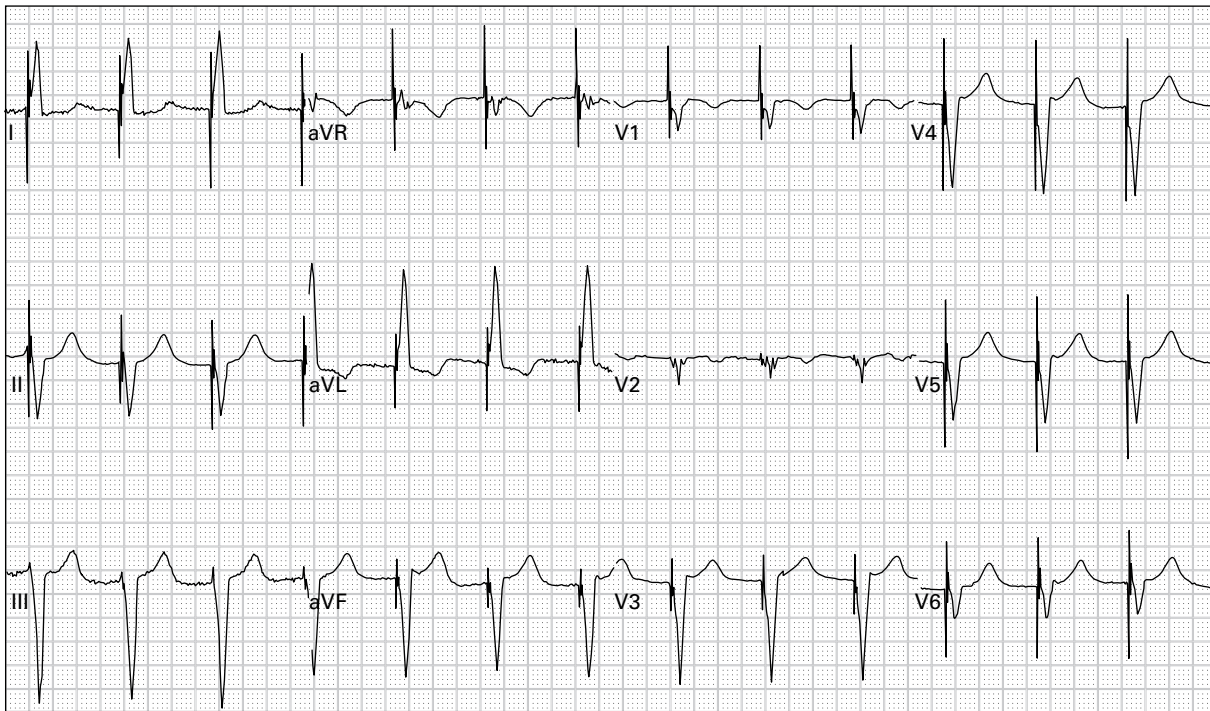
23. 43 year old man with severe palpitations



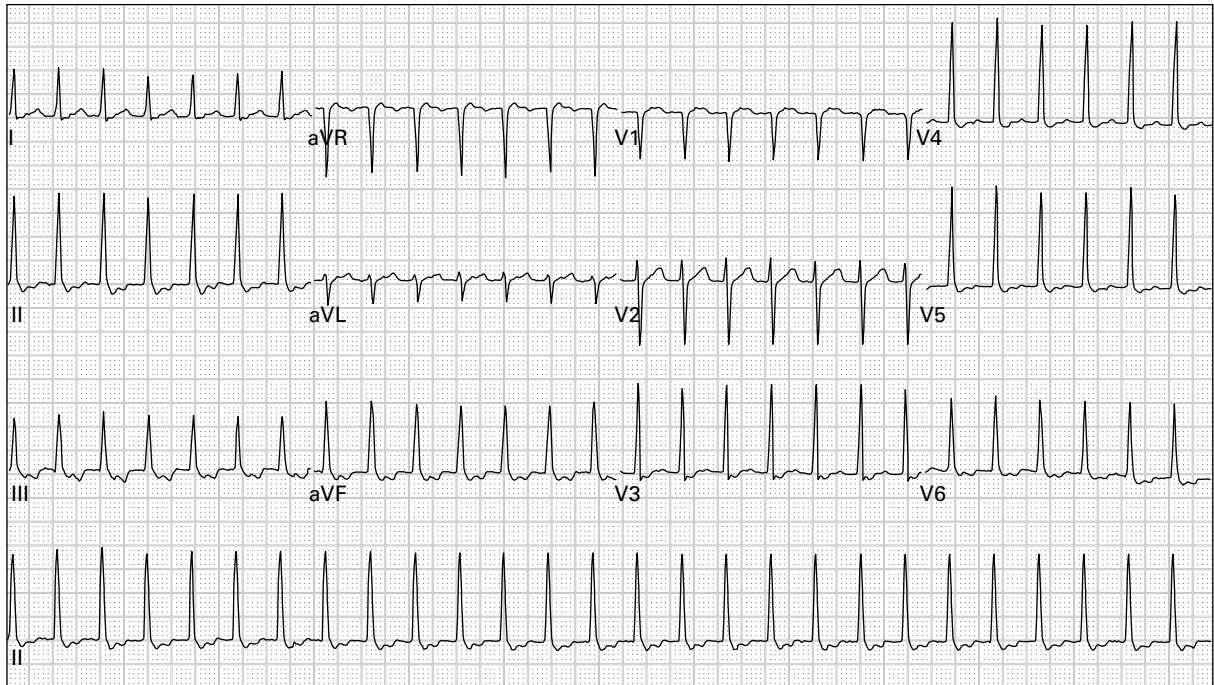
24. 52 year old homeless, alcoholic man found lying in an alley



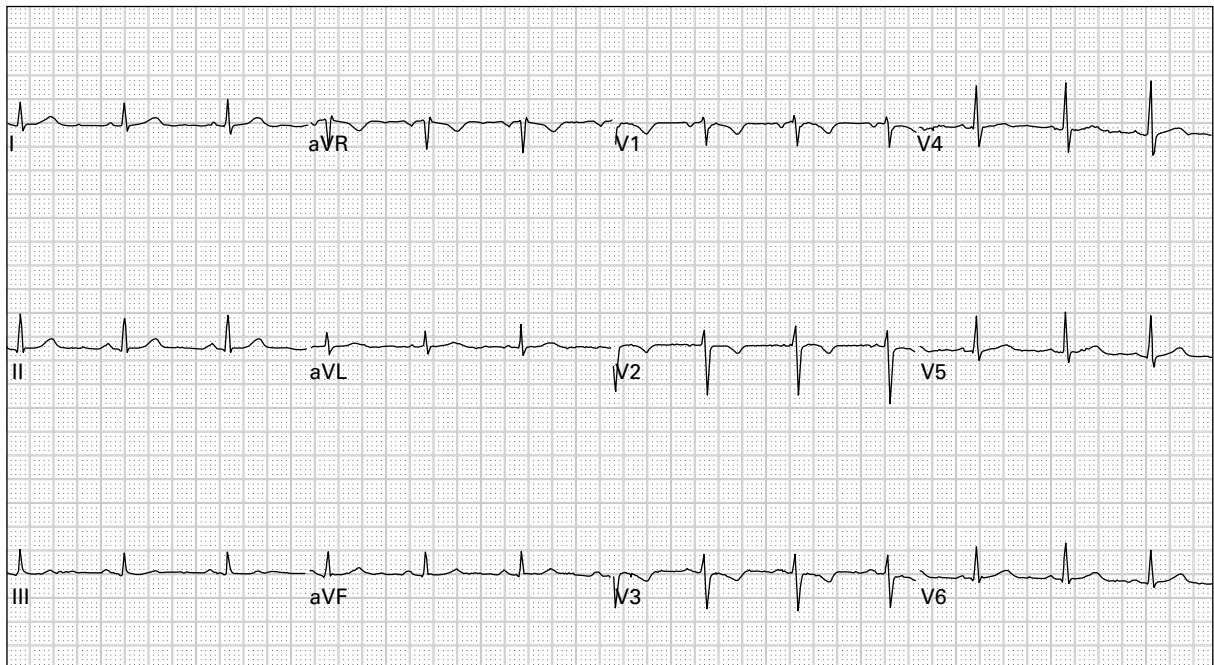
25. 68 year old man with history of congestive heart failure complains of dyspnea



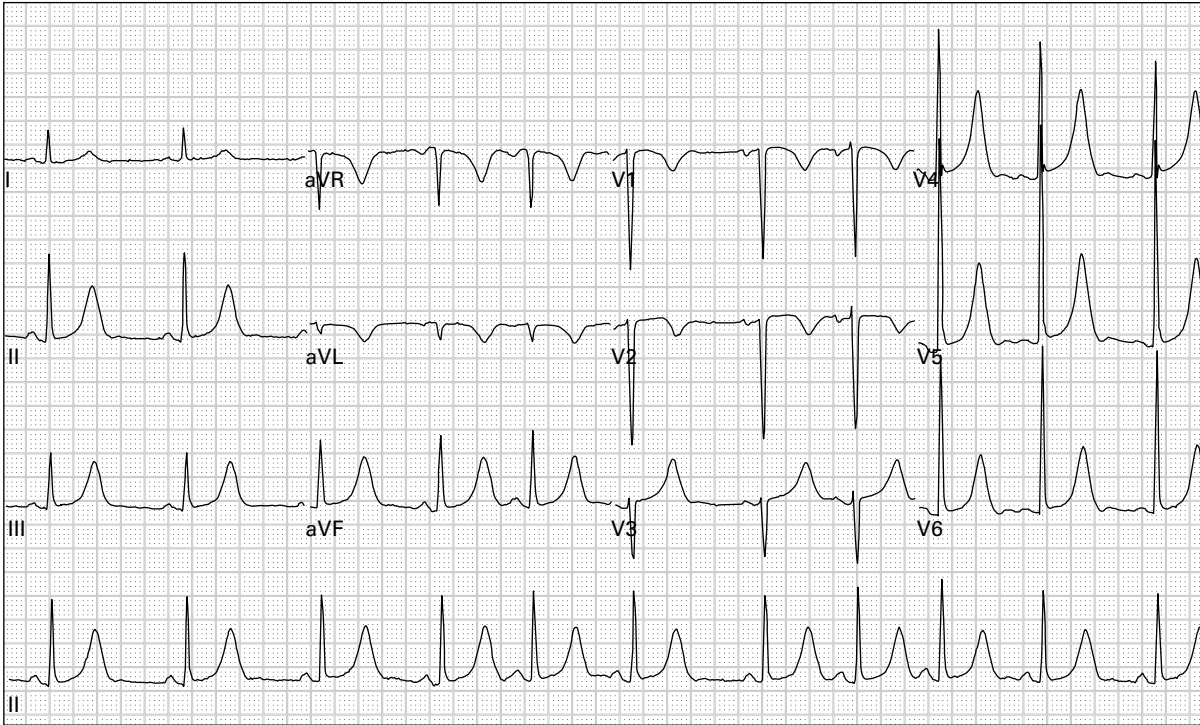
26. 85 year old woman reports a recent syncopal episode



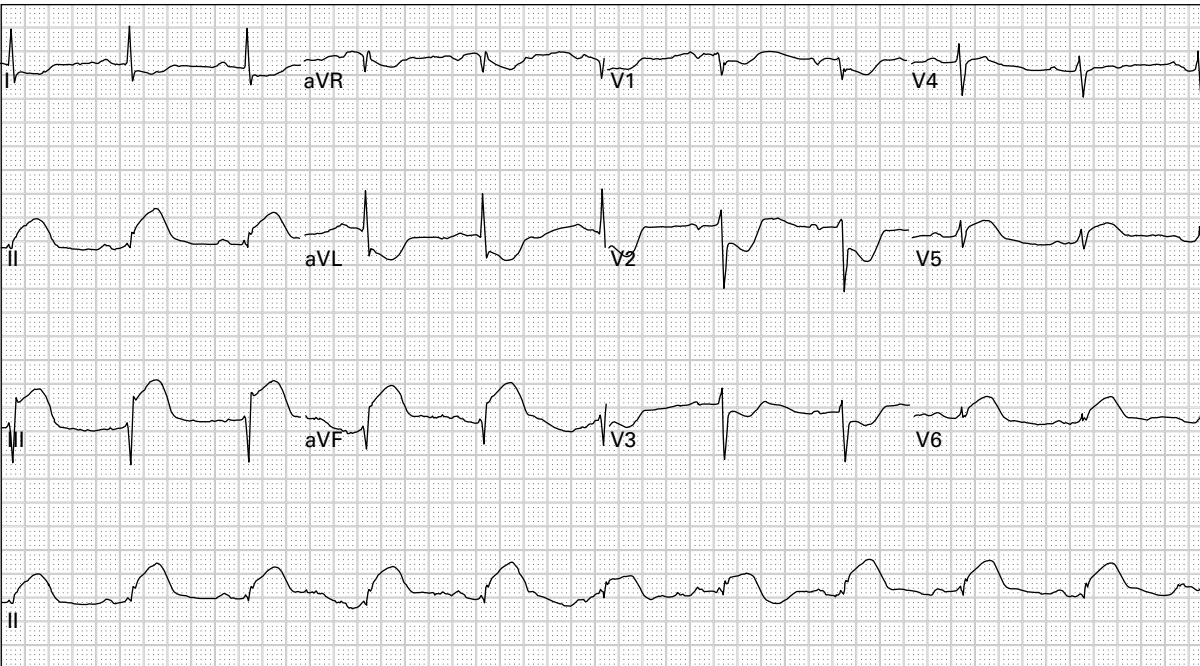
27. 40 year old woman with palpitations and lightheadedness



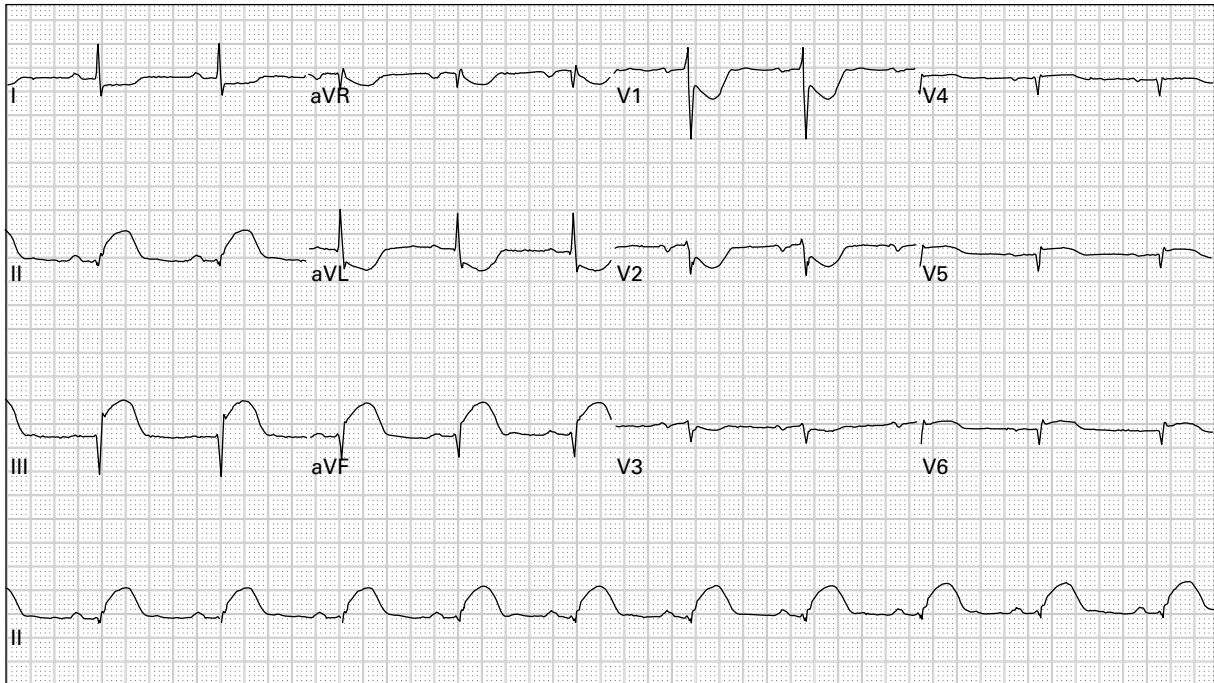
28. 35 year old woman with dyspnea



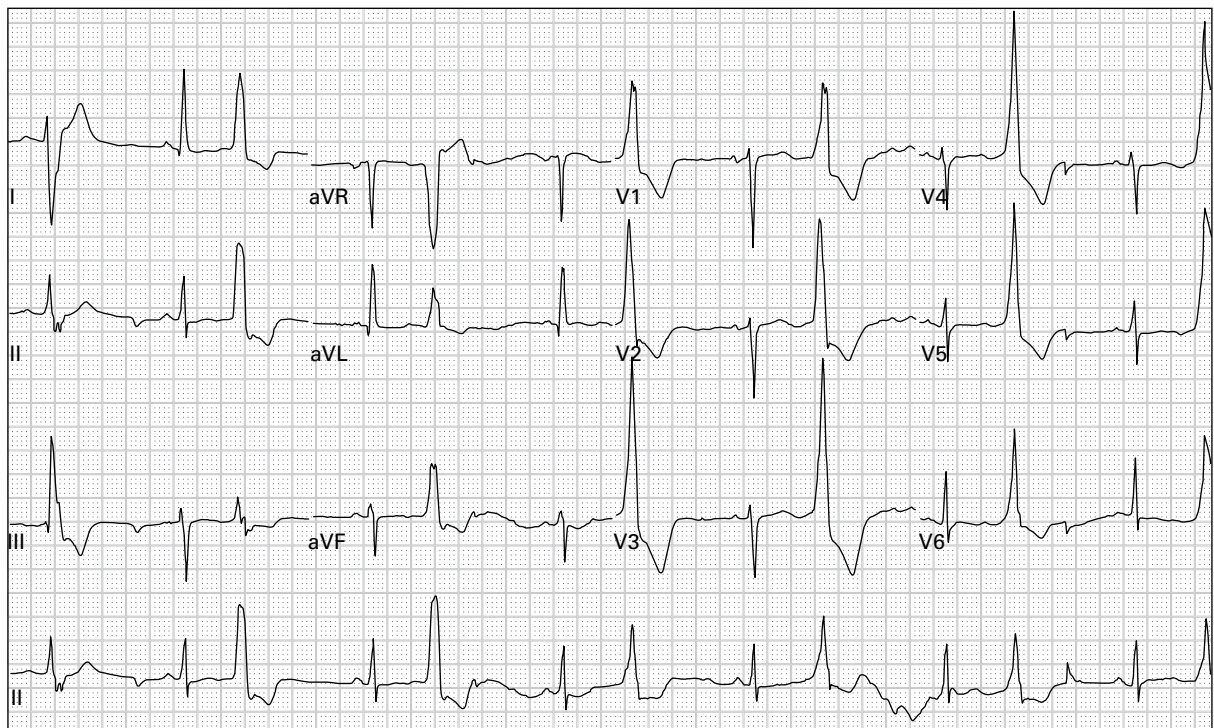
29. 41 year old woman with chest pain after cocaine use



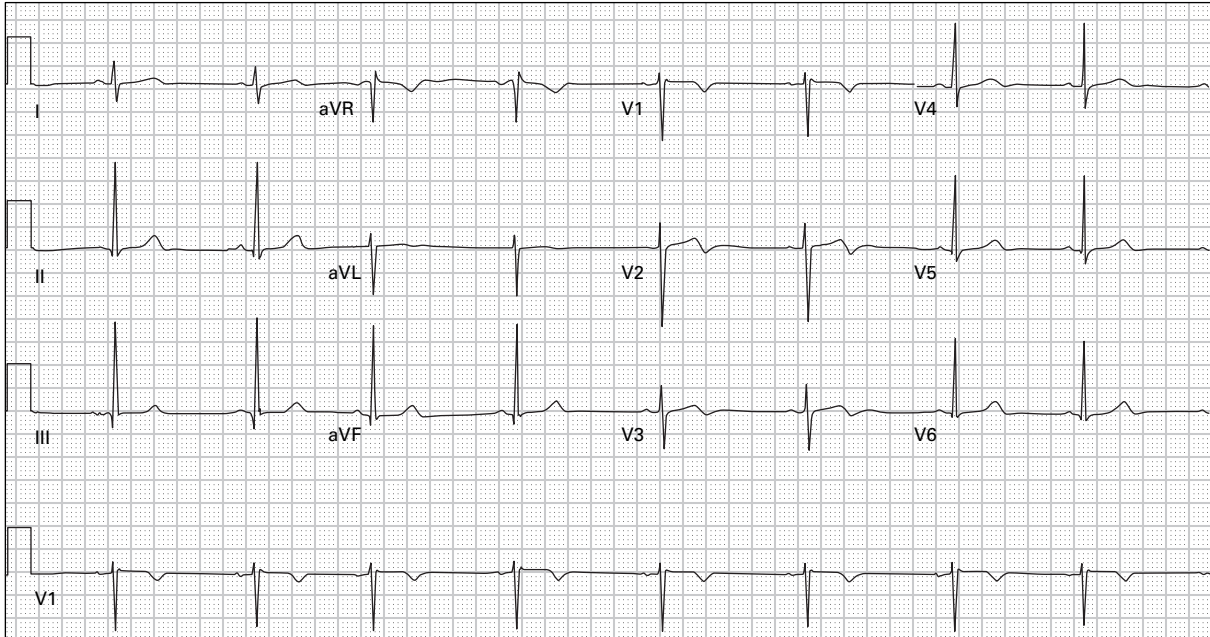
30. 57 year old man with chest pressure and diaphoresis



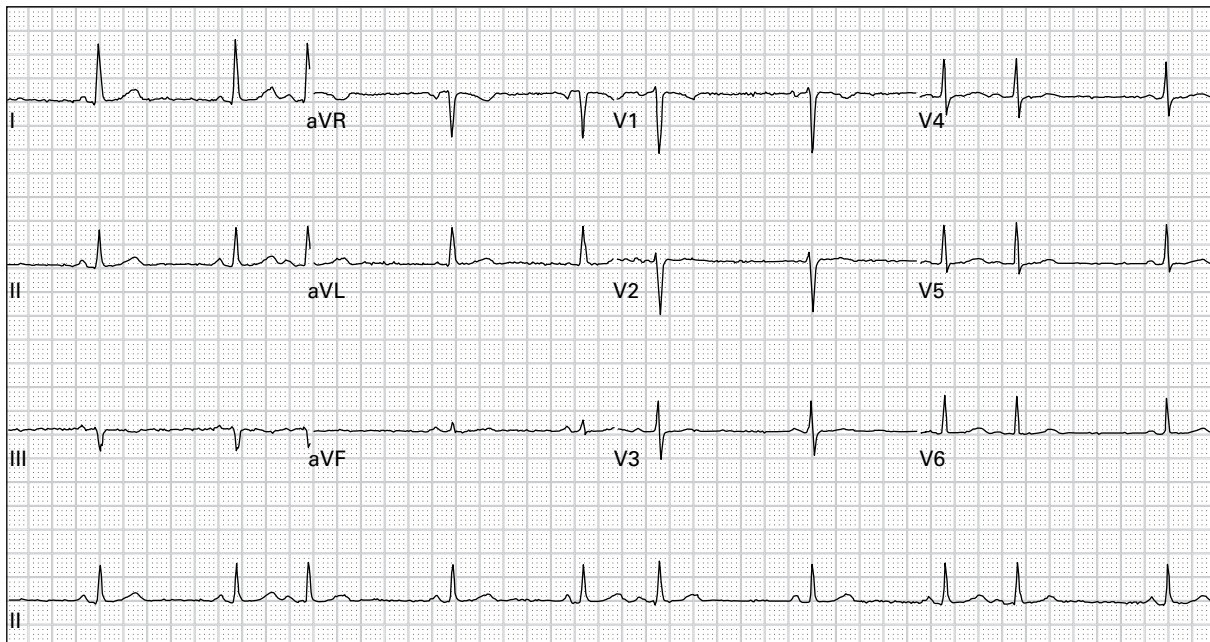
31. 57 year old man with chest pressure and diaphoresis (right-sided precordial leads)



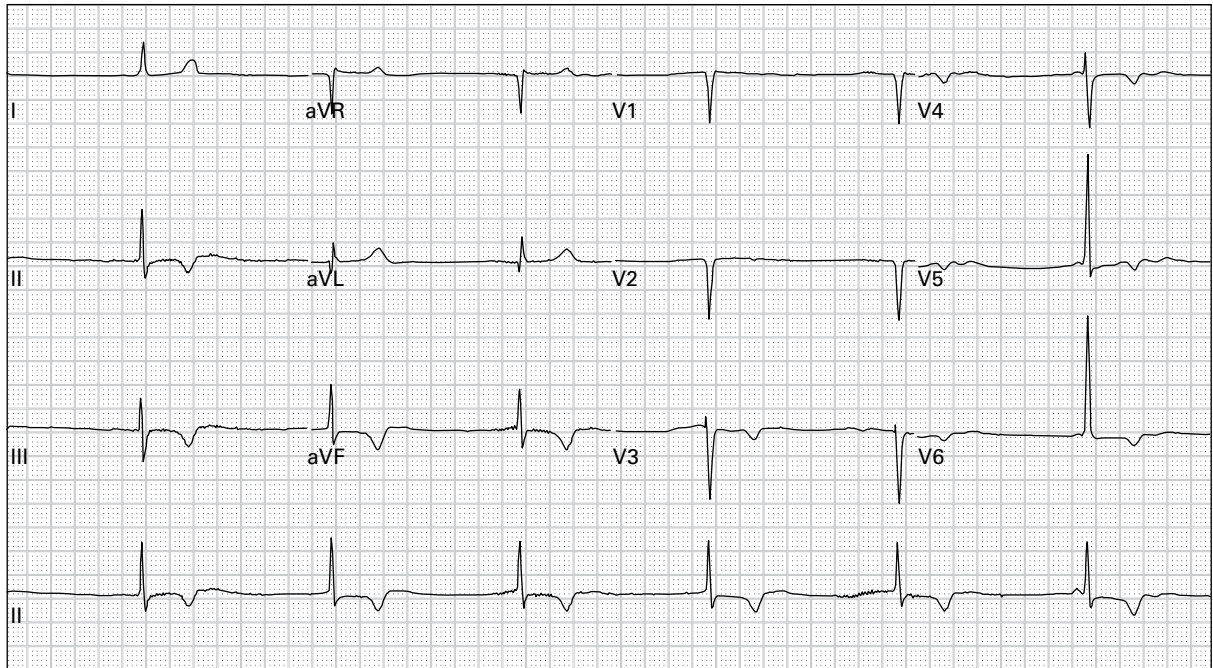
32. 60 year old woman with acute onset of expressive aphasia



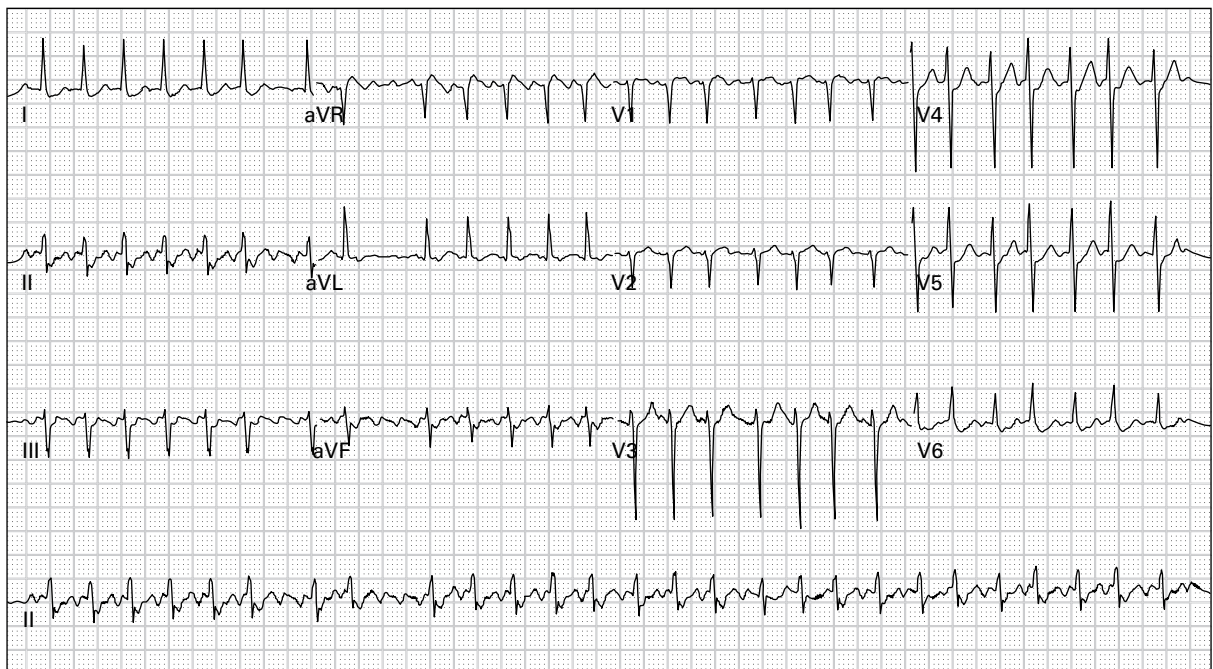
33. 51 year old man presenting after a one-hour episode of severe chest pressure with diaphoresis; currently asymptomatic



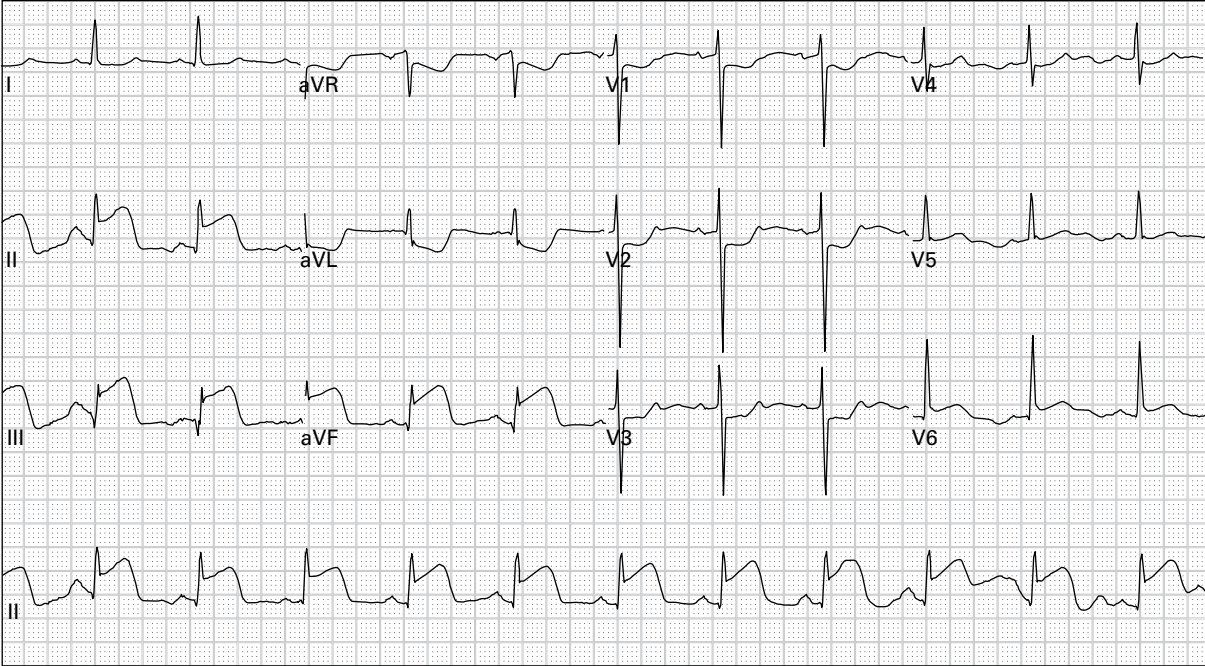
34. 41 year old woman with nausea and vomiting



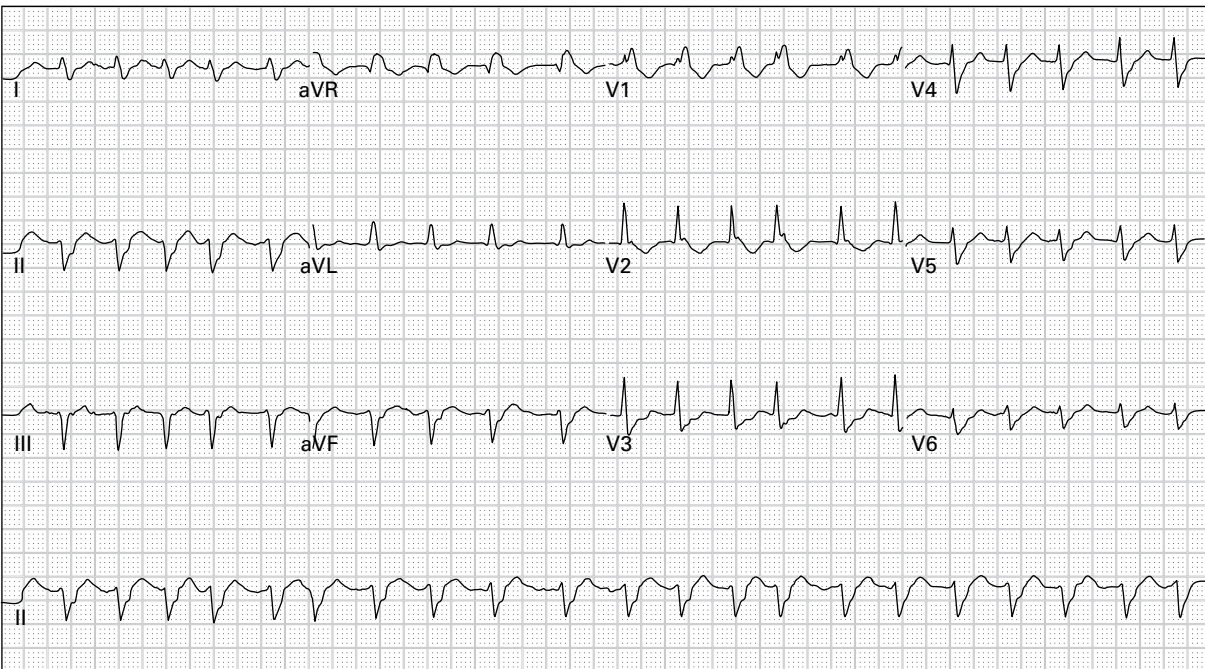
35. 75 year old woman accidentally took too many of her beta-blocker tablets



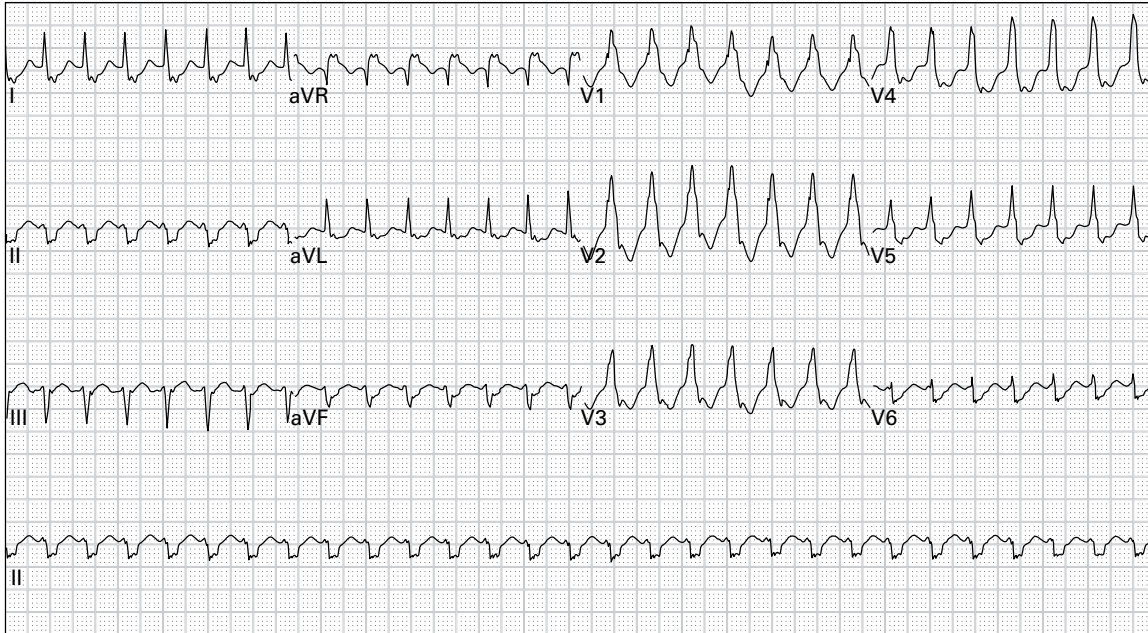
36. 68 year old man with palpitations and generalized weakness



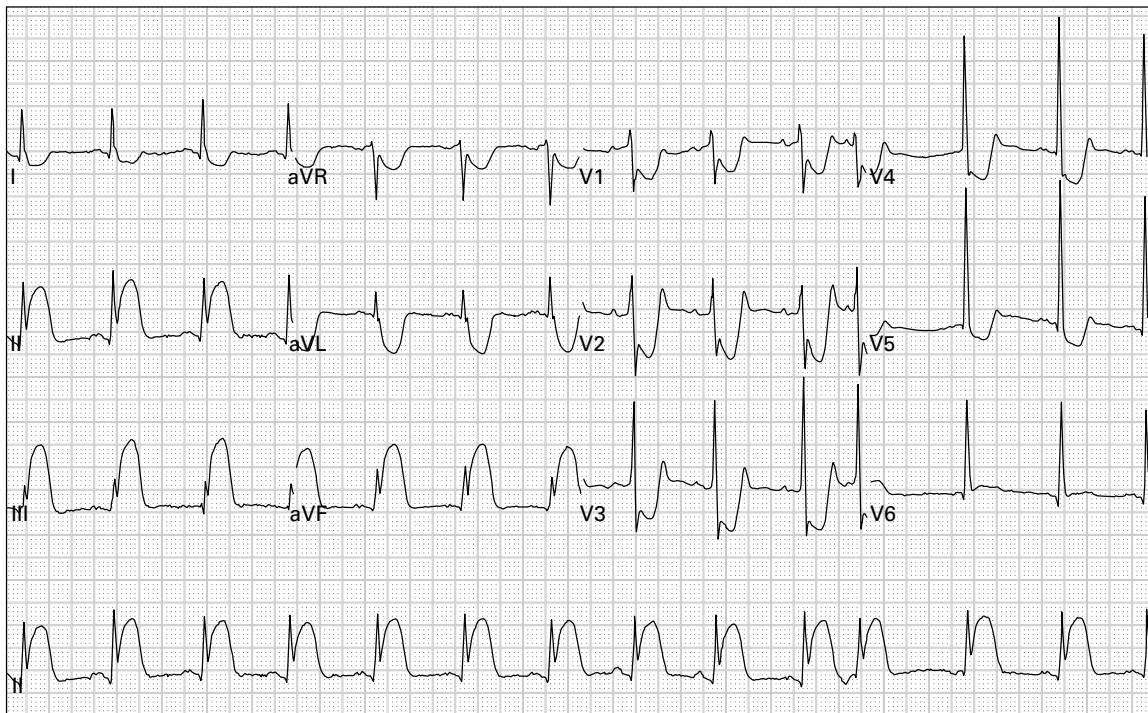
37. 38 year old man with chest pain, nausea, and diaphoresis



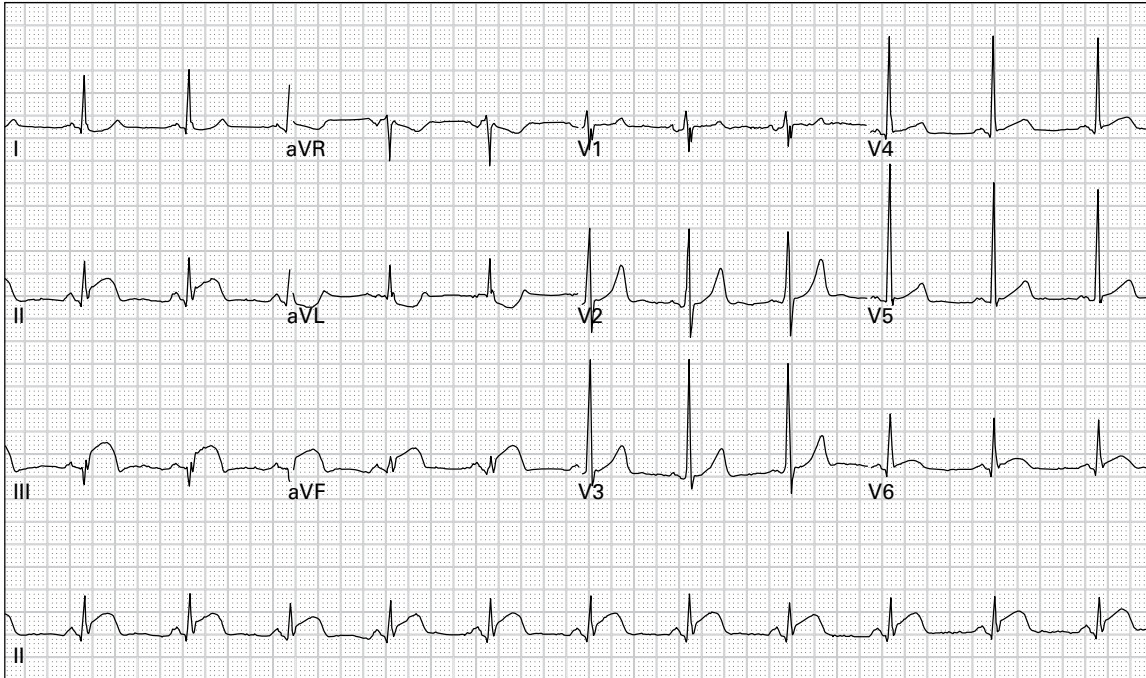
38. 62 year old woman with palpitations



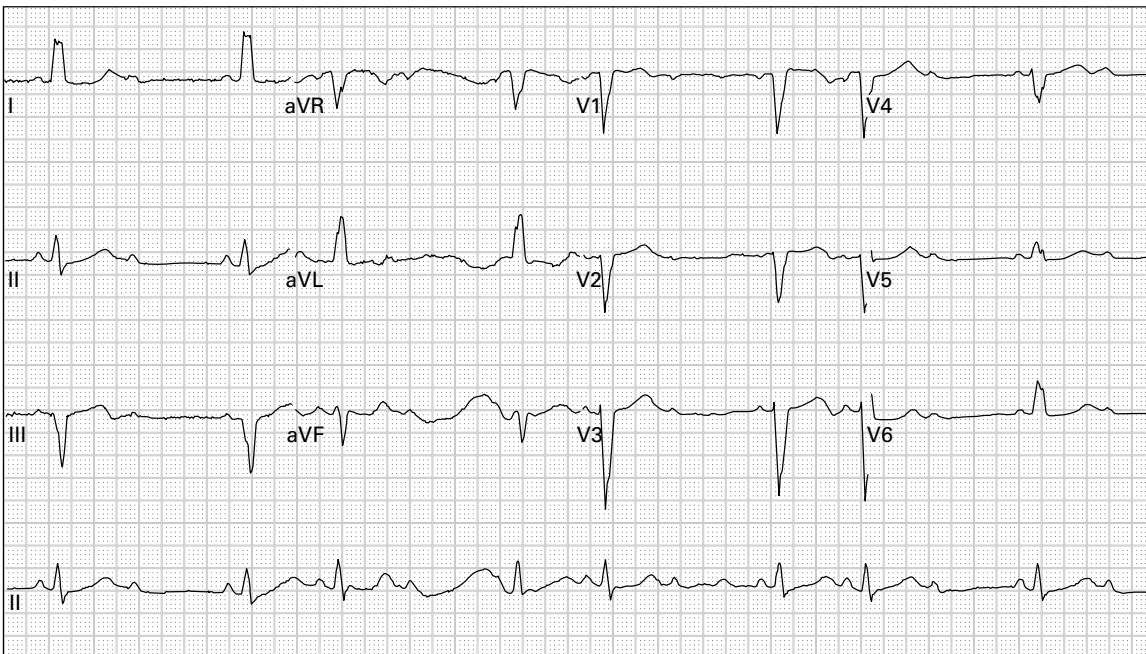
39. 74 year old man with chest pain and palpitations



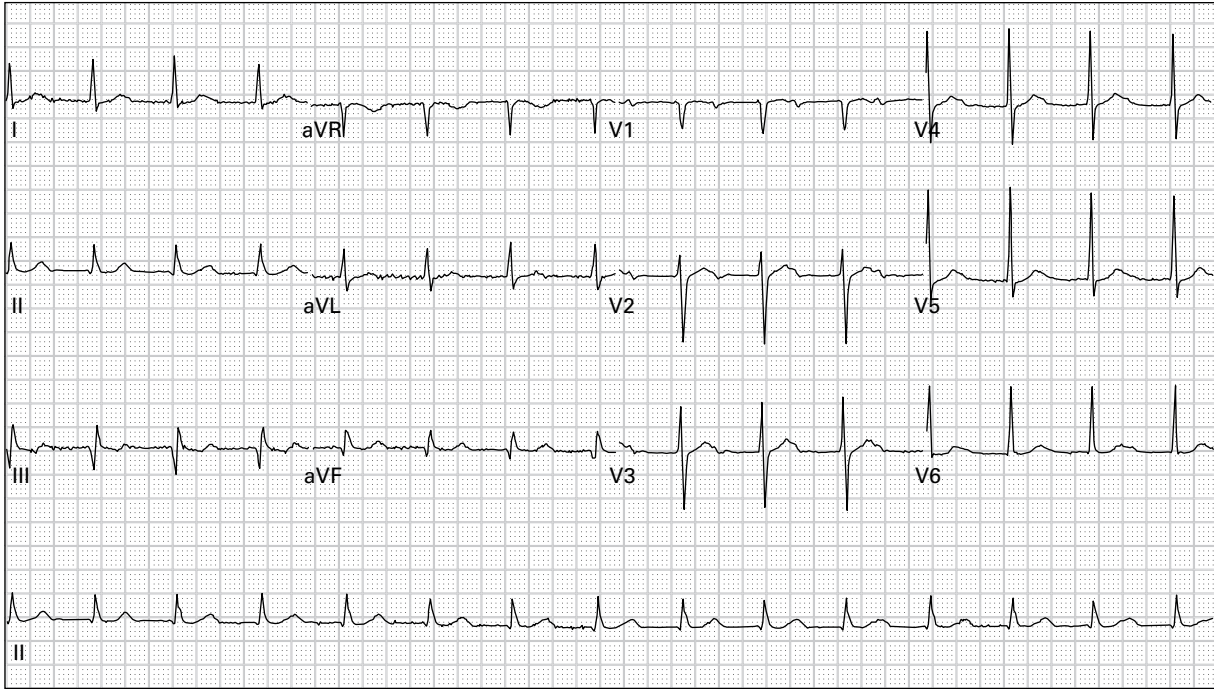
40. 45 year old man with severe left chest pressure, nausea, and dyspnea



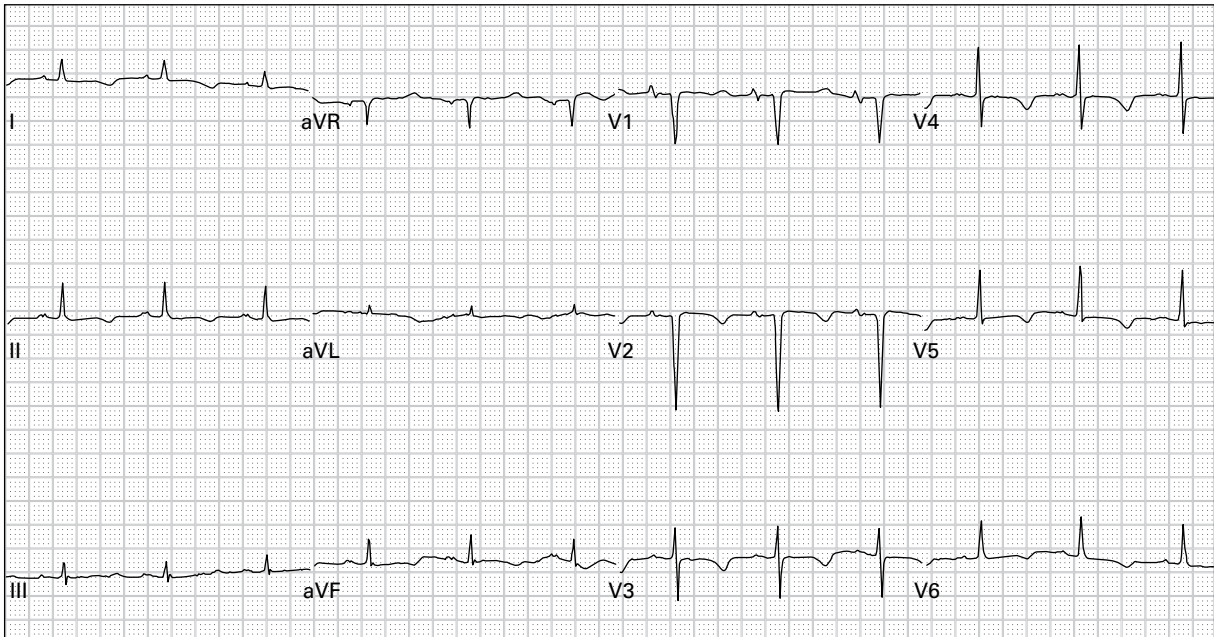
41. 45 year old man with left chest pressure



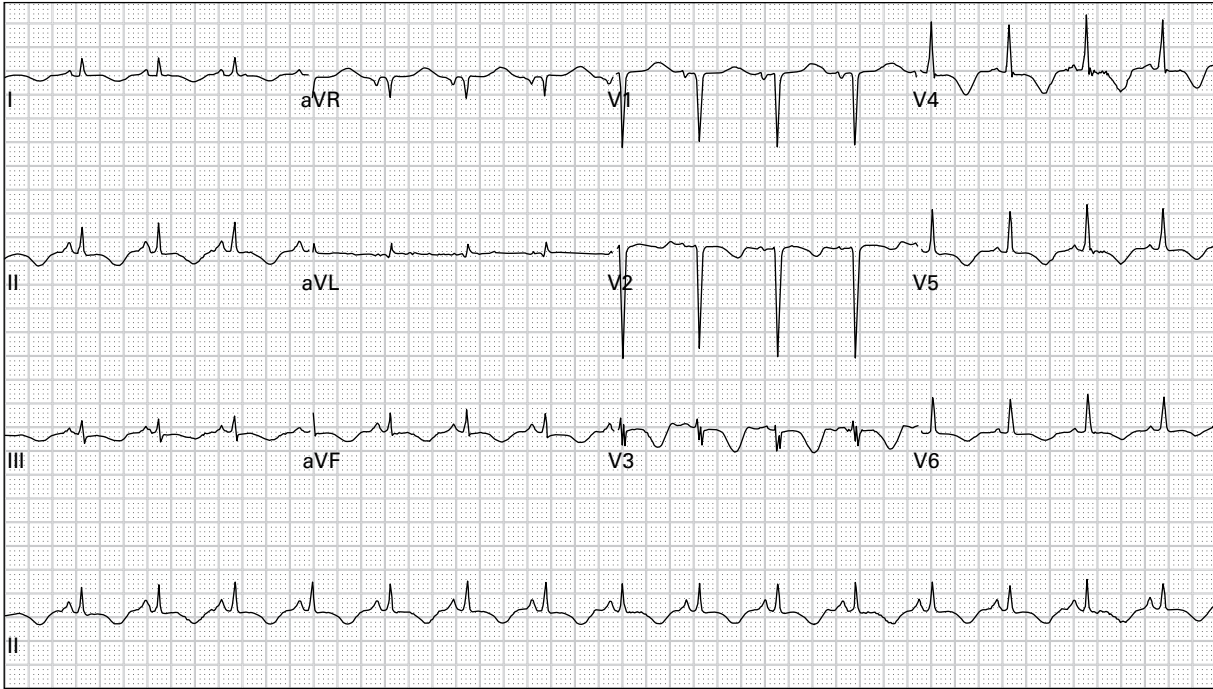
42. 85 year old woman presents after a syncopal episode, and still reports lightheadedness



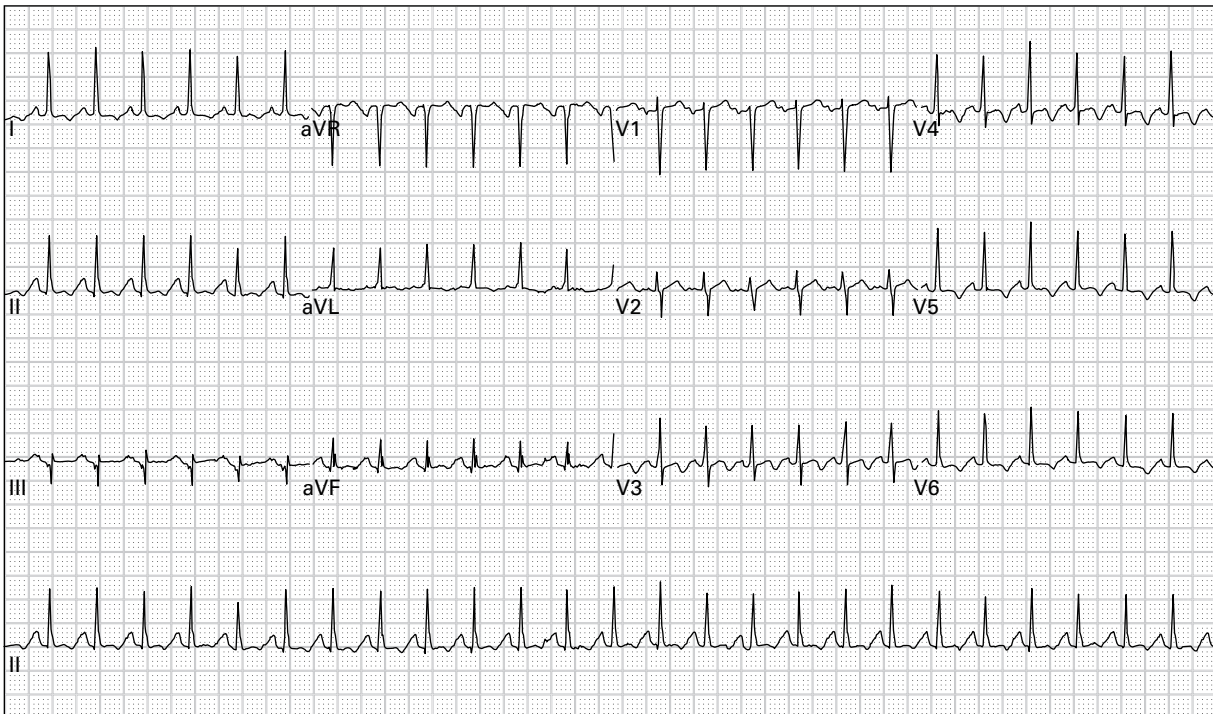
43. 81 year old man being admitted for pneumonia



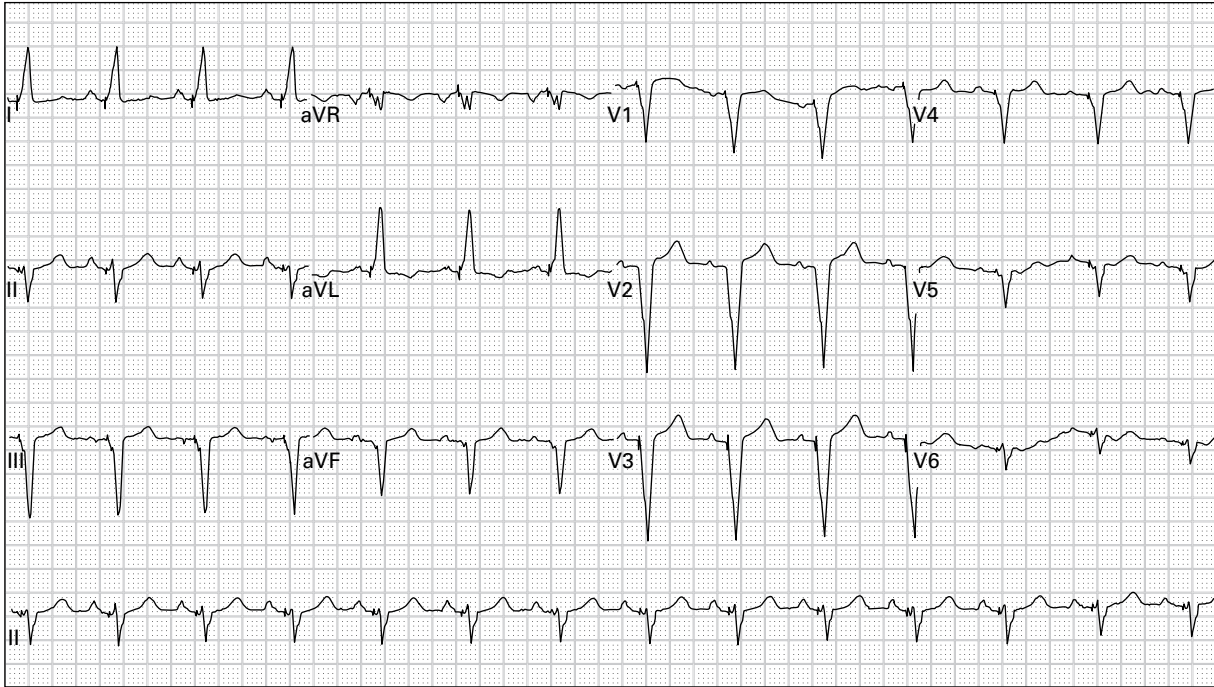
44. 71 year old woman with chronic renal insufficiency presents with carpopedal spasm



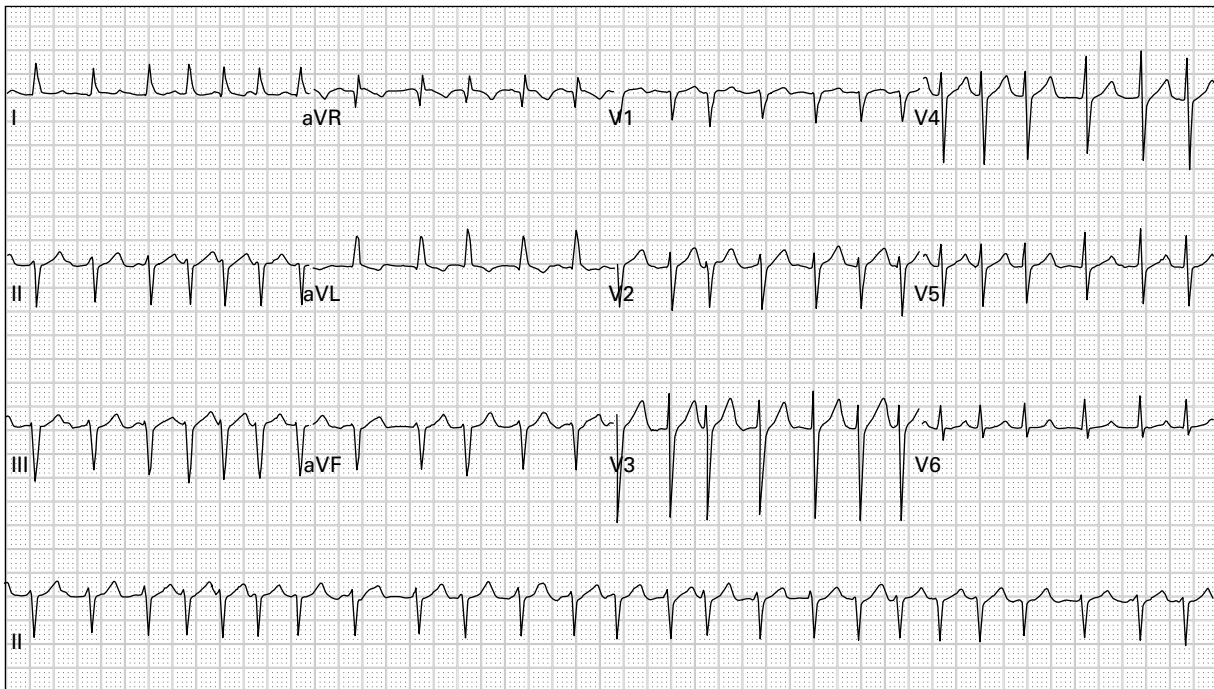
45. 46 year old man with chest and left arm pain, vomiting, and diaphoresis



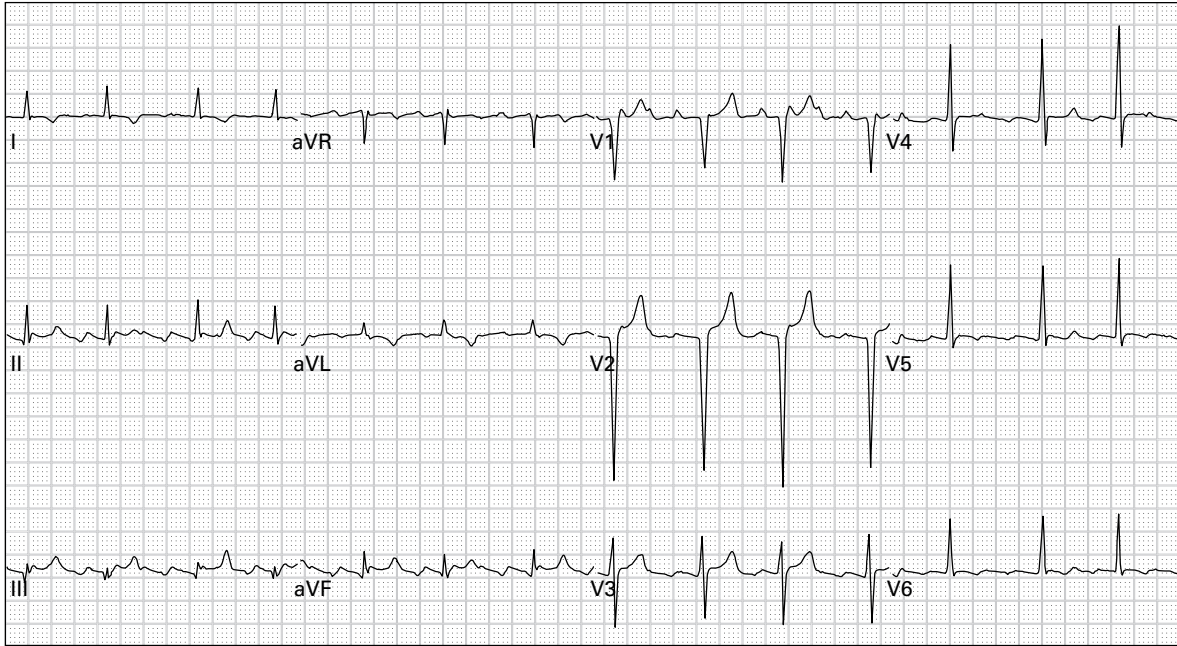
46. 53 year old diabetic woman with four days of nausea, vomiting, and lightheadedness



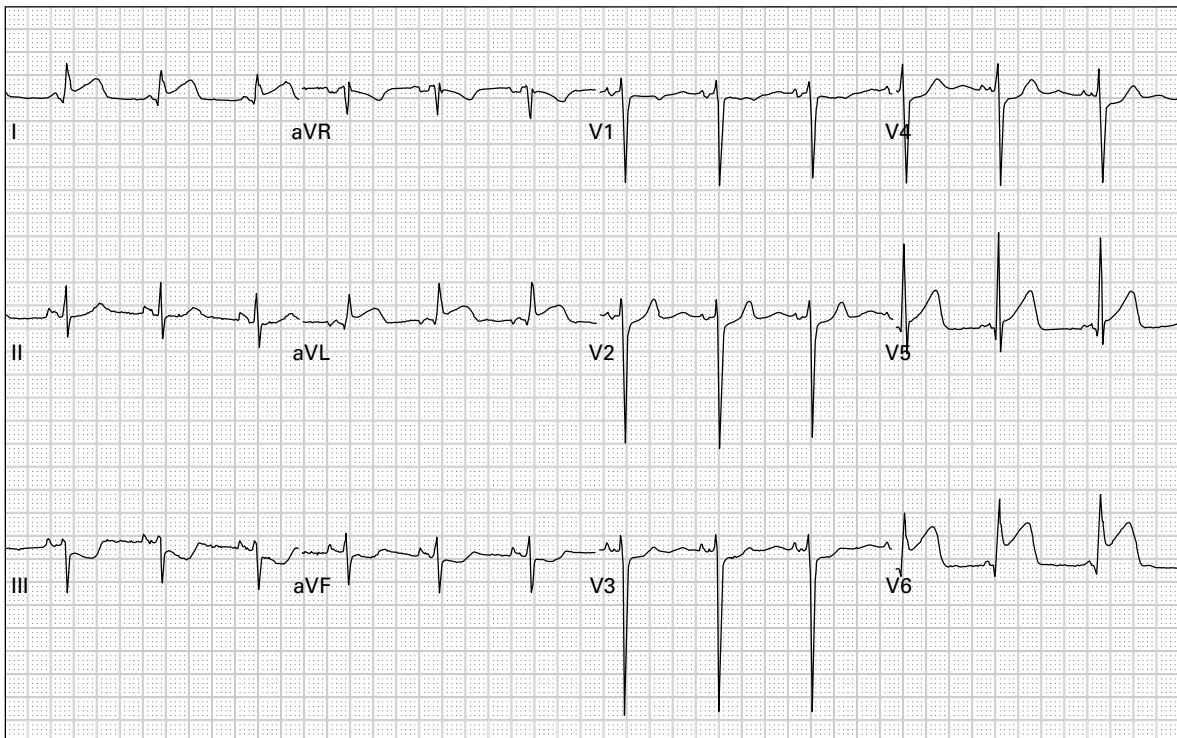
47. 85 year old woman with chest pain



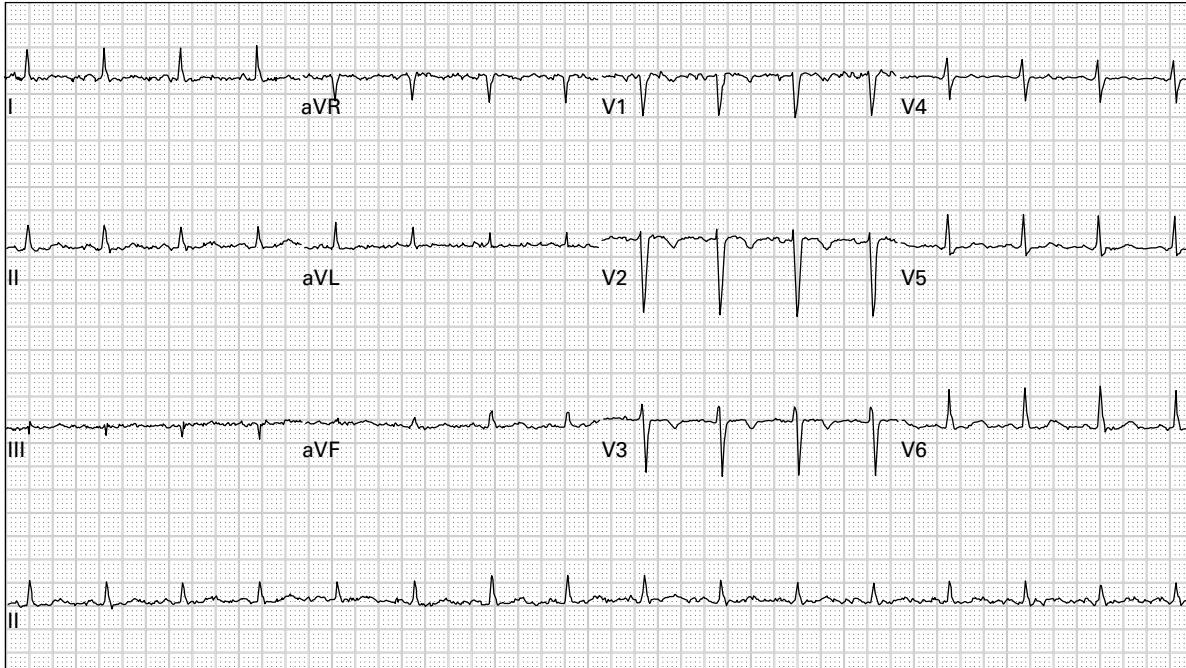
48. 66 year old man with severe lightheadedness and diaphoresis



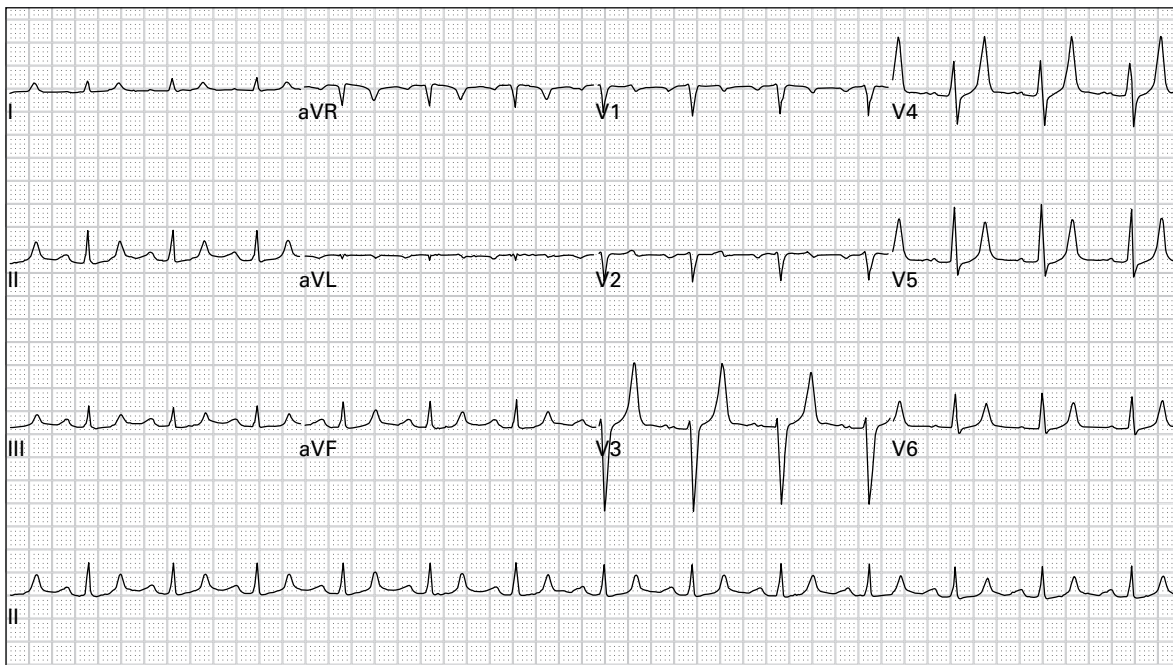
49. 58 year old man with congestive heart failure reports increasing dyspnea and lower extremity edema



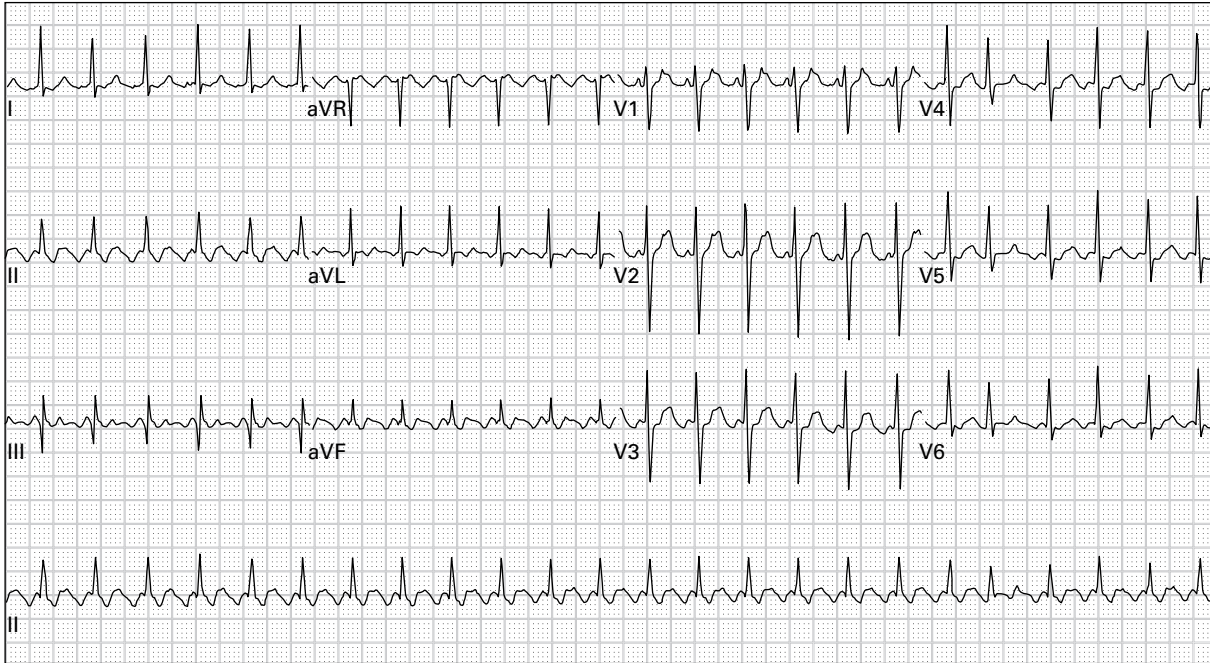
50. 43 year old man reports eight hours of left chest and arm pain



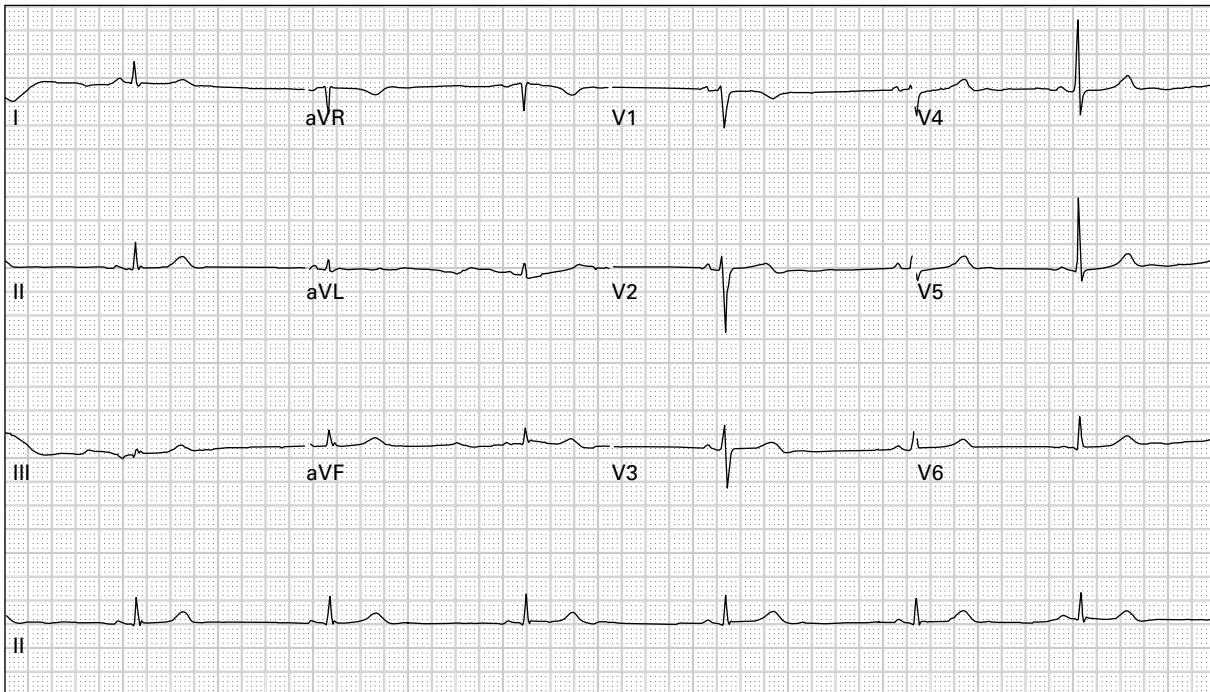
51. 52 year old woman with chest pain



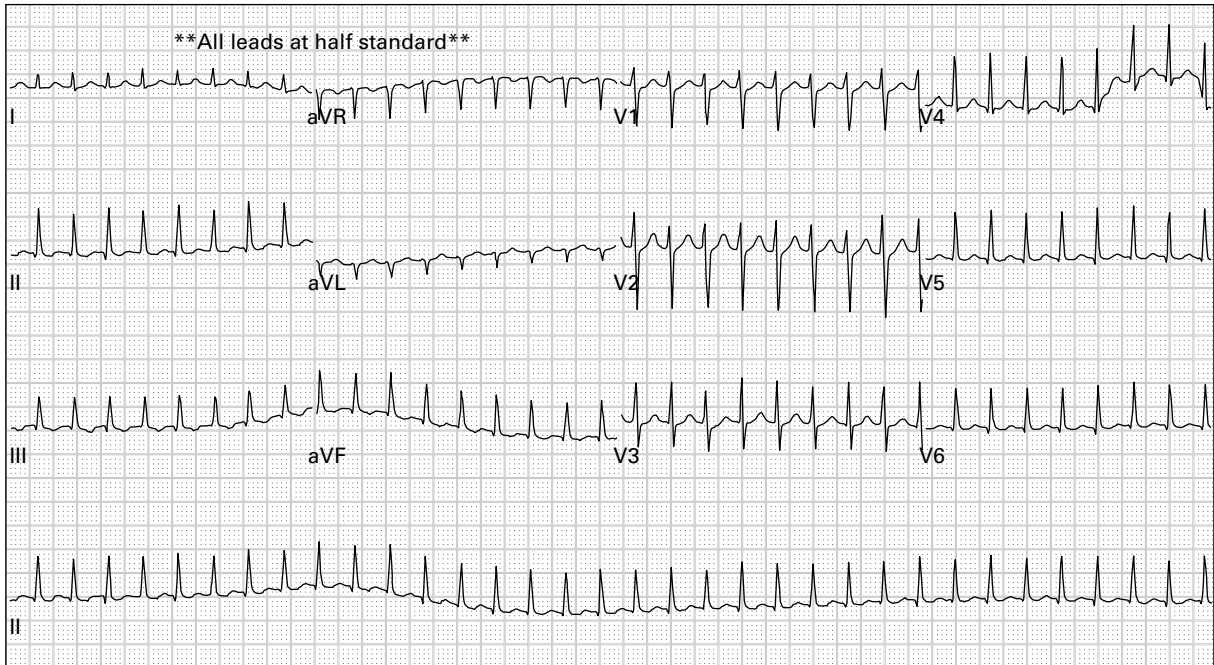
52. 62 year old man with renal failure complains of progressive dyspnea and orthopnea after missing his last two hemodialysis sessions



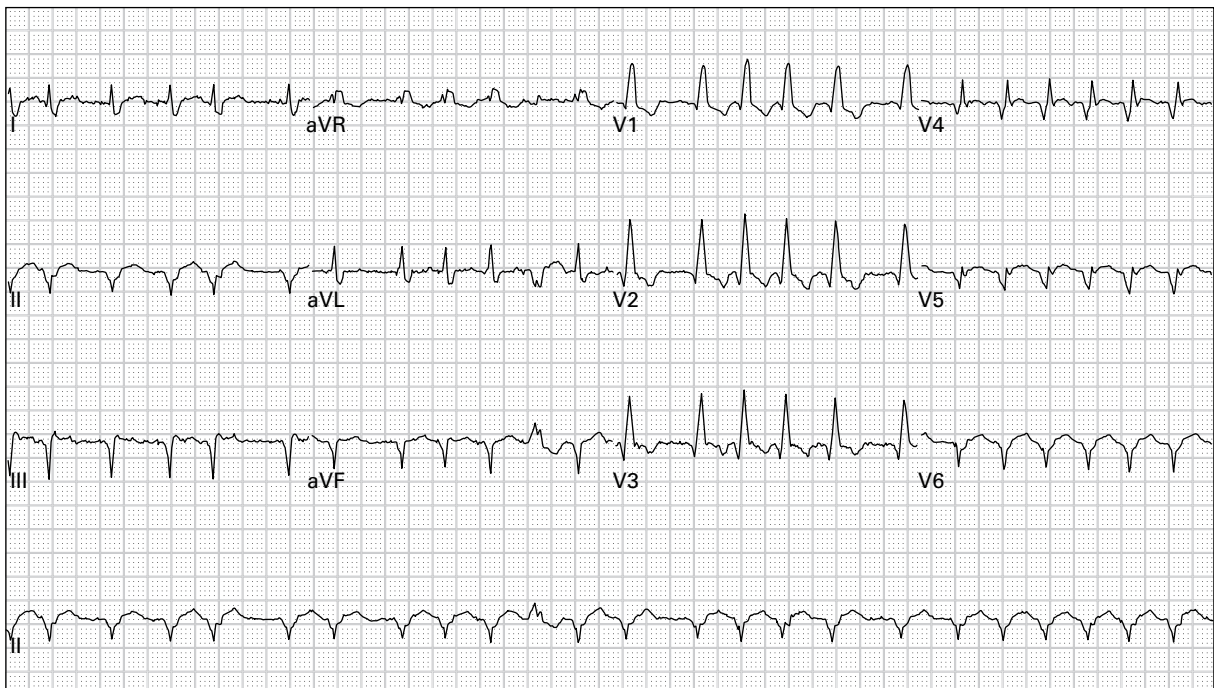
53. 47 year old man with palpitations and dyspnea



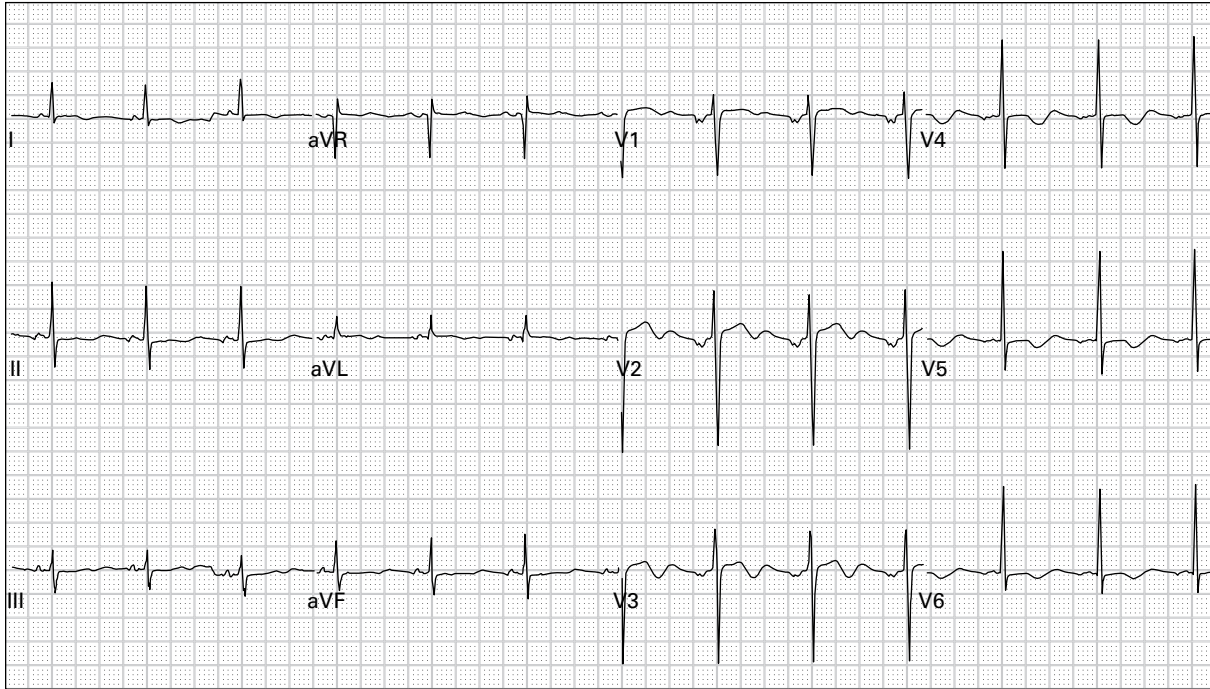
54. 48 year old woman presents after a clonidine overdose



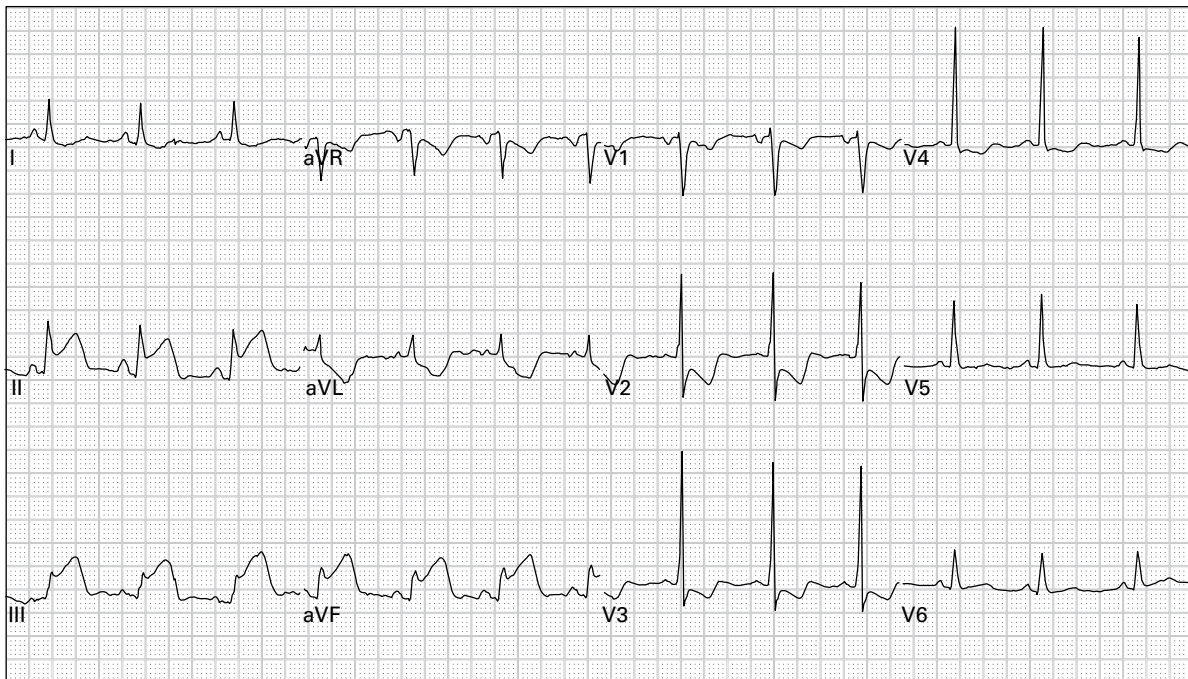
55. 23 year old man reports dyspnea and palpitations



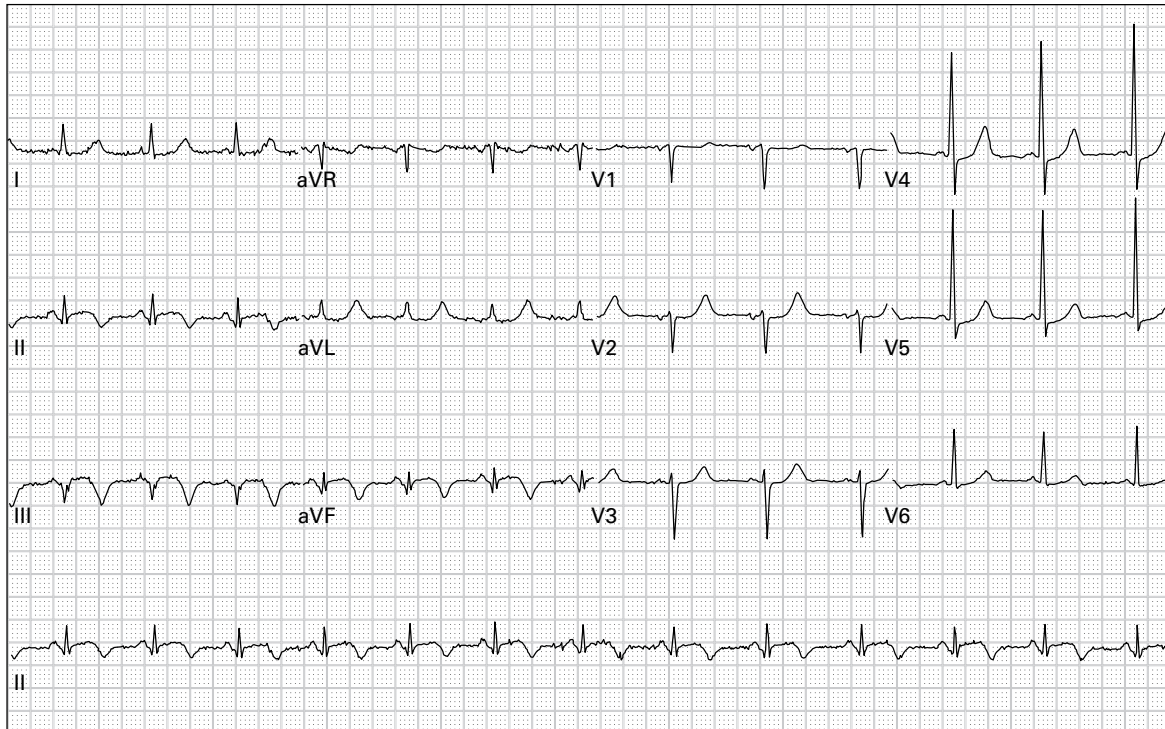
56. 57 year old man reports generalized weakness and palpitations



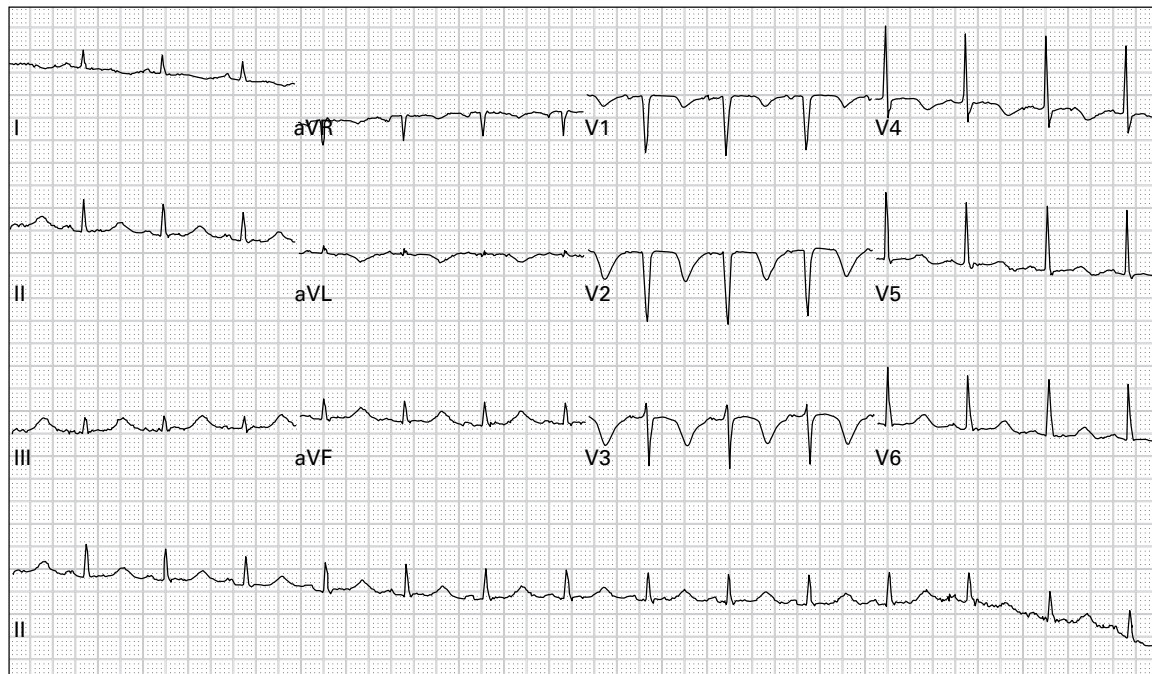
57. 54 year old man with five days of anorexia, nausea, and vomiting



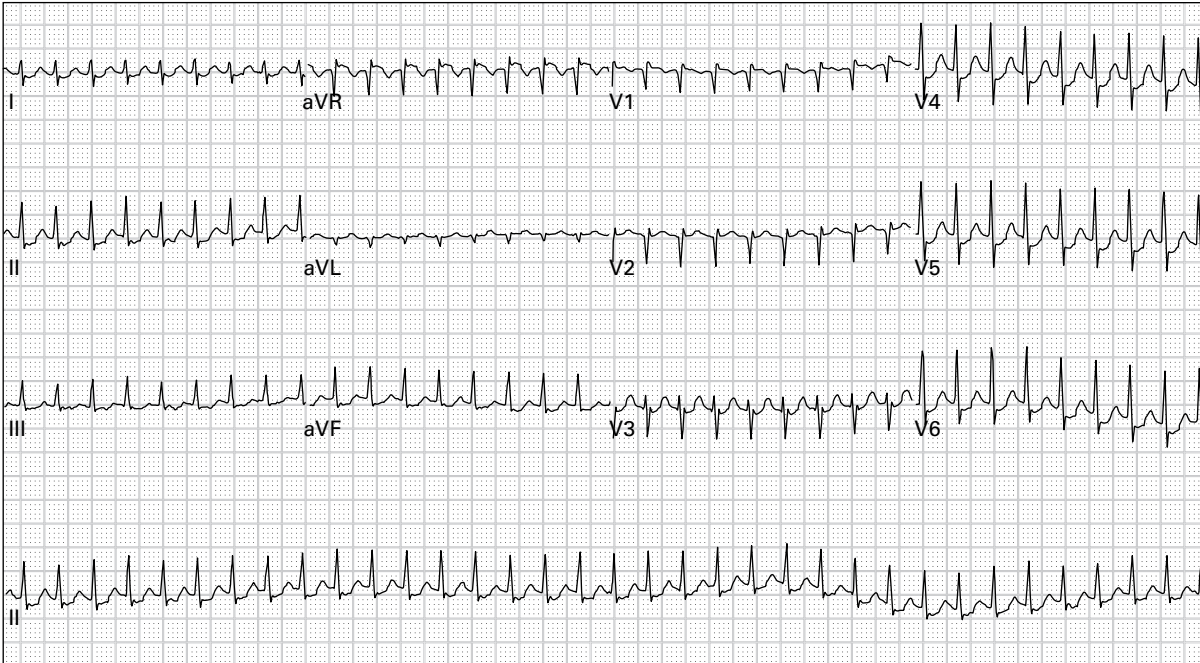
58. 66 year old woman with epigastric pain, nausea, dyspnea, and diaphoresis



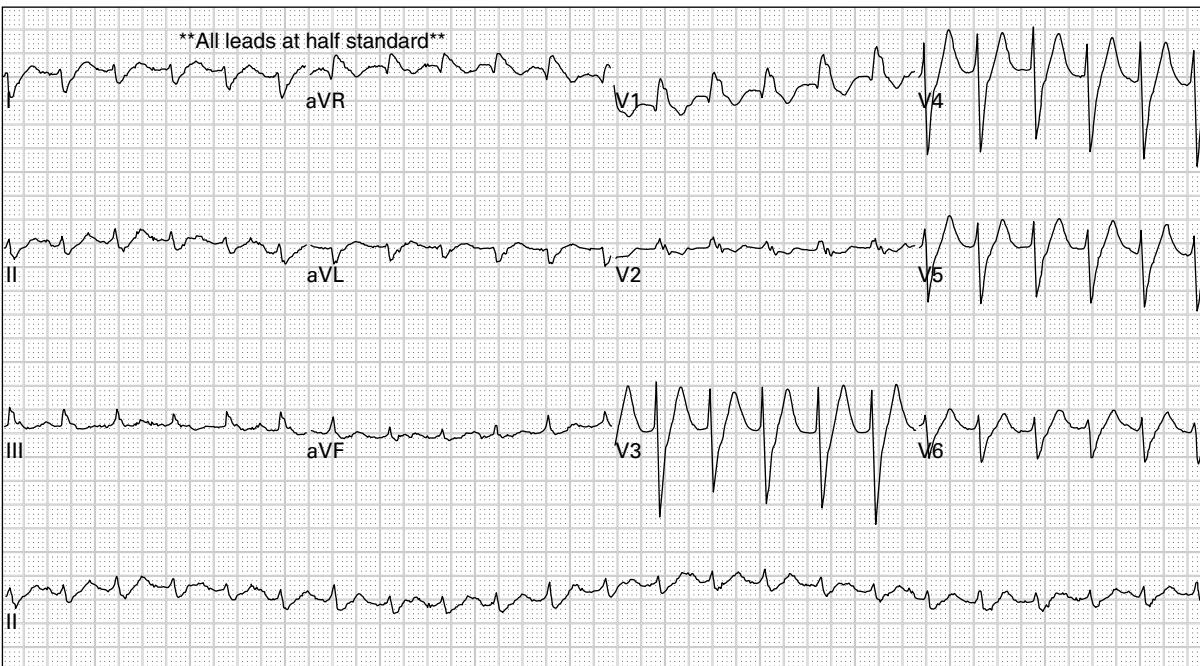
59. 70 year old woman with nine hours of chest pain and dyspnea



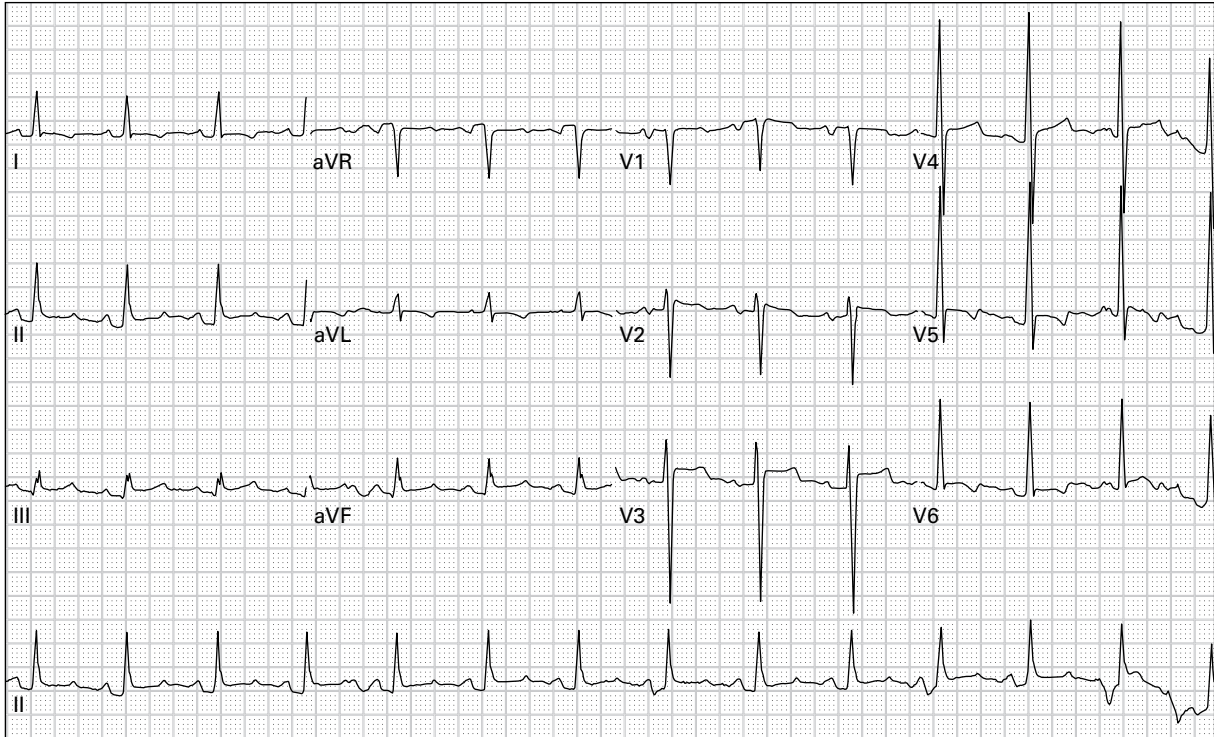
60. 52 year old alcoholic woman presents with frequent vomiting



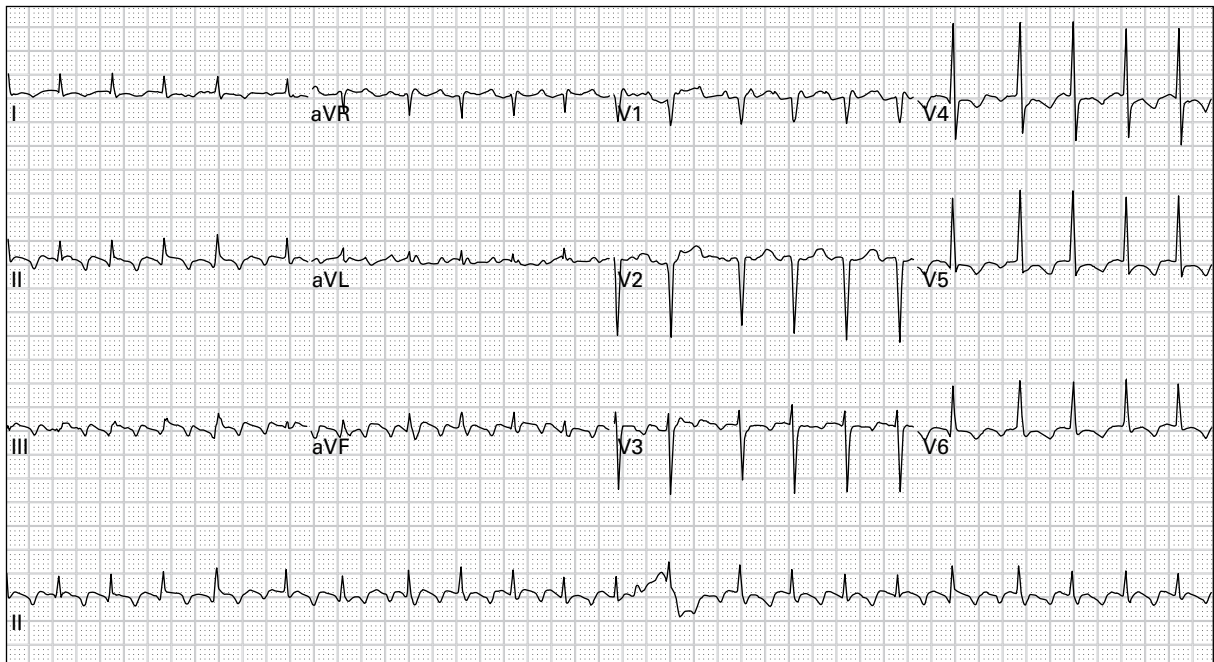
61. 45 year old woman with palpitations and lightheadedness



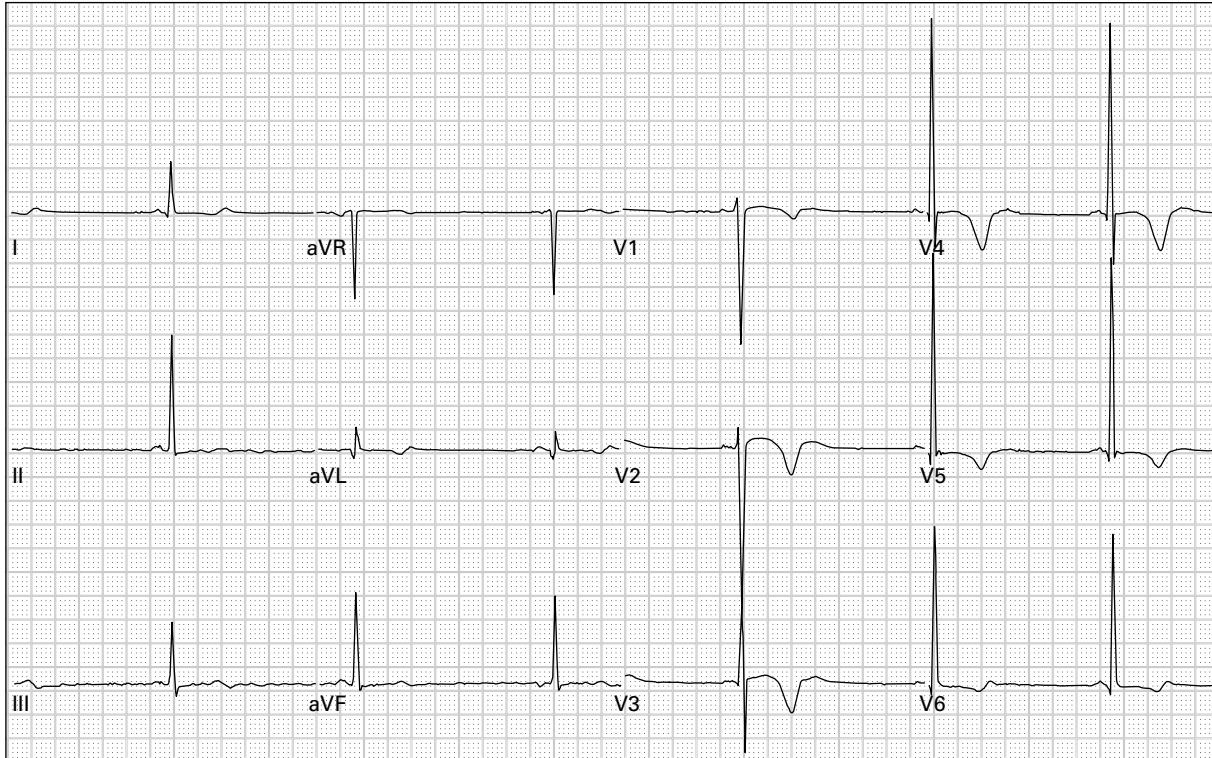
62. 45 year old man with severe lightheadedness



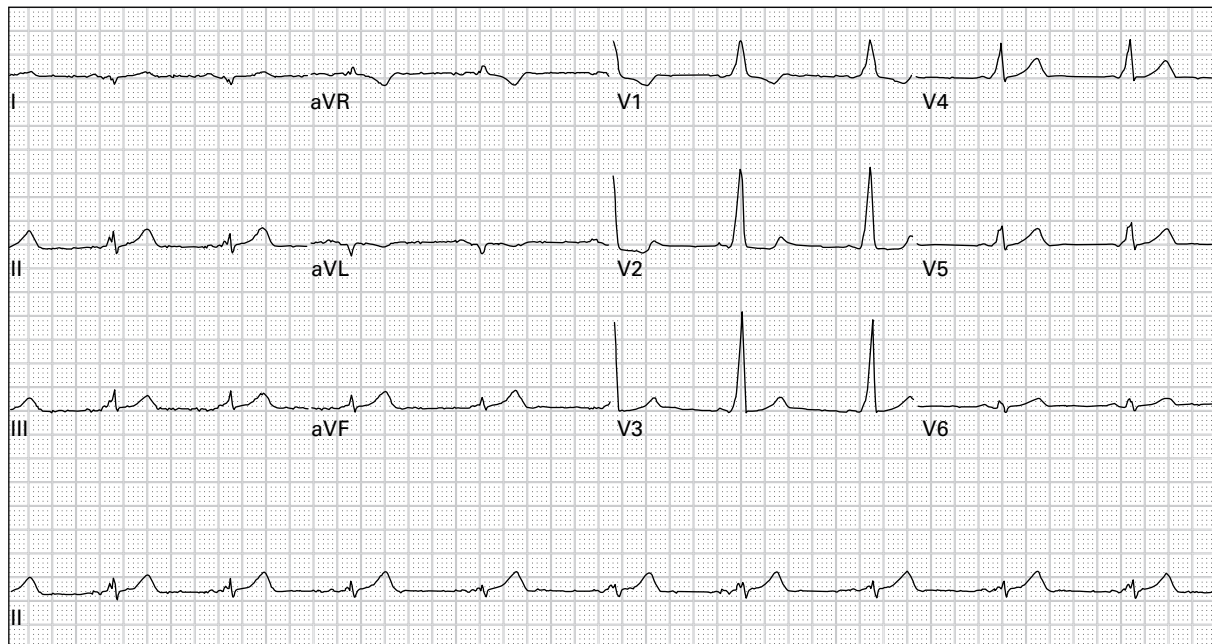
63. 52 year old man with sharp, pleuritic chest pain



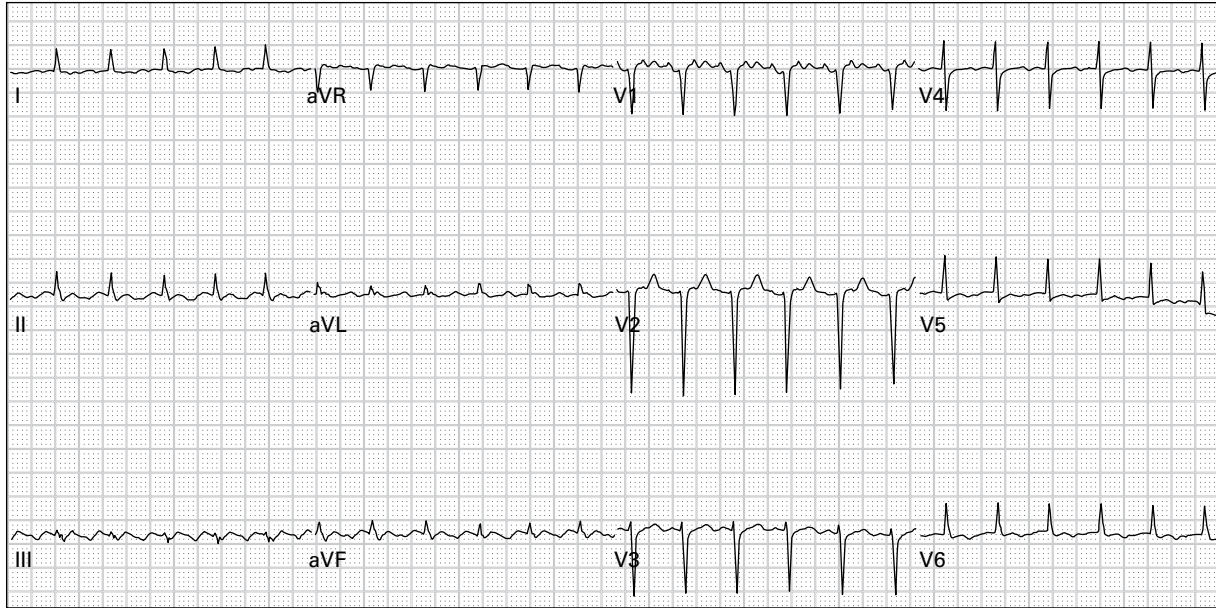
64. 71 year old woman with generalized weakness



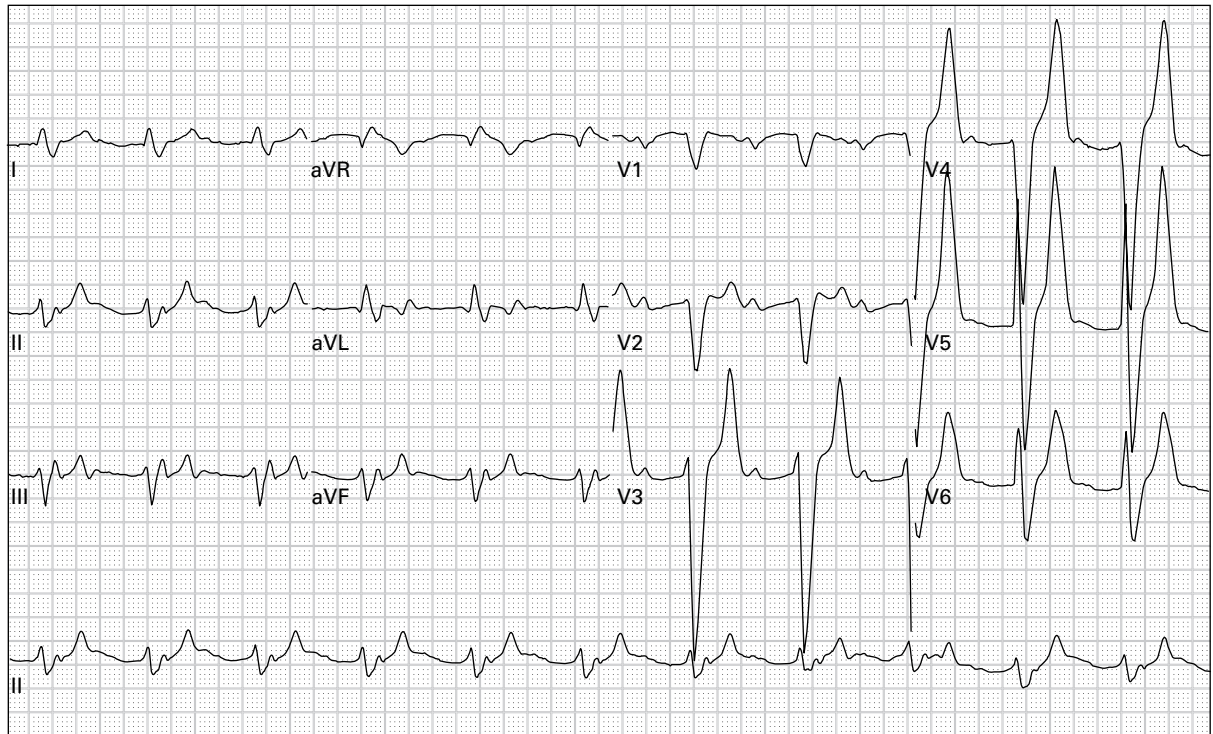
65. 34 year old woman presents unconscious with respiratory depression and pinpoint pupils



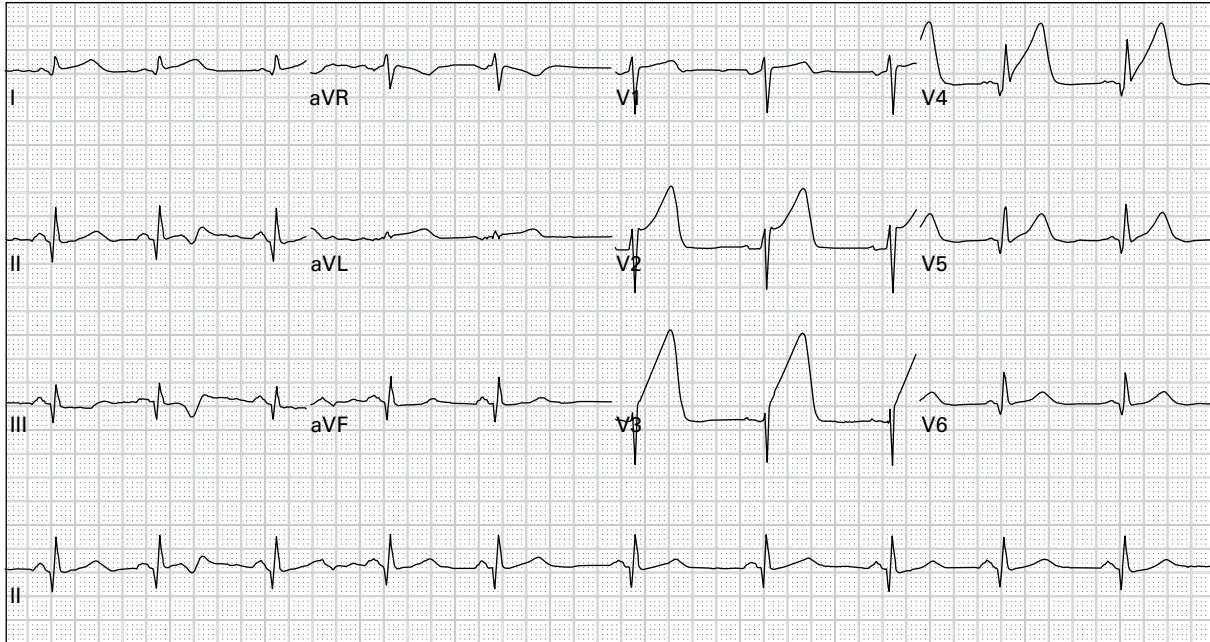
66. 36 year old woman has had intermittent episodes of palpitations and lightheadedness



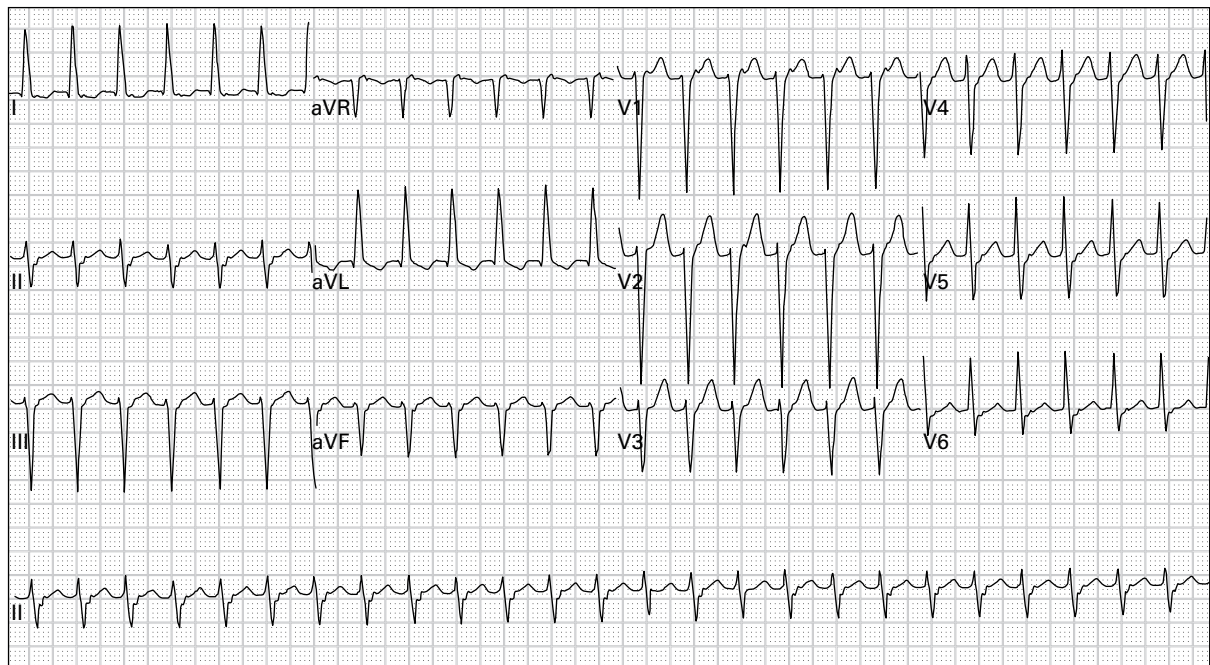
67. 70 year old woman with chest discomfort and generalized weakness



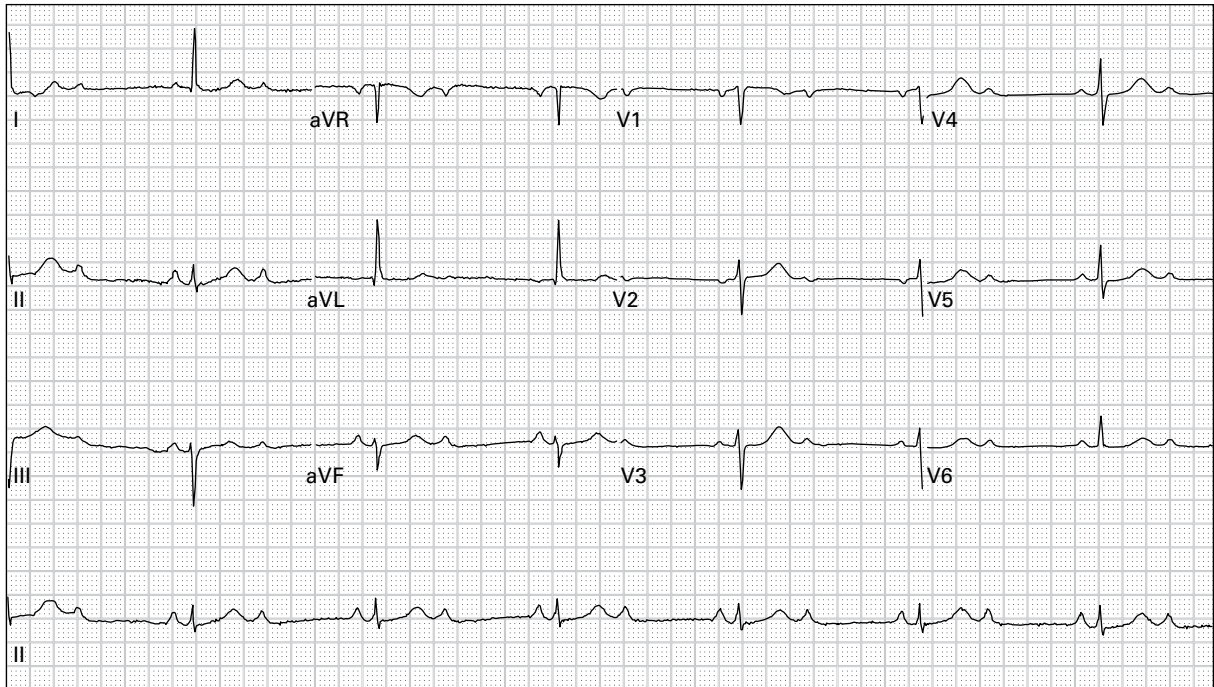
68. 41 year old man with end-stage renal failure presents with generalized weakness after missing his last three hemodialysis sessions



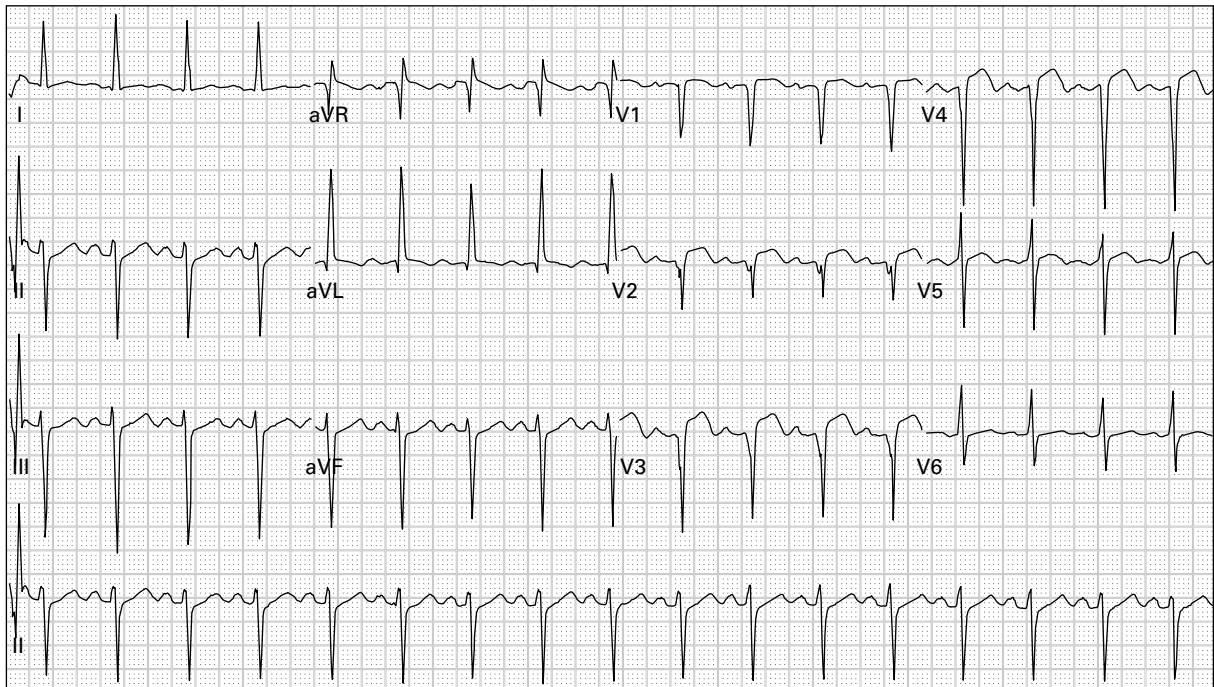
69. 45 year old woman with left chest and arm pain and dyspnea



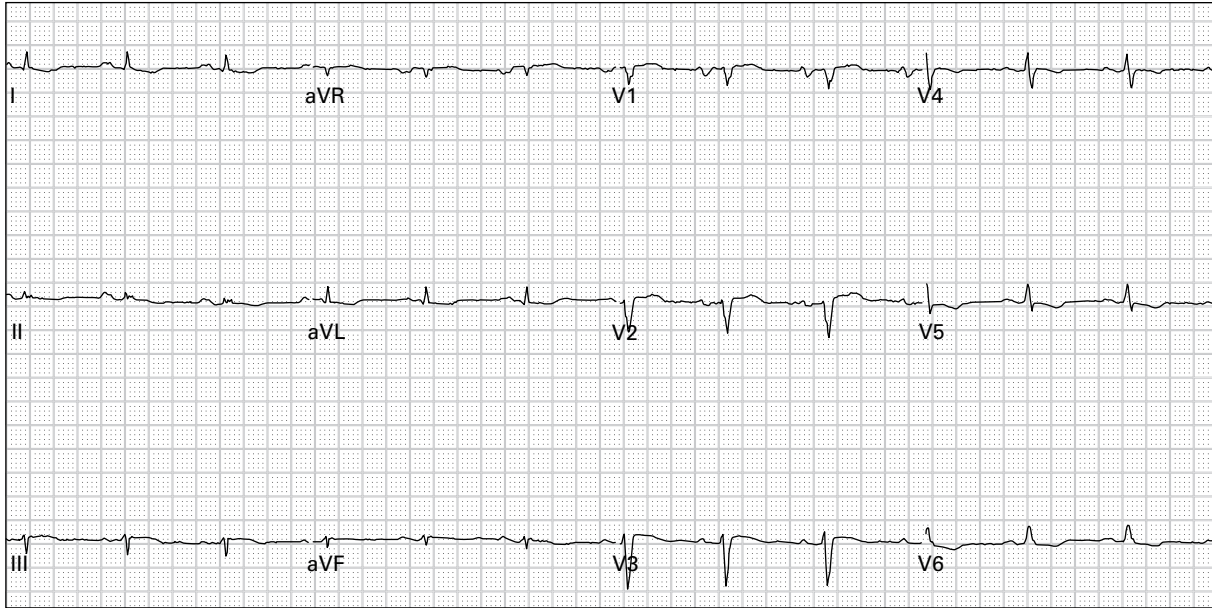
70. 78 year old woman with dyspnea and nausea



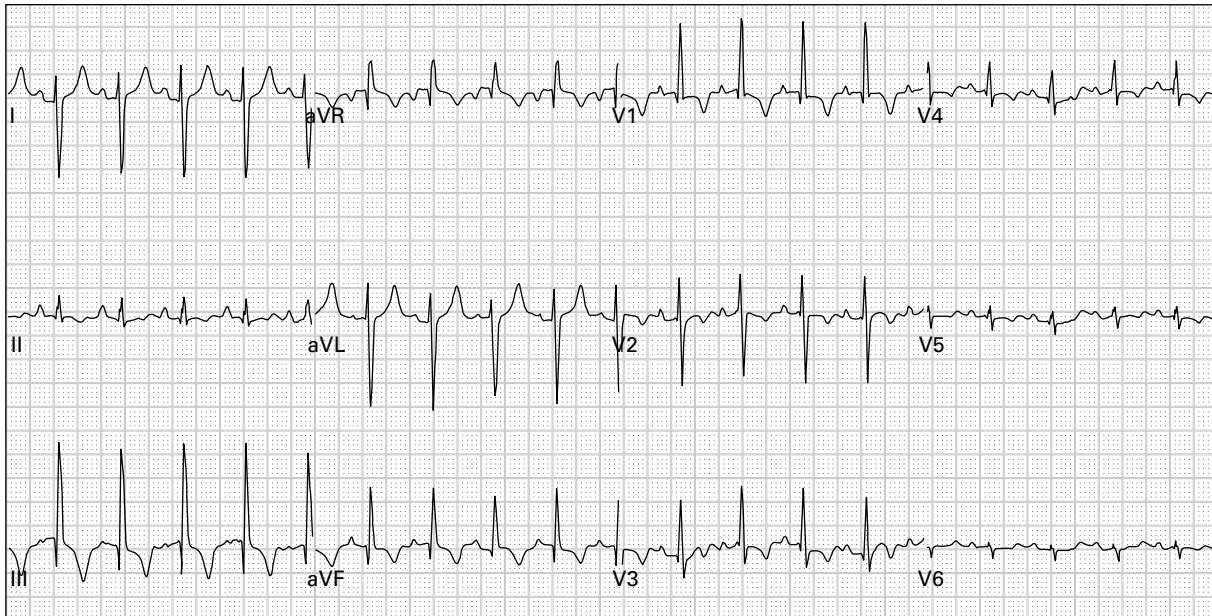
71. 75 year old woman presents after a syncopal episode



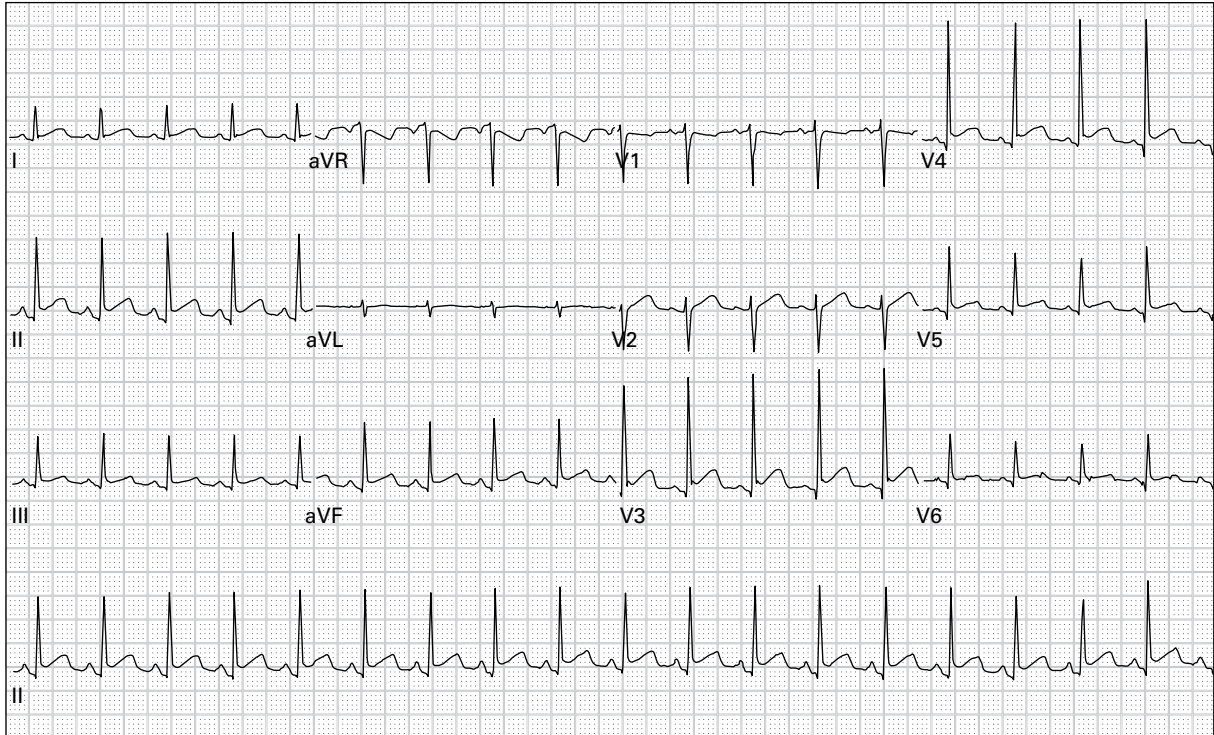
72. 50 year old woman with chest pain and diaphoresis for five hours



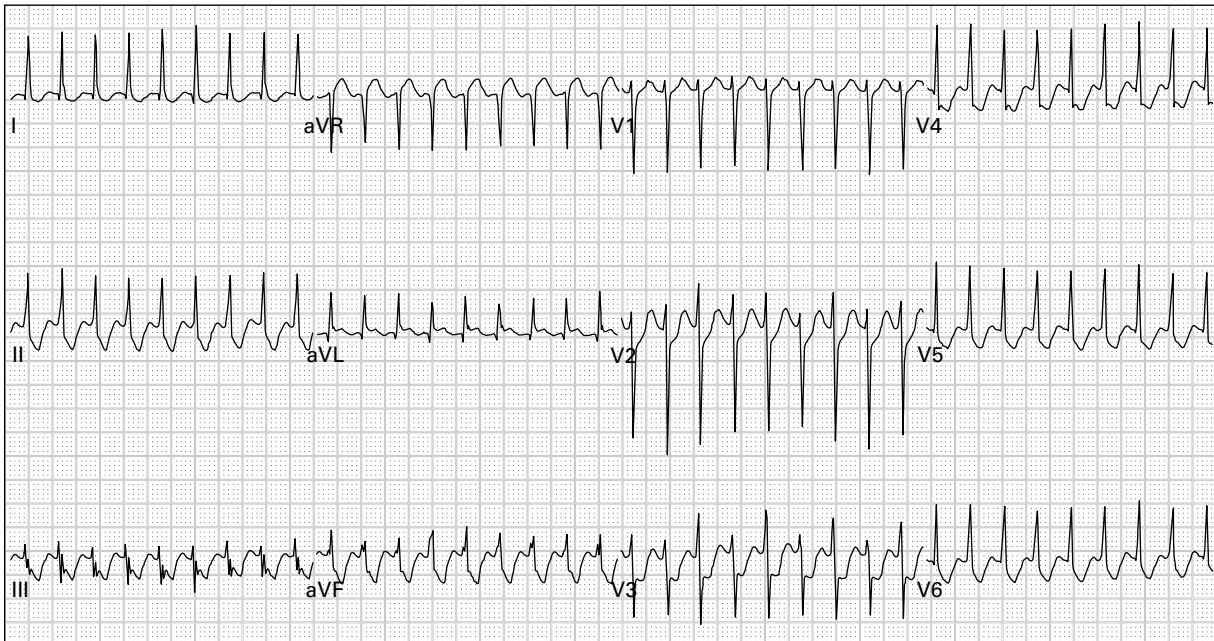
73. 59 year old man presents with dyspnea, cough, and hypoxia



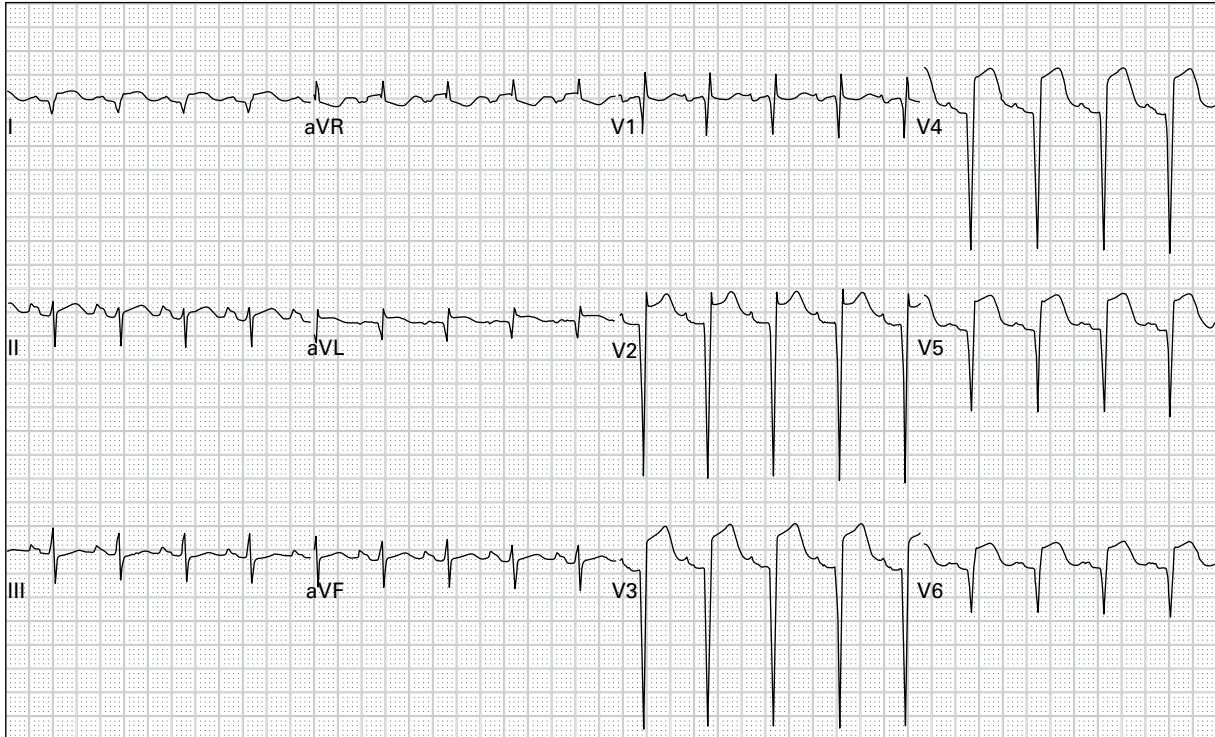
74. 62 year old woman with chest pain and severe dyspnea gradually worsening for three days



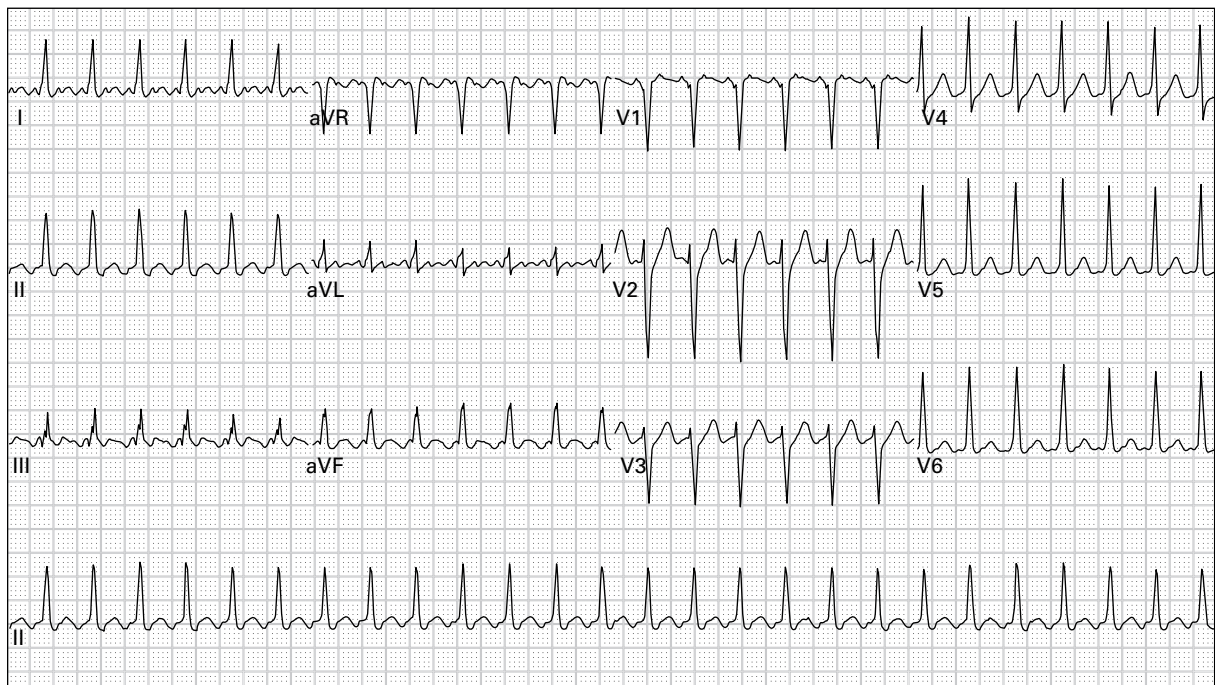
75. 40 year old man with sharp left-sided chest pain and dyspnea



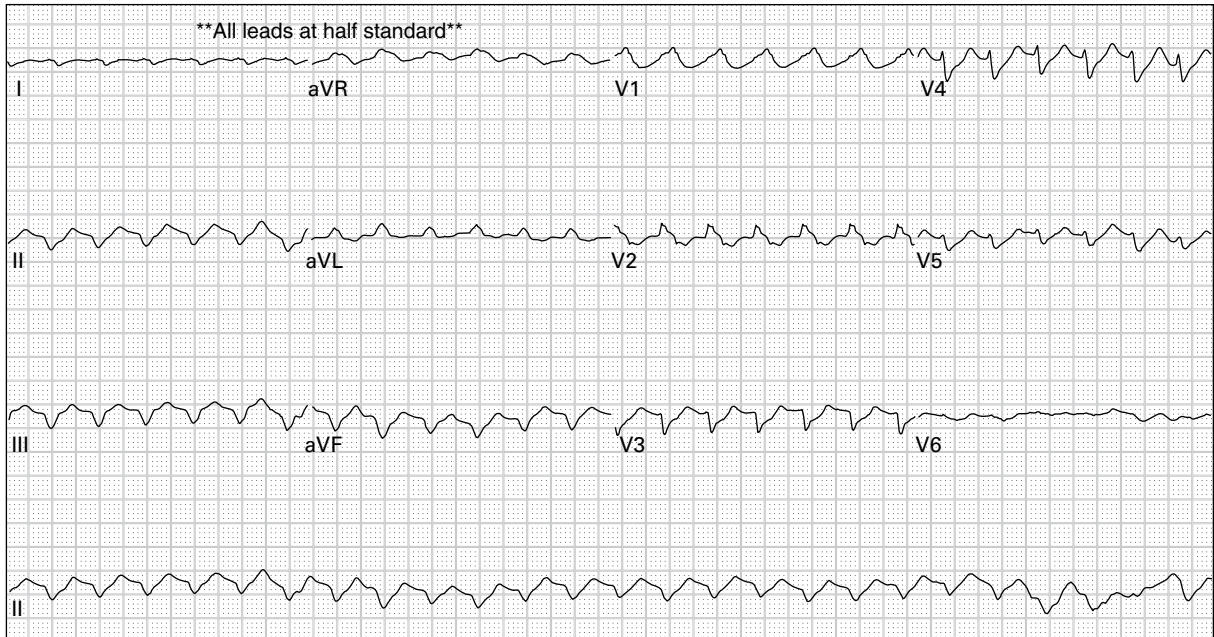
76. 28 year old woman with palpitations and chest pain



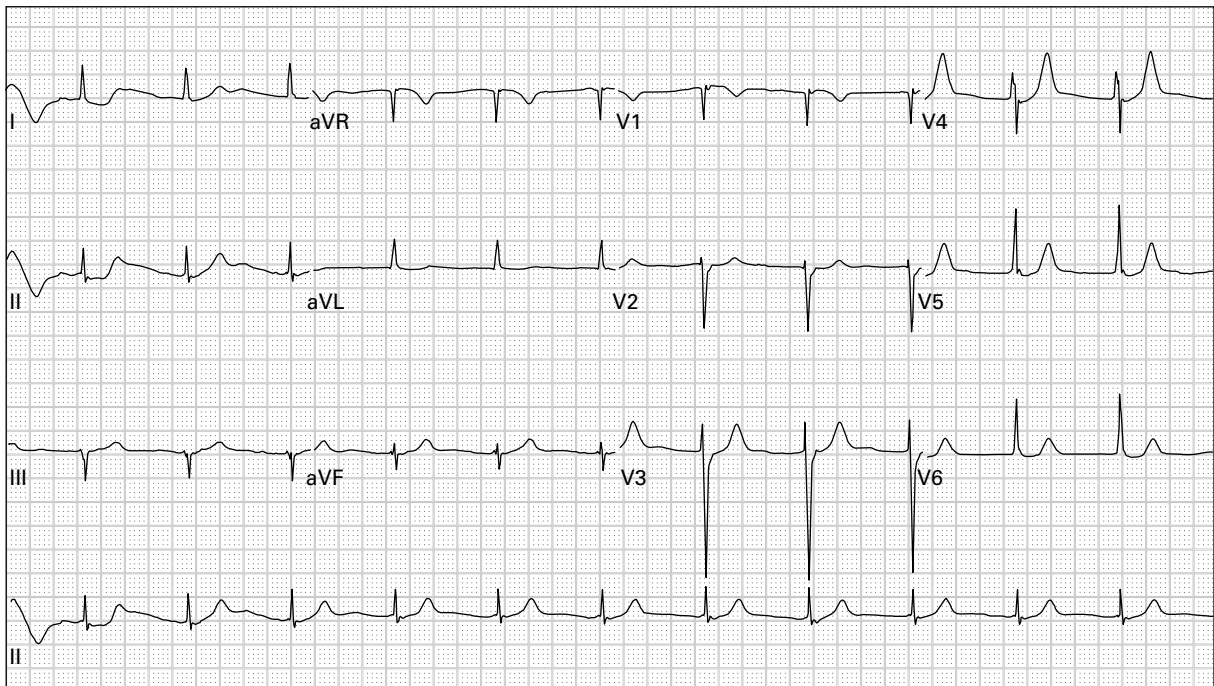
77. 53 year old man with left arm "squeezing sensation" and nausea for eight hours



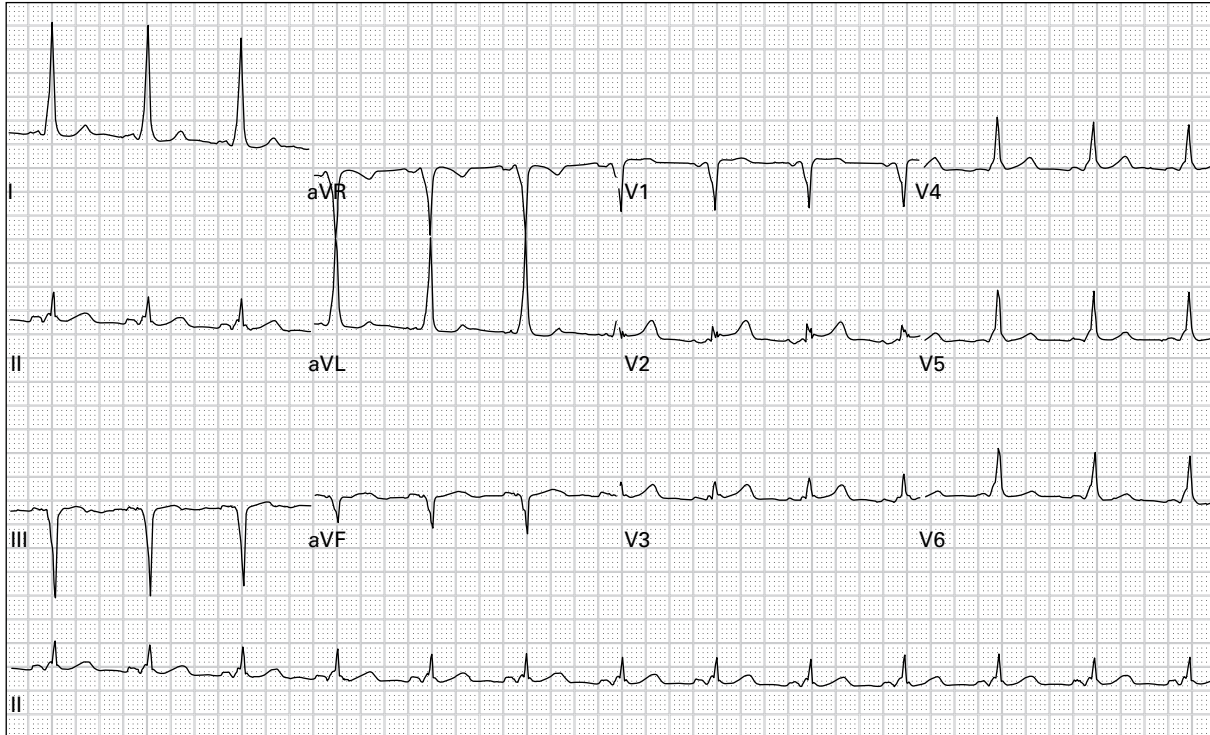
78. 69 year old woman with severe nausea and dyspnea



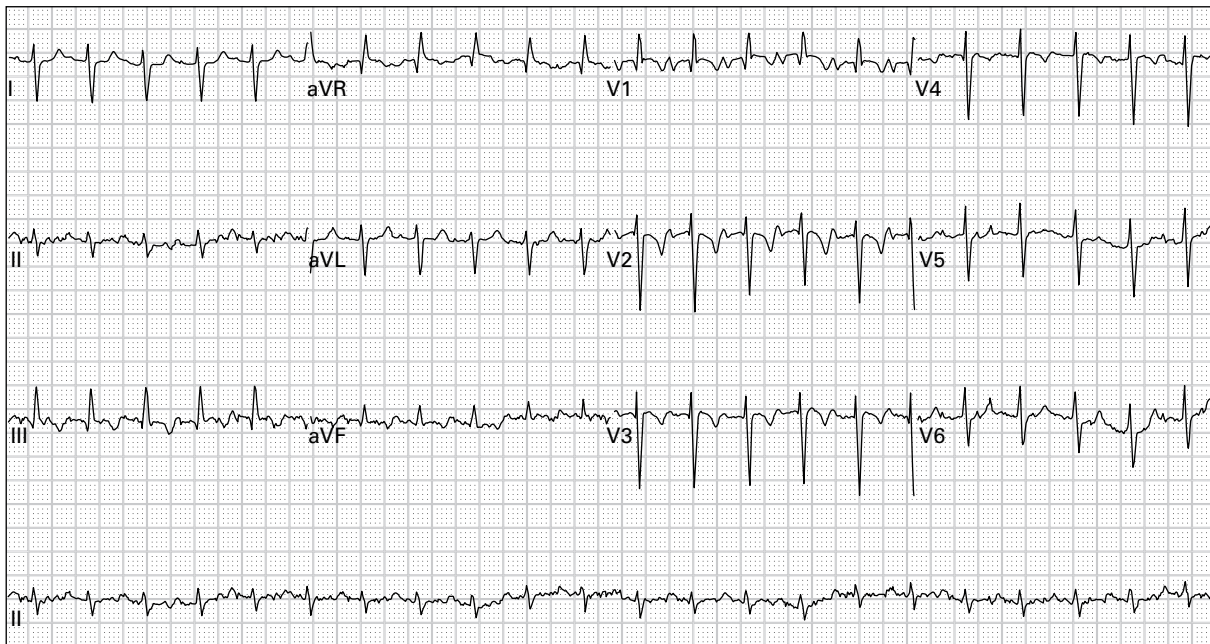
79. 68 year old man presents unconscious with blood pressure 108/60



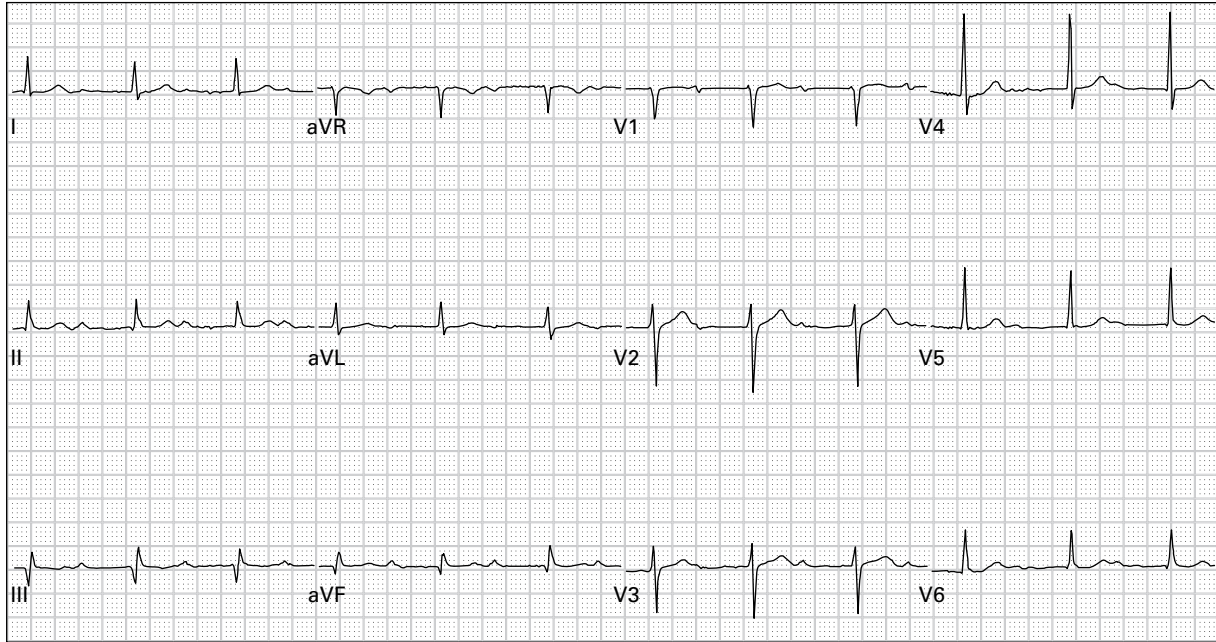
80. 65 year old woman with "funny feeling in chest"



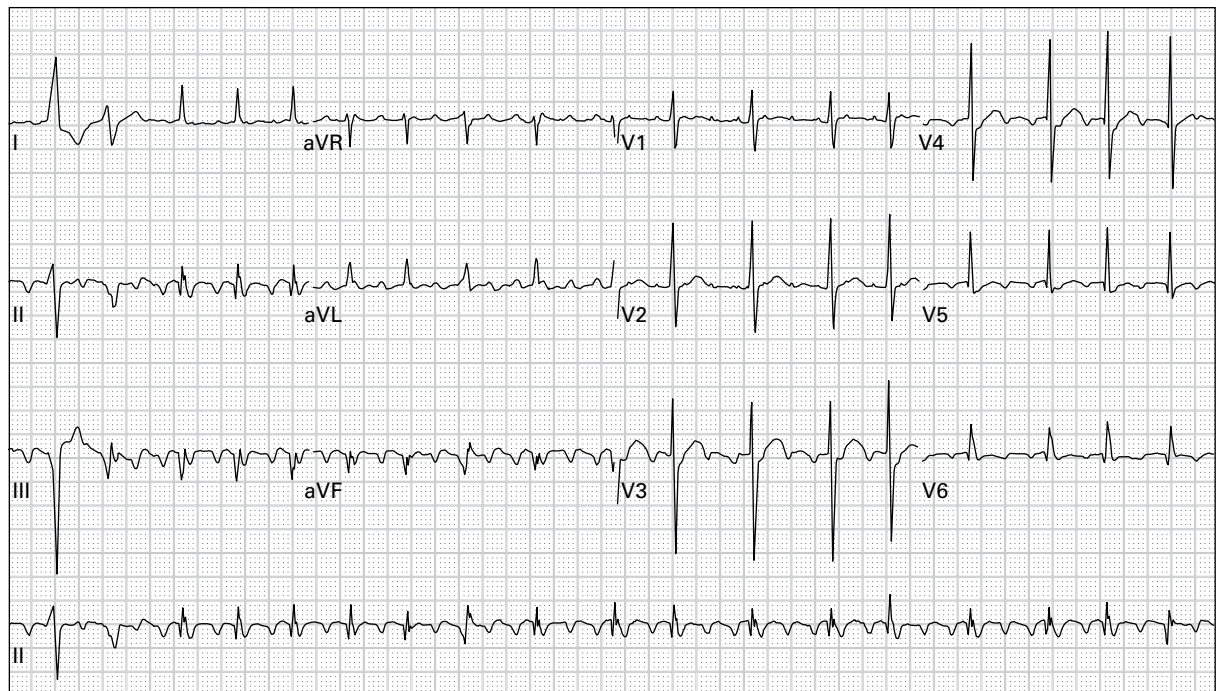
81. 55 year old woman with occasional syncopal episodes and a recent episode of palpitations



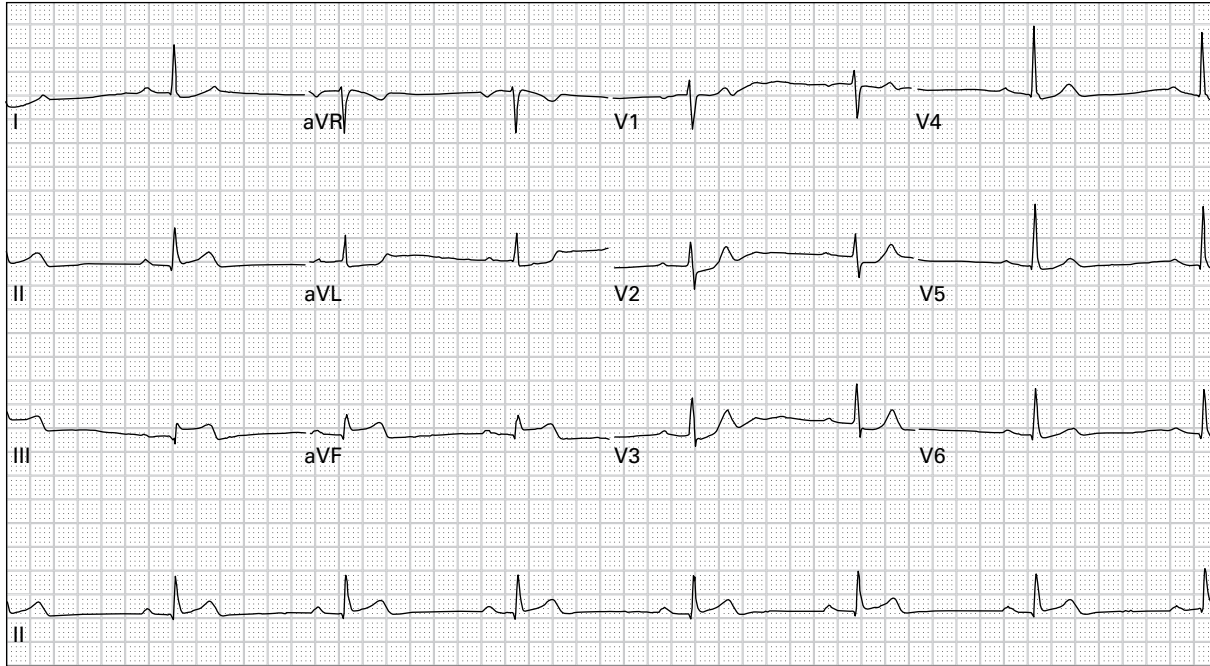
82. 69 year old man with dyspnea and diaphoresis



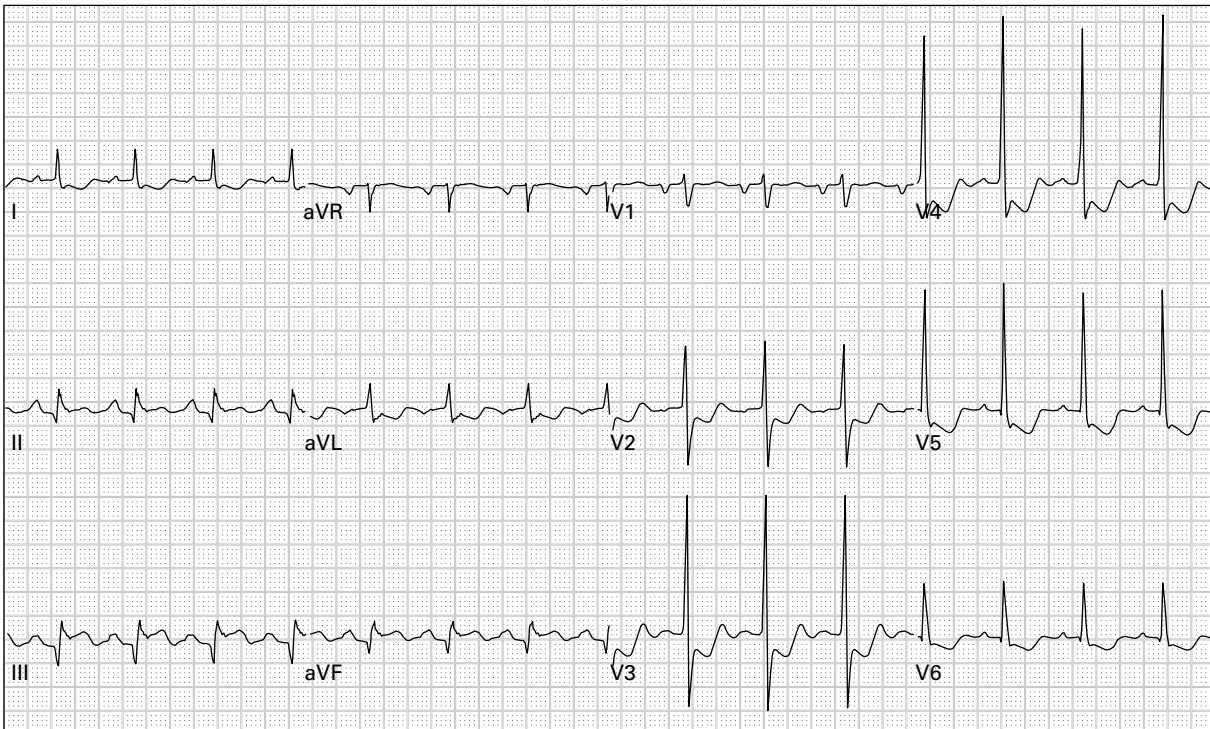
83. 79 year old man with abdominal pain



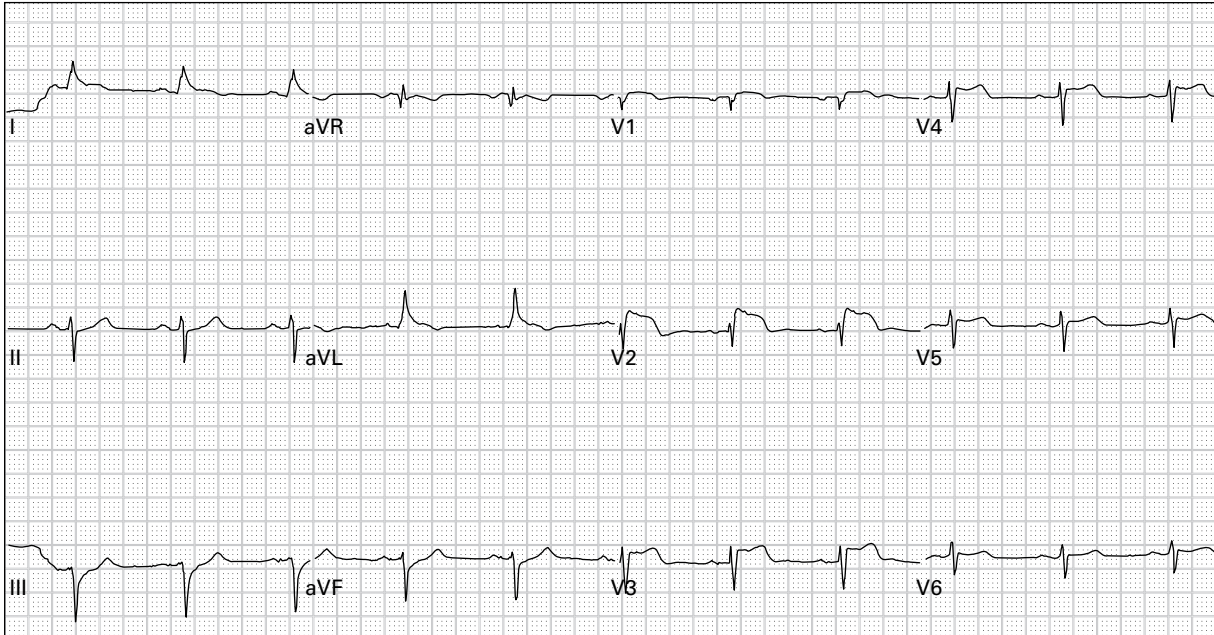
84. 85 year old man with palpitations and fatigue



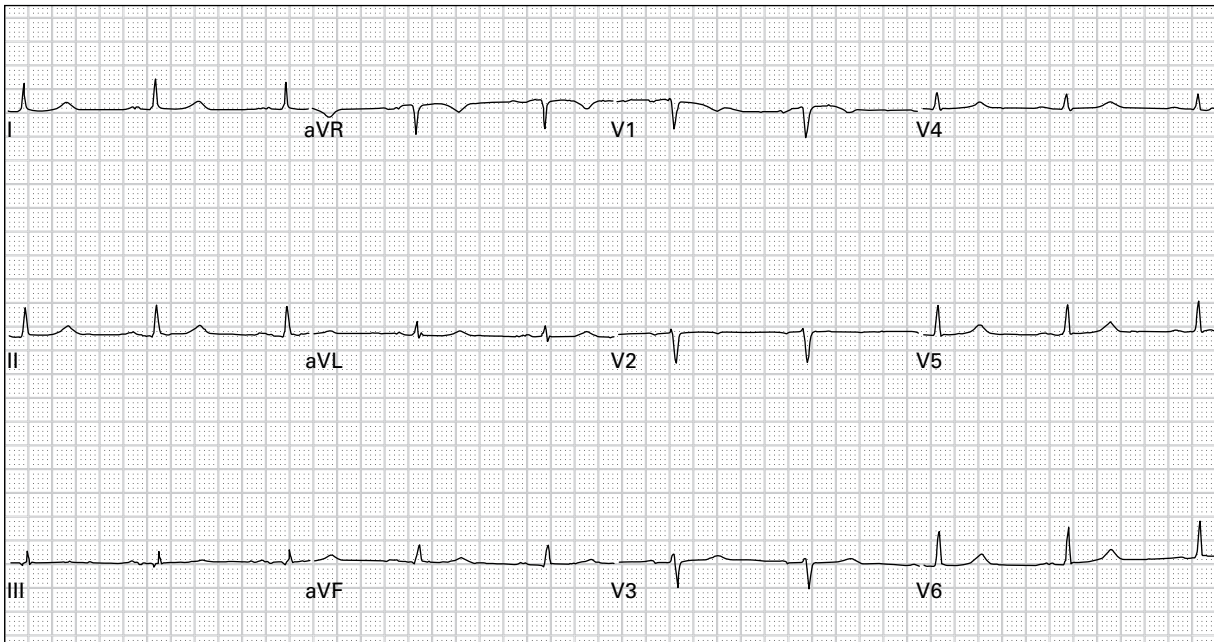
85. 63 year old man with epigastric burning, belching, diaphoresis, and lightheadedness



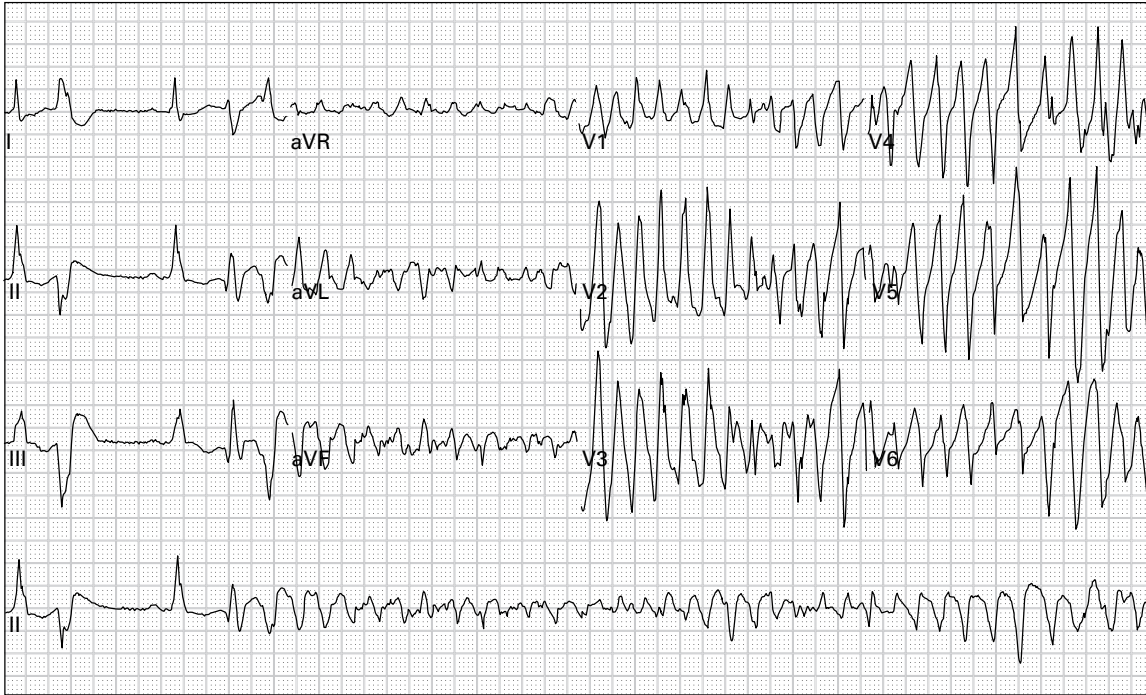
86. 70 year old man with dyspnea and generalized weakness



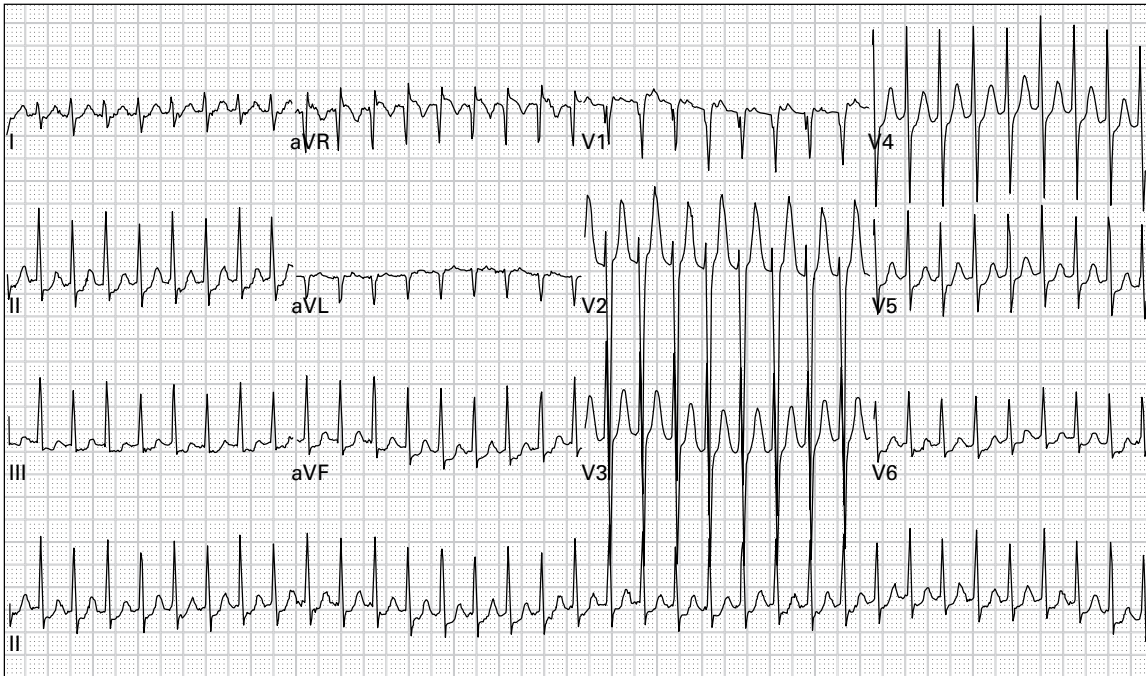
87. 70 year old woman with nausea, vomiting, and diaphoresis



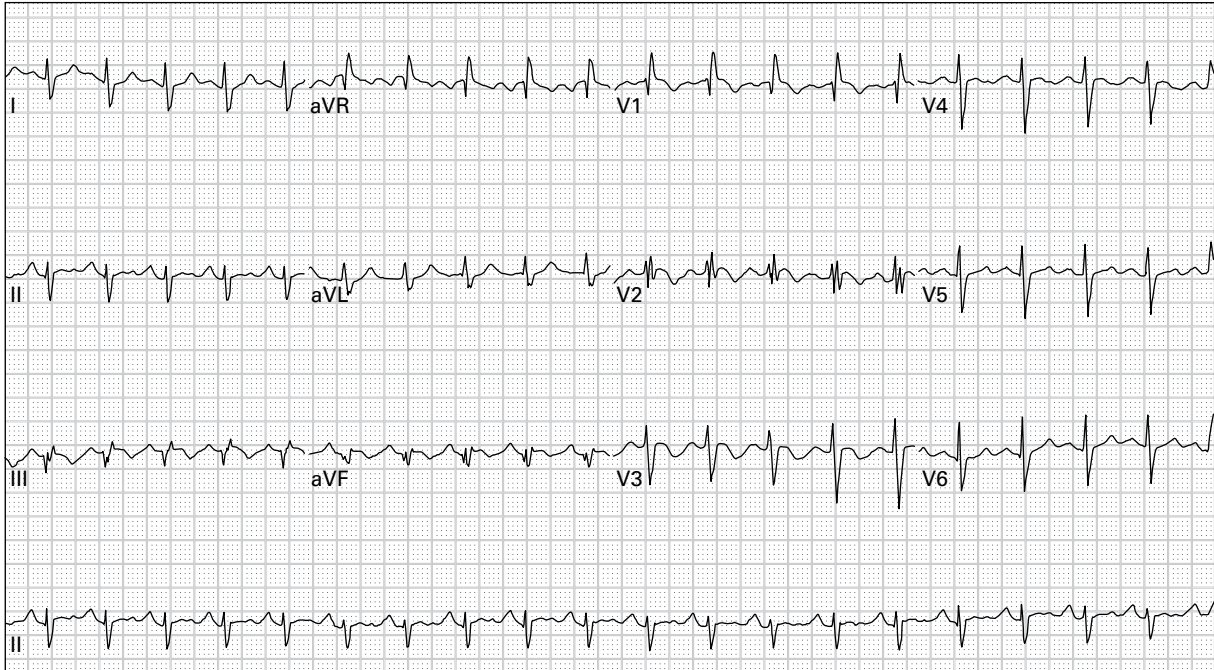
88. 55 year old morbidly obese woman with generalized abdominal pain



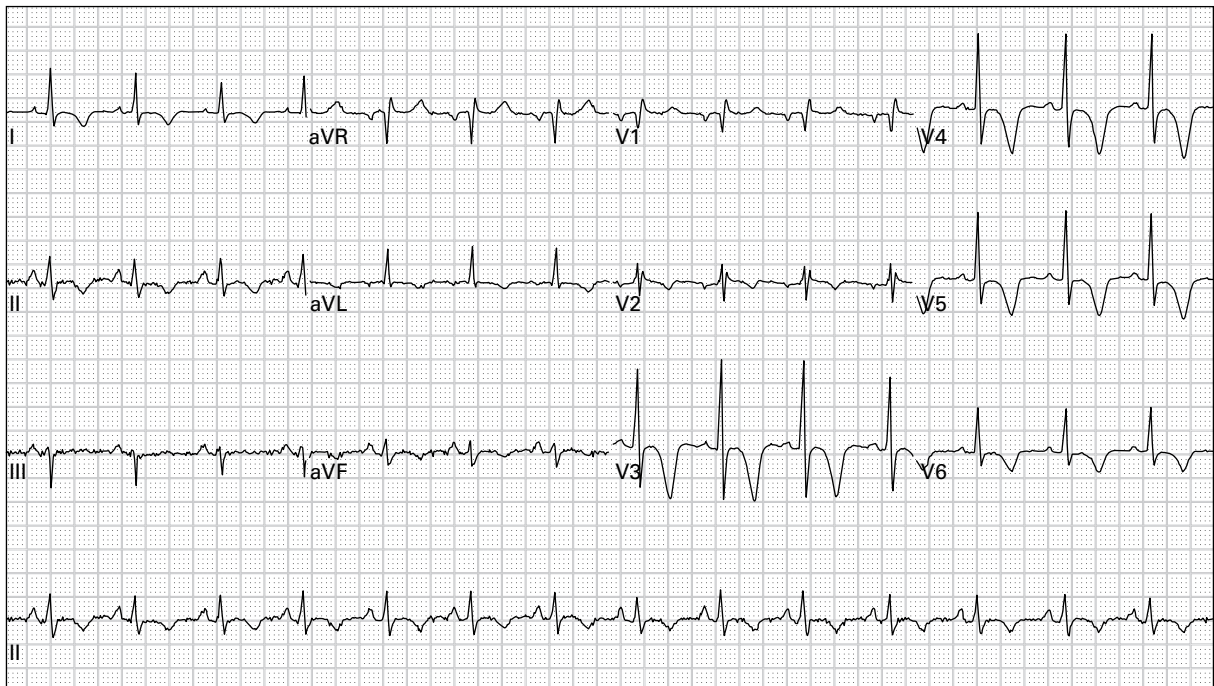
89. 44 year old chronic alcoholic with persistent vomiting; becomes unresponsive during the ECG



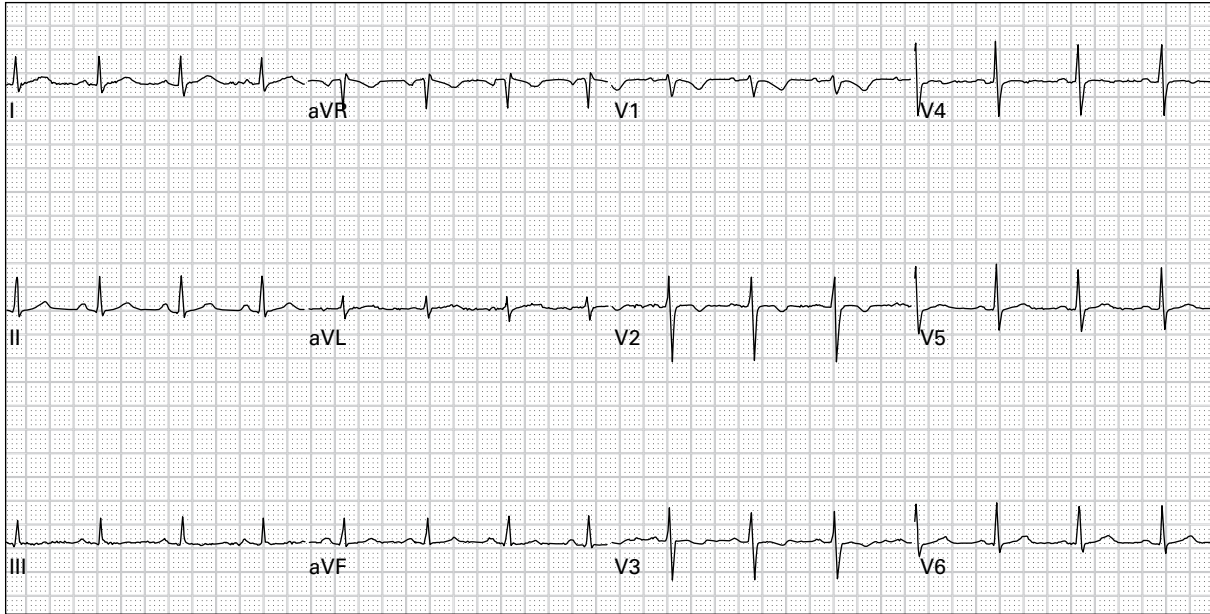
90. 25 year old woman with palpitations and lightheadedness



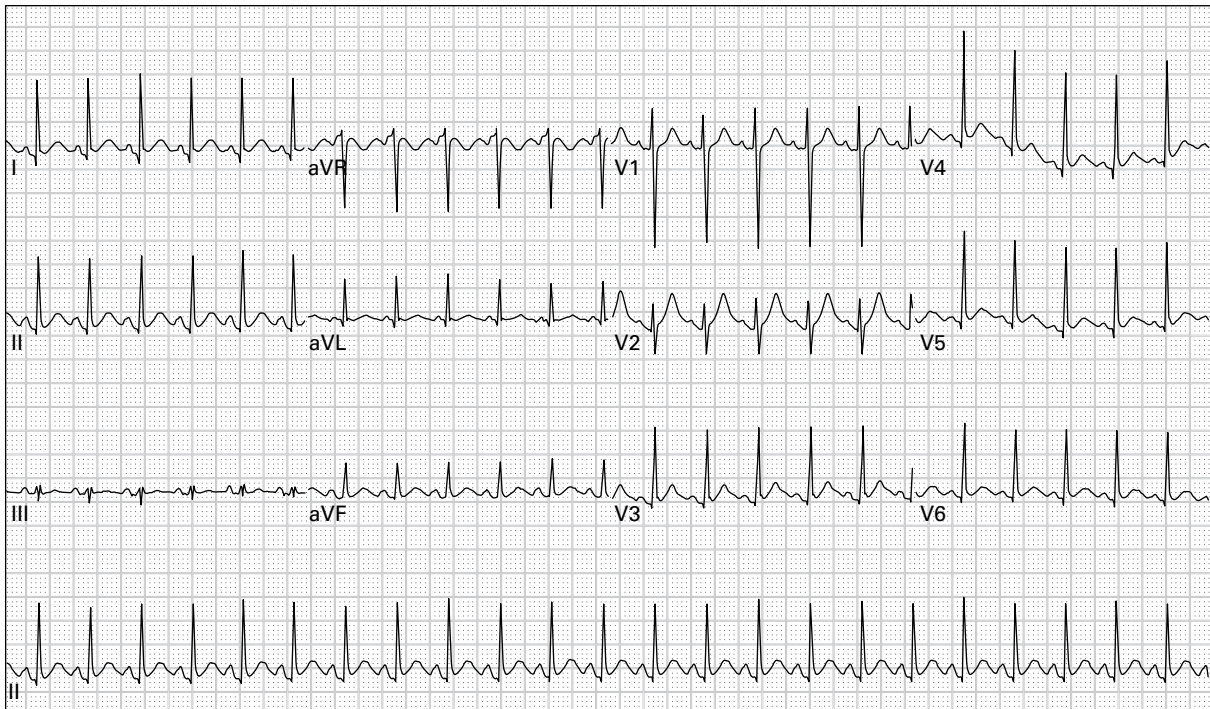
91. 28 year old woman eight weeks pregnant presents with chest pain, dyspnea, and blood pressure 80/40



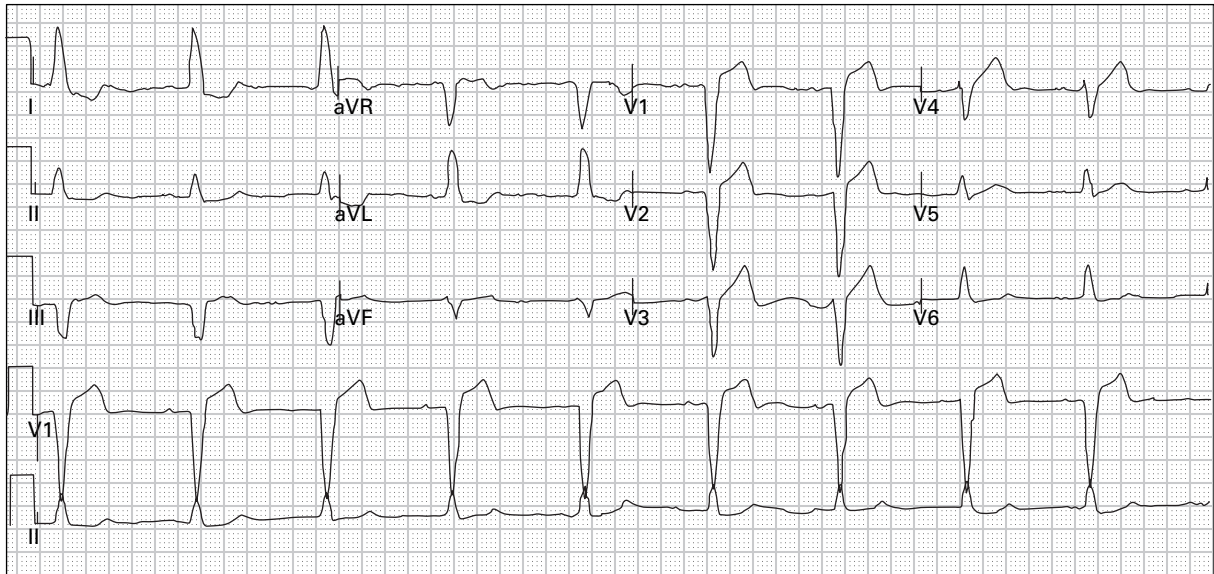
92. 47 year old woman with chest pain; now pain-free after use of sublingual nitroglycerin



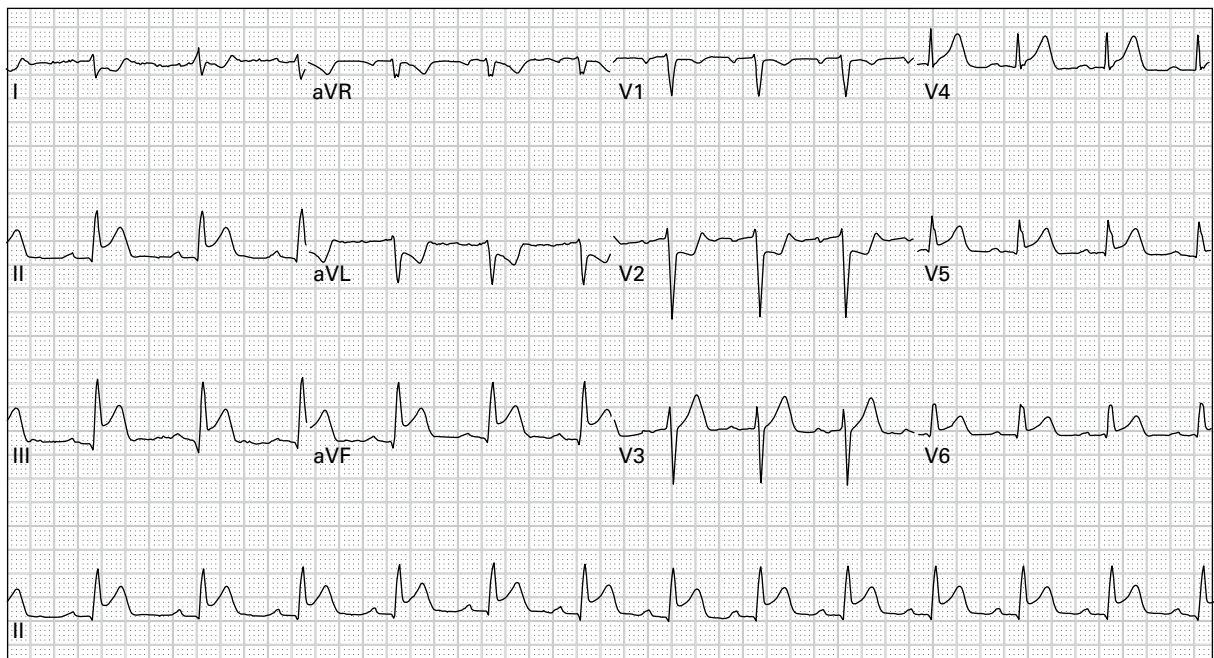
93. 38 year old woman with chest pain, dyspnea, fever, and productive cough



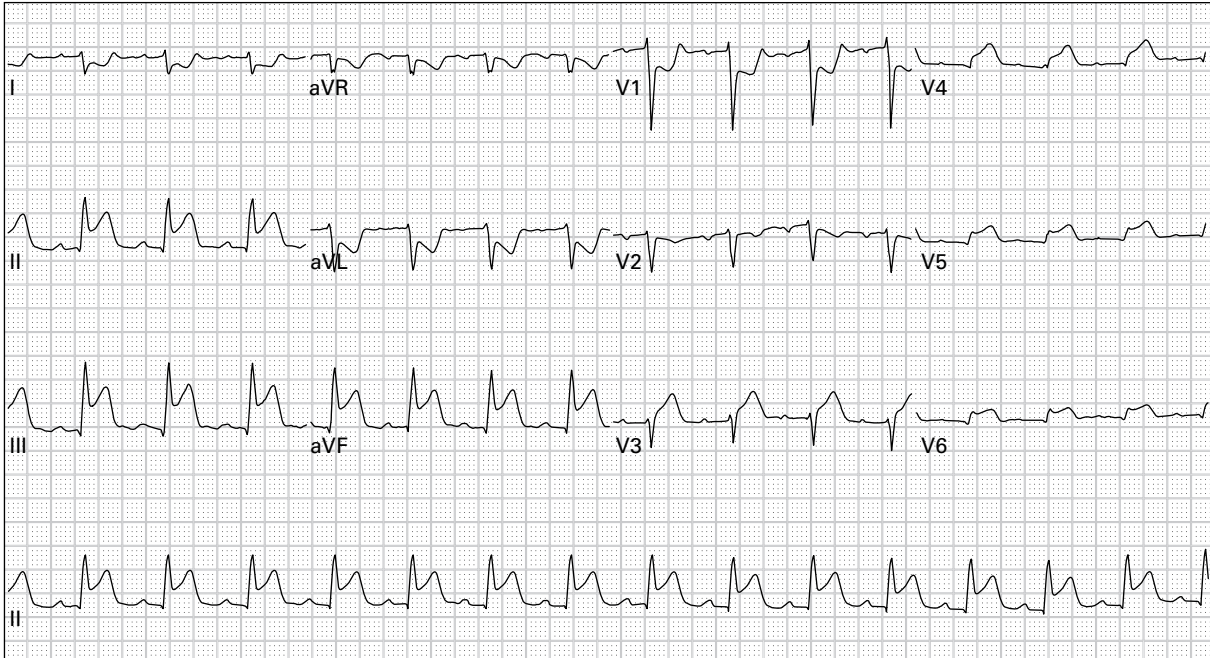
94. 46 year old woman with episodic palpitations, frequent diaphoresis, and a 15 pound weight loss over the past one month



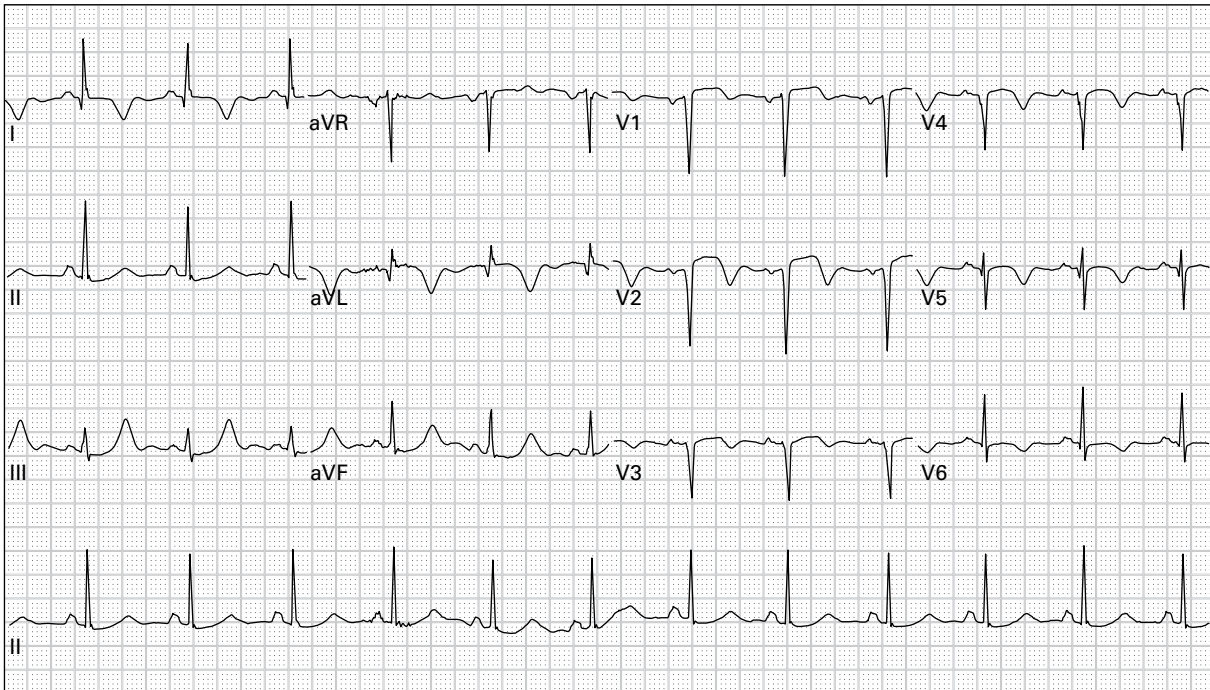
95. 84 year old woman with nausea and vomiting



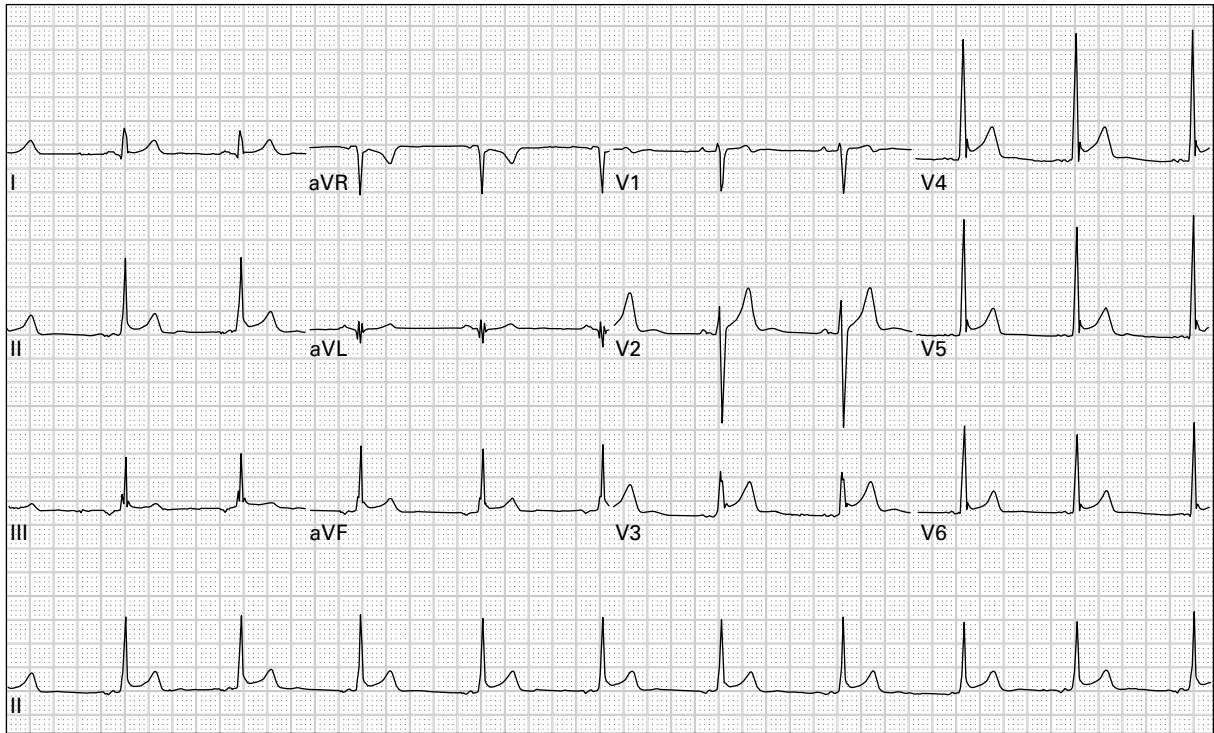
96. 57 year old man with chest pressure, dyspnea, and nausea



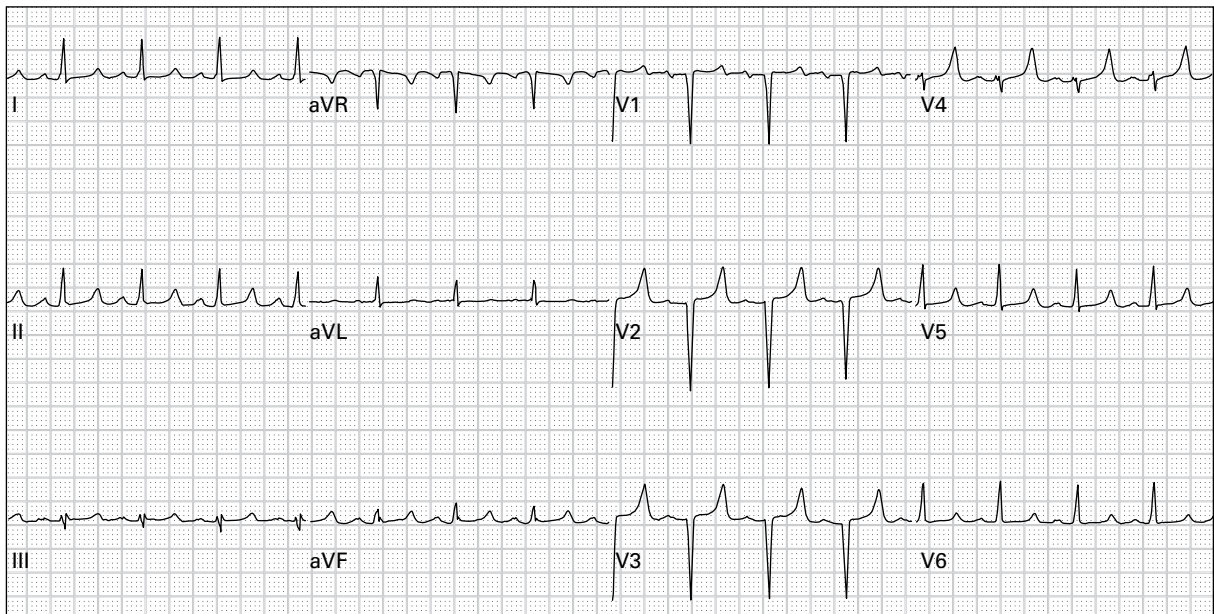
97. 57 year old man with chest pressure, dyspnea, and nausea (right-sided precordial leads)



98. 45 year old woman with eight hours of chest and left neck pain



99. 24 year old woman had a syncopal episode after seeing blood; she has no pain



100. 26 year old woman with history of renal failure reports generalized weakness and nausea