

1

The Nature of Leukaemia, Cytology, Cytochemistry and the Morphological Classification of Acute Leukaemia

CHAPTER MENU

<p>The nature of leukaemia, 2 The aetiology of leukaemia, 2 The importance of classification, 4 The nature and classification of acute leukaemia, 5 The nature and classification of the myelodysplastic syndromes, 6 The nature and classification of chronic myeloid leukaemias and myelodysplastic/myeloproliferative neoplasms, 7 The nature and classification of lymphoid neoplasms, 8 Defining a blast cell, a promyelocyte and a promonocyte, 8 The FAB classification of acute leukaemia, 11 Diagnosing acute leukaemia, 11 Distinguishing between acute myeloid and acute lymphoblastic leukaemias, 13 Defining remission, 14 The incidence of acute leukaemia, 14 The FAB categories and other morphological categories of acute myeloid leukaemia, 15 Acute myeloid leukaemia with minimal evidence of myeloid differentiation: M0 acute myeloid leukaemia, 15 Acute myeloid leukaemia without maturation: M1 acute myeloid leukaemia, 19 Acute myeloid leukaemia with maturation: M2 acute myeloid leukaemia, 22 Acute hypergranular promyelocytic leukaemia: M3 acute myeloid leukaemia, 25 The variant form of acute promyelocytic leukaemia: M3 variant acute myeloid leukaemia, 28 Acute myelomonocytic leukaemia: M4 acute myeloid leukaemia, 33 Acute monocytic/monoblastic leukaemia: M5 acute myeloid leukaemia, 35 Acute myeloid leukaemia with predominant erythroid differentiation: M6 acute myeloid leukaemia, 37 Acute megakaryoblastic leukaemia: M7 acute myeloid leukaemia, 42 Acute eosinophilic leukaemia, 50 Acute basophilic leukaemia, 51 Acute mast cell leukaemia, 52 Langerhans cell leukaemia, 55 Hypoplastic or hypocellular acute myeloid leukaemia, 55 Clinical correlates of FAB categories of acute myeloid leukaemia, 56 The FAB classification of acute lymphoblastic leukaemia, 56 'Acute lymphoblastic leukaemia' of L3 subtype, 61 Automated full blood counts in acute leukaemia, 62 References, 65</p>
--

The nature of leukaemia

Leukaemia is a disease resulting from the neoplastic proliferation of haemopoietic or lymphoid cells. It results from mutation of a single stem cell, the progeny of which form a clone of leukaemic cells. Usually there is a series of genetic alterations rather than a single event. Genetic events contributing to malignant transformation include inappropriate expression of oncogenes and loss of function of tumour suppressor genes. Oncogenes may be either normal cellular genes (proto-oncogenes) that have mutated or are dysregulated, or novel hybrid genes resulting from the fusion of parts of two genes. The cell in which the leukaemic transformation occurs may be a lymphoid precursor, a myeloid precursor or a pluripotent haemopoietic stem cell capable of differentiating into both myeloid and lymphoid cells. Myeloid leukaemias can arise in a lineage-restricted cell, in a multipotent stem cell capable of differentiating into cells of erythroid, granulocytic, monocytic and megakaryocytic lineages, or in a pluripotent lymphoid-myeloid stem cell. Recent molecular evidence suggests that some cases of acute myeloid leukaemia (AML) are derived from a myeloid stem cell and others from a myeloid-T-lymphoid stem cell [1]. Lymphoid leukaemias usually arise in a B- or T-lineage stem cell but occasionally acute lymphoblastic leukaemia (ALL, either B-ALL or T-ALL) arises in a lymphoid-myeloid stem cell, as shown by development of histiocytic sarcoma with the same clonal origin as the preceding B- or T-lineage ALL [2,3].

Genetic alterations leading to leukaemic transformation often result from major alterations in the chromosomes, which can be detected by microscopic examination of the chromosomes of cells in metaphase. Other changes, such as point mutations or partial duplications, are at a submicroscopic level but can be recognised by analysis of deoxyribonucleic acid (DNA) or ribonucleic acid (RNA).

Neoplastic cells are genetically unstable so that further mutations can occur in cells of the clone. If a new mutation gives the progeny of that cell a growth or survival advantage it tends to replace the parent clone. Such clonal evolution can lead to transformation into a more aggressive or treatment-refractory

form of the disease with an associated worsening of prognosis. A series of mutations can occur with progressive worsening of prognosis at each stage.

Leukaemias are broadly divided into: (i) acute leukaemias, which, if untreated, lead to death in weeks or months; and (ii) chronic leukaemias, which, if untreated, lead to death in months or years. They are further divided into lymphoid, myeloid and mixed phenotype leukaemias, the latter showing both lymphoid and myeloid differentiation (or both T- and B-lineage differentiation). Acute leukaemias are characterised by a defect in maturation, leading to an imbalance between proliferation and maturation; since cells of the leukaemic clone continue to proliferate without maturing to end cells and dying, there is continued expansion of the leukaemic clone and immature cells predominate. Chronic leukaemias are characterised by an expanded pool of proliferating cells that retain their capacity to differentiate to end cells but fail to die due to defects in programmed cell death.

The clinical manifestations of the leukaemias are due, directly or indirectly, to the proliferation of leukaemic cells and their infiltration into normal tissues. Increased cell proliferation has metabolic consequences, and infiltrating cells also disturb tissue function. Anaemia, neutropenia and thrombocytopenia are important consequences of infiltration of the bone marrow, which in turn can lead to symptomatic anaemia, infection and haemorrhage.

The aetiology of leukaemia

Many potential causes of leukaemia are known, but nevertheless the majority of cases remain unexplained. There may be an underlying genetic or other constitutional predisposition in addition to oncogenic environmental factors.

The early childhood peak of ALL has been linked to exposure to infection, particularly delayed exposure to common pathogens. A role for infection is supported by preliminary evidence of reduced incidence during lockdown related to the SARS-CoV-2 pandemic [4].

There is a familial predisposition to myelodysplastic syndromes (MDS) and AML (Table 1.1) [5–10].

Table 1.1 Inherited susceptibility to acute myeloid leukaemia* [5–10].

Disease classification	Condition and genes responsible
Inherited bone marrow failure syndromes	Fanconi anaemia: <i>FANCA, FANCB, FANCC, BRCA2 (FANCD1), FANCD2, FANCE, FANCF, FANCG, FANCI, BRIP1 (FANCI), FANCL, FANCM, PALB2 (FANCN), SLX4 (FANCP), RAD51 (FANCR), BRCA1 (FANCS)</i> Dyskeratosis congenita: <i>DKC1, TERC, TERT, ACD, CTC1, NHP2, NOP10, PARN, RTEL1, TINF2, WRAP53</i> Familial aplastic anaemia with sensorineural deafness: <i>SRP72</i> Ataxia-pancytopenia syndrome: <i>SAMD9L, ERCC6L2</i> (bone marrow failure in some patients)
Severe congenital neutropenia	<i>ELANE, HAX1, GFI1</i>
Associated with thrombocytopenia	Familial platelet disorder with associated myeloid malignancy: <i>RUNX1</i> Thrombocytopenia 2: <i>ANKRD26</i> [†] Thrombocytopenia 5: <i>ETV6</i>
Cancer predisposition syndromes	Li–Fraumeni syndrome: <i>TP53</i> Breast and ovarian cancer syndrome: <i>BRCA1, BRCA2</i> Lynch syndrome (mismatch repair deficiency): <i>EPCAM, MLH1, MSH2, MSH6, PMS2</i> Werner syndrome: <i>WRN</i> Bloom syndrome: <i>BLM</i>
Other syndromes	RAS-activating syndromes: <i>NF1, PTPN1, KRAS, CBL</i> Shwachman–Diamond syndrome: <i>SBDS</i> GATA deficiency (deafness, lymphoedema, monocytopenia, susceptibility to infection): <i>GATA2</i> Familial mosaic monosomy 7 (bone marrow insufficiency) MIRAGE syndrome: <i>SAMD9</i> Diamond–Blackfan anaemia: <i>RPS19, RPL5, RPL11</i> and other Xeroderma pigmentosum: <i>XPC</i> null mutation
Non-syndromic	<i>CEBPA, DDX41</i> , [†] <i>ATG2B/GSKIP</i> (duplication) [‡]

* In addition, Down syndrome, which is constitutional but not inherited, predisposes to acute megakaryoblastic leukaemia in infancy.

[†] Lymphoid neoplasms have also been reported.

[‡] Also essential thrombocythaemia.

In the cases of MDS/AML, predisposing mutations have been identified in a number of genes: *RUNX1, CEBPA, GATA2, ANKRD26, SRP72, DDX41, ETV6, ATG2B/GSKIP* (duplication), *WRN, XPC* (null mutation) and *ERCC6L2* and possibly *HYDIN, MUC16, NMUR2, RNF213* and *ACD (TPPI)*. Fanconi anaemia, dyskeratosis congenita, Down syndrome, Shwachman–Diamond syndrome and severe congenital neutropenia (with life sustained by treatment with granulocyte colony-stimulating factor) predispose to AML. Neurofibromatosis, Noonan syndrome and *CBL*-mutation-associated syndrome predispose

to juvenile myelomonocytic leukaemia. *ATG2B/GSKIP* duplication and *RBBP6* mutation predispose to myeloproliferative neoplasms [7]. There is a strong association between AML and zygodactyly (bilateral partial webbing between the second and third toes) but the genetic basis is not certain [11].

Down syndrome predisposes to ALL as well as AML. Familial ALL can be a feature of the Li–Fraumeni syndrome and mismatch repair deficiency (Table 1.2) [12–21]; in the case of the Li–Fraumeni syndrome there is an association with hypodiploid ALL [8]. Familial predisposition to ALL can also

Table 1.2 Constitutional and inherited susceptibility to acute lymphoblastic leukaemia (ALL) [12–21].

Type of genetic alteration	Chromosomes or genes implicated
Constitutional trisomy 21 (Down syndrome)	+21c, sometimes <i>CRLF2</i> rearrangement associated with Ph-like ALL; sometimes +X; sometimes t(8;14)(q11.2;q32.3) with dysregulation of <i>CEBPD</i>
Robertsonian translocation	rob(15;21)(q10;q10)c, often associated iAMP21
Gene mutation or deletion	<i>TP53</i> (Li–Fraumeni syndrome) Lynch syndrome (mismatch repair deficiency) (see Table 1.1) RAS-activating syndromes: <i>NRAS</i> , <i>PTPN11</i> , <i>NF1</i> , <i>CBL</i> <i>PAX5</i> mutation with somatic deletion of the normal allele (B-ALL) [19] <i>ETV6</i> including inherited translocation (B-ALL) [20] <i>IKZF1</i> (<i>IKAROS</i>) inactivating mutation or deletion (B- or T-ALL, preceded by immune deficiency) [17,21] <i>IKZF1</i> mutation, B-ALL in the absence of immune deficiency [19] Bloom syndrome: <i>BLM</i> Ataxia telangiectasia (T-ALL): <i>ATM</i> Xeroderma pigmentosum: <i>XPC</i> null mutation <i>SH2B3</i> <i>RUNX1</i> <i>TYK2</i>
Polymorphism	<i>ARID5B</i> , <i>CEBPE</i> , <i>GATA3</i> , <i>IKZF1</i> , <i>IKZF3</i> , <i>CDKN2A</i> , <i>CDKN2B</i> , <i>ERG</i> , <i>PIP4K2A</i> , <i>TP63</i> [18,19]

result from mutation in *SH2B3* (associated with autoimmunity) and *PAX5*, and from mutation or deletion of *ETV6* [8,12,13] and from polymorphisms in other genes (Table 1.2).

The incidence of therapy-related AML, MDS and ALL is increased in Li–Fraumeni syndrome [22]. The significance of cases of AML and MDS that have followed gene therapy for sickle cell disease is not yet clear [23]. Predisposition to juvenile myelomonocytic leukaemia is discussed further in Chapter 5.

There is a familial predisposition to chronic lymphocytic leukaemia.

Cytotoxic chemotherapy, immunosuppressive therapy and acquired aplastic anaemia predispose to MDS and AML. To a lesser extent, cytotoxic chemotherapy predisposes to ALL and mixed phenotype acute leukaemia (MPAL). Irradiation predisposes also to AML, ALL and chronic myeloid leukaemia (CML). Obesity is a risk factor for CML [24].

The importance of classification

The purpose of any pathological classification is to bring together cases that have fundamental similarities and that are likely to share features of causation, pathogenesis and natural history. Making an accurate diagnosis of a haematological neoplasm is crucial for selection of the most appropriate treatment. Since there are many dozens, if not hundreds, of different types of leukaemia it is essential to have a classification that an individual case can be related to. Identification of homogeneous groups of biologically similar cases is important as it permits an improved understanding of the leukaemic process and ultimately benefits individual patients. Since such diagnostic categories or subgroups may differ from each other in the cell lineage affected, natural history, optimal choice of treatment, and prognosis with and without treatment, their recognition permits the development of a selective evidence-based therapeutic

approach with a resultant overall improvement in outcome. Identifying valid diagnostic categories also increases the likelihood of causative factors and pathogenetic mechanisms being recognised.

The diagnosis and classification of leukaemia is based initially on morphology. A significant advance in the diagnosis and morphological classification of leukaemias occurred with the development of the French–American–British (FAB) classification of acute leukaemia [25–29], and subsequently of other leukaemias and related conditions. This classification, developed by a collaborating group of French, American and British haematologists provided clearly defined criteria, permitting uniform diagnosis and classification of these diseases over three decades. The FAB classification was based on morphology supplemented by cytochemistry and to some extent by immunophenotyping. Over the last one and a half decades the FAB classification has been increasingly supplemented and replaced by the 4th, revised 4th and 5th editions of the *WHO Classification of Tumours of Haematopoietic and Lymphoid Tissues*. The WHO (World Health Organization) classification is based on morphology (either cytology or histology) but also makes extensive use of immunophenotyping and of cytogenetic and molecular genetic analysis with defining genetic abnormalities taking precedence in the latest iteration. Unfortunately, from 2022 onwards there have been two not always compatible classifications of haematological neoplasms, the 5th edition of the WHO classification [30] and the International Consensus Classification of myeloid and lymphoid neoplasms [31]. These are dealt with in detail in subsequent chapters. The FAB classification continues to provide a useful shorthand description of morphological subtypes. It is of value in the preliminary evaluation of a case, since a careful morphological assessment indicates which supplementary tests are indicated and provides a context in which such tests can be interpreted. The FAB classification also remains in use in circumstances where immunophenotypic and genetic analysis is not readily available, and in this circumstance it is important that cytochemistry is not neglected. However, since a precise diagnosis is important for choice of

treatment it is desirable that even resource-poor countries try to establish those diagnostic methods that are essential for optimal patient management and outcome.

For clarity, it is important that FAB designations (which have a precise, carefully defined meaning) are not applied to WHO categories for which the diagnostic criteria differ.

The nature and classification of acute leukaemia

Acute leukaemia comprises a heterogeneous group of conditions that differ in aetiology, pathogenesis, molecular mechanisms, optimal treatment and prognosis. The heterogeneity is reduced when cases of acute leukaemia are divided into AML, ALL and MPAL; even then, however, considerable heterogeneity remains within each of the groups.

Although the best criteria for categorising a case of acute leukaemia as myeloid or lymphoid may be disputed, the importance of such categorisation is beyond doubt. Not only does the natural history differ but the best current modes of treatment are still sufficiently different for an incorrect categorisation to adversely affect prognosis. Assigning patients to subtypes of AML or ALL is becoming increasingly important as the benefits of more targeted treatment are identified. Similarly, the suspected poor prognosis of MPAL suggests that the identification of such cases may lead to a different therapeutic approach and an improved outcome. Cases of acute leukaemia can be classified on the basis of morphology, cytochemistry, immunophenotype, cytogenetic abnormality or molecular genetic abnormality, or by combinations of these characteristics. Morphology and cytochemistry of acute leukaemia will be discussed in this chapter, other diagnostic techniques in Chapter 2, and the integration of all these techniques in the WHO and International Consensus classifications in Chapter 3. The cytochemical stains most often employed in acute leukaemia are summarised in Table 1.3 [32–34].

Patients may be assigned to the same or different subgroups depending on the characteristics studied and the criteria selected for separating subgroups.

Table 1.3 Cytochemical stains of use in the diagnosis and classification of acute leukaemia [32–34].

Cytochemical stain	Specificity
Myeloperoxidase (MPO)	Stains primary and secondary granules of cells of neutrophil lineage, eosinophil granules (granules appear solid), granules of monocytes and Auer rods; granules of normal mature basophils do not stain
Sudan black B (SBB)	Stains primary and secondary granules of cells of neutrophil lineage, eosinophil granules (periphery of granule may stain or granules may appear to have a solid core), granules of monocytes and Auer rods; basophil granules are usually negative but sometimes show metachromatic staining (red/purple)
Naphthol AS-D chloroacetate esterase (chloroacetate esterase, CAE, 'specific' esterase)	Stains neutrophil and mast cell granules; Auer rods are usually negative except in acute myeloid leukaemia associated with t(15;17)(q24.1;q21.2) and t(8;21)(q22;q22.1)
α-Naphthyl acetate esterase (ANAE) ('non-specific' esterase)	Stains monocytes and macrophages, megakaryocytes and platelets, most T lymphocytes and some T lymphoblasts (focal); may be expressed by melanoma cells [13]
α-Naphthyl butyrate esterase (ANBE) ('non-specific' esterase)	Stains monocytes and macrophages; variable staining of T lymphocytes
Periodic acid–Schiff (PAS)*	Stains cells of neutrophil lineage (granular, increasing with maturation), leukaemic promyelocytes (diffuse cytoplasmic), eosinophil cytoplasm (but not granules), basophil cytoplasm (blocks), monocytes (diffuse plus granules), megakaryocytes and platelets (diffuse plus granules), some T and B lymphocytes, and many leukaemic blast cells (blocks, B more than T)
Acid phosphatase*	Stains neutrophils, most T lymphocytes, T lymphoblasts (focal); variable staining of eosinophils, monocytes and platelets; strong staining of macrophages, plasma cells and megakaryocytes and some leukaemic megakaryoblasts
Toluidine blue	Stains basophil and mast cell granules
Perls stain	Stains haemosiderin in erythroblasts, macrophages and, occasionally, plasma cells

* These cytochemical stains are largely redundant if immunophenotyping is available, but see Chapter 8.

All classifications necessarily have an element of arbitrariness, particularly since they need to incorporate cut-off points for continuous variables such as the percentage of cells falling into a defined morphological category, positivity for a certain cytochemical reaction, or the presence of a certain immunological marker. An ideal classification of acute leukaemia must be biologically relevant. If it is to be useful to the clinical haematologist, as well as to the research scientist, it should also be readily reproducible and easily and widely applicable. Rapid categorisation should be possible so that therapeutic decisions can be based on the classification. The classification should be widely acceptable and

should change as little as possible over time so that valid comparisons can be made between different groups of patients. Ideal classifications of acute leukaemia do not yet exist, although many have been proposed.

The nature and classification of the myelodysplastic syndromes

The myelodysplastic syndromes are a group of myeloid neoplasms that are closely related to AML and in some cases precede it. Like AML, they result from mutation of a multipotent or, occasionally, a

pluripotent haemopoietic stem cell. They are characterised by ineffective haemopoiesis, that is, there is usually a normocellular or hypercellular bone marrow but despite this there is peripheral cytopenia as a result of an acquired intrinsic defect in myeloid maturation; there is an increased rate of death of precursor cells in the bone marrow (by a process known as programmed cell death, or apoptosis) leading to a failure of production of adequate numbers of normal mature cells. MDS is also characterised by morphologically abnormal maturation, referred to as dysplasia. However, it should be noted that dysplasia is not specific for MDS, or even for a myeloid neoplasm. MDS evolves into AML as a result of further mutations that interfere with myeloid maturation leading to a progressive accumulation of blast cells. Not only may MDS evolve into AML, but also patients presenting with apparently *de novo* AML may have associated dysplastic features. AML evolving from MDS and AML with associated dysplasia are likely to be closely related conditions. MDS is very heterogeneous, in some patients persisting unchanged for many years and in others leading to death from acute leukaemia or from the complications of bone marrow failure in a relatively short period of time. An adequate classification of MDS must therefore be directed at recognising categories of disease that differ in prognosis or that indicate a particular, sometimes relatively specific, choice of treatment. The diagnosis and classification of this group of disorders is dealt with in detail in Chapter 4.

The nature and classification of chronic myeloid leukaemias and myelodysplastic/myeloproliferative neoplasms

The chronic myeloid leukaemias can result from a mutation either in a multipotent myeloid stem cell or in a pluripotent lymphoid-myeloid stem cell. In contrast to the majority of cases of AML, they are characterised by an increased peripheral blood count of mature granulocytes. Usually neutrophils predominate but often there is also an increase in

eosinophils and basophils; less often the dominant cell is the eosinophil. Monocytes may also be increased. When the leukaemic clone derives from a pluripotent stem cell, the lymphoid component may be apparent before the myeloid component, simultaneously or subsequently. Irrespective of the timing of the appearance of the lymphoid component, the lymphoid cells are immature and their appearance represents evolution of the disease, known as acute transformation.

The chronic myeloid leukaemias are classified partly on morphological criteria, which in the past were supplemented by cytochemistry (a neutrophil alkaline phosphatase (NAP) score). However, when a specific cytogenetic or molecular genetic abnormality has been found to characterise a subtype of chronic myeloid leukaemia it becomes of considerable importance to incorporate this into any scheme of classification. A crucial distinction is between chronic myeloid leukaemias with and without a translocation between chromosomes 9 and 22 that leads to the formation of an abbreviated chromosome 22 known as the Philadelphia (Ph) chromosome. Chronic myeloid leukaemia with t(9;22)(q34.1;q11.2) has been variously referred to as 'chronic granulocytic leukaemia', 'chronic myelogenous leukaemia', 'chronic myelogenous leukaemia, *BCR-ABL1* positive' and 'chronic myeloid leukaemia'. The designation chronic myeloid leukaemia will be generally used in this book since it is the term now favoured in the WHO and International Consensus classifications, but it is not an ideal term since it is also used as a generic term and is thus ambiguous.

Chronic myeloid leukaemia is similar in nature to other myeloproliferative neoplasms (MPN) such as polycythaemia vera, essential thrombocythaemia and primary myelofibrosis, with which it is grouped. In these related conditions differentiation is to erythrocytes in polycythaemia vera, to platelets in essential thrombocythaemia, to all myeloid lineages in primary myelofibrosis, and to neutrophils in chronic neutrophilic leukaemia. The distinguishing features of primary myelofibrosis are extramedullary haemopoiesis and bone marrow fibrosis, which despite the name is not actually 'primary' but is reactive to the myeloid neoplasm. These other MPN can undergo clonal evolution, including

evolution to a chronic myeloid leukaemia and blast transformation.

Certain other chronic myeloid leukaemias are associated with specific molecular abnormalities and are classified on this basis. These include cases with mutation of genes encoding proteins on signalling pathways, including rearrangement of *PDGFRA*, *PDGFRB*, *FGFR1* and *JAK2*. Such cases are classified on the basis of the molecular abnormality.

Other chronic myeloid leukaemias are more closely related to MDS than to MPN and are thus classified as myelodysplastic/myeloproliferative neoplasms (MDS/MPN). MPN are characterised by effective proliferation of myeloid cells and increased numbers of end cells, whereas MDS are characterised by ineffective proliferation, morphological dysplasia and inadequate numbers of end cells of one or more lineages. When a condition shows effective proliferation of cells of one lineage and ineffective proliferation of cells of another lineage with associated dysplasia it is classified as MDS/MPN. If these overlap syndromes also have a high white blood cell count (WBC) they can legitimately be regarded as a form of (Ph-negative) chronic myeloid leukaemia. Juvenile myelomonocytic leukaemia (JMML), atypical chronic myeloid leukaemia (aCML) and chronic myelomonocytic leukaemia (CMML) have generally been classified as subtypes of MDS/MPN.

The MDS/MPN are discussed in detail in Chapter 5, and other chronic myeloid leukaemias in Chapter 6.

The nature and classification of lymphoid neoplasms

Lymphoid neoplasms can be categorised in two ways, according to the immaturity of the cell or according to the presence or absence of 'leukaemia' as a key feature of a type of disease. A lymphoid leukaemia is a neoplasm in which the predominant manifestations are in the blood and bone marrow, whereas the term 'lymphoma' refers to a disease characterised by a neoplastic proliferation of cells of lymphoid origin in organs and tissues such as lymph nodes, spleen, thymus and skin.

In some lymphoid neoplasms, the neoplastic cells are lymphoblasts, cells that are cytologically and immunophenotypically immature. If lymphoblasts are present in the bone marrow, with or without overspill into the blood, the condition is designated ALL. Primary infiltration of other lymphoid organs or tissues by lymphoblasts is designated lymphoblastic lymphoma. In either case the lymphoblasts can be of either B lineage or T lineage, although ALL is more often of B lineage and lymphoblastic lymphoma more often of T lineage. In the WHO classification, lymphoid precursor neoplasms are designated 'B-lymphoblastic leukaemia/lymphoma' and 'T-lymphoblastic leukaemia/lymphoma'.

In other lymphoid neoplasms the neoplastic cells are mature, and again a given condition is regarded as 'leukaemia' or 'lymphoma' according to the usual manifestations of the disease. However, again there is overlap. Thus the most common leukaemia of mature lymphoid cells, chronic lymphocytic leukaemia, has a tissue counterpart designated 'small lymphocytic lymphoma' in which the peripheral blood lymphocyte count is not elevated. Similarly, a rare subtype of mature T-cell neoplasm, designated adult T-cell leukaemia/lymphoma, presents as leukaemia in about 90% of patients and as lymphoma in about 10%. Conditions that predominantly present as lymphomas can also have a leukaemic phase when there is extensive disease or with disease progression. This is often the case with mantle cell lymphoma and sometimes with follicular lymphoma. It should be noted that leukaemias and lymphomas of immunophenotypically mature lymphocytes do not necessarily have cells that resemble normal mature lymphocytes cytologically. The neoplastic cells may be very large and appear very abnormal. They are also not necessarily clinically indolent; some, such as Burkitt lymphoma, are as clinically aggressive as acute leukaemia.

Defining a blast cell, a promyelocyte and a promonocyte

Blast cells are large cells with a high nucleocytoplasmic ratio, often nucleoli and usually a delicate, diffuse chromatin pattern although some lymphoblasts are

smaller with some chromatin condensation. The enumeration of blasts in the bone marrow is crucial in the diagnosis of acute leukaemia, and the definition of a blast cell is therefore important. Whether immature myeloid cells containing small numbers of granules are classified as blasts is a matter of convention. The FAB group chose to classify such cells as myeloblasts rather than promyelocytes. They recognised two types of myeloblast [35]. Type I blasts lack granules and have a diffuse chromatin pattern, a high nucleocytoplasmic ratio and usually prominent nucleoli. Type II blasts resemble type I blasts except for the presence of a few azurophilic granules and a somewhat lower nucleocytoplasmic ratio. Type II blast cells may contain Auer rods (see page 22) rather than granules; less often they contain large rectangular crystals [36] or large inclusions (pseudo-Chédiak–Higashi inclusions). Auer rods and pseudo-Chédiak–Higashi granules may coexist in the same blast cell (Fig. 1.1) and Auer rods can be seen within such granules [37]. Occasionally, blast cells contain micronuclei, which may represent acentric chromosomal fragments, damaged single chromosomes or amplified oncogenes [38]. Rarely leukaemic myeloblasts have aberrant condensation of chromatin into large blocks [39].

The International Working Group on Morphology of MDS (IWGM-MDS) revised the definition of a blast cell, accepting as blast cells that have more than scanty granules but lacking other characteristics of promyelocytes [40]. They have divided blast cells into ‘agranular blasts’ and ‘granular blasts’. This definition of a blast cell was accepted in the WHO classifications.

Cells are categorised as promyelocytes rather than type II/III or granular blasts when they develop an eccentric nucleus, more abundant cytoplasm, a Golgi zone and some chromatin condensation (but with the retention of a nucleolus). The cytoplasm, except in the pale Golgi zone, remains basophilic. Cells that have few or no granules, but that show the other characteristics of promyelocytes, are regarded as hypogranular or agranular promyelocytes rather than as blasts. Examples of cells classified as type I, II and III blasts and as promyelocytes are shown in Figs 1.2, 1.3, 1.4 and 1.5. The great majority of lymphoblasts lack granules and are therefore type I blasts; they resemble myeloblasts but are often smaller with scanty cytoplasm and may show some chromatin condensation (see Table 1.13). Granular blast cells are generally myeloid, but occasionally lymphoblasts have a few myeloperoxidase-negative granules. Rarely there are

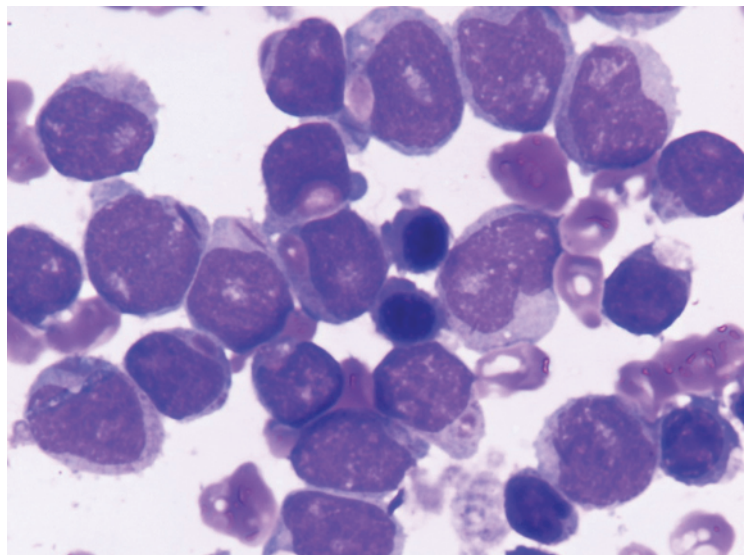


Fig. 1.1 Peripheral blood (PB) film of a patient with acute myeloid leukaemia (AML) showing some blast cells containing Auer rods and others containing pseudo-Chédiak–Higashi granules. May–Grünwald–Giemsa (MGG) $\times 100$ objective. (With thanks to Dr Abbas Hashim Abdulsalam, Baghdad.)

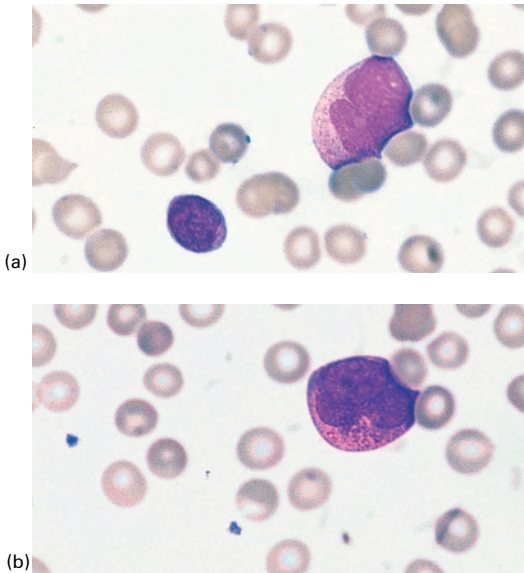


Fig. 1.2 PB film of a patient with AML showing: (a) a type II blast with scanty azurophilic granules; (b) a promyelocyte with more numerous granules and a Golgi zone in the indentation of the nucleus. MGG $\times 100$.

prominent granules [41]. Rarely lymphoblasts contain inclusions resembling Russell bodies but unrelated to immunoglobulin [42,43].

Monoblasts (Fig. 1.5a) differ from myeloblasts in being larger with more voluminous cytoplasm. The

cytoplasm is moderately to markedly basophilic and may have fine granules or vacuoles. The nucleus is round or somewhat oval with a dispersed chromatin pattern and often a large single nucleolus. The cell may be round or have an irregular cytoplasmic margin.

A promonocyte has been described in similar terms by the FAB group and in the WHO classification. Since the WHO classification regards the promonocyte as a 'blast equivalent' in the diagnosis of myeloid neoplasms, its recognition has become of considerable importance. The misclassification of immature or abnormal monocytes as promonocytes can lead to a disease being categorised as AML rather than as MDS or CMML.

A promonocyte (Figs 1.5b and 1.6) is a large cell with an irregular or convoluted nucleus. The cytoplasm is weakly or moderately basophilic. The cytoplasm may be vacuolated or contain granules. The chromatin pattern is diffuse, like that of a monoblast. A nucleolus with similar characteristics may be present or the nucleolus may be smaller. It is the features of the nucleus that permit a distinction between a monoblast and a promonocyte; both have the same delicate or dispersed chromatin pattern but the monoblast has a regular nucleus whereas that of the promonocyte is irregular.

Promonocytes must be distinguished from immature or atypical monocytes, which have some chromatin condensation and rarely have nucleoli, these

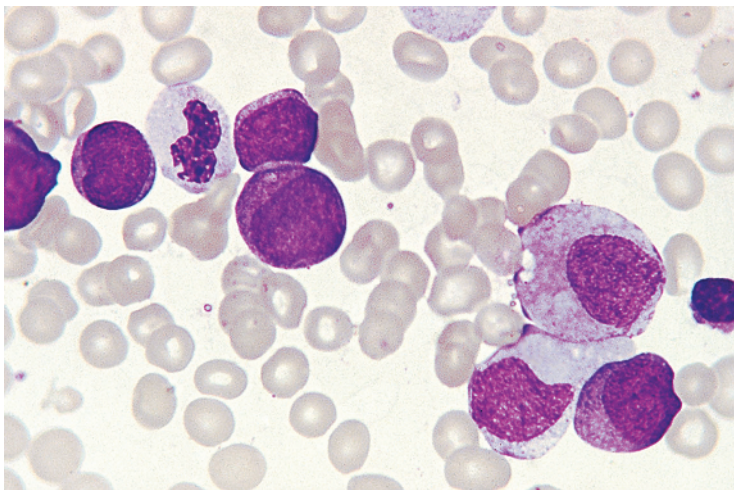


Fig. 1.3 Bone marrow (BM) film of a patient with AML, French-American-British (FAB) M2/t(8;21)(q22;q21.2), showing a cell that has scanty granules but nevertheless would be classified as a promyelocyte rather than a blast because of its low nucleocytoplasmic ratio; defective granulation of a myelocyte and a neutrophil is also apparent. Type I and type II blasts are also present. MGG $\times 100$.

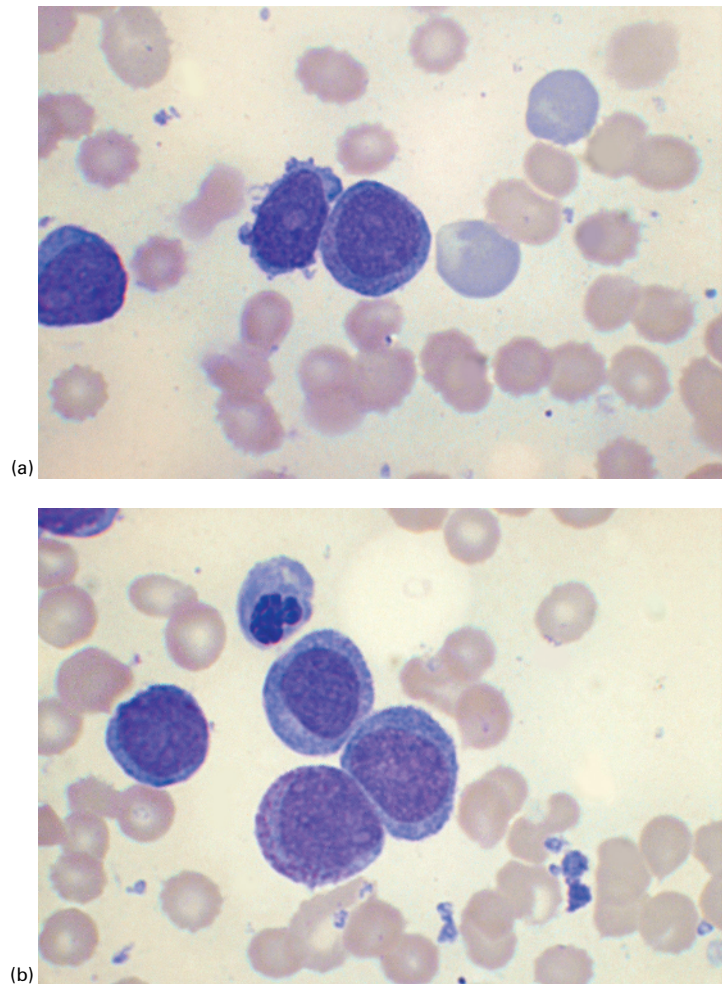


Fig. 1.4 BM film from a patient with FAB M2 AML showing: (a) a type I blast cell (left of centre) and a type II blast cell with scanty granules (centre); (b) a type II (granular) blast cell with numerous granules but with a central nucleus and no Golgi zone; there are also three type I blast cells and a dysplastic erythroblast. MGG $\times 100$.

being the essential features that differentiate them from promonocytes. They have lobulated or indented nuclei and cytoplasm that shows variable basophilia and may have granules or vacuoles; the cytoplasmic outline may be irregular.

The FAB classification of acute leukaemia

The FAB classification of acute leukaemia was first published in 1976 and was subsequently expanded, modified and clarified [25–29]. It deals with both diagnosis and classification.

Diagnosing acute leukaemia

The diagnosis of acute leukaemia usually starts from a clinical suspicion. It is uncommon for this diagnosis to be incidental, resulting from the performance of a blood count for a quite different reason. Clinical features leading to suspicion of acute leukaemia include pallor, fever or other signs of infection, pharyngitis, petechiae and other haemorrhagic manifestations, bone pain, hepatomegaly, splenomegaly, lymphadenopathy, gum hypertrophy and skin infiltration. Rarely presentation is with features of hypercalcaemia. A suspicion of acute leukaemia generally leads to a blood count and film being performed and, if this shows a relevant abnormality, to a bone marrow

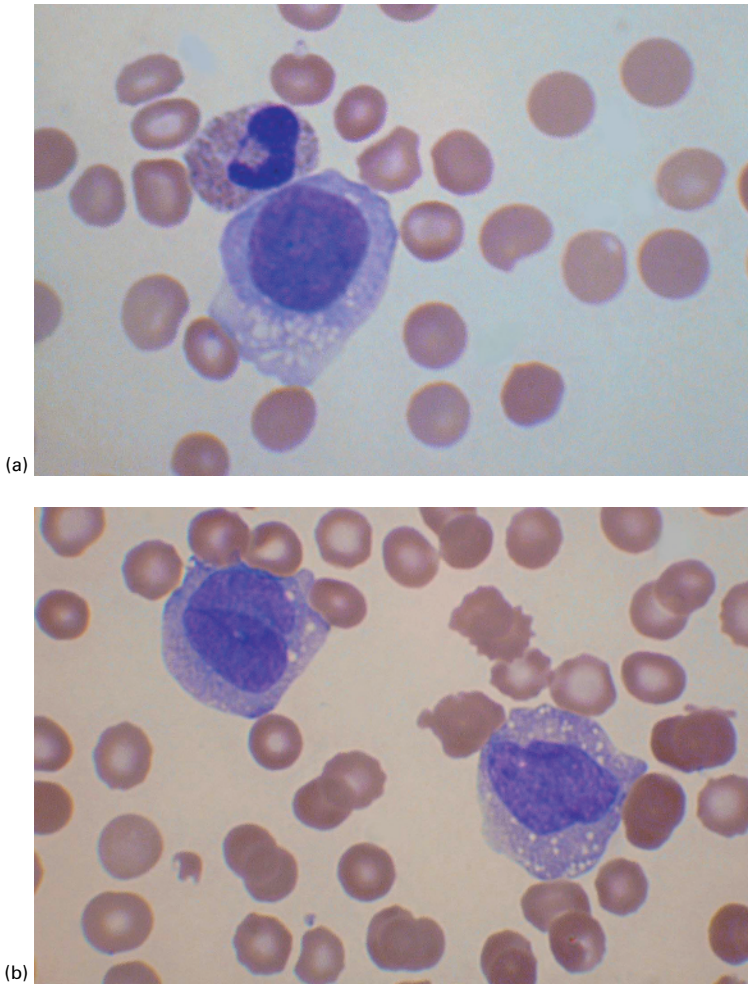


Fig. 1.5 BM film from a patient with FAB M5 AML showing: (a) a monoblast and a neutrophil; (b) two promonocytes. MGG $\times 100$.

aspiration. The diagnosis then rests on an assessment of the peripheral blood and bone marrow. Radiological features can also be of value, with a mediastinal mass being strongly suggestive of T-lineage ALL.

The peripheral blood in AML usually shows leucocytosis, anaemia and thrombocytopenia. The leucocytosis reflects the presence of circulating blast cells, while the number of neutrophils is usually reduced and few cells of intermediate stages of maturation are seen (*hiatus leukaemicus*). In some patients the total WBC is normal or low and, in the latter group, circulating blast cells may be infrequent or even absent. In a minority of patients, there are increased eosinophils and, considerably less

often, increased basophils. There may be evidence of dysplastic maturation such as poikilocytosis and macrocytosis, hypolobated or agranular neutrophils, or hypogranular/agranular or giant platelets. Rarely there are hyperlobated neutrophils [44].

The peripheral blood film in ALL may show leucocytosis resulting from the presence of considerable numbers of circulating blast cells, but many patients have a normal total leucocyte count, and blast cells may be infrequent or even absent. In one large study of children and adolescents, 14.7% of patients presented with circulating blast cells absent or less than 1%, this being more common in those with hyperdiploidy and in B-lineage rather than

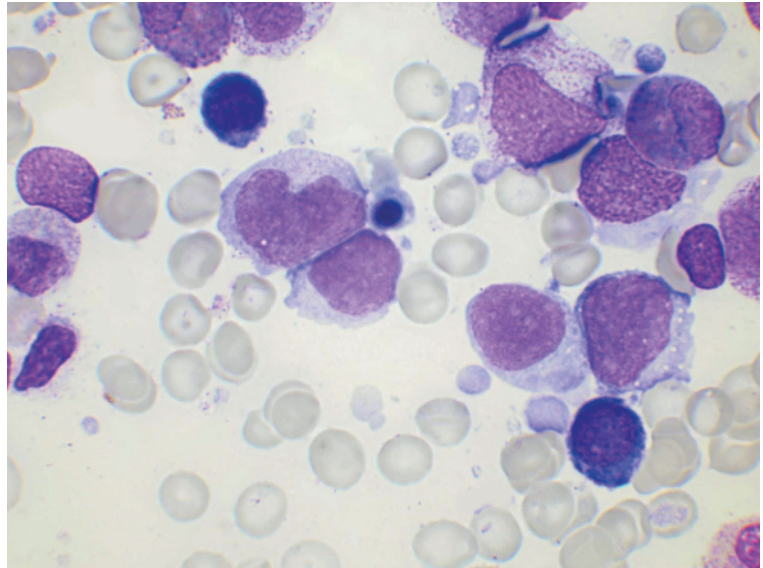


Fig. 1.6 BM film from a patient with FAB M5 AML showing a promonocyte and three monoblasts; the promonocyte has an irregular nucleus but otherwise is very similar to the three monoblasts. MGG $\times 100$.

T-lineage disease [45]. There is usually anaemia, neutropenia or thrombocytopenia, but sometimes the neutrophil count, platelet count or even both are normal and occasionally the platelet count is actually increased. In contrast to AML, the myeloid cells do not show any dysplastic features. A minority of patients have a reactive eosinophilia. In the rare cases in which leukaemic lymphoblasts are heavily granulated, myeloperoxidase cytochemistry or immunophenotyping is essential in making the correct diagnosis [41,46].

The FAB classification requires that peripheral blood and bone marrow films be examined and that differential counts be performed on both. In the case of the bone marrow, a 500-cell differential count is required. Acute leukaemia is diagnosed if one of the following three features is present:

- 1) At least 30%* of the total nucleated cells in the bone marrow are blast cells; *or*
- 2) The bone marrow shows erythroid predominance (erythroblasts $\geq 50\%$ of total nucleated

cells) and at least 30% of non-erythroid cells are blast cells (lymphocytes, plasma cells and macrophages also being excluded from the differential count of non-erythroid cells); *or*

- 3) The characteristic morphological features of acute promyelocytic leukaemia (see page 25) are present.

Cases of ALL will be diagnosed on the first criterion since erythroid hyperplasia does not occur in this condition, but the diagnosis of all cases of AML requires application also of the second and third criteria. The bone marrow in acute leukaemia is usually hypercellular, or at least normocellular, but this is not necessarily so since some cases meet the above criteria when the bone marrow is hypocellular.

Distinguishing between acute myeloid and acute lymphoblastic leukaemias

The diagnosis of acute leukaemia using FAB criteria requires that bone marrow blast cells (type I plus type II) constitute at least 30% either of total nucleated cells or of non-erythroid cells. The further classification of acute leukaemia as AML or ALL is of critical importance. When the FAB classification was first proposed, tests to confirm the nature of

*It should be noted that the criterion of at least 30% blast cells has been altered, in the 2022 WHO and International Consensus classifications, to at least 20% blast cells and, in some genetic subtypes, to at least 10% blast cells (see Chapter 3).

lymphoblasts were not widely available. The group therefore defined as AML cases in which at least 3% of the blasts gave positive reactions for myeloperoxidase (MPO) or with Sudan black B (SBB). Cases that appeared to be non-myeloid were classed as 'lymphoblastic'. The existence of cases of AML in which fewer than 3% of blasts gave cytochemical reactions appropriate for myeloblasts or monoblasts was not established at this stage, and no such category was provided in the initial FAB classification. In the 1980s and 1990s the wider availability and application of immunological markers for B- and T-lineage lymphoblasts, supplemented by ultrastructural cytochemistry and the application of molecular biological techniques to demonstrate rearrangements of immunoglobulin and T-cell receptor genes, demonstrated that the majority of cases previously classified as 'lymphoblastic' were genuinely lymphoblastic but that a minority were myeloblastic with the blast cells showing only minimal evidence of myeloid differentiation.[†] These latter cases were designated M0 AML [29]. It should be noted that SBB is more sensitive than MPO in the detection of myeloid differentiation, and more cases will be categorised as M1 rather than M0 if it is used [47].

Correct assignment of patients to the categories of AML and ALL, respectively, is very important for prognosis and choice of therapy. Appropriate tests to make this distinction must therefore be employed. Despite the advances in immunophenotyping, cytochemical reactions remain useful in the diagnosis of AML [48], particularly in resource-limited settings. Cytochemical demonstration of MPO activity can give prognostic information, since a higher percentage of MPO-positive blasts is strongly associated with a better prognosis [49]. The FAB group recommended the use of MPO, SBB and non-specific

[†]In discussing the FAB classification we have used the terms 'differentiation' and 'maturation' in the sense in which they were used by the FAB group, that is, with differentiation referring to an alteration in gene expression that commits a multipotent stem cell to one pathway or lineage rather than another, and maturation indicating the subsequent changes within this cell and its progeny as they mature towards end cells of the lineage.

esterase (NSE) stains. If cytochemical reactions for myeloid cells are negative, a presumptive diagnosis of ALL should be confirmed by immunophenotyping. When immunophenotyping is available the acid phosphatase reaction and the periodic acid–Schiff (PAS) reaction (the latter identifying a variety of carbohydrates including glycogen) are no longer indicated for the diagnosis of ALL. When cytochemical reactions indicative of myeloid differentiation and immunophenotyping for lymphoid antigens are both negative, immunophenotyping to demonstrate myeloid antigens and thus identify cases of M0 AML is necessary; the panel of antibodies used for characterising suspected acute leukaemia should include antibodies directed at both lymphoid and myeloid antigens so that the one procedure will identify both M0 AML and ALL. It should be noted that when individuals with an inherited MPO deficiency develop AML, leukaemic cells will give negative reactions for both MPO and SBB.

Defining remission

Morphological remission in acute leukaemia is often defined as the absence of clinical evidence of leukaemia (e.g. no extramedullary disease) with bone marrow blast cells being less than 5%, no Auer rods being present, the neutrophil count being at least $1 \times 10^9/l$ and the platelet count being at least $100 \times 10^9/l$ [50]. A bone marrow blast percentage of less than 5% has been validated as a criterion [51]. Sometimes the definition includes a provision that these criteria are met for a minimum of 1 month or that, if immunophenotypic analysis is carried out, there is no persistence of a leukaemia-associated immunophenotype. A more strictly defined remission is a cytogenetic remission, which requires there to be no cytogenetic evidence of a persisting leukaemic clone [50]. Similarly, a molecular complete remission requires that there be no molecular evidence of minimal (measurable) residual disease [50].

The incidence of acute leukaemia

Acute myeloid leukaemia has a low incidence in childhood, less than one case per 100 000/year. Among adults the incidence rises increasingly rapidly with age, from approximately 1/100 000/year in

the fourth decade to approximately 10/100 000/year in those over 70 years. AML is commoner in males than in females. US surveys have shown AML to have a higher age-adjusted incidence in non-Hispanic whites than in blacks, Asian/Pacific islanders and Hispanics [52]. ALL is most common in childhood, although cases occur at all ages. In children up to the age of 15 years, the overall incidence is of the order of 2.5–3.5/100 000/year; the disease is more common in males than in females. In childhood, ALL is more common than AML, except under the age of 1 year. ALL has also been observed to be more common in Caucasians than in those of African ancestry, but this appears to be related to environmental factors rather than being a genetic difference since the difference disappears with an alteration in socioeconomic circumstances.

The FAB categories and other morphological categories of acute myeloid leukaemia

Once criteria for the diagnosis of AML have been met and cases have been correctly assigned to the broad categories of myeloid or lymphoid, further classification can be carried out. The FAB group suggested that this be based on a peripheral blood differential count and a 500-cell bone marrow differential count, supplemented when necessary by cytochemistry, studies of lysozyme concentration in serum or urine, and immunophenotyping; with the greater availability of immunophenotyping, measurement of lysozyme concentration is no longer in current use and the use of cytochemistry has declined markedly. Broadly speaking, AML is categorised as acute myeloblastic leukaemia without maturation (M1) and with granulocytic maturation (M2), acute hypergranular promyelocytic leukaemia and its variant (M3 and M3V), acute myelomonocytic leukaemia (M4), acute monoblastic (M5a) and monocytic (M5b) leukaemia, acute erythroleukemia (M6) and acute megakaryoblastic leukaemia (M7). M0 is AML without maturation and with minimal evidence of myeloid differentiation. In addition to the above categories there are several very rare types of AML that are not included in the FAB classification. These include mast cell leukaemia

and Langerhans cell leukaemia. In addition, the diagnosis of hypoplastic AML requires consideration. Transient abnormal myelopoiesis of Down syndrome (see page 215) should also be regarded as a variant of AML.

Acute myeloid leukaemia with minimal evidence of myeloid differentiation:

M0 acute myeloid leukaemia

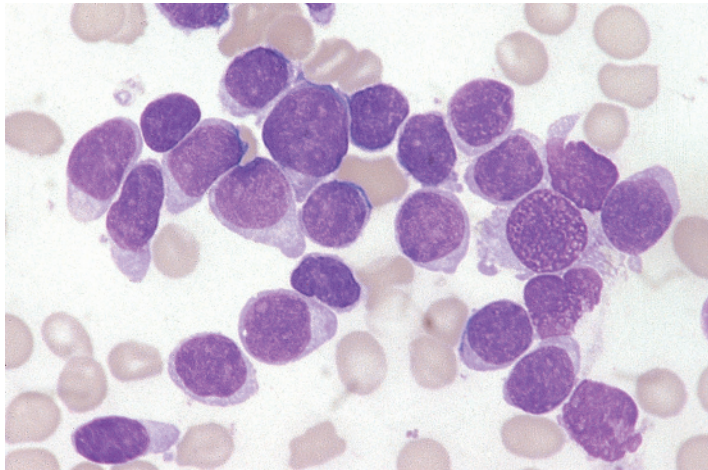
The FAB criteria for the diagnosis of M0 AML are shown in Table 1.4 and the morphological and immunocytochemical features are illustrated in Figs 1.7 and 1.8. The blasts in M0 AML usually resemble M1 myeloblasts or L2 lymphoblasts (see page 56) but in a minority of cases they resemble the monoblasts of M5 AML. Associated dysplastic features in erythroid and megakaryocyte lineages may provide indirect evidence that a leukaemia is myeloid not lymphoid. Dysplastic features are present in up to a quarter of cases. Definite evidence of myeloid differentiation that permits assignment to this category may be provided by the following:

- 1) The demonstration of ultrastructural features of cells of granulocytic lineage, e.g. characteristic basophil granules (Table 1.5) [53–58].
- 2) The demonstration of cytoplasmic MPO activity by ultrastructural cytochemistry (Table 1.6; Fig 1.9) [47,54,59,60].
- 3) The demonstration of cytoplasmic MPO protein by immunocytochemistry or flow cytometric immunophenotyping with an anti-MPO monoclonal antibody.

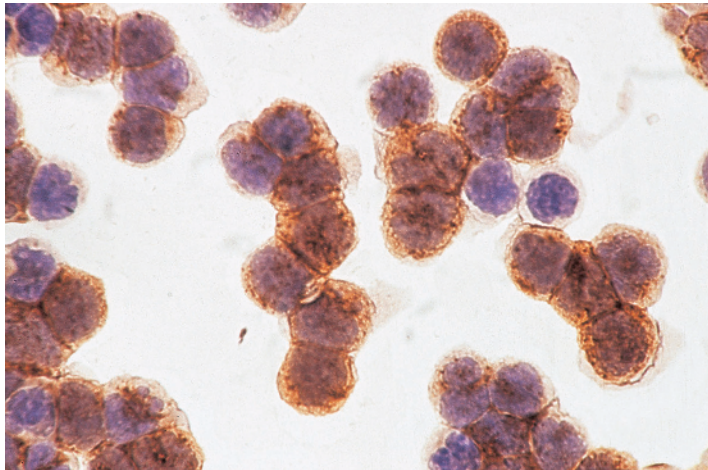
Table 1.4 Criteria for the diagnosis of acute myeloid leukaemia of M0 category (acute myeloid leukaemia with minimal evidence of myeloid differentiation).

- Blasts $\geq 30\%$ of bone marrow nucleated cells
- Blasts $\geq 30\%$ of bone marrow non-erythroid cells*
- $< 3\%$ of blasts positive for Sudan black B or for myeloperoxidase by light microscopy
- Blasts demonstrated to be myeloblasts by immunological markers or by ultrastructural cytochemistry

* Exclude also lymphocytes, plasma cells, macrophages and mast cells from the count.



(a)



(b)

Fig. 1.7 PB and BM preparations from a patient with FAB M0 AML. (a) BM film stained by MGG showing agranular blasts. MGG $\times 100$. (b) Immunoperoxidase reaction of PB cells in a cytopsin preparation stained with a CD13 monoclonal antibody (McAb) showing many strongly positive blasts; the blasts were also positive for CD34, human leucocyte antigen DR (HLA-DR) and terminal deoxynucleotidyl transferase (TdT). Immunoperoxidase $\times 100$.

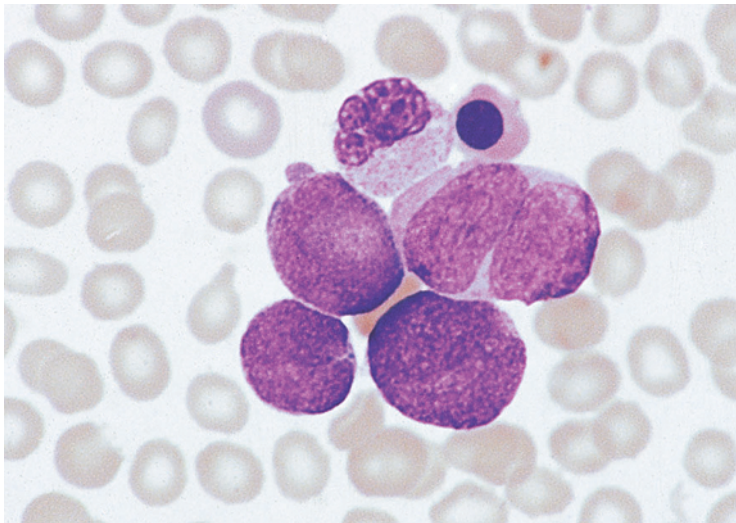


Fig. 1.8 BM film of a patient with FAB M0 AML showing agranular pleomorphic blasts with a high nucleocytoplasmic ratio; the presence of a neutrophil with a nucleus of abnormal shape suggests the correct diagnosis. MGG $\times 100$.

Table 1.5 Ultrastructural characteristics distinguishing blast cells and other immature leukaemic cells from each other [53–58].*Myeloblasts of neutrophil lineage*

Small, medium or large granules; sometimes Auer rods, which may be homogeneous or composed of longitudinal tubules or dense material with a periodic substructure [55]

Promyelocytes of promyelocytic leukaemia

In hypergranular promyelocytic leukaemia the cytoplasm is packed with granules ranging from 120 to 1000 nm in diameter [56,57]; in the variant form of hypergranular promyelocytic leukaemia the granules are much smaller, ranging from 100 to 400 nm, with some cells being packed with granules and others being agranular. Auer rods in promyelocytic leukaemia differ from those in M1 and M2 acute myeloid leukaemia (AML); they are composed of hexagonal structures and have a different periodicity from other Auer rods [57]; microfibrils and stellate configurations of rough endoplasmic reticulum are also characteristic of M3 AML, particularly M3 variant [58]

Myeloblasts of eosinophil lineage

Granules tend to be larger than those of neutrophil series; homogeneous in early cells, in later cells having a crystalline core set in a matrix; sometimes there is asynchrony with granules lacking a central core, despite a mature nucleus. Auer rods similar to those of the neutrophil lineage may be present [55]

*Myeloblasts of basophil or mast cell lineage**

Basophil granules may be any of three types: (i) large, electron-dense granules composed of coarse particles; (ii) pale granules composed of fine particles; or (iii) θ granules, which are small granules containing pale flocculent material and bisected by a membrane [54]. Mast cell precursors sometimes have granules showing the scrolled or whorled pattern that is characteristic of normal mast cells

Monoblasts and promonocytes

Monoblasts are larger than myeloblasts and cytoplasm may be vacuolated. Granules are smaller and less numerous

Megakaryoblasts

More mature megakaryoblasts show α granules, bull's eye granules and platelet demarcation membranes

Early erythroid precursors

Immature cells can be identified as erythroid when they contain aggregates of ferritin molecules or iron-laden mitochondria or when there is rhopheocytosis (invagination of the surface membrane in association with extracellular ferritin molecules)

* Sometimes in myeloid leukaemias and myeloproliferative neoplasms there are cells containing a mixture of granules of basophil and mast cell type.

- 4) The demonstration of other antigens characteristic of myeloid cells by the use of monoclonal antibodies such as cluster of differentiation 13 (CD13), CD14, CD15, CD33, CD64, CD65 and CD117 (but without expression of platelet-specific antigens, which would lead to the case being categorised as AML M7).

Although not included in the criteria suggested by the FAB group, the demonstration of messenger RNA (mRNA) for MPO has also been suggested as a criterion for recognition of myeloid differentiation

[61] but its expression may not be restricted to myeloid cells [62].

Flow cytometric immunophenotyping is now widely used for identifying cases of M0 AML and as a consequence other techniques are now largely redundant. However, alternative techniques remain useful for the identification of immature cells of basophil, mast cell and eosinophil lineage. Immunophenotyping shows that the most specific lymphoid markers – CD3 and CD22 – are not expressed in M0 AML but there may be expression of less specific lymphoid-associated antigens such as CD2, CD4, CD7, CD10

Table 1.6 Ultrastructural cytochemistry in the identification of blast cells and other immature cells of different myeloid lineages [47,54,59,60].

Myeloblasts of neutrophil lineage

MPO activity in endoplasmic reticulum, perinuclear space, Golgi zone, granules and Auer rods (if present); detected by standard technique for MPO and by PPO techniques (reviewed in reference [47])

Myeloblasts of eosinophil lineage

MPO-positive granules and Auer rods (if present) detected by MPO and PPO techniques

Myeloblasts of basophil or mast cell lineage

Granules may be peroxidase positive or negative; endoplasmic reticulum, perinuclear space and Golgi zone are rarely positive; more cases are positive by PPO technique than MPO technique

Promyelocytes of acute promyelocytic leukaemia

MPO positivity is seen in granules, Auer rods, perinuclear space and some rough endoplasmic reticulum profiles [58]; strong lysozyme activity of granules and Auer rods is seen in M3 AML, whereas in M3 variant AML activity varies from weak to moderately strong [58]

Monoblasts and promonocytes

The first granule to appear in a monoblast is a small, peripheral acid phosphatase-positive granule [59]. MPO activity appears initially in the perinuclear envelope, Golgi apparatus and endoplasmic reticulum. Subsequently, mainly at the promonocyte stage, there are small MPO-positive granules. A PPO technique is more sensitive in the detection of peroxidase-positive granules than an MPO technique. Non-specific esterase activity can also be demonstrated cytochemically

Megakaryoblasts

PPO activity in endoplasmic reticulum and perinuclear space only [54,60]

Proerythroblasts

PPO-like activity may be present in the Golgi zone

AML, acute myeloid leukaemia; MPO, myeloperoxidase; PPO, platelet peroxidase.

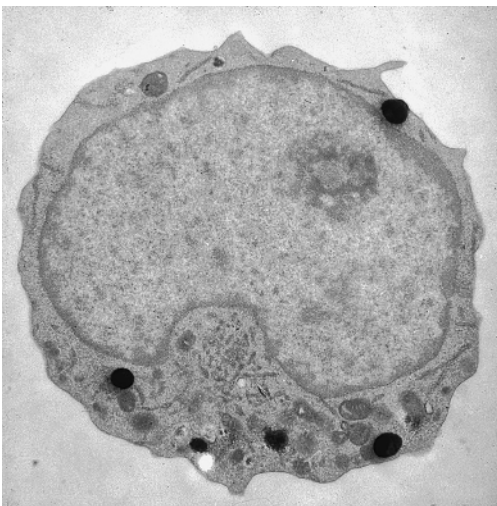


Fig. 1.9 Ultrastructural cytochemistry showing peroxidase-positive granules in a myeloblast. (By courtesy of the late Professor Daniel Catovsky.)

and CD19, in addition to CD34, human leucocyte antigen DR (HLA-DR) and terminal deoxynucleotidyl transferase (TdT). CD7 is more often expressed than in other FAB categories of AML [63].

M0 AML has been associated with older age, higher WBC, adverse cytogenetic abnormalities and poor prognosis [63–65]. The molecular genetic abnormalities recognised include a high incidence of loss-of-function mutations of the *RUNX1* gene, most of which are biallelic [63,66]. In a study of 20 genes in 67 patients with leukaemia defined according to FAB criteria, the genes most often found to be mutated were *FLT3* (28.4%), followed by mutations in *IDH1* or *IDH2* (28.8%), *RUNX1* (23.9%), *NRAS* or *KRAS* (12.3%), *TET2* (8.2%), *DNMT3A* (8.1%), *KMT2A* (7.8%) and *ASXL1* (6.3%) [67]. The gene expression profile of M0 AML is distinctive and differs between cases with and without *RUNX1* mutation; the latter show upregulation of B-lineage related genes [68]. In children, M0 AML has been

associated with a lower WBC, more frequent $-5/\text{del}(5q)$, more frequent $+21$, more frequent hypodiploidy and an inferior outcome [69].

Cytochemical reactions in M0 acute myeloid leukaemia

By definition fewer than 3% of blasts are positive for MPO, SBB and naphthol AS-D chloroacetate esterase (chloroacetate esterase, CAE) since a greater degree of positivity would lead to the case being classified as M1 AML. Similarly, blast cells do not show NSE activity, since positivity would lead to the case being classified as M5 AML. Maturing myeloid cells may show peroxidase deficiency or aberrant positivity for both chloroacetate and non-specific esterases [70]. Rarely there is block positivity on a PAS stain [71].

Acute myeloid leukaemia without maturation: M1 acute myeloid leukaemia

The criteria for diagnosis of M1 AML are shown in Table 1.7, and the cytological features are illustrated in Figs 1.10, 1.11, 1.12 and 1.13. M1 blasts are usually medium to large in size with a variable nucleocytoplasmic ratio, a round or oval nucleus, one or more nucleoli – which range from inconspicuous to prominent – and cytoplasm that sometimes contains Auer rods, a few granules or some vacuoles. Rarely bundles of Auer rods are found in mature neutrophils and metamyelocytes but not in blast cells [72]. Auer rods are crystalline cytoplasmic structures derived from primary granules either just after their formation in

Table 1.7 Criteria for the diagnosis of acute myeloid leukaemia of M1 category (acute myeloid leukaemia without maturation).

- Blasts $\geq 30\%$ of bone marrow cells
- Blasts $\geq 90\%$ of bone marrow non-erythroid cells*
- $\geq 3\%$ of blasts positive for peroxidase or Sudan black B
- Bone marrow maturing monocytic component (promonocytes to monocytes) $\leq 10\%$ of non-erythroid cells
- Bone marrow maturing granulocytic component (promyelocytes to polymorphonuclear leucocytes) $\leq 10\%$ of non-erythroid cells

* Exclude also lymphocytes, plasma cells, macrophages and mast cells from the count.

the cisternae of the Golgi apparatus or by coalescence of granules within autophagic vacuoles. They were first described by Thomas McCrae in 1905 and a year later by John Auer [73–76]. Auer rods are usually seen as cytoplasmic inclusions. Less often they form within a cytoplasmic vacuole or, rarely, within a pseudo-Chédiak–Higashi inclusion (Fig. 1.14) [37]. Similar structures have been reported in rare myeloid cells in the fetus [77], but otherwise these structures appear to be specific for myeloid neoplasms. In children, the presence of Auer rods has been found to be associated with a better prognosis [78]. In M1 AML the blasts are predominantly type I blasts. In some cases the blasts are indistinguishable from L2 or even L1 lymphoblasts (see page 56).

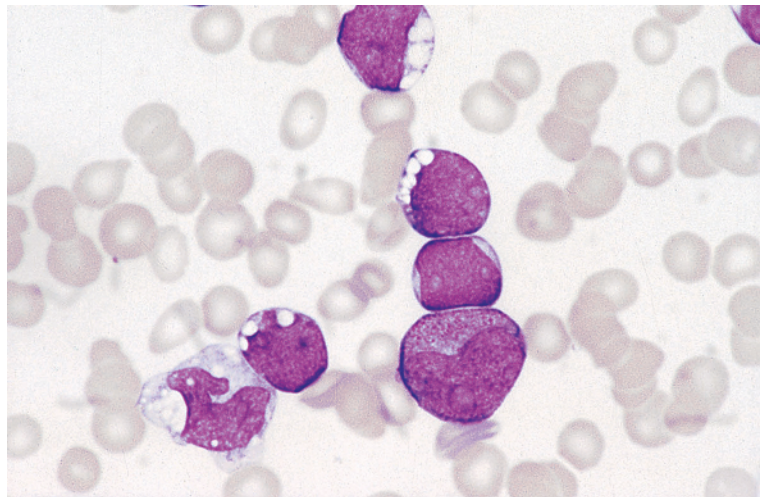


Fig. 1.10 PB film of a patient with FAB M1 AML showing type I and type II blasts, some of which are heavily vacuolated; a promyelocyte is also present. MGG $\times 100$.

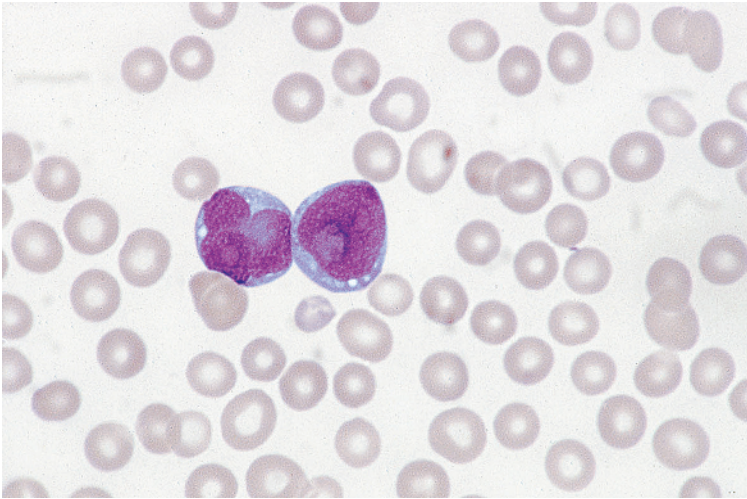


Fig. 1.11 PB film of a patient with FAB M1 AML showing type I blasts with cytoplasmic vacuolation and nuclear lobulation. MGG $\times 100$.

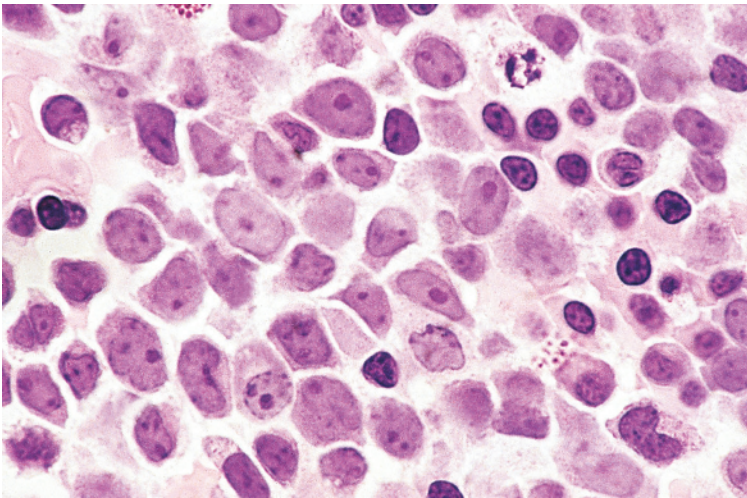


Fig. 1.12 Trephine biopsy section from a patient with FAB M1 AML. The majority of cells present are blasts with a high nucleocytoplasmic ratio and prominent nucleoli; there are also some erythroblasts. Resin embedded, haematoxylin and eosin (H&E) $\times 100$.

M1 AML is arbitrarily separated from M2 AML by the requirement that no more than 10% of non-erythroid cells in the bone marrow belong to the maturing granulocytic component (promyelocytes to neutrophils).

The M1 category accounts for 15–20% of AML.

Cytochemical reactions in M1 acute myeloid leukaemia

By definition, M1 AML has a minimum of 3% of blasts that are positive for MPO or SBB. Hayhoe and Quaglino [33] found that the SBB reaction is a more

sensitive marker of early granulocyte precursors than MPO. M1 blasts are usually positive for CAE, although this marker is usually less sensitive than either MPO or SBB in the detection of neutrophilic differentiation. Myeloblasts give a weak or negative reaction for a number of esterases that are more characteristic of the monocyte lineage, and that are collectively referred to as non-specific esterases. In the case of α -naphthyl acetate esterase (ANAE) and α -naphthyl butyrate esterase (ANBE) the reaction is usually negative, whereas in the case of naphthol AS-D acetate esterase (NASDA) there is usually a

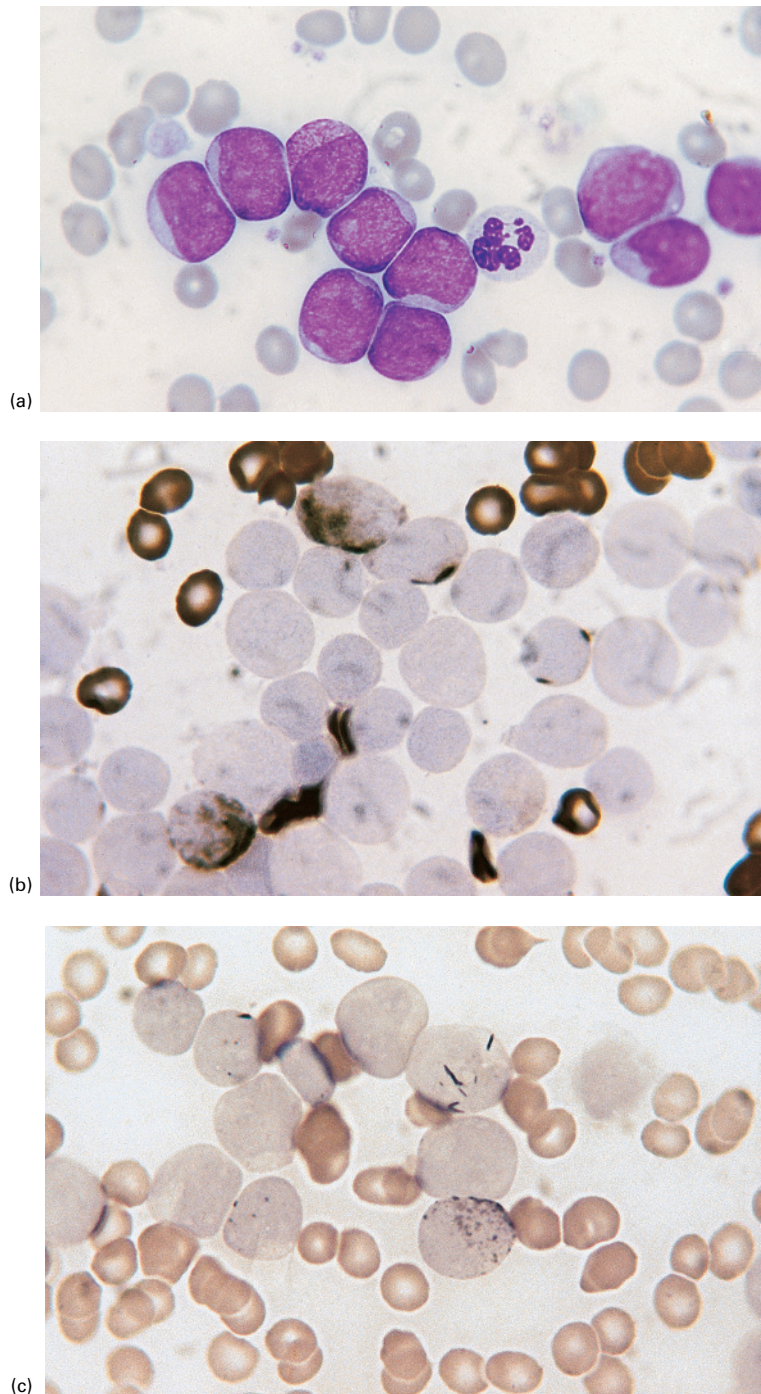


Fig. 1.13 Cytochemical reactions in a patient with FAB M1 AML. (a) MGG-stained PB film showing largely type I blasts, which in this patient are morphologically similar to lymphoblasts. One leukaemic cell is heavily granulated and would therefore be classified as a promyelocyte; this cell and the presence of a hypogranular neutrophil suggest that the correct diagnosis is M1 AML. MGG $\times 100$. (b) Myeloperoxidase (MPO)-stained BM film showing two leukaemic cells with peroxidase-positive granules and two with Auer rods. MPO $\times 100$. (c) Sudan black B (SBB) stain of a BM film showing some blasts with Auer rods and some with granules. SBB $\times 100$.

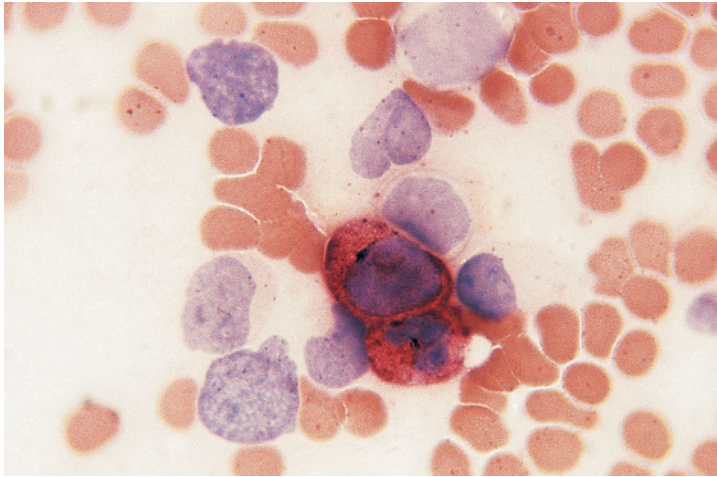


Fig. 1.13 (Continued)
(d) Chloroacetate esterase (CAE) stain of a BM film showing a positive neutrophil and a positive blast; other blasts present are negative. CAE $\times 100$.

weak fluoride-resistant reaction. Myeloblasts show diffuse acid phosphatase activity, which varies from weak to strong. The PAS reaction is usually negative, but may show a weak diffuse reaction with superimposed fine granular positivity.

Auer rods give positive MPO and SBB reactions and occasionally weak PAS reactions. The reaction for CAE is usually weak or negative [33]. Although Auer rods are often detectable on a Romanowsky stain, they are more readily detectable on an MPO or SBB stain and larger numbers are apparent. Sometimes they are detectable only with cytochemical stains. Typical cytochemical stains in a case of M1 AML are shown in Fig. 1.13.

Acute myeloid leukaemia with maturation:

M2 acute myeloid leukaemia

The criteria for the diagnosis of M2 AML are shown in Table 1.8. In this context, cells included in the maturing granulocytic category are promyelocytes, myelocytes, metamyelocytes and granulocytes, and also cells that differ cytologically from normal promyelocytes but that are too heavily granulated to be classified as blasts when using FAB criteria. Typical cytological and cytochemical features in M2 AML are shown in Figs 1.15, 1.16 and 1.17. In contrast to M1 AML, blasts are often predominantly type II. Auer rods may be present. In children, Auer rods have been associated with a better prognosis [78], probably because of an association between Auer

rods and t(8;21) (see Chapter 3). Dysplastic features, such as hypo- or hypergranularity or abnormalities of nuclear shape are common in the differentiating granulocytic component of M2 AML. Maturation of myeloblasts to promyelocytes occurs in both M2 and M3 AML, and promyelocytes are prominent in some cases of M2 AML. Such cases are distinguished from M3 AML by the lack of the specific features of the latter condition (see later in this chapter). M2 AML is distinguished from M4 AML by the monocytic component in the bone marrow being less than 20% of non-erythroid cells and by the lack of other evidence of significant monocytic differentiation. In most cases of M2 AML, maturation is along the neutrophil pathway but eosinophilic or basophilic maturation occurs in a minority. Such cases may be designated M2Eo or M2Baso. Other morphologically distinctive categories within M2, associated with specific cytogenetic abnormalities, are recognised (see Chapter 3).

The M2 subtype accounts for about 30% of cases of AML.

Cytochemical reactions in M2 acute myeloid leukaemia

The cytochemical reactions in M2 AML are the same as those in M1 AML, but generally reactions are stronger and a higher percentage of cells are positive with MPO and SBB stains. CAE is more often positive in M2 than in M1 AML and reactions

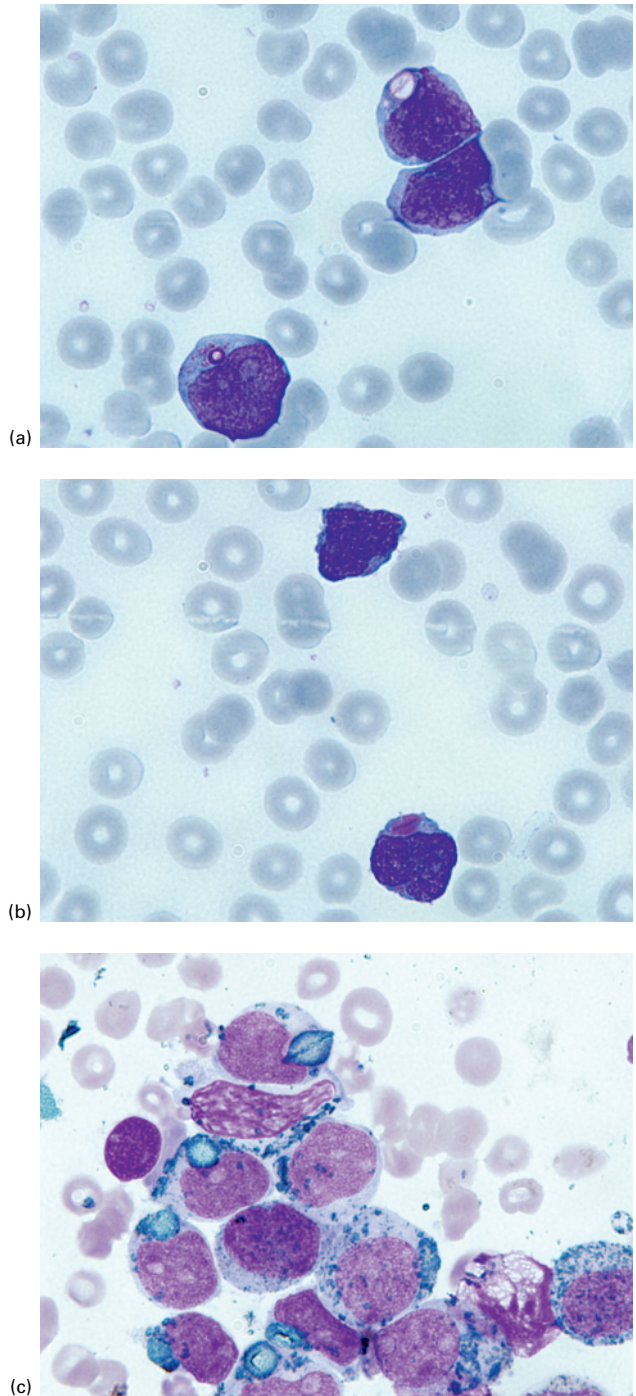


Fig. 1.14 Unusual forms of Auer rod. (a) PB film showing an Auer rod within a vacuole. MGG $\times 100$. (b) PB film showing an Auer rod within a pseudo-Chédiak-Higashi granule. MGG $\times 100$. (c) BM film showing, at the top, an Auer rod forming within a pseudo-Chédiak-Higashi granule. MPO $\times 100$. (With thanks to Dr Songshan Zhu, Guangxi, China.)

Table 1.8 Criteria for the diagnosis of acute myeloid leukaemia of M2 category (acute myeloid leukaemia with maturation*).

- Blasts $\geq 30\%$ of bone marrow cells
- Blasts 30–89% of bone marrow non-erythroid cells
- Bone marrow maturing granulocytic component (promyelocytes to polymorphonuclear leucocytes) $>10\%$ of non-erythroid cells
- Bone marrow monocytic component (monoblasts to monocytes) $<20\%$ of non-erythroid cells and other criteria for M4 not met

* Granulocytic maturation is intended.

are stronger. Auer rods show the same staining characteristics as in M1 AML but are likely to be more numerous. The reaction for CAE is usually weak or negative [33] except in M2 AML associated with t(8;21) in which Auer rods are often positive for CAE [32]. When leukaemic myeloblasts undergo maturation, as occurs in M2 AML, there may be a population of neutrophils, presumably derived from leukaemic blasts, that lack SBB and MPO activity. This may be demonstrated cytochemically or by means of an automated differential counter based on the peroxidase reaction, which shows a low mean peroxidase score and an abnormally placed

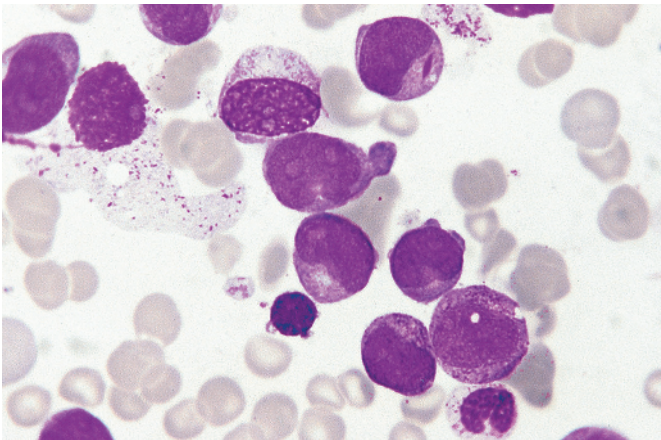
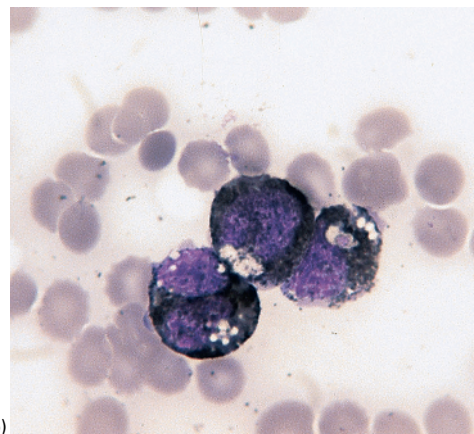
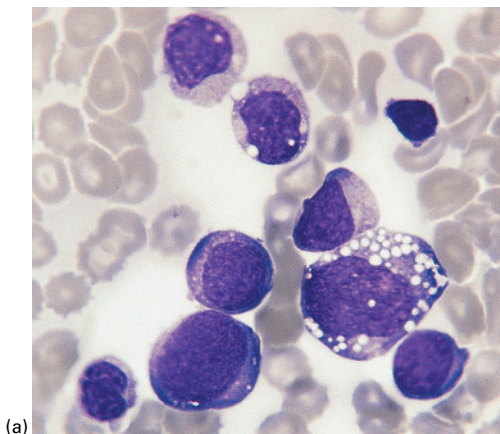


Fig. 1.15 BM film of a patient with FAB M2 AML showing blasts (one of which contains an Auer rod), promyelocytes and a neutrophil. Note the very variable granulation. MGG $\times 100$.



(a)

(b)

Fig. 1.16 BM film of a patient with FAB M2 AML stained by (a) MGG and (b) SBB. In this patient both blasts and maturing cells were heavily vacuolated. $\times 100$.

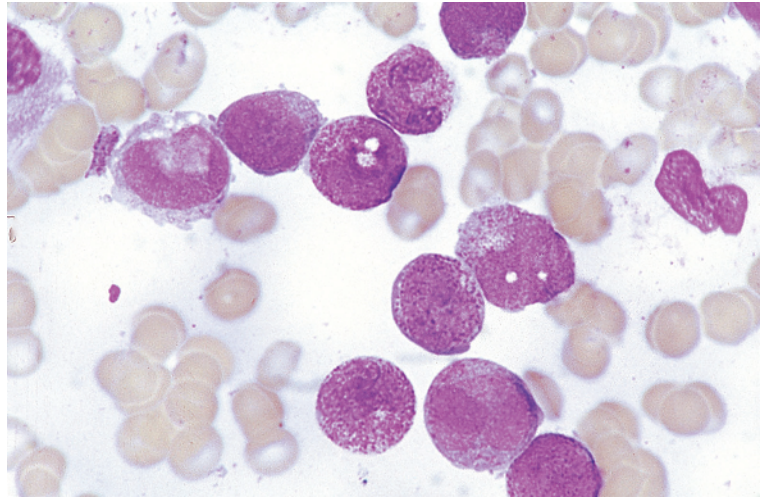


Fig. 1.17 BM film of a patient with FAB M2 AML showing unusually heavy granulation of neutrophils and precursors. MGG $\times 100$. (By courtesy of the late Dr David Swirsky.)

neutrophil cluster. The neutrophil cluster with such automated instruments is often dispersed in AML in contrast to the normal compact cluster in ALL. The NAP score is often low in M2 AML but this test is redundant.

**Acute hypergranular promyelocytic leukaemia:
M3 acute myeloid leukaemia**

In acute hypergranular promyelocytic leukaemia, the predominant cell is a highly abnormal promyelocyte. In the majority of cases, blasts are fewer than 30% of bone marrow nucleated cells. The distinctive cytological features are sufficient to permit a diagnosis, and cases are classified as M3 AML despite the low blast percentage. M3 AML is associated with a specific cytogenetic abnormality, $t(15;17)(q24.1;q21.2)$, and with abnormal coagulation. There is disseminated intravascular coagulation and activation of fibrinolysis, resulting in abnormal bleeding and bruising (Fig. 1.18). This diagnosis can sometimes be suspected from the prominent haemorrhagic manifestations. However, there can also be venous thromboembolism including presentation with pulmonary embolism (Fig. 1.19) [79]. Typical cytological and histological features are shown in Figs 1.20, 1.21 and 1.22. The predominant cell is a promyelocyte, the cytoplasm of which is densely packed with coarse red or purple granules, which can obscure the nucleus. There is often nucleocyto-

plasmic asynchrony, with the nucleus having a diffuse chromatin pattern and one or more nucleoli. When the nuclear shape can be discerned it is found, in the majority of cases, to be reniform or folded or bilobed with only a narrow bridge between the two lobes. The nuclear form is often more apparent on histological sections (Fig. 1.22). Auer rods are common. In one series they were noted in fewer than 50% of cases [80], but others have observed them to be almost always present, at least in a minority of cells [81]. In some cases there are giant granules or multiple Auer rods, which are often present in sheaves or 'faggots' (Fig. 1.21). Bundles of Auer rods are uncommon in other types of AML but are occasionally seen, reported, for example, in a patient with acute myelomonocytic leukaemia with eosinophilia associated with $inv(16)$ [82] and in a patient with $del(5q)$ without rearrangement of *RARA* [83]. Rarely rectangular peroxidase-negative crystals are present [84]. Most cases have a minority of cells that are agranular, have sparse granules or have fine red or rust-coloured dust-like granules rather than coarse, brightly staining granules. Cells that lack granules but have lakes of hyaline pink material in the cytoplasm may also be seen. There may be basophilic differentiation in M3 AML, in addition to the dominant neutrophilic differentiation [85]. Occasionally, the percentage of blast cells plus abnormal promyelocytes is less than 20% [86] and

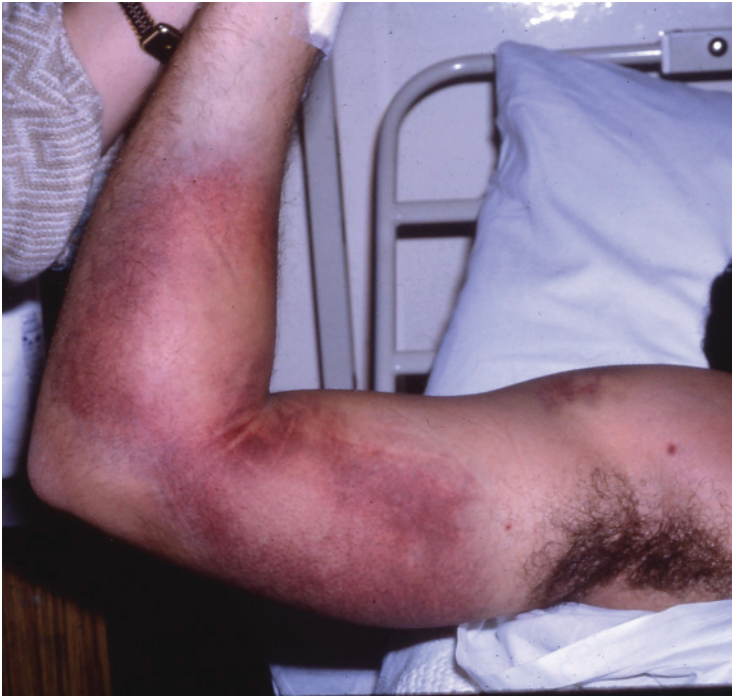

Fig. 1.18 Clinical photograph of a patient with FAB M3 AML showing extensive spontaneous bruising of the arm.

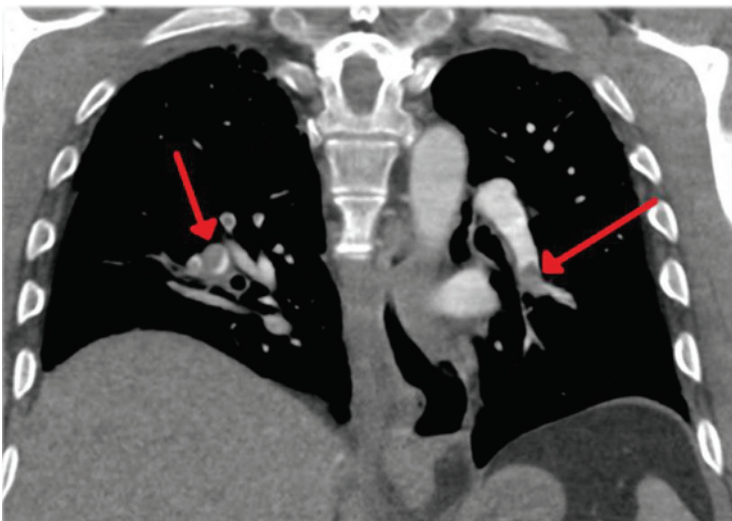


Fig. 1.19 Computed tomography scan of the chest showing bilateral pulmonary emboli. (With thanks to Dr Richard Dillon, London.)

rarely presentation is as a granulocytic sarcoma with the peripheral blood, bone marrow aspirate and trephine biopsy sections being normal [87]. Rarely Auer rods are present pre-treatment

in mature neutrophils. Following treatment with all-*trans*-retinoic acid (ATRA), neutrophils containing numerous Auer rods can appear in the peripheral blood film. Bone marrow macrophages may contain

Fig. 1.20 BM film of a patient with FAB M3 AML showing hypergranular promyelocytes, one of which has a giant granule. MGG $\times 100$.

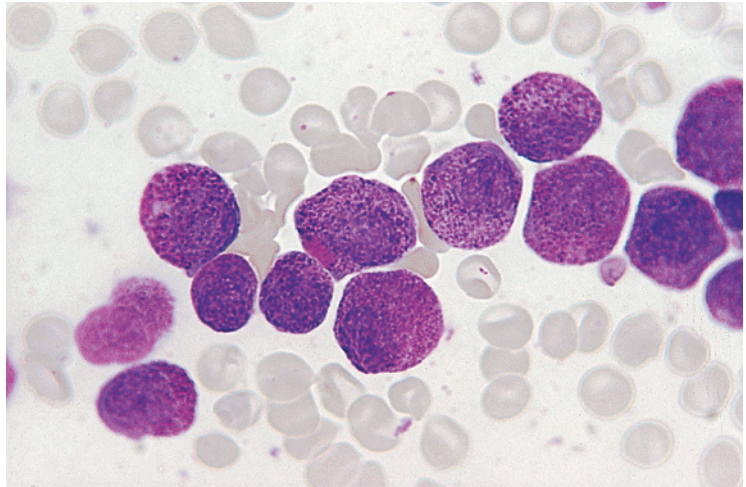
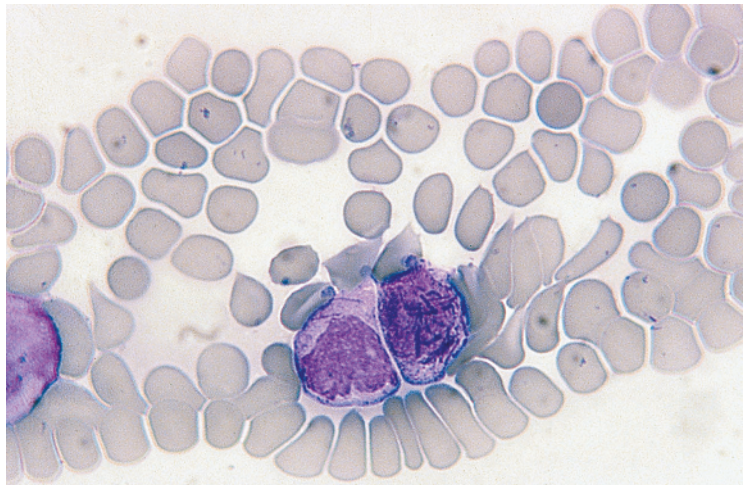


Fig. 1.21 PB film of a patient with FAB M3 AML. One of the abnormal promyelocytes contains loose bundles of Auer rods. MGG $\times 100$.



giant granules or Auer rods derived from ingested leukaemic cells (Fig. 1.23). Auer rods can persist in macrophages after the patient has entered complete remission [88]. Dysplastic changes in the erythroid and megakaryocyte lineages are usually absent.

Examining an adequate bone marrow aspirate is particularly important in M3 AML, as the WBC is often low and, even when there is a leucocytosis, typical hypergranular promyelocytes may not be present in the blood. The specimen may clot during attempted aspiration, as a consequence of the

associated hypercoagulable state, but usually sufficient cells are obtained for diagnosis.

M3 AML has been found to be very sensitive to the differentiating capacity of ATRA. Following such therapy an increasing proportion of cells beyond the promyelocyte stage are apparent. Maturing cells are cytologically abnormal (Fig. 1.24). Metamyelocytes and neutrophils may contain Auer rods [89]. The neutrophil count rises and in some patients also the basophil count [90]. Following treatment with ATRA, the terminally differentiated

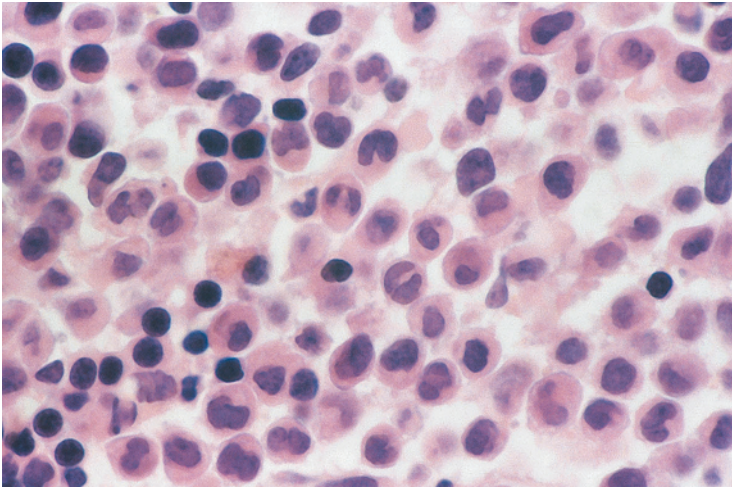


Fig. 1.22 Trephine biopsy section from a patient with FAB M3 AML. Paraffin embedded, H&E $\times 100$.

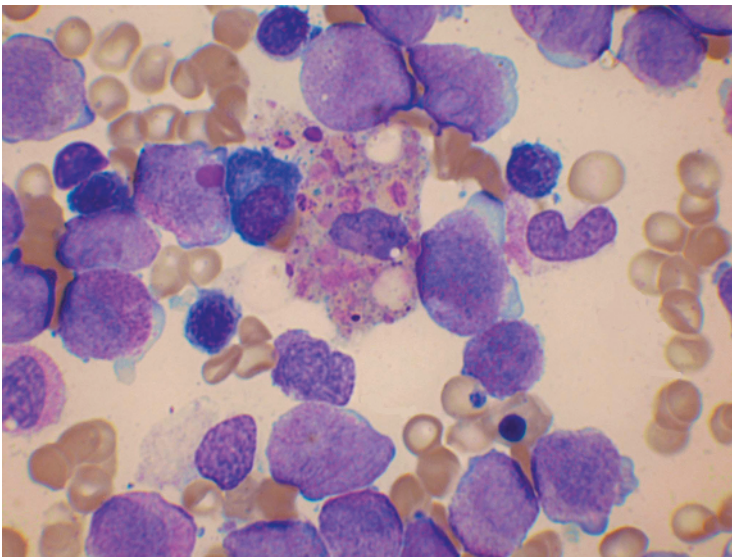


Fig. 1.23 BM film from a patient with acute promyelocytic leukaemia a few days after starting treatment with all-*trans*-retinoic acid (ATRA): one leukaemic cell contains a giant granule; a prominent macrophage contains granules and Auer rods from ingested leukaemic cells. MGG $\times 100$.

cells in a late stage of apoptosis are engulfed by bone marrow macrophages [91]. M3 AML is also responsive to treatment with arsenic trioxide, As_2O_3 . Hyperleucocytosis may occur during therapy with both ATRA and arsenic trioxide [92].

Rarely acute promyelocytic leukaemia represents transformation of a myeloproliferative neoplasm, either CML or primary myelofibrosis, in which case it is classified as secondary AML [93].

The variant form of acute promyelocytic leukaemia: M3 variant acute myeloid leukaemia

Some years after the initial description of hypergranular promyelocytic leukaemia it was noted that there were other cases of acute leukaemia that showed the same cytogenetic abnormality and coagulation abnormality but were cytologically different. Such cases were recognised as a variant form

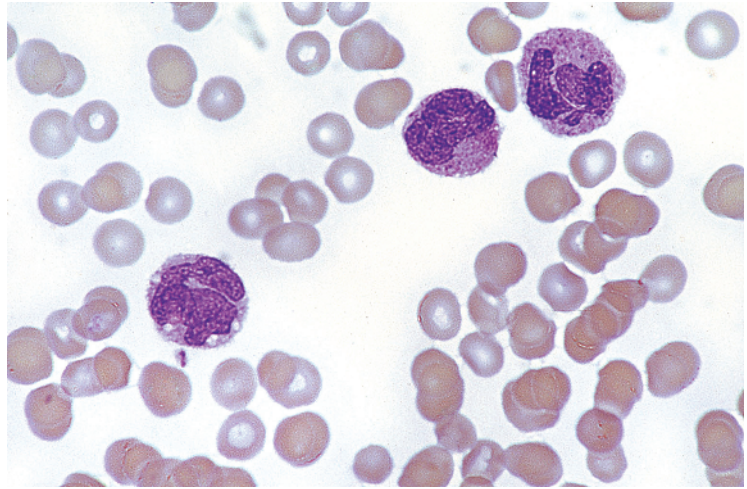


Fig. 1.24 PB film of a patient with FAB M3 AML being treated with ATRA and granulocyte colony-stimulating factor (G-CSF); leukaemic promyelocytes are undergoing maturation into highly abnormal cells. MGG $\times 100$.

of promyelocytic leukaemia, designated microgranular or hypogranular promyelocytic leukaemia [94–96]. Such cases were subsequently incorporated into the FAB classification as M3 variant AML. In addition to cytogenetic and molecular evidence indicating the close relationship of M3 and M3V AML, it has been noted that the cells of M3V may show a marked increase in granularity on culture (Fig. 1.25) [96] and, conversely, cases of M3 AML may have less granular cells on relapse [57]. There is not a clear demarcation between cases of classical M3 AML and the variant form – cases with intermediate features are seen. This is not surprising since these are morphological variants of a single biological entity.

Most cases of M3V AML are characterised by a cell with a reniform, bilobed, multilobed or convoluted nucleus and either sparse fine granules or apparently agranular cytoplasm (Fig. 1.26). A variable proportion of cells may have multiple Auer rods, fine dust-like granules, or large oval, elliptiform or somewhat angular cytoplasmic inclusions with the same staining characteristics as primary granules. Typical hypergranular promyelocytes constitute a small minority of the leukaemic cells in the peripheral blood but they are usually more numerous in the bone marrow. On ultrastructural examination, the granules are smaller and usually less numerous than in hypergranular promyelocytic leukaemia

(Fig. 1.27) [57]. The WBC is usually higher in M3V than in M3 AML.

In a minority of cases of M3V AML the characteristic cell is a small, abnormal promyelocyte with the same lobulated nucleus as described previously but with hyperbasophilic cytoplasm; cytoplasmic projections are sometimes present so that cells may resemble megakaryoblasts (Fig. 1.28) [57]. Hypergranular promyelocytes and Auer rods may be totally absent [97]. However, it is important to examine crushed cells in blood films as Auer rods may then be apparent [98]. Hyperbasophilic promyelocytes are seen in the majority of cases of M3V AML, but usually as a minor population. On ultrastructural examination, there are sparse small granules and, in addition, abundant dilated rough endoplasmic reticulum (Fig. 1.27) [57]. Occasional cases have a hand-mirror conformation [99].

M3V may be confused with acute monocytic leukaemia (M5b) if blood and bone marrow cells are not examined carefully and if the diagnosis is not considered. The use of an automated blood cell counter based on cytochemistry (MPO or SBB) is useful for the rapid distinction between M3V and M5 AML (see Fig. 1.72). When M3V appears likely from the cytological and cytochemical features, the diagnosis can be confirmed by cytogenetic, molecular genetic or immunophenotypic analysis.

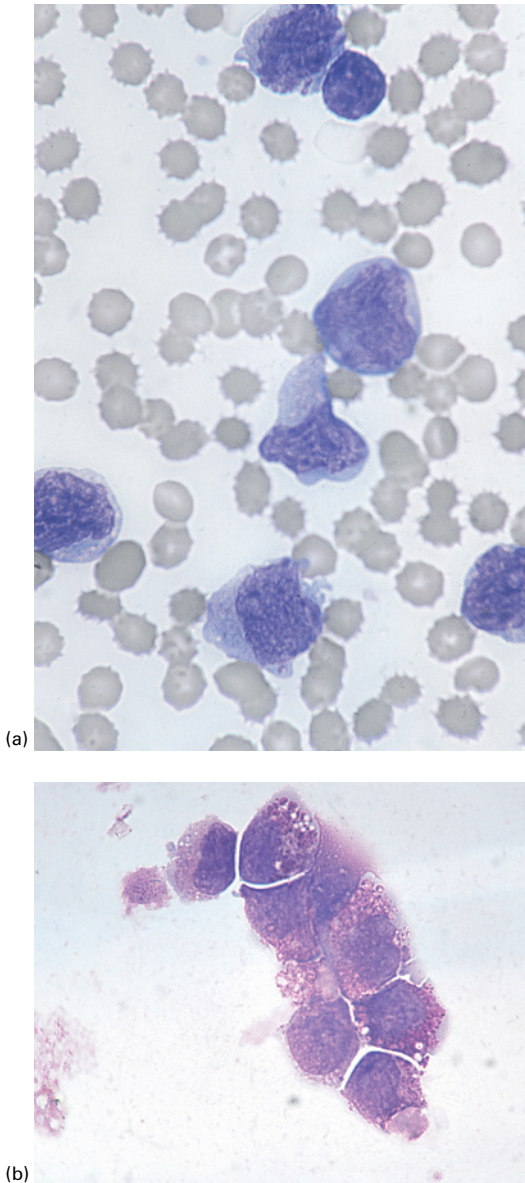


Fig. 1.25 (a) PB film and (b) film of cultured leukaemic cells from a patient with FAB M3 variant AML showing the acquisition of granules on culture. MGG $\times 100$. (By courtesy of the late Professor David Grimwade.)

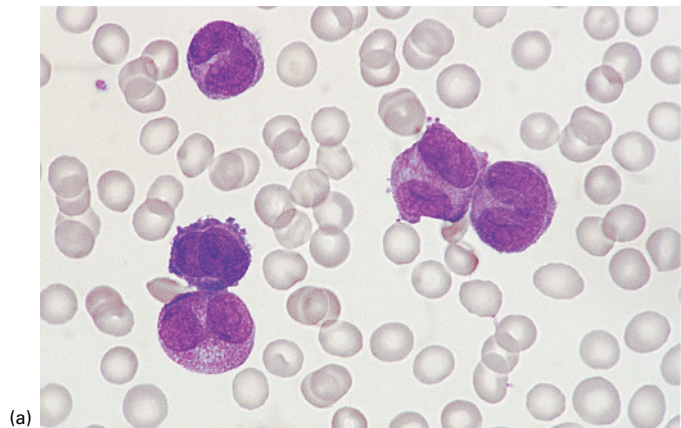
When treated with chemotherapy alone, the prognosis of M3 variant was somewhat worse than that of M3 AML [100]. This is likely to be related

to the higher WBC, since the WBC is of prognostic importance in M3/M3V AML [65], and the greater prevalence of a secondary mutation, an internal tandem duplication of the *FLT3* gene (*FLT3*-ITD). As a higher WBC remains an adverse prognostic feature when M3/M3V AML is treated with ATRA plus chemotherapy [100] it is likely that M3V also has a worse prognosis with combined modality treatment.

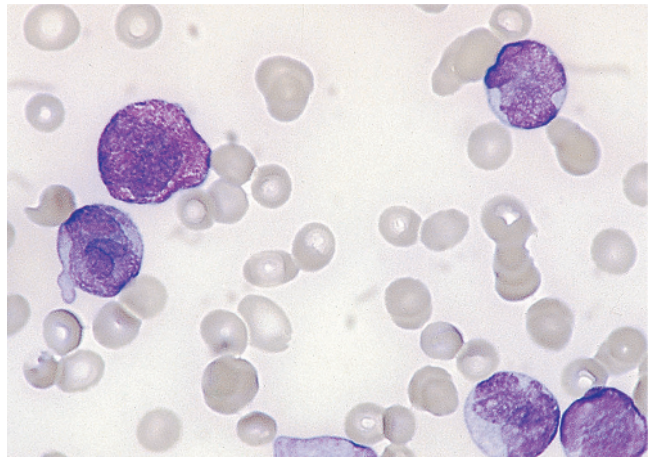
M3 and M3V AML usually together constitute 5–10% of cases of AML but in Hispanics promyelocytic leukaemia is more frequent.

Cytochemical reactions in M3 and M3 variant acute myeloid leukaemia

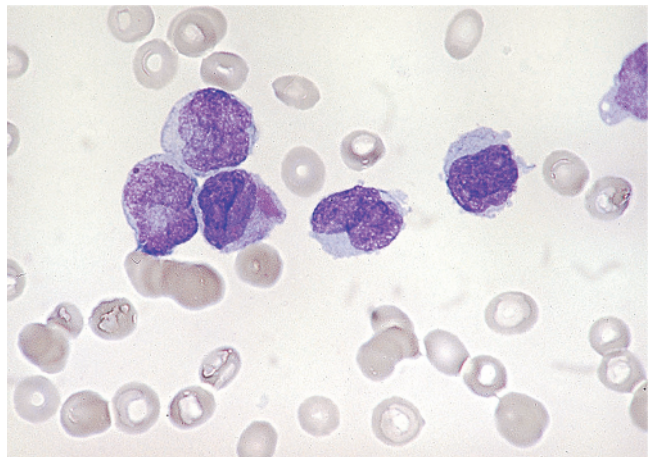
Hypergranular promyelocytes are usually strongly positive with MPO, SBB and CAE stains although cases have been described that were MPO and SBB negative but strongly CAE positive [101]. In a unique patient, promyelocytes were peroxidase negative although neutrophils were positive; this was the result of uniparental disomy for a mutation of the *MPO* gene [102]. The PAS reaction usually shows a cytoplasmic 'blush' – a fine diffuse or dust-like positivity; the reaction is stronger than in M1 or M2 AML. PAS-positive erythroblasts are not generally seen. The acid phosphatase reaction is strongly positive. M3V AML usually shows similar cytochemical reactions (Fig. 1.29) [57] but sometimes the reactions are weaker [103]. A potentially confusing cytochemical reaction in both M3 and M3V AML is the presence in some cases of NSE activity [56,57,80], a reactivity otherwise characteristic of monocytic rather than granulocytic differentiation. ANAE, ANBE and NASDA may be positive and, as for the monocytic lineage, the reaction is fluoride sensitive. The reaction is weaker than in monocytes, and isoenzymes characteristic of the monocytic lineage are not present [103]. Some cells show double staining for NSE and CAE. Cases that are positive for ANAE tend to have a weaker reaction for CAE, and occasionally the MPO reaction is unexpectedly weak [80]. The minority of cases that are positive for NSE do not appear to differ from other cases with regard to morphology, haematological or cytogenetic findings, or prognosis [80].



(a)



(b)



(c)

Fig. 1.26 (a) PB film of a patient with FAB M3 variant AML showing cells with bilobed and reniform nuclei and sparse, fine granules. One binucleate cell is present and another cell is characterised by basophilic cytoplasm and cytoplasmic projections. MGG $\times 100$. (b, c) PB film of another patient with FAB M3 variant AML showing: (b) predominantly agranular cells with twisted nuclei but with one typical hypergranular cell being present; (c) agranular cells with twisted nuclei; one cell contains a large azurophilic inclusion. MGG $\times 100$.

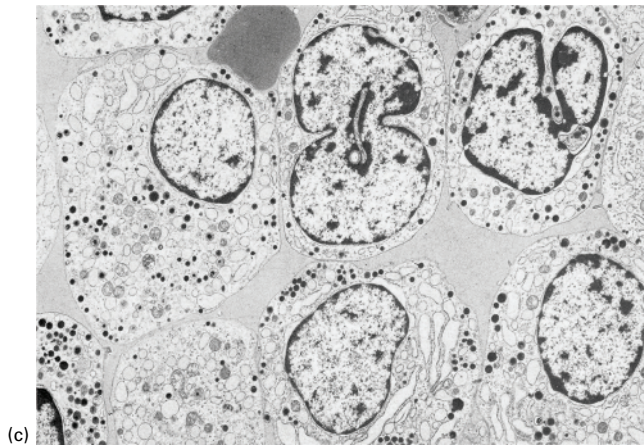
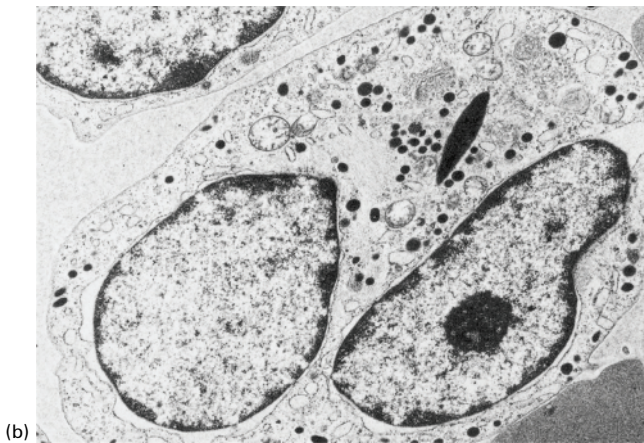
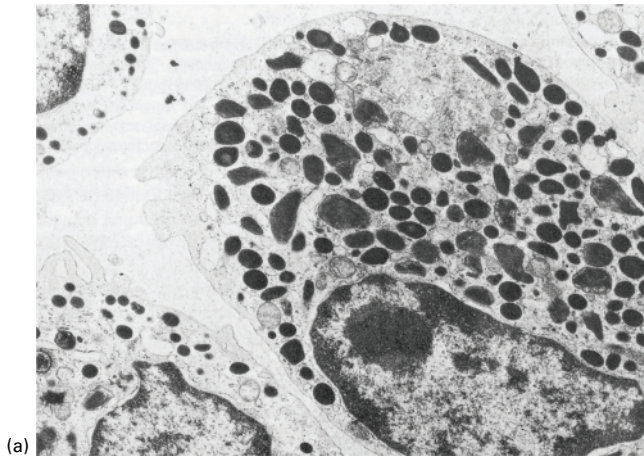
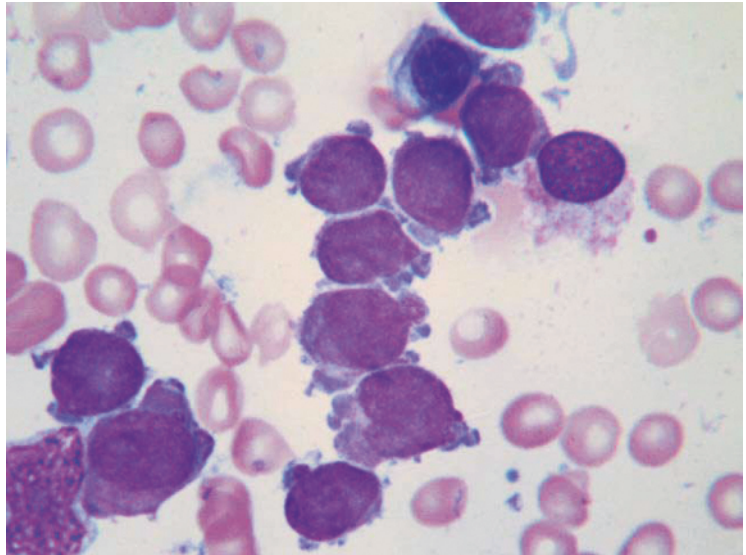


Fig. 1.27 Ultrastructural examination of leukaemic cells of three patients with acute promyelocytic leukaemia: (a) typical M3 AML showing granules that are numerous and large; (b) M3 variant AML showing a lobulated nucleus, granules that are smaller and more sparse and one Auer rod; (c) hyperbasophilic M3 variant AML showing fewer and smaller granules than in typical M3 AML plus abundant dilated rough endoplasmic reticulum. Uranyl acetate, lead citrate stain. (With thanks to Dr Robert McKenna, Minnesota, and by courtesy of the British Journal of Haematology.)

Fig. 1.28 BM film from a patient with the hyperbasophilic variant of acute promyelocytic leukaemia showing abnormal promyelocytes with blebbed basophilic cytoplasm; some also have a dusting of fine cytoplasmic granules. MGG $\times 100$.



Cases with basophilic differentiation show metachromatic staining with toluidine blue.

Auer rods in M3 AML are SBB, MPO and CAE positive, whereas in other categories of AML they are usually negative with CAE; they may be PAS positive [104]. On SBB, MPO and CAE staining, the core of the rod may be left unstained, and occasionally the core is ANAE positive on a mixed esterase stain [33].

Acute myelomonocytic leukaemia:

M4 acute myeloid leukaemia

The criteria for the diagnosis of AML of M4 subtype, that is, AML with both granulocytic and monocytic differentiation, are shown in Table 1.9 and typical cytological and histological features in Figs 1.30 and 1.31. The criterion for recognition of a significant granulocytic component is a morphological one; the granulocytic component, which in this context includes myeloblasts as well as maturing cells, must be at least 20% of non-erythroid cells. The recognition of a significant monocytic component requires two criteria to be satisfied, both of which may be morphological or one morphological and the other cytochemical, as shown in Table 1.9. In assessing the monocytic component, monoblasts, promonocytes and monocytes are included in the count.

The FAB criteria for the recognition of monocytic differentiation are the presence of fluoride-sensitive naphthol AS acetate esterase (NASA) or NASDA activity [25], or the presence of ANAE activity [28]. ANBE activity would also identify monocytic differentiation. Alternatively, lysozyme activity of leukaemic cells can be demonstrated cytochemically or lysozyme concentration can be measured in serum or urine, an elevation to more than three times the normal value being regarded as significant [28]. Careful examination of the peripheral blood is important if all cases of M4 AML are to be recognised since the bone marrow is sometimes morphologically indistinguishable from that of M2 AML. In M4 AML, the granulocytic differentiation is usually along the neutrophil pathway, but in some cases it is eosinophilic (M4Eo) (Fig. 1.31), basophilic (M4Baso) or both (Fig. 1.32). A rare observation is the presence of grey-green crystals in bone marrow macrophages [105]. When there is eosinophilic differentiation, Charcot–Leyden crystals may be seen.

The M4 subtype accounts for 15–20% of cases of AML.

Cytochemical reactions in M4 acute myeloid leukaemia

In M4 AML some leukaemic cells show cytochemical reactions typical of neutrophilic, eosinophilic or

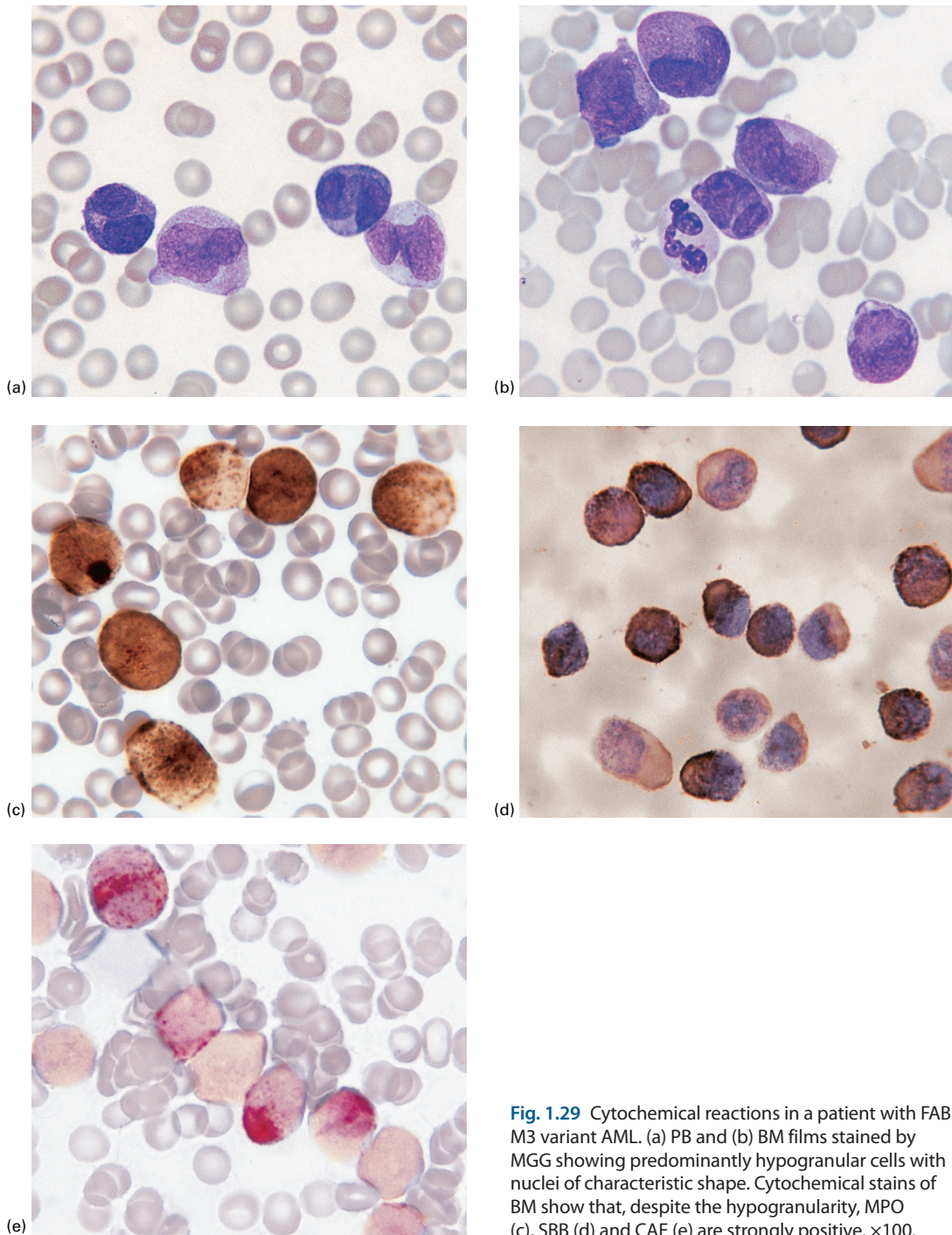


Fig. 1.29 Cytochemical reactions in a patient with FAB M3 variant AML. (a) PB and (b) BM films stained by MGG showing predominantly hypogranular cells with nuclei of characteristic shape. Cytochemical stains of BM show that, despite the hypogranularity, MPO (c), SBB (d) and CAE (e) are strongly positive. $\times 100$.

Table 1.9 Criteria for the diagnosis of acute myeloid leukaemia of M4 category (acute myelomonocytic leukaemia).

- Blasts $\geq 30\%$ of bone marrow cells
- Blasts $\geq 30\%$ of bone marrow non-erythroid cells
- Bone marrow granulocytic component (myeloblasts to polymorphonuclear leucocytes) $\geq 20\%$ of non-erythroid cells
- Significant monocytic component as shown by one of the following:
 - bone marrow monocytic component (monoblasts to monocytes) $\geq 20\%$ of non-erythroid cells and peripheral blood monocytic component $\geq 5 \times 10^9/l$, *or*
 - bone marrow monocytic component (monoblasts to monocytes) $\geq 20\%$ of non-erythroid cells and confirmed by cytochemistry or increased serum or urinary lysozyme concentration, *or*
 - bone marrow resembling M2 but peripheral blood monocyte component $\geq 5 \times 10^9/l$ and confirmed by cytochemistry or increased serum or urinary lysozyme concentration

basophilic lineages while other cells show reactions typical of the monocytic lineage (see earlier in this chapter). A double esterase stain for CAE (neutrophil lineage) and ANAE (monocyte lineage) [106] is a convenient method for demonstrating the pattern of differentiation and maturation in M4 AML (Fig. 1.32c).

Acute monocytic/monoblastic leukaemia:

M5 acute myeloid leukaemia

The criteria for the diagnosis of acute monocytic/monoblastic leukaemia, M5 AML, are shown in Table 1.10, and typical cytological and histological features in Figs 1.33, 1.34, 1.35 and 1.36. This diagnosis may be suspected from clinical features when there is infiltration of the skin and the gums (Figs 1.37 and 1.38). Disseminated intravascular coagulation and increased fibrinolysis are more common in M5 AML than in other categories of AML, with the exception of M3 [107]. M5 AML is further subdivided into M5a AML (acute monoblastic leukaemia) and M5b AML (acute monocytic leukaemia) on the basis of whether monoblasts comprise at least 80% of the total bone marrow monocytic component. Auer rods are quite uncommon in M5 AML. There is often disorderly maturation leading to cells of monocytic lineage with nucleocytoplasmic asynchrony and other dysplastic features. This can make it difficult to assign cells reliably to monoblast, promonocyte and immature monocyte categories. Leukaemic cells in the peripheral blood may be more mature than those in the bone marrow (Fig. 1.35). Occasionally leukaemic cells are phagocytic, particularly but not only in patients with t(16;21)(p11.2;q22.2) or with t(8;16)

(p11.2;p13.3) or a related abnormality [108]; in one patient with a normal karyotype the clinicopathological features of a haemophagocytic syndrome were present [109]. Two patients have been reported with nuclear fragments or micronuclei associated with the presence of double minute chromosomes [110,111]. Monocytic differentiation can be confirmed by cytochemistry and by measurement of urinary and serum lysozyme concentrations but immunophenotyping is more useful.

In a rare form of acute monocytic leukaemia, cells have cytological features resembling those of macrophages or histiocytes (Fig. 1.39). This may be regarded as the leukaemic phase of malignant histiocytosis. The designation M5c has been suggested [112].

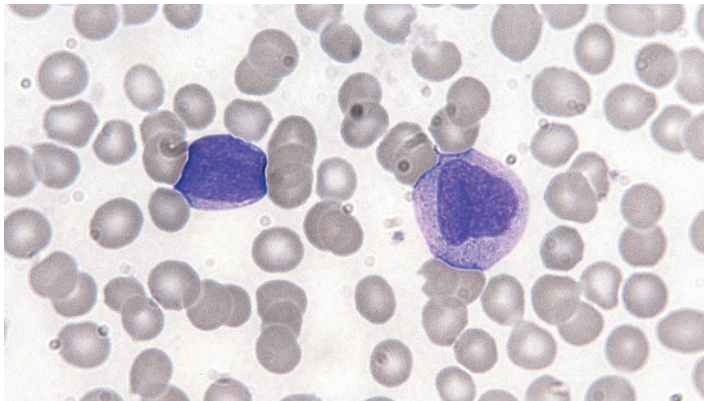
M5a and M5b are cytogenetically and genetically distinct. M5a has a significantly higher prevalence of cytogenetic abnormalities with an 11q23 breakpoint and *KMT2A* rearrangement, and also of isolated trisomy 8 [113]; it has a lower prevalence of *FLT3*-ITD.

There is some evidence that M5 AML is more sensitive than other types of AML to certain anti-leukaemic drugs, specifically etoposide, cytarabine, anthracyclines, vincristine, asparaginase and cladribine [114].

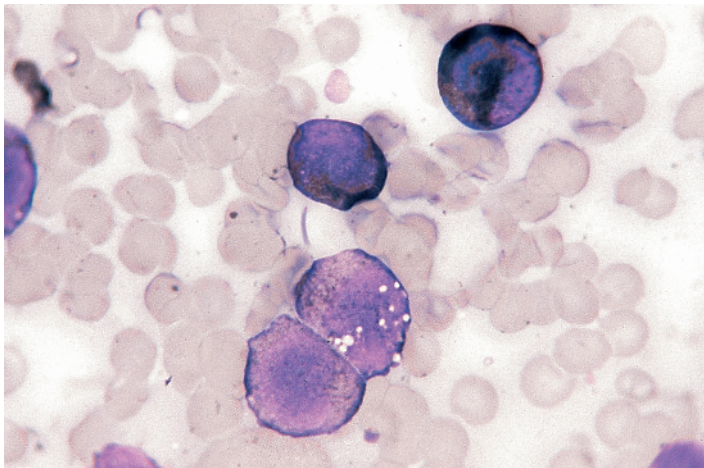
The M5 subtype accounts for about 15% of cases of AML.

Cytochemical reactions in M5 acute myeloid leukaemia

In M5a AML, MPO and SBB reactions are often negative, although a few fine, positive granules may be present. CAE is negative or very weak. Hayhoe and



(a)



(b)

Fig. 1.30 (a) PB film of a patient with FAB M4 AML showing a myeloblast of medium size with a high nucleocytoplasmic ratio and a monoblast that is larger with more plentiful cytoplasm and a folded nucleus with a lacy chromatin pattern. MGG $\times 100$. (b) BM of the same patient stained with SBB showing two monoblasts with a weak granular reaction and two cells of the granulocytic series with a much stronger reaction. SBB $\times 100$.

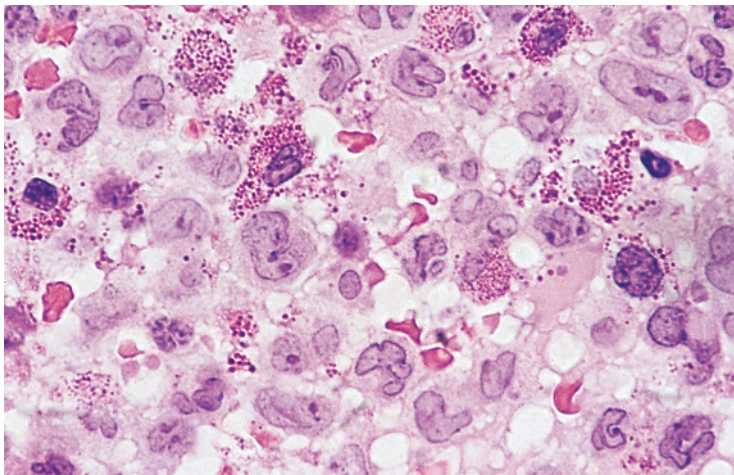


Fig. 1.31 Trehphine biopsy section from a patient with M4Eo AML. Cells are either monoblasts/promonocytes, recognised as large cells with round or lobulated nuclei containing prominent nucleoli, or eosinophils. Resin embedded, H&E $\times 100$.

Quaglino [33] found SBB to be more sensitive than MPO in detecting monocytic differentiation; they noted that, with SBB, granules in monoblasts were usually scattered and fine whereas in myeloblasts the reaction was either localised or filled all the cytoplasm. Monoblasts were characteristically negative for MPO. Monoblasts are usually strongly positive for NSE, that is, for ANAE (Fig. 1.40a), ANBE, NASA (Fig. 1.40b, c) and NASDA. All these esterase activities are inhibited by fluoride, but only in the case of NASA and NASDA is it necessary to carry out the reaction with and without fluoride to convey specificity; in the case of ANAE and ANBE, the reaction is negative or weak in cells of the granulocytic lineage. Aberrant esterase reactions are sometimes seen; occasional cases have negative reactions for NSE, whereas other cases, when the reaction for NSE is very strong, give a positive reaction also for CAE. Monoblasts show diffuse acid phosphatase activity, which, along with NSE activity, appears in advance of SBB and MPO reactivity. Lysozyme activity, which appears at about the same time as MPO activity, can be demonstrated cytochemically (Fig. 1.40d). The PAS reaction of monoblasts is either negative or diffusely positive with a superimposed fine or coarse granular positivity or, occasionally, superimposed PAS-positive blocks (Fig. 1.40e).

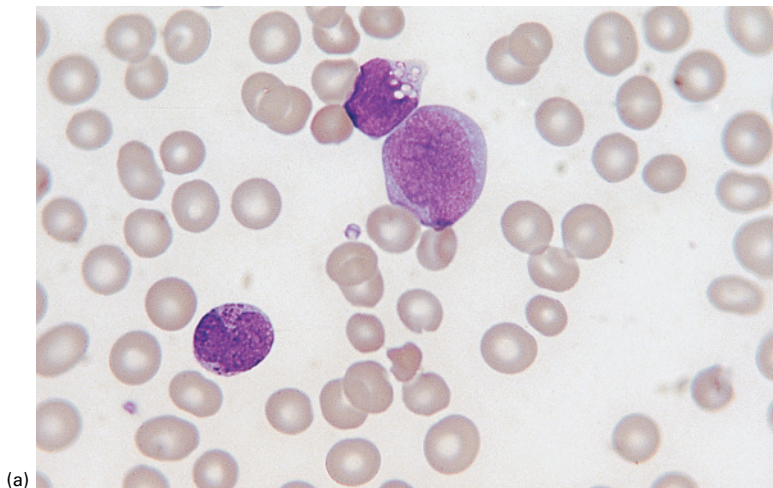
It should be noted that in some case of M5a AML there are negative reactions for SBB, MPO and NSE.

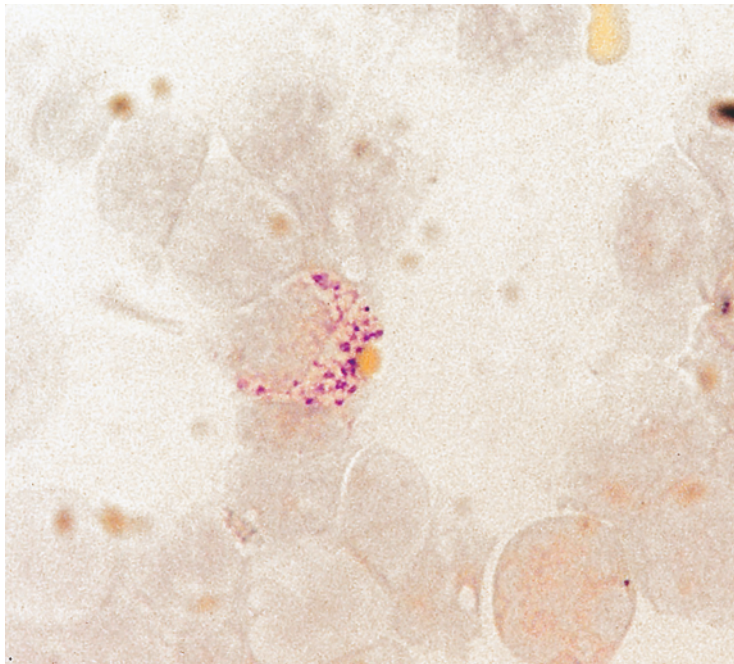
Such cases will be recognised as monoblastic only if the cytological features are assessed in relation to the immunophenotype. If the FAB classification is used such cases would be classified as M0 AML.

Acute myeloid leukaemia with predominant erythroid differentiation: M6 acute myeloid leukaemia

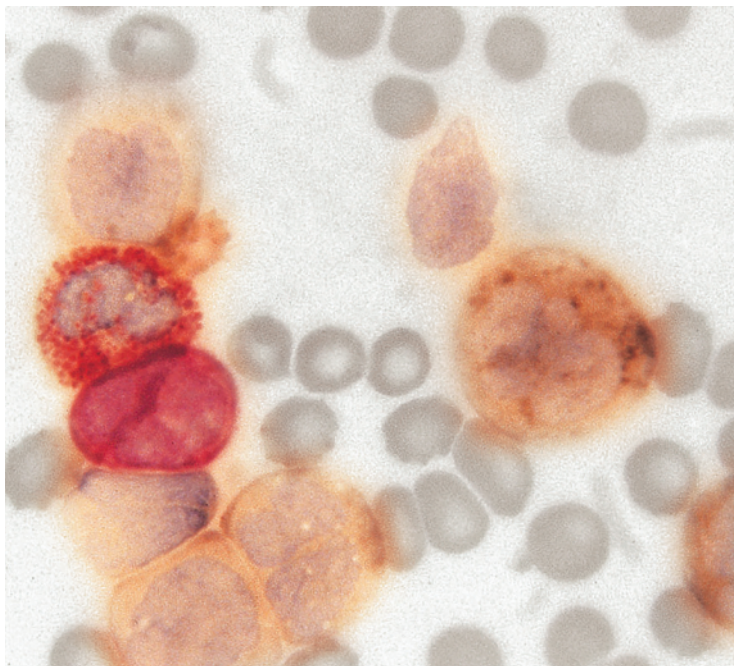
The FAB criteria for diagnosis of M6 AML are shown in Table 1.11 and cytological and histological features in Figs 1.41, 1.42, 1.43, 1.44, 1.45, 1.46 and 1.47. It should be noted that the WHO definitions of erythroleukaemia (see Chapter 3) are very different from the FAB definition. Some cases of M6 AML represent leukaemic transformation of MDS, and a significant proportion of reported cases have been therapy related; however, in one large series only 1 of 62 cases was therapy related with another 2 of 62 being secondary to MDS [115]. Presentation is often with pancytopenia and macrocytosis, with circulating blast cells being present in only a minority of patients [115]. Schistocytes, teardrop cells, pincer cells and basophilic stippling are often present [115]. Circulating erythroblasts are present in around half of patients [115] and may show dysplastic features. Circulating micromegakaryocytes are present in a significant minority [115]. There may also be hypogranular and hypolobated neutrophils and giant and hypogranular platelets. In the bone

Fig. 1.32 PB film of a patient with FAB M4 AML – M4Eo/inv(16) – who had both eosinophil and basophil differentiation. (a) A blast cell and two primitive cells containing basophilic granules; one of the latter is vacuolated. MGG $\times 100$.





(b)



(c)

Fig. 1.32 (Continued)
(b) Toluidine blue stain showing metachromatic staining of a basophil precursor. $\times 100$. (c) Double esterase stain showing positivity of the granulocyte series with CAE (red) and positivity of the monocyte series with α -naphthyl acetate (non-specific) esterase (ANAE) (brownish-black). $\times 100$.

Table 1.10 Criteria for the diagnosis of acute myeloid leukaemia of M5 category (acute monoblastic/monocytic leukaemia)

- Blasts $\geq 30\%$ of bone marrow cells
- Blasts $\geq 30\%$ of bone marrow non-erythroid cells
- Bone marrow monocytic component $\geq 80\%$ of non-erythroid cells

Acute monoblastic leukaemia (M5a)

- Monoblasts $\geq 80\%$ of bone marrow monocytic component

Acute monocytic leukaemia (M5b)

- Monoblasts $< 80\%$ bone marrow monocytic component

marrow, moderate to marked erythroid dysplasia is particularly common, with erythroid precursors showing features such as nucleocytoplasmic asynchrony (megaloblastosis), nuclear lobulation, karyorrhexis, binuclearity, internuclear bridges, basophilic stippling and cytoplasmic vacuolation. There may be coalescence of prominent cytoplasmic vacuoles, this appearance correlating with the cytochemical demonstration of PAS positivity. Giant and multinucleated erythroid cells are sometimes prominent. In some cases, erythropoiesis is predominantly megaloblastic and in others it is macronormoblastic. Phagocytosis, particularly erythrophagocytosis, by abnormal erythroid precursors is sometimes seen. In some cases

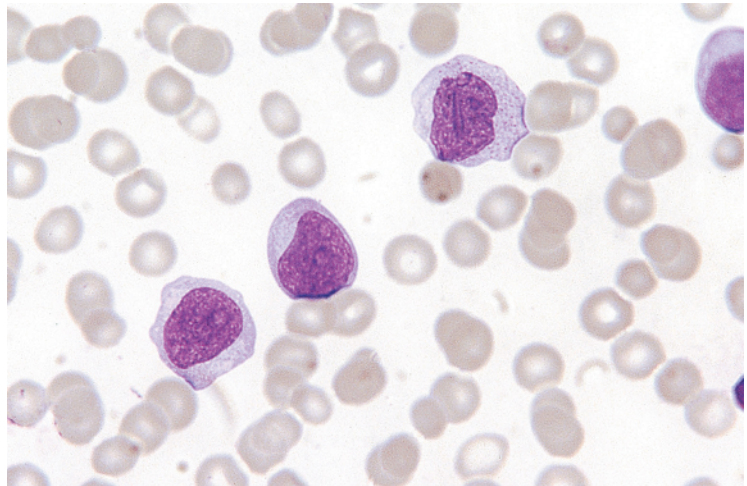


Fig. 1.33 PB film of a patient with FAB M5a AML showing three monoblasts. MGG $\times 100$.

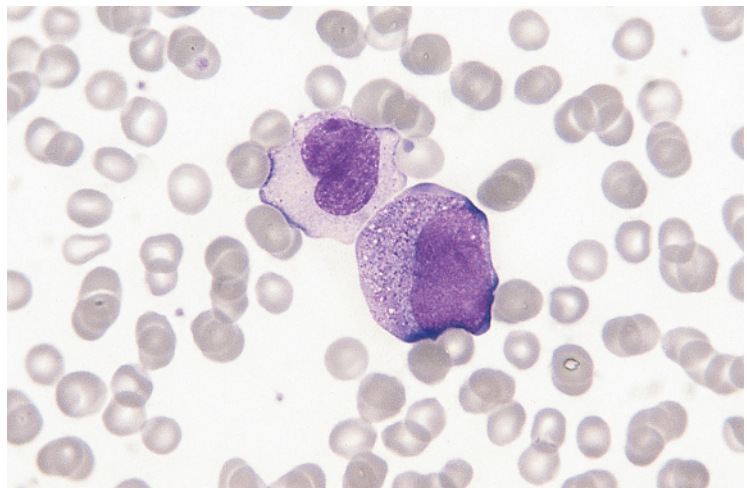
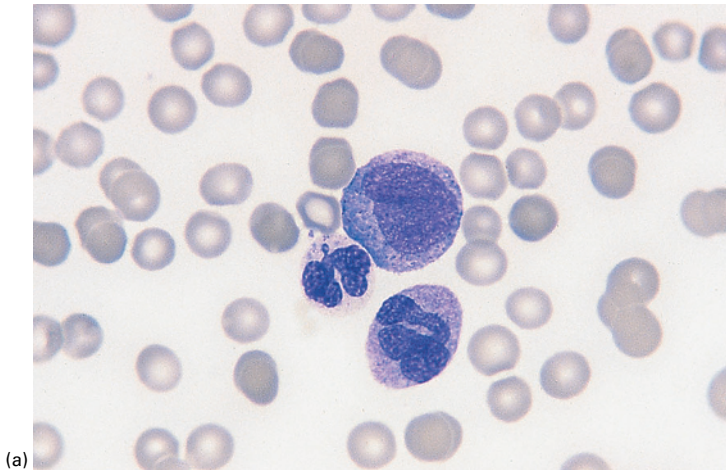
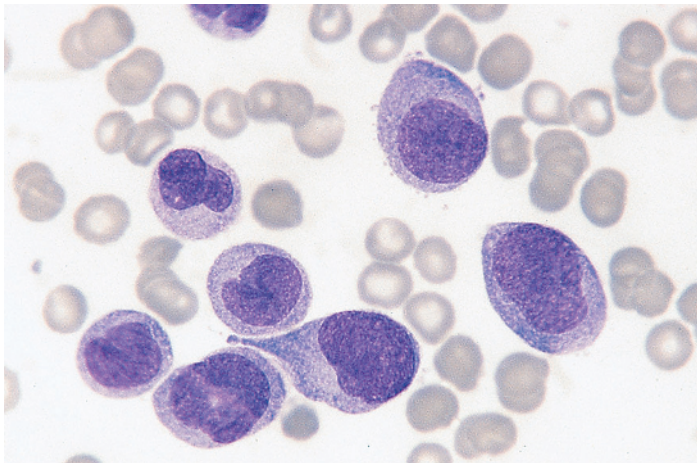


Fig. 1.34 PB film of a patient with FAB M5b AML showing a monocyte and a promonocyte; the latter is moderately heavily granulated. MGG $\times 100$.



(a)



(b)

Fig. 1.35 PB and BM films of a patient with FAB M5b AML in whom the PB cells were more mature than the BM cells. (a) PB film showing a promonocyte and a monocyte with a nucleus of abnormal shape; the third cell is probably an abnormal neutrophil. MGG $\times 100$. (b) BM film showing predominantly monoblasts and promonocytes. MGG $\times 100$.

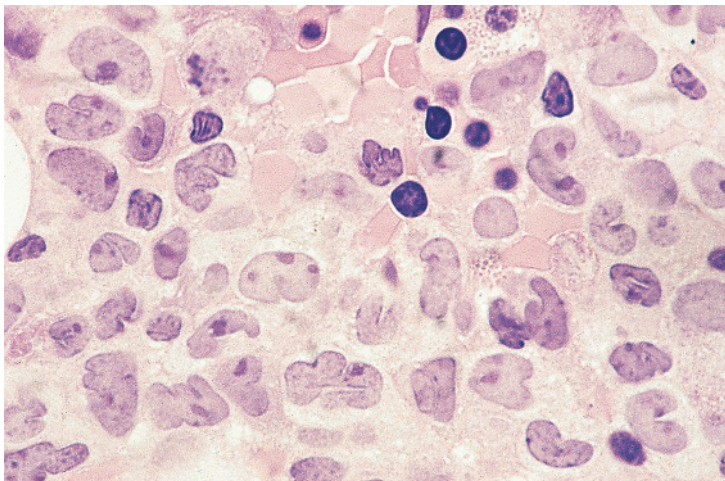


Fig. 1.36 Trephine biopsy section from a patient with FAB M5b AML and myelodysplasia. Monoblasts and monocytes can be identified; the former are the larger cells with a round or lobulated nucleus, a dispersed chromatin pattern and prominent nucleoli whereas the latter have lobulated nuclei. The cells with smaller dark nuclei are erythroblasts, one of which has a nucleus of abnormal shape. Resin embedded, H&E $\times 100$.

Fig. 1.37 Clinical photograph of a patient with FAB M5a AML showing infiltration of the gums. (With thanks to Dr Devinder Gill, Brisbane.)

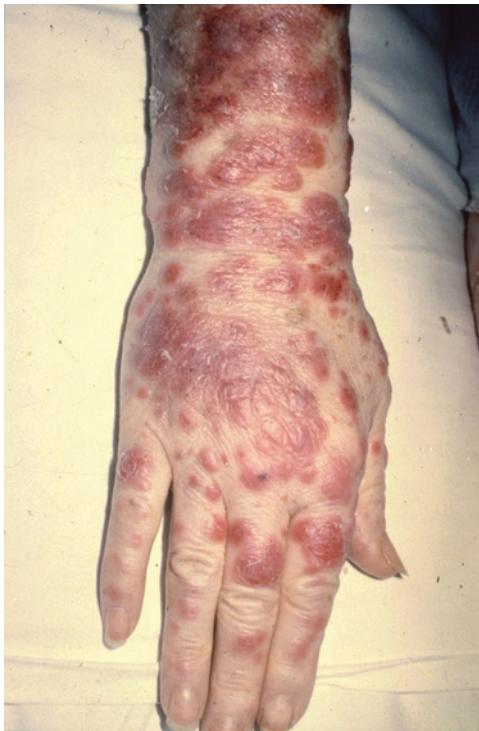
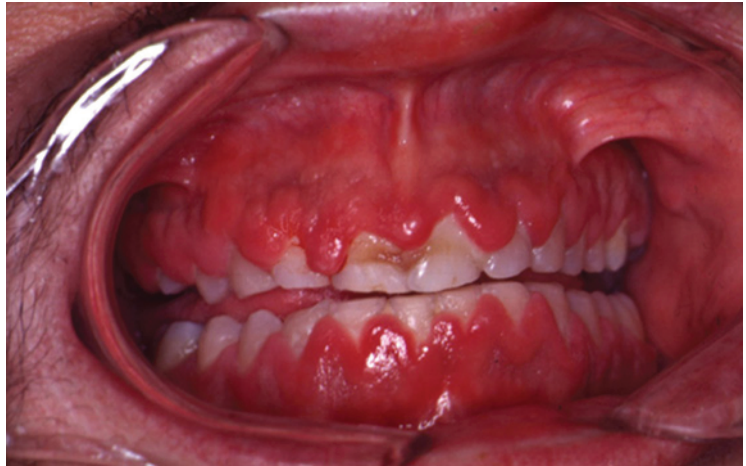
Fig. 1.38 Clinical photograph of a patient with FAB M5b AML showing skin infiltration. (With thanks to Dr Devinder Gill.)

proerythroblasts and basophilic erythroblasts are markedly increased as a percentage of total erythroblasts. Dysplasia is not confined to the erythroid

lineage, trilineage myelodysplasia being present in around half of patients [115–117]. The non-erythroid component of M6 may resemble any other FAB category with the exception of M3/M3V AML. Myeloblasts may show Auer rods.

The FAB criteria for M6 AML required that at least 50% of bone marrow nucleated cells are recognisable erythroblasts and that at least 30% of non-erythroid cells are blasts. There are also cases of AML in which the leukaemic cells appear by light microscopy to be undifferentiated blasts but can be shown by immunophenotyping or ultrastructural analysis to be primitive erythroid cells. When such cases lack a significant non-erythroid component, including more than 30% of non-erythroid blasts, they do not fit the FAB criteria for M6 AML. Nevertheless, it seems reasonable for such cases (which are rare except when AML occurs in Down syndrome [118]) to be assigned to the FAB M6 category. Domingo-Claros *et al.* [115] found only 2 of 62 cases of erythroleukaemia to have these characteristics. Use of the terms M6 variant or 'pure erythraemia' could be considered appropriate [115,117,119].

Overall, the M6 category accounts for about 3–4% of cases of AML. The frequency is higher in the elderly [120]. Prognosis appears to be worse than for AML in general [65,121]. The survival of patients with M6 variant AML was a great deal worse than the survival of patients with FAB M6 AML in one series of patients [116], but in another both had an equally bad prognosis [117].

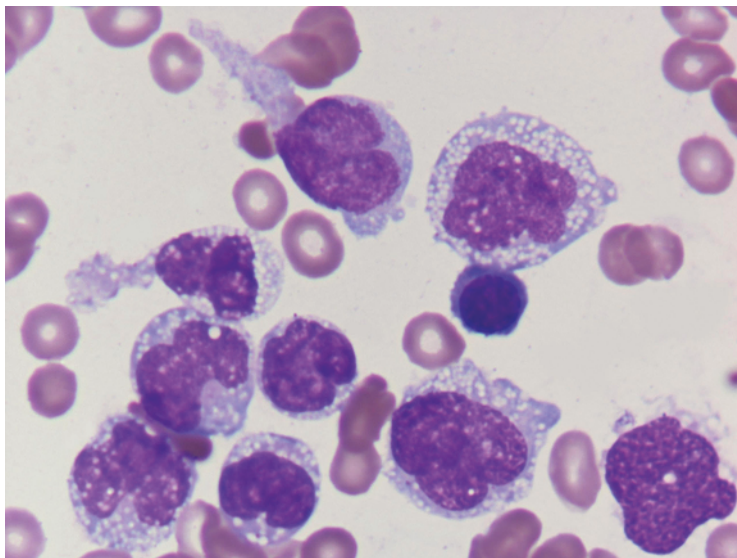


Fig. 1.39 BM film of a patient with leukaemic cells showing histiocytic or macrophage differentiation ('M5c' AML). MGG $\times 100$. (With thanks to Dr Abbas Hashim Abdulsalam.)

Cytogenetic abnormalities in M6 AML differ significantly from those in other types of AML. Cytogenetic abnormalities are common and include those of adverse prognostic significance; there may be complex cytogenetic abnormalities, hypodiploidy and abnormalities of chromosomes 5, 7, 8 and 17 [116,122].

Cytochemical reactions in M6 acute myeloid leukaemia

In M6 AML, myeloblasts and any Auer rods show the same cytochemical reactions as in other categories of AML. The NAP score may be reduced or increased and a population of neutrophils lacking SBB and MPO activity may be present.

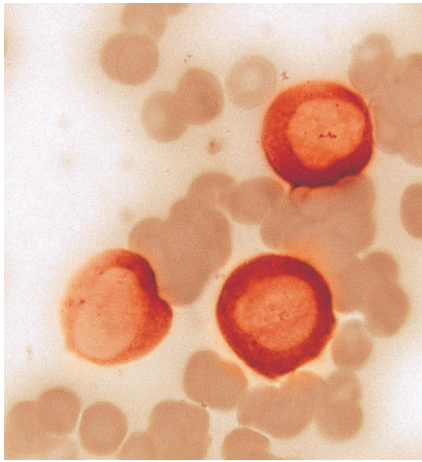
On a PAS stain the erythroblasts show diffuse or finely granular positivity with or without coarse granular or block positivity (see Fig. 1.46). Hayhoe and Quaglino [33] described a characteristic block or granular positivity in early erythroblasts and diffuse positivity in late erythroblasts and some erythrocytes. PAS positivity is not pathognomonic of M6 AML, being seen also in iron deficiency anaemia, severe haemolytic anaemia and thalassaemia major and in occasional cases of megaloblastic anaemia. PAS positivity is seen also in MDS and in other categories of AML (overall in about one in five cases)

and suggests that the erythroblasts, even when they are fewer than 50% of nucleated cells, are part of the leukaemic or myelodysplastic clone. Erythroblasts in M6 AML may have focal acid phosphatase activity, which is localised to the Golgi zone [54]; they are usually positive for ANAE and ANBE [33]. These reactions differentiate M6 erythroblasts from the erythroblasts of congenital dyserythropoietic anaemia, in which acid phosphatase and NSE reactions are negative; however, positive reactions can also be seen in megaloblastic anaemia consequent on pernicious anaemia [33]. A Perls stain for iron may show coarse siderotic granules; in a minority of cases numerous ring sideroblasts are present.

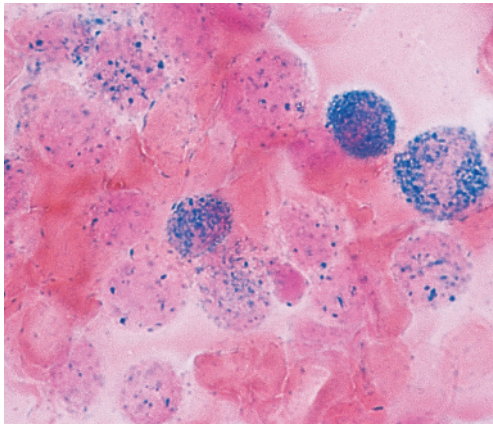
Acute megakaryoblastic leukaemia:

M7 acute myeloid leukaemia

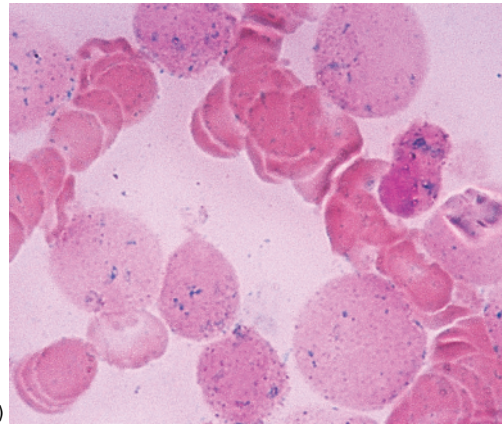
Acute megakaryoblastic leukaemia was not included in the original FAB classification of AML but, following the demonstration that in some cases apparently undifferentiated blasts were actually megakaryoblasts, this category was added [16] (Table 1.12). This category represents only about 1% of cases of AML in adults but 2–15% of childhood cases [123]. M7 AML shows a markedly increased incidence in children with Down syndrome (see Chapter 3). In infants and children M7 AML may be



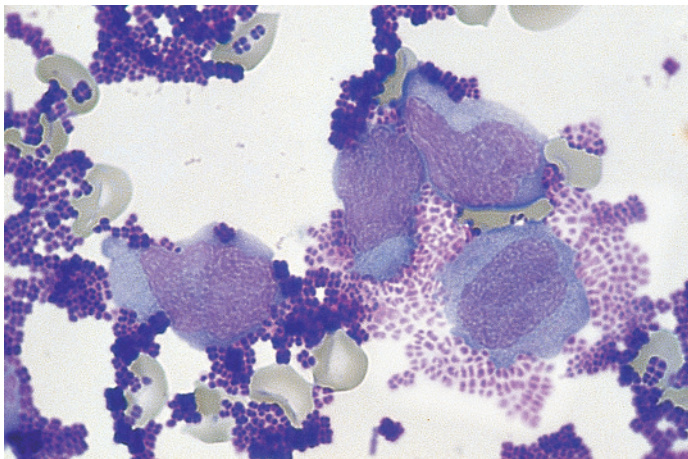
(a)



(b)



(c)



(d)

Fig. 1.40 (a) BM film of a patient with FAB M5a AML stained for ANAE activity. ANAE $\times 100$. (b, c) BM film of a patient with FAB M5b AML stained for naphthol AS acetate esterase (NASA) activity without (b) and with (c) fluoride; inhibition of activity by fluoride is apparent. NASA $\times 100$. (d) Lysozyme preparation from a patient with FAB M5b AML. Leukaemic cells have been mixed with a suspension of *Micrococcus lysodeikticus* bacteria; some of the leukaemic cells have secreted lysozyme, which has lysed adjacent bacteria so that they appear paler in comparison with intact bacteria (same patient as b and c). This test is now only of historic interest. MGG $\times 100$.

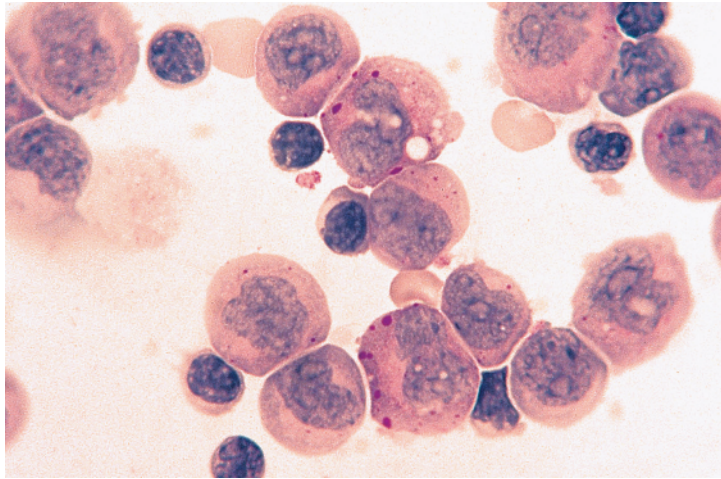


Fig. 1.40 (Continued) (e) Periodic acid–Schiff (PAS) stain of a PB cytospin preparation from a patient with FAB M5a AML showing block positivity superimposed on fine granular and diffuse positivity. PAS $\times 100$.

Table 1.11 Criteria for the diagnosis of acute myeloid leukaemia of M6 category (acute erythroleukaemia).

- Erythroblasts $\geq 50\%$ of bone marrow nucleated cells
- Blasts $\geq 30\%$ of bone marrow non-erythroid cells

associated with $t(1;22)(p13.3;q13.1)$ (see Chapter 3) and with other recurring cytogenetic abnormalities [123] including $t(9;11)(p22;q23)$ [124] – now interpreted as $t(9;11)(p21.3;q23.3)$, and in adults, and to a lesser extent in children, a significant

proportion of cases are associated with abnormalities of chromosome 3q21.3q26.2, with loss or long arm deletion of chromosome 5 or 7 [125]. Children may have gain of chromosome 21, 19 or 8 [124]. Karyotypic abnormalities are more often found in M7 than in other FAB categories of AML (with the exception of M3) and the abnormalities are more often complex [125]. *GATA1* mutations are invariably present in Down syndrome-associated cases but are also sometimes seen in other cases [126]. Diagnosis is usually made by immunophenotyping, there being expression of platelet antigens such as

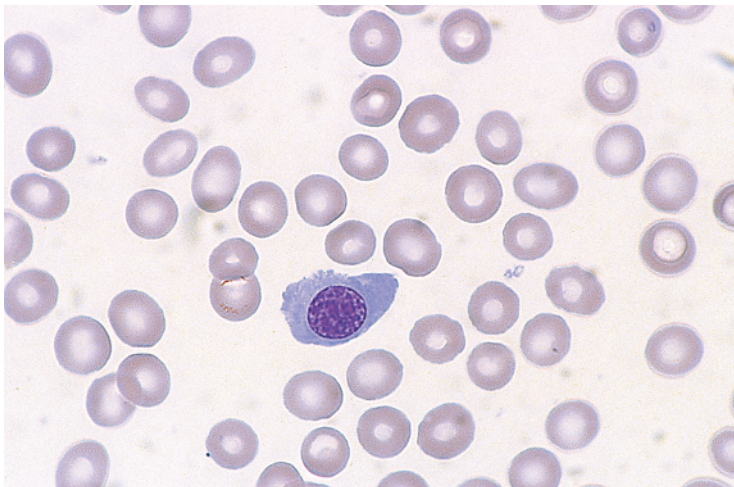


Fig. 1.41 PB film in a patient with FAB M6 AML showing anaemia, severe thrombocytopenia and an abnormal circulating erythroblast. MGG $\times 100$.

Fig. 1.42 BM film from a patient with FAB M6 AML (erythroleukaemia) showing a multinucleated erythroblast and two heavily vacuolated myeloblasts. MGG $\times 100$.

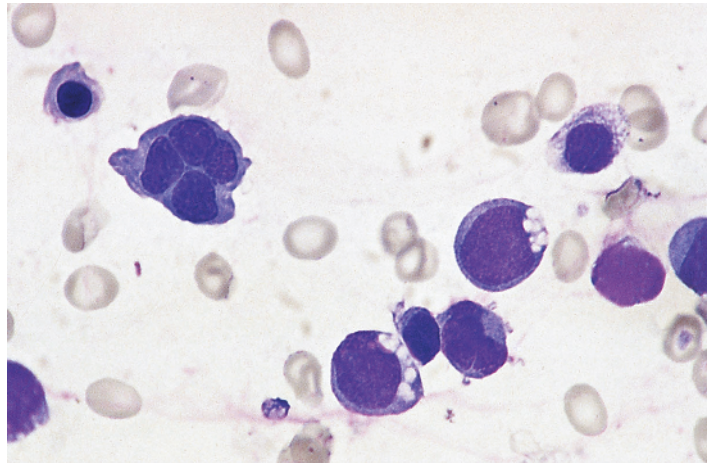


Fig. 1.43 BM film from a patient with FAB M6 AML showing marked erythroid hyperplasia but only mild dyserythropoiesis; one binucleated erythroblast is present. MGG $\times 100$.

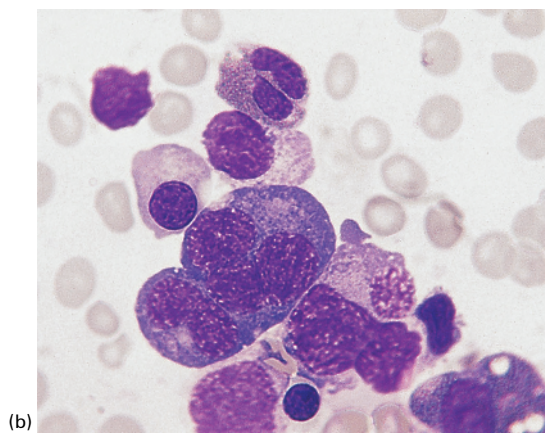
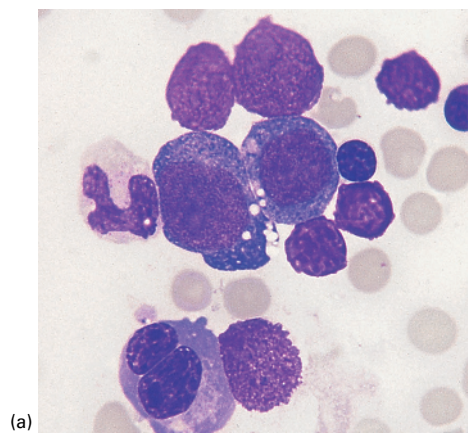
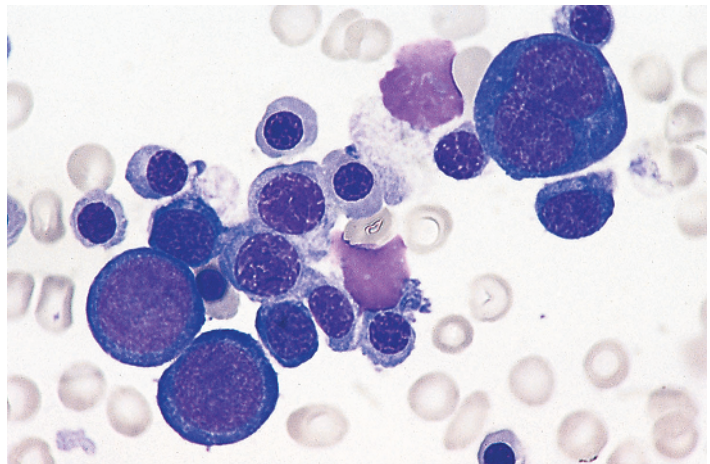


Fig. 1.44 BM film from a patient with FAB M6 AML showing: (a) a binucleated erythroblast and two vacuolated erythroblasts; (b) a giant multinucleated erythroblast. MGG $\times 100$.

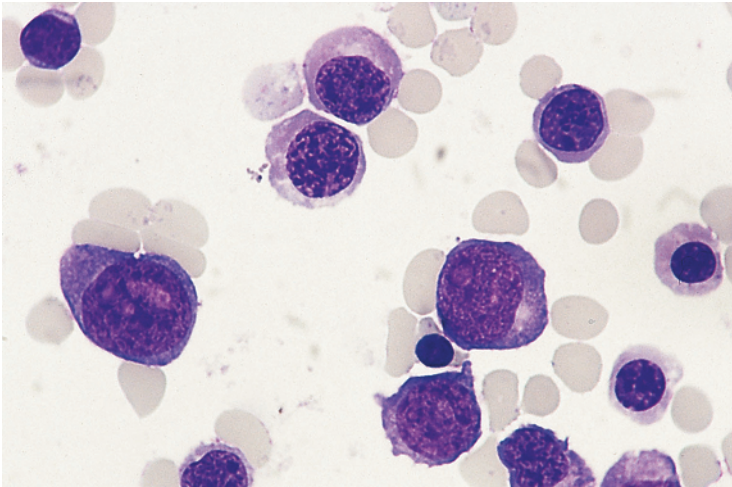
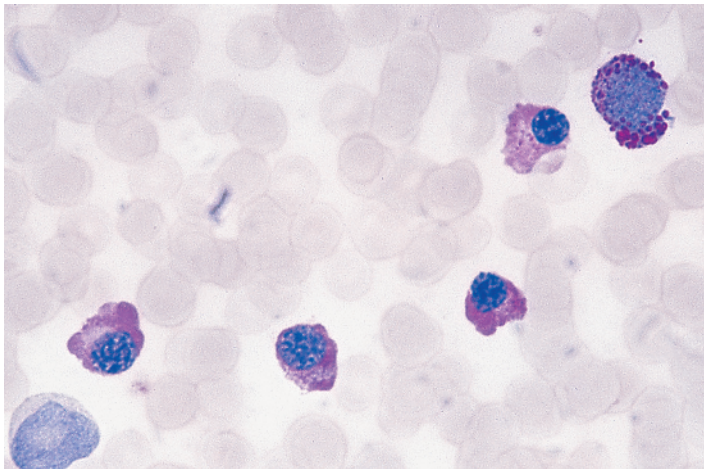
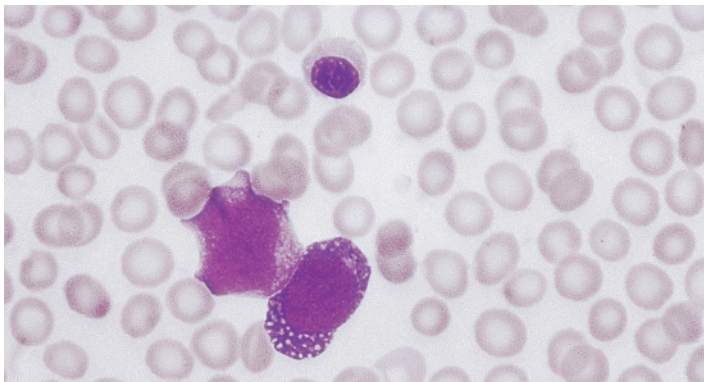


Fig. 1.45 A cytospin preparation of BM cells of a patient with FAB M6 AML showing late erythroblasts and three undifferentiated blasts. A positive reaction of the blast cells with a McAb to glycophorin A in this patient showed that these were primitive erythroid cells. MGG $\times 100$.



(a)



(b)

Fig. 1.46 (a, b) BM film in FAB M6 AML showing diffuse PAS positivity in late erythroblasts and block positivity in an early erythroblast; the corresponding MGG stain shows vacuolation of an early erythroblast, the vacuoles being attributable to the solubility of glycogen. (a) PAS $\times 100$. (b) MGG $\times 100$.

Fig. 1.47 BM trephine biopsy section in FAB M6 AML showing primitive erythroid cells, which can be distinguished from granulocyte precursors by their linear nucleoli, some of which abut on the nuclear membrane, and by their more basophilic cytoplasm (readily apparent on this Giemsa stain but not so apparent on an H&E stain). Paraffin embedded, Giemsa $\times 100$.

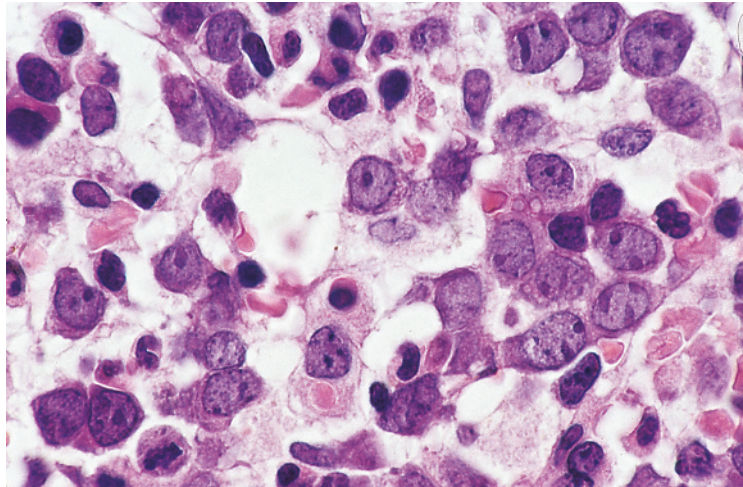


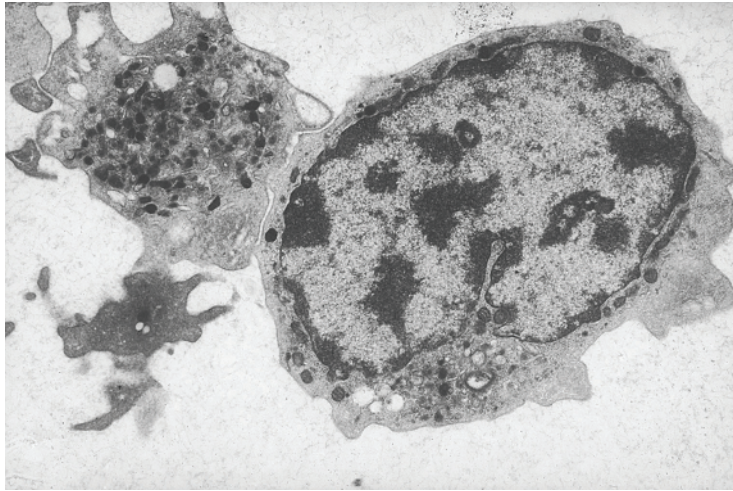
Table 1.12 Criteria for the diagnosis of acute myeloid leukaemia of M7 category (acute megakaryoblastic leukaemia).

- Blasts $\geq 30\%$ of bone marrow nucleated cells
- Blasts demonstrated to be megakaryoblasts by immunological markers, ultrastructural examination or ultrastructural cytochemistry

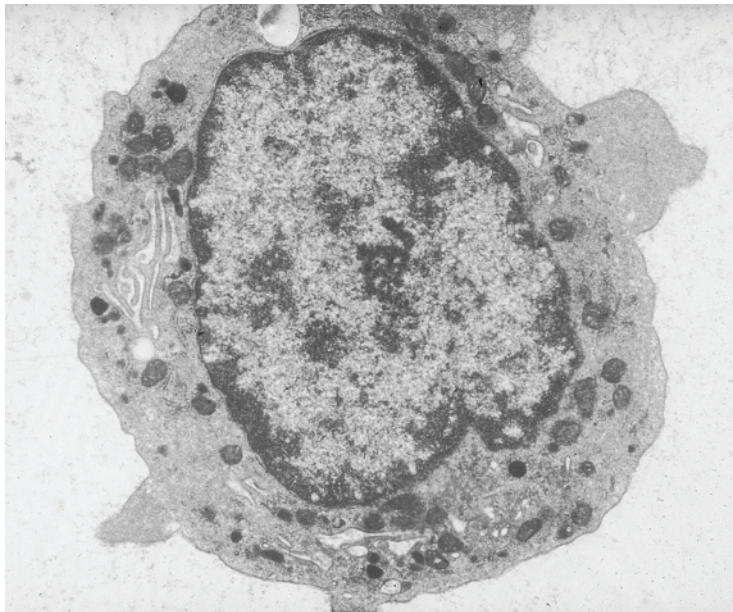
CD41, CD42 and CD61. There is often coexpression of CD13, CD33 and CD7 [126]. Adult M7 AML, in comparison with other non-M3 AML, is associated with more adverse cytogenetic abnormalities, a lower complete remission rate and worse survival [127]. There is often an antecedent haematological abnormality, and in one series of patients 19% were therapy related [127].

Leukaemic megakaryoblasts are often highly pleomorphic. Prominent and multiple nucleoli and cytoplasmic basophilia have been noted [54]. Binuclearity and clumping of blast cells have been noted to be frequent features [128]. Rarely there is erythrophagocytosis or haemophagocytosis [109,129] or ‘cannibalism’ of leukaemic blast cells; the latter phenomenon was associated with t(10;17) in two cases [130,131]. In some cases the diagnosis can be suspected from the cytological features when the blasts show cytoplasmic protrusions or blebs, or when blasts coexist with apparently bare nuclei,

with large bizarre platelets or with more mature cells showing megakaryocytic differentiation. Micromegakaryocytes are sometimes present and there may be emperipolesis [126]. In other cases the blasts cannot be distinguished from myeloblasts or resemble lymphoblasts, being small with a high nucleocytoplasmic ratio and with some chromatin condensation. The WBC is often reduced rather than elevated [132]. A minority of patients with M7 AML have thrombocytosis rather than thrombocytopenia. The percentage of bone marrow blasts may be underestimated as a result of fibrosis so that trephine biopsy can be important in assessment. The nature of megakaryoblasts may be suggested by the pattern of cytochemical reactions (see later) but a reliable identification requires immunophenotyping, ultrastructural examination (Fig. 1.48) or ultrastructural cytochemistry (Fig. 1.49). The clinicopathological picture designated acute myelofibrosis, that is, pancytopenia with bone marrow fibrosis, usually represents acute megakaryoblastic leukaemia. There may be osteosclerosis as well as bone marrow fibrosis [133]. Other patients present with the usual features of AML, with hepatomegaly and splenomegaly being quite common. Cytological and histological features of M7 AML are shown in Figs 1.50 and 1.51. Some cases show some maturation to dysplastic megakaryocytes, as is shown in Fig. 1.52. With the exception of cases among



(a)



(b)

Fig. 1.48 Ultrastructural examination of peripheral blood cells from a patient with megakaryoblastic transformation of chronic myeloid leukaemia showing: (a) a blast cell and a giant platelet; the megakaryoblast has characteristic granules including several bull's eye granules; (b) a megakaryoblast with platelet demarcation membranes. (By courtesy of the late Professor Daniel Catovsky.)

children with Down syndrome, the prognosis in both children and adults appears to be poor [65,128,132].

Cytochemical reactions in M7 acute myeloid leukaemia

Megakaryoblasts are negative for MPO, SBB and CAE. The more mature cells of this lineage are PAS

positive and have partially fluoride-sensitive NSE activity, demonstrated with ANAE. ANBE activity is demonstrable in only a minority of cases [128]. On PAS staining there are positive granules on a diffusely positive background. In some cases, those showing more cytoplasmic maturation, there are positive granules or block positivity, localised to the periphery of the cell or packed into the cytoplasmic

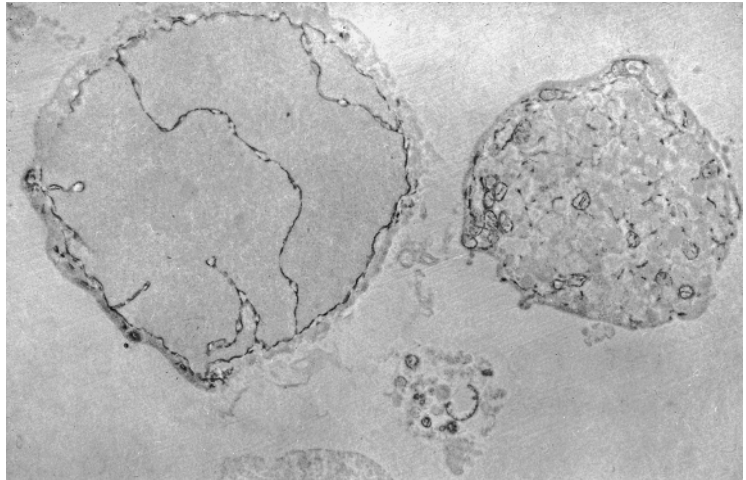
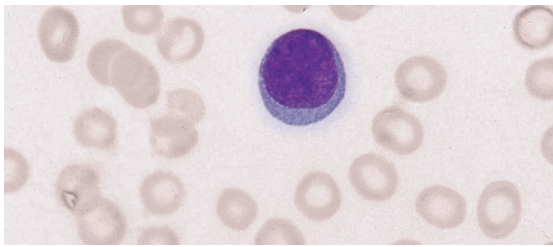
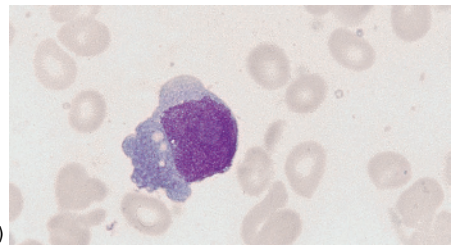


Fig. 1.49 Ultrastructural cytochemistry of a blast cell showing a positive platelet peroxidase reaction. (By courtesy of the late Professor Daniel Catovsky.)



(a)



(b)

Fig. 1.50 PB and BM films from a patient with FAB M7 AML presenting as acute myelofibrosis; the nature of the leukaemia was demonstrated by a positive reaction for platelet peroxidase. (a) PB film showing mild anisocytosis and a blast cell with no distinguishing features. (b) BM film showing a megakaryoblast. MGG $\times 100$.

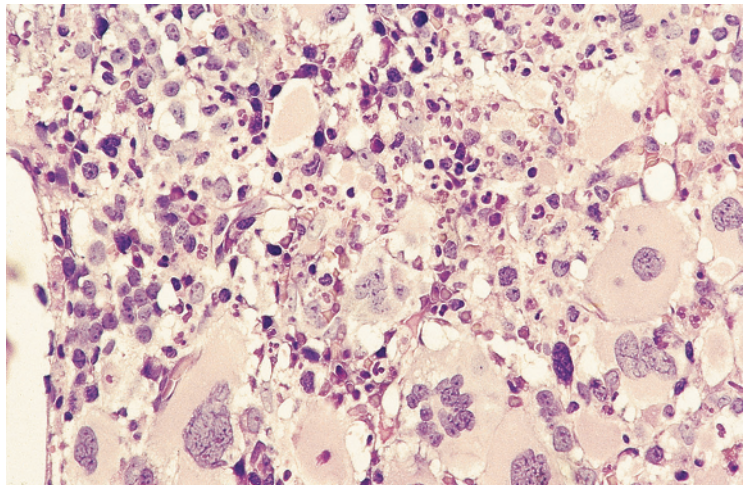


Fig. 1.51 Trephine biopsy section from a patient with FAB M7 AML showing increased blasts and large dysplastic megakaryocytes. Paraffin embedded, H&E $\times 40$.

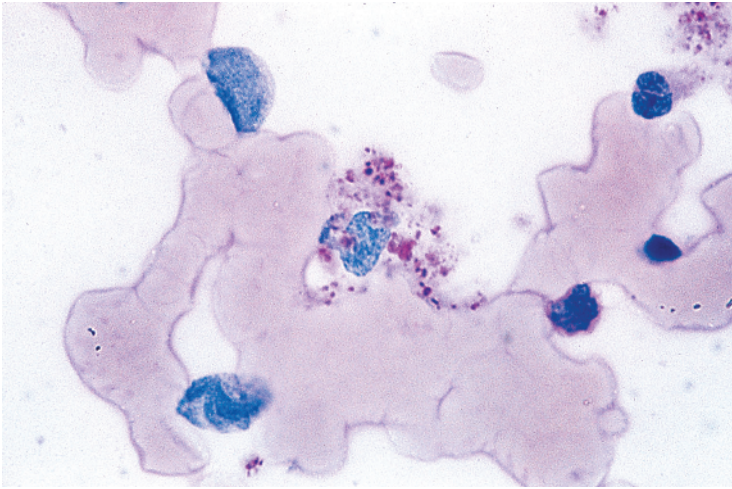


Fig. 1.52 BM film in FAB M7 AML showing a micromegakaryocyte with cytoplasmic blebs, which are PAS positive. PAS $\times 100$.

blebs. A PAS stain can highlight the presence of micromegakaryocytes and megakaryoblasts with cytoplasmic maturation (Fig. 1.52). Esterase activity is usually multifocal punctate [128] but is sometimes localised to the Golgi zone [58,128]. There is a similar localisation of acid phosphatase activity, which is tartrate sensitive [54]. In very immature megakaryoblasts, PAS and NSE reactions are negative.

Acute eosinophilic leukaemia

In the FAB classification, cases of eosinophilic leukaemia with a minimum of 30% bone marrow blast cells should be categorised as AML. They can be assigned to FAB categories with the addition of the abbreviation 'Eo' to indicate the eosinophilic differentiation, for example M2Eo and M4Eo. Such cases may have cardiac and other tissue damage as a result of the release of eosinophil granule contents. Generally there is both neutrophilic and eosinophilic differentiation. Occasional cases show only eosinophilic differentiation. A minimum of 5% of bone marrow eosinophils has been suggested as a criterion for the recognition of significant eosinophilic differentiation [134]. In cases with maturation, eosinophils are readily recognisable by the characteristic staining of their granules. However, recognition of eosinophil precursors in M1Eo AML may require cytochemistry or the ultrastructural demonstration of characteristic granule structure

(see Table 1.5), since primitive eosinophil granules differ little in their staining characteristics from the granules of neutrophil lineage myeloblasts (Fig. 1.53). Mature eosinophils often show vacuolation, degranulation and nuclear hyper- or hypobation. However, these cytological abnormalities are not specific for eosinophilic leukaemia, being seen also in reactive eosinophilia. The bone marrow in acute eosinophilic leukaemia sometimes shows the presence of Charcot–Leyden crystals, either free or within macrophages (Fig. 1.54). Occasionally similar crystals are seen within leukaemic cells (Fig. 1.55).

Cytochemical reactions in acute eosinophilic leukaemia

Blast cells of eosinophil lineage are positive with MPO and SBB. With the SBB stain, the granule core may be left unstained. Peroxidase activity differs from that of the neutrophil lineage in being resistant to cyanide [106]. Cells of the eosinophil lineage are usually CAE negative but positively staining granules may be seen in acute eosinophilic leukaemia [104]. A combined cytochemical stain for CAE and cyanide-resistant peroxidase activity is a convenient means of distinguishing cells of neutrophil and eosinophil lineage [106]. On immunophenotyping, immature eosinophils can express 2D7, CD123 and basogranulin [135].

Fig. 1.53 PB film in acute eosinophilic leukaemia with abnormal eosinophil precursors showing a mixture of eosinophilic and azurophilic granules; maturing eosinophils are degranulated and some have nuclei of bizarre shapes. MGG $\times 100$. (With thanks to Dr Alastair Smith, Southampton.)

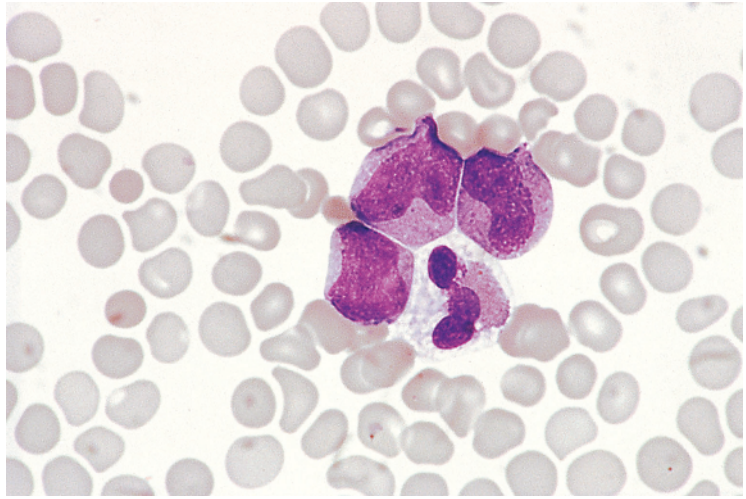
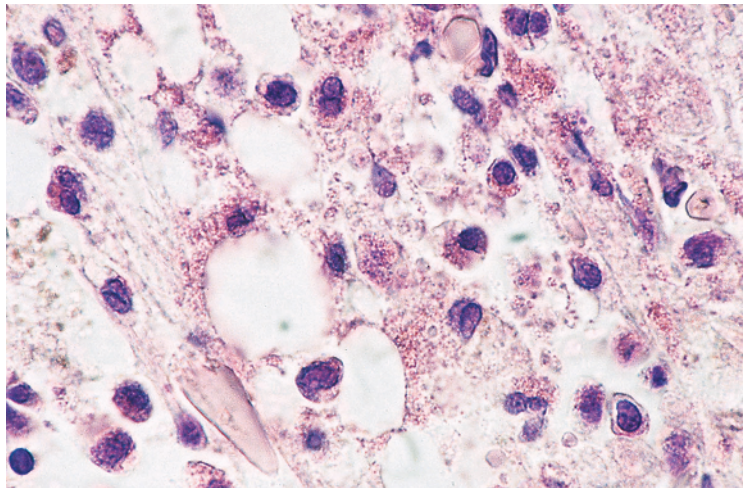


Fig. 1.54 Trepine biopsy section in acute eosinophilic leukaemia showing numerous eosinophils and part of a Charcot–Leyden crystal (same patient as Fig. 1.53). Paraffin embedded, H&E $\times 100$. (With thanks to Dr Alastair Smith and Dr Bridget Wilkins, West Moors, Ferdown.)



Acute basophilic leukaemia

In the FAB classification cases of basophilic leukaemia with a minimum of 30% bone marrow blasts should be classified as AML. They can be assigned to FAB categories with the abbreviation 'Baso' to indicate the basophilic differentiation. Some cases show maturation and can be categorised as M2Baso or M4Baso. Others show very little maturation and fall into the M1Baso category. Cases that do not meet the minimal criteria for M1 AML but show evidence of basophil differentiation can be

categorised as M0Baso. Cases of M2Baso and M4Baso AML usually have mixed neutrophilic and basophilic differentiation, whereas cases with very primitive basophil precursors (M1baso and M0Baso AML) may show only basophilic differentiation. Cases of mixed phenotype acute leukaemia with basophilic, megakaryoblastic and T-lineage maturation have been recognised [136]. Patients with acute basophilic leukaemia do not usually show features of histamine excess [137] but some patients have had urticaria, peptic ulceration or

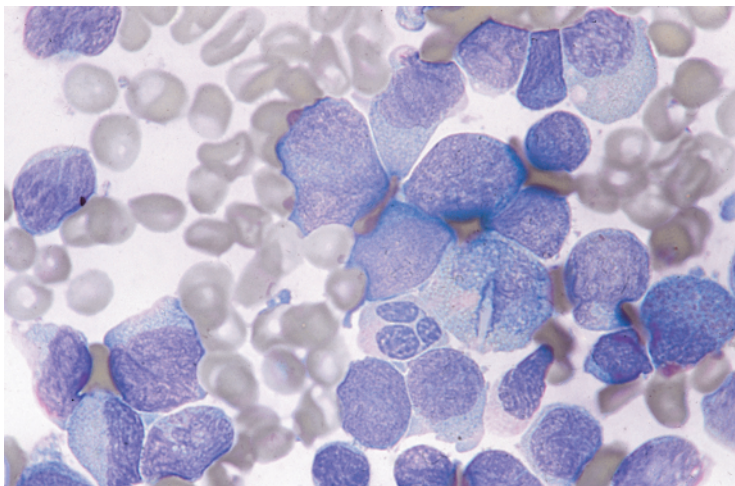


Fig. 1.55 BM film from a patient with acute eosinophilic leukaemia showing a Charcot–Leyden crystal within a leukaemic cell. MGG $\times 100$.

other gastrointestinal disturbance [138], and anaphylactoid reactions can occur following chemotherapy [139].

In cases with maturation, basophils are usually easily recognised by their cytological and cytochemical characteristics (Fig. 1.56). In other cases with little or no maturation, ultrastructural examination (see Table 1.5) or immunophenotyping is necessary. Sometimes there are granules with whorls or scrolls (characteristic of mast cells) in addition to typical basophil granules [139]. Blasts of basophil lineage may contain Auer rods [140].

Cytochemical reactions in acute basophilic leukaemia

In acute basophilic leukaemia without maturation [141], SBB is commonly negative and MPO is negative by light microscopy. Often CAE is also negative, although it is weakly positive in later cells of basophil lineage. In cases showing maturation there is positivity with SBB, MPO and CAE, and metachromatic staining with toluidine blue, alcian blue and astra blue. Sometimes, staining with SBB is also metachromatic, granules being grey, black, pinkish or red while granules of the eosinophil and neutrophil lineages are greenish-black. On MPO staining, blasts may have particularly coarse granules [136]. ϵ -amino caproate activity [142] is specific for the basophil lineage. At an ultrastructural level, ruthenium red can be used to identify basophil gran-

ules [141]. Flow cytometry shows expression of CD123 and CD203c. Immunohistochemistry shows expression of CD63, CD88, CD123, CD203c, 2D7, VEGF, interleukin 4 and basogranulin (BB1) [135]. Immature basophils can express mast cell tryptase (but not usually CD117) [135]. The t(X;6)(p11;q23) translocation occurring in male infants has been associated with acute basophilic leukaemia with a *MYB::GATA1* fusion gene [135].

Acute mast cell leukaemia

Mast cell leukaemia can occur either *de novo* (three-quarters of cases) or as the terminal phase of systemic mastocytosis (one-quarter of cases) [143]. Uncommonly, it follows paediatric mastocytosis, sometimes after an interval of many decades [143]. Clinical features often include hepatomegaly and splenomegaly but lymphadenopathy, present in 37% of cases, is more common than in other types of AML [143]. Skin infiltration is seen mainly, but not only, in those with previous systemic mastocytosis [143]. Mast cell activation symptoms (e.g. fever, flushing, diarrhoea and palpitations) are common. Mast cell leukaemia is not included in the FAB classification and in the WHO classification is regarded as a form of systemic mastocytosis. However, it should be noted that not only are the majority of cases *de novo*, but also systemic mastocytosis terminates in other types of AML more often than in

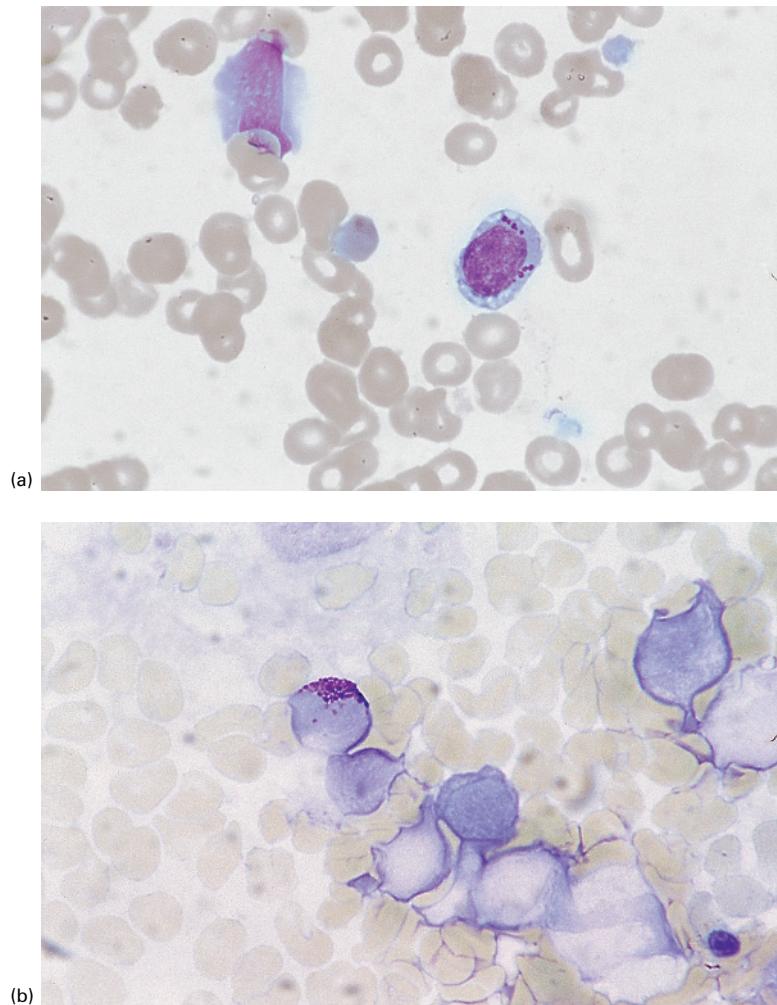


Fig. 1.56 BM film in acute basophilic leukaemia. (a) Vacuolated blast with large granules. MGG $\times 100$. (b) Metachromatic staining with a toluidine blue stain. Toluidine blue $\times 100$.

mast cell leukaemia; in one such patient, with acute erythroid leukaemia, a *KIT* D816V mutation was demonstrated both in mast cells and in leukaemic blasts and erythroid cells [144]. The peripheral blood may show mast cells (Fig. 1.57), which are often immature or morphologically abnormal with hypogranularity or nuclear lobulation; however, about 60% of cases are aleukaemic [143]. The bone marrow is hypercellular and infiltrated by mast cells (Fig. 1.58). The neoplastic mast cells can include granular and agranular blast cells, promastocytes and mast cells; all express mast cell tryptase. Haemophagocytosis by the leukaemic cells has been

reported [145,146]. Ultrastructural examination can confirm the diagnosis but it should be noted that in some cases cells show both basophil and mast cell characteristics [147]. As for acute basophilic leukaemia, anaphylactoid reactions may follow chemotherapy [148]. In some patients there is differentiation to both myeloblasts and mast blasts (Fig. 1.59) [149]. The term 'myelomastocytic leukaemia' has been suggested for these cases [150]. Mutations in the *KIT* gene are found, including, but not only, the D816V mutation characteristic of systemic mastocytosis, which was reported in 13/28 cases (46%) in one series [143]; intragenic deletions

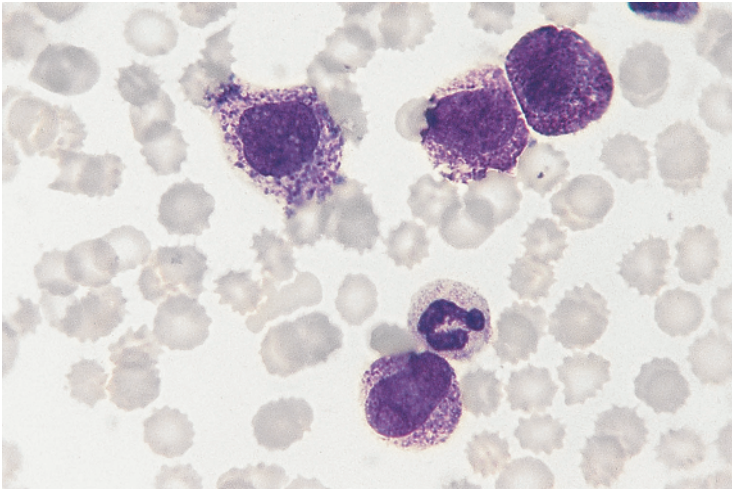


Fig. 1.57 PB film in mast cell leukaemia showing a neutrophil and four mast cells. MGG $\times 100$. (With thanks to Dr Ian Bunce, Brisbane, and the late Miss Desley Scott.)

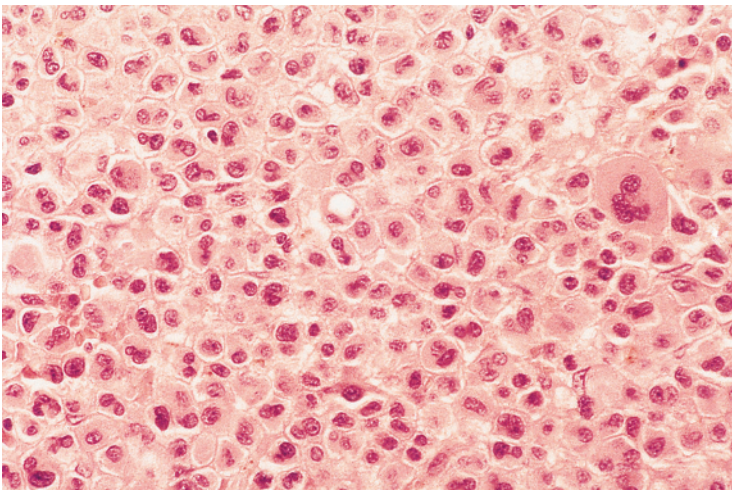


Fig. 1.58 Trehphine biopsy section from a patient with acute mast cell leukaemia showing neoplastic mast cells with irregular nuclei and voluminous cytoplasm. Paraffin embedded, H&E $\times 40$. (With thanks to Professor Ghulam Mufti, London.)

have also been demonstrated [151]. Reported cytogenetic abnormalities include $\text{del}(5q)$, $\text{t}(10;16)(q22;q13q22)$ and $\text{t}(8;21)(q22;q22.1)$ [143].

Immunophenotype in acute mast cell leukaemia

There may be expression of CD25 (75%) or CD2 (52%) plus markers of immaturity such as CD34, HLA-DR and CD123 [143]. CD30 may be expressed [152]. There is also expression of CD117.

Cytochemical reactions in acute mast cell leukaemia

Mast cells stain metachromatically with a Giemsa stain and with toluidine blue, alcian blue and astra blue. They are CAE positive. There may be cytoplasmic crystals, which stain pink on a May–Grünwald–Giemsa (MGG) stain. When cells are relatively agranular, immunocytochemistry for mast cell tryptase is more sensitive than cytochemical staining (Fig. 1.60) [149].

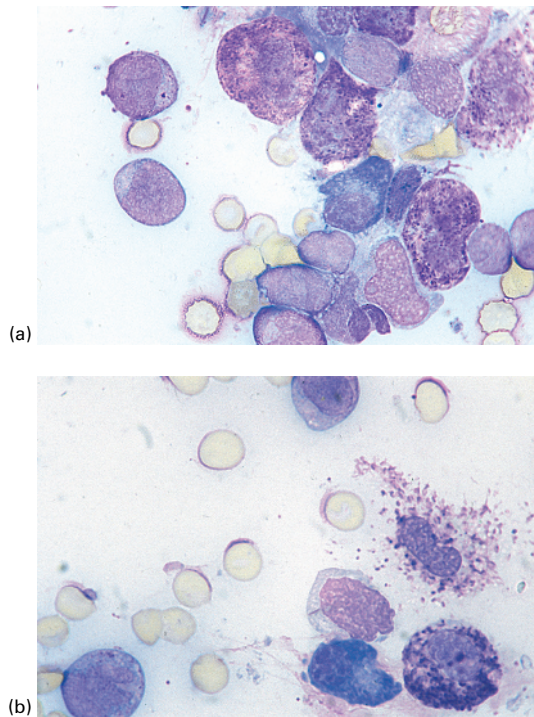
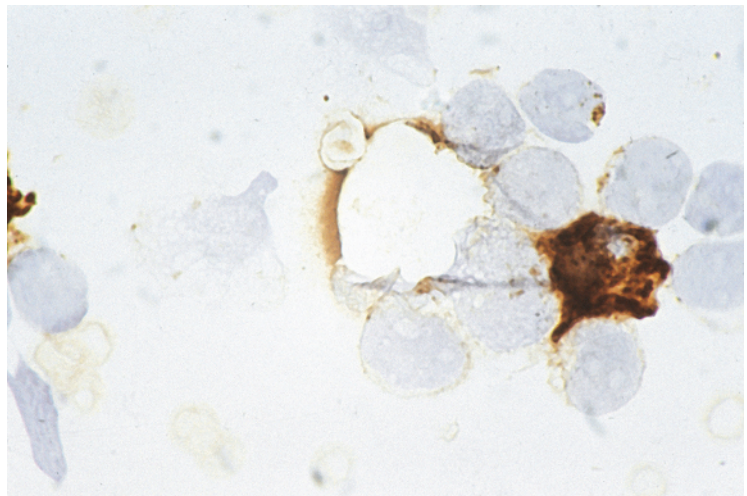


Fig. 1.59 BM film from a patient with acute leukaemia showing mast cell and neutrophilic differentiation, showing: (a) blast cells and immature abnormal mast cells; (b) abnormal mast cells and a blast cell containing an Auer rod. MGG $\times 100$. (With thanks to Dr Neelam Varma, Chandigar.)

Fig. 1.60 BM film from a patient with acute mast cell leukaemia showing a mature mast cell packed with granules that are strongly positive for mast cell tryptase and several blast cells with tryptase-positive granules; these latter cells are therefore identified as blast cells of mast cell lineage (same patient as Fig. 1.59). Immunoperoxidase $\times 100$. (With thanks to Dr Neelam Varma and Dr Bridget Wilkins.)



Genetics

Mutations in *KIT* are found in the majority of patients and include *KIT* D816V and *KIT* D816H/Y, with additional mutations in *SRSF2*, *ASXL1* or *RUNX1* being common [153].

Langerhans cell leukaemia

Rare cases of AML have leukaemic cells showing features of Langerhans cells (Fig. 1.61) [154]. Such cases may occur *de novo* but it is likely that cases resembling M5 AML supervening in Langerhans cell histiocytosis [155] also represent a leukaemia of Langerhans cells. The diagnosis is made by assessment of cytology and immunophenotype (CD1a is expressed), with the demonstration of Birbeck granules by ultrastructural examination providing a definitive diagnosis.

Hypoplastic or hypocellular acute myeloid leukaemia

The majority of cases of AML have a hypercellular bone marrow. However, in a minority of cases the bone marrow is hypocellular. Hypoplastic AML has been variously defined as AML with bone marrow cellularity being less than 50% [156], less than 40% [157], less than 30% [158] or, in the 2016 WHO classification, less than 20% [159]. Hypoplastic AML can occur *de novo* or supervene in MDS. Often examination of the peripheral blood and

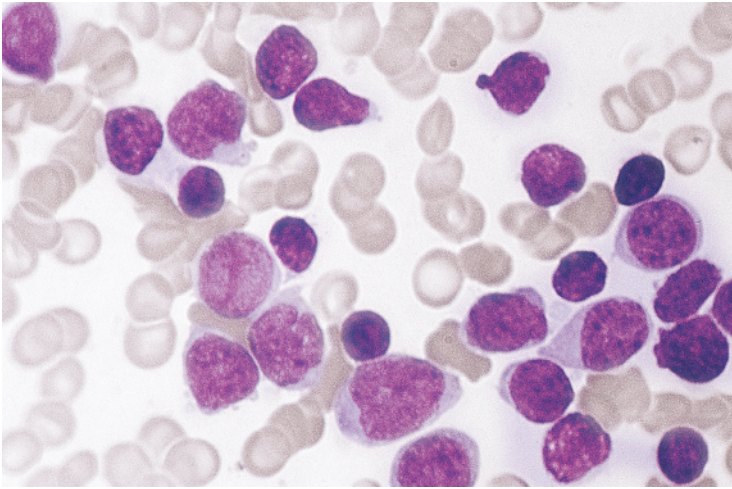


Fig. 1.61 Langerhans' cell leukaemia. MGG $\times 100$. (With thanks to Dr B.I.S. Srivastava, Buffalo, New York.)

bone marrow does not permit a distinction from MDS since there is often pancytopenia with few circulating blast cells and a hypocellular bone marrow aspirate. Diagnosis, using FAB criteria, is then dependent on identifying more than 30% of blast cells on examination of bone marrow trephine biopsy sections. Hypocellular AML can be assigned to FAB categories, often falling into M0, M1 or M2 categories. Because of the high percentage of lymphoid cells in hypocellular AML it has been suggested that the FAB criteria for the diagnosis of AML should be modified in respect to this subtype so that blasts are counted as a percentage of all nucleated cells with the exception of lymphocytes [160]. Hypocellular AML often has a smouldering clinical course. However, intensive chemotherapy often achieves a complete remission, which may be associated with restoration of normal bone marrow cellularity [160].

Clinical correlates of FAB categories of acute myeloid leukaemia

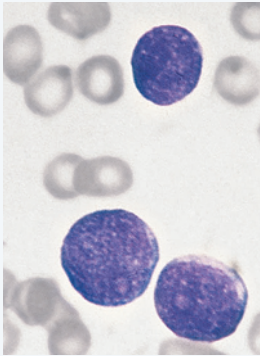
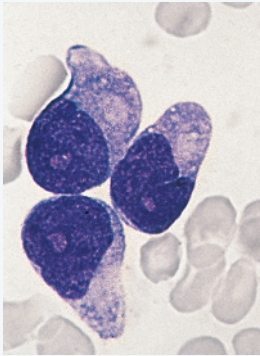
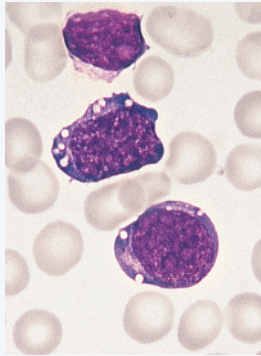
The FAB category of M3 AML is a distinct disease entity. Otherwise there are only minor clinical differences between FAB categories. M4 and M5 AML are associated with more hepatosplenomegaly, skin infiltration and gum infiltration. M0 AML [161] and M6 AML are associated with complex cytogenetic abnormalities and with a worse prognosis than other categories.

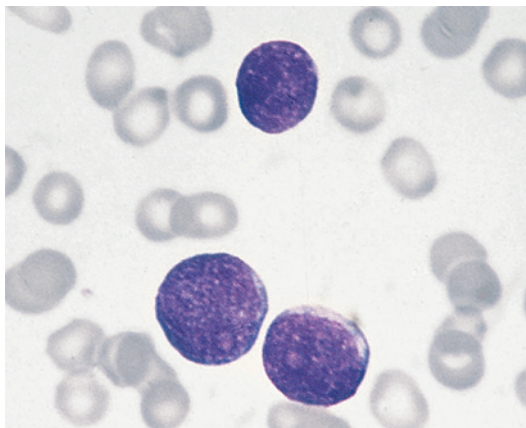
The FAB classification of acute lymphoblastic leukaemia

Initially, ALL was largely a diagnosis of exclusion. Although some cases had characteristic cytological features, others were categorised as 'lymphoid' only because they did not show any definite cytological or cytochemical evidence of myeloid differentiation. With the availability of a wide range of monoclonal antibodies directed at antigens expressed on lymphoid cells, the diagnosis of ALL is now based on positive criteria. The role of immunophenotyping in the diagnosis and classification of ALL will be discussed in detail in Chapter 2. It is sufficient at this stage to say that ALL is classified broadly as B lineage or T lineage.

The FAB group have assigned ALL to three cytological categories: L1 (70–80% of childhood cases), L2 (about a quarter of childhood cases) and L3 (1–2%). The classification is summarised in Table 1.13 and illustrated in Figs 1.62, 1.63, 1.64, 1.65, 1.66, 1.67, 1.68, 1.69, 1.70 and 1.71. The only clinical significance of the FAB classification of ALL is that: (i) cases with L1 cytological features are highly likely to be ALL, which can be useful in a resource-poor setting (whereas cases with L2 cytological features may represent M0 AML); and (ii) that the rapid recognition of L3 cytological features is important because this is usually associated with a mature B immunophenotype and represents a leukaemic phase of Burkitt lymphoma or, occasionally,

Table 1.13 Morphological features of acute lymphoblastic leukaemia (ALL) subtypes.

FAB category	L1 ALL	L2 ALL	L3 ALL
			
Cell size	Mainly small	Large, heterogeneous	Medium to large, homogeneous
Nuclear chromatin	Fairly homogeneous, may be condensed in some cells	Heterogeneous	Finely stippled, homogeneous
Nuclear shape	Mainly regular	Irregular; clefting and indentation common	Regular; oval or round
Nucleolus	Not visible or small and inconspicuous	Usually visible, often large	Usually prominent
Amount of cytoplasm	Scanty	Variable, often abundant	Moderately abundant
Cytoplasmic basophilia	Slight to moderate	Variable	Strong
Cytoplasmic vacuolation	Variable	Variable	Often prominent

**Fig. 1.62** PB film of a patient with FAB L1 acute lymphoblastic leukaemia (ALL). MGG $\times 100$.

transformation of a low-grade lymphoma, such as follicular lymphoma, as the result of the occurrence of a Burkitt lymphoma-related translocation occurring as a second event [162]. Neither of these groups of cases is any longer classified as ALL.

Cytological features of L1 and L2 ALL were described in detail in earlier editions of this book. L1 type lymphoblasts are medium sized with a fairly regular nucleus, high nucleocytoplasmic ratio, a diffuse chromatin pattern and small and inconspicuous nucleoli. L2 type lymphoblasts may be larger and are more pleomorphic. Because L3 cytological features retain clinical significance, they are described in more detail here.

It should be noted that although myeloblasts do not show any appreciable chromatin condensation,

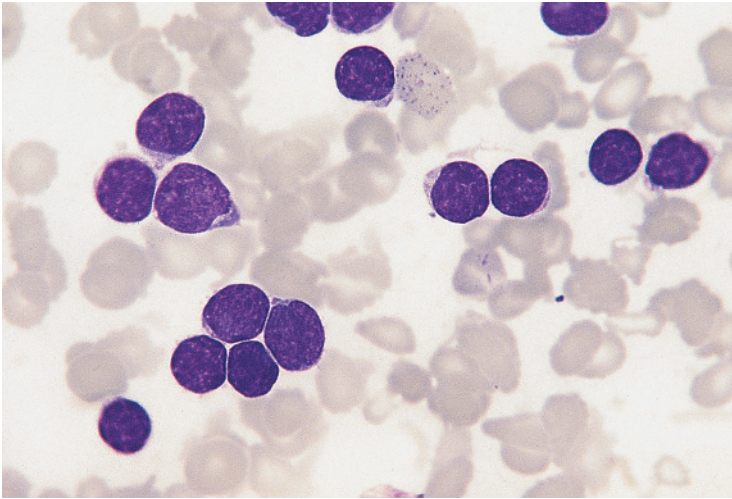


Fig. 1.63 BM film from a patient with FAB L1 ALL. MGG $\times 100$.

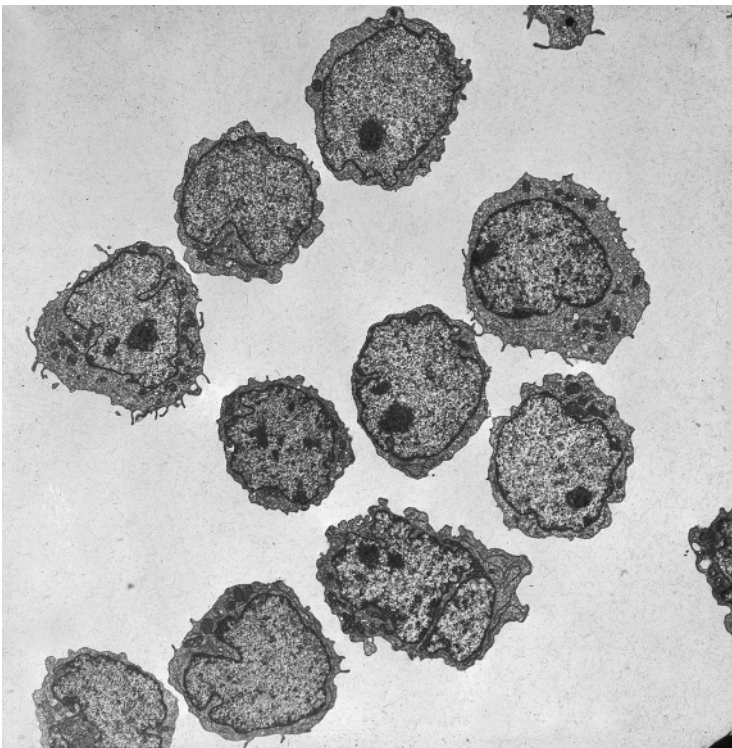


Fig. 1.64 Ultrastructure of lymphoblasts in FAB L1 ALL. (By courtesy of the late Professor Daniel Catovsky.)

lymphoblasts may do so. This is often noticeable in some of the smaller blasts in common ALL of L1 type. It has also been noted that a minority of cases of T-lineage ALL, particularly those with a relatively mature immunophenotype, have leukaemic cells that

are difficult to recognise as blasts because of chromatin condensation and inconspicuous nucleoli [163]; immunophenotyping is of importance in these cases. Occasionally leukaemic lymphoblasts have cup-shaped nuclei (Fig. 1.72) [164–166], a feature that is

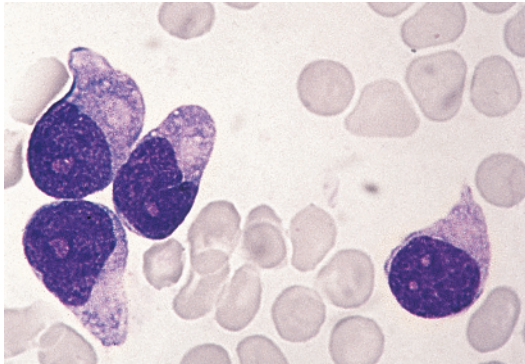


Fig. 1.65 BM film from a patient with FAB L2 ALL showing large pleomorphic blasts; the cells were CD10 positive. MGG $\times 100$.

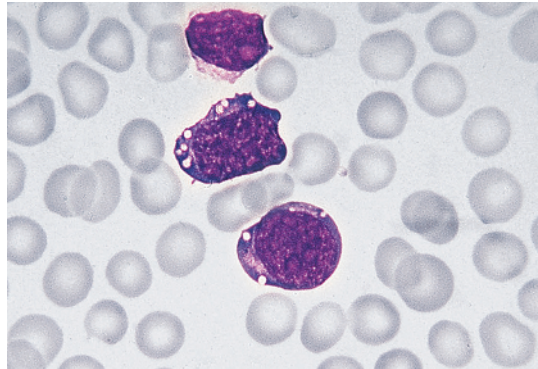


Fig. 1.68 PB film of a patient with FAB L3 ALL with the immunological phenotype being mature B cell. MGG $\times 100$.

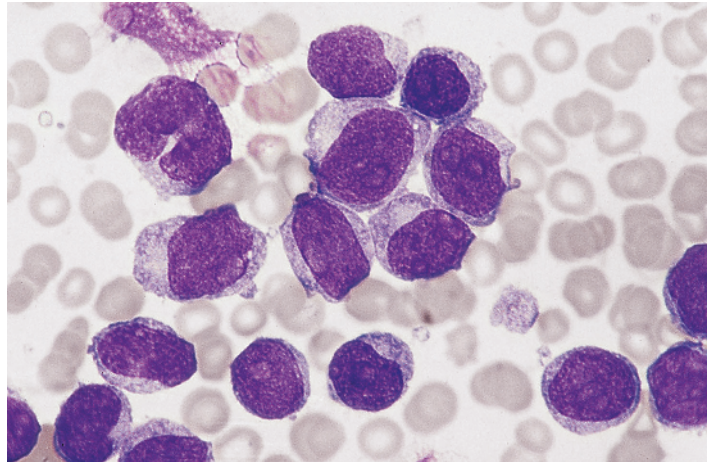


Fig. 1.66 BM film from a patient with FAB L2 ALL showing medium to large pleomorphic blasts, which were CD19 negative but positive for CD19, HLA-DR and TdT. MGG $\times 100$.

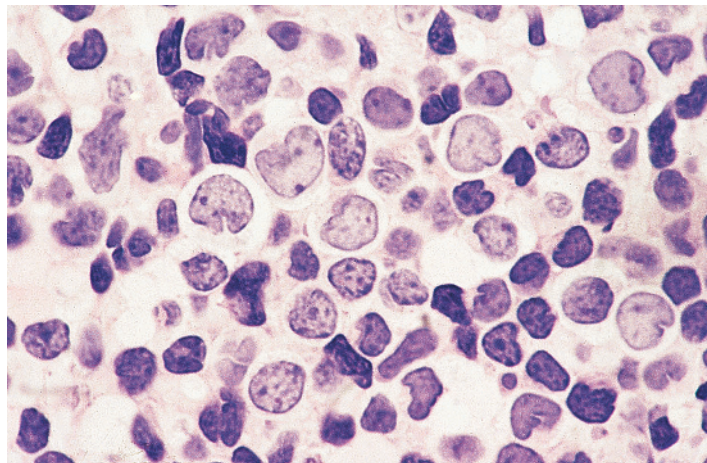


Fig. 1.67 Trephine biopsy section from a patient with FAB L2 ALL. Note the pleomorphism of the blast cells. Resin embedded, H&E $\times 100$.

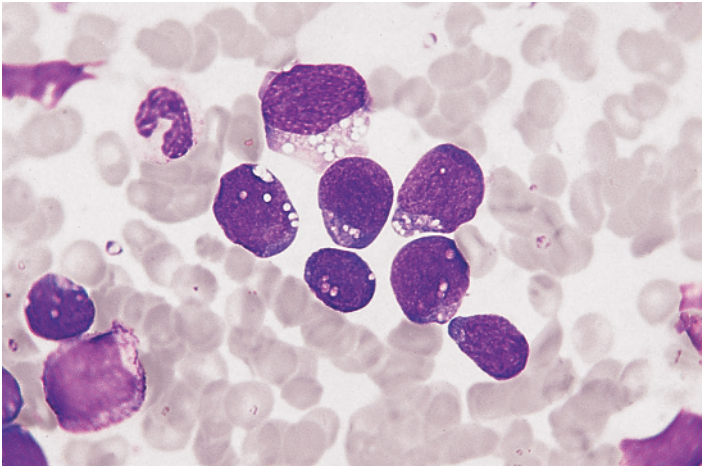


Fig. 1.69 BM film of a patient with FAB L3 ALL with the immunological phenotype being mature B cell. MGG $\times 100$.

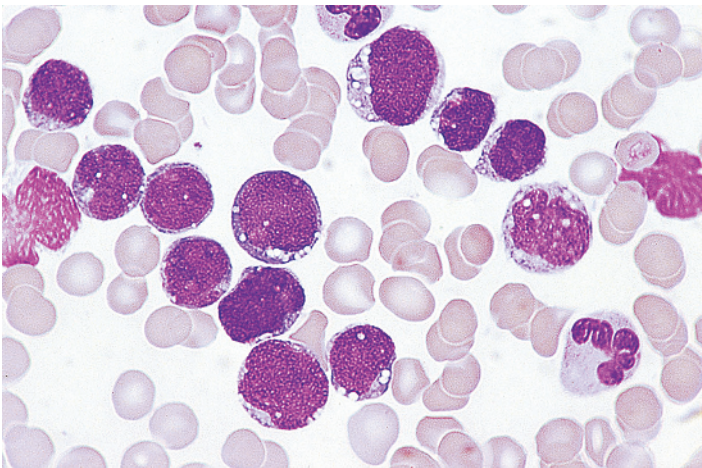


Fig. 1.70 PB film a patient with FAB L3 ALL which was unusual in being of T lineage and having a $t(7;9)$ translocation. MGG $\times 100$.

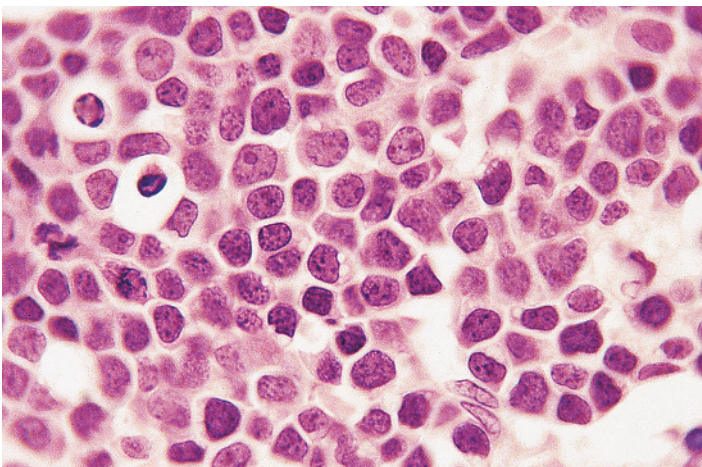


Fig. 1.71 Trephine biopsy section from a patient with FAB L3 ALL, B-cell phenotype; vacuolation of some of the blasts can be observed and there are two blasts undergoing apoptosis. Paraffin embedded, H&E $\times 100$.

much more common in AML. Cup-shaped nuclei in B-ALL have been strongly linked to *IKZF1* deletion [166]. In a minority of cases there are small numbers of azurophilic granules. Sometimes granules are prominent (Fig. 1.73) [41,167]. Occasional patients have lymphoblasts with coarse purple granules [104]. Rarely there are structures resembling Auer rods [168].

When immunophenotyping is available, cytochemical reactions are redundant in ALL. Their role is described in Chapter 8.

'Acute lymphoblastic leukaemia' of L3 subtype

In L3 'ALL' [29] the blast cells are medium to large and homogeneous. There is a moderate amount of cytoplasm. The nucleus is regular in shape, varying from round to somewhat oval. The chromatin pattern is uniformly stippled or homogeneous, with one or more prominent, sometimes vesicular, nucleoli. The mitotic index is high and many apoptotic cells are seen. The cytoplasm is strongly basophilic with variable but prominent vacuolation. Typical examples are shown in Figs 1.68, 1.69, 1.70 and 1.71.

Fig. 1.72 PB film of a patient with B-lineage ALL showing two cup-shaped blast cells; this feature is much more common in AML with *NPM1* and *FLT3*-ITD mutations than in ALL.

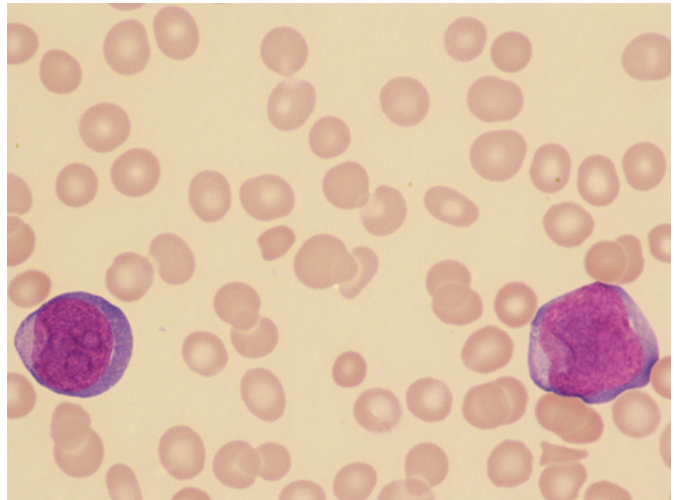
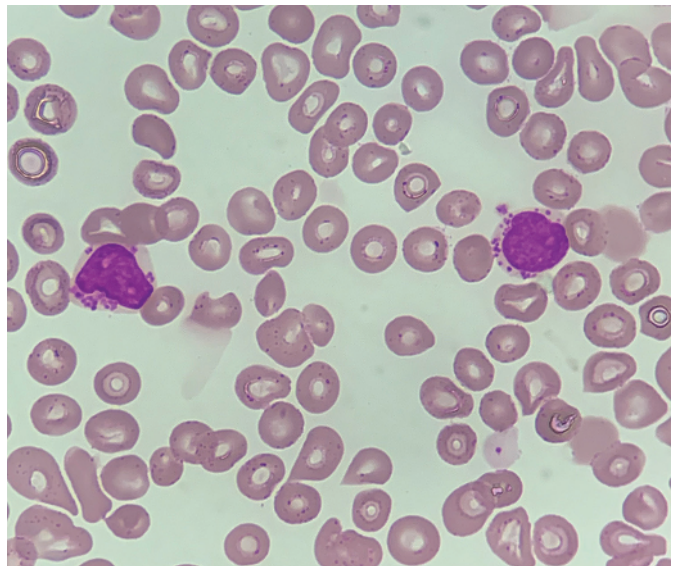


Fig. 1.73 PB film of a patient with B-lineage ALL showing two lymphoblasts with prominent granules. MGG $\times 100$. (With thanks to Dr Biswadip Hazarika, New Delhi.)



A minority of cases with L3 cytological features have a common ALL phenotype, a pre-B immunophenotype (cytoplasmic immunoglobulin positive) [169] or even a T-cell phenotype (Fig. 1.70) [170]; such cases continue to be classified as ALL. Sometimes cases with an immature immunophenotype show the *MYC::IGH* rearrangement characteristic of Burkitt lymphoma [171]. Rarely the immunophenotype is of MPAL [172] including hybrid B–T [173] or B-myeloid [174]. Cases have also been reported with a lack of B or T markers but with the characteristics of very early erythroid cells [175,176]; as these latter cases had cytogenetic findings usually associated with Burkitt lymphoma the involvement of a primitive cell with the potential for both B lymphoid and erythroid differentiation is suggested. Rarely L3 cytology is associated with small cell carcinoma of the lung [177] or undifferentiated carcinoma [178].

When a patient shows L3 cytological features, further investigation is essential and is urgent; immunophenotyping and cytogenetic or molecular genetic analysis are required. Patients with L3 cytology and a mature B immunophenotype may have not only Burkitt lymphoma-related translocations but also $t(14;18)(q32;q21.3)$; the prognosis of the

latter group is poor and optimal management has not been defined. Rare cases with a B-cell precursor immunophenotype have $t(9;22)(q34.1;q11.2)$ or $t(1;19)(q23;p13.3)$ and should be classified and treated as ALL.

Only when FAB L3 cytological features are associated with a precursor-B (or precursor-T) immunophenotype, can the diagnosis of ALL be sustained. Other cases are usually non-Hodgkin lymphoma, particularly Burkitt lymphoma.

Automated full blood counts in acute leukaemia

Modern automated instruments that perform full blood counts detect the majority of cases of AML and ALL, identifying blast cells by means of their light-scattering, cytochemical and other characteristics. The Siemens Advia 120 instrument includes peroxidase cytochemistry and produces scatterplots similar to those of earlier Bayer instruments, which are of some use in the further classification of AML (Fig. 1.74) [179]. Cases of ALL and FAB M0 and M7 AML show an abnormal cluster of large, peroxidase-negative cells

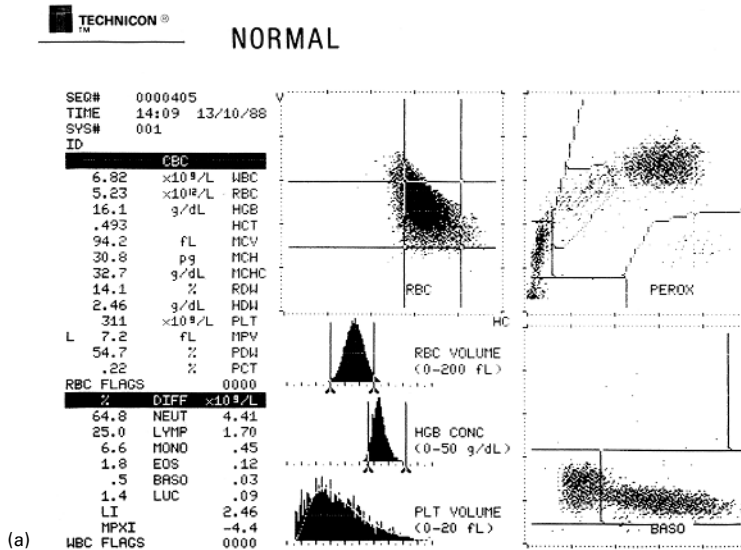


Fig. 1.74 Printouts from Bayer-Technicon H.1 series instruments on blood samples from a healthy volunteer and from patients with AML. (a) Histograms, red cell cytogram and scatterplots on a normal blood sample using a Bayer-Technicon H2 automated blood cell analyser. In the peroxidase cytogram separate clusters are identified, which represent neutrophils, eosinophils, monocytes, lymphocytes and 'large unstained (i.e. peroxidase-negative) cells' (LUC); in the basophil-lobularity channel there is a rounded head, which represents mononuclear cells (monocytes and lymphocytes) and an extended tail, which represents neutrophils and eosinophils. Basophils fall above the horizontal threshold.

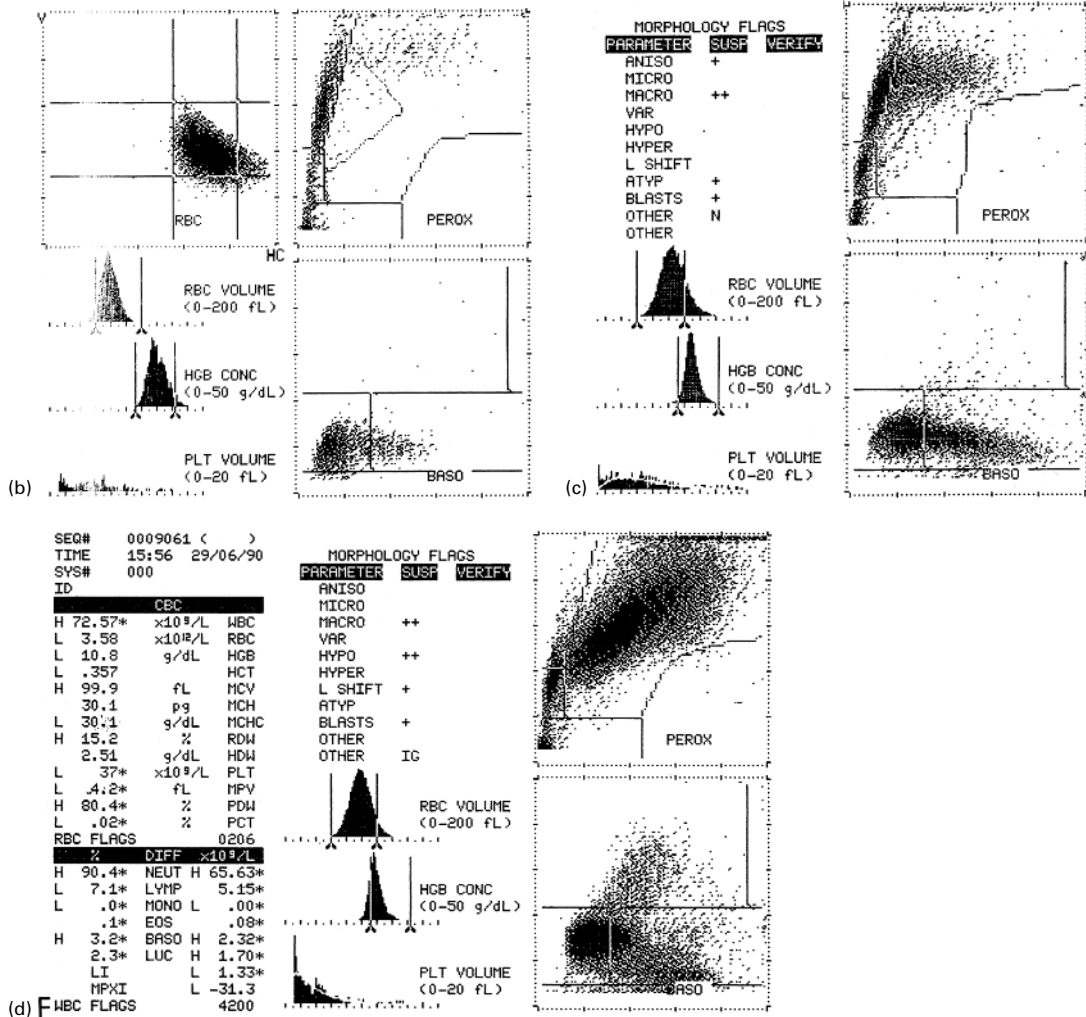


Fig. 1.74 (Continued) (b) Histograms, red cell cytogram and scatterplots on a blood sample from a patient with FAB M0 AML performed on a Bayer-Technicon H2 automated analyser. The blasts are peroxidase negative and therefore fall into the LUC area; the only indication that this is AML not ALL is that the neutrophil cluster is more dispersed than normal, indicating neutrophil dysplasia. Note also the dense mononuclear cluster expanded leftwards in the basophil-lobularity channel, which indicates the presence of blast cells. The platelet histogram shows that there is severe thrombocytopenia. Similar scattergrams to this are also seen in FAB M7 AML. (c) Histograms and scatterplots on a blood sample from a patient with FAB M1 AML performed on a Bayer-Technicon H2 automated analyser. Some of the blasts fall into the LUC area but others have peroxidase activity and thus fall into the areas normally occupied by monocytes and neutrophils; the platelet histogram shows thrombocytopenia. (d) Histograms and scatterplots on a blood sample from a patient with FAB M2 AML performed on a Bayer-Technicon H2 automated analyser. The blasts show more peroxidase activity than those in the case of FAB M1 AML, falling further to the right in the peroxidase histogram. The basophil-lobularity histogram shows the presence of blast cells expanding the mononuclear cluster leftwards and, in addition, causing pseudobasophilia since some of them fall in the area normally occupied by basophils; there is also thrombocytopenia.

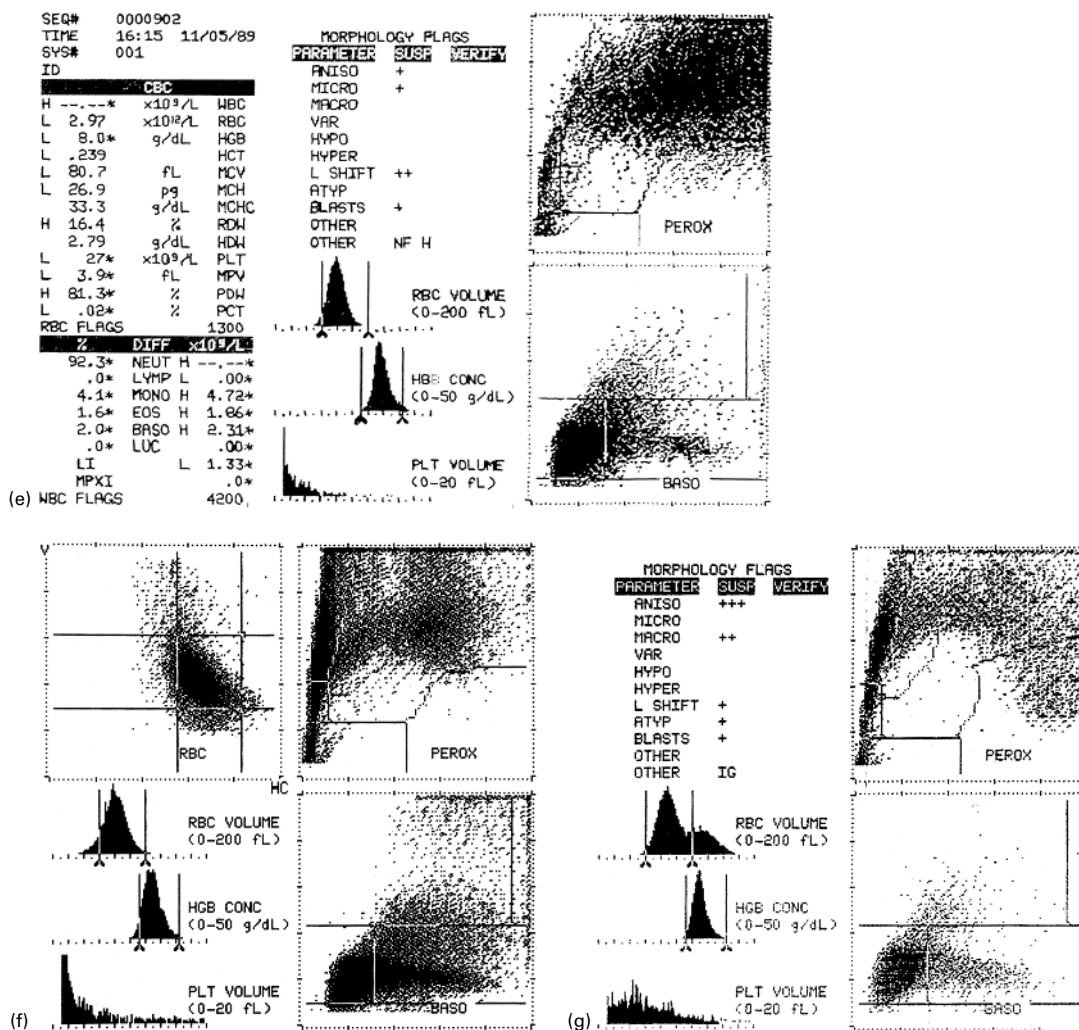


Fig. 1.74 (Continued) (e) Histograms and scatterplots on a blood sample from a patient with FAB M3V AML performed on a Bayer-Technicon H2 automated analyser. The abnormal promyelocytes are intensely peroxidase positive and form a triangular cluster based on the right-hand margin; there is pseudobasophilia and thrombocytopenia. The scattergrams in FAB M3 AML show the same features as are shown in this case of FAB M3V AML. (f) Histograms, red cell cytogram and scatterplots on a blood sample from a patient with FAB M4 AML performed on a Bayer-Technicon H2 automated analyser. There are two populations of blasts, peroxidase-negative monoblasts falling into the LUC area and peroxidase-positive myeloblasts forming a large abnormal cloud in the neutrophil area; there is pseudobasophilia and thrombocytopenia. Note that the blast cluster in the LUC area extends further upwards than in the case of FAB M1 AML (cf. part c of this figure) indicating that many of the blasts are very large. (g) Histograms and scatterplots on a blood sample from a patient with M4Eo AML performed on a Bayer-Technicon H2 automated analyser. The peroxidase scatterplot is similar to that seen in FAB M4 AML but extension into the eosinophil area is apparent; there is pseudobasophilia and thrombocytopenia. The double population shown in the red cell histogram is a result of blood transfusion, the patient having macrocytic red cells and the transfused cells being normocytic.

(Fig. 1.74b). In M1 AML it is apparent that blasts have peroxidase activity (Fig. 1.74c), and in M2 AML the peroxidase activity is stronger (Fig. 1.74d), giving a higher mean peroxidase score. In M3 and M3V AML there is very strong peroxidase activity, giving a characteristic scatterplot, which can provide rapid confirmation of a provisional diagnosis of M3V AML (Fig. 1.74e). M4 (Fig. 1.74f, g) and M5 AML show blasts cells with variable peroxidase activity.

ABX and related instruments (Horiba Medical) employ SBB instead of peroxidase cytochemistry and give similar information to Siemens instruments. Other automated instruments, for example those produced by Beckman-Coulter, Sysmex and Abbott, also produce abnormal scatterplots in acute leukaemia. These show some difference between AML and ALL but do not differentiate well between FAB subclasses [180].

References

- 1 Thol F, Klesse S, Köhler L, Gabdoulline R, Kloos A, Liebich A *et al.* (2017) Acute myeloid leukemia derived from lympho-myeloid clonal hematopoiesis. *Leukemia*, **31**, 1286–1295.
- 2 Feldman AL, Minniti C, Santi M, Downing JR, Raffeld M and Jaffe ES (2004) Histiocytic sarcoma after acute lymphoblastic leukaemia: a common clonal origin. *Lancet Oncol*, **5**, 248–250.
- 3 Feldman AL, Berthold F, Arceci RJ, Abramowsky C, Shehata BM, Mann KP *et al.* (2005) Clonal relationship between precursor T-lymphoblastic leukaemia/lymphoma and Langerhans-cell histiocytosis. *Lancet Oncol*, **6**, 435–437.
- 4 Hauer J, Fischer U and Borkhardt A (2021) Toward prevention of childhood ALL by early-life immune training. *Blood*, **318**, 1412–1428.
- 5 Churpek JE, Pyrtel K, Kanchi KL, Shao J, Koboldt D, Miller CA *et al.* (2015) Genomic analysis of germ line and somatic variants in familial myelodysplasia/acute myeloid leukemia. *Blood*, **126**, 2484–2490.
- 6 Tawana K and Fitzgibbon J (2016) Inherited *DDX41* mutations: 11 genes and counting. *Blood*, **127**, 960–961.
- 7 The University of Chicago Hematopoietic Malignancies Risk Team (2016) How I diagnose and manage individuals at risk for inherited myeloid malignancies. *Blood*, **128**, 1800–1813.
- 8 Kohlmann W and Schiffman JD (2016) Discussing and managing hematologic germ line variants. *Blood*, **128**, 2497–2503.
- 9 Sarasin A, Quentin S, Droin N, Sahbatou M, Saada V, Auger N *et al.* (2019) Familial predisposition to TP53/complex karyotype MDS and leukemia in DNA repair-deficient xeroderma pigmentosum. *Blood*, **133**, 2718–2724.
- 10 Douglas SPM, Siipola P, Kovanen PE, Pyörälä M, Kakko S, Savolainen ER *et al.* (2019) *ERCC6L2* defines a novel entity within inherited acute myeloid leukemia. *Blood*, **133**, 2724–2728.
- 11 Niblock A, McConville DO and Morrison PJ (2017) Zygodactyly is strongly associated with acute myeloid leukaemia. *Br J Haematol*, **177**, 659–660.
- 12 Tasian SK and Hunger SP (2017) Genomic characterization of paediatric acute lymphoblastic leukaemia: an opportunity for precision medicine therapeutics. *Br J Haematol*, **176**, 867–882.
- 13 Rampersaud E, Ziegler DS, Iacobucci I, Payne-Turner D, Churchman ML, Schrader KA *et al.* (2019) Germline deletion of *ETV6* in familial acute lymphoblastic leukemia. *Blood Adv*, **3**, 1039–1046.
- 14 Moriyama T, Relling MV and Yang JJ (2015) Inherited genetic variation in childhood acute lymphoblastic leukemia. *Blood*, **125**, 3988–3995.
- 15 Moriyama T, Metzger ML, Wu G, Nishii R, Qian M, Devidas M *et al.* (2015) Germline genetic variation in *ETV6* and risk of childhood acute lymphoblastic leukaemia: a systematic genetic study. *Lancet Oncol*, **16**, 1659–1666.
- 16 Perez-Andreu V, Roberts KG, Xu H, Smith C, Zhang H, Yang W *et al.* (2015) A genome-wide association study of susceptibility to acute lymphoblastic leukemia in adolescents and young adults. *Blood*, **125**, 680–686.
- 17 Yoshida N, Sakaguchi H, Muramatsu H, Okuno Y, Song C, Dovat S *et al.* (2017) Germline IKAROS mutation associated with primary

- immunodeficiency that progressed to T-cell acute lymphoblastic leukemia. *Leukemia*, **31**, 1221–1223.
- 18 Qian M, Xu H, Perez-Andreu V, Roberts KG, Zhang H, Yang W *et al.* (2019) Novel susceptibility variants at the *ERG* locus for childhood acute lymphoblastic leukemia in Hispanics. *Blood*, **133**, 724–729.
 - 19 Gocho Y and Yang JJ (2019) Genetic defects in hematopoietic transcription factors and predisposition to acute lymphoblastic leukemia. *Blood*, **134**, 793–797.
 - 20 Järviaho T, Bang B, Zachariadis V, Taylan F, Moilanen J, Möttönen M *et al.* (2019) Predisposition to childhood acute lymphoblastic leukemia caused by a constitutional translocation disrupting *ETV6*. *Blood Adv*, **3**, 2722–2731.
 - 21 Järviaho T, Zachariadis V, Tesi B, Chiang S, Bryceson YT, Möttönen M *et al.* (2019) Microdeletion of 7p12.1p13, including *IKZF1*, causes intellectual impairment, overgrowth, and susceptibility to leukaemia. *Br J Haematol*, **185**, 354–357.
 - 22 Valdez JM, Nichols KE and Kesserwan C (2017) Li-Fraumeni syndrome: a paradigm for the understanding of hereditary cancer predisposition. *Br J Haematol*, **176**, 539–552.
 - 23 Jones RJ and DeBaun MR (2021) Leukemia after gene therapy for sickle cell disease: insertional mutagenesis, busulfan, both, or neither. *Blood*, **138**, 942–947.
 - 24 Lichtman MA (2012) Obesity and the risk of chronic myelogenous leukemia: is this another example of the neoplastic effects of increased body fat? *Leukemia*, **26**, 183–184.
 - 25 Bennett JM, Catovsky D, Daniel MT, Flandrin G, Galton DAG, Gralnick HR and Sultan C (1976) Proposals for the classification of the acute leukaemias (FAB cooperative group). *Br J Haematol*, **33**, 451–458.
 - 26 Bennett JM, Catovsky D, Daniel MT, Flandrin G, Galton DAG, Gralnick HR and Sultan C (1980) A variant form of acute hypergranular promyelocytic leukaemia (M3). *Br J Haematol*, **44**, 169–170.
 - 27 Bennett JM, Catovsky D and Daniel M-T (1985) Criteria for the diagnosis of acute leukemia of megakaryocytic lineage (M7): a report of the French–American–British cooperative group. *Ann Intern Med*, **103**, 460–462.
 - 28 Bennett JM, Catovsky D, Daniel MT, Flandrin G, Galton DAG, Gralnick HR and Sultan C (1985) Proposed revised criteria for the classification of acute myeloid leukemia. *Ann Intern Med*, **103**, 626–629.
 - 29 Bennett JM, Catovsky D, Daniel MT, Flandrin G, Galton DAG, Gralnick HR and Sultan C (1991) Proposal for the recognition of minimally differentiated acute myeloid leukaemia (AML M0). *Br J Haematol*, **78**, 325–329.
 - 30 WHO Classification of Tumours Editorial Board. *Haematolymphoid Tumours*, WHO Classification of Tumours Series, 5th edn, vol. 11 (online beta version ahead of print). International Agency for Research on Cancer, Lyon. <https://tumourclassification.iarc.who.int/chapters/63> (last accessed February 2023).
 - 31 Arber DA, Orazi A, Hasserjian RP, Borowitz MA, Calvo KR, Kvasnicka H-M *et al.* (2022) International Consensus Classification of myeloid neoplasms and acute leukemias: integrating morphologic, clinical, and genomic data. *Blood*, **140**, 1200–1228.
 - 32 Bain BJ (2016) Erythrocyte and leucocyte cytochemistry. In: Bain BJ, Bates I and Laffan MA (eds) *Dacie and Lewis Practical Haematology*, 12th edn. Churchill Livingstone, Edinburgh, pp. 312–329.
 - 33 Hayhoe FGJ and Quaglini D (1988) *Haematological Cytochemistry*, 2nd edn. Churchill Livingstone, Edinburgh.
 - 34 Kaliks RA, Silveira PAA, Osawa A, Campregher PV, Bacal NS and Velloso EDRP (2014) Metastatic melanoma mimicking acute leukaemia. *Br J Haematol*, **165**, 1.
 - 35 Bennett JM, Catovsky D, Daniel MT, Flandrin G, Galton DAG, Gralnick HR and Sultan C (1982) Proposals for the classification of the myelodysplastic syndromes. *Br J Haematol*, **51**, 189–199.
 - 36 Merino A and Esteve J (2005) Acute myeloid leukaemia with peculiar blast cell inclusions and pseudo-eosinophilia. *Br J Haematol*, **131**, 286.
 - 37 Yin J, Zhu S, Luo Y, Lin Z and Chen Y (2020) Acute myeloid leukaemia with Auer rods within

- pseudo-Chédiak-Higashi granules. *Br J Haematol*, **188**, 9.
- 38 Yamamoto K, Okamura A, Sanada Y, Yakushijin K, Matsuoka H and Minami H (2013) Micronuclei-associated MYC amplification in the form of double minute chromosomes in acute myeloid leukemia. *Am J Hematol*, **88**, 717–718.
- 39 Skeith L and Lee A (2016) Abnormal chromatin clumping in myeloblasts. *Blood*, **127**, 2645.
- 40 Mufti GJ, Bennett JM, Goasguen J, Bain BJ, Baumann I, Brunning R *et al.* (2008) Diagnosis and classification of MDS: International Working Group on Morphology of MDS (IWGM-MDS) consensus proposals for the definition and enumeration of myeloblasts and ring sideroblasts. *Haematologica*, **93**, 1712–1717.
- 41 Hazarika B and Bain BJ (2023) Granular B lymphoblastic leukemia. *Am J Hematol*, **98**, 210–211.
- 42 Bunting ST and Lew G (2014) “Russell-like” bodies in Philadelphia chromosome-positive B-lymphoblastic leukemia. *Blood*, **123**, 2448.
- 43 Gavillet M, Spertini O and Blum S (2018) Pseudo Chédiak-Higashi anomaly in blasts from acute lymphoblastic leukemia. *Leuk Res*, **70**, 87–90.
- 44 Hou X, Wang X, Liu C, Ma F and Hao J (2021) Abnormally hypersegmented neutrophilia in pediatric acute myeloid leukemia associated with t(2;11)(q31;p15) and NUP98 rearrangement. *J Pediatr Hematol Oncol*, **46**, 156–158.
- 45 Mangum DS, Bishop JD, Zhou Y, Cheng C, Karol SF, Rubnitz JE *et al.* (2023) Characterisation of children and adolescents with acute lymphoblastic leukaemia who presented without peripheral blood blasts at diagnosis. *Br J Haematol*, **200**, 338–343.
- 46 Loyola I, Cadahía P and Trastoy A (2018) Hypergranular lymphoblastic leukaemia. *Br J Haematol*, **182**, 466.
- 47 Cuneo A, Ferrant A and Michaux JL (1995) Cytogenetic profile of minimally differentiated (FAB M0) acute myeloid leukaemia: correlation and clinicobiologic findings. *Blood*, **85**, 3688–3695.
- 48 Li C-Y and Yam LT (1994) Cytochemistry and immunochemistry in hematologic diagnoses. *Hematol Oncol Clin North Am*, **8**, 665–681.
- 49 Ohno R and Tomonaga M (2002) JALSG studies on adult AML: myeloperoxidase is a strong prognostic factor, even in AML (excluding APL) with normal karyotype. *Leuk Lymphoma*, **44** (Suppl. S6).
- 50 Cheson BD, Bennett JM, Kopecky KJ, Büchner T, Willman CL, Estey EH *et al.* (2003) Revised recommendations of the International Working Group for Diagnosis, Standardization of Response Criteria, Treatment Outcomes, and Reporting Standards for Therapeutic Trials in Acute Myeloid Leukemia. *J Clin Oncol*, **21**, 4642–4649.
- 51 de Greef GE, van Putten WL, Boogaerts M, Huijgens PC, Verdonck LF, Vellenga E *et al.*; The Dutch-Belgian Hemato-Oncology Co-operative Group HOVON; The Swiss Group for Clinical Cancer Research SAKK (2005) Criteria for defining a complete remission in acute myeloid leukaemia revisited. An analysis of patients treated in HOVON-SAKK co-operative group studies. *Br J Haematol*, **128**, 184–191.
- 52 Kirtane K and Lee SJ (2017) Racial and ethnic disparities in hematologic malignancies. *Blood*, **130**, 1699–1705.
- 53 Parkin JL, McKenna RW and Brunning RD (1982) Philadelphia-positive blastic leukaemia: ultrastructural and ultracytochemical evidence of basophil and mast cell differentiation. *Br J Haematol*, **52**, 663–677.
- 54 Polli N, O’Brien M, Tavares de Castro J, Matutes E, San Miguel JF and Catovsky D (1985) Characterization of blast cells in chronic granulocytic leukaemia in transformation, acute myelofibrosis and undifferentiated leukaemia. *Br J Haematol*, **59**, 277–296.
- 55 Cawley JC and Hayhoe FGJ (1973) *The Ultrastructure of Haemic cells*. W.B. Saunders Company, London.
- 56 Golomb HM, Rowley JD, Vardiman JW, Testa JR and Butler A (1980) ‘Microgranular’ acute promyelocytic leukaemia: a distinct clinical, ultrastructural and cytogenetic entity. *Blood*, **55**, 253–259.
- 57 McKenna RW, Parkin J, Bloomfield CD, Sundberg RD and Brunning RD (1982) Acute promyelocytic leukaemia: a study of 39 cases with identification of a hyperbasophilic microgranular variant. *Br J Haematol*, **50**, 201–214.

- 58 Shaft D, Shtalrid M, Berebi A, Catovsky D and Resnitzky P (1998) Ultrastructural characteristics and lysozyme content of hypergranular and variant type of acute promyelocytic leukaemia. *Br J Haematol*, **103**, 729–739.
- 59 O'Brien M, Catovsky D and Costello C (1980) Ultrastructural cytochemistry of leukaemic cells. Characterization of the early small granules of monoblasts. *Br J Haematol*, **45**, 201–208.
- 60 Breton-Gorius J, Van Haeke D, Pryzwansky KB, Guichard J, Tabilio A, Vainchenker W and Carmel R (1984) Simultaneous detection of membrane markers with monoclonal antibodies and peroxidatic activities in leukaemia: ultrastructural analysis using a new method of fixation preserving the platelet peroxidase. *Br J Haematol*, **58**, 447–458.
- 61 Crisan D, Kaplan SS, PENCHANSKY L and Krause JR (1993) A new procedure for cell lineage determination in acute leukemias: myeloperoxidase mRNA detection. *Diagn Mol Pathol*, **2**, 65–73.
- 62 Kaleem Z and White G (2001) Diagnostic criteria for minimally differentiated acute myeloid leukemia (AML-M0): evaluation and a proposal. *Am J Clin Pathol*, **115**, 876–884.
- 63 Roumier C, Eclache V, Imbert M, Davi F, MacIntyre E, Garand R *et al.* (2003) M0 AML, clinical and biologic features of the disease, including *AML1* gene mutations: a report of 59 cases by the Groupe Français d'Hématologie Cellulaire (GFHC) and the Groupe Français de Cytogénétique Hématologique (GFCH). *Blood*, **101**, 1277–1283.
- 64 Cascavilla N, Melillo L, d'Arena G, Greco MM, Carella AM, Sajeve MR *et al.* (2000) Minimally differentiated acute myeloid leukemia (AML M0): clinicobiological findings in 29 cases. *Leuk Lymphoma*, **37**, 105–113.
- 65 Löwenberg B (2001) Prognostic factors in acute myeloid leukaemia. *Baillière's Clin Haematol*, **14**, 65–75.
- 66 Preudhomme C, Warot-Loze D, Roumier C, Gardel-Duflos N, Garand R, Lai JL *et al.* (2000) High incidence of biallelic point mutations in the Runt domain of the AML/PEGBP2 α B gene in M0 acute myeloid leukemia and in myeloid malignancies with acquired trisomy 21. *Blood*, **96**, 2862–2869.
- 67 Kao H-W, Liang D-C, Wu J-H, Kuo M-C, Wang P-N, Yang C-P *et al.* (2014) Gene mutation patterns in patients with minimally differentiated acute myeloid leukemia. *Neoplasia*, **16**, 481–488.
- 68 Silva FP, Swagemakers SM, Erpelinck-Verschueren C, Wouters BJ, Delwel R, Vrieling H *et al.* (2009) Gene expression profiling of minimally differentiated acute myeloid leukemia: M0 is a distinct entity subdivided by *RUNX1* mutation status. *Blood*, **114**, 3001–3007.
- 69 Barbaric D, Alonzo TA, Gerbing RB, Meshinchi S, Heerema NA, Barnard DR *et al.* (2007) Minimally differentiated acute myeloid leukemia (FAB AML-M0) is associated with an adverse outcome in children: a report from the Children's Oncology Group, studies CCG-2891 and CCG-2961. *Blood*, **109**, 2314–2321.
- 70 Elghetany MT (1999) Double esterase staining of the bone marrow contributes to lineage identification in a case of minimally differentiated acute myeloid leukaemia (AML M0). *Clin Lab Haematol*, **21**, 293–295.
- 71 Shanmugam V and Dorfman DM (2019) Acute myeloid leukemia with minimal differentiation (AML M0) mimicking acute lymphoblastic leukemia. *Am J Hematol*, **94**, 955–956.
- 72 Ohnishi H, Yoshino H, Yoneyama R, Ishii M, Watanabe T and Bessho F (2008) Faggot formation in mature neutrophils and metamyelocytes in acute myeloid leukemia without maturation. *Pediatr Hematol Oncol*, **25**, 165–170.
- 73 McCrae T (1905) Acute lymphatic leukaemia with a report of five cases. *BMJ*, **i**, 404–408.
- 74 Auer J (1906) Some hitherto undescribed structures found in the large lymphocytes of a case of acute leukemia. *Am J Med Sci*, **131**, 1002–1015.
- 75 Seymour JF (2006) 101 years of McCrae's (not Auer's) rods. *Br J Haematol*, **133**, 690.
- 76 Bain BJ (2011) Auer rods or McCrae rods? *Am J Hematol*, **86**, 689.
- 77 Newburger PE, Novak TJ and McCaffrey RP (1983) Eosinophilic cytoplasmic inclusions in fetal leukocytes: are Auer bodies a recapitulation of fetal morphology. *Blood*, **61**, 593–595.

- 78 Creutzig U, Zimmermann M, Ritter J, Henze G, Graf N, Löffler H and Schellong G (1999) Definition of a standard-risk group in children with AML. *Br J Haematol*, **104**, 630–639.
- 79 Sorà F, Chiusolo P, Laurenti L, Autore F, Giammarco A and Sica S (2016) Massive pulmonary embolism at the onset of acute promyelocytic leukemia. *Med J Hematol Inf Dis*, **8**, e2016027.
- 80 Matsuo T, Jain NC and Bennett JM (1988) Nonspecific esterase of acute promyelocytic leukemia. *Am J Hematol*, **29**, 148–151.
- 81 Brunning RD and McKenna RW (1994) *Tumors of the Bone Marrow*, 3rd Series, Fascicle 9. Armed Forces Institute of Pathology, Washington.
- 82 Jerez A, del Mar Osma M, Amigo ML and Ortuño FJ (2010) Faggot cells in an HIV-positive patient with inv(16)/therapy-related acute myeloid leukaemia. *Br J Haematol*, **150**, 646.
- 83 Wuillème S and Le Bris Y (2015) Misleading acute promyelocytic leukemia morphology. *Blood*, **125**, 3815.
- 84 Mo X and Chen H (2020) Acute promyelocytic leukaemia with myeloperoxidase-negative rectangular inclusions. *Br J Haematol*, **188**, 8.
- 85 Zhang J, Li M and He Y (2019) Acute promyelocytic leukaemia with increased basophils. *Br J Haematol*, **185**, 7.
- 86 Jiang X, Zhang L and Zhou D (2016) Acute promyelocytic leukaemia with promyelocyte count below 20%. *Br J Haematol*, **173**, 11.
- 87 Sawhney S, Holtzman NG, Davis DL, Kaizer H, Giffi V, Emadi A and Koka R (2017) Promyelocytic sarcoma of the right humerus: an unusual clinical presentation with unique diagnostic and treatment considerations. *Clin Case Rep*, **5**, 1874–1877.
- 88 Brown C and Opat S (2006) An unusual case of indigestion: persistence of phagocytosed Auer rods in acute promyelocytic leukaemia. *Br J Haematol*, **133**, 112.
- 89 Luu HS and Rahaman PA (2015) Mature neutrophils with Auer rods following treatment with all-*trans*-retinoic acid for acute promyelocytic leukemia. *Blood*, **126**, 121.
- 90 Koike T, Tatewaki W, Aoki A, Yoshimoto H, Yagisawa K, Hashimoto S *et al.* (1992) Brief report: severe symptoms of hyperhistaminaemia after the treatment of acute promyelocytic leukemia with tretinoin (all-*trans*-retinoic acid). *N Engl J Med*, **327**, 385–387.
- 91 Kumakura S, Ishikura H, Tsumura H and Kobayashi S (2003) Phagocytosis of terminally differentiated acute promyelocytic leukemia cells by marrow histiocytes during treatment with all-*trans* retinoic acid. *Leuk Lymphoma*, **44**, 2147–2150.
- 92 Roberts TF, Sprague K, Schenkein D, Miller KB and Relias V (2000) Hyperleucocytosis during induction therapy with arsenic trioxide for relapsed acute promyelocytic leukemia associated with central nervous system infarction. *Blood*, **96**, 4000–4001.
- 93 Kwong JHY, Leung RYY, Wong MLG, Gill H and Kwong YL (2017) Primary myelofibrosis presenting in acute promyelocytic transformation. *Br J Haematol*, **178**, 349.
- 94 Medical Research Council's Working Party on Leukaemia in Adults (1975) The relationship between morphology and other features of acute myeloid leukaemia, and their prognostic significance. *Br J Haematol*, **31** (Suppl. 1), 165–180.
- 95 Testa JR, Golomb HM, Rowley JD, Vardiman JW and Sweet DL (1978) Hypergranular promyelocytic leukaemia (APL): cytogenetic and ultrastructural specificity. *Blood*, **52**, 272–280.
- 96 Berger R, Bernheim A, Daniel M-T, Valensi F and Flandrin G (1981) Karyotype and cell phenotypes in primary acute leukemias. *Blood Cells*, **7**, 287–292.
- 97 Aventin A, Mateu R, Martino R, Colomer D and Bordes R (1998) A case of cryptic acute promyelocytic leukemia. *Leukemia*, **12**, 1490–1506.
- 98 Ahmed SO, Deplano S, May PC and Bain BJ (2013) Observation of Auer rods in crushed cells helps in the diagnosis of acute promyelocytic leukemia. *Am J Hematol*, **88**, 236.
- 99 Sun T and Weiss R (1991) Hand-mirror variant of microgranular acute promyelocytic leukemia. *Leukemia*, **5**, 266–269.
- 100 Fenaux P, Chomienne C and Degos L (2001) Treatment of acute promyelocytic leukaemia. *Baillière's Clin Haematol*, **14**, 153–174.
- 101 Cui W, Qing Sm Xu Y, Hao Y, Xue Y and He G (2002) Negative stain for myeloid peroxidase and

- Sudan black B in acute promyelocytic leukemia (APL) cells: report of two patients with APL variant. *Haematologica*, **87**, ECR16.
- 102 Heiblig M, Paubelle E, Plesa A, Geay MO, Manzoni D, Gazzo S *et al.* (2017) Comprehensive analysis of a myeloperoxidase-negative acute promyelocytic leukemia. *Blood*, **129**, 128–131.
- 103 Scott CS, Patel D, Drexler HG, Master PS, Limbert HJ and Roberts BE (1989) Immunophenotypic and enzymatic studies do not support the concept of mixed monocytic–granulocytic differentiation in acute promyelocytic leukaemia (M3): a study of 44 cases. *Br J Haematol*, **71**, 505–509.
- 104 Löffler H, Rastetter J and Haferlach T (2005) *Atlas of Clinical Hematology*, 6th edn, Springer, Berlin.
- 105 Sud A, Morilla R, Ethell M, Taussig D and Liapis K (2015) Green-grey crystals in acute myeloid leukaemia. *Br J Haematol*, **168**, 618.
- 106 Yam LT, Li CY and Crosby WH (1971) Cytochemical identification of monocytes and granulocytes. *Am J Clin Pathol*, **55**, 283–290.
- 107 Weltermann A, Pabinger I, Geissler K, Jäger U, Gisslinger H, Knöbl P *et al.* (1998) Hypofibrinogenemia in non-M3 acute myeloid leukemia. Incidence, clinical and laboratory characteristics and prognosis. *Leukemia*, **12**, 1182–1186.
- 108 Sánchez CM, de Castro DR, de Viñaspre AVG, Zilaurren AU, Abad AM and de Castro JMG (2020) Acute monoblastic leukemia with erythrophagocytosis and absence of KAT6A rearrangement. *Turk J Haematol*, **37**, 282–283.
- 109 Hatano K, Nagai T, Matsuyama T, Sakaguchi Y, Fujiwara S, Oh I *et al.* (2015) Leukemia cells directly phagocytose blood cells in AML-associated hemophagocytic lymphohistiocytosis: a case report and review of the literature. *Acta Haematol*, **133**, 98–100.
- 110 Bouvier S and Martin M (2017) Atypical monoblasts with micronuclei. *Blood*, **130**, 1958.
- 111 Podvin B, Guermouche H, Fournier E, Berthon C, Duployez N and Roche-Lestienne C (2022) Acute myeloid leukaemia with double minute chromosomes and encompassing the 8q24 region. *Br J Haematol*, **198**, 413.
- 112 Laurencet FM, Chapuis B, Roux-Lombard P, Dayer JM and Beris P (1994) Malignant histiocytosis in the leukemic stage: a new entity (M5c-AML) in the FAB classification? *Leukemia*, **8**, 502–506.
- 113 Haferlach T, Schoch C, Schnittger S, Kern W, Löffler H and Hiddemann W (2002) Distinct genetic patterns can be identified in acute monoblastic and acute monocytic leukaemia (FAB AML M5a and M5b); a study of 124 patients. *Br J Haematol*, **118**, 426–431.
- 114 Zwaan ChM and Kaspers GJL (2004) Possibilities for tailored and targeted therapy in paediatric acute myeloid leukaemia. *Br J Haematol*, **127**, 264–279.
- 115 Domingo-Claros A, Larriba I, Rozman M, Irriguible D, Vallespi T, Aventin A *et al.* (2002) Acute erythroid neoplastic proliferations. A biological study based on 62 patients. *Haematologica*, **87**, 148–153.
- 116 Mazzella FM, Kowal-Vern A, Shrit A, Wibowo AL, Rector JT, Cotelingam JD *et al.* (1998) Acute erythroleukemia: evaluation of 48 cases with reference to classification, cell proliferation, cytogenetics, and prognosis. *Am J Clin Pathol*, **110**, 590–598.
- 117 Park S, Picard F, Azgui Z, Viguie F, Merlat A, Guesnu M *et al.* (2002) Erythroleukemia: a comparison between previous FAB approach and the WHO classification. *Leuk Res*, **26**, 423–429.
- 118 Villeval JL, Cramer F, Lemoine A, Henri A, Bettaieb A, Bernaudin F *et al.* (1986) Phenotype of early erythroblastic leukaemias. *Blood*, **68**, 1167–1174.
- 119 Hasserjian RP, Howard J, Wood A, Henry K and Bain B (2001) Acute erythremic myelosis (true erythroleukaemia): a variant of AML FAB-M6. *J Clin Pathol*, **54**, 205–209.
- 120 Yoshida S, Kuriyama K, Miyazaki Y, Taguchi J, Fukushima T, Honda M *et al.* (2001) De novo acute myeloid leukemia in the elderly: a consistent fraction of long-term survivors by standard-dose chemotherapy. *Leuk Res*, **25**, 33–38.
- 121 Davey FR, Abraham N, Brunetto VL, MacCallum JM, Nelson DA, Ball ED *et al.* (1995) Morphological characteristics of

- erythroleukemia (acute myeloid leukemia; FAB M6): a CALGB study. *Am J Hematol*, **49**, 29–38.
- 122 Preiss BS, Kerndrup GB, Schmidt KG, Sorensen AG, Clausen N-AT, Gadeberg OV *et al.* (2003) Cytogenetic findings in adult de novo acute myeloid leukaemia. A population-based study of 303/337 patients. *Br J Haematol*, **123**, 219–234.
- 123 Gruber TA and Downing JR (2015) The biology of pediatric acute megakaryoblastic leukemia. *Blood*, **126**, 943–949.
- 124 Inaba H, Zhou Y, Ablal O, Adachi S, Auvrignon A, Beverloo HB *et al.* (2015) Heterogeneous cytogenetic subgroups and outcomes in childhood acute megakaryoblastic leukemia: a retrospective international study. *Blood*, **126**, 1575–1584.
- 125 Dastague N, Lafage-Pochitaloff M, Pagès M-P, Radford I, Bastard C, Talmant P *et al.* (2002) Cytogenetic profile of childhood and adult megakaryoblastic leukemia (M7): a study of the Groupe Français de Cytogénétique Hématologique (GFCH). *Blood*, **100**, 618–626.
- 126 Hama A, Yagasaki H, Takahashi Y, Nishio N, Muramatsu H, Yoshida N *et al.* (2008) Acute megakaryoblastic leukaemia (AMKL) in children: a comparison of AMKL with and without Down syndrome. *Br J Haematol*, **140**, 552–561.
- 127 Oki Y, Kantarjian HM, Zhou X, Cortes J, Faderl S, Verstovsek S *et al.* (2006) Adult acute megakaryocytic leukemia: an analysis of 37 patients treated at M. D. Anderson Cancer Center. *Blood*, **107**, 880–884.
- 128 Athale UH, Razzouk BI, Raimondi SC, Tong X, Behm FG, Head DR *et al.* (2001) Biology and outcome of childhood acute megakaryoblastic leukemia: a single institution's experience. *Blood*, **87**, 3727–3732.
- 129 Wong KP and Yu PH (2010) Erythrophagocytic megakaryoblasts in acute megakaryoblastic leukaemia. *Br J Haematol*, **148**, 672.
- 130 Wang E and Stoecker M (2010) "Cannibalistic" phagocytosis in acute megakaryoblastic leukemia (AML M7) with t(10;17)(p15;q22). *Leuk Lymphoma*, **51**, 1944–1947.
- 131 Plesa A and Sujobert P (2019) Cannibalistic acute myeloid leukemia with ZMYND11-MBTD1 fusion. *Blood*, **133**, 1789.
- 132 Tallman MS, Neuberg D, Bennett JM, Francois CJ, Paietta E, Wiernik PH *et al.* (2000) Acute megakaryocytic leukemia: the Eastern Cooperative Oncology Group experience. *Blood*, **96**, 2405–2411.
- 133 Sato T, Matsunaga T, Kida M, Morii K, Machida T, Kawano Y *et al.* (2004) Interleukin-11 as an osteoprotegerin-inducing factor in culture medium of blastic cells from a patient with acute megakaryoblastic leukemia complicated with osteosclerosis. *Am J Hematol*, **77**, 62–66.
- 134 Swirsky DM, Li YS, Matthews JG, Flemans RJ, Rees JKH and Hayhoe FGJ (1984) 8;21 translocation in acute granulocytic leukaemia: cytological, cytochemical and clinical features. *Br J Haematol*, **56**, 199–213.
- 135 Valent P, Sotlar K, Blatt K, Hartmann K, Reiter A, Sadovnik I *et al.* (2017) Proposed diagnostic criteria and classification of basophilic leukemias and related disorders. *Leukemia*, **31**, 788–797.
- 136 Shvidel L, Shaft D, Stark B, Shtalrid M, Berrebi A and Besnitzky P (2003) Acute basophilic leukaemia: eight unsuspected new cases diagnosed by electron microscopy. *Br J Haematol*, **120**, 774–781.
- 137 Peterson LC, Parkin JL, Arthur DC and Brunning RD (1991) Acute basophilic leukaemia: a clinical, morphologic, and cytogenetic study of eight cases. *Am J Clin Pathol*, **96**, 160–170.
- 138 Duchayne E, Demur C, Rubie H, Robert A and Dastague N (1999) Diagnosis of acute basophilic leukemia. *Leuk Lymphoma*, **32**, 269–278.
- 139 Bernini JC, Timmons CF and Sandler ES (1995) Acute basophilic leukemia in a child: anaphylactoid reaction and coagulopathy secondary to vincristine-mediated degranulation. *Cancer*, **75**, 110–114.
- 140 Castoldi G and Cuneo A (1996) Special cytological subtypes of acute myeloid leukaemias and myelodysplastic syndromes. *Baillière's Clin Haematol*, **9**, 19–33.
- 141 Wick MR, Li C-Y and Pierre RV (1982) Acute nonlymphocytic leukemia with basophilic differentiation. *Blood*, **60**, 38–45.
- 142 Yam LT, Yam C-F and Li CY (1980) Eosinophilia and systemic mastocytosis. *Am J Clin Pathol*, **73**, 48–54.

- 143 Georgin-Lavialle S, Lhermitte L, Dubreuil P, Chandesris MO, Hermine O and Damaj G (2013) Mast cell leukemia. *Blood*, **121**, 1285–1295.
- 144 McClintock-Treep SA, Horny H-P, Sotlar K, Foucar MK and Reichard KK (2009) KIT^{D816V+} systemic mastocytosis associated with KIT^{D816V+} acute erythroid leukaemia: first case report with molecular evidence for the same progenitor cell derivation. *J Clin Pathol*, **62**, 1147–1149.
- 145 Morales-Camacho RM, Caballero-Velázquez T, Prats-Martín C, Pérez-López O, Vargas MT and Carrillo-Cruz E (2016) Haemophagocytosis by neoplastic cells in aleukaemic variant of mast cell leukaemia. *Br J Haematol*, **174**, 501.
- 146 Yang J and Gabali A (2019) Mast cell leukemia and hemophagocytosis in a patient with myelodysplastic syndrome. *Blood*, **133**, 2243.
- 147 Schmiegelow K (1990) Philadelphia chromosome-negative acute hemopoietic malignancy: ultrastructural, cytochemical and immunocytochemical evidence of mast cell and basophil differentiation. *Eur J Haematol*, **44**, 74–77.
- 148 Labar B, Mrsić M, Boban D, Batinić D, Marković-Glamočak M, Hitrec V *et al.* (1994) Acute mastocytic leukaemia – case report. *Br J Haematol*, **87** (Suppl. 1), 13.
- 149 Varma N, Varma S and Wilkins B (2000) Acute myeloblastic leukaemia with differentiation to myeloblasts and mast cell blasts. *Br J Haematol*, **111**, 991.
- 150 Valent P, Samorapoompichit P, Sperr WR, Horny H-P and Lechner K (2002) Myelomastocytic leukemia: myeloid neoplasm characterized by partial differentiation of mast cell-lineage cells. *Hematol J*, **3**, 90–94.
- 151 Ozer O, Zhao YD, Ostler KR, Akin C, Anastasi J, Vardiman JW and Godley LA (2008) The identification and characterisation of novel *KIT* transcripts in aggressive mast cell malignancies and normal CD34+ cells. *Leuk Lymphoma*, **49**, 1567–1577.
- 152 Valent P, Sotlar K and Horny HP (2011) Aberrant expression of CD30 in aggressive systemic mastocytosis and mast cell leukemia: a differential diagnosis to consider in aggressive hematopoietic CD30-positive neoplasms. *Leuk Lymphoma*, **52**, 740–744.
- 153 Jawhar M, Jschaab J, Meggendorfer M, Naumann N, Horny H-P, Sotlar K *et al.* (2017) The clinical and molecular diversity of mast cell leukemia with or without associated hematologic neoplasm. *Haematologica*, **102**, 1035–1043.
- 154 Srivastava BIS, Srivastava A and Srivastava MD (1994) Phenotype, genotype and cytokine production in acute leukaemia involving progenitors of dendritic Langerhans' cells. *Leuk Res*, **18**, 499–512.
- 155 Fontana J, Koss W, McDaniel D, Jenkins J and Whelton W (1989) Histiocytosis X and acute monocytic leukaemia. *Am J Med*, **82**, 137–142.
- 156 Needleman SW, Burns P, Dick FR and Armitage JO (1981) Hypoplastic acute leukaemia. *Cancer*, **48**, 1410–1414.
- 157 Howe RB, Bloomfield CD and McKenna RW (1982) Hypocellular acute leukemia. *Am J Med*, **72**, 391–395.
- 158 Cheson BD, Cassileth PA, Head DR, Schiffer CA, Bennett JM, Bloomfield CD *et al.* (1990) Report of the National Cancer Institute-sponsored workshop on definitions of diagnosis and response in acute myeloid leukemia. *J Clin Oncol*, **8**, 813–819.
- 159 Arber D, Orazi A, Hasserjian RP, Brunning RD, Le Beau MM, Porwit A *et al.* (2017) Introduction and overview of the classification of the myeloid neoplasms. In: Swerdlow SH, Campo E, Harris NL, Jaffe ES, Pileri SA, Stein H and Thiele J (eds) *World Health Organization Classification of Tumours of Haematopoietic and Lymphoid Tissue*, revised 4th edn. IARC Press, Lyon, pp. 16–27.
- 160 Nagai K, Kohno T, Chen Y-X, Tsushima H, Mori H, Nakamura H *et al.* (1996) Diagnostic criteria for hypocellular acute leukemia: a clinical entity distinct from overt acute leukemia and myelodysplastic syndrome. *Leuk Res*, **20**, 563–574.
- 161 Venditti A, Del Poeta G, Buccisano F, Tamburini A, Cox C, Stasi R *et al.* (1997) Minimally differentiated acute myeloid leukemia (AML-M0): comparison with 25 cases with other French–American–British subtypes. *Blood*, **89**, 621–629.
- 162 Brito-Babapulle V, Crawford A, Khokar T, Laffan M, Matutes E, Fairhead S and Catovsky D (1991)

- Translocations t(14;18) and t(8;14) with rearranged *bcl-2* and *c-myc* in a case presenting with B-ALL (L3). *Leukemia*, **5**, 83–87.
- 163 Gassman W, Haferlach T, Ludwig W-D, Löffler H, Thiel E and Hoelzer D (1996) Diagnostic problems in T-ALL – morphological and cytochemical analysis of the German ALL Study Group Diagnostic Review Panel. *Br J Haematol*, **93** (Suppl. 2), 56–57.
- 164 Wang W, Xie W and Hu S (2015) Cup-like blasts in B-lymphoblastic leukaemia. *Br J Haematol*, **170**, 596.
- 165 Richardson AI and Li W (2018) Cuplike nuclear morphology in pediatric B-cell acute lymphoblastic leukemia. *Blood*, **132**, 457.
- 166 Li W, Cooley LD, August KJ, Richardson AI, Shao L, Ahmed AA *et al.* (2019) Cuplike nuclear morphology is highly associated with *IKZF1* deletion in pediatric precursor B-cell ALL. *Blood*, **134**, 324–329.
- 167 Zhang J, Li M and He Y (2019) Granular B-lineage acute lymphoblastic leukaemia mimicking acute myeloid leukaemia. *Br J Haematol*, **184**, 894.
- 168 Dunphy CH, Chung D and Dunphy FR (1994) Auer rod-like inclusions in adult common acute lymphoblastic leukemia. *Hum Pathol*, **25**, 211–214.
- 169 Ganick DJ and Finlay JL (1980) Acute lymphoblastic leukemia with Burkitt cell morphology and cytoplasmic immunoglobulin. *Blood*, **56**, 311–314.
- 170 Koziner B, Mertelsmann R, Andreeff M, Arlin Z, Hansen H, de Harven E *et al.* (1980) Heterogeneity of cell lineages in L3 leukemias. *Blood*, **53**, 694–698.
- 171 Li Y, Gupta G, Molofsky A, Xie Y, Shihabi N, McCormick J and Jaffe ES (2018) B lymphoblastic leukemia/lymphoma with Burkitt-like morphology and IGH/MYC rearrangement: report of 3 cases in adult patients. *Am J Surg Pathol*, **42**, 269–276.
- 172 Wright S, Chucrallah A, Chong YY, Kantarjian H, Keating M and Albitar M (1996) Acute lymphoblastic leukaemia with myeloperoxidase activity. *Leuk Lymphoma*, **51**, 147–151.
- 173 Berman M, Minowada J, Loew JM, Ramsey MM, Ebie N and Knospe WH (1985) Burkitt cell acute lymphoblastic leukemia with partial expression of T-cell markers and subclonal chromosome abnormalities in a man with acquired immunodeficiency syndrome. *Cancer Genet Cytogenet*, **16**, 341–347.
- 174 Duployez N, Debarri H and Fouquet G (2013) Mixed phenotype acute leukaemia with Burkitt-like cells and positive peroxidase cytochemistry. *Br J Haematol*, **163**, 148.
- 175 Ekblom M, Elonen E, Vuopio P, Heinonen K, Knuutila S, Gahmberg CG and Andersson LC (1982) Acute erythroleukaemia with L3 morphology and the 14q+ chromosome. *Scand J Haematol*, **29**, 75–82.
- 176 Knuutila S, Elonen E, Heinonen K, Borgström GH, Lakkala-Paranko T, Perkkio M *et al.* (1984) Chromosome abnormalities in 16 Finnish patients with Burkitt's lymphoma or L3 acute lymphoblastic leukemia. *Cancer Genet Cytogenet*, **13**, 139–151.
- 177 Iguchi T, Awaya N, Yobayashi K and Okamoto S (2005) Bone marrow metastases of small cell carcinoma of the lung mimicking Burkitt lymphoma/leukaemia. *Br J Haematol*, **130**, 652.
- 178 Castella A, Davey FR, Kurec AS and Nelson DA (1982) The presence of Burkitt-like cells in non-Burkitt's neoplasms. *Cancer*, **50**, 1764–1770.
- 179 d'Onofrio G and Zini G, translated by Bain BJ (2015) *Morphology of Blood Disorders*, 2nd edn. Verduci Editore, Rome, and Wiley-Blackwell, Oxford.
- 180 Hoyer JD, Fisher CP, Soppa VM, Lantis KL and Hanson CA (1996) Detection and classification of acute leukemia by the Coulter STKS Hematology Analyzer. *Am J Clin Pathol*, **106**, 352–358.

