

1

Potential Adult Orthodontic Patients – Who Are They?

Birte Melsen

Introduction	1
Who are the patients?	1
How do the patients express their needs?	6
The first visit	7
How can the orthodontist advise such patients?	7
Communicating with the patient	9
Summary	10
References	10

Introduction

The number of adult patients receiving orthodontic treatment is increasing worldwide. According to the editor of the *Journal of Clinical Orthodontics*, the time when orthodontics was just for children is definitely over (Keim et al. 2005a,b). The increase in the number of adult patients requesting orthodontic treatment is also reflected in European countries (Burgersdijk et al. 1991; Stenvik et al. 1996; Kerosuo et al. 2000). Vanarsdall and Musich (1994) listed five reasons for this change. Three concerned the improved capacity of the profession to treat problems in adult patients either only orthodontically or in combination with orthognathic surgery. Two points referred to the patient's desire to maintain their natural teeth.

Proffit (2000) explained that the increase in the number of adult patients seeking treatment was due to greater availability of information, and analyzed the motivation necessary to seek orthodontic treatment as an adult. However, the patients referred to by Proffit are mostly well informed about the possibilities and limitations of orthodontic treatment, and while this assertion may be valid within certain socioeconomic groups in the USA, it is rarely the case in

Europe. A possible explanation of this difference between the USA and Europe could be the marketing of orthodontics in the USA. In Europe it is often ignorance and insecurity that characterize the adult patients seen in the orthodontist's office. Patients may come on their own initiative because they are dissatisfied with either the appearance of their teeth or their ability to chew, or due to a combination of both, or they may have been referred by their family dentist.

Who are the patients?

How can we characterize the adult population presenting to an orthodontic office? Adult patients can be classified according to several criteria. While they all share the fact that they are no longer growing, we must differentiate between young adults, who have recently stopped growing, and older adults, who have experienced deterioration of their dentition and changes in their occlusion over time (Figs 1.1 and 1.2).

Young adult patients are those who, from a professional point of view, should have been treated earlier, or those in whom optimal treatment can be carried out only after cessation of growth. Based on the importance of the impact of genetics on the final skeletal morphology (Savoye et al. 1998), it is frequently considered desirable to postpone treatment of severe skeletal deviations that can be recognized in other members of the family until adulthood, at which time surgical treatment can be carried out (Fig. 1.3).

Some young adult patients with severe malocclusions should, however, have been treated earlier. Their malocclusion, which was not considered as an indication for treatment when younger, worsens with time and leads them to

seek treatment as adults (Figs 1.2 and 1.4). Proffit (2006) diagrammatically illustrated where tooth movement alone can solve the problem, where tooth movements combined with growth modification is needed and where surgery is considered necessary. However, the lines indicating the limits should not be considered as sharp cut-off points but rather as indicative of a 'grey zone' in which more than one treatment option can be considered (Fig. 1.5). Cassidy et al. (1993) discussed making a decision about surgery based on the advantages and disadvantages of surgical and orthodontic approaches to the treatment of these patients. On the basis of analysis of post-treatment changes and a risk analysis they concluded that conventional orthodontic treatment is a better choice in borderline cases.

Surgery should not be a substitute for orthodontic treatment but when treatment is delayed beyond the time when growth modification is possible, surgery is often the only

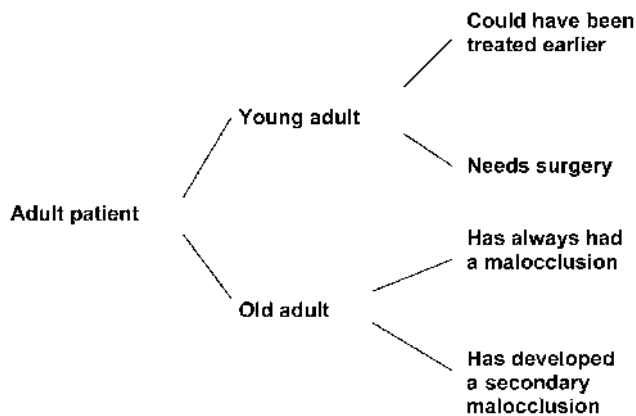


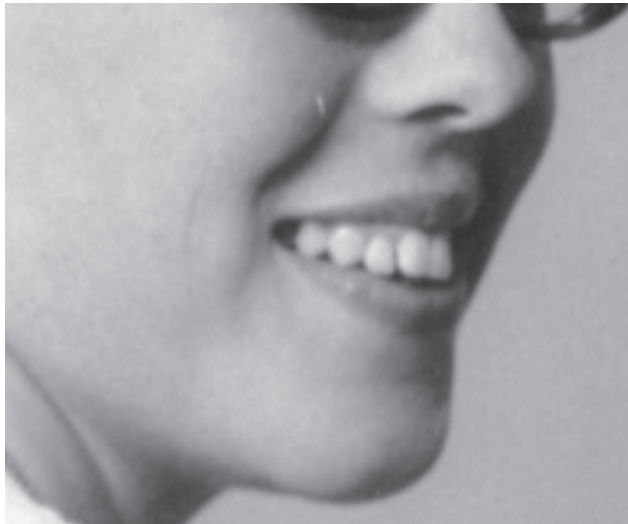Fig. 1.1 Classification of adult patients.



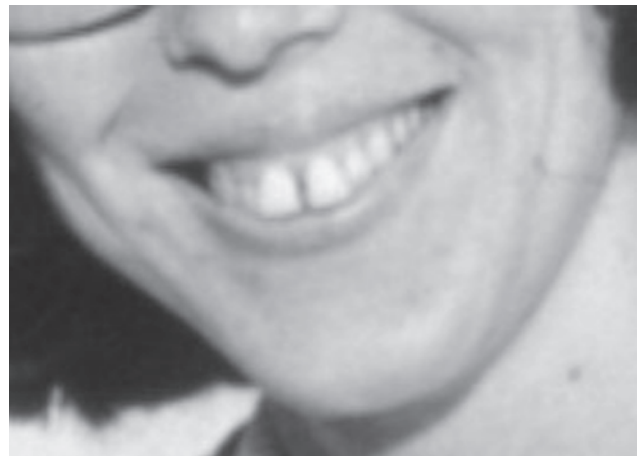
Fig. 1.3 Extraoral photograph of a young woman whose treatment was postponed until adulthood as a surgical solution was foreseen. The malocclusion had worsened over puberty but since it was reflecting a family facial pattern, treatment was delayed until cessation of growth.



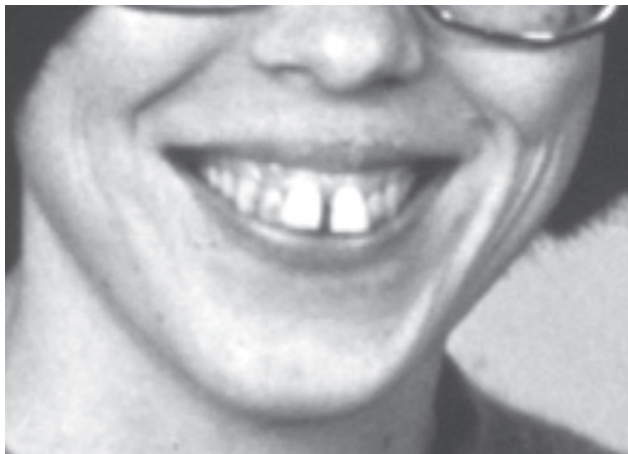Fig. 1.2 (1–3) An adult patient demonstrating a gradual increase in overjet over time.



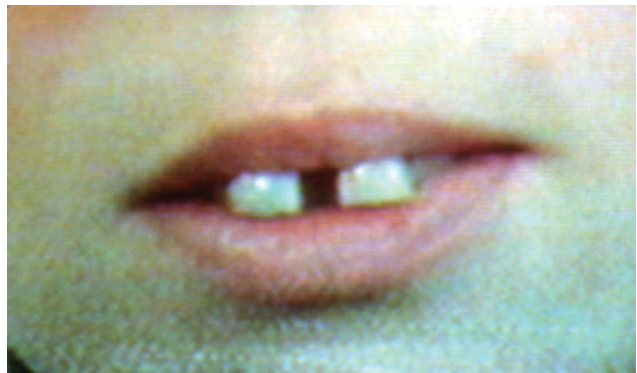(1)



(2)



(3)



(4)

Fig. 1.4 (1–3) A slight increase in overjet which did not qualify for publicly funded treatment. The overjet increased over the years and a medial diastema developed, leading to a more severe malocclusion. (4) In addition to the increased overjet there was extrusion of the upper incisors.

possible solution. A lack of treatment at the most convenient time thus adds to the number of surgical candidates. Another factor contributing to the increased demand for orthognathic surgery is the simplification of orthodontic techniques. The use of pre-adjusted brackets and the 'straightwire appliance' (SWA) has certain limitations and may contribute to the increased indication for orthognathic surgery. When the available mechanics are limited to 'straight wires' only, however, for patients in 'grey zone', the most suitable treatment option seems to be leaning more and more towards surgery (Burstone 1991).

Lack of availability or financial considerations may also be a reason for not having orthodontics at the optimal time. Third-party payments may have an impact on which children will be offered orthodontic treatment and in several countries such as Denmark, the percentage of children who

will be offered conventional orthodontic treatment is politically determined. Orthodontic treatment will not be performed if the severity of the malocclusion is below the criteria established by law (National Board of Health 2003), and as a consequence the patient in Figure 1.4 might not be offered treatment today either.

Very few features of malocclusion reduce with time (Harris and Behrents 1988), with both Class II and Class III malocclusions becoming more severe (Fig. 1.6). Therefore, if a skeletal deviation which could have been handled by growth modification is left to worsen until growth ceases, the only possible treatment may be a combination of orthodontics and surgery. A reason, although not acceptable, for the increase in the number of patients receiving orthognathic surgery is the fact that treatment comprising orthognathic surgery is frequently paid for by

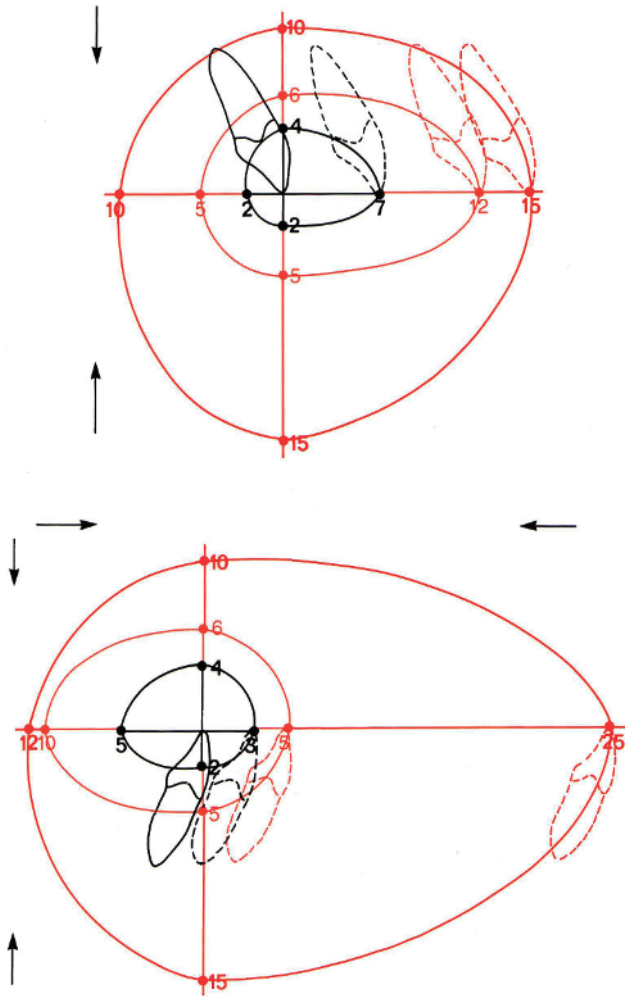


Fig. 1.5 Diagrammatic illustration of the changes in incisor position in growing and non-growing individuals that are possible with orthodontic tooth movement, growth adaptation and orthognathic surgery. The teeth in the centre of the coordinate system illustrate the ideal position. The inner envelope of each diagram illustrates the possible correction that can be obtained by tooth movements alone. It should be noted that the envelope is elliptical in shape as the limits of movement in the labial and lingual direction are not the same. Labial movement is easier in the maxilla and lingual movement is easier in the mandible. The middle envelope indicates what can be achieved if orthodontic tooth movement is combined with growth modification. The outer envelope indicates the possibilities of treatment when surgery is performed. (From Proffit [2006], with permission from Elsevier.)

a third party, i.e. insurance or public funds. This has led to a preference for a surgical solution in borderline patients who could be treated either with or without surgery. Third party involvement in orthodontic services may thus result in the unfortunate development of an increase in the number of adult patients needing treatment when the indication for treatment depends on the severity of the malocclusion as based on static morphological criteria. Where the percentage of children who can be offered publicly funded treatment is determined politically, the orthodontist has only limited freedom in determining how the resources

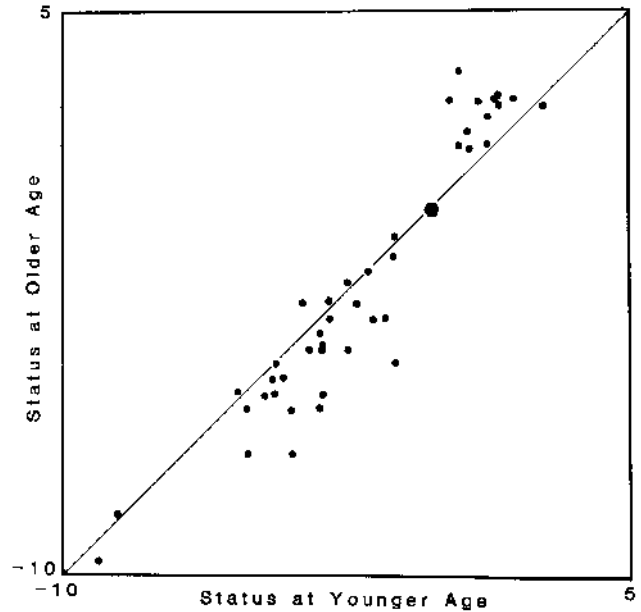


Fig. 1.6 Graphic illustration of the development of occlusion with age. Note that the Class II and III malocclusions have worsened. (Redrawn from Harris and Behrents 1988, with permission from Elsevier.)

available should be used in the most efficient way (National Board of Health 2003). As a result, the orthodontist may opt not to treat the most difficult cases but refer them to surgery, thus shifting the responsibility for these cases to another part of the health service. Excessive tightening of the criteria for reimbursing treatment costs may therefore increase rather than reduce the total costs for the 'third party' in the long run (Mavreas and Melsen 1995).

Older adult patients, over age 40, present with signs of ageing, deterioration or a dentition often characterized by extensive rehabilitation (Proffit 2000). The number of these patients is also increasing and the patients often present with a 'secondary malocclusion', i.e. malocclusion that has developed or has worsened in adulthood. This may occur as a result of deterioration of the dentition and the periodontium due to poor dental care. The aetiology of these malocclusions will be dealt with in more detail in Chapter 3.

In addition to age, adult patients can also be classified based on reasons for the first consultation. Some patients may come on their own intuition; others are referred by family or friends or a general dentist. Family and friends may hear about the possible treatments offered by orthodontists or they may have noted an ongoing deterioration in the patient's occlusion, e.g. increasing spacing or crowding. Aesthetics plays a major role as a motive for treatment among these patients (Fig. 1.7). Functional problems related to speaking (Fig. 1.8), chewing or temporomandibular disorder (TMD) symptoms are other motives for seeking orthodontic treatment. The family dentist may also refer a patient because he or she considers orthodontic



Fig. 1.7 This patient came with a photograph taken at home and declared, 'I was not aware that my teeth were sticking out that much'.

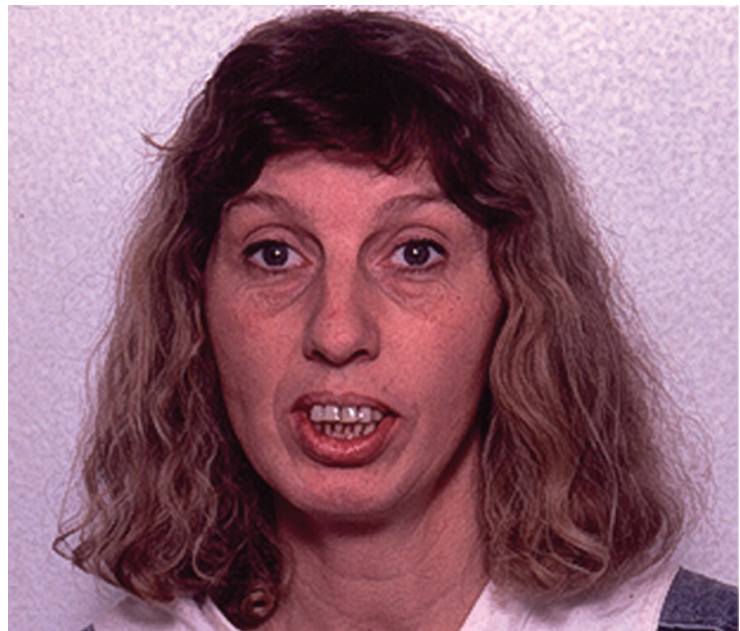treatment necessary in order to halt ongoing deterioration of a dentition or because the present tooth position and/or occlusion do not provide a satisfactory basis for planned prosthodontic rehabilitation (Fig. 1.9).

An alternative classification of adult patients could therefore also be based on the chief complaint: aesthetics, function or difficulty in achieving suitable occlusal rehabilitation due to, for example tooth malposition (Melsen and Agerbaek 1994).

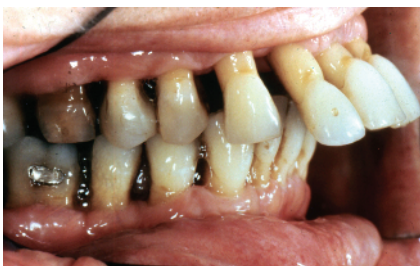Malocclusions detected by adult patients are generally confined to the anterior teeth and comprise spacing or crowding, often related to changes in the overjet and overbite. Factors of importance for development of secondary malocclusion within the masticatory apparatus are, among others, loss of one or more teeth in the buccal segments and



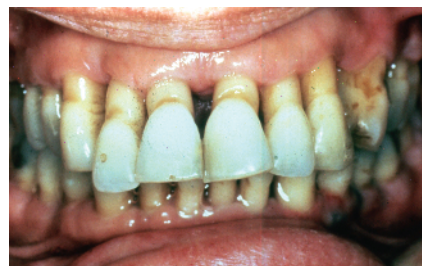(1)



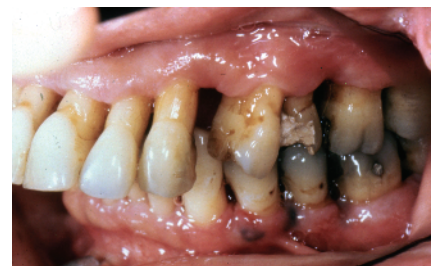(2)



(3)



(4)



(5)

Fig. 1.8 As a young person (1), this patient had been a singer. With the increase in overjet (2), this was no longer possible but it was not until she saw a periodontist that she became aware that something could be done about her occlusion. The intraoral photographs (3–5) demonstrated extreme periodontal involvement, elongated clinical crowns following periodontal surgery, flaring of the upper incisors and crowding of the lower incisors.

Box 1.1 Problem list for the patient in Figure 1.8

Chief complaint:

- 'I used to sing, this is not possible anymore. My top teeth are moving. I do not bite very well.'

History:

- Previous orthodontic treatment with a removable appliance to align the upper incisors.

Problem list:

- *Extraoral*: Insufficient lip closure, prominent lower lip.
- *Function*: Lip pressure during swallowing, hyperactive mentalis muscle, inactive upper lip, unstable occlusion, dual bite.
- *Dental status*: Heavily restored permanent dentition with temporary fillings in some teeth, endodontic treatment of 16 and 25.
- *Periodontal status*: 30–40% bone loss but following periodontal surgery, no pathological pockets.
- *Tooth position anomalies*: Mesial rotation: 16, 17, 23, 25, 27; distal rotation: 24.
- *Occlusion*: Distal relationship of canines and molars bilaterally, 14 mm overjet, 2.5 mm overbite, scissors bite corresponding to 24, 34; dental midline discrepancy, with the lower incisors off the midline compared with the upper.
- *Space relationship*: upper arch: spacing of 4 mm; lower arch: crowding of 3 mm; deep curve of Spee.

Box 1.2 Treatment goal for patient in Figure 1.8

Treatment goal

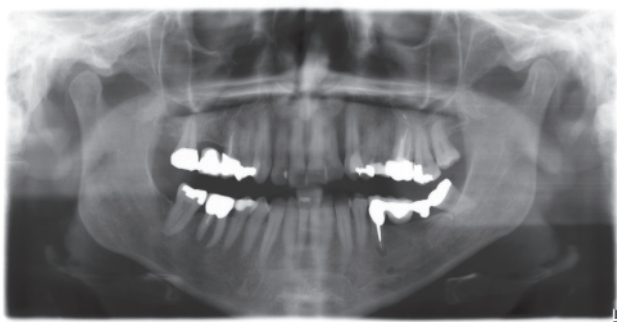
- *Function*: To find the structural position of the mandible; prepare for occlusal onlays to facilitate lip closure, making it possible for the patient to sing again.
- *Occlusion*: Close spaces in the upper arch by retraction and intrusion of the incisors, expand sagittally to align in the lower arch. Reduction of the overjet to achieve incisal contact. Correction of scissors bite by buccal movement of 44 and of the midline discrepancy by differential space closure.
- *Maintenance*: cast upper retainer optimizing the load transfer to the upper anterior teeth.

periodontal disease. Both factors influence the internal balance (Fig. 1.10).

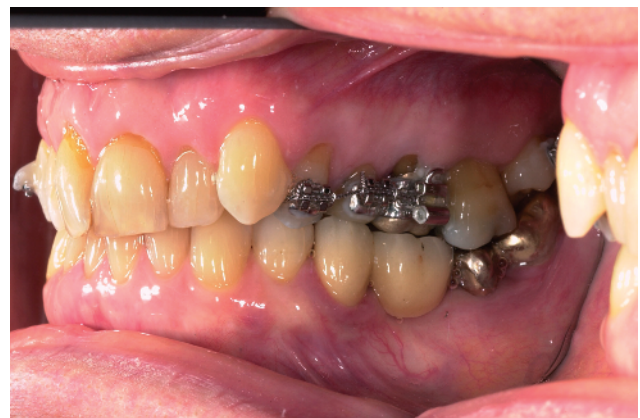How do the patients express their needs?

Some adult patients indicate that they have desired treatment for some time, but for various reasons, it had not been possible – some would have grown up in areas where orthodontic services were not available; others would not have received treatment for financial reasons. With increasing availability of orthodontic services, the first type of adult patient may be less prevalent in the future. The increased sensitivity to deviation in appearance within many societies will eventually lead some patients to seek treatment (Lazaridou-Terzoudi et al. 2003). Appearance is becoming increasingly more important and the level of deviation from socially determined norms is reducing. This tendency is reflected in the increased desire for aesthetic treatment, including cosmetic surgery, orthodontics and aesthetic dentistry (Schweitzer 1989a,b; Nathanson 1991; Matarasso 1997; Figueroa 2003).

Some patients who did not perceive a need for treatment earlier will, as a result of continuing deterioration of the dentition, find themselves no longer satisfied with the function or the appearance of their dentition. Some of these patients may have been treated earlier, but were not aware of the possibility for treatment or did not perceive a need for it until recently (Fig. 1.11). The individual level of acceptance varies greatly. The mere thought of having to wear braces keeps some patients from consulting the orthodontist. Awareness of this problem within the profession has led to the development of various attempts to reduce or even totally avoid visibility of the necessary appliances. Placement of the appliances on the lingual side has been

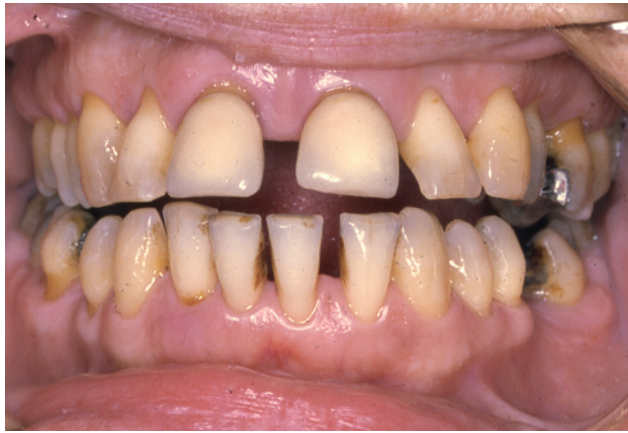

(1)

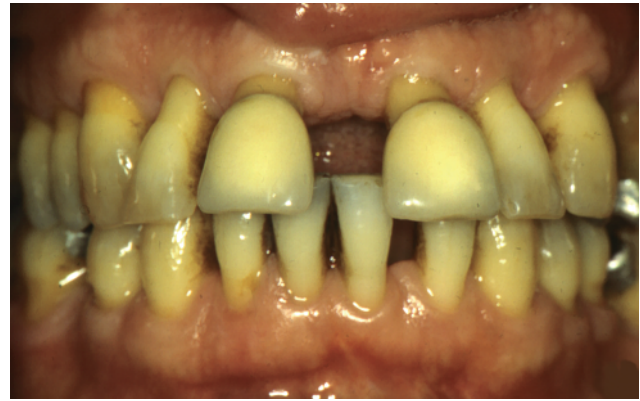

(2)

Fig. 1.9 (1–2) This patient had a bridge to replace the left first and second lower molars. The bridge was made after the upper molar had overerupted and the third molar had tipped mesially. The adverse direction of loading of the bridge led to fracture of the second premolar. The patient then required orthodontic treatment in addition to three implants. This could have been avoided had the bridge been fitted soon after the extraction.



(1)

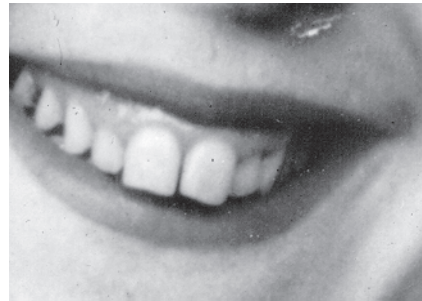

(2)

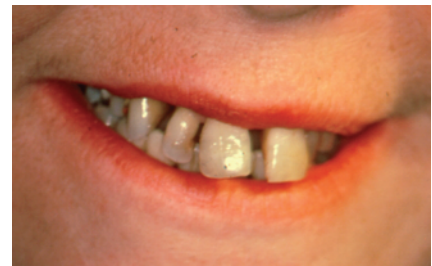Fig. 1.10 (1) Patient who had 'always' had a diastema. However, it increased in size following the extraction of two lower molars. (2) Situation 2 years later.



(1)



(2)



(3)

Fig. 1.11 (1–3) This patient brought in a series of personal photographs clearly demonstrating the development of a malocclusion. It was, however, not until the dentist explained that an incisor was at risk but no replacement was possible due to the diastema that the patient requested treatment.

one way of preventing their being seen. Smaller sized or transparent brackets have also made labial appliances more acceptable. The introduction of Invisalign® reflects the desire to develop and use orthodontic appliances that are not seen while in the mouth (Smith et al. 1986a,b; Fontenelle 1991; Bishara and Fehr 1997; Sinha and Nanda 1997; Norris et al. 2002; Vlaskalic and Boyd 2002; Wong 2002; Bollen et al. 2003; Joffe 2003; Wiechmann 2003; Wiechmann et al. 2003; Wheeler 2004; Eliades and Bourauel 2005; Nedwed and Miethke 2005; Turpin 2005).

It is well known that most minor malocclusions become more pronounced with increasing age (Harris and Behrens 1988; Baumrind 1991).

The first visit

At the first consultation, on the one hand, adult patients may seem insecure due to lack of knowledge regarding the aetiology of their malocclusion and the available treatment alternatives. They are, on the other hand, conscious regarding their desire to improve the appearance or function of their teeth, but there may be some doubts and even a reluctance to undergo orthodontic treatment.

How can the orthodontist advise such patients?

Which malocclusions require orthodontic correction? Only scarce evidence indicates a relationship between the existence of a malocclusion and the prevalence of other dental problems such as caries, periodontal disease and gnathological problems (Gher 1998).

On this basis, how can the orthodontist give appropriate advice to the patient? Recently Johnston (2000) proposed that a need for treatment in this group of adult patients is identical to the demand for treatment, and that the demand for improved aesthetics would usually be the main reason for undertaking treatment. This implies that the priority given by an individual patient to aesthetics determines his or her need for treatment. The present author does not share this opinion. The reasons for seeking an orthodontic consultation are often: fear of losing teeth; lack of the possibility of a fixed prosthodontic solution; or functional problems. In any case, it is important to inform the patient of the likelihood of further deterioration of the malocclusion if left untreated.

Even a patient given adequate information may refrain from having treatment. If the patient is in doubt, it may be advisable to produce a set of study casts, preferably digital,

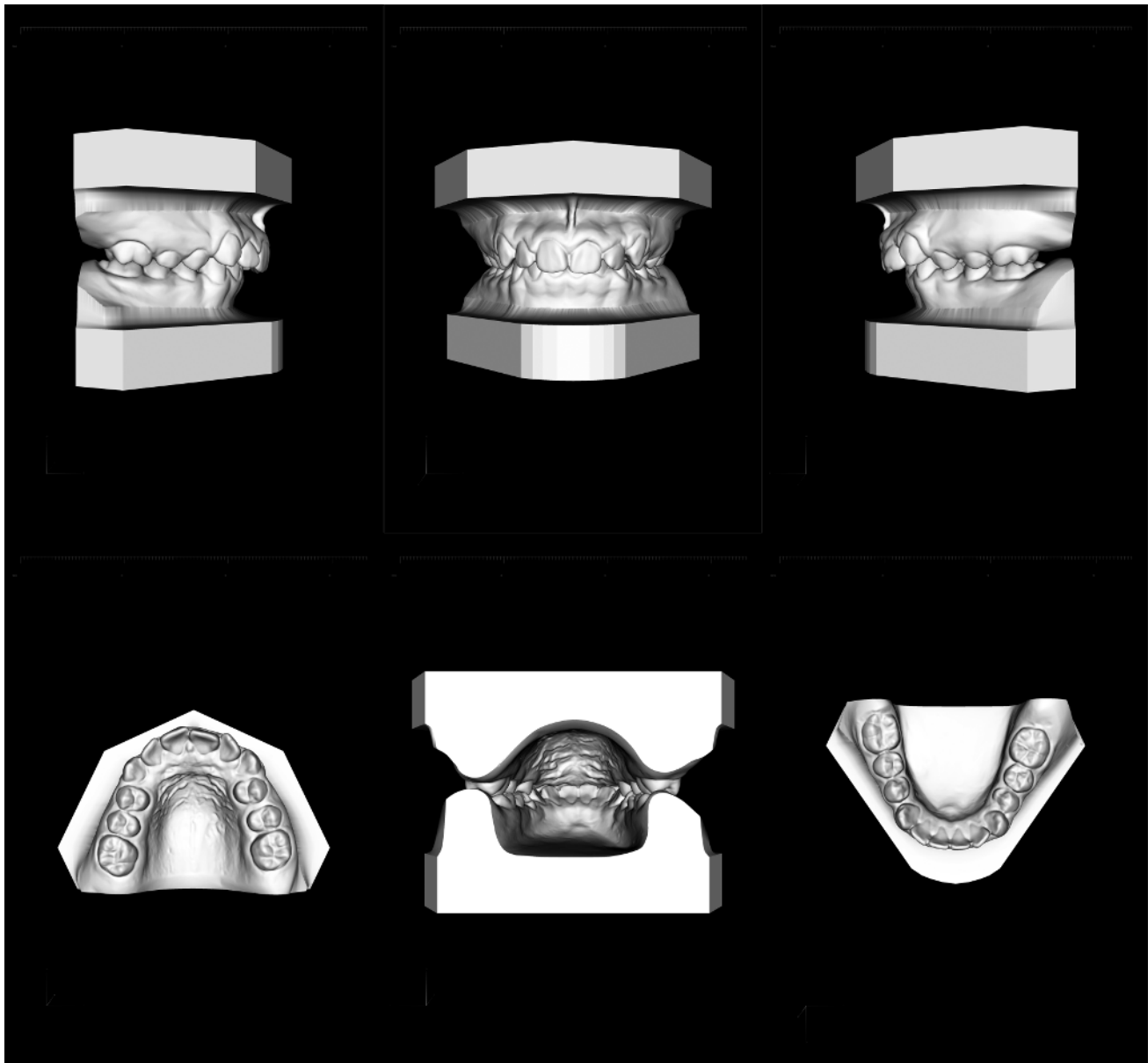


Fig. 1.12 Virtual models. Images can be printed or downloaded by the patient at home where she or he can discuss the problems with family and friends and also follow the eventual deterioration of the occlusion over time.

and then observe the changes over one or more years. Based on the changes seen, the patient can then reconsider whether to initiate orthodontic treatment (Fig. 1.12). Another approach is to ask the patient to present with personal photographs from over his or her lifetime, which could illustrate the development of the malocclusion. Changes within the dentition occur slowly and it is often only when seeing together pictures taken after long intervals of time that patients realize what is happening.

Other patients will have noted changes in their dentition, and will describe either deterioration of a previously acceptable malocclusion or the development of a secondary

malocclusion in relation to the loss of one or more teeth or periodontal disease. They may request intervention to prevent further development or treatment that can restore the original occlusion. Should we fulfil this request or even establish an occlusion that is better than the original? Do these patients really need orthodontic treatment?

The event that triggers the patient to seek treatment may differ from patient to patient. The problems most frequently mentioned are related to flaring of the front teeth. A patient may have had an increased overjet as long as they can remember, but slow and gradual worsening, and the development of an anterior diastema, makes the situation

unacceptable. A photograph taken at a social event may be the primary trigger (Fig. 1.7). Comparison of this image with an earlier photograph would clearly demonstrate the aggravation of the situation and the patient may decide to seek treatment to stop this, or they may at least seek advice from an orthodontist.

Communicating with the patient

The first visit to the orthodontist may result in conflict (Kalia and Melsen 2001) between the orthodontist and the general dentist, between the patient and the orthodontist, or even between the patient and the general dentist. The orthodontist may wonder why the patient was not referred

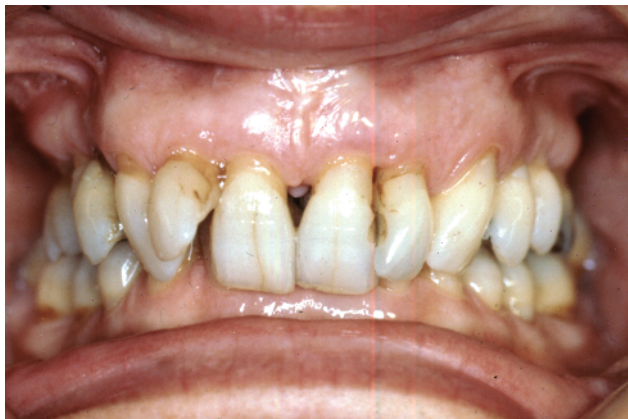

Fig. 1.13 The patient's main problem was the flared incisor. The patient was not aware of the deep bite and the crowding in the lower teeth.

earlier and remark on the rehabilitation that has been done so far, and even indicate that this may interfere with the solution considered best by the orthodontist. If the orthodontist approaches the general dentist for information on the patient's dental care and recent development, the general dentist may well consider it undesirable interference, especially when the patient consults an orthodontist without a referral from their general dentist. It may, however, also occur if the patient is referred to the orthodontist from the general dentist but without sufficient information of the situation. The general dentist may not have worked up a comprehensive problem list but used a single symptom as the basis of referral to the orthodontist. If the patient also perceives the cause of referral as a minor problem, the orthodontist's explanation of the situation may generate a problem. The patient in Figure 1.13 was referred for flaring of a single incisor without their being aware that this may be related to crowding in the lower jaw and a deepening of the bite. The patient may react negatively to the information about the complexity of the problem and confront their general dentist with the new information; this may create conflict between the patient and dentist. The patient may feel that he or she has been misinformed by the general dentist and therefore even choose to change their family dentist, or the patient may perceive the complexity of the problem as an overreaction from the orthodontist's side. This is particularly difficult in cases where previous prosthodontic work has to be redone following the treatment suggested by the orthodontist (Fig. 1.14).

An orthodontic consultation may thus result in problems between the two colleagues involved in the treatment. This



Fig. 1.14 A group of colleagues discussing possible treatment options with a patient.

can be further aggravated when a third colleague is consulted, for example a periodontist, who may find that insufficient periodontal maintenance has contributed to the present situation. Neglect on the part of a colleague who has been taking care of a patient in the period when a secondary malocclusion has developed may result in negative feelings between the patient and the involved dentist.

The scenario that an apparently small problem can be a sign of a severe condition often occurs in other professions as well: 'The strange noise in my car proved to be the sign of a gearbox breaking down.' Pain in the arm can temporarily be alleviated with analgesics but it may be a symptom of a severe heart condition. In the medical profession, it is not unusual to find patients with a simple problem where it turns out to be a symptom of a more complex disease. Why does it then seem so difficult for the dental profession to accept such a diagnosis?

In order to avoid conflicts related to adult patients, close teamwork between dental colleagues, maintaining a high level of communication, should be established. The information given to the patient by different colleagues should not be contradictory. The consequences of failing to give or giving insufficient information can lead to neglect on the patient's side, for instance insufficient interest in replacing a tooth that was extracted.

A crucial requirement in relation to treatment planning where multiple disciplines are involved is agreeing on a common problem list and treatment plan in which there are no disagreements among the colleagues involved. Possible and unavoidable differences of opinion should be discussed but never in front of the patient. The final problem list and the treatment plan agreed by all specialists should then be communicated to the patient and all dental colleagues involved.

The patient may desire a more detailed explanation of both the problem list and treatment plan (Boxes 1.1 and 1.2). This should be carried out by the team member who is in closest contact with the patient or by the one bringing the team together. The level of information must be the same among the team members and all data of importance for the treatment decision should be presented to the patient in a diplomatic way. When explaining the problem and possible treatment options to the patient, it is of the utmost importance also to explain the consequences of completing versus not completing the treatment.

Summary

Adult patients consulting the orthodontist present with a large variety of problems and a dentition often characterized by deterioration and extensive rehabilitation that may make treatment planning complicated. In most cases the treatment will have to be done as a team approach because periodontal, functional and prosthodontic problems also have to be taken into consideration. The importance of

good communication both between the involved team members and between the patient and the clinicians cannot be sufficiently stressed. Sharing information on the various treatment options with various specialties will improve the likelihood that patients receive the best possible outcome (Fig. 1.14).

References

- Baumrind S (1991) Prediction in the planning and conduct of orthodontic treatment. In Melsen B (ed.) *Current Controversies in Orthodontics*, pp. 25–44. Chicago, IL: Quintessence.
- Bishara SE and Fehr DE (1997) Ceramic brackets: something old, something new, a review. *Semin Orthod* 3, 178–188.
- Bollen AM, Huang G, King G, Hujoel P and Ma T (2003) Activation time and material stiffness of sequential removable orthodontic appliances. Part 1: Ability to complete treatment. *Am J Orthod Dentofacial Orthop* 124, 496–501.
- Burgersdijk R, Truin GJ, Frankenmolen F, Kalsbeek H, van't Hof M and Mulder J (1991) Malocclusion and orthodontic treatment need of 15–74-year-old Dutch adults. *Commun Dent Oral Epidemiol* 19, 64–67.
- Burstone CJ (1991) The biomechanical rationale of orthodontic therapy. In Melsen B (ed.) *Current Controversies in Orthodontics*, pp. 147–180. Chicago, IL: Quintessence.
- Cassidy DW Jr, Herbosa EG, Rotskoff KS and Johnston LE Jr (1993) A comparison of surgery and orthodontics in 'borderline' adults with Class II, division 1 malocclusions. *Am J Orthod Dentofacial Orthop* 104, 455–470.
- Eliades T and Bourauel C (2005) Intraoral aging of orthodontic materials: the picture we miss and its clinical relevance. *Am J Orthod Dentofacial Orthop* 127, 403–412.
- Figuerola C (2003) Self-esteem and cosmetic surgery: is there a relationship between the two? *Plast Surg Nurs* 23, 21–24.
- Fontenelle A (1991) Lingual orthodontics in adults. In Melsen B (ed.) *Current Controversies in Orthodontics*, pp. 219–268. Chicago, IL: Quintessence.
- Gher ME (1998) Changing concepts. The effects of occlusion on periodontitis. *Dent Clin North Am* 42: 285–299.
- Harris EF and Behrents RG (1988) The intrinsic stability of Class I molar relationship: a longitudinal study of untreated cases. *Am J Orthod Dentofacial Orthop* 94, 63–67.
- Joffe L (2003) Invisalign: early experiences. *J Orthod* 30, 348–352.
- Johnston LE (2000) Stop me before I write again... *Am J Orthod Dentofacial Orthop* 117, 540–542.
- Kalia S and Melsen B (2001) Interdisciplinary approaches to adult orthodontic care. *J Orthod* 28, 191–196.
- Keim RG, Gottlieb EL, Nelson AH and Vogels DS III (2005a) 2005 JCO orthodontic practice study. Part 1: trends. *J Clin Orthod* 39, 641–650.
- Keim RG, Gottlieb EL, Nelson AH and Vogels DS III (2005b) 2005 JCO orthodontic practice study. Part 2. Practice success. *J Clin Orthod* 39, 687–695.
- Kerosuo H, Kerosuo E, Niemi M and Simola H (2000) The need for treatment and satisfaction with dental appearance among young Finnish adults with and without a history of orthodontic treatment. *J Clin Orthod* 61, 330–340.
- Lazaridou-Terzoudi T, Kiyak HA, Moore R, Athanasiou AE and Melsen B (2003) Long-term assessment of psychologic outcomes of orthognathic surgery. *J Oral Maxillofac Surg* 61, 545–552.
- Matarasso A (1997) Facialplasty. *Dermatol Clin* 15, 649–658.
- Mavreas D and Melsen B (1995) Financial consequences of reducing treatment availability in a publicly-funded orthodontic service. A decision analysis problem. *Br J Orthod* 22, 47–51.
- Melsen B and Agerbaek N (1994) Orthodontics as an adjunct to rehabilitation. *Periodontol* 2000 4, 148–159.
- Nathanson D (1991) Current developments in esthetic dentistry. *Curr Opin Dent* 1, 206–211.
- National Board of Health, Denmark (2003) Bekendtgørelse nr. 1073 af 11. december om tandpleje.
- Nedwed V and Miethke RR (2005) Motivation, acceptance and problems of Invisalign ((R)) patients. *J Orofac Orthop* 66, 162–173.

- Norris RA, Brandt DJ, Crawford CH and Fallah M (2002) Restorative and Invisalign: a new approach. *J Esthet Restor Dent* 14, 217–224.
- Proffit WR (2000) Treatment for adults: special consideration in comprehensive treatment for adults. In Proffit WR (ed.) *Contemporary Orthodontics*, p. 648. St Louis, MO: Mosby.
- Proffit WR (2006) Combined surgical and orthodontic treatment. In Proffit WR (ed.) *Contemporary Orthodontics*, p. 690, Fig. 17.4. St Louis, MO: Mosby.
- Savoye I, Loos R, Carels C, Derom C and Vlietinck R (1998) A genetic study of anteroposterior and vertical facial proportions using model-fitting. *Angle Orthod* 68, 467–470.
- Schweitzer I (1989a) The psychiatric assessment of the patient requesting facial surgery. *Aust N Z J Psychiatry* 23, 249–254.
- Schweitzer I (1989b) The psychiatric assessment of the patient requesting facial surgery. *Aust N Z J Psychiatry* 23, 314.
- Sinha PK and Nanda RS (1997) Esthetic orthodontic appliances and bonding concerns for adults. *Dent Clin North Am* 41, 89–109.
- Smith JR, Gorman JC, Kurz C and Dunn RM (1986a) Keys to success in lingual therapy. *J Clin Orthod* 20, 604.
- Smith JR, Gorman JC, Kurz C and Dunn RM (1986b) Keys to success in lingual therapy. Part 2. *J Clin Orthod* 20, 330–340.
- Stenvik A, Espeland L, Berset GP, Eriksen HM and Zachrisson BU (1996) Need and desire for orthodontic (re-)treatment in 35-year-old Norwegians. *J Orofac Orthop* 57, 334–342.
- Turpin DL (2005) Clinical trials needed to answer questions about Invisalign. *Am J Orthod Dentofacial Orthop* 127, 157–158.
- Vanarsdall RL and Musich DR (1994) Adult orthodontics: diagnosis and treatment. In Graber L and Vanarsdall RL (eds) *Orthodontics Current Principles and Techniques*, 2nd edn, pp. 750–834. St Louis, MO: Mosby.
- Vlaskalic V and Boyd RL (2002) Clinical evolution of the Invisalign appliance. *J Calif Dent Assoc* 30, 769–776.
- Wheeler TT (2004) Invisalign material studies. *Am J Orthod Dentofacial Orthop* 125, 19A.
- Wiechmann D (2003) A new bracket system for lingual orthodontic treatment. Part 2: First clinical experiences and further development. *J Orofac Orthop* 64, 372–388.
- Wiechmann D, Rummel V, Thalheim A, Simon JS and Wiechmann L (2003) Customized brackets and archwires for lingual orthodontic treatment. *Am J Orthod Dentofacial Orthop* 124, 593–599.
- Wong BH (2002) Invisalign A to Z. *Am J Orthod Dentofacial Orthop* 121, 540–541.