

Growth and Development **1**

COPYRIGHTED MATERIAL

An introduction to human craniofacial growth and development

'Growth' is a general term implying simply that something changes in magnitude. It does not, however, presume to account for **how** it happens. For the clinician, such a loose meaning is often used quite properly. However, to try to understand 'how' it works, and what actually happens, the more descriptive and explanatory term 'development' is added. This connotes a maturational process involving progressive differentiation at the cellular and tissue levels, thereby focusing on the actual biological mechanism that accounts for growth.

'Growth and development' is an essential topic in many clinical disciplines and specialties, and the reason is important. Morphogenesis is a biological process having an underlying **control** system at the cellular and tissue levels. The clinician intervenes in the course of this control process at some appropriate stage and substitutes (augments, overpowers or replaces) some activities of the control mechanism with calculated clinical regulation. It is important to understand that the actual biological process of development itself is the same. That is, the histogenic functioning of the cells and tissues still

carry out their individual roles, but the **control signals** that selectively activate the composite of them are now clinically manipulated. It is the rate, timing, direction and magnitude of cellular divisions, and tissue differentiation that become altered when the clinician's signals modify or complement the body's own intrinsic growth signals. The subsequent course of development thus proceeds according to a programmed treatment plan by 'working with growth' (an old clinical tenet). Of course, if one does not understand the workings of the underlying biology, any real grasp of the actual basis for treatment design and results, and why, is an illusion. Importantly, craniofacial biology is independent of treatment intervention strategy. Therefore, although some clinicians may argue about the relative merits of different intervention strategies (e.g. extraction versus arch expansion), the biological rules of the game are the same.

Morphogenesis works constantly towards a state of composite, architectonic **balance** among all of the separate growing parts. This means that the various parts developmentally merge

into a functional whole, with each part complementing the others as they all grow and function together.

During development, balance is continuously transient and can never actually be achieved because growth itself constantly creates ongoing, normal regional imbalances. This requires other parts to constantly adapt (develop) as they all work toward composite equilibrium. It is such an imbalance itself that fires the signals which activate the interplay of histogenic responses. Balance, when achieved for a time, turns off the signals and regional growth activity ceases. The process recycles throughout childhood, into and through adulthood (with changing magnitude) and finally on to old age, sustaining a changing morphological equilibrium in response to ever-changing intrinsic and external conditions. For example, as a muscle continues to develop in mass and function, it will outpace the bone into which it inserts, both in size and in mechanical capacity. However, this imbalance signals the osteogenic, chondrogenic, neurogenic and fibrogenic tissues to immediately respond, and the whole bone with its connective tissues, vascular supply and innervation develops (undergoes modelling) to work continuously towards homeostasis.

By an understanding of how this process of progressive morphogenic and histogenic differentiation operates, the clinical specialist thus selectively augments the body's own intrinsic activating signals using controlled procedures to jump-start the modelling process in a way that achieves an intended treatment result. For example, in patients with maxillary transverse deficiency, rapid palatal expansion can be used to separate the right and left halves of the maxilla (displacement). This in turn initiates a period of increased remodelling activity in the midpalatal suture and dentoalveolus.

The genetic and functional **determinants** of a bone's development (i.e. the origin of the growth-regulating signals) reside in the composite of **soft tissues** that turn on or turn off, or speed up or slow down, the histogenic actions

of the osteogenic connective tissues (periosteum, endosteum, sutures, periodontal ligament). Growth is not 'programmed' within the bone itself or its enclosing membranes. The 'blueprint' for the design, construction and growth of a bone thus lies in the muscles, tongue, lips, cheeks, integument, mucosae, connective tissues, nerves, blood vessels, airway, pharynx, the brain as an organ mass, tonsils, adenoids and so forth, all of which provide information signals that pace the histogenic tissues responsible for a bone's development.

A major problem with therapeutic modification of the growing face can be **relapse** (rebound subsequent to treatment). The potential for relapse exists when the functional, developmental or biomechanical aspects of growth among key parts are clinically altered to a physiologically imbalanced state. The possibility of instability exists because clinicians strive to bring about a state of aesthetic balance that at times produces physiological imbalance. Rebound is especially strong when the underlying conditions in the 'genic' tissues that led to the pretreatment dysplasia still exist and thus trigger the growth process to rebound in response to the clinically induced changes in morphology. The 'genic' tissues are attempting to restore physiological balance, thereby returning in a developmental direction towards the pretreatment state or some combination between. Physiological compensation is, in effect, a built-in protective mechanism that allows the final occlusion of the teeth to vary only a mere few millimetres, despite enormous variation in the human face (see Figure 1.1).

The evolutionary design of the human head is such that certain regional clinical situations naturally exist. For example, variations in head-form design establish natural tendencies toward different kinds of malocclusions. The growth process, in response, develops some regional imbalances, the aggregate of which serves to make corrective adjustments. A Class I molar relationship with an aesthetically pleasing face is the common result in which the underlying

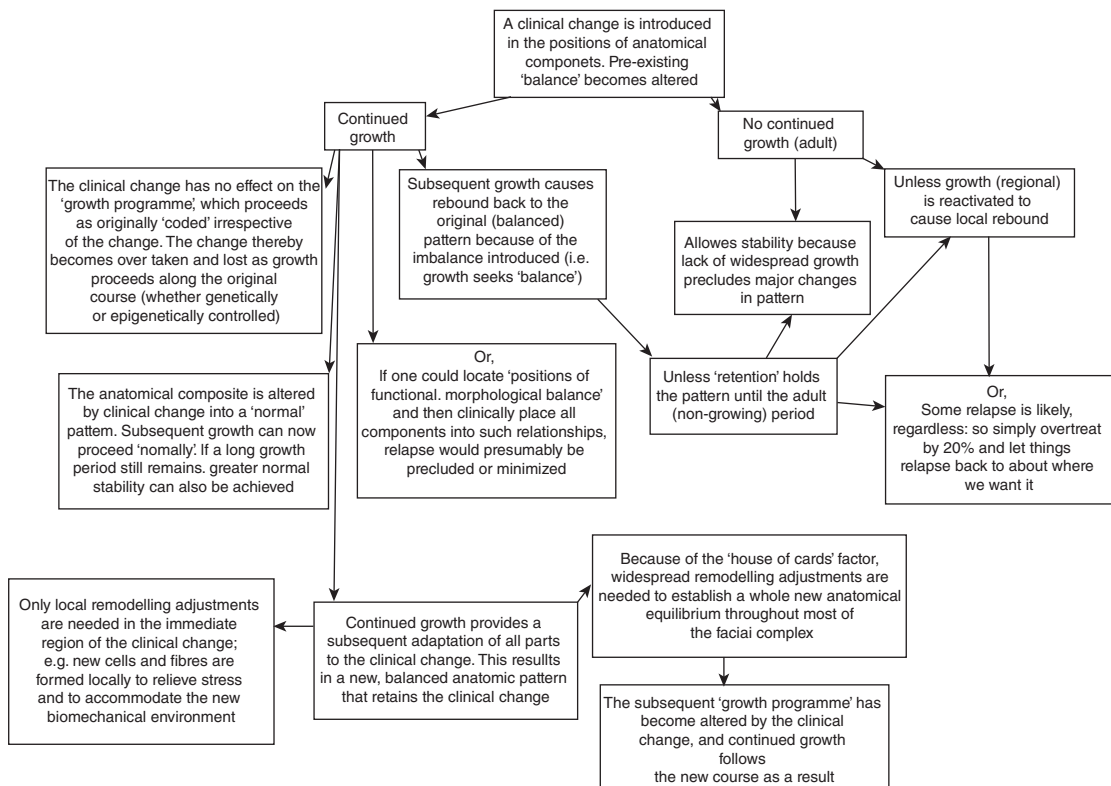


Figure 1.1 Summary of factors involved in clinical modification of the growth process.

factors that would otherwise have led to a more severe Class II or III malocclusion still exist but have been 'compensated for' by the growth process itself. The net effect is an overall, composite balance.

As pointed out above, clinical treatment can disturb a state of structural and functional equilibrium, and a natural rebound can follow. For example, a premature fusion of some cranial sutures can result in growth-retarded development of the nasomaxillary complex because the anterior endocranial fossae (a template for mid-facial development) are foreshortened, as in the Crouzon or Apert syndrome. The altered nasomaxillary complex itself nonetheless has grown in a balanced state proportionate to its basicranial template, even though abnormal in comparison with a population norm for aesthetics

and function. Craniofacial surgery disturbs the former balance and some degree of natural rebound can be expected. The growth process attempts to restore the original state of equilibrium, since some extent of the original underlying conditions (e.g. the basicranium) can still exist that was not, or could not be, altered clinically. These are examples in which the biology of the growth process is essentially normal, either with treatment or without, but is producing abnormal results because of altered input control signals.

THE BIG PICTURE

No craniofacial component is developmentally self-contained and self-regulated. Growth of a component is not an isolated event unrelated to

other parts. Growth is the composite change of all components. For example, it might be perceived that the developing palate is essentially responsible for its own intrinsic growth and anatomical positioning, and that an infant's palate is the same palate in the adult simply grown larger. The palate in later childhood, however, is not composed of the same tissue (with more simply added), and it does not occupy the same actual position. Many factors influence (impact) the growing palate from without, such as developmental rotations, displacements in conjunction with growth at sutures far removed, and multiple remodelling movements that relocate it to progressively new positions and adjust its size, shape and alignment continuously throughout the growth period.

Similarly, for the mandible, the multiple factors of middle cranial fossa expansion, anterior cranial fossa rotations, tooth eruption, pharyngeal growth, bilateral asymmetries, enlarging tongue, lips and cheeks, changing muscle actions, headform variations, an enlarging nasal airway, changing infant and childhood swallowing patterns, adenoids, head position associated with sleeping habits, body stance and an infinite spread of morphological and functional variations all have input in creating constantly changing states of structural balance.

As emphasised above, **development** is an architectonic process leading to an aggregate state of structural and functional equilibrium, with or without an imposed malocclusion or other morphologic dysplasia. Very little, if anything, can be exempted from the 'big picture' of factors affecting the operation of the growth control process and no region can be isolated. Meaningful insight into all of this underlies the basis for clinical diagnosis and treatment planning. Ideally, the target for clinical intervention should be the control process regulating the growth and development of the component out of balance. However, gaps in our understanding of these processes limit the clinician's ability to treat malocclusions in this manner. Since cause is unknown, clinicians target the effect of

the imbalance. Therefore, a thorough understanding of the process and pattern of facial growth serves as the foundation for craniofacial therapies.

A CORNERSTONE OF THE GROWTH PROCESS

A grasp of how facial growth operates begins with distinguishing between the two basic kinds of **growth movement**: remodelling and displacement (Figure 1.2). Each category of movement involves virtually all developing hard and soft tissues.

For the bony craniofacial complex, the process of growth **remodelling** is paced by the composite of soft tissues relating to each of the bones. The functions of remodelling are to: (1) progressively create the changing **size** of each whole bone; (2) sequentially **relocate** each of the component regions of the whole bone to allow for overall enlargement; (3) progressively **shape** the bone to accommodate its various functions; (4) provide progressive fine-tune **fitting** of all the separate bones to each other and to their contiguous, growing, functioning soft tissues; and (5) carry out continuous structural adjustments to **adapt** to the intrinsic and extrinsic changes in conditions. Although these remodelling functions relate to childhood growth, most also continue on into adulthood and old age in reduced degrees to provide the same ongoing functions. This is what is meant in freshman histology when it is stated that bones 'remodel throughout life', but without an explanation of the reasons. Added to this, now, is that all soft tissues *also* undergo equivalent changes and for all of the same reasons.

In Figures 1.3 and 1.4 note that many external (periosteal) surfaces are actually resorptive. Opposite surfaces are depository. This is required in order to sculpt the complex morphology of the facial bones.

As a bone enlarges, it is simultaneously carried away from other bones in direct articu-

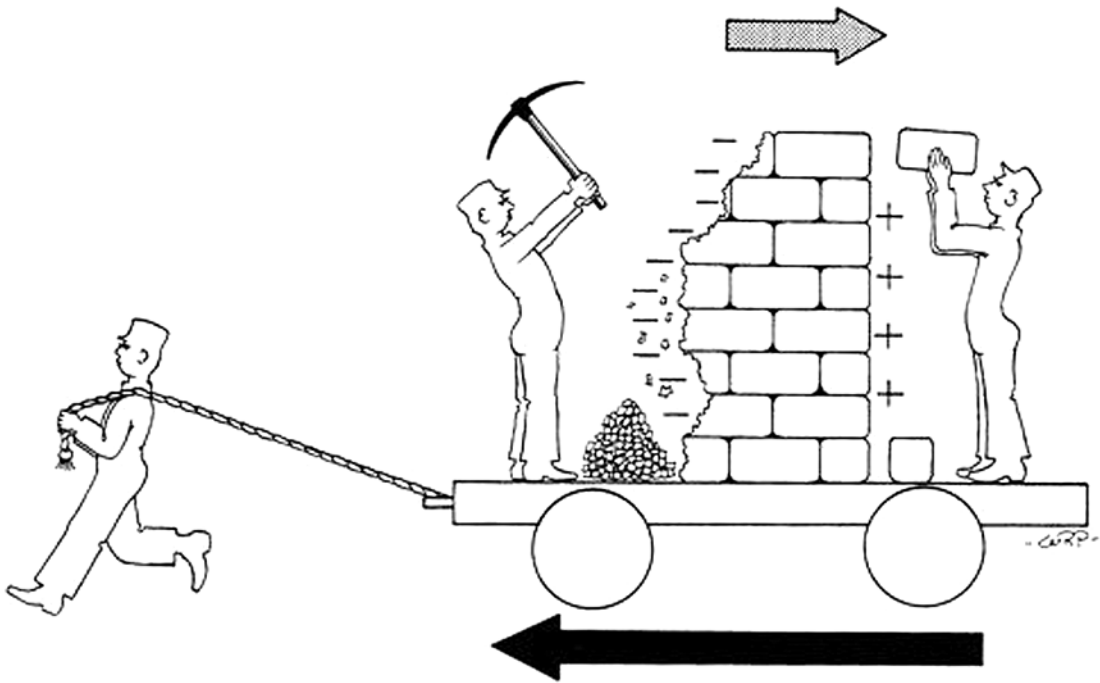


Figure 1.2 Diagrammatic depiction of displacement and remodelling – the two basic types of growth movement.

lation with it. This creates the ‘space’ between bones and allows bony enlargement to take place. The process is termed **displacement** (also called ‘translation’). It is a physical movement of a whole bone and occurs while the bone simultaneously remodels by resorption and deposition. As the bone enlarges in a given direction within a bony interface, it is simultaneously displaced in the **opposite** direction (Figure 1.5). The relationships underscore why facial articulations (sutures and condyles) are important factors; they are often direct clinical targets.

The process of new bone deposition does not cause displacement by **pushing** against the articular contact surface of another bone. Rather, the bone is **carried** away by the expansive force of all the growing soft tissues surrounding and attached to it by anchoring fibres. As this takes place, new bone is added immediately (modelling), the whole bone enlarges

and the two separate bones thereby remain in contact. The nasomaxillary complex, for example, is in sutural contact with the floor of the cranium. The whole maxillary region, *in toto*, is **displaced** downwards and forwards away from the cranium by the expansive growth of the soft tissues in the midfacial region (Figure 1.6a). This then triggers new bone growth at the various sutural contact surfaces between the nasomaxillary composite and the cranial floor (Figure 1.6b). Displacement thus proceeds downwards and forwards an equivalent amount as maxillary remodelling simultaneously takes place in an opposite upward and backward direction (i.e. **towards** its contact with the cranial floor).

Similarly, the whole mandible (Figure 1.5) is **displaced** ‘away’ from its articulation in each glenoid fossa by the growth enlargement of the composite of soft tissues in the developing face. As this occurs, the condyle and ramus grow

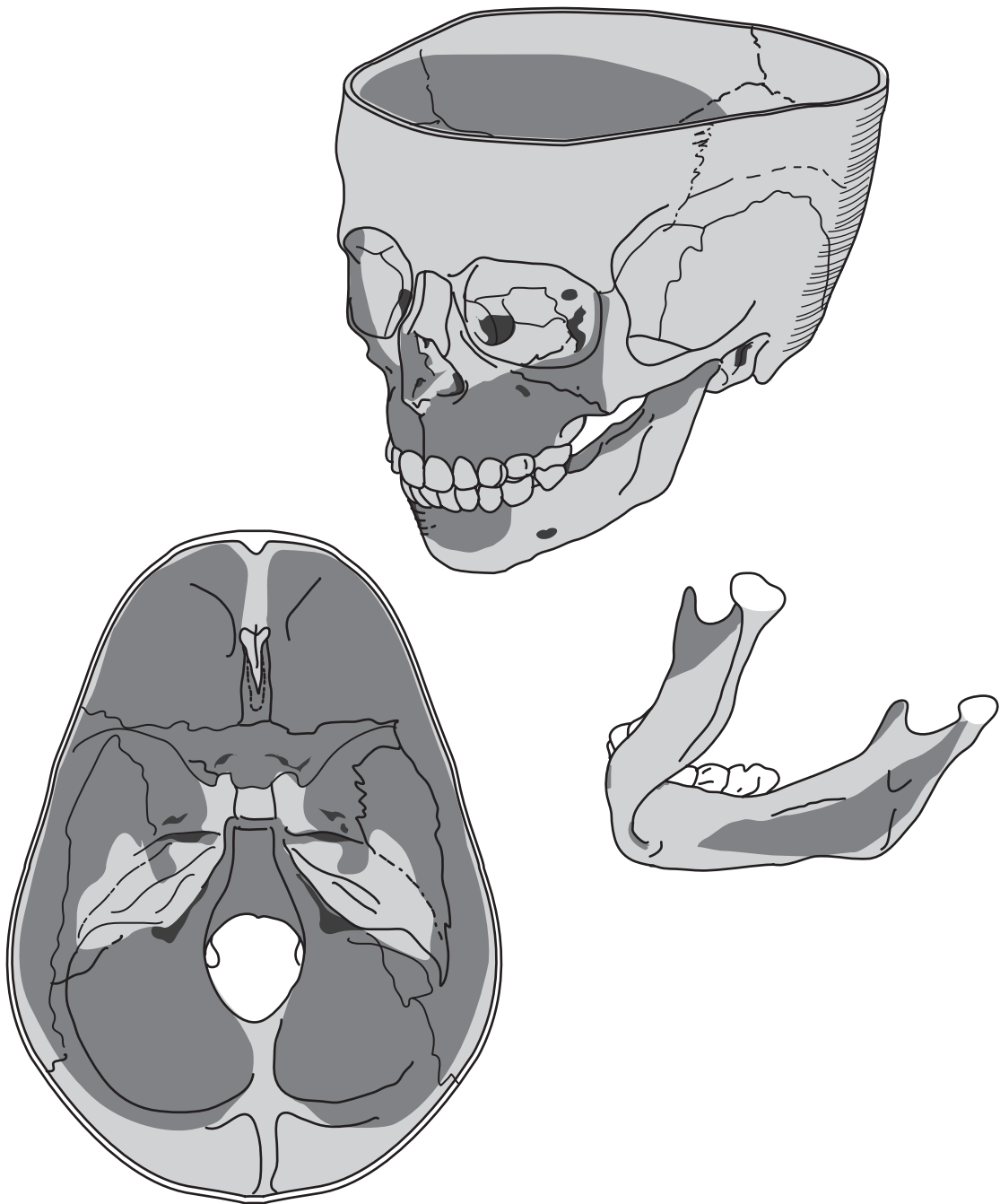


Figure 1.3 Summary diagram of the resorptive (darkly stippled) and depository (lightly stippled) fields of remodelling. (From Enlow DH, Kuroda T, Lewis AB. The morphological and morphogenetic basis for craniofacial form and pattern. *Angle Orthod* 1971;41:161. Reproduced with permission from the Angle Foundation.)

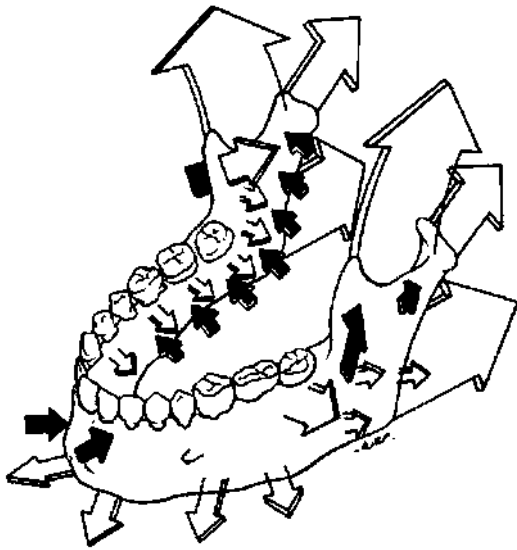


Figure 1.4 Black arrows are surface resorptive and white arrows are depository.

upwards and backwards (relocate) into the 'space' created by the displacement process. Note that the ramus also changes in both shape and size due to the remodelling process as it relocates posterosuperiorly. It becomes longer and wider to accommodate the increasing mass of masticatory muscles inserted onto it, the enlarged breadth of the pharyngeal space and the vertical lengthening of the nasomaxillary part of the growing face.

A beginning student is always confused because it is repeatedly heard and read that the face 'grows forwards and downwards'. It would seem reasonable, then, that the growth activity of the mandible and the maxilla would be in their anterior, forward-facing parts. However, it is mostly the displacement movement that is forwards and downwards, thereby complementing the predominantly posterosuperior vectors of remodelling. This is one fundamental reason, as mentioned above, that all joint contacts and bone ends are of basic significance in the growth picture. They are the points away from which displacement proceeds and, at the same time, the sites where remodelling

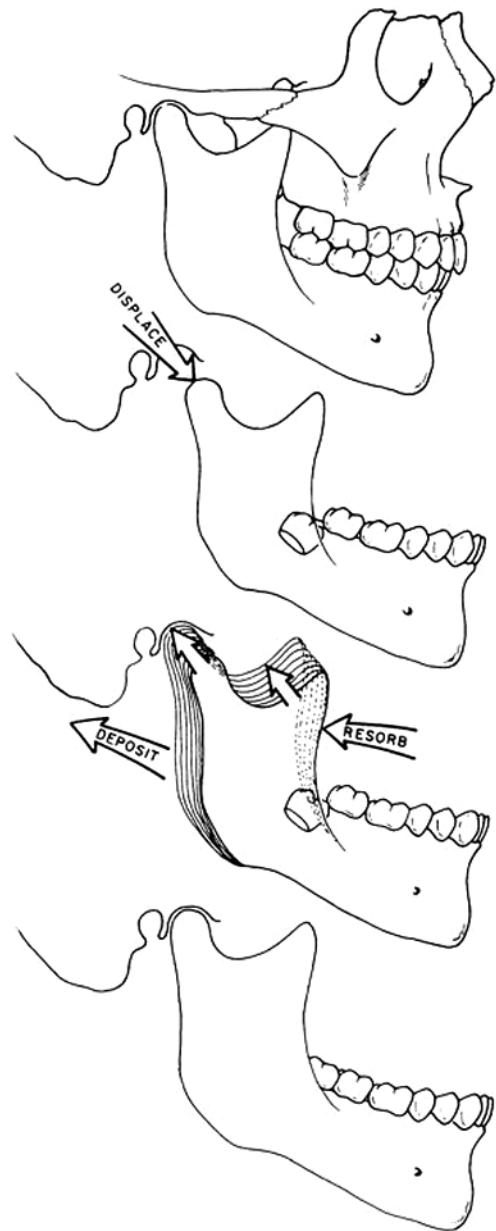


Figure 1.5 Illustrates the displacement of the mandible downwards and forwards with upward and backward remodelling.

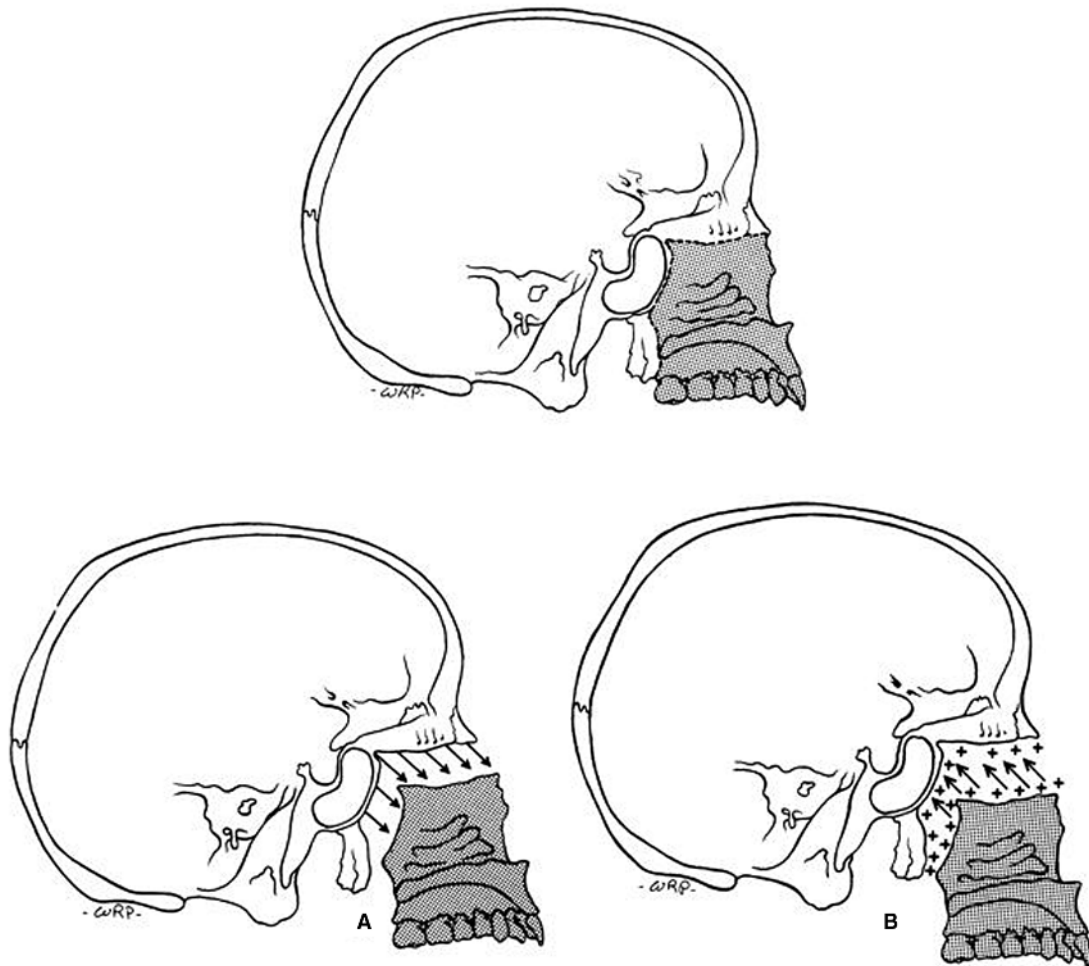


Figure 1.6 Illustrates the displacement of the nasomaxillary complex downward and forwards (A) with upward and backward (B) remodelling.

lengthens a given bone. Thus, they are key locations where clinical procedures can alter the growth process.

THE THREE PRINCIPAL REGIONS OF FACIAL AND NEUROCRANIAL DEVELOPMENT

The major but mutually interrelated form/function components involved in development

are the brain with its associated sensory organs and basicranium, the facial and pharyngeal airway, and the oral complex. Although discussed below separately, they are, of course, developmentally inseparable. The fact that all three are interrelated becomes important when applying growth concepts to clinical situations since the developmental factors underlying most craniofacial dysplasias involve all three. In addition, very few clinical procedures address malocclusions at the level of the cranial base.

The brain and basicranium

The configuration of the neurocranium (and brain) determines a person's headform type which, in turn, sets up many of the proportionate and topographical features characterising facial type. A long and narrow basicranium (dolichocephalic) with its more elongate and open-angle configuration, for example, programmes the developmental process so that it characteristically leads to an anteroposteriorly and vertically elongated facial pattern and a more frequent built-in tendency for mandibular retrusion (Figure 1.7, top panel). A rounder basicranium (brachycephalic) is characterised by a proportionately wider but anteroposteriorly shorter configuration, a more closed basicranial flexure, and a vertically and protrusively shorter but wider midface (nasomaxillary complex). These features generally underlie a more orthognathic (or less retrognathic) profile

or, in the extreme, a tendency for mandibular protrusion (Figure 1.7, bottom panel).

These characteristic features exist because the basicranium is the template that establishes the shape and perimeter of the facial growth fields. The mandible articulates by its condyles onto the ectocranial side of the middle endocranial fossae and the bicondylar dimension is thus determined by this part of the cranial floor. The nasomaxillary complex is suspended from the anterior endocranial fossae, and the width of the facial airway, the configuration of the palate and maxillary arch, and the placement of all these parts are thus established by it.

The airway

The facial and pharyngeal airway is a space determined by the multitude of separate parts comprising its enclosing walls. The configuration

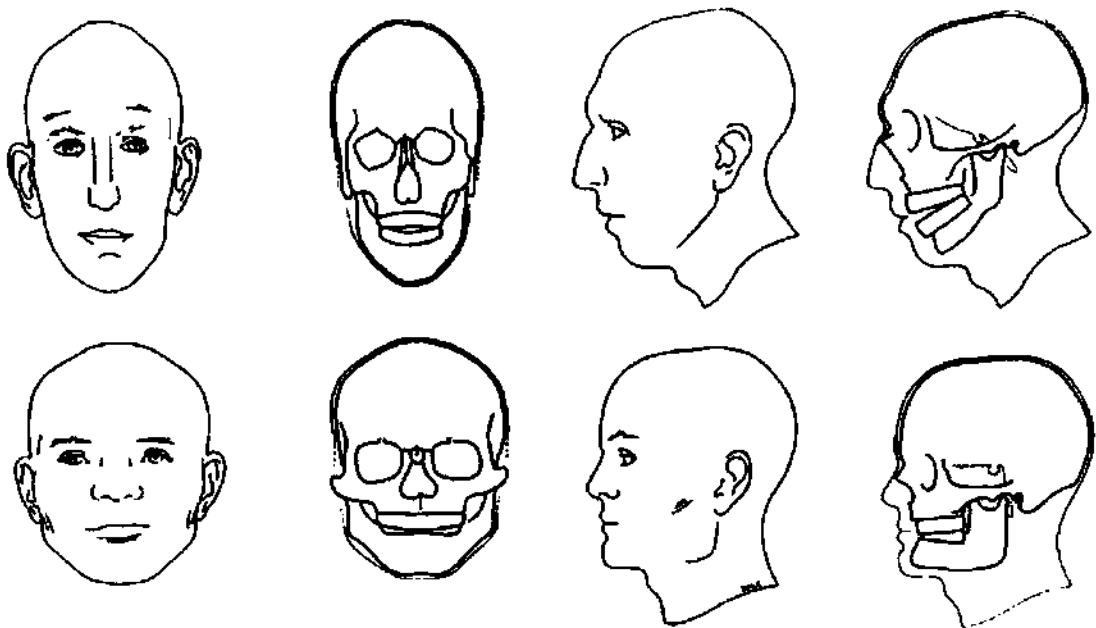


Figure 1.7 The underlying tendency for dolichocephaly towards Class II malocclusions with increased lower vertical facial height and brachycephaly towards Class III malocclusions with decreased lower vertical facial height. (From Enlow DH, Dale J. In: Ten Cate R. (ed.) *Oral Histology*, 4th edn. St. Louis: CV Mosby, 1994, with permission.)

and dimensions of the airway are thus a product of the composite growth and development of many hard and soft tissues along its pathway from nares to glottis.

Although determined by surrounding parts, those parts in turn are dependent on the airway for maintenance of their own functional and anatomical positions. If there develops any regional childhood variation along the course of the airway that significantly alters its configuration or size, growth then proceeds along a different course, leading to a variation in overall facial assembly that may exceed the bounds of normal pattern. The airway functions, in a real sense, as a keystone for the face. A keystone is that part of an arch which, if of proper shape and size, stabilises the positions of the remaining parts of the arch. In Figure 1.8 a few of the many 'arches' in a face can be recognised and the bony remodelling (+ and -) producing them. Horizontally and vertically, the arch form of the orbits, the nasal and oral sides of the palate, the maxillary arch, the sinuses, the zygomatic arches and so forth are all subject to airway configuration, size and integrity. Note that the airway is strategically pivotal to all of them.

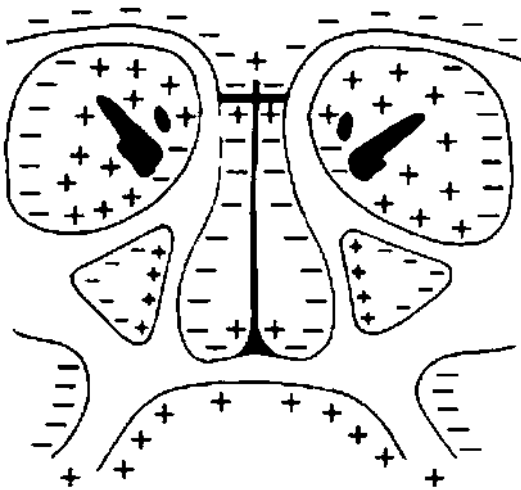


Figure 1.8 The depository (+) and resorptive (-) areas of the midface in coronal section.

Two easy personal tests can be performed illustrating the airway as a significant factor in programming the developmental course of the facial 'genic' tissues. This is useful in explanations of malocclusion aetiology for patients or their parents. First, starting with an open mouth, close the lips and jaws (note that your tongue will likely rise against the palate) and, momentarily, swallow. This evacuates the oral air into the pharynx, creating an oral vacuum. The effect is to stabilise the mandible and hold it in a closed position with minimal muscle effort. Now, open the jaws and lips, feeling a rush of air into the mouth. To hold the lower jaw in this 'mouth breathing' posture requires a different pattern of muscle activity, and the osteogenic, chondrogenic, periodontal, fibrogenic and other histogenic tissues thereby receive a correspondingly different pattern of signals. This causes different developmental responses to a different functional morphology adapted to the conditions. As emphasised before, the operation of the growth process itself functions normally. It is the nature of the **activating signals** that produces emerging deviations in the course of development that results in any morphological variation and perhaps malocclusion.

The second test is similar. Swallow with your teeth in occlusion and your lips touching. Next, swallow with your teeth and lips apart. Open-jawed swallows are possible, but can be difficult when one is accustomed to a closed mouth. Note the very different pattern of masticatory and hyoid muscle actions required. As with the mouth breathing test outlined above, altered signals are generated, and the genic tissues work toward a different balance combination, producing a variation in facial morphology. A factor often overlooked by clinicians is that these altered signals may result in different treatment responses to the same intervention. For example, patients' response to a removable orthopaedic appliance such as a bionator or twin block may vary dramatically based on their mode of breathing.

The oral region

In addition to the basicranial and airway factors described above affecting mandibular and maxillary shape, size and positioning, other basic considerations are involved. If a brain and basicranial asymmetry exists, this condition can either be passed on to cause a corresponding facial asymmetry, or compensated by the facial developmental process to either offset or reduce its magnitude. For the latter, remodelling adjustments produce an actual opposite asymmetry in the nasomaxillary complex and/or mandible that counteracts the basicranial condition. Advances in craniofacial imaging such as cone beam computed tomography have made it easier for clinicians to identify the site of facial asymmetry and plan treatment accordingly.

For the maxilla, if not developmentally compensated or only partially so, the maxillary arch can become deviated laterally, matching the lateral asymmetry of the anterior endocranial fossae. Or, vertically, one side can become lowered or elevated relative to the other, including the orbits, palate and maxillary arch. For the mandible, the middle endocranial fossae determine the placement of the temporomandibular joints and, if asymmetrical, one or the other will be lower or higher, forward or back. Whole mandible alignment necessarily follows if not fully or partially adjusted by remodelling during development.

Many other such compensatory adjustments by the remodelling process occur throughout growth and development in many ways. These involve the development of certain regional imbalances to offset others, resulting in a composite overall structural and functional equilibrium.

CRANIOFACIAL LEVELS

When the face is in balance, there exists a descending, cause-and-effect stratigraphic arrangement of structural **levels** in the design of the face. Beginning with the frontal lobes of the cerebrum,

the floor of the anterior endocranial fossae adapts in size and shape during their interrelated development. The ectocranial side of this floor is the roof of the nasal chambers, thus programming the perimeter of that key facial part of the airway. This configuration, in turn, is projected inferiorly to the next level, establishing the proportions and configuration of the nasal side of the palate. Then, the perimeter of the apical base of the maxillary dental arch is set by the oral side of the hard palate, all representing configurational projections from the anterior endocranial fossae. The next level following is maxillary intercanine width, and then mandibular intercanine width, all preprogrammed in configuration and in proportion to the basicranium.

The mandible has a component not represented in the maxilla, and that is its **ramus**. The anteroposterior size of the ramus develops by an amount approximating the horizontal span of the pharynx, which has a programmed anteroposterior dimension established by its ceiling, which is the ectocranial side of the middle endocranial fossae underlying the temporal lobes of the cerebrum. The ramus, thus, places the mandibular arch in occlusion with the maxillary arch following a pattern set up by the basicranium. Vertically, the developing ramus lowers the corpus by progressive amounts, adapting to the vertical growth of the middle cranial fossae (clivus) as well as the vertical expansion of the nasal airway and developing dentition.

The face, thus, is a stratified series of vertical levels all sharing a common developmental template. This makes possible a workable morphogenic system having a structural design allowing large numbers of separate parts to develop together in harmony and to carry out respective functions while it happens.

THE TWO BASIC CLINICAL TARGETS

There is one developmental concept that needs to be addressed with particular emphasis

because of its great significance to the old clinical axiom 'working with growth'. While a factor such as the basicranium can prescribe and determine a 'growth field' in the contiguous facial complex, as described above, it is within the boundaries of that field that remodelling then engineers the **shape and size and functional fit** of all parts and develops them through time. However, it can be misunderstood if one presumes that all 'local growth' is regulated solely by a single local, intrinsic growth system. Remember, there are *two* kinds of growth activity: localised, regional **remodelling** ('genic' tissues); and the **displacement** movements of all the separate parts as they remodel. Thus, there are two corresponding histogenic recipients of clinical intervention.

To illustrate this fundamental concept, the incisor and premaxillary alveolar region of the maxilla develops into its adult shape and dimensions by the local remodelling process. But the principal source of the considerable extent of its downwards and forwards growth movement is by displacement, and *that* comes from biomechanical forces of growth enlargement occurring *outside* the premaxillary region itself. Thus, most of the growth movements responsible for the anatomical **placement** of this region, along with, passively, its teeth, are not controlled within its own tissues or any genetic blueprint therein, even though this might be a natural presumption. *Two* clinical targets thereby exist for orthodontists: local remodelling and, separately, the displacement of some whole part produced by the sum of developmental expansions occurring everywhere. There are certain clinical procedures that relate specifically to one or the other target and some that involve both. For example, rapid palatal expansion mimics displacement; incisor retraction primarily involves remodelling of the anterior portion of the alveolar arch, and functional appliance treatment involves both remodelling of the alveolar process and displacement of the mandible, triggering changes in the remodelling of the ramus.

These two basic growth movements are difficult to separate in clinical interventions since the majority of therapeutic procedures require the teeth to be used to deliver biomechanical forces to the surrounding tissues. This limits the clinician's ability to separate displacement from modelling using traditional cephalometric techniques. It is likely that the new three-dimensional imaging modalities currently available will help with this problem.

CHILD-TO-ADULT CHANGING PROPORTIONS

The three principal craniofacial growing parts (brain and basicranium, airway, oral region) each has its own separate timetable of development even though all are inseparably bound as an interrelated whole. Some body systems, such as the nervous and cardiovascular systems, develop earlier and faster compared with others, including the airway and oral regions. The reason is that airway growth is proportionate to growing body and lung size, and the oral region is linked to developmental stages involving the fifth and seventh cranial nerves and associated musculature, the suckling process, dental eruption stages and masticatory development.

The infant and young child are characterised by a wide-appearing face because of the precociously broad basicranial template, but the face otherwise is vertically short (Figure 1.9). This is because the nasal and oral regions are yet diminutive, matching the smallish body and pulmonary parts, and with masticatory development in a transitory state. The vertical height of the mandibular ramus is still relatively short because it is linked in developmental feedback with the shorter, later-maturing nasal and dental regions. Masticatory musculature is proportionately sized and shaped to progressively match increasing function and to interplay developmentally with the ramus.

During later childhood and into adolescence, vertical nasal enlargement keeps pace




Figure 1.9 Infant, child and adult skulls showing the changes in both size and proportion that occur with growth and development. (Courtesy of William L. Brudon. From Enlow DH. *The Human Face*. New York: Harper & Row, 1968, with permission.)

with growing body and lung size, and dental and other oral components have approached adult sizes and configuration. The mandibular arch is lowered by increasing vertical ramus length. Overall, the early wide face has become altered in proportion by the later vertical changes. The end effect is particularly marked in the dolichocephalic long-headed and long-face patterns and less so in the brachycephalic headform type.

TOOTH MOVEMENT

To begin, a tooth is moved by either or both of two developmental means: by becoming actively moved in combination with its own remodelling periodontal connective tissue and alveolar socket; and by being carried along

passively as the entire maxilla or mandible is displaced anteroinferiorly during facial morphogenesis. Another basic and clinically significant concept is that **bone and connective tissues** (such as the periodontal connective tissue, periosteum, endosteum and submucosa, all of which participate directly and actively in a tooth's movement) have an intrinsic remodelling process that, when activated, move themselves as a growth function. When a tooth is moved, these other contiguous parts move with it by their own 'genic' remodelling process to sustain relationships. A tooth, however, *cannot move itself* in a comparable manner by its own remodelling. Teeth erupt 'fully grown' and are mobile, but not motile. A tooth is *moved* by bio-mechanical forces external to the tooth itself and there is an elaborate 'biology' in the composite process that produces a tooth's growth movements. A tooth must move (drift, erupt, etc.) during maxillary and mandibular growth in order to become properly placed in progressively changing anatomical positions. Whether the force producing the tooth's change in position is intrinsic or **clinically induced**, the biology is the same. As mentioned again because the point is important, it is the nature of the **activating signals** that is different, and this causes either the multiple array of genic tissues to alter the course of remodelling or the displacement process of a whole bone to become altered in direction or magnitude.

DRIFT

A worthy advance was made when it was realised that teeth undergo a process of **drift**. For many years this fundamental concept was limited to horizontal (mesial and distal) movements and the essential function was held to be a stabilisation of the dental palisade to compensate for interproximal attrition. Added to this, now, is that drift has a basic **growth** function. It serves to anatomically place the teeth in occlusion as the maxilla and mandible enlarge.

Such movements are significant considering that a jawbone lengthens considerably from prenatal to adult sizes. Also, the original drift concept was for horizontal movement. This is in addition to 'eruption' and should not be so termed. **Vertical drift** is a basic growth movement the clinician 'works with' because it can be modified by clinical intervention (i.e. orthodontic treatment).

Just as teeth undergo a drifting movement, the bone housing them also moves. Unlike a tooth, however, bone moves by the remodelling action of its enclosing osteogenic membranes, and this is also a direct target for clinical intervention. The intrinsic coordination of these bone-tooth movements is remarkable.

GROWTH ROTATIONS

Growth rotations occur throughout the craniofacial region and fall into two categories: remodelling rotations and displacement rotations. They are particularly important in orthodontics when they occur in the mandible. Small rotations occur in everyone during growth, however, when these are significant they can have a large impact on facial form. For example, a significant clockwise mandibular growth rotation can lead to a long face and an anti-clockwise rotation to a short face deformity.

Growth rotations can also have a significant effect on determining the direction of tooth eruption.

FINAL THOUGHTS

It has been emphasised in the preceding pages that facial growth is a process requiring intimate morphogenic interrelationships among all of its component growing, changing and functioning soft and hard tissue parts. No part is developmentally independent and self-contained. This is a fundamental and very important principle of growth. As underscored earlier, the growth process works toward an ongoing state of composite functional and structural equilibrium. In clinical treatment, no key anatomical part can be fully segregated and altered without affecting 'balance' with other parts and their state of physiological equilibrium as well. In essence, orthodontic treatment seeks to maximise the effectiveness of anatomical compensations to achieve an aesthetically harmonious masticatory system.

Further Reading

Enlow D, Hans M. *Essentials of Facial Growth*, 2nd edn. Needham Press, Ann Arbor, MI, 2008.