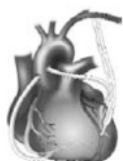

CHAPTER 1

Synopsis of Adult Cardiac Surgical Disease

<i>Coronary Artery Disease</i>	3
<i>Left Ventricular Aneurysm</i>	13
<i>Ventricular Septal Rupture</i>	16
<i>Aortic Stenosis</i>	18
<i>Aortic Regurgitation</i>	26
<i>Mitral Stenosis</i>	29
<i>Mitral Regurgitation</i>	33
<i>Tricuspid Valve Disease</i>	36
<i>Endocarditis</i>	39
<i>Hypertrophic Obstructive Cardiomyopathy</i>	41
<i>Aortic Dissections</i>	43
<i>Thoracic Aortic Aneurysms</i>	48
<i>Atrial Fibrillation</i>	54
<i>Ventricular Tachycardia and Sudden Death</i>	56
<i>End-Stage Heart Failure</i>	60
<i>Pericardial Disease</i>	63
<i>Congenital Heart Disease: Atrial Septal Abnormalities</i>	67
<i>Adults with Other Congenital Heart Disease</i>	68



1 Synopsis of Adult Cardiac Surgical Disease

It is essential that all individuals involved in the assessment and management of patients with cardiac surgical disease have a basic understanding of the disease processes that are being treated. This chapter presents the spectrum of adult cardiac surgical disease that is encountered in most cardiac surgical practices. The pathophysiology, indications for surgery, specific preoperative considerations, and surgical options for various diseases are presented. Diagnostic techniques and general preoperative considerations are presented in the next two chapters. Issues related to cardiac anesthesia and postoperative care specific to most of the surgical procedures presented in this chapter are discussed in Chapters 4 and 8, respectively. The most current guidelines for the evaluation and management of patients with cardiac disease can be obtained from the American College of Cardiology website (www.acc.org).

I. Coronary Artery Disease

A. Pathophysiology. Coronary artery disease (CAD) results from progressive blockage of the coronary arteries by atherothrombotic disease. Significant risk factors include hypertension, dyslipidemia (especially high LDL and low HDL levels), diabetes mellitus, cigarette smoking, and obesity. Clinical syndromes result from an imbalance of oxygen supply and demand resulting in inadequate myocardial perfusion to meet metabolic demand (ischemia). Progressive compromise in luminal diameter producing supply/demand imbalance usually produces a pattern of chronic stable angina. Plaque rupture with superimposed thrombosis is responsible for most acute coronary syndromes (ACS), which include classic “unstable angina”, non-ST-elevation myocardial infarctions (NSTEMI), and ST-elevation infarctions (STEMI). Interestingly, plaque rupture commonly occurs in coronary segments that are not severely stenotic. Endothelial dysfunction has become increasingly recognized as a contributing factor to worsening ischemic syndromes. Generalized systemic inflammation, indicated by elevated C-reactive protein levels, is usually noted in patients with ACS, and appears to be associated with adverse outcomes.¹

B. Management strategies

1. Symptomatic coronary disease is initially treated with medical therapy, including aspirin, nitrates, and β -adrenergic blockers. Calcium channel blockers (CCBs) are considered if β -blockers are contraindicated. Statins should be given to control dyslipidemias and are effective for plaque stabilization. Angiotensin-converting

enzyme (ACE) inhibitors are used for control of hypertension, especially in patients with compromised left ventricular function. Clopidogrel generally does not provide benefit to patients with chronic stable angina, except in selected subsets, but is beneficial in patients with an ACS.²⁻⁶

2. STEMI is preferentially treated by percutaneous coronary intervention (PCI) (angioplasty and stenting), although thrombolytic therapy may be considered when PCI cannot be performed within a few hours. Clinical benefit is time-related ("time is myocardium"), and the best results are obtained with "door to balloon" times less than 90 minutes. However, myocardial salvage may still occur if reperfusion can be accomplished within 6 hours of the onset of chest pain.^{7,8}
3. Patients presenting with an ACS should be treated with aspirin and unfractionated or low-molecular-weight heparin (LMWH), as well as the standard therapy listed above (nitrates, β -blockers, statins).^{9,10} Clopidogrel may provide clinical benefit to these patients if they are to be treated medically, and it may be given if an early invasive strategy is proposed. The 2007 ACC/AHA recommendations were that it should not be given if urgent surgery is considered likely, but this can be difficult to predict and therefore it is given routinely. Most studies have shown that 30-day outcomes are better in patients undergoing coronary artery bypass graft (CABG) surgery who initially received clopidogrel.²⁻⁶ However, one study showed that there was no difference in outcomes whether clopidogrel was given or not if patients had surgery within 5 days, but outcome was better if it was initially given on presentation, then stopped for at least 5 days before surgery.¹¹ This study supports the ACC/AHA recommendation that clopidogrel be stopped at least 5 days before surgery except in urgent or emergent situations.⁹ If prasugrel is given in anticipation of PCI, but CABG is recommended instead, it should be stopped at least 7 days prior to surgery.
4. In patients with continuing ischemia and high-risk features (crescendo angina over 48 hours, rest pain, ECG changes at rest, congestive heart failure [CHF], hemodynamic instability, or an elevated troponin level), platelet glycoprotein IIb/IIIa inhibitors, such as tirofiban or eptifibatide, may be added to the regimen with plans to proceed to an early invasive strategy of catheterization. At that time, the appropriate means of intervention (PCI vs. CABG) can be determined. If a IIb/IIIa inhibitor is used and a clopidogrel load is not given prior to PCI, it will provide antiplatelet activity until the initial dosing of clopidogrel achieves adequate platelet inhibition (a few hours after a 600 mg load). Numerous trials are evaluating the role of various platelet inhibitors and the use of bivalirudin rather than heparin during PCI.

C. Selection of an interventional procedure

1. An assessment of the patient's clinical presentation, the extent and nature of coronary disease, degree of inducible ischemia on stress testing, and status of ventricular function are taken into consideration when determining whether the patient is an appropriate candidate for an interventional procedure.¹² In patients with convincing evidence of an ACS, stress tests are not indicated prior to cardiac catheterization. The primary objective of any intervention is the relief of ischemia to prevent or minimize the extent of myocardial damage.
2. PCI has seen wide applicability beyond its proven benefit in early randomized trials, which generally had very selective inclusion criteria. It is often preferable to surgery in patients presenting with STEMI or with ongoing ischemia with NSTEMIs because

it can more promptly salvage myocardium – unless the anatomy is such that CABG is preferable (see below). The benefits of PCI in patients with chronic stable angina are not as well defined.^{13,14}

3. The indications for PCI in multivessel disease are controversial. Although several studies suggest that CABG improves long-term survival better than PCI, other trials indicate that survival is comparable, although more patients undergoing PCI require reintervention.^{15–20} The rationale is that PCI only addresses focal lesions despite CAD being a multifocal disease, whereas CABG bypasses the entire proximal segment. Thus, repeat intervention, usually in sites other than the original stent location, is much more likely if PCI is utilized. Evidence-based guidelines have been established by major organizations to identify when PCI and/or CABG is indicated (Figures 1.1 and 1.2).¹² These guidelines will continue to evolve when the results of additional trials including multivessel and left main disease,^{21–23} reoperative situations, varying patient subpopulations, and newer stent technologies become available. One approach to decision making is use of the SYNTAX score (accessible at www.syntaxscore.com), which assesses the extent and nature of coronary artery disease and provides comparative major adverse cardiac event (MACE) rates for PCI and CABG for multivessel as well as left main disease.^{23–25} Use of such data can provide patients with adequate evidence-based clinical information to give informed consent for any interventional procedure.
 4. Although drug-eluting stents (DES) are associated with a lower risk of restenosis than bare-metal stents (BMS), most studies have not shown a significant impact on the risk of myocardial infarction or death.²⁶ In fact, the risk of stent thrombosis is greater with DES, and this is accentuated in patients who are resistant to the antiplatelet effects of aspirin and/or clopidogrel.²⁷ Platelet function testing may be beneficial in determining which patients are resistant to their antiplatelet effects. To minimize the risk of stent thrombosis, it is recommended that patients receiving BMS take aspirin and clopidogrel for at least 1 month, and those receiving DES take these medications for at least 1 year.²⁸
 5. One should not consider either PCI or CABG an exclusive approach to a patient's coronary artery disease. For example, one hybrid approach is to perform a PCI of the culprit lesion in an unstable patient in the interest of myocardial salvage and then refer the patient for surgical revascularization of other lesions.²⁹ It has even been proposed that placing a left internal thoracic artery (LITA) to the left anterior descending artery (LAD) in a patient with three-vessel disease provides the essential long-term benefit of a CABG and converts the patient's anatomy to two-vessel disease which can be managed medically or with PCI.³⁰
- D. Indications for surgery.** The justification for proceeding with an intervention is based primarily upon an assessment of whether the patient is at increased risk for an adverse cardiac event. Studies have shown that surgery is very effective in relieving angina, in many cases is able to delay infarction, and in most cases can improve survival compared with continued medical management. CABG can be deemed appropriate based on an assessment of the patient's symptom status, non-invasive imaging studies, and the degree of anatomic disease (Figure 1.1).¹² It should be considered when PCI is not feasible or when the short- and long-term benefits of CABG are superior to those of PCI (Figure 1.2).

6 SYNOPSIS OF ADULT CARDIAC SURGICAL DISEASE

Asymptomatic					
Stress Test Med. Rx					
High Risk Max Rx	U	A	A	A	A
High Risk No/min Rx	U	U	A	A	A
Int. Risk Max Rx	U	U	U	U	A
Int. Risk No/min Rx	I	I	U	U	A
Low Risk Max Rx	I	I	U	U	U
Low Risk No/min Rx	I	I	U	U	U
Coronary Anatomy	CTO of 1 vz.: no other disease	1-2 vz. disease; no Prox. LAD	1 vz. disease; of Prox. LAD	2 vz. disease with Prox. LAD	3 vz. disease; no Left Main

CCS Class I or II Angina					
Stress Test Med. Rx					
High Risk Max Rx	A	A	A	A	A
High Risk No/min Rx	U	A	A	A	A
Int. Risk Max Rx	U	A	A	A	A
Int. Risk No/min Rx	U	U	U	A	A
Low Risk Max Rx	U	U	A	A	A
Low Risk No/min Rx	I	I	U	U	U
Coronary Anatomy	CTO of 1 vz.: no other disease	1-2 vz. disease; no Prox. LAD	1 vz. disease; of Prox. LAD	2 vz. disease with Prox. LAD	3 vz. disease; no Left Main

CCS Class III or IV Angina					
Stress Test Med. Rx					
High Risk Max Rx	A	A	A	A	A
High Risk No/min Rx	A	A	A	A	A
Int. Risk Max Rx	A	A	A	A	A
Int. Risk No/min Rx	U	U	A	A	A
Low Risk Max Rx	U	A	A	A	A
Low Risk No/min Rx	I	U	A	A	A
Coronary Anatomy	CTO of 1 vz.: no other disease	1-2 vz. disease; no Prox. LAD	1 vz. disease; of Prox. LAD	2 vz. disease with Prox. LAD	3 vz. disease; no Left Main

	CABG			PCI		
	No diabetes and normal LVEF	Diabetes	Depressed LVEF	No diabetes and normal LVEF	Diabetes	Depressed LVEF
Two vessel coronary artery disease with proximal LAD stenosis	A	A	A	A	A	A
Three vessel coronary artery disease	A	A	A	U	U	U
Isolated left main stenosis	A	A	A	I	I	I
Left main stenosis and additional coronary artery disease	A	A	A	I	I	I

Figure 1.2 • Recommended method of revascularization based on extent of coronary disease. A, appropriate; U, uncertain; I, inappropriate. (Reproduced with permission from Smith, *Ann Thorac Surg* 2009;87:1328–31.)¹⁹

- Clinical scenarios.** The patient with refractory angina or a large amount of myocardium in ischemic jeopardy has an indication for an intervention relatively independent of the extent of coronary involvement:
 - Class III–IV chronic stable angina refractory to medical therapy
 - Acute coronary syndromes, including unstable angina and NSTEMIs
 - Acute ischemia or hemodynamic instability following attempted PCI, which may include dissection and compromised flow or coronary perforation with tamponade
 - Acute evolving STEMI within 4–6 hours of the onset of chest pain or later if there is evidence of ongoing ischemia (early postinfarction ischemia)
 - Markedly positive stress test prior to major intra-abdominal or vascular surgery – but not necessarily if the patient has chronic stable angina
 - Ischemic pulmonary edema
- Anatomy.** A second group of patients includes those without disabling angina or refractory ischemia in whom the extent of coronary disease, the status of ventricular function, and the degree of inducible ischemia on stress testing are such that surgery may improve long-term survival. This is presumed to occur by preventing infarction and preserving ventricular function. Surgery is especially beneficial for patients with impaired ventricular function and inducible ischemia, in whom the medical prognosis is unfavorable. The following recommendations for surgery, based on the randomized controlled trials of primarily chronic stable angina in the early 1980's have been incorporated into the 2009 appropriateness criteria guidelines noted in Figure 1.2. For patients with ACS, they are all class I indications for surgery, and for patients

Figure 1.1 • Appropriateness ratings for coronary artery bypass grafting. The grid incorporates Canadian Cardiovascular Society (CCS) class, extent of coronary disease, and results of non-invasive testing in determining whether CABG is an appropriate procedure. A, appropriate; U, uncertain; I, inappropriate. (Reproduced with permission from Patel et al., *J Am Coll Cardiol* 2009;53:530–53.)¹²

with fewer symptoms or moderate degrees of ischemia, they are class IIa and IIb indications (see Appendix 1).

- a. Left main stenosis $>50\%$
- b. Three-vessel disease with ejection fraction (EF) $<50\%$
- c. Three-vessel disease with EF $>50\%$ and significant inducible ischemia on stress testing
- d. Two-vessel disease with involvement of proximal LAD and EF $<50\%$ or significant inducible ischemia on stress testing
- e. One- and two-vessel disease not involving the LAD with extensive myocardium in jeopardy but lesions not amenable to PCI

Although surgery is appropriate in these patients, most patients with one- or two-vessel disease are preferentially treated by PCI. Furthermore, although the 2009 guidelines consider PCI for left main disease to be “inappropriate” and for three-vessel disease to be “uncertain”, use of the SYNTAX score, the Mayo Clinic risk score, and other risk models for PCI may modify this approach.^{23–25}

- 3. **Other conditions.** A third group of patients should undergo bypass surgery for coronary stenoses exceeding 50% when other open-heart procedures are indicated:
 - a. Valve operations, septal myectomy, etc.
 - b. Surgery for postinfarction mechanical defects (left ventricular aneurysm, ventricular septal rupture, acute mitral regurgitation)
 - c. Coronary artery anomalies with risk of sudden death (vessel passing between the aorta and pulmonary artery)

E. Preoperative considerations

- 1. Preoperative autologous blood donation has been considered to reduce the requirement for homologous transfusion. This may be feasible in patients with chronic stable angina, but not in those with acute coronary syndromes or left main disease. With the increasing safety of blood, the use of antifibrinolytic drugs, and the performance of off-pump surgery, this is no longer a common practice.³¹
- 2. **Anemia.** Preoperative blood transfusions should be considered in patients with an ACS and a hematocrit $<28\%$. This may not only improve the ischemic syndrome but will minimize hemodilution during surgery. Low preoperative hematocrits may increase operative mortality following CABG, often because of an association with other adverse risk factors for mortality, and it is not known whether transfusions can reduce that risk.³² Certainly, indiscriminate use of transfusions must be avoided because of their association with adverse outcomes following cardiac surgery.^{33–35}
 - a. In addition to blood withdrawal for preoperative lab tests, it is not uncommon for the hematocrit to fall several points after a cardiac catheterization from both blood loss and hemodilution with hydration. One study showed that coronary angiography was associated with a fall in hemoglobin of 1.8 g/dL (equivalent to about a 5.4% fall in hematocrit).³⁶
 - b. Hemodilution on cardiopulmonary bypass (CPB) to a hematocrit $<20\%$ may be associated with an increased risk of renal dysfunction, stroke, optic neuropathy, and death.^{37–40} Low hematocrits lower oncotic pressure and viscosity, increase fluid requirements, which contributes to extracellular edema, and make it more difficult to maintain an adequate blood pressure during and after CPB. Patients with

profound anemia tend to bleed and require more blood component transfusions. Thus, preoperative transfusions to an adequate level may be considered to reduce patient morbidity, possibly reduce the overall number of transfusions required intra- and postoperatively, and potentially decrease mortality.

3. **Ischemia.** Aggressive management of ongoing or potential ischemia is indicated in patients with critical coronary disease to reduce surgical risk. This may include adequate sedation and analgesia, antiischemic medications to control heart rate and blood pressure (intravenous nitrates and β -blockers), antiplatelet and anticoagulant medications (aspirin, clopidogrel, heparin, IIb/IIIa inhibitors), and/or placement of an intra-aortic balloon pump (IABP) for refractory ischemia. It cannot be over-emphasized that just because a patient has been catheterized and accepted for surgery does not mean that medical care should not be aggressive up to the time of surgery! If the patient has persistent ischemia despite all of these measures, emergency surgery is mandatory.
 - a. All antianginal medications should be continued up to and including the morning of surgery. Studies have demonstrated the benefit of preoperative **β -blocker** therapy in lowering perioperative mortality in cardiac surgery patients.⁴¹ Patients being admitted the morning of surgery should be reminded to take their medications before coming to the hospital.
 - b. **Unfractionated heparin (UFH)** is often used in patients with acute coronary syndromes, left main coronary disease, or a preoperative IABP. The heparin should generally be continued up to the time of surgery. Central lines can usually be placed safely while the patient is heparinized. Patients receiving heparin should have their platelet count rechecked daily to be vigilant for the development of heparin-induced thrombocytopenia (HIT). Note that preoperative assessment for HIT antibodies is not indicated in the absence of a clinical indication.⁴²
 - c. **Low-molecular-weight heparin (LMWH)** is often used in patients presenting with an ACS and may be used in the cath lab as well. It must be stopped at least 18–24 hours prior to surgery to minimize the risk of perioperative bleeding. **Fondaparinux**, often used routinely for venous thromboembolism prophylaxis, has a half-life of 17–21 hours and must be stopped at least 48 hours prior to surgery.
 - d. **Aspirin** is routinely used in patients with known coronary disease or given upon presentation to the hospital. Platelet function generally returns to normal within 3 days of cessation of aspirin, so it can be stopped at that time for truly elective cases.^{43,44} Otherwise, aspirin 81 mg should be continued up to the time of surgery in patients with an ACS or critical coronary disease, since it may improve outcomes without a significant increase in the risk of bleeding.^{44–47}
 - e. Preoperative use of **clopidogrel** has generally been shown to significantly increase the risk of bleeding and reexploration for bleeding.^{5,44,47,48} Thus, it has been recommended that it should be stopped 5–7 days before elective surgery, although stopping it for only 3 days may be acceptable prior to off-pump surgery.⁴⁹ **Prasugrel** is a more potent ADP inhibitor that can achieve 80% platelet inhibition within 30 minutes of administration. Because of its effectiveness and comparable half-life to clopidogrel, it may contribute to an even greater risk of perioperative bleeding and should be stopped at least 7 days prior to surgery, if possible.

- i. A loading dose of clopidogrel (300–600 mg) is frequently given to patients presenting with an ACS in the emergency room or in preparation for a PCI. Alternatively, a loading dose of prasugrel (60 mg) may be given in the cath lab. If PCI is not feasible or fails, the patient will then be at higher risk for bleeding following CABG.
 - ii. In some cases, emergency stenting of a culprit lesion causing an evolving infarction may be performed with subsequent referral for urgent surgery to achieve complete revascularization. In this situation, it is preferable to use a IIb/IIIa inhibitor to minimize stent thrombosis as a bridge to surgery. It should be stopped 4 hours prior to surgery, so that by the time surgery starts, 80% of platelet activity will have recovered.
 - iii. In patients with prior stenting (<1 month for a BMS and <1 year for a DES), there is an increased risk of stent thrombosis if clopidogrel is stopped.²⁸ Either surgery must be performed with the patient still taking clopidogrel or one might possibly stop the clopidogrel for only 3 days to have some residual protective antiplatelet activity, yet hopefully less intraoperative bleeding.
4. Other preoperative medications to be considered
- a. **Amiodarone** is beneficial in reducing the incidence of postoperative atrial fibrillation (AF). One respected randomized trial showed a benefit to giving 10 mg/kg daily starting 6 days prior to surgery, although a shorter course may be just as effective.⁵⁰
 - b. **Statins** have been demonstrated to reduce operative mortality, the risk of stroke, and the occurrence of AF when used in high doses (atorvastatin 40 mg).^{51–53}
 - c. **Steroids** have been evaluated as a means of reducing the systemic inflammatory response of surgery and have been shown to improve myocardial function and possibly reduce the incidence of AF.^{54–57} However, improvement in pulmonary function has not been clearly shown, and steroids do worsen postoperative hyperglycemia. Since the benefits are controversial, steroids have not seen widespread usage.

F. Surgical procedures

1. **Traditional coronary artery bypass grafting** is performed through a median sternotomy incision with use of CPB. Myocardial preservation is usually provided by cardioplegic arrest. The procedure involves bypassing the coronary blockages with a variety of conduits. The left internal thoracic (or mammary) artery (ITA) is usually used as a pedicled graft to the LAD and is supplemented by either a second ITA graft or radial artery graft to the left system and/or saphenous vein grafts interposed between the aorta and the coronary arteries (Figure 1.3).
 - a. The saphenous vein should be harvested endoscopically to minimize patient discomfort, reduce the incidence of leg edema and wound healing problems, and optimize cosmesis.⁵⁸ There are some concerns that endoscopic harvesting could produce endothelial damage that might compromise long-term patency and reduce long-term survival.^{59,60}
 - b. Use of additional arterial conduits (bilateral ITAs, radial artery) can be recommended to improve event-free survival,^{61–63} although one study of statin use showed comparable survival of patients receiving one or two ITAs.⁶⁴ The radial artery can be harvested endoscopically using a tourniquet to minimize bleeding

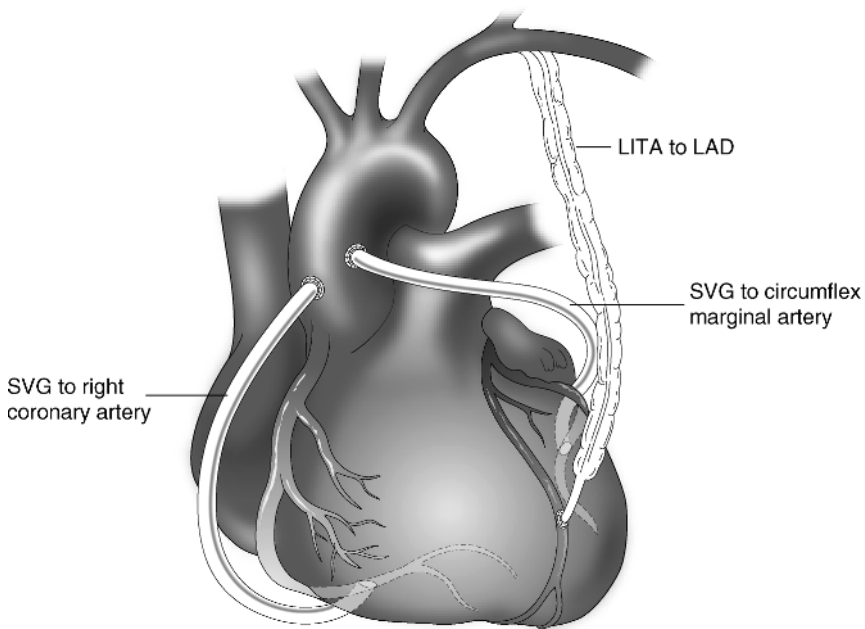


Figure 1.3 • Coronary artery bypass grafting. A left internal thoracic artery (LITA) has been placed to the left anterior descending artery (LAD) with aortocoronary saphenous vein grafts (SVG) to the circumflex marginal and right coronary arteries.

during the harvest with placement of a drain afterwards to prevent blood accumulation within the tract.^{65–67} With radial artery grafting, a vasodilator is initiated during surgery to minimize spasm (either IV diltiazem 0.1 mg/kg/h (usually 5–10 mg/h) or IV nitroglycerin 10–20 µg/min (0.1–0.2 µg/kg/min)).⁶⁸ This is continued in the ICU and then converted to either amlodipine 5 mg po qd or Imdur 20 mg po qd for several months. The benefit of such pharmacologic management to prevent spasm has been universally accepted, but not proven.

2. Concerns about the adverse effects of CPB spurred the development of “**off-pump**” **coronary surgery (OPCAB)**, during which complete revascularization should be achieved with the avoidance of CPB. Deep pericardial sutures and various retraction devices are used to position the heart for grafting without hemodynamic compromise. A stabilizing platform minimizes movement at the site of the arteriotomy (Figure 1.4). Intracoronary or aortocoronary shunting can minimize ischemia after an arteriotomy is performed.⁶⁹
 - a. Conversion to on-pump surgery may be necessary in the following circumstances:
 - i. Coronary arteries are very small, severely diseased or intramyocardial.
 - ii. LV function is very poor, or there is severe cardiomegaly or hypertrophy that precludes adequate cardiac translocation without hemodynamic compromise or arrhythmias.
 - iii. The heart is extremely small and vertical in orientation.

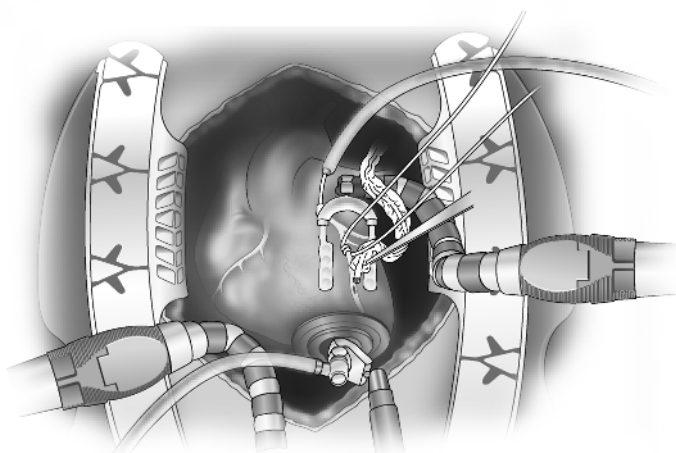


Figure 1.4 • Off-pump bypass grafting requires displacement of the heart using techniques to avoid hemodynamic compromise. These may include placement and elevation of deep pericardial sutures or the use of an apical suction device. A stabilizing device is used to minimize motion and a proximal vessel loop is placed to minimize bleeding at the site of the anastomosis.

- iv. Uncontrollable ischemia or arrhythmias develop with vessel occlusion that persists despite distal shunting.
 - v. Intractable bleeding occurs that cannot be controlled with vessel loops or an intracoronary shunt.
- b. OPCABs reduce transfusion requirements, and arguably lower mortality and reduce the risk of stroke, renal dysfunction, and atrial fibrillation.^{70–73} Despite these potential advantages, enthusiasm for this technique is modest, and it is estimated that fewer than 20% of CABGs are performed off-pump. Many surgeons reserve its use for patients with limited disease. Its major advantage may be in the very high-risk patient with multiple comorbidities in whom it is critical to avoid CPB.
 - c. In some patients with severe ventricular dysfunction, the heart will not tolerate the manipulation required during off-pump surgery. In this circumstance, right ventricular assist devices can be used to improve hemodynamics. Alternatively, surgery can be done on-pump on an empty beating heart to avoid the period of cardioplegic arrest. This technique may be beneficial in patients with ascending aortic disease that prevents safe aortic cross-clamping, but does allow for safe cannulation and use of aortic punches, such as the HEARTSTRING proximal seal system (Maquet Cardiovascular), to perform the proximal anastomoses.
3. **Minimally invasive direct coronary artery bypass (MIDCAB)** involves bypassing the LAD with the LITA without use of CPB via a short left anterior thoracotomy incision.⁷⁴ An additional incision in the right chest can be used to bypass the right coronary artery. Combining a LITA to the LAD with stenting of other vessels (“hybrid” procedure) has also been described.^{29,30}

4. **Robotic or totally endoscopic coronary artery bypass (TECAB)** can be used to minimize the extent of the surgical incisions and reduce trauma to the patient. Robotics can be used for both ITA takedown and grafting to selected vessels through small ports. These procedures can be done without CPB or using CPB with femoral cannulation. Generally, TECAB is used for limited grafting, but wider applicability is certainly feasible.⁷⁵
5. **Transmyocardial revascularization (TMR)** is a technique in which laser channels are drilled in the heart with CO₂ or holmium-YAG lasers to improve myocardial perfusion. Although the channels occlude within a few days, the inflammatory reaction created induces neoangiogenesis that may be associated with upregulation of various growth factors, such as vascular endothelial growth factor. This procedure can be used as a sole procedure performed through a left thoracotomy for patients with inoperable CAD in regions of viable myocardium. Alternatively, it can be used as an adjunct to CABG in viable regions of the heart where bypass grafts cannot be placed.⁷⁶

II. Left Ventricular Aneurysm

- A. **Pathophysiology.** Occlusion of a major coronary artery may produce extensive transmural necrosis which converts muscle into thin scar tissue. This results in formation of a left ventricular aneurysm (LVA) which exhibits dyskinesia during ventricular systole. In contrast, early reperfusion of an occluded vessel may limit the extent of myocardial damage with preservation of epicardial viability, resulting in an area of akinesia. This will result in an ischemic cardiomyopathy with a dilated ventricle that remodels with altered spherical geometry but does not produce an aneurysm.
- B. **Presentation.** The most common presentation of LVAs and ischemic cardiomyopathies is CHF due to systolic dysfunction. With LVAs, there is a reduction of stroke volume caused by geometric remodeling of the aneurysmal segment due to loss of contractile tissue and an increase in ventricular dimensions. Angina may also occur due to the increased systolic wall stress of a dilated ventricle and the presence of multivessel CAD. Systemic thromboembolism may result from thrombus formation within the dyskinetic or akinetic segment. Malignant ventricular arrhythmias or sudden death may result from the development of a macroreentry circuit at the border zone between scar tissue and viable myocardium.
- C. **Indications for surgery.** Surgery is usually not indicated for the patient with an asymptomatic aneurysm because of its favorable natural history. This is in contrast to the unpredictable prognosis and absolute indication for surgery in a patient with a false aneurysm, which is caused by a contained rupture of the ventricular muscle. Surgery may be beneficial in the asymptomatic patient with an extremely large aneurysm or when extensive clot formation is present within the aneurysm. Surgery is most commonly indicated to improve symptoms and prolong survival when one of the four clinical syndromes noted above (angina, CHF, embolization, or arrhythmias) is present. Arrhythmias may be treated by a non-guided endocardial resection through the aneurysm with/without cryosurgery along with subsequent placement of a transvenous implantable cardioverter-defibrillator (ICD).
- D. **Preoperative considerations**
 1. A biplane left ventriculogram is helpful in identifying regions of akinesia and dyskinesia and assessing the function of noninfarcted segments. Echocardiography

is best for assessing ventricular size and dimensions, wall motion of the noninfarcted segments, the presence of thrombus, and mitral valve function, which is often abnormal with dilated cardiomyopathies.

2. The patient should be maintained on heparin up to the time of surgery if left ventricular thrombus is present.

E. Surgical procedures

1. Standard aneurysmectomy entails a ventriculotomy through the aneurysm, resection of the aneurysm wall, including part of the septum if involved, and linear closure over felt strips (Figure 1.5).⁷⁷

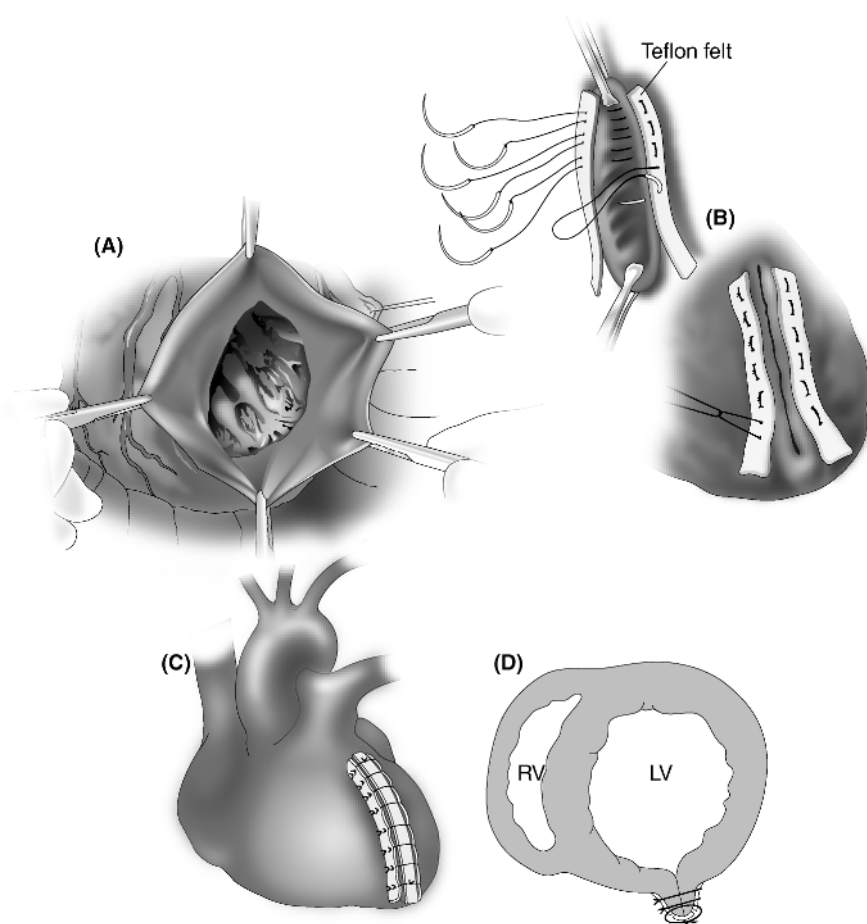


Figure 1.5 • Repair of a left ventricular aneurysm using the linear closure technique. (A) The thinned-out scar tissue is opened and partially resected. Any left ventricular thrombus is removed. (B) The aneurysm is then closed with mattress sutures over felt strips. (C) An additional over-and-over suture is placed over a third felt strip. (D) Cross-section of the final repair.

2. Endoventricular reconstruction techniques are applicable to large aneurysms or akinetic segments with the intent of reducing ventricular volume and restoring an elliptical shape.
 - a. The “endoaneurysmorrhaphy” technique is used for large aneurysms. A pericardial or Dacron patch is sewn to the edges of viable myocardium at the base of the aneurysm and the aneurysm wall is reapproximated over the patch (Figure 1.6). This preserves left ventricular geometry and improves ventricular function to a greater degree than the linear closure method.
 - b. A slightly more elaborate endoventricular reconstruction involves the endoventricular circular patch plasty technique of Dor, which is termed “surgical ventricular restoration” (SVR). This can be applied to left ventricular aneurysms as well as cases of ischemic cardiomyopathy with anterior akinesis (Figure 1.6D).^{78,79} The procedure involves placement of an encircling suture at the junction of the contracting and noncontracting segments, and then

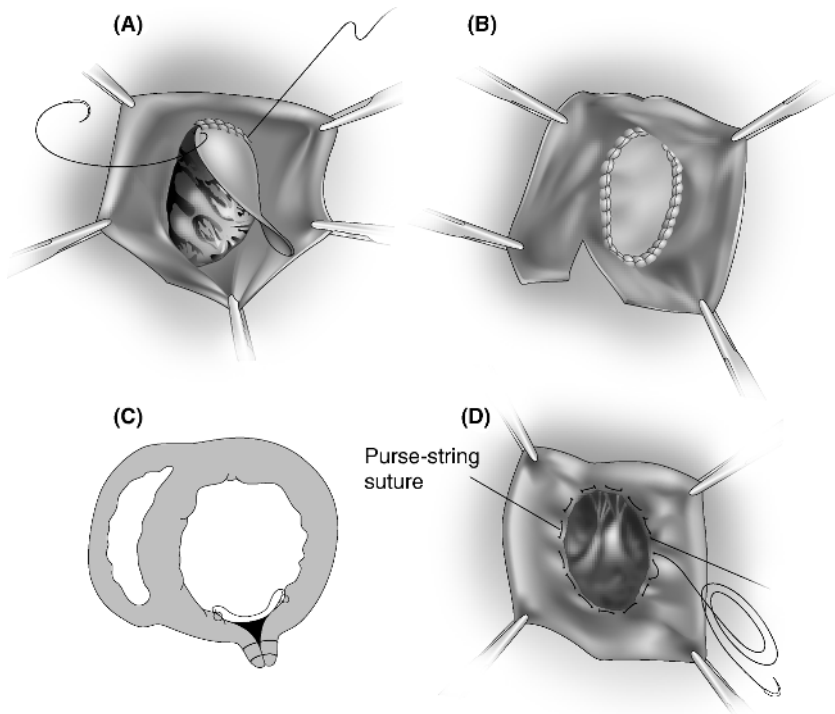


Figure 1.6 • Repair of a left ventricular aneurysm using the endoaneurysmorrhaphy technique. (A,B) A pericardial patch is sewn at the base of the defect at the junction of scar and normal myocardium to better preserve ventricular geometry. The resected edges of the left ventricle are closed in a similar fashion to the linear technique. (C) Cross-section of the final repair. (D) The Dor procedure is a modification of this technique in which a circumferential pursestring suture is placed at the base of the defect to restore a normal orientation to the ventricle. A patch is then sewn over the defect.

exclusion of the noncontracting segment with a patch. This produces an elliptical contour of the heart and results in significant improvement in ventricular size and function. This procedure is generally done on a beating heart to allow for better differentiation of akinetic and normal segments of the heart.

- c. Although SVR is associated with a reduction in LV volume, clinical improvement is not uniform. Several studies have suggested that the addition of SVR to a CABG improves clinical status and long-term survival.^{80,81} However, the STICH trial of patients with CAD-related anterior akinesia or dyskinesia with EF <35% was unable to demonstrate that reduction in LV size was associated with an improvement in symptoms or a reduction in mortality after 4 years (see also page 62).⁸²
3. Coronary bypass grafting of critically diseased vessels should be performed. Bypass of the LAD and diagonal arteries should be considered if septal reperfusion can be accomplished.
4. Mitral valve repair with a complete annuloplasty ring is indicated when the severity of mitral regurgitation (MR) is 2+ or greater. MR is usually related to apical tethering of the leaflets due to ventricular dilatation or may result from annular dilatation.

III. Ventricular Septal Rupture

- A. **Pathophysiology.** Extensive myocardial damage subsequent to occlusion of a major coronary vessel may result in septal necrosis and rupture. This usually occurs within the first week of an infarction, more commonly in the anteroapical region (from occlusion of the left anterior descending artery), and less commonly in the inferior wall (usually from occlusion of the right coronary artery). It is noted in fewer than 1% of acute MIs, and the incidence has been reduced by use of early reperfusion therapy for STEMIs. The presence of a ventricular septal defect (VSD) is suggested by the presence of a loud holosystolic murmur that reflects the left-to-right shunting across the ruptured septum. The patient usually develops acute pulmonary edema and cardiogenic shock from the left-to-right shunt.⁸³
- B. **Indications for surgery.** Surgery is indicated on an emergency basis for nearly all postinfarction VSDs to prevent the development of progressive multisystem organ failure. The overall surgical mortality rate is about 30%, but once the patient develops cardiogenic shock (which is often present), the surgical mortality rate is even higher.^{84,85} Occasionally, a small VSD with a shunt of <2:1 can be managed medically, but it usually should be repaired after 6 weeks to prevent future hemodynamic problems.
- C. **Preoperative considerations**
 1. Prompt diagnosis can be made using a Swan-Ganz catheter, which detects a step-up of oxygen saturation in the right ventricle. Two-dimensional echocardiography can confirm the diagnosis of a VSD and differentiate it from acute MR, which can produce a similar clinical scenario.
 2. Inotropic support and reduction of afterload, usually with an IABP, are indicated in all patients with VSDs in anticipation of emergent cardiac catheterization and surgery.
 3. Cardiac catheterization with coronary angiography should be performed to confirm the severity of the shunt and to identify associated coronary artery disease.

D. Surgical procedures

1. The traditional surgical treatment for postinfarct VSDs had been the performance of a ventriculotomy through the infarcted zone, resection of the area of septal necrosis, and Teflon felt or pericardial patching of the septum and free wall. This technique requires transmural suturing and is prone to recurrence.
2. The preferred approach is to perform circumferential pericardial patching around the border of the infarcted ventricular muscle. This technique excludes the infarcted septum to eliminate the shunt and reduces recurrence rates, because suturing is performed to viable myocardium away from the area of necrosis (Figure 1.7).⁸⁶
3. Coronary bypass grafting of critically diseased vessels should be performed, since it has been shown to improve short- and long-term survival after surgery.^{85,87}

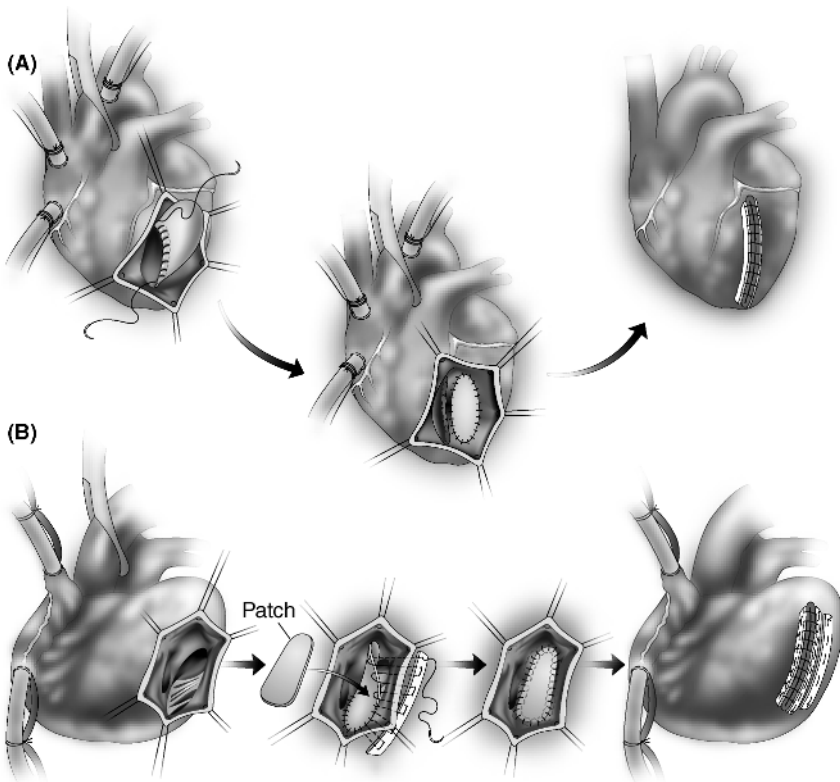


Figure 1.7 • Closure of a postinfarction ventricular septal defect using the exclusion technique. (A) Anterior VSD. (B) Inferior VSD. The pericardial patch is anchored to viable myocardium away from the site of the defect, thus eliminating shunt flow across the septal defect.

IV. Aortic Stenosis

A. Pathophysiology.⁸⁸ Aortic stenosis (AS) results from thickening, calcification, and/or fusion of the aortic valve leaflets, which produce an obstruction to left ventricular outflow. In younger patients, AS usually develops on congenitally bicuspid valves, whereas in older patients, degenerative change in trileaflet valves is more common. Aortic sclerosis is a very common finding in elderly patients, and may be a manifestation of atherosclerosis, but usually does not progress to aortic stenosis. Progression of AS may be related to endothelial cell activation and atherogenesis, but it has not been shown conclusively that statins will slow the progression of degenerative AS.^{89,90} In contrast, there is some evidence that statins may retard the progression of rheumatic AS.⁹¹

1. The impairment to cusp opening leads to pressure overload, compensatory left ventricular hypertrophy (LVH), and reduced ventricular compliance. The development of LVH maintains normal wall stress and a normal EF.
2. If the increase in wall thickness does not increase in proportion to the rise in intraventricular pressure, wall stress will increase and EF will fall. It is important to assess whether a reduced EF in patients with severe AS is the result of excessive afterload (i.e., inadequate hypertrophy to overcome the obstruction) or depressed contractility. If the latter is present, surgical risk is higher.
3. In patients with excessive and inappropriate degrees of LVH, wall stress is low and the heart will become hyperdynamic with a very high EF. This finding portends a worse prognosis after surgical correction.⁹²

B. Symptoms. Angina may result from the increased myocardial oxygen demand caused by increased wall stress, from reduction in blood supply per gram of hypertrophied tissue, and/or from limited coronary vasodilator reserve. Hypertrophied hearts are more sensitive to ischemic injury, and exercise may induce subendocardial ischemia, inducing systolic or diastolic dysfunction. Thus, angina may occur with or without concomitant epicardial CAD. Congestive heart failure results from elevation of filling pressures (LV end-diastolic pressure) with diastolic dysfunction and eventually by progressive decline in LV systolic function. Cardiac output is relatively fixed across the valve orifice and can lead to syncope in the face of peripheral vasodilation. The development of atrial fibrillation leads to clinical deterioration because the hypertrophied ventricle relies on atrial contraction to maintain a satisfactory stroke volume.

C. Diagnosis. The severity of AS can be readily diagnosed by either echocardiography or cardiac catheterization. In some patients with a critically narrowed valve, it may not be possible to cross the valve with a catheter to measure the gradient. In most cases, echocardiography should be sufficient in assessing the degree of AS, and because of the increased risk of embolic stroke during catheterization, hemodynamic assessment of AS during catheterization is not recommended (a class III recommendation) unless echo results are equivocal.⁹³ Coronary angiography is indicated before surgery to identify whether CAD is present.

1. Doppler echocardiography assesses the severity of aortic stenosis by measuring the maximum jet velocity and the mean transvalvular gradient, and allows for calculation of the aortic valve area using the continuity equation. Echo imaging can also measure the valve area directly by planimetry in the short-axis view (Table 1.1).

Table 1.1 • Correlation of Echocardiographic Measurements with the Severity of Aortic Stenosis			
Indicator	Mild	Moderate	Severe
Jet velocity (m/s)	< 3.0	3.0–4.0	> 4.0
Mean gradient (mm Hg)	< 25	25–40	> 40
Aortic valve area (cm ²)	> 1.5	1.0–1.5	< 1.0
Aortic valve area index (cm ² /m ²)			< 0.6
Dimensionless index			≤ 0.25

- At catheterization, the degree of valve stenosis (effective valve area) is assessed by a measurement of transvalvular flow (essentially the cardiac output or stroke volume) with a calculation of the peak or mean pressure gradient across the valve calculated from pressures obtained on a catheter pull-back from the left ventricle into the aorta (Figure 2.4, page 97). A valve area is calculated using the Gorlin formula:

$$AVA = \frac{CO / (SEP \times HR)}{44.3 \times \sqrt{\text{mean gradient}}}$$

where:

AVA = aortic valve area in cm² (normal = 2.5–3.5 cm²)

CO = cardiac output in mL/min

SEP = systolic ejection period/beat

HR = heart rate

Since the pressure gradient is related to both the orifice area and the transvalvular flow, low gradients may be noted in low cardiac output states despite severe AS; conversely, high gradients may be noted in high output states in the absence of severe AS. This concept may account for apparent inconsistencies in the degree of AS using different measurements and in different clinical states.

- Assessing the severity of aortic stenosis in a patient with a low gradient and poor ventricular function can be problematic. A patient may have a calculated valve area consistent with severe AS, although the degree of AS may not be significant. Dobutamine stress echocardiography (DSE) can be used in this circumstance to determine whether poor ventricular function with a low stroke volume is primarily related to afterload mismatch from true severe AS or is due to contractile dysfunction.
 - If dobutamine produces an increase in stroke volume and cardiac output with little increase in gradient, the valve area will increase, indicating that the severity of valve stenosis was overestimated and surgery is not indicated.
 - In contrast, if dobutamine increases both the stroke volume and the gradient, the valve area will remain the same, confirming that true aortic stenosis is present that will benefit from surgery.

- c. If dobutamine fails to produce an increase in stroke volume, the patient has poor contractile reserve and is a poor candidate for surgery.^{88,94,95} However, despite a high operative mortality, patients with poor contractile reserve (<20% increase in stroke volume with DSE) still have a better long-term prognosis with surgery than with medical management. In these patients, an alternative approach to aortic valve replacement (AVR), such as a transcatheter valve replacement, may be preferable.⁹⁵
- d. Interestingly, studies have suggested that an elevated B-type natriuretic peptide (BNP) level (>550) is a very strong predictor of operative mortality, even more important than contractile reserve documented by DSE.⁹⁶

D. Indications for surgery. The grading of indications for surgery and the levels of evidence for all types of valve surgery listed in the next few sections (see Appendix 1) are based on 2008 ACC guidelines⁸⁸ and are available at www.acc.org.

1. The presence of symptoms (angina, CHF, syncope or resuscitation from sudden death) with severe AS is a class I indication for surgery, because once symptoms are present, the average survival is only about 2 years with a less than 20% chance of surviving 5 years.^{88,97} Generally, mean survival is 1 year for patients with CHF, 2 years with syncope, and 4 years with angina.⁹⁷ Surgery will improve survival even in patients with LV dysfunction not caused by excessive afterload, although LV dysfunction and symptoms may not completely resolve.
2. In contrast, surgery has traditionally not been considered for the asymptomatic patient, no matter how severe the degree of stenosis, because the risk of sudden death is considered to be low (estimated at <1%/year), and the risk of the AVR may exceed the potential benefit of surgery.⁹⁸ However, patients with severe AS need to be followed carefully for the development of symptoms or rapidly progressive valve stenosis. Failure to perform surgery once patients become symptomatic is the most important risk factor for late mortality.⁹⁹
 - a. It is estimated that up to 40% of patients with severe AS will become symptomatic within 2 years and about 67% will be symptomatic by 5 years.^{100,101} However, in patients with high jet velocities, LV hypertrophy, or severe valve calcification, the rate of progression of valve stenosis is faster and the symptom-free interval is shorter.¹⁰¹
 - b. On the average, the annual increase in jet velocity is 0.3 m/sec, the increase in mean gradient is 7 mm, and the decrease in valve area is 0.1 cm². However, the rate of progression of AS can be quite variable, and serial Doppler echos should be used to assess the rate of hemodynamic progression of the AS, which is predictive of clinical outcome.
3. Indications for surgery in the asymptomatic patient are:
 - a. Class I: LV systolic dysfunction (EF <50%)
 - b. Class IIb
 - i. Abnormal response to exercise (hypotension, symptoms) – note that stress testing is contraindicated in the symptomatic patient with severe AS
 - ii. Severe AS with high likelihood of progression (elderly patients, calcified valve, presence of CAD) or if there will be a potential delay from symptom onset to surgery
 - iii. Extremely severe AS (AVA <0.6 cm², mean gradient >60 mm Hg, jet velocity >5.0 m/s)

4. AVR is generally indicated for patients undergoing other cardiac surgery if the AVA is $<1.2 \text{ cm}^2$, and possibly as high as 1.4 cm^2 . Invariably, a native valve with at least moderate stenosis will require surgery within a few years for progressive obstruction, thus mandating a reoperative procedure at higher risk. Clearly, it is essential that the prosthetic valve being placed have hemodynamics as good as and hopefully better than the valve being replaced. Nonetheless, one must remember that placing a prosthetic valve introduces at least a 1–2% annual risk for each of the prosthetic-related complications, including endocarditis, thromboembolism, and bleeding.
5. When indications for aortic valve surgery are met and an enlarged aorta $\geq 4.5 \text{ cm}$ is present, the ascending aorta should also be replaced. Although this is a standard criterion for bicuspid valves, it is not inappropriate for patients with trileaflet valves.

E. Preoperative considerations

1. Coronary angiography should be performed in any patient over the age of 40 or in a younger patient with coronary risk factors, angina, or a positive stress test.
2. Ischemic syndromes in patients with AS require judicious management. Medications that must be used very cautiously are those that can reduce preload (nitroglycerin), afterload (calcium channel blockers), or heart rate (β -blockers), because they may lower cardiac output and precipitate cardiac arrest in a patient with critical AS. The ventricular response to atrial fibrillation must be controlled, and cardioversion should be performed if this rhythm is poorly tolerated.
3. Dental work should be performed before surgery to minimize the risk of prosthetic valve endocarditis unless it is felt to be a prohibitive risk.
4. Selection of the appropriate procedure and valve type depends on a number of factors, including the patient's age, contraindications to long-term anticoagulation, and the patient's desire to avoid anticoagulation.

F. Surgical procedures

1. Aortic valve procedures may be performed through a full median sternotomy incision or through a minimally invasive incision. These include an upper or lower sternotomy with a "J" or "T" incision into the third or fourth intercostal space, or an anterior right second or third interspace incision.^{102,103} Cannulation for CPB for minimally invasive approaches can be performed either through the incision or using the femoral vessels.
2. Aortic valve replacement with either a tissue or mechanical valve is the standard treatment for AS (Figure 1.8).
 - a. In general, tissue valves are selected for patients >65 to avoid use of warfarin. Current-generation tissue valves have anticalcification treatment to reduce the risk of structural valve deterioration, and thus these valves are being used more commonly in younger patients.
 - b. A stentless valve may be selected to provide a larger effective orifice area and may be placed in the subcoronary position or as a root replacement.¹⁰⁴ Significant clinical benefits of this valve are controversial, and the operation is more complex (Figure 1.9).
 - c. The Ross procedure, in which the patient's own pulmonary valve is used to replace the aortic root, with the pulmonary valve replaced with a homograft

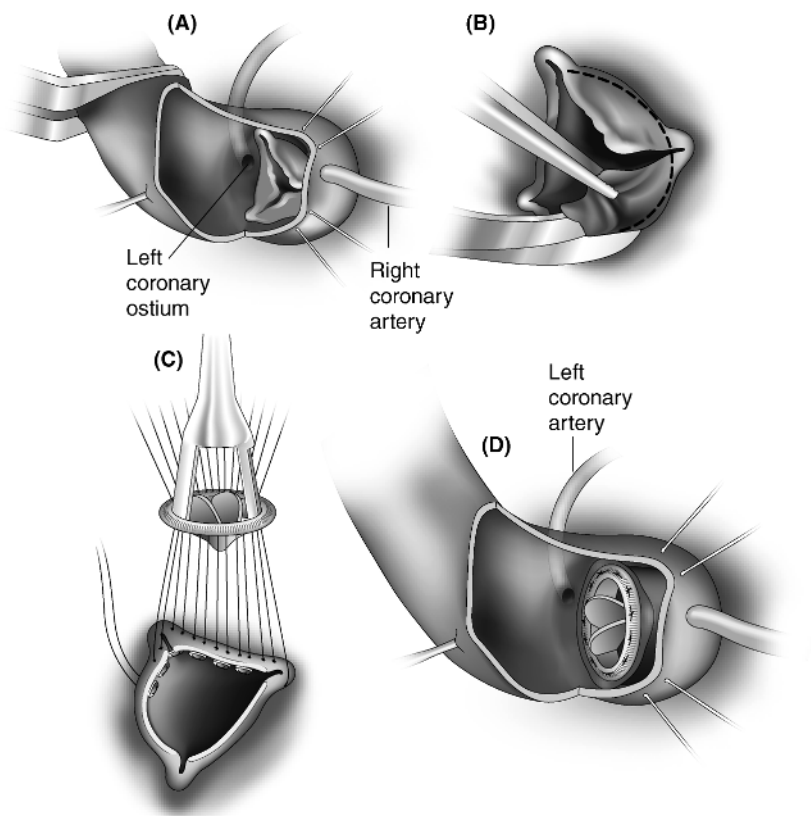


Figure 1.8 • Aortic valve replacement. (A) A transverse aortotomy incision is made and holding sutures are placed. (B) The valve is excised, and the annulus is debrided and sized. (C,D) Pledgeted mattress sutures are placed through the annulus and through the sewing ring of the valve, which is tied into position. The aortotomy is then closed.

(basically a double valve operation for single valve disease), is an even more complicated procedure generally reserved for patients younger than age 50 who wish to avoid anticoagulation (Figure 1.10).¹⁰⁵

- d. Homografts are usually reserved for patients with aortic valve endocarditis, although other types of prostheses arguably provide comparable results.^{106–109}
 - e. An aortic root replacement, usually as a valved conduit, is indicated when the ascending aorta must also be replaced (Figure 1.11).¹¹⁰ If the sinuses of Valsalva are not dilated, replacing the aortic valve and using a supracoronary graft simplifies the procedure.
3. Reparative procedures, such as commissurotomy or debridement, have little role in the management of critical aortic stenosis. However, debridement may be

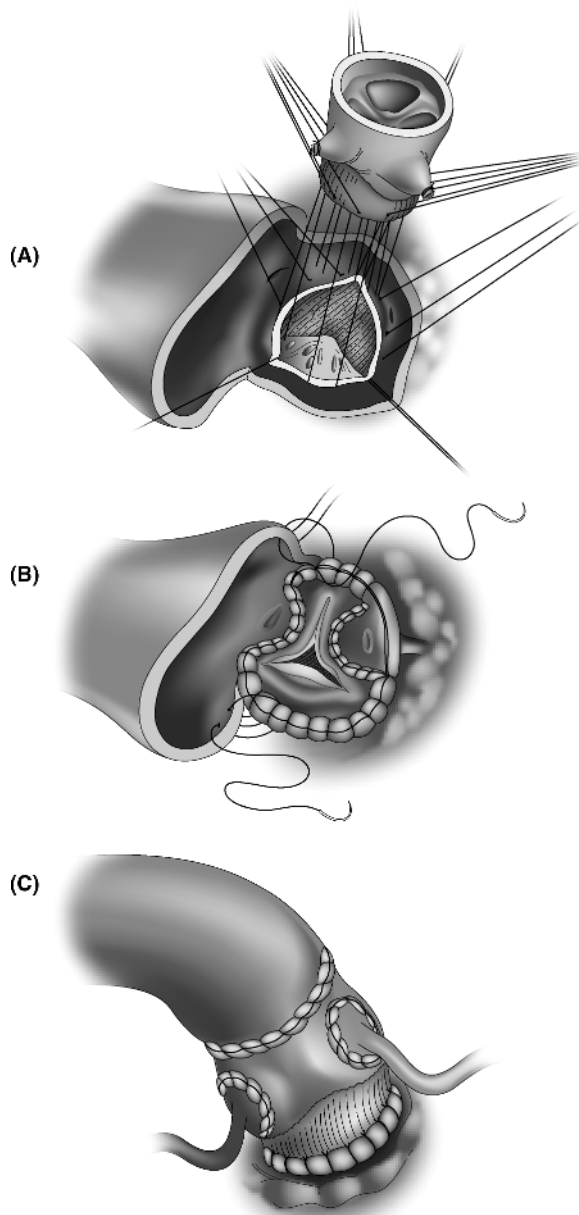


Figure 1.9 • Stentless valves have a larger effective orifice than stented valves, allowing for more regression of LV hypertrophy. (A) The proximal suture line sews the lower Dacron skirt of the prosthesis to the aortic annulus. (B) Subcoronary implantation of a Medtronic Freestyle valve. This requires scalloping of two sinuses with the distal suture line carried out below the coronary ostia. (C) A stentless valve can be used as a root replacement, requiring reimplantation of buttons of the coronary ostia. The distal suture line is an end-to-end anastomosis to the aortic wall.

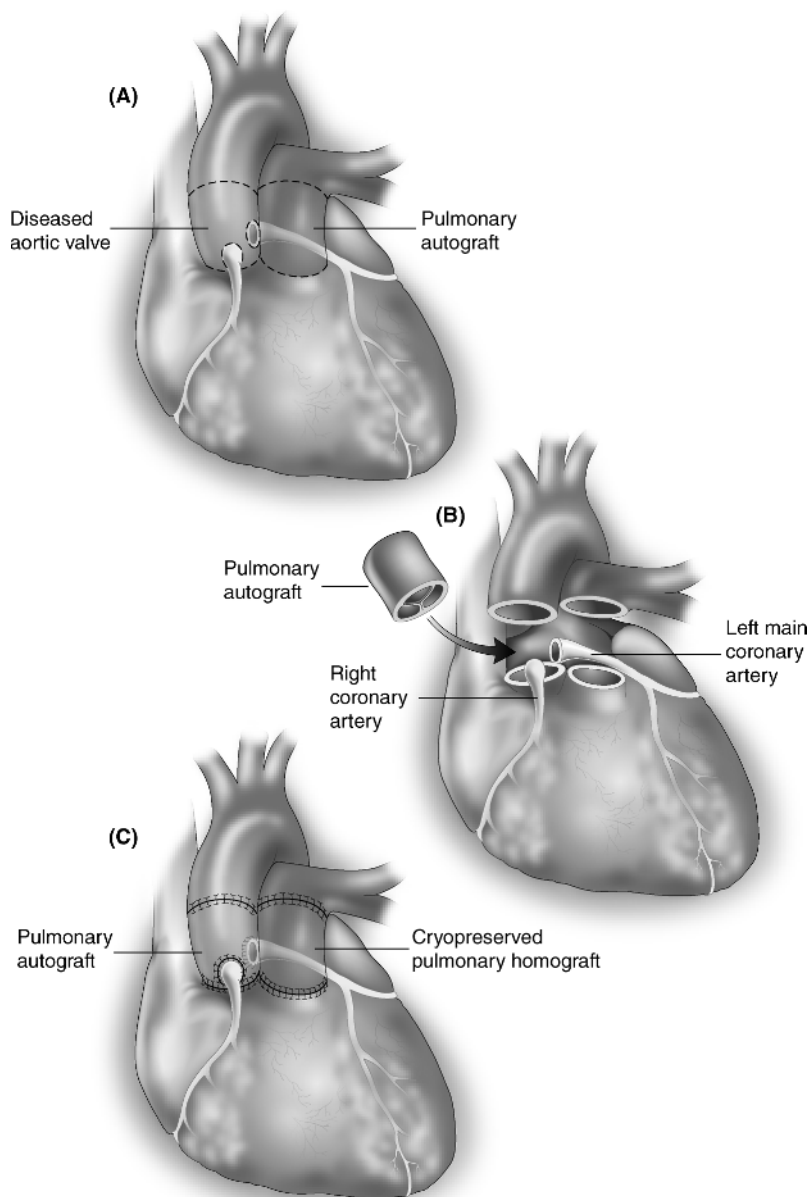


Figure 1.10 • Ross procedure. (A) The aorta is opened and the diseased aortic valve is removed. The pulmonic valve and main pulmonary artery are carefully excised and the coronary arteries are mobilized. (B) The pulmonary autograft is then transposed to the aortic root. (C) The coronary arteries are reimplanted and the RV outflow tract is reconstructed with a cryopreserved pulmonary valved homograft.

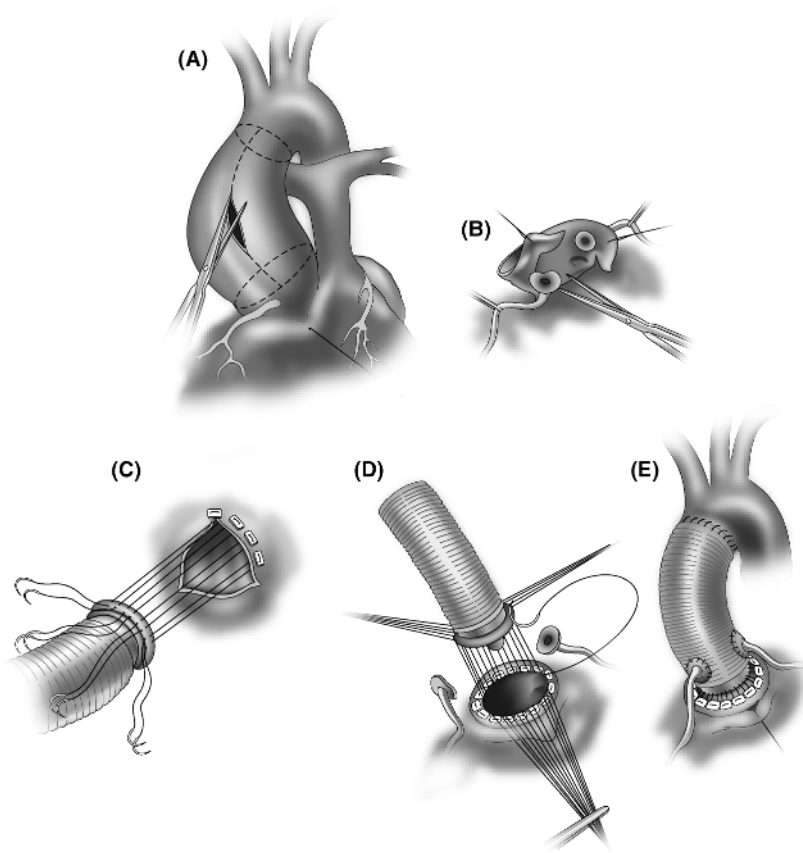


Figure 1.11 • Bentall procedure. (A) The aorta is opened longitudinally and then divided proximally and distally. (B) Coronary ostial buttons are mobilized. (C,D) A valve incorporated into the proximal end of the conduit is then sewn to the aortic annulus. (E) The coronary ostial buttons are reimplanted and the distal suture line is completed.

considered in the patient with moderate AS in whom the valve disease is not severe enough to warrant valve replacement, but in whom decalcification may delay surgery for a number of years.

4. Transcatheter aortic valve implantation (TAVI) involves placement in the aortic root of a tissue valve mounted on a catheter that is advanced either antegrade through the LV apex (via a left thoracotomy) or retrograde through the femoral vessels (Figure 1.12). Using rapid ventricular pacing, the device is positioned fluoroscopically at the level of the aortic annulus amidst the diseased valve and then inflated manually. Potential serious complications include migration, coronary obstruction, and stroke. Technical complications noted during apical implantation include acute aortic and mitral regurgitation, septal hematomas, and apical rupture. Early trials have limited inclusion criteria primarily to patients considered too high

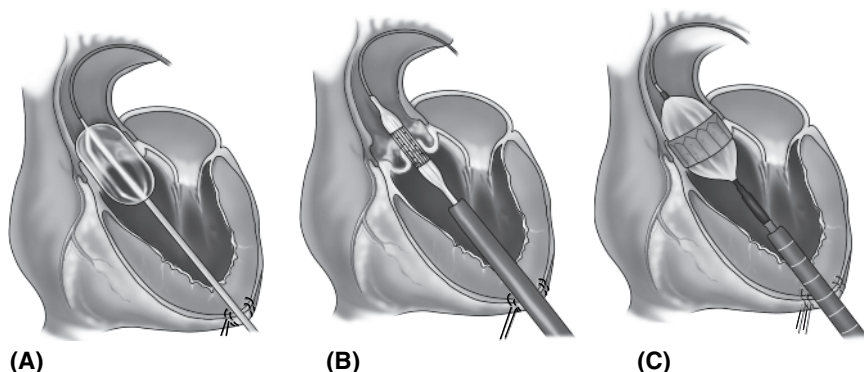


Figure 1.12 • Transcatheter aortic valve implantation (TAVI). (A) Using the transapical approach, a wire is placed through the aortic valve over which a balloon is used to dilate the valve. (B) Using fluoroscopic imaging, the catheter is positioned across the valve, and (C) the valve is inflated.

risk for surgery, with a resultant mortality rate consistently exceeding 10%. The role for transcatheter AVR in patients who are surgical candidates has yet to be defined.^{111–115} Matched for annular size, percutaneous valves have been shown to be superior in hemodynamic performance to both stented and stentless bioprosthetic valves.¹¹⁶

V. Aortic Regurgitation

A. Pathophysiology.⁸⁸ Aortic regurgitation (AR) results from abnormalities in the aortic valve leaflets (calcific degeneration, bicuspid valves, destruction from endocarditis) or from aortic root dilatation that prevents leaflet coaptation (idiopathic root dilatation causing annuloaortic ectasia, aortic dissection with cusp prolapse).

1. Acute AR usually results from endocarditis or a type A dissection. The ventricle is unable to dilate acutely to handle the sudden increase in regurgitant volume which increases the LV end-diastolic volume (LVEDV) and pressure (LVEDP), resulting in acute LV failure, cardiogenic shock, and pulmonary edema. Dramatic elevations in filling pressures may occur if acute AR is superimposed on a hypertrophic ventricle. Acute myocardial ischemia may result from increased afterload (LV dilatation), compensatory tachycardia, and a reduction in perfusion pressure as the LVEDP approaches the aortic diastolic pressure. As a result, sudden death may occur.
2. Chronic AR produces pressure and volume overload of the left ventricle, resulting in progressive LV dilatation (increase in LVEDV) with an increase in wall stress, an increase in ventricular compliance, and progressive hypertrophy. Most patients remain asymptomatic for decades, even with severe AR, because recruitment of preload reserve and compensatory hypertrophy maintain a normal EF despite the increased afterload. The increased stroke volume maintains forward output and is manifest by an increase in pulse pressure with bounding peripheral pulses. Eventually, increased afterload and impaired contractility lead to LV systolic dysfunction and a fall in EF. Usually at this point, the patient becomes symptomatic with

dyspnea, and impairment of coronary flow reserve may cause angina. The normalization of a depressed EF may occur after surgery when afterload excess is the cause of LV systolic dysfunction, but is less likely when it is caused by depressed myocardial contractility.

B. Diagnosis. Echocardiography and aortic root aortography at the time of catheterization can delineate the degree of AR (Figure 2.8, page 99). Echo is valuable in assessing the valve morphology, aortic root size, LV cavity dimensions, wall thickness, and systolic function. Color and pulsed wave Doppler findings can be used to assess the degree of AR.

C. Indications for surgery

1. **Symptomatic patients** with severe AR, irrespective of LV systolic function or LV size, should undergo surgery (class I). Without surgery, the estimated mortality rate is >10%/year for patients with angina and >20%/year for patients with CHF. Symptomatic patients with LV dysfunction and severely dilated hearts are considered high risk, because they often have irreversible myocardial damage.
2. Endocarditis with hemodynamic compromise, persistent bacteremia or sepsis, conduction abnormalities, recurrent systemic embolization from vegetations, large mobile vegetations, or annular abscess formation should prompt urgent surgery (see section IX, pages 39–41).
3. **Asymptomatic patients** must be followed closely for the development of symptoms or evidence of ventricular decompensation. Although the rate of progression to symptoms or LV dysfunction in asymptomatic patients with normal LV systolic function is only about 4%/year, about 25% of patients may develop LV dysfunction or die before they become symptomatic. Both medical survival and surgical operative and long-term survival are influenced significantly by impaired LV function. Thus, in asymptomatic patients, surgery is indicated at the earliest signs of LV decompensation:
 - a. Class I: EF <50% at rest. Symptoms develop in these patients at a rate of 25%/year.⁸⁸
 - b. Class IIa: EF >50% but severe LV dilatation (end-diastolic dimension >75 mm or end-systolic dimension >55 mm). These patients are at high risk for sudden death.
 - c. Class IIb: EF >50% with less severe LV dilatation (end-diastolic dimension >70 mm or end-systolic dimension >50 mm when there is evidence of progressive dilatation, declining exercise tolerance, or abnormal hemodynamic response to exercise).
4. In patients with severe AR from annuloaortic ectasia with an enlarged aortic root, it is recommended that the aorta be replaced if it exceeds 4.5 cm in diameter (and perhaps 4.0 cm in patients with Marfan syndrome).

D. Preoperative considerations

1. Systemic hypertension should be controlled with vasodilators to increase forward flow and reduce the degree of regurgitation. However, excessive afterload reduction may reduce diastolic coronary perfusion pressure and exacerbate ischemia. β -blockers for control of ischemia must be used cautiously because a slow heart rate increases the amount of regurgitation. They are contraindicated in acute AR because they will block the compensatory tachycardia.

2. Placement of an IABP for control of anginal symptoms is contraindicated.
3. As for all valve patients, dental work should be completed before surgery.
4. Contraindications to warfarin should be identified so that the appropriate valve can be selected.

E. Surgical procedures

1. Aortic valve replacement has traditionally been the procedure of choice for adults with AR. This may involve use of a tissue or mechanical valve, the Ross procedure, or a cryopreserved homograft.
2. Aortic valve repair, involving resection of portions of the valve leaflets and reapproximation to improve leaflet coaptation (especially for bicuspid valves), often with a suture annuloplasty, has been performed successfully. This is valuable in the younger patient in whom a valve-sparing procedure is preferable to valve replacement.¹¹⁷
3. A valved conduit (Bentall procedure) is placed if an ascending aortic aneurysm ("annuloaortic ectasia") is also present (Figure 1.11). In younger patients, manufactured mechanical valved conduits are preferable, but if there is a strong indication for avoiding anticoagulation, sewing a tissue valve into a graft can easily be accomplished.^{118,119} Alternatively, a Medtronic Freestyle stentless valve can be placed with distal graft extension to replace an aortic aneurysm.¹²⁰
4. Aortic valve-sparing root replacement is feasible in some patients with significant AR if adequate remodeling of the root can be accomplished, and it can be used successfully even in patients with bicuspid valves or Marfan syndrome (Figure 1.13).

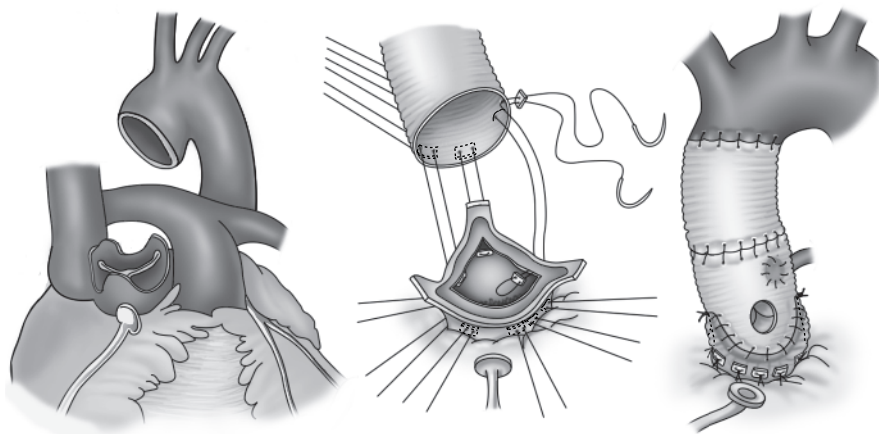


Figure 1.13 • Aortic valve-sparing root replacement. (A) The aortic root is resected, sparing the pillars that support the commissures and excising the coronary arteries as buttons. (B) Sutures are placed at the subannular level in a horizontal plane and passed through a tubular graft. (C) The graft is tied down and the aortic valve is reimplemented within the graft by elevating the commissural posts, suspending them from the graft, and sewing the aortic remnants to the graft. Finally, the coronary buttons are reimplemented.

The aorta is resected, sparing commissural pillars. A graft is then sewn at the subannular level, the aortic valve is resuspended within the graft, and the aortic remnants are sewn to the graft. Coronary ostial buttons are then sewn to the graft.^{121–123}

5. Transcatheter AVR is generally not applicable to cases of AR because the absence of calcification prevents adequate seating of the valve.

VI. Mitral Stenosis

- A. **Pathophysiology.**⁸⁸ Mitral stenosis (MS) occurs nearly exclusively as a consequence of rheumatic fever. Thickening of the valve leaflets with commissural fusion, and thickening and shortening of the chordae tendineae gradually reduce the size of the mitral valve orifice and the efficiency of LV filling. The increase in the diastolic transmitral gradient increases the left atrial and pulmonary venous pressures, leading to CHF. An adaptive measure that can minimize symptoms is a decrease in pulmonary microvascular permeability and the development of pulmonary arteriolar vasoconstriction and thickening, which leads to pulmonary hypertension (PH). This may then lead to right-sided heart failure and functional tricuspid regurgitation (TR). As the severity of MS and PH worsen, the cardiac output is compromised at rest and fails to increase with exercise. The development of atrial fibrillation further increases LA pressures, decreases ventricular filling, and compromises cardiac output.
- B. **Natural history.** MS is a slowly progressive process which may not produce symptoms for several decades. The minimally symptomatic patient has an 80% 10-year survival, but once the patient becomes significantly symptomatic, survival is very poor, with less than a 15% 10-year survival. Severe pulmonary hypertension (pulmonary artery [PA] pressure >60 mm Hg) is associated with an average survival of less than 3 years. Therefore, intervention should be considered when the patient develops class II–III symptoms.
- C. **Diagnosis.** The severity of MS can be determined by echocardiography or cardiac catheterization (Table 1.2). Echo is valuable in assessing the severity of MS by the continuity equation, estimating the PA pressure from the tricuspid velocity jet, and evaluating valve morphology using an echo score.¹²⁴ This assesses leaflet mobility, thickening, calcification, and subvalvular thickening and can be used to determine whether the valve is amenable to balloon valvuloplasty.

Table 1.2 • Measurement of the Severity of Mitral Stenosis

Indicator	Mild	Moderate	Severe
Mean gradient (mm Hg)	<5	5–10	>10
PA systolic pressure (mm Hg)	<30	30–50	>50
Mitral valve area (cm ²)	>1.5	1.0–1.5	<1.0

At catheterization, the mitral valve area is calculated from measurements of the cardiac output and the transvalvular mean gradient (pulmonary capillary wedge pressure [PCWP] minus the LV mean diastolic pressure). The PA pressure should be measured by right-heart catheterization.

$$MVA = \frac{CO / (DFP \times HR)}{37.7 \times \sqrt{\text{mean gradient}}}$$

where:

MVA = mitral valve area in cm^2 (normal = 4–6 cm^2)

DFP = diastolic filling period/beat

mean gradient = PCWP – left ventricular mean diastolic pressure

D. Indications for intervention

1. An interventional procedure is indicated for a patient in NYHA class III–IV with moderate or severe mitral stenosis ($MVA < 1.5 \text{ cm}^2$). It may also be considered for patients with class II symptoms when critical MS ($MVA < 1 \text{ cm}^2$) is present and for other patients with lesser degrees of MS when exercise testing precipitates significant hemodynamic changes.
2. **Percutaneous balloon mitral valvuloplasty (PBMV)** is the procedure of choice for patients with moderate-to-severe MS if valve morphology is favorable by echo score. This generally results in a doubling of the valve area and a 50% reduction in the mean gradient, with excellent long-term results. The presence of left atrial thrombus or more than 2+ MR usually contraindicates this procedure.
 - a. Class I: symptomatic class II–IV patients
 - b. Class IIa: symptomatic class III–IV patients with moderate or severe MS with nonpliable calcified valves who are not good surgical candidates
 - c. Class IIb
 - Symptomatic class II–IV patients with $MVA > 1.5 \text{ cm}^2$ but hemodynamically significant MS (PA > 60 mm Hg, PCWP > 25 mm Hg, or mean gradient > 15 mm Hg with exercise or dobutamine stress echo)
 - Asymptomatic patients with pulmonary hypertension (PA > 50 mm Hg at rest or > 60 mm Hg with exercise) or new-onset atrial fibrillation
3. **Surgery** is indicated when PBMV is contraindicated or not feasible due to unfavorable valve morphology, left atrial thrombus, or 3–4+ MR.
 - a. Class I
 - Symptomatic class III–IV patients with $MVA < 1.5 \text{ cm}^2$
 - Symptomatic patients with moderate-to-severe MS and moderate-to-severe MR
 - b. Class IIa: symptomatic class I–II patients with severe MS and PA > 60 mm Hg – surgery is generally indicated with these hemodynamics even if the patient is asymptomatic
 - c. Class IIb: asymptomatic patients with $MVA < 1.5 \text{ cm}^2$ with recurrent embolism on anticoagulation if valve repair can be performed

E. Preoperative considerations

1. Hemodynamic performance is frequently compromised by a low cardiac output state, which can be worsened by the presence of atrial fibrillation. A rapid

ventricular response will shorten the diastolic filling period, reduce LV preload, and elevate LA pressures. Thus, the ventricular response to AF is best controlled in the perioperative period by β -blockers or calcium channel blockers, although many patients are on digoxin for chronic rate control, which can be continued up to the time of surgery. There is usually a delicate balance between fluid overload, which can precipitate pulmonary edema, and hypovolemia from aggressive diuresis, which can compromise renal function when the cardiac output is marginal. Thus, preload must be adjusted judiciously to ensure adequate LV filling across the stenotic valve.

2. Many patients with long-standing MS are cachectic and at increased risk for developing respiratory failure. Aggressive preoperative diuresis and nutritional supplementation may reduce morbidity in the early postoperative period.
3. Warfarin used for AF, left atrial thrombus, or a history of systemic embolism should be stopped 4 days before surgery. If the patient is considered at high risk for embolization, outpatient low-molecular-weight heparin may be prescribed, but must be stopped at least 18–24 hours before surgery. Admission for unfractionated heparin the day before surgery may be considered once the international normalized ratio (INR) falls below the therapeutic range.

F. Surgical procedures

1. Closed mitral commissurotomy has been supplanted by PBMV, which produces superior results. Either should be considered in the pregnant patient with critical MS in whom CPB should be avoided.
2. Open mitral commissurotomy is performed if PBMV is not considered to be feasible or there is evidence of left atrial thrombus. It produces better hemodynamics than either a PBMV or a closed commissurotomy and is associated with improved long-term event-free survival, especially in patients with high echo scores or atrial fibrillation.¹²⁵ Although recurrent symptoms are noted in 60% of patients after 9 years, most symptoms are related to the development of MR or CAD, not to recurrent MS.⁸⁸
3. Mitral valve replacement (MVR) is indicated if the valve leaflets are calcified and fibrotic or there is significant subvalvular fusion (Figure 1.14).
4. A Maze procedure should be considered in a patient with either paroxysmal or persistent AF. The “cut and sew” Cox-Maze procedure has been replaced by use of energy sources (usually radiofrequency, cryoablation, or high-frequency ultrasound) that can be applied to create transmural ablation lines in well-described patterns to ablate this arrhythmia with fairly good success rates (see section XIII, pages 54–57).^{126–128}
5. Although functional TR usually improves after left-sided surgery, tricuspid valve repair is recommended for patients with significant TR. It has also been recommended for patients with significant RV dilatation with lesser degrees of TR, especially when the pulmonary vascular resistance (PVR) is elevated, AF is present, or the left atrium is significantly enlarged.^{129–131} However, although tricuspid valve repair may improve the functional outcome in patients with significant TR and may prevent the progression of TR in those with lesser degrees of TR, neither strategy may improve long-term survival.¹³²

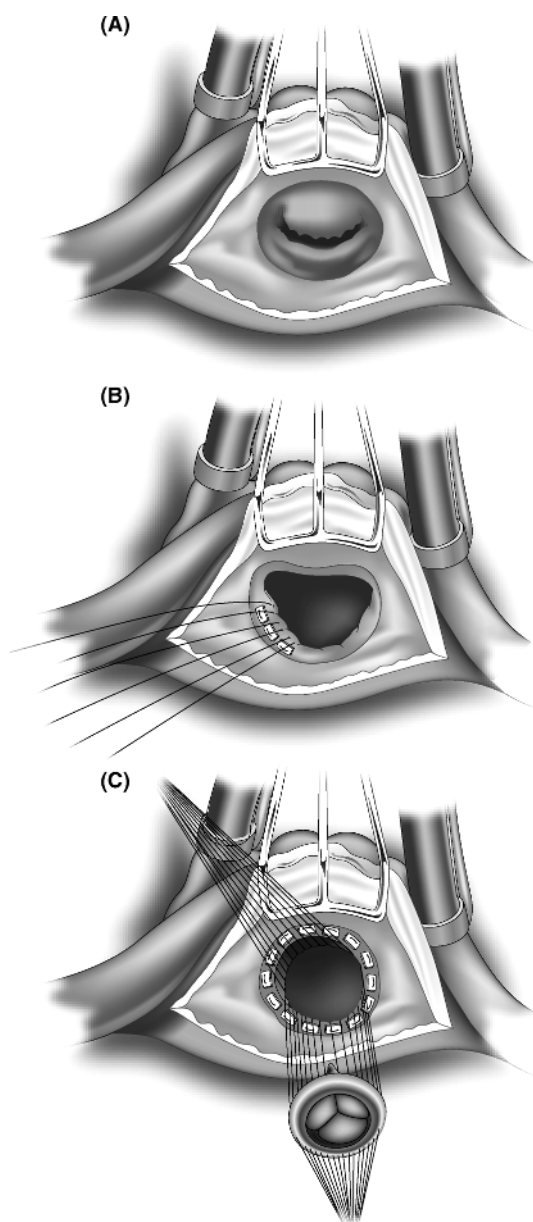


Figure 1.14 • Mitral valve replacement via the posterior approach. (A) The left atrium is opened behind the intraatrial groove and the retractor is positioned. Although both leaflets may be retained, the anterior leaflet is usually resected. (B) The posterior leaflet is retained and imbricated into the suture line. (C) Pledgeted mattress sutures are placed through the annulus, through or around the valve tissue, and into the sewing ring. The valve is then tied into position. The left atrial appendage may be oversewn from inside the left atrium.

VII. Mitral Regurgitation

A. Pathophysiology.^{88,133} Mitral regurgitation (MR) may result from abnormalities of the annulus (dilatation), valve leaflets (myxomatous change with redundancy and prolapse, leaflet defect or damage from endocarditis, leaflet shrinkage from rheumatic disease), chordae tendineae (rupture, elongation), or papillary muscles (rupture, ischemic dysfunction).

1. Acute MR usually results from myocardial ischemia or infarction with papillary muscle rupture, from endocarditis, or from idiopathic chordal rupture. Acute left ventricular volume overload develops with a reduction in forward output and regurgitant flow into a small noncompliant left atrium. This may result in both cardiogenic shock and acute pulmonary edema.
2. Chronic MR is a condition of volume overload that is characterized by a progressive increase in compliance of the left atrium and ventricle, followed by progressive increase in LVEDV as the LV dilates. The increase in preload increases overall stroke volume and maintains forward cardiac output. At the same time, there is a decrease in afterload due to ventricular unloading into the left atrium, so that a normal EF may be maintained despite contractile dysfunction. Patients are usually asymptomatic during this compensatory phase and may remain so even as ventricular decompensation occurs. Eventually, prolonged volume overload causes significant contractile dysfunction, more LV dilatation, an increase in end-systolic volume and elevated filling pressures. This reduces forward output and worsens symptoms of CHF. The progression of MR and assessment of LV dimensions and function should be followed by serial echocardiograms.
3. "Ischemic MR" may be acute or chronic. Acute MR may be the result of a mechanical complication, such as papillary muscle rupture, or it may be functional, due to ongoing ischemia. Chronic "ischemic MR" may develop following a myocardial infarction either from annular dilatation that prevents leaflet coaptation or from papillary muscle displacement from LV remodeling that produces apical tethering of the leaflets. The prognosis of ischemic MR is worse because the MR results from LV dysfunction, not from primary disease of the mitral valve or chordae tendineae.

B. Diagnostic evaluation

1. Left ventriculography may be used to assess LV function and the degree of MR, but it is frequently insensitive in assessing its severity, which may depend on catheter position, the amount and force of contrast injection, the size of the left atrium or ventricle, and the presence of arrhythmias or ischemia.
2. Transesophageal echocardiography (TEE) is the best technique to determine the degree and nature of the MR, and it also assesses the status of LV function and provides an estimate of PA pressures. It can define whether MR is functional on the basis of a dilated annulus or enlarged LV with apical tethering of the leaflets, or whether it is primarily from leaflet prolapse with chordal elongation or rupture. Generally, single-leaflet prolapse produces eccentric jets (Figure 2.16, page 109) whereas annular dilatation causes central MR. Apical tethering will also produce eccentric jets. TEE assessment is invaluable to the surgeon in helping to determine whether a valve can be repaired, what type of repair may be necessary, or whether replacement is indicated from the outset.

3. A discrepancy is often noted between the degree of MR identified preoperatively in the awake patient and that assessed under general anesthesia, which alters systemic resistance and loading conditions. Thus, a preoperative TEE is important to quantitate the degree of MR and define the precise anatomic mechanism for the MR.

C. Indications for surgery

1. Class I
 - Symptomatic acute MR (usually CHF or cardiogenic shock)
 - Symptomatic class II–IV patients with chronic severe MR as long as EF >30% and/or end-systolic dimension >55 mm
 - Acute endocarditis with hemodynamic compromise, persistent bacteremia or sepsis, annular abscess, recurrent systemic embolization from vegetations, or threatened embolization from large vegetations (Figure 2.17, page 110)
 - Asymptomatic patients with chronic severe MR and EF 30–60% and/or end-systolic dimension \geq 40 mm
2. Class IIa: patients with very advanced MR with class III–IV symptoms, EF <30%, and/or end-systolic dimension >55 mm if repair is highly likely.
3. Class IIb: asymptomatic patients with chronic severe MR and EF >60% with end-systolic dimension <40 mm (if repair likely), new onset of atrial fibrillation, or PA >50 mm Hg at rest or >60 mm Hg with exercise. In many experienced centers, repair is recommended in asymptomatic patients with severe MR and normal LV function to prevent the long-term sequelae of chronic MR.
4. Persistence of AF after mitral valve surgery alone is more likely when LA size exceeds 50 mm or AF has been present over 6 months. Because of the adverse influence of postoperative AF on outcome in patients with nonischemic MR (reduced survival, late cardiac function, and freedom from late stroke), a Maze procedure with obliteration of the left atrial appendage is recommended.^{134,135} It should also be considered in patients with AF and ischemic MR, primarily to reduce the risk of stroke. Reducing the size of a dilated left atrium may improve atrial mechanical function and improve the results of a Maze procedure.¹³⁶
5. In patients with CAD requiring CABG who also have concomitant MR, degenerative MR of grade 3–4+ should generally be repaired. Although ischemic MR may improve after myocardial revascularization, this is often unpredictable, and moderate-to-severe ischemic MR should be addressed by mitral repair or replacement. The effect of residual moderate MR on long-term survival is unclear, being comparable in some studies and worse in others.^{137,138}
6. In patients with concomitant severe AS and moderate MR, the severity of MR improves in about two-thirds of patients after AVR, with comparable survival to those in whom mitral valve repair is performed.¹³⁹ However, the likelihood of improvement is greater in patients with functional MR, a small left atrium, preoperative CHF, and AR as the indication for surgery.¹⁴⁰ If degenerative MR is present with single-leaflet prolapse and eccentric jets, it is unlikely that the MR will improve after relief of the outflow tract obstruction, and consideration should be given to repairing 2–3+ MR.

D. Preoperative considerations

1. Patients with acute MR are susceptible to pulmonary edema and multisystem organ failure from a reduced forward cardiac output. Use of inotropes, vasodilators, and an

IABP can transiently improve myocardial function and forward flow in anticipation of urgent cardiac catheterization and surgery. Intubation and mechanical ventilation are frequently required for progressive hypoxia or hypercarbia. Diuretics must be used judiciously to improve pulmonary edema while not creating prerenal azotemia. Some patients with chordal rupture who present with acute pulmonary edema may stabilize and develop chronic MR that can be treated electively.

2. Patients with chronic MR are managed with diuretics to reduce preload and with vasodilators, such as the ACE inhibitors, to improve forward flow. However, ACE inhibitors are only indicated if the patient is symptomatic and has hypertension or systolic dysfunction. ACE inhibitors should not be given the morning of surgery because of concerns about perioperative hypotension associated with their use.
3. Adequate preload must be maintained to ensure forward output while carefully monitoring the patient for evidence of CHF. Systemic hypertension should be avoided because it will increase the amount of regurgitant flow. If the patient has ischemic MR or a borderline cardiac output, use of systemic vasodilators or an IABP generally improves forward flow.

E. Surgical procedures

1. Mitral valve reconstruction is applicable to more than 90% of patients with degenerative MR, although success rates are greater for posterior than anterior leaflet repairs. Techniques include annuloplasty rings, leaflet repairs, and chordal transfers and replacement (Figure 1.15).^{141,142} These reparative techniques can also be applied to patients with mitral valve endocarditis.^{143–145} Mitral valve repair gives a survival advantage over mitral valve replacement in patients with degenerative MR and coexisting CAD,¹⁴⁶ but advantages of repair over replacement for ischemic MR are not as well defined.^{147,148} Thus, the decision to repair or replace a valve for ischemic MR can be difficult and depends on an understanding of the pathophysiology of the MR and patient-related factors.
2. Mitral valve replacement (MVR) is indicated when satisfactory repair cannot be accomplished. Acute MR from papillary muscle rupture usually requires MVR. Chordal preservation of at least the posterior leaflet should be considered for all MVRs performed for MR. This improves ventricular function and will minimize the risk of LV rupture.
3. Traditional mitral valve operations have been performed through a median sternotomy incision. Other “minimal access” approaches, such as an upper sternotomy incision (using the “superior” approach to the valve between the aorta and superior vena cava), a right parasternal incision (using the biatrial transseptal approach), or a right anterolateral thoracotomy or lower sternotomy incision (using the posterior approach behind the interatrial septum) can also be considered. CPB can be established either directly through the chest or through the femoral vessels. Minimally invasive video-assisted surgery has seen increasing applicability in patients undergoing mitral valve repairs and replacements, whereas a robotic approach has been limited primarily to patients undergoing mitral valve repairs.^{149–152}
4. A concomitant Maze procedure should be performed in patients with either paroxysmal or persistent AF.
5. Functional TR should be managed as noted on page 31 above.

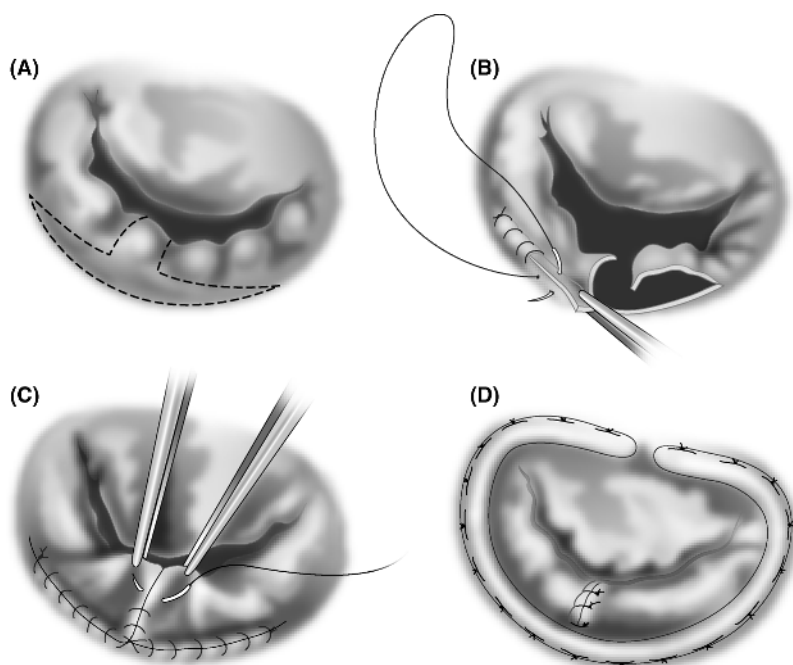


Figure 1.15 • Mitral valve repair. The most common pathology involves a flail posterior mitral leaflet. (A) A quadrangular excision is made as indicated by the dotted lines and the flail segment is resected. The remaining leaflet tissue may be incised along the annulus. (B) It is then advanced and reattached to the annulus ("sliding plasty"). (C) The leaflet tissue is then approximated, and (D) an annuloplasty ring is placed.

VIII. Tricuspid Valve Disease

- A. Pathophysiology.**¹⁵³ Tricuspid stenosis (TS) is very rare, usually developing as a result of rheumatic heart disease in association with mitral stenosis. Tricuspid regurgitation (TR) most commonly is "functional" in nature, occurring as a consequence of advanced mitral valve disease which leads to pulmonary hypertension, RV dilatation, and tricuspid annular dilatation. RV systolic dysfunction contributes to elevated right atrial and systemic venous pressures, producing signs of right-sided heart failure. Atrial fibrillation is common. Forward output may also be reduced, resulting in fatigue and a low output state. Other common causes of TR include endocarditis (usually with intravenous drug abuse, an indwelling pacemaker wire, or hemodialysis catheter) and pulmonary hypertension, independent of etiology.
- B. Diagnosis.** Clinical examination in TR will reveal a systolic murmur that increases with inspiration, prominent jugular venous pulsations, and occasionally a pulsatile liver. The diagnosis is confirmed by echocardiography, which can assess the tricuspid valve anatomy, the severity of TR, RV size and function, provide estimates of PA and RV pressures, and identify associated contributing pathology.

C. Indications for surgery

1. Tricuspid stenosis. Surgery is indicated for class III–IV symptoms, including hepatic congestion, ascites, and peripheral edema that are refractory to salt restriction and diuretics.
2. Tricuspid regurgitation
 - a. Class I: TV repair is indicated when severe TR is present with mitral valve disease requiring mitral valve surgery.
 - b. Class IIa: TV repair (annuloplasty) or replacement (if leaflets not amenable to repair) is reasonable for symptomatic, severe primary TR. Note that the surgical risk is high in the presence of severe pulmonary hypertension (PA systolic > 60 mm Hg) in the absence of left-sided valve disease, especially if RV dysfunction is present.
 - c. Class IIb: TV annuloplasty is reasonable if less than severe TR is noted at the time of mitral valve surgery, but pulmonary hypertension or a dilated tricuspid annulus is present. These patients may subsequently develop RV dysfunction and worsening TR, although the impact on long-term clinical outcome is not clear.^{129–132}
 - d. Persistent sepsis or recurrent pulmonary embolization from tricuspid valve vegetations is an indication for surgery.
 - e. Class III: surgery should not be considered in asymptomatic patients with a PA pressure < 60 mm Hg and no mitral valve disease.

D. Preoperative considerations

1. Passive congestion of the liver resulting from elevated right-heart pressures frequently leads to coagulation abnormalities, which should be treated aggressively before and during surgery. Frequently, these patients have uncorrectable INRs before surgery.
2. Salt restriction and diuretics may improve hepatic function, but significant improvement in liver function tests may not be possible until after surgery.
3. Maintenance of an elevated central venous pressure is essential to achieve satisfactory forward flow. A normal sinus mechanism provides better hemodynamics than atrial fibrillation, although the latter is frequently present. Slower heart rates are preferable for TS, and faster heart rates for TR.

E. Surgical procedures

1. Tricuspid commissurotomy can be performed for rheumatic TS.
2. Tricuspid annuloplasty with a ring (Carpentier) or suture technique (DeVega or bicuspidization) is feasible and preferred for the majority of patients with annular dilatation and functional TR (Figure 1.16).¹⁵⁴
3. Tricuspid valve replacement (TVR) is necessary when leaflet shrinkage and poor coaptation prevent an annuloplasty technique from eliminating the TR. There is no particular preference for valve selection. Tissue valves have a lower risk of thromboembolism than mechanical valves when placed in the right heart, and valve survival may be better due to lower stress on the valve leaflets. Tissue valves may also be preferable because long-term survival after TVR is somewhat limited, most likely because it reflects more advanced multivalvular disease. The overall mortality rate for TVR is consistently about 20%, because most patients are in a higher functional class and have pulmonary hypertension.^{155–158}

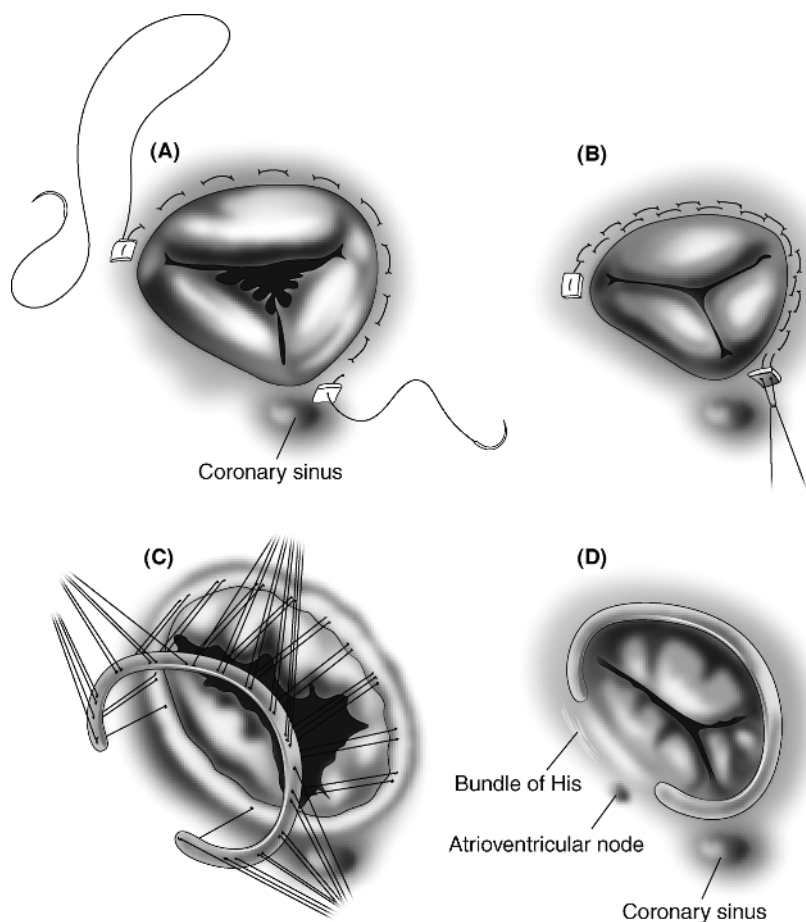


Figure 1.16 • Tricuspid valve repair involves reduction of annular dilatation to correct functional tricuspid regurgitation. (A,B) The circumferential suturing technique (DeVega repair). (C,D) Placement of an annuloplasty ring. Note the location of the coronary sinus and the proximity of the conduction system to the repair.

4. Due to the necessity of placing sutures near the conduction system, patients are more prone to developing heart block after tricuspid valve surgery. If there are concerns that permanent pacing may be required, epicardial pacing leads should be placed on the right ventricle, pacing and sensing thresholds are determined, and the pacing leads are buried in a subcutaneous pocket for later attachment to a permanent pacemaker. In one report, more than 20% of patients required postoperative permanent pacemakers.¹⁵⁹
5. The management of tricuspid valve endocarditis is noted in the next section.

IX. Endocarditis

A. Pathophysiology. Endocarditis can result in the destruction of valve leaflets, invasion of surrounding myocardial tissue, systemic embolization of valve vegetations, or persistent systemic sepsis. Embolization is more likely with mitral than aortic valve involvement, staphylococcal organisms, and large or mobile vegetations. Native valve endocarditis is most commonly caused by *Streptococcus viridans*, *Staphylococcus aureus*, or coagulase-negative staph. Tricuspid valve endocarditis is usually caused by intravenous drug abuse, although the left-sided valves are actually more commonly involved with IV drug abusers.¹⁶⁰ The incidence of prosthetic valve endocarditis (PVE) is approximately 0.5–1% per patient-year for most mechanical and tissue valves. It is most commonly caused by staph organisms.

B. Indications for surgery in native valve endocarditis⁸⁸

1. Class I indications include:
 - a. Presence of moderate-to-severe CHF from regurgitant lesions. Surgery should not be delayed if cardiogenic shock is present unless the likelihood of recovery from complications (severe stroke) is remote.
 - b. Hemodynamically significant regurgitant lesions (elevated LVEDP or LA pressures or moderate-to-severe pulmonary hypertension)
 - c. Evidence of local extension resulting in aortic or annular abscesses (usually manifest by heart block) or destructive lesions (intracardiac fistulas, mitral leaflet perforation from aortic valve endocarditis)
 - d. Organisms unlikely to be adequately treated with antibiotics alone, especially fungal endocarditis
 - e. Persistent sepsis or bacteremia despite antibiotics for more than 1 week, especially with staph infections. This is commonly noted with the above two indications and should be considered an indication for proceeding with urgent surgery, although not listed as an indication in the ACC guidelines. Surgery during septic shock portends a very poor prognosis with an operative mortality rate exceeding 50%.¹⁶¹
2. Class IIa: recurrent embolization and persistent vegetations despite antibiotic treatment. Note that the incidence of embolization decreases significantly once antibiotic therapy has been initiated, but evidence of increasing vegetation size on antibiotics may predict later embolization.^{162,163}
3. Class IIb: mobile vegetations >10 mm in diameter even in the absence of documented embolization. These vegetations, especially on the mitral valve, have an increased risk of embolization.

C. Indications for surgery in prosthetic valve endocarditis (PVE)¹⁶⁴

1. Class I
 - a. Heart failure
 - b. Valve dehiscence (unstable prosthesis or perivalvular leak)
 - c. Evidence of increasing valvular obstruction or worsening regurgitation
 - d. Complications, such as abscess formation or heart block
 - e. Fungal etiology
2. Class IIa
 - a. Persistent bacteremia or recurrent emboli despite antibiotics
 - b. Relapsing infection

D. Preoperative considerations

1. TEE is the gold standard for the identification of endocarditis and is more sensitive and specific than transthoracic echocardiography in identifying and quantifying the size and mobility of vegetations, detecting annular destruction, and identifying valvular abnormalities (Figure 2.17, page 110).
2. Ideally, the patient should receive a 6-week course of antibiotics prior to surgery to reduce the risk of PVE, because the risk of prosthetic valve endocarditis is lowered from about 10% to 2% once a successful course of antibiotics has been completed. However, hemodynamic deterioration and intracardiac invasion are compelling indications that mandate earlier surgery. Attempts should be made to optimize hemodynamic and renal status before operation, but surgery should not be delayed if there is evidence of progressive organ system deterioration.
3. Appropriate timing of surgery in patients suffering cerebral embolization is controversial. Some reports suggest that the risk of exacerbating a cerebral insult is greatest if surgery is performed within 2–3 weeks of the embolic event, primarily from cerebral edema rather than from hemorrhage.^{165,166} However, others suggest that earlier surgery can be performed safely and should be considered within several days to prevent recurrent embolization from persistent vegetations, as long as an immediate preoperative CT scan shows no hemorrhage.^{167–169} In these situations, the benefit of surgery usually exceeds the risk. However, in patients with a hemorrhagic stroke, the risk of early surgery is high and it should be delayed at least 3–4 weeks, if possible.
4. The appropriate antibiotics should be given for a total perioperative course of 6 weeks. However, if intraoperative cultures are positive, 6 weeks of postoperative antibiotics are generally recommended.
5. Patients with aortic valve endocarditis may have evidence of heart block from involvement of the conduction system by periannular infection. This may require preoperative placement of a transvenous pacing wire.
6. Coronary angiography should be avoided, if possible, if mobile aortic valve vegetations are identified.

E. Surgical procedures

1. Surgery entails excision of all infected valve tissue, drainage and debridement of abscess cavities, and repair or replacement of the damaged valves. An aortic valve homograft is arguably the valve of choice because of its increased resistance to infection and adaptability to disrupted tissue in the aortic root.¹⁰⁶ However, homograft replacement is technically quite complex and the operative mortality may be greater when performed by surgeons without extensive experience with these conduits. Aortic valve replacement with either mechanical or tissue valves is a satisfactory alternative.^{108,109} The risk of prosthetic valve endocarditis on tissue or mechanical valves is fairly comparable.¹⁶⁴
2. Mitral endocarditis can frequently be repaired, especially if leaflet perforation is the primary pathology, and there are proponents of earlier surgery in mitral valve endocarditis to preserve the patient's native valve.^{143–145} More advanced stages of endocarditis usually require valve replacement.
3. Tricuspid valve repair is recommended for tricuspid endocarditis and should be attempted aggressively in intravenous drug abusers, who are more prone to reinfection if a valve replacement is performed.^{160,170,171} If repair cannot be accomplished, tricuspid valvectomy can be performed in patients without

pulmonary hypertension with few adverse hemodynamic sequelae.¹⁷² Otherwise, a tricuspid valve should be placed, accepting the higher risk of recurrence in IV drug abusers.

X. Hypertrophic Obstructive Cardiomyopathy

A. Pathophysiology. Hypertrophic obstructive cardiomyopathy (HOCM) is characterized by diastolic dysfunction and varying degrees of dynamic left ventricular outflow tract obstruction. The latter most commonly results from hypertrophy of the basal septum with mitral–septal apposition from systolic anterior motion of the mitral valve (SAM). This also contributes to mitral regurgitation from incomplete leaflet apposition. An anomalous papillary muscle insertion into the leaflets can also cause mitral regurgitation and may contribute to midcavity obstruction, especially with excessive midventricular hypertrophy. Four different clinical patterns may be noted and they dictate how HOCM should be managed.^{173–175}

1. Patients generally become symptomatic with congestive heart failure, which is related to both **diastolic dysfunction** and **outflow tract obstruction**. The latter is most predictive of a worse prognosis. Angina may develop because of abnormal coronary microvasculature and inadequate capillary density for the degree of hypertrophy. Syncope may also occur.
2. The risk of **sudden death** is estimated at 1%/year, but is increased in patients with any of the following major risk factors: a history of cardiac arrest, sustained ventricular tachycardia (VT) or repetitive prolonged bursts of nonsustained VT, a family history of premature HOCM-related death, unexplained syncope, a hypotensive blood pressure response to exercise, or extreme LVH with wall thickness over 30 mm.
3. Advanced heart failure may develop with remodeling and **systolic dysfunction** that may require heart transplantation.
4. **Atrial fibrillation** may develop due to left atrial enlargement in 20–25% of patients and may contribute to an embolic stroke.

B. Indications and options for intervention¹⁷⁴

1. No pharmacologic regimen has been shown conclusively to reduce the risk of sudden death. Therefore, medications are used to alleviate symptoms, which are usually related to diastolic heart failure. β -blockers or verapamil can be recommended to patients with or without obstruction. Disopyramide can be added when there is significant outflow tract obstruction as it will decrease SAM and the outflow gradient.
2. ICD placement should be considered in patients at high risk for sudden death (as noted above).¹⁷⁶
3. Dual-chamber pacing with a short atrioventricular delay to ensure complete ventricular-paced activation is effective in reducing the gradient by approximately 35% and in improving symptoms.¹⁷⁷ Biventricular pacing has been found beneficial in a few reports of patients with either intraventricular conduction delay or normal conduction.^{178,179}
4. Further intervention is indicated in patients with a peak gradient >50 mm Hg and persistent symptoms despite medications. It may also be considered in asymptomatic patients considered at high risk for sudden death, including younger patients and those with a peak gradient >80 mm Hg.

5. Alcohol septal ablation of the upper septal perforator branch of the LAD produces an infarct of the upper septum. This should reduce basal septal thickness, enlarging the LV outflow tract and reducing SAM in appropriately selected patients. It has been shown to produce a substantial reduction in gradient with improvement in symptoms and exercise tolerance. Potential complications include need for a permanent pacemaker in about 10% of patients (up to 40% at 3 years) and the potential creation of an arrhythmogenic focus.^{180,181} Comparative studies of alcohol ablation and myectomy have shown comparable clinical improvement, but a lower gradient and less requirement for pacing with a myectomy.¹⁸¹

C. Preoperative considerations

1. Measures that produce hypovolemia or vasodilation must be avoided because they increase the outflow tract gradient. Volume infusions should be used to maintain preload with the use of α -agonists to maintain systemic resistance.
2. Use of β -blockers and calcium channel blockers to reduce heart rate and contractility are the mainstay of medical management of HOCM and should be continued up to the time of surgery.

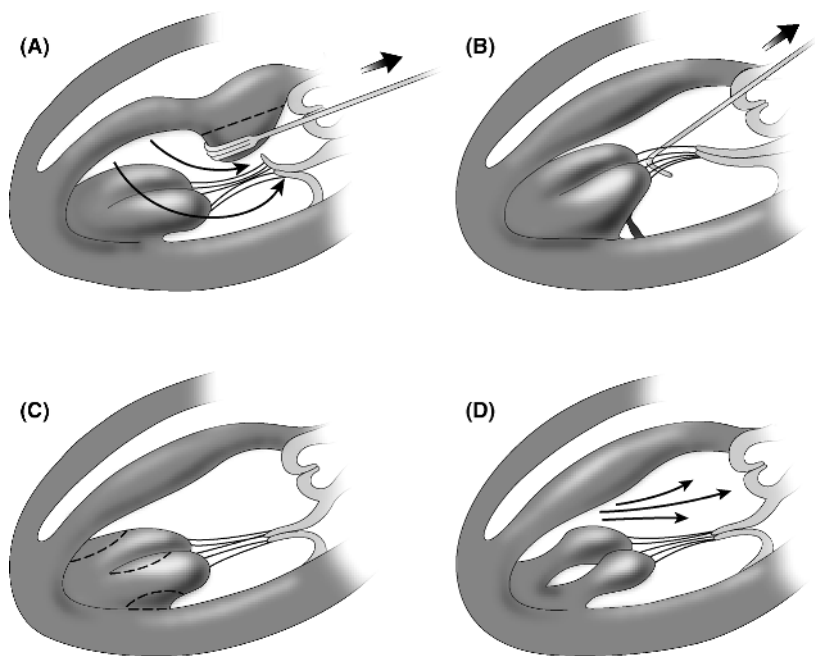


Figure 1.17 • (A) Hypertrophic obstructive cardiomyopathy is characterized by septal hypertrophy which orients the outflow jet into the anterior leaflet of the mitral valve, producing systolic anterior motion (SAM). An extensive septal myectomy is performed, often requiring a mid-ventricular resection. (B,C) Using a nerve hook to provide traction, the atypical attachments of hypertrophied anomalous papillary muscles are partially detached from the ventricular wall and trimmed. (D) After this procedure, the outflow jet is directed more anteriorly.

D. Surgical procedures

1. The traditional surgical approach of a left ventricular septal myectomy entailed resection of a 1.5×4 cm wedge of septum below the right coronary aortic leaflet through an aortotomy incision.
2. With further understanding of the mechanism of SAM, the current operation is more elaborate and involves performing an extended septal myectomy to the base of the papillary muscles, mobilization and partial excision of the papillary muscles off the ventricular wall to allow the papillary muscles to assume a more posterior position in the left ventricle, and anterior mitral leaflet plication if there is any redundancy. This reduces chordal and leaflet slack that can produce SAM (Figure 1.17). Resection of midventricular obstruction or anomalous chords and relief of papillary muscle fusion may be necessary. A successful operation dramatically reduces the gradient, eliminates mitral regurgitation, improves functional status, and may reduce the risk of sudden death.^{182–186}
3. Mitral valve replacement is indicated if the septal thickness is less than 18 mm, or if there is atypical septal morphology, significant MR, or failure of the other procedures to relieve the outflow tract gradient.

XI. Aortic Dissections

A. Pathophysiology. An aortic dissection results from an intimal tear that allows passage of blood into the media, creating a false channel. This channel is contained externally by the outer medial and adventitial layers of the aorta. With each cardiac contraction, the dissected channel can extend proximally or distally, potentially causing branch artery compromise or rupture as the outer wall weakens. Dissections involving the ascending aorta are classified as Stanford type A (DeBakey type I–II, or proximal), whereas those not involving the ascending aorta are called Stanford type B (DeBakey type III, or distal) dissections (Figure 1.18). The dissection is termed acute when it is diagnosed within 2 weeks of its onset; otherwise, it is termed chronic.^{187,188}

B. Presentation

1. **Type A dissection.** This is a life-threatening condition that must be considered in any patient presenting to the emergency room with the acute onset of chest pain. Failure to be aware of the various presentations of type A dissections has led to a misdiagnosis in up to 40% of patients.¹⁸⁹
 - a. The traditional notion is that patients develop tearing, ripping chest pain that radiates to the back, but this has been found to be less common than non-radiating sharp chest pain according to contemporary analyses published by the International Registry of Acute Aortic Dissections (IRAD).^{190,191} Two key elements to the pain are that it is invariably acute in onset and severe in nature – usually the worst pain the patient has ever experienced. The pain is associated with the tearing of the aortic wall and its extension; it often abates and may wax and wane – this may be deceptive to the clinician if this fact is not appreciated.
 - b. Depending on the location of the intimal tear and the extent of the dissection, potential complications include cardiac tamponade from hemopericardium (the most common cause of death), aortic regurgitation, myocardial infarction,

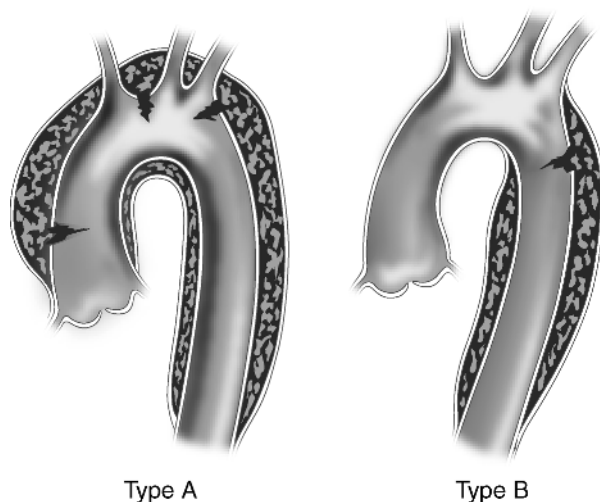


Figure 1.18 • Classification of aortic dissection. Type A dissections involve the ascending aorta. Type B dissections usually originate distal to the left subclavian artery and do not involve the ascending aorta. If they do extend retrograde, they are then considered type A dissections.

stroke, and branch artery compromise causing malperfusion. The latter may involve the brachiocephalic vessels, causing syncope, a stroke, or a discrepancy in upper-extremity blood pressures; the intercostal vessels, causing paraplegia; the mesenteric or renal vessels, compromising blood flow to the bowel or the kidneys; or the iliofemoral vessels, reducing distal blood flow to the legs.

- c. An elevation in D-dimer levels is usually, but not always, noted in acute dissections and may be useful in supporting suspicion of the diagnosis.^{192,193} Another biomarker that is being studied is smooth muscle myosin heavy chain protein that is released from damaged aortic medial smooth muscle.

2. **Type B dissection.** This usually presents with back pain that may radiate into the abdomen. It generally does not cause anterior chest wall pain since the ascending aorta is not involved. Potential rupture into the mediastinum, pleural spaces or abdomen may occur. Malperfusion from branch artery compromise from the descending thoracic and abdominal aorta may occur as noted above.

C. Indications for surgery

1. **Type A dissection.** Surgery is indicated for all patients unless it is considered to carry a prohibitive risk because of patient age, overall medical condition and comorbidities, or the development of extensive renal, myocardial, or bowel infarction or massive stroke. In selected cases of mesenteric malperfusion, fenestration and stenting may be indicated prior to surgical repair of the site of the dissection.^{194,195} Surgery is also indicated for virtually all patients with chronic type A dissections.
2. **Type B dissections.** Patients with uncomplicated type B dissections are usually treated medically. Interventional (endovascular) or surgical procedures are

reserved for patients with complicated dissections, i.e., persistent pain, uncontrollable hypertension, evidence of aneurysmal expansion or rupture, or visceral, renal, or lower-extremity vascular compromise.^{196,197} The long-term prognosis of medically treated dissections is not ideal and is influenced by the potential for subsequent aneurysmal expansion.¹⁹⁸ This is more likely if the patient's heart rate and blood pressure are not well controlled, the false lumen remains patent, or the initial false lumen diameter is $>40\text{--}45\text{ mm}$.^{199–202} Because of this concern, studies are being done to assess whether low-risk patients with uncomplicated type B dissections might benefit from surgery or endovascular stenting to prevent subsequent expansion and improve long-term survival. Chronic type B dissections should be operated upon when they reach 6–6.5 cm in diameter.

D. Preoperative considerations and diagnostic testing

1. Upon suspicion of the diagnosis, all patients must be treated pharmacologically to reduce the blood pressure (to about 110 mm Hg systolic), the heart rate (to 60–70 bpm), and the force of cardiac ejection (dp/dt). The patient should be carefully monitored and must undergo diagnostic testing as soon as possible to establish or exclude the diagnosis.
2. Recommended antihypertensive regimens include a β -blocker (esmolol, metoprolol, or labetalol) with or without addition of sodium nitroprusside (see Table 11.8, page 497, for doses). Aggressive management up to the time of surgery is essential to prevent rupture.
3. A careful pulse examination may indicate the extent of the dissection. Particular attention should be paid to the carotid, radial, and femoral pulses. Differential upper-extremity blood pressures in a young patient with chest pain is a strong clue to the presence of a dissection. Cardiac evaluation may reveal the presence of an aortic regurgitation murmur.
4. A detailed preoperative neurologic examination is essential because a deficit recognized postoperatively may have been present at the time of presentation. A change in neurologic status may indicate progressive compromise of cerebral perfusion that can resolve with emergency surgery. However, cerebral malperfusion during CPB may also cause a significant cerebral insult. Evidence of renal dysfunction (rising BUN or creatinine, oliguria) or bowel ischemia (abdominal pain, acidosis) may necessitate modification of the surgical approach. Recurrent chest or back pain usually indicates extension, expansion, or rupture of the dissection.
5. The chest x-ray will usually demonstrate either a widened mediastinum or irregularity of the aortic contour, but may be normal in 10–15% of patients with type A dissections.¹⁹⁰
6. In a patient with severe chest pain, one might suspect that an abnormal ECG would be more consistent with an acute coronary syndrome, and a normal ECG would suggest the diagnosis of dissection. However, IRAD data showed that only 33% of patients with type A dissections had a normal ECG.¹⁹⁰ Nonspecific ST changes were noted in about 40% of patients and about 20% had ischemic changes, possibly related to coronary ostial involvement with the dissection.

7. Dissections can be diagnosed by a variety of techniques.
 - a. In most hospitals, a CT scan **with contrast** is performed first. It has about 90% sensitivity and specificity in identifying intimal flaps and differential flow into true and false lumens (Figure 2.23, page 117). 64-slice CT scanning, especially with three-dimensional reconstruction, can provide beautiful images of aortic dissections (Figure 2.24, page 118) and can demonstrate branch artery compromise as well.
 - b. TEE is the best procedure for identifying intimal flaps, evidence of tamponade, and aortic regurgitation (Figure 2.18, page 111). If the diagnosis of a type A dissection is unequivocal on CT scanning, TEE is best deferred until the patient is anesthetized. If the diagnosis is in doubt, TEE should be performed **very cautiously** because sedation may lead to hypotension in a patient with a pericardial effusion, and acute hypertension in an inadequately sedated patient could precipitate rupture. A transthoracic echo may be valuable in ruling out a significant pericardial effusion before proceeding with a TEE.
 - c. Magnetic resonance imaging (MRI) may be the most sensitive and specific diagnostic technique to identify a dissection, but only rarely can it be obtained on an emergency basis (Figure 2.27, page 121). Furthermore, there are usually limitations to its performance in a patient requiring careful monitoring and intravenous drug infusions.
 - d. There is little role for aortography in the evaluation of an acute dissection; branch vessel perfusion in the abdomen can be identified by CT angiography.
 - e. Coronary angiography is usually not indicated in cases of acute aortic dissection because of the necessity of urgent surgical repair. Evidence of significant ECG changes may lead to coronary angiography as the initial diagnostic test, only to find that coronary ostial compromise is caused by an aortic dissection. In contrast, coronary angiography is helpful in planning surgical strategy in patients with chronic dissections.

E. Surgical procedures

1. Type A dissections

- a. Repair involves resuspension or replacement of the aortic valve (if AR is present), resection of the intimal tear, and placement of an interposition graft to reapproximate the aortic wall (Figure 1.19). Biologic glue (preferably BioGlue) can be used to improve tissue integrity for grafting. If the root is destroyed and cannot be reconstructed, a Bentall procedure (valved conduit) is performed. If the tear extends across the arch, consideration should be given to replacing the entire arch, often with an elephant trunk, using standard techniques of cerebral perfusion to protect the brain.²⁰³ Patients with visceral malperfusion have a high mortality rate and may benefit from a fenestration procedure prior to repair of the ascending aorta.²⁰⁴ Iliofemoral malperfusion may require additional revascularization procedures after the ascending aorta is replaced.
- b. Repair of any type A dissection should be performed during a period of deep hypothermic circulatory arrest (DHCA) (see page 52).
- c. The complex situation of the type A dissection with a tear in the descending aorta can be managed by an initial repair via a median sternotomy, leaving an

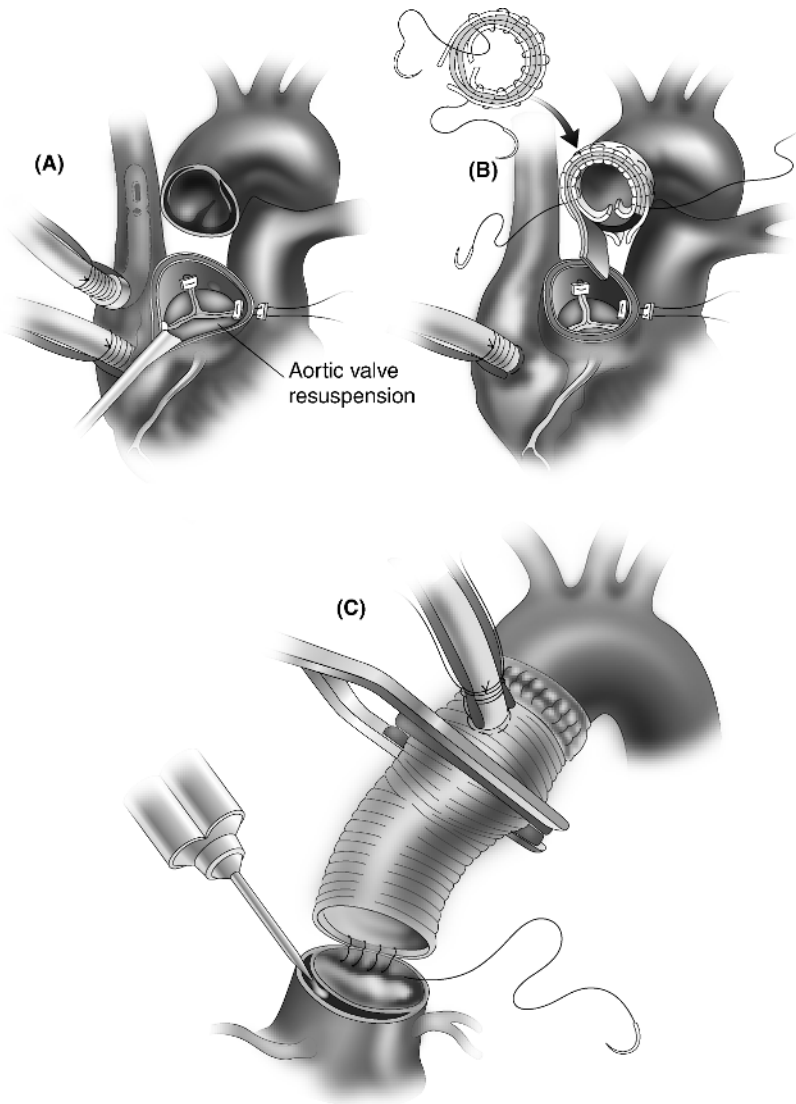


Figure 1.19 • Repair of a type A aortic dissection. (A) During circulatory arrest without aortic cross-clamping, the aorta is opened and the entry site is resected. The aortic valve is resuspended. (B) The proximal and distal suture lines are fragile and are reinforced. Two felt strips are shown for the distal suture line, being placed inside the true lumen and outside the adventitia. (C) After the distal suture line is completed, the graft is cannulated to reestablish antegrade cardiopulmonary bypass flow with proximal application of a cross-clamp. BioGlue may be injected to stabilize the distal and proximal (shown here) suture lines, and the proximal graft anastomosis is performed, again using felt reinforcement.

elephant trunk for repair of the descending aorta. Alternatively, an endovascular stent can be placed through the arch into the descending aorta.^{205,206} A retrograde dissection occurring after placement of an endovascular stent for a type B dissection is a difficult problem that usually requires open surgery through a sternotomy.²⁰⁷

2. Type B dissections

- a. The traditional surgical approach to complicated type B dissections involves resection of the intimal tear and interposition graft replacement to reapproximate the aortic wall. The risk of paraplegia is greater than in patients with atherosclerotic aneurysms because less collateral flow is present. Thus, measures to reduce spinal cord ischemia by maintaining distal perfusion should be taken (see page 53). Visceral malperfusion may improve with restoration of flow into the true lumen. Otherwise a percutaneous fenestration procedure to produce a communication between the true and false lumens or additional grafting may be necessary to improve organ system or distal limb perfusion.²⁰⁸
- b. Due to the substantial morbidity and mortality associated with surgical repair, endovascular stenting is becoming increasingly popular.^{209–211} This procedure should seal the entry site to allow for thrombosis of the false lumen. It has been used primarily in complicated type B dissections, as it is not yet clear whether endografting for uncomplicated type B dissections will provide superior results to medical management. Additional fenestration and stenting may be required if reconstitution of true channel flow does not correct malperfusion.

XII. Thoracic Aortic Aneurysms

A. Pathophysiology. Ascending aortic (AAo) aneurysms usually result from medial degeneration or atherosclerosis, whereas those in the distal arch, descending thoracic, and thoracoabdominal aorta are generally atherosclerotic in nature. Aneurysms in any location may result from expansion of chronic dissections. Although progressive enlargement may result in compression of adjacent structures, most deaths result from aneurysm rupture or dissection. Natural history studies have been used to correlate aneurysm size with the risk of rupture or dissection in an attempt to provide objective data on when surgery should be performed.²¹²

B. Indications for surgery

1. Ascending aortic aneurysms

- a. Symptomatic, expanding, or ≥ 5.5 cm without Marfan syndrome.²¹² These recommendations are based on natural history studies that suggest that the risk of rupture or dissection is $<5\%$ /year for an aortic diameter <6 cm and 16–34% once the aorta reaches 6 cm.²¹² Although the Society of Thoracic Surgeons (STS) consensus document noted that 15% of aortas that dissect in patients with bicuspid valves or Marfan syndrome are <5 cm in size, other reports (including one IRAD study) indicate that 60% of aortic dissections occur in aortas that measure <5.5 cm and 40% occur when the aorta is <5 cm.^{213–215} Although studies have correlated initial aortic size with the risk of rupture or dissection (Figure 1.20), it has been proposed that indexing the aortic size to the patient's size rather than using aortic size alone may provide better guidelines for resection (Figure 1.21).²¹⁵ The risk is low for an aortic size

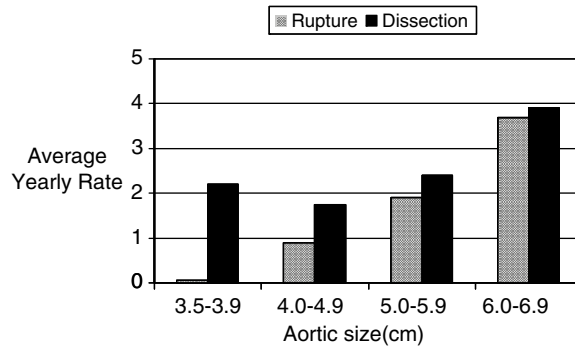


Figure 1.20 • Risk of aortic dissection or rupture based on the initial aortic size. (Adapted with permission from Davies et al., *Ann Thorac Surg* 2002;73:17–27.)

index (ASI) $<2.75 \text{ cm/m}^2$, moderate for an ASI of $2.75\text{--}4.25 \text{ cm/m}^2$, and significant once the ASI exceeds 4.25 cm/m^2 .

- b. Aneurysms $\geq 5 \text{ cm}$ in patients with bicuspid aortic valves
- c. Aneurysms $\geq 4.5 \text{ cm}$ if an operation is indicated for aortic stenosis or regurgitation. One study showed that the risk of developing an aortic dissection following AVR was more than 25% if the aortic size exceeds 5 cm at the time of AVR, but current recommendations are to replace an aorta $\geq 4.5 \text{ cm}$, probably for both bicuspid and trileaflet valves.²¹⁶
- d. Aneurysms $\geq 4.5 \text{ cm}$ in Marfan syndrome
- e. Virtually all acute type A dissections (as noted above)
- f. Mycotic aneurysms

2. Transverse arch aneurysms

- a. Ascending aortic aneurysms that require replacement that also extend into the arch. It should be noted that the “aortopathy” associated with bicuspid valves tends to involve the arch in 75% of patients in whom hemiarch or arch replacement should be performed.²¹⁷
- b. Acute arch dissections with intimal tear in the arch or evidence of arch expansion or rupture
- c. Aneurysms $\geq 5\text{--}6 \text{ cm}$ in diameter

3. Descending thoracic (DAo) and thoracoabdominal aneurysms (see Figure 1.22 for classification)

- a. Symptomatic aneurysms
- b. Aneurysms $\geq 6.5 \text{ cm}$ in diameter (atherosclerotic or chronic dissections)
- c. Complicated acute type B dissections (uncomplicated if low risk patient)

C. Preoperative considerations

1. Coronary angiography is required before surgery for ascending aortic and proximal arch aneurysms (not acute dissections). If significant coronary disease is present, it is bypassed at the time of the aneurysm resection.
2. Myocardial perfusion stress imaging (dipyridamole–thallium or sestamibi) is indicated in patients with descending thoracic aneurysms because of the

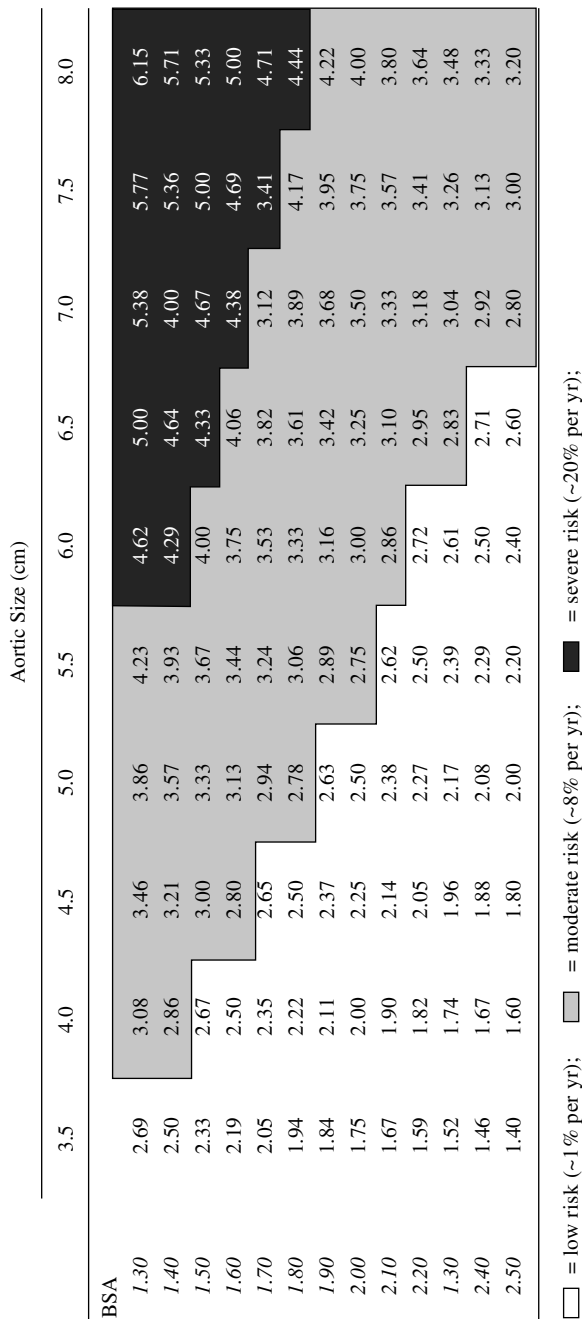


Figure 1.21 • Risk of aortic complications (dissection, rupture, and death) correlating the patient's body surface area and the aortic size in cm measured by CT scan. The values within the chart reflect the aortic size index (ASI). The risk is moderate with an ASI > 2.75 cm/m² and significant once the ASI exceeds 4.25 cm/m². BSA, body surface area. (Reproduced with permission from Davies et al., *Ann Thorac Surg* 2006;81:169–77.)

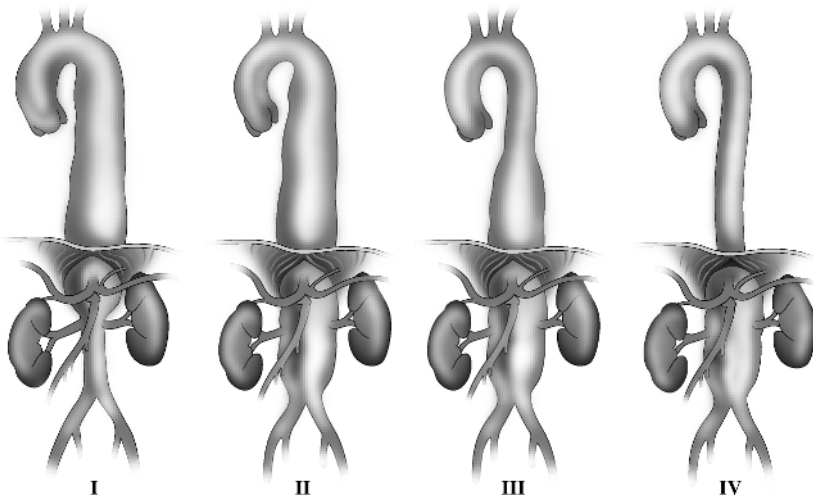


Figure 1.22 • Crawford classification of thoracoabdominal aneurysms.

likelihood of coexistent CAD. If the scan is positive, coronary angiography should be performed. The presence of significant coronary disease usually warrants some form of intervention (PCI or CABG) to reduce the risk of cardiac complications associated with repair of the aneurysm.

3. A careful preoperative baseline neurologic evaluation is important because of the risks associated with circulatory arrest (stroke, seizures) and aortic cross-clamping (paraplegia). A detailed informed-consent discussion with the patient about these devastating complications is essential and must be documented.
4. An assessment of aortoiliac disease is essential prior to any endovascular stenting procedure. Severe stenosis, tortuosity, or extensive atherosclerotic disease may necessitate an alternative site for arterial access or may lead to abandonment of the proposed procedure.
5. Pulmonary status must be optimized prior to surgery. Many patients with aneurysmal disease have concomitant chronic obstructive pulmonary disease, and the use of a thoracotomy incision, lung manipulation during surgery, anticoagulation, and multiple blood transfusions may have a detrimental effect on pulmonary function.
6. Renal function must be monitored carefully after angiography, especially in diabetic patients. The creatinine should be allowed to return to baseline before surgery to reduce the risk of renal dysfunction associated with aortic cross-clamping.

D. Surgical procedures

1. Ascending aortic aneurysms

- a. Supracoronary interposition graft placement is performed if the aneurysm develops above the sinotubular junction, thus sparing the segment from which the coronary arteries arise.

- b. If the sinuses are aneurysmal, they should be resected and replaced. Most commonly a valved conduit (Bentall procedure) is placed (Figure 1.11).^{110,218} However, an aortic valve-sparing operation can be performed even if aortic regurgitation is present, and is applicable to patients with Marfan syndrome or bicuspid valves (Figure 1.13).^{121–123,219–221} The design of this procedure depends on the extent of the aneurysm and the pathophysiology of aortic regurgitation.
- c. CPB is required for repair of AAO aneurysms. Depending on the site of the distal anastomosis, simple aortic cross-clamping or a period of DHCA may be necessary. Arterial access for CPB can be achieved through the femoral artery or the axillary artery if significant descending aortic atherosclerosis is present.²²²
- d. For DHCA, the central core temperature should be lowered to 18 °C, at which time there is presumed to be electroencephalographic silence. This should provide 45–60 minutes of safe arrest with minimal risk of neurologic insult. Adjuncts to improve cerebral protection during a period of DHCA include methylprednisolone 30 mg/kg, packing the head in ice, and either continuous retrograde cerebral perfusion (RCP) through the superior vena cava (SVC) or preferably antegrade cerebral perfusion (ACP) directly or through the axillary artery.^{223,224} With the latter approach, the operation can be done at moderate systemic hypothermia.²²⁵

2. Transverse arch aneurysms²²⁶

- a. Hemiarch repair using DHCA with RCP or ACP is performed if the ascending aorta and proximal arch are involved. A graft is sewn to the undersurface of the arch leaving the brachiocephalic vessels attached to the native aorta.
- b. Extended arch repair involves placement of an interposition graft sewn to the proximal descending aorta and reimplantation of a brachiocephalic island during a period of circulatory arrest. Alternatively, a debranching operation with use of individual trifurcation grafts to the arch vessels may be performed. This should reduce the duration of DHCA and improve cerebral protection, potentially reducing neurologic morbidity (Figure 1.23).^{226,227}
- c. Distal arch repair can be performed via a left thoracotomy without cardiopulmonary bypass. Use of CPB and a period of DHCA through either a sternotomy or thoracotomy incision may be useful when clamping is not feasible for the proximal anastomosis or for more complex operations. Several creative operations for distal arch aneurysms have been described, such as open transaortic stent endografting of distal arch aneurysms with carotid artery bypass.²²⁸
- d. If it is anticipated that a descending aortic repair may be necessary in the future, a piece of graft material is left dangling from the distal anastomosis and can be retrieved at a subsequent operation through the left chest (the “elephant trunk” procedure).²²⁹

3. Descending thoracic aorta

- a. Graft replacement of the diseased aorta is performed with reimplantation of intercostal vessels at the level of T8–T12 for more extensive aneurysms. This is performed through a left thoracotomy or thoracoabdominal incision with use of one-lung anesthesia.

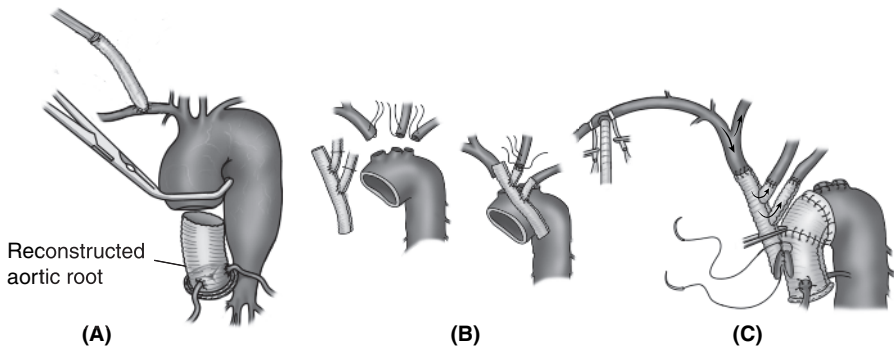


Figure 1.23 • Aortic arch replacement using a trifurcation graft (TC). (A) Using axillary cannulation for CPB, the aorta is clamped and the proximal root reconstruction is performed. (B) During DHCA, the arch vessels are divided 1 cm from their origins, and individual anastomoses are sequentially performed to the arch vessels with side limbs off the trifurcation graft. (C) Flow is then restored to the brain with a clamp on the proximal segment of the trifurcation graft. The distal arch anastomosis is constructed and the two aortic grafts are reapproximated. Finally, the trifurcation graft is sewn to the proximal portion of the aortic graft.

- b. Consideration should be given to the use of adjuncts (medications, cerebrospinal fluid [CSF] drainage, shunting) to prevent spinal cord ischemia during the period of aortic cross-clamping, which may reduce the risk of paraplegia to less than 5%.^{230,231} Shunting can be accomplished by draining blood from a site proximal to the aortic cross-clamp (inferior pulmonary vein/left atrium/proximal aorta) and returning it distally (distal aorta/femoral artery) to perfuse the spinal cord and kidneys. A BioMedicus centrifugal pump, which actively returns blood to the patient at a designated rate, can be used with or without oxygenation. Left-heart bypass alone has been shown to reduce the incidence of paraplegia during surgery for thoracoabdominal aneurysms, but not necessarily more limited descending thoracic aneurysms.^{232,233}
- c. Femoro-femoral bypass can be used to provide distal protection. It can also be used along with DHCA when clamping is not possible due to extensive disease or calcification. This technique also provides visceral and spinal cord protection.^{234–236}
- d. Arterial monitoring lines are inserted in the right radial and femoral arteries to monitor proximal and distal pressures during the period of aortic cross-clamping, especially if left-heart bypass is used.
- e. Because of the inherent risk of descending aortic clamping, thoracic endovascular aortic repair (TEVAR) has become popularized for the treatment of descending thoracic and thoracoabdominal aneurysms. This may reduce the risk of early death and postoperative complications, including paraplegia, acute kidney injury, bleeding, pneumonia, and cardiac morbidity.^{212,237–239}

XIII. Atrial Fibrillation

A. Pathophysiology

1. Atrial fibrillation (AF) results from the presence of multiple reentrant circuits that prevent the synchronous activation of adequate atrial tissue to generate mechanical contraction. It is perpetuated by the variable refractoriness of atrial tissue to the generation of these circuits. Atrial distention may predispose to this arrhythmia, which then promotes progressive atrial dilatation and remodeling, leading to permanent AF. Atrial fibrillation can lead to:
 - a. Loss of atrioventricular (AV) synchrony, which reduces ventricular filling and stroke volume. This can produce dizziness, fatigue, and shortness of breath, especially in hypertrophied hearts and when the ventricular rate is high.
 - b. Thrombus formation in the left atrium with a predisposition to thromboembolism and stroke
 - c. Symptoms of an irregular heartbeat (palpitations)
 - d. A cardiomyopathy if the rate is not controlled
2. Atrial fibrillation may occur as an isolated entity ("lone AF") in patients with no structural heart disease or in patients with underlying heart disease. It is more common in patients with hypertension and valvular heart disease. It is categorized as paroxysmal (recurrent AF that terminates spontaneously within 7 days), persistent (lasts >7 days and responds to cardioversion), or long-standing persistent or permanent (fails to respond to medications or cardioversion and lasts over 1 year). In paroxysmal AF, the atrial foci that serve as the trigger are usually located in the tissue surrounding the pulmonary veins as they enter the left atrium. The reentrant circuits in patients with persistent AF usually originate in the left atrium.

B. Management considerations and indications for surgery

1. AF is managed with medications to control the ventricular rate (β -blockers, calcium channel blockers, digoxin) and prevent thromboembolism (warfarin). When the rate cannot be controlled, symptoms are disabling, thromboembolism occurs on anticoagulation, or anticoagulation cannot be tolerated or is not desirable, an ablative procedure should be considered.
2. In the absence of the above indications, surgery for AF is generally not indicated. However, with the use of thoracoscopic approaches and advances in catheter ablation technology, the indications have been liberalized to include patients with lone AF. Transcatheter ablations are very successful in ablating paroxysmal AF arising from pulmonary veins, and with adequate mapping, reasonable success (about 60%) can be achieved in patients with persistent AF.
3. The ability to restore sinus rhythm with an ablative procedure during concomitant cardiac surgery improves long-term survival and may also improve cardiac function and reduce the incidence of stroke.^{134,135,240} Therefore, it is strongly recommended during mitral valve surgery, and can be considered in patients undergoing other types of cardiac surgery.
4. Medications used for rate control or for AF prophylaxis should be continued up to the time of surgery. Because reversion to sinus rhythm may not occur immediately after surgery, these medications are generally continued afterwards.

C. Surgical procedures²⁴¹

1. In 1986, Cox designed a technically complex “cut-and-sew” operation called the “Maze” procedure that was designed to ablate AF, restore AV synchrony, and preserve atrial transport function. This was subsequently redesigned as the Cox-Maze III operation, in which the incisions not only interrupted the microreentrant circuits, but also allowed the sinus node to function, and directed propagation of the sinus impulse through both atria. Atrial fibrillation was eliminated in about 90% of patients, but about 10% of patients still required pacemakers.
2. Various ablation technologies have now been developed to mimic the suture lines of the Cox-Maze III operation, the best of which appear to be cryoablation, radiofrequency, and high-frequency ultrasound (HIFU). To achieve success, the lesions created must achieve transmural. Since the left atrium is usually the primary focus of reentry, a left-sided Maze is most commonly performed.
3. The basic operation involves bilateral pulmonary vein isolation with obliteration of the left atrial appendage. This can be performed epicardially and thus is amenable to bilateral thoracoscopic approaches. It is only applicable with good success to patients with paroxysmal AF.²⁴² However, an additional ablation line that mimics the mitral isthmus lesion of a left atrial Maze procedure can be performed epicardially across the left atrial dome from the left fibrous trigone at the mitral valve annulus to the base of the noncoronary cusp of the aortic valve (Figure 1.24). This should improve the success rate in patients with persistent AF.^{243,244}
4. A left-sided Maze operation is usually performed in conjunction with mitral valve surgery (Figure 1.25). This procedure produces ablation lines that encircle and connect the right and left pulmonary veins (“box lesion”), and one that

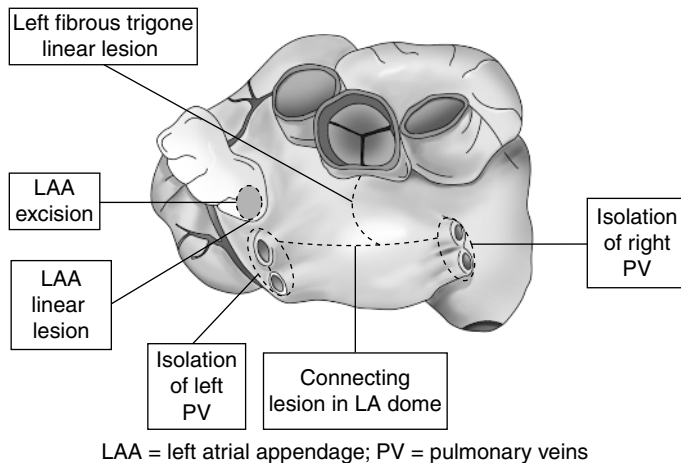


Figure 1.24 • Epicardial lesion set for thoracoscopic approaches to atrial fibrillation. Bilateral pulmonary vein isolation and a connecting lesion between the right- and left-sided pulmonary veins are performed. In addition, a linear lesion over the dome of the left atrium is created extending from the left fibrous trigone at the anterior mitral valve annulus to the base of the junction of the left and noncoronary cusps to mimic the mitral isthmus lesion performed endocardially.

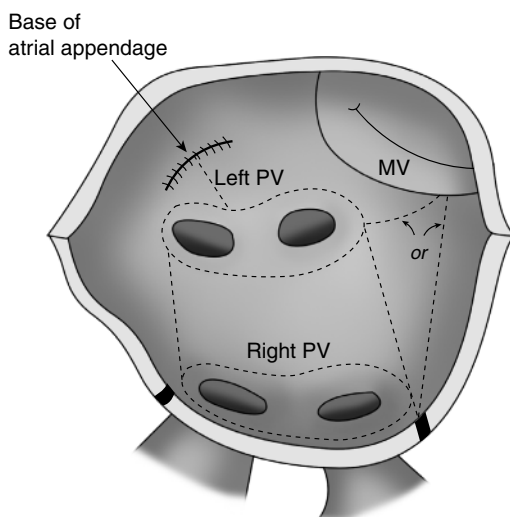


Figure 1.25 • The left-sided Maze involves ablation lines that encircle and connect the right and left pulmonary veins and one that extends from the inferior box lesion near the right or left inferior pulmonary vein to the mitral valve annulus. The left atrial appendage is amputated and an additional ablation line is placed from the base of the appendage to the left pulmonary veins. The base of the left atrial appendage is then oversewn.

extends from the inferior pulmonary vein ablation line to the mitral valve annulus.^{245,246} The left atrial appendage is amputated and an ablation line carried from the base of the appendage to the left pulmonary vein encircling line. Left atrial volume reduction may be helpful when the LA dimension exceeds 6 cm.^{136,247} Use of ganglionic plexi mapping and ablation with confirmation of conduction block by pacing may improve results.²⁴⁸

5. The right-sided Maze includes amputation of the right atrial appendage (or an ablation line across its base) and an incision into the right atrium from the septum towards the AV groove. Through this incision, ablation lines are extended laterally up the SVC and down to the inferior vena cava (IVC), across the fossa ovalis down to the coronary sinus, from the IVC to the coronary sinus and from the sinus to the tricuspid annulus (isthmus lesions). Additional ablation lines extend from the anterior tricuspid leaflet to the base of the excised RA appendage and from the posterior tricuspid leaflet to the AV groove (Figure 1.26).

XIV. Ventricular Tachycardia and Sudden Death

A. Pathophysiology

1. Nonidiopathic ventricular tachycardia (VT) occurs in association with structural heart disease, and may be subdivided into ischemic and nonischemic etiologies.
 - a. Ischemic VT is caused either by active ischemia (usually from a ruptured plaque or induced during hemodynamic stress) or from a previous myocardial infarction (MI) that produces scar tissue and impaired LV function. The latter results from heterogeneous myocardial damage that produces the electrophysiologic substrate for the development of a reentrant rhythm. This

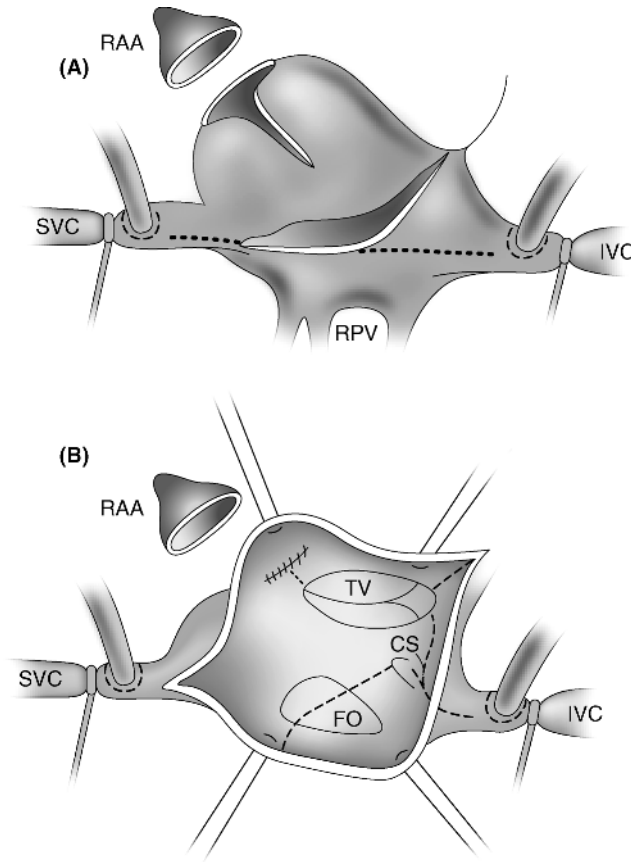


Figure 1.26 • (A) The right-sided Maze includes ablation of the base of the right atrial appendage and an incision in the right atrial wall through which multiple bipolar and unipolar ablation lines can be carried out. (B) Sites for endocardial ablation are shown by the dotted lines (see text).

commonly occurs at the border zone of an LV aneurysm between dense subendocardial scar tissue and normal myocardium. Premature stimuli delivered during electrophysiologic testing may initiate an impulse that triggers the reentrant circuit of monomorphic VT (“inducible VT”).

- b. Nonischemic VT may result from reentrant circuits or triggered automaticity. It is most commonly noted in patients with dilated cardiomyopathies and markedly depressed ventricular function, as well as less common entities such as arrhythmogenic RV dysplasia. In these conditions, the arrhythmogenic focus frequently cannot be adequately mapped and it is difficult to ablate with catheter intervention.
2. Idiopathic VT occurs in the absence of structural heart disease and may arise along the RV outflow tract or in the left posterior fascicle of the left ventricle. It is usually

caused by triggered activity related to a high adrenergic state. As such, it can be treated by medical therapy, or, if that fails, by radiofrequency catheter ablation.

3. Out-of-hospital cardiac arrest (so-called sudden cardiac death [SCD]) is estimated to be the first manifestation of coronary disease in 40% of patients, usually as a result of rupture of an unstable plaque. Other patients have no identifiable cause for such an event and may or may not have inducible arrhythmias.

B. Interventional procedures and their indications

1. The presence of malignant ventricular arrhythmias mandates an assessment for potentially correctable causes. Surgery, such as a CABG or LVA resection, can be considered based on standard indications with the understanding that no antiarrhythmic benefit may be achieved. In these situations, and in patients in whom no cardiac surgical procedure is indicated, ICD implantation can be considered to improve survival. The recommendations for ICD implantation are based upon the 2008 guidelines, which evaluated numerous primary and secondary prevention trials.^{249,250}
2. Class I indications (ICD implantation is indicated)
 - a. Survivors of cardiac arrest due to VF/VT not due to a reversible cause
 - b. Spontaneous sustained VT with structural heart disease (usually a dilated cardiomyopathy)
 - c. Unexplained syncope if hemodynamically significant sustained VT or VF is inducible during an electrophysiology (EP) study
 - d. In patients with prior MI:
 - i. LVEF < 40% if nonsustained VT (NSVT) or inducible VF or sustained VT at EP study
 - ii. LVEF < 35% at least 40 days post-MI in NYHA class II–III
 - iii. LVEF < 30% at least 40 days post-MI in NYHA class I
 - iv. LVEF ≤ 35% with nonischemic dilated cardiomyopathy in NYHA class II–III
3. Class IIa indications (ICD implantation is reasonable)
 - a. Unexplained syncope, significant LV dysfunction, and nonischemic dilated cardiomyopathy
 - b. Sustained VT and normal or near-normal LV function
 - c. HOCM with one or more major risk factors for SCD (see page 41)
 - d. Other conditions of nonschemic VT, including outpatients awaiting transplantation
4. Class IIb indications (ICD implantation should be considered)
 - a. Nonischemic heart disease with LVEF ≤ 35% in NYHA class I
 - b. Unexplained syncope with advanced structural heart disease
5. The 2008 guidelines do not provide specific recommendations on how to manage postoperative cardiac surgical patients who develop sustained or nonsustained VT or have a preoperative EF < 30%, but inferences can be drawn.
 - a. Since patients undergoing cardiac surgery generally have structural heart disease, the occurrence of postoperative sustained VT is both a class I and IIa indication for an ICD, independent of LVEF.

- b. In patients with NSVT, the decision can be based on LVEF and EP studies.
 - i. For LVEF >40%, an ICD is not recommended and β -blockers are generally prescribed.
 - ii. For LVEF of 30–40%, an EP study is indicated. A noninducible patient is considered at low risk for sudden death and β -blockers are prescribed. If inducible, an ICD is placed.
 - iii. For LVEF <30%, an ICD is indicated if the patient is at least 40 days post-MI, even in the absence of VT. However, this ACC/AHA/HRS recommendation does not specifically address patients who have NSVT, recent revascularization (in the MADIT-II trial, patients with LVEF <30% had to be more than 3 months post-CABG), or depressed LVEF from symptomatic yet repaired valvular heart disease. If the patient has NSVT and depressed LV function, the options are to (1) place an ICD, (2) rely on an EP study to assess for inducibility, or (3) simply use β -blockers until the patient is 40 days after an MI and then place an ICD. Most centers would probably place an ICD prior to patient discharge. If the patient has an EF <30% but no VT, elective evaluation and placement of an ICD are indicated.

C. Preoperative considerations

1. A thorough preoperative evaluation should be undertaken to determine whether structural heart disease is present. Preliminary cardiac catheterization should be performed to ascertain whether myocardial revascularization is indicated. This may lower the risk of ICD implantation, and may also reduce the risk of recurrent VT if it was occurring on an ischemic basis.
2. Many patients with cardiomyopathies are maintained on warfarin, which must be held for several days to prevent bleeding into the ICD pocket. Infection developing in the pocket implies infection of the entire lead system and mandates its removal.²⁵¹
3. Careful monitoring and provisions for cardiac resuscitation (trained personnel and equipment) are essential during ICD implantation.

D. Surgical procedures

1. Myocardial revascularization should be performed in the patient with reversible ischemia and bypassable anatomy. It provides excellent results in patients with ischemic VT/VF.²⁵² The role of PCI in such patients is undefined. Standard indications for ICD implantation, including EP testing for inducibility, should then be followed.
2. Blind endocardial resection should be performed when ischemic ventricular tachycardia is present in a patient undergoing resection of an LV aneurysm. Aggressive resection of scar tissue, including that on the septum, with cryoablation at the periphery of the scar tissue and reconstruction of the ventricle by geometric modeling (SVR noted on page 62) should be performed. These procedures have supplanted the map-guided surgery performed in the mid-1990s that achieved success rates greater than 75% and reached 90% with the addition of medications. In high-risk patients with depressed ventricular function, one study showed that long-term survival was fairly similar with direct VT surgery or placement of an ICD, often with associated CABG.²⁵³

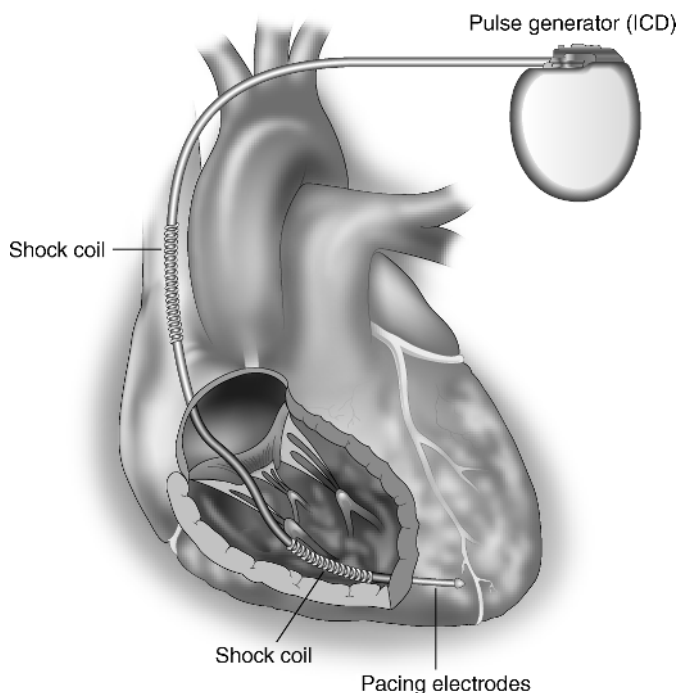


Figure 1.27 • Transvenous ICD system. The single-chamber system consists of one right ventricular lead that contains shocking coils that lie within the SVC and the right ventricle, and bipolar sensing and pacing electrodes that lie within the ventricle.

3. ICD implantation is performed in the EP lab. Most patients receive biventricular ICD systems that can perform AV sequential pacing and antitachycardia pacing. The device is implanted in a prepectoral pocket. Testing of the leads for sensing and defibrillation thresholds (DFTs) is performed. The generator is then connected to the leads and the system is retested (Figure 1.27).
4. Prior to the development of transvenous systems, ICD implantation was performed through left thoracotomy, median sternotomy, subcostal, or sub-xiphoid approaches. Device replacement and removal of infected lead systems mandate an understanding of their implantation methods. These systems usually involved two rate-sensing electrodes placed into the right or left ventricular epicardium and two titanium mesh patches for defibrillation placed over the ventricles, either inside or outside the pericardium.

XV. End-Stage Heart Failure

- A. **Pathophysiology.** End-stage heart failure is a clinical syndrome that develops due to progressive deterioration in LV function associated with LV remodeling. It is most commonly the result of multiple infarctions from coronary artery disease (ischemic cardiomyopathy), but may result from a dilated cardiomyopathy or

end-stage valvular heart disease. As ventricular function deteriorates, the left ventricle dilates and changes from an elliptical to a spherical shape. This increases wall stress, which then increases oxygen requirements, causes pathologic cardiomyocyte hypertrophy that further compromises contractile function, and induces functional MR. These changes lead to intractable heart failure. In addition, ventricular remodeling increases the tendency to develop ventricular arrhythmias.

1. Neurohormonal activation, with elevated levels of angiotensin II, aldosterone, norepinephrine, endothelin, vasopressin, and cytokines, may contribute to remodeling. These increase sodium retention and produce peripheral vasoconstriction, increasing hemodynamic stress. They also have direct toxic effects on myocardial cells, stimulating the development of fibrosis. This relationship between neurohormonal activation and worsening of CHF forms the basis of the medical approach to CHF.
2. Patients with long-standing hypertension tend to develop diastolic heart failure, although both systolic and diastolic components coexist in most patients.
3. The ACC/AHA guidelines have defined four stages in the progression of CHF: stage A (high risk for development of CHF), stage B (structural heart disease with LVH and reduced EF without CHF), stage C (structural heart disease with CHF), and stage D (refractory CHF requiring specialized intervention). Stage A patients should have their risk factors aggressively addressed. Stage B and C patients should receive more aggressive medical therapy with consideration of the surgical procedures listed below. Stage D patients may require destination assist devices or cardiac transplantation.^{254,255}

B. Medical therapy. The prognosis for patients with end-stage heart failure with NYHA class III–IV CHF is very poor, with a markedly impaired quality of life and a limited life span. Clinical improvement and improved survival have been noted with use of ACE inhibitors or angiotensin receptor blockers (ARBs), β -blockers such as carvedilol, bisoprolol and metoprolol, and diuretics, such as the aldosterone blockers (spironolactone or eplerenone). However, even with optimal medical therapy, annual mortality rates exceed 12%/year. Thus, alternative strategies are essential to treat this growing segment of the population.

C. Indications for surgery and surgical procedures. A variety of surgical procedures can be utilized to treat the patient with end-stage heart failure, depending on the pathophysiology of the disease.²⁵⁶

1. Coronary bypass surgery should be performed in patients with an ischemic cardiomyopathy if they have angina or documentation of ischemic, viable, hibernating myocardium. This can reduce anginal symptoms, in many cases will improve ventricular function and symptoms of CHF, may lower the risk of sudden cardiac death, and may improve survival.²⁵⁷ Patients with fewer viable segments of LV dyssynchrony do poorly.²⁵⁸ Clearly, revascularization earlier in a patient's course will produce a better clinical outcome.
2. Mitral valve repair with a small restrictive annuloplasty ring can be offered to patients with chronic severe MR and ischemic cardiomyopathies. This can promote reverse remodeling (usually a reduction in end-systolic volume index >15%), restore normal geometric relationships, alleviate symptoms of CHF, and prevent recurrent MR.²⁵⁹ Although a restrictive annuloplasty is usually successful

in improving symptoms, an improvement in long-term survival is less evident.^{260–262} Poor results are noted when mitral valve repair is performed in patients with severely dilated ventricles (LV end-diastolic dimension >65 mm) and in many patients with nonischemic cardiomyopathy.^{263,264} The 2009 ACCF/AHA guidelines consider mitral valve repair a class IIb indication in stage D patients since its effectiveness is not well-established.²⁵⁵ Percutaneous approaches to annular remodeling via the coronary sinus and edge-to-edge apposition techniques (MitraClip [Abbott]) are being investigated.

3. Cardiac resynchronization therapy (CRT) (atrial-synchronized biventricular pacing) has been demonstrated to improve heart failure symptoms and exercise tolerance and promote reverse remodeling. It is applicable to patients with an EF \leq 35%, NYHA class II–III symptoms, and a QRS duration \geq 120 msec. In these patients, ventricular dyssynchrony produces suboptimal ventricular filling, a reduction in contractility, paradoxical septal wall motion, and worsening MR. By activating both ventricles in a synchronized manner, CRT is able to increase LV filling time, decrease septal dyskinesis, and reduce MR.^{255,265} An ICD can also be considered in these patients. In patients in NYHA class III–IV who are dependent on ventricular pacing, CRT is considered a reasonable approach.
4. An ICD is indicated in many patients with stage B–D heart failure because of the frequent association of a dilated dysfunctional ventricle with ventricular tachyarrhythmias.
 - a. Ischemic cardiomyopathy with EF \leq 30%, at least 40 days post-MI in Stage B (NYHA class I)
 - b. Nonischemic cardiomyopathy with EF \leq 35% in Stage B (NYHA class I)
 - c. Stage C with current or past symptoms of CHF, reduced EF, and a history of cardiac arrest, VF, or unstable VT (class I recommendation for secondary prevention)
 - d. Stage C (NYHA II–III) with EF $<$ 35% of any etiology
5. Surgical ventricular restoration (SVR) can be used for patients who develop akinesia or dyskinesia subsequent to a single-territory MI.
 - a. It has been shown that LV end-systolic volume index (ESVI) is a major determinant of survival in patients with ischemic cardiomyopathy.²⁶⁶ Thus, combining CABG with resection of nonfunctioning tissue to decrease ventricular size and restore geometry should improve ventricular function, produce symptomatic improvement, and improve survival. These benefits have been documented in some studies comparing CABG + SVR with CABG alone, although an improvement in survival may not be evident.^{80,267,268} However, the STICH trial of patients with CAD-related anterior akinesia or dyskinesia with an ejection fraction $<$ 35% was unable to demonstrate that reduction in LV size was associated with an improvement in symptoms or reduction in mortality after 4 years.⁸² The methodology of this report has been criticized, because the literature suggests a benefit to adjunctive SVR with proper patient selection (ESVI $>$ 60 mL/m², more than 35% akinesia from anterior wall necrosis), and appropriately performed surgery (ensuring a 30% reduction in ESVI at follow-up).²⁶⁹ Some patients in the STICH trial did not satisfy these criteria.

- b. In patients with mild-to-moderate MR, CABG + SVR may reduce MR by reducing sphericity of the LV, thus reducing the longitudinal and transverse dimensions of the LV that increase the interpapillary muscle distance and cause apical tethering of the leaflets.²⁷⁰ However, in patients with 3–4+ MR, mitral repair should be considered. Resecting viable myocardium simply to reduce the size of the ventricle (Batista procedure) is not recommended.
- 6. Techniques and devices that prevent ventricular dilatation, such as a cardiomyoplasty, the CorCap restraint device (Acorn International), and the Myocor myosplint and Coapsys devices, have been investigated as means of improving symptoms of CHF. These have been shown to reduce end-diastolic dimensions, reduce wall stress, improve EF, and reduce MR.^{271,272}
- 7. When the patient has advanced heart failure and is not a candidate for any of the above procedures, more advanced interventional therapy may be required.
 - a. Cardiac transplantation should be considered in patients with end-stage heart failure who have an EF <15% and a peak $\text{VO}_2 < 10\text{--}15 \text{ mL/min/m}^2$ with maximal exercise testing. In potential transplant recipients, insertion of a left ventricular or even biventricular assist device (VAD) may be necessary if the patient develops progressive hemodynamic deterioration despite maximal pharmacologic therapy and an IABP. This can serve as a bridge to transplantation.²⁷³
 - b. VADs can be considered for destination therapy in patients who are not considered transplant candidates (usually because of age). Several devices, including the Thoratec HeartMate II, the Jarvik 2000, and the Micromed Heart Assist 5 (DeBakey) axial flow pumps have been used for destination therapy, with numerous other devices undergoing evaluation.^{274–276}
- 8. Muscle and stem cell transplantation into areas of infarcted myocardium are being investigated as a means of improving ventricular function.^{277,278}

XVI. Pericardial Disease

- A. Pathophysiology and diagnostic techniques.** The pericardium may become involved in a variety of systemic disease processes that produce either pericardial effusions or constriction. The most common causes of effusions are idiopathic (probably viral), malignant, uremic, pyogenic, and tuberculous. The most common causes of constriction are idiopathic, radiation, and tuberculous. Early and late postoperative cardiac tamponade due to hemopericardium are discussed on pages 372 and 660.
1. Large effusions result in tamponade physiology with progressive low output states. They are best documented by two-dimensional echocardiography, which delineates their size and provides hemodynamic evidence of tamponade. Findings include right atrial and ventricular diastolic collapse, increased reversal of flow in the hepatic veins during atrial systole, a dilated IVC with lack of inspiratory collapse, and decreased SVC flow during diastole.²⁷⁹ Equilibration of intracardiac pressures ($\text{RVEDP} = \text{PCWP} = \text{LVEDP}$) will be detected by cardiac catheterization.
 2. Constriction can also produce a low output state despite preserved systolic function. Cardiac catheterization will demonstrate a “square-root sign” in the

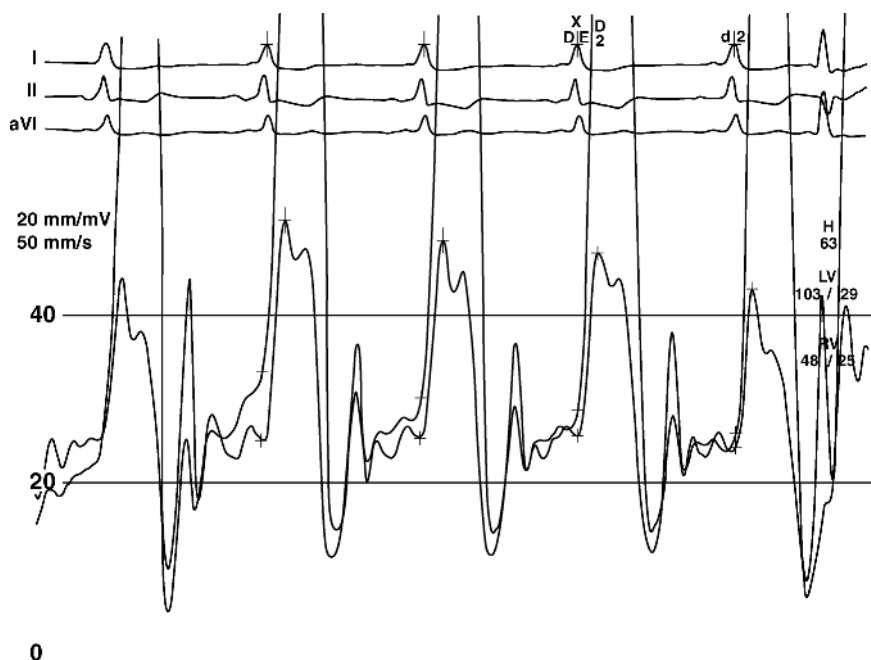


Figure 1.28 • Simultaneous right and left ventricular pressure tracings in constrictive pericarditis. Note the “dip-and-plateau” pattern as diastolic filling of the ventricular chambers is abruptly truncated by the constriction. Note also the equilibration of diastolic ventricular pressures. (Reproduced with permission from Myers and Spodick, *Am Heart J* 1999;138:219–32.)²⁸¹

right ventricular tracing, indicating rapid early filling and a diastolic plateau caused by severe impairment to RV filling (Figure 1.28).^{280,281} Cardiovascular CT and MRI scanning can be done to assess the thickness of the pericardium.²⁸² The differentiation of constriction, which is surgically correctable, from restriction, which is not, can be difficult because they have many findings in common. Although restrictive pathology is associated with diastolic dysfunction, it may or may not be associated with systolic dysfunction. However, the presence of significant pulmonary hypertension suggests a restrictive process, since it is rarely seen with constriction. A number of echocardiographic methods are helpful in differentiating constriction from restriction.^{283,284}

B. Indications for surgery

1. Large effusions that fail to respond to noninvasive measures (dialysis for uremia, antibiotics for infection, radiation or chemotherapy for malignancy, thyroid replacement for myxedema) may be treated initially by a percutaneous drainage procedure (either pericardiocentesis with catheter drainage or balloon pericardiostomy).^{285,286} Echocardiography is helpful in localizing the effusion and determining whether it is easily accessible to a percutaneous needle or not. If these procedures cannot be performed or the effusion recurs, surgical drainage should be performed.

2. Constriction that produces a refractory low output state, hepatomegaly, or peripheral edema should be treated by a pericardiectomy. Lesser degrees of constriction may resolve spontaneously or respond to a course of nonsteroidal antiinflammatory medications or steroids. Factors that compromise the long-term results of pericardiectomy include radiation-induced constriction, higher PA pressures, worse LV systolic function, and the presence of hyponatremia or renal dysfunction.²⁸⁷

C. Preoperative considerations

1. The subacute development of cardiac tamponade increases systemic venous pressures with eventual compromise in organ system perfusion from a low cardiac output syndrome. Patients frequently develop oliguric renal dysfunction, worsening respiratory status, and hepatic congestion. None of these will improve until drainage is accomplished. Fresh frozen plasma should be available if there is a preexisting coagulopathy.
2. Both tamponade and constriction are associated with low cardiac output states. Intrinsic compensatory mechanisms to maintain blood pressure and cardiac output include a tachycardia and increased sympathetic tone. Maintenance of adequate preload is essential to increase cardiac output. β -blockers and vasodilators must be avoided. Patients with low output states from severe constriction may benefit from a few days of inotropic support prior to surgery. Patients with abnormal LV contractility and relaxation properties before surgery have a higher inotropic requirement after surgery with a higher mortality rate and worse long-term outcome. They might benefit the most from preoperative support.²⁸⁸
3. Preliminary pericardiocentesis for a very large effusion improves the safety of anesthetic induction, which can produce vasodilation, a fall in filling pressures, and profound hypotension.
4. Prepping and draping the patient prior to the induction of anesthesia may be a prudent maneuver in patients with extremely tenuous hemodynamic status.

D. Surgical procedures

1. **Pericardial effusions.** If percutaneous drainage is inadequate or contraindicated, surgery should be performed.
 - a. A subxiphoid pericardiostomy opens the pericardium, drains the pericardial space, allows for obtaining a small biopsy specimen, and obliterates the pericardial space by promoting the formation of adhesions with several days of chest tube drainage (Figure 1.29). It is the safest approach in the unstable patient and the best for patients with malignancies and a limited life span. Recurrence rate is lower with this procedure than with percutaneous catheter drainage.²⁸⁵
 - b. A pericardial window, created with a balloon technique, a videothoracoscopic approach (VATS), or a limited thoracotomy, can be used to drain the effusion into the pleural space and obtain a biopsy specimen. The latter two procedures require general anesthesia and are best utilized when there is suspicion of underlying pleuropulmonary pathology. One study suggested that a VATS approach produced a lower recurrence rate than a subxiphoid drainage procedure.²⁸⁹

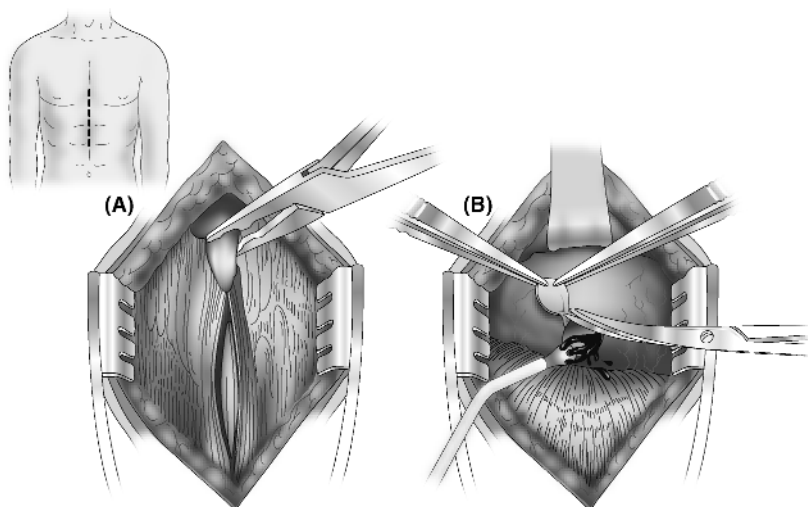


Figure 1.29 • The subxiphoid approach to pericardial disease. (A) An incision is made over the xiphisternal junction, extending inferiorly for 5 cm. The rectus fascia is incised and the xiphoid process is removed. (B) With upward traction on the distal sternum, the preperitoneal fat is swept away. The pericardium is grasped and incised and a small specimen may be removed. A finger is insinuated to break up any loculations, and pericardial fluid is aspirated with a suction catheter. One or two chest tubes are then placed within the pericardium.

2. Constrictive pericarditis²⁹⁰

- a. Pericardiectomy is best performed through a median sternotomy approach with pump standby. The pericardium is removed to within 2 cm of the phrenic nerves on either side, or at least as far as exposure allows. Dissection of the aorta and pulmonary arteries should be performed first, followed by the left and then the right ventricle to avoid pulmonary edema. One comparative study of sternotomy vs. thoracotomy approaches found both approaches to be effective, but generally the thoracotomy approach is associated with more pulmonary complications and should be reserved for cases of infectious pericarditis (usually tuberculosis) to avoid a sternal infection.^{291–293}
- b. When there is no dissection plane between the thickened pericardium and the epicardium, the operation can be quite difficult. When dense calcific adhesions are present without a cleavage plane, use of CPB may allow for a safer dissection, although bleeding may be increased by heparinization. It is frequently prudent to leave heavily calcified areas adherent to the heart to minimize bleeding and pericardial damage.
- c. Rarely, patients will develop epicardial constriction with a severe inflammatory response postoperatively, anecdotally noted in some patients with prior mediastinal radiation. This problem is approached using a “waffle” procedure, which entails multiple crisscrossing incisions in the scar tissue to optimize ventricular expansion and filling.²⁹⁴

XVII. Congenital Heart Disease: Atrial Septal Abnormalities

A. Pathophysiology

1. The atrial septum is comprised embryologically of two separate septa which form a flap-like orifice that permits right-to-left blood flow as part of the fetal circulation. After birth, the septum seals, producing an intact atrial septum. In 25% of patients, it remains patent and is called a “patent foramen ovale” or PFO. The risk of a PFO is that of paradoxical embolism associated with right-to-left shunting when the RA pressure exceeds the LA pressure. This may be noted during straining, heavy lifting, and coughing, but can be present in more than half of patients at rest.
2. An atrial septal aneurysm (ASA) reflects redundant tissue in the area of the fossa ovalis that produces excessive mobility of the septum. This promotes adherence of platelet–fibrin debris to the left atrial side which can embolize into the systemic circulation, most commonly when there is a right-to-left shunt, which is present in 50–80% of patients with these aneurysms. This may result from a PFO or perforations developing within the aneurysm. Aneurysms are present in only 2% of patients with PFOs, but when present, the likelihood of sustaining a stroke is four times greater than with PFOs alone. Overall, PFOs are noted in 40% of patients with cryptogenic stroke, with 10% having both an ASA and a PFO.^{295,296}
3. A small percentage of patients born with congenital atrial septal defects (ASDs) will reach adult life with a persistent left-to-right communication that may remain asymptomatic for decades. The increased shunt flow results in right atrial and right ventricular enlargement, eventually leading to pulmonary hypertension, atrial fibrillation, and tricuspid regurgitation. An untreated large ASD will eventually cause reversal of shunt flow, which is an inoperable situation.

B. Clinical presentation

1. **PFO.** Most patients with a PFO are asymptomatic. Clinical presentation is usually a transient ischemic attack (TIA) or stroke, or migraine-like headaches. In one study, a PFO and/or ASA could be identified in about 30% of patients <age 55 and 40% >age 55 who were diagnosed with a cryptogenic stroke.²⁹⁷ Shunting through a PFO is believed to be the mechanism in platypnea–orthodeoxia syndrome (dyspnea and deoxygenation when sitting or standing up from a recumbent position).
2. **ASDs.** Depending on the size of the ASD, the degree of shunt flow, and the presence of partial anomalous pulmonary venous drainage (noted with sinus venosus defects), a patient may develop shortness of breath, fatigue, exercise intolerance, frequent pulmonary infections, and palpitations from atrial arrhythmias. Although the flow is predominantly left-to-right, paradoxical embolism is noted in about 15% of patients.²⁹⁸

C. Evaluation

1. **PFO.** Transesophageal echocardiography with agitated saline injection should be performed in patients with cryptogenic stroke to detect right-to-left shunting through a PFO. Transcranial Doppler studies with agitated saline are also helpful. Noninvasive lower-extremity venous studies tend to be negative

because the embolus usually arises from the heart or consists of platelet–fibrin particles that are too small to detect.

2. **ASDs.** An echocardiogram can define the location and size of the septal defect, which can determine whether percutaneous closure is feasible. It should also quantitate the degree of left-to-right shunting, and assess RA and RV dilatation, RV dysfunction, and the degree of pulmonary hypertension.

D. Indications for intervention

1. There is no indication for a prophylactic intervention in an asymptomatic patient with a PFO, because alone it is not an independent risk factor for stroke.²⁹⁶
2. There is increasing interest in PFO closures in patients with migraine headaches and documented ischemic cerebral events.²⁹⁹
3. The optimal treatment for patients with prior TIA or cryptogenic stroke associated with a PFO is controversial.³⁰⁰ Medical therapy with aspirin and/or warfarin can be recommended, because the risk of recurrent stroke is fairly low (about 2.5% at 4 years).³⁰¹ However, excellent results have been obtained with percutaneous closure, which is safe and effective, and thus might be justifiable.³⁰² Closure can be recommended for patients with coexistent PFO and ASA, in whom the risk of recurrent stroke is significantly greater (15% at 4 years).³⁰¹
4. An ASD associated with symptoms, RA and RV enlargement (even if asymptomatic), or shunt flow exceeding 1.5:1 should be closed.³⁰³ Surgery can improve clinical status and prevent RV dilatation independent of the patient's age, although patients undergoing closure after age 30 tend to have higher PA pressures and a greater incidence of atrial fibrillation, which are predictive of an increase in late death from arrhythmias or heart failure. An intervention can be offered as long as the PA pressure is less than 2/3 systemic or responds to vasodilators; irreversible pulmonary hypertension contraindicates closure.^{304–306}

E. Interventions

1. Percutaneous closure can be performed for PFOs and secundum ASDs that are less than 38 mm in size and have a satisfactory tissue rim. Anticoagulation with antiplatelet therapy (aspirin +/– clopidogrel) is indicated for 6 months after placement of the device (Amplatzer).
2. Surgical closure, usually with a patch, is indicated in large secundum ASDs not amenable to percutaneous closure and for all non-secundum ASDs, including sinus venosus defects close to the SVC with associated anomalous pulmonary venous drainage, and ostium primum defects. This can frequently be done through a minithoracotomy incision.³⁰⁷

XVIII. Adults with Other Congenital Heart Disease

For the management of adults with all other forms of congenital heart disease, the reader is referred to the ACC/AHA guidelines available at www.acc.org.³⁰³

References

1. Kim H, Yang DH, Park Y, et al. Incremental prognostic value of C-reactive protein and N-terminal proB-type natriuretic peptide in acute coronary syndrome. *Circ J* 2006;70:1379–84.
2. Jneid H, Bhatt DL, Corti R, Badimon JJ, Fuster V, Francis GS. Aspirin and clopidogrel in acute coronary syndromes: therapeutic insights from the CURE study. *Arch Intern Med* 2003;163:1145–53.
3. Fox KA, Mehta SR, Peters R, et al. Benefits and risks of the combination of clopidogrel and aspirin in patients undergoing surgical revascularization for non-ST elevation acute coronary syndrome: the Clopidogrel in Unstable Angina to prevent Recurrent Ischemic Events (CURE) trial. *Circulation* 2004;110:1202–8.
4. Keller TT, Squizzato A, Middeldorp S. Clopidogrel plus aspirin versus aspirin alone for preventing cardiovascular disease. *Cochrane Database Syst Rev* 2007;3:CD005158.
5. Berger JS, Frye CB, Harshaw Q, Edwards FH, Steinhubl SR, Becker RC. Impact of clopidogrel in patients with acute coronary syndromes requiring coronary artery bypass surgery: a multicenter analysis. *J Am Coll Cardiol* 2008;52:1693–701.
6. Bhatt DL, Flather MD, Hacke W, et al. Patients with prior myocardial infarction, stroke, or symptomatic peripheral vascular disease in the CHARISMA trial. *J Am Coll Cardiol* 2007;49:1982–8.
7. Antman EM, Hand M, Armstrong PW, et al. 2007 focused update of the ACC/AHA 2004 guidelines for the management of patients with ST-elevation myocardial infarction. A report of the American College of Cardiology/American Heart Association Task Force on Practice Guidelines (writing group to review new evidence and update the ACC/AHA 2004 guidelines for the management of patients with ST-elevation myocardial infarction). *J Am Coll Cardiol* 2008;51:210–47.
8. Armstrong PW. Contemporary therapy of acute ST-elevation myocardial infarction. *Tex Heart Inst J* 2009;36:273–81.
9. Anderson JL, Adams CD, Antman EM, et al. ACC/AHA 2007 guidelines for the management of patients with unstable angina/non ST-elevation myocardial infarction: a report of the American College of Cardiology/American Heart Association task force on practice guidelines (writing committee to review the 2002 guidelines for the management of patients with unstable angina/non-ST elevation myocardial infarction) developed in collaboration with the American College of Emergency Physicians, the Society for Cardiovascular Angiography and Intervention, and the Society of Thoracic Surgeons endorsed by the American Association of Cardiovascular and Pulmonary Rehabilitation and the Society for Academic Emergency Medicine. *J Am Coll Cardiol* 2007;50:1965–72 or *Circulation* 2007;116:e148–304 (available online at acc.org).
10. Giugliano RP, Braunwald E. The year in non-ST-segment elevation acute coronary syndrome. *J Am Coll Cardiol* 2008;52:1095–1103.
11. Ebrahimi R, Dyke C, Mehran R, et al. Outcomes following pre-operative clopidogrel administration in patients with acute coronary syndromes undergoing coronary artery bypass surgery. The ACUTITY (Acute Catheterization and Urgent Intervention Triage strategy) Trial. *J Am Coll Cardiol* 2009;53:1965–72.
12. Patel MR, Dehmer GJ, Hirshfeld JW, Smith PK, Spertus JA. ACCF/SCAI/AATS/AHA/ASNC 2009 appropriateness criteria for coronary revascularization. *J Am Coll Cardiol* 2009;53:530–53.
13. Katritsis DM, Meier B. Percutaneous coronary intervention for stable coronary artery disease. *J Am Coll Cardiol* 2008;52:889–93.
14. Holmes DR Jr, Gersh BJ, Whitlow P, King SB III, Dove JT. Percutaneous coronary intervention for chronic stable angina. A reassessment. *JACC Cardiovasc Interv* 2008;1:34–43.
15. Hannan EL, Wu C, Walford G, et al. Drug-eluting stents vs. coronary-artery bypass grafting in multivessel coronary disease. *N Engl J Med* 2008;358:331–41.
16. Booth J, Clayton T, Pepper J, et al. Randomized, controlled trial of coronary artery bypass surgery versus percutaneous coronary intervention in patients with multivessel coronary artery disease: six-year follow-up from the Stent or Surgery trial (SoS). *Circulation* 2008;118:381–8.
17. Serruys PW, Morice MC, Kappetein AP, et al. Percutaneous coronary intervention versus coronary-artery bypass grafting for severe coronary artery disease. *N Engl J Med* 2009;360:961–72.
18. Mack MJ, Prince SL, Herbert M, et al. Current clinical outcomes of percutaneous coronary intervention and coronary artery bypass grafting. *Ann Thorac Surg* 2008;86:496–503.

19. Smith PK. Treatment selection for coronary artery disease: the collision of a belief system with evidence. *Ann Thorac Surg* 2009;87:1328–31.
20. May SA, Wilson JM. The comparative efficacy of percutaneous and surgical coronary revascularization in 2009. *Tex Heart Inst J* 2009;36:375–86.
21. Seung KB, Park DW, Kim YH, et al. Stents versus coronary-artery bypass grafting for left main coronary artery disease. *N Engl J Med* 2008;358:1781–92.
22. Ellis SG. Percutaneous left main intervention. An evolving perspective. *JACC Cardiovasc Interv* 2010;3:642–7.
23. Garg S, Stone GW, Kappetein AP, Sabik JF, Simonton C, Serruys PW. Clinical and angiographic risk assessment in patients with left main stem lesions. *JACC Cardiovasc Interv* 2010;3:891–901.
24. Sianos G, Morel MA, Kappetein AP, et al. The SYNTAX score: an angiographic tool grading the complexity of coronary artery disease. *Eurointervention* 2005;1:219–27.
25. Capodanno D, Capranzano P, Di Salvo ME, et al. Usefulness of SYNTAX score to select patients with left main coronary artery disease to be treated with coronary artery bypass graft. *JACC Cardiovasc Interv* 2009;2:731–8.
26. Roukoz H, Bavry AA, Sarkees ML, et al. Comprehensive meta-analysis on drug-eluting stents versus bare-metal stents during extended follow-up. *Am J Med* 2009; 122:581.e1–10.
27. Garg P, Cohen DJ, Gaziano T, Mauri L. Balancing the risks of restenosis and stent thrombosis in bare-metal versus drug-eluting stents. *J Am Coll Cardiol* 2008;51:1844–53.
28. Grines CL, Bonow RO, Casey DE Jr, et al. Prevention of premature discontinuation of dual antiplatelet therapy in patients with coronary artery stents: a science advisory from the American Heart Association, American College of Cardiology, Society for Cardiovascular Angiography and Interventions, American College of Surgeons, and American Dental Association, with representation from the American College of Physicians. *Circulation* 2007;115:813–8 and *J Am Coll Cardiol* 2007;49:734–9.
29. Byrne JG, Leacche M, Vaughan DE, Zhao DX. Hybrid cardiovascular procedures. *JACC Cardiovasc Interv* 2008;1:459–68.
30. Hholzey DM, Jacobs S, Mochalski M, et al. Minimally invasive hybrid coronary artery revascularization. *Ann Thorac Surg* 2008;86:1856–60.
31. Society of Thoracic Surgeons Blood Conservation Task Force, Ferraris VA, Ferraris SP, Saha SP, et al. Perioperative blood transfusion and blood conservation in cardiac surgery: the Society of Thoracic Surgeons and the Society of Cardiovascular Anesthesiologists clinical practice guideline. *Ann Thorac Surg* 2007;83(5 suppl):S27–86.
32. Bell ML, Grunwald GK, Baltz JH, et al. Does preoperative hemoglobin independently predict short-term outcomes after coronary artery bypass surgery? *Ann Thorac Surg* 2008;86:1415–23.
33. Kuduvalli M, Oo AY, Newall N, et al. Effect of peri-operative red blood cell transfusion on 30-day and 1-year mortality following coronary artery bypass surgery. *Eur J Cardiothorac Surg* 2005;27:592–8.
34. Scott BH, Seifert FC, Grimson R. Blood transfusion is associated with increased resource utilisation, morbidity and mortality in cardiac surgery. *Ann Card Anaesth* 2008;11:15–9.
35. Spiess BD. Choose one: damned if you do/damned if you don't! *Crit Care Med* 2005;33:1871–3.
36. Ereth MH, Nuttall GA, Orszulak TA, Santrach PJ, Cooney WP IV, Oliver WC Jr. Blood loss from coronary angiography increases transfusion requirements for coronary artery bypass graft surgery. *J Cardiothorac Vasc Anesth* 2000;14:177–81.
37. Karkouti K, Beattie WS, Wijesundera DN, et al. Hemodilution during cardiopulmonary bypass is an independent risk factor for acute renal failure in adult cardiac surgery. *J Thorac Cardiovasc Surg* 2005;129:391–400.
38. Karkouti K, Djaiani G, Borger MA, et al. Low hematocrit during cardiopulmonary bypass is associated with increased risk of perioperative stroke in cardiac surgery. *Ann Thorac Surg* 2005;80:1381–7.
39. DeFoe GR, Ross CS, Olmstead EM, et al. Lowest hematocrit on bypass and adverse outcomes associated with coronary artery bypass grafting. Northern New England Cardiovascular Disease Study Group. *Ann Thorac Surg* 2001;71:769–76.

40. Kalyani SD, Miller NR, Dong LM, Baumgartner WA, Alejo DE, Gilbert TB. Incidence of and risk factors for perioperative optic neuropathy after cardiac surgery. *Ann Thorac Surg* 2004;78:34–7.
41. Ferguson TB, Coombs LP, Peterson ED. Preoperative beta-blocker use and mortality and morbidity following CABG surgery in North America. *JAMA* 2002;287:2221–7.
42. Warkentin TE, Greinacher A, Koster A, Lincoff AM. Treatment and prevention of heparin-induced thrombocytopenia. American College of Chest Physicians evidence-based clinical practice guidelines (8th edition). *Chest* 2009;133:340S–80S.
43. Gibbs NM, Weightman WM, Thackray NM, Michalopoulos N, Weidmann C. The effects of recent aspirin ingestion on platelet function in cardiac surgical patients. *J Cardiothorac Vasc Anesth* 2001;15:55–9.
44. Ferraris VA, Ferraris SP, Moliterno DJ, et al. The Society of Thoracic Surgeons practice guidelines series: aspirin and other antiplatelet agents during operative coronary revascularization (executive summary). *Ann Thorac Surg* 2005;79:1454–61.
45. Bybee KA, Powell BD, Valeti U, et al. Preoperative aspirin therapy is associated with improved postoperative outcomes in patients undergoing coronary artery bypass grafting. *Circulation* 2005; 112(9 Suppl):I-286–92.
46. Sun JC, Whitlock R, Cheng J, et al. The effect of pre-operative aspirin on bleeding, transfusion, myocardial infarction, and mortality in coronary artery bypass surgery: a systematic review of randomized and observational studies. *Eur Heart J* 2008;29:1057–71.
47. Mahla E, Metzler H, Tantry US, Gurbel PA. Controversies in oral antiplatelet therapy in patients undergoing aortocoronary bypass surgery. *Ann Thorac Surg* 2010; 90:1040–51.
48. Aranki SF, Body SC. Antiplatelet agents used for early intervention in acute coronary syndrome: myocardial salvage versus bleeding complications. *J Thorac Cardiovasc Surg* 2009;138:807–10.
49. Maltais S, Perrault LP, Do QB. Effect of clopidogrel on bleeding and transfusions after off-pump coronary artery bypass graft surgery: impact of discontinuation prior to surgery. *Eur J Cardiothorac Surg* 2008;34:127–31.
50. Mitchell LB, Exner DV, Wyse DG, et al. Prophylactic oral amiodarone for the prevention of arrhythmias that begin early after revascularization, valve replacement or repair: PAPABEAR: a randomized controlled trial. *JAMA* 2005;294:3093–100.
51. Kourliouros A, De Souza A, Roberts N, et al. Dose-related effect of statins on atrial fibrillation after cardiac surgery. *Ann Thorac Surg* 2008;85:1515–20.
52. Liakopoulos OJ, Choi YH, Kuhn EW, et al. Statins for prevention of atrial fibrillation after cardiac surgery: a systematic literature review. *J Thorac Cardiovasc Surg* 2009;138:678–86.
53. Liakopoulos OJ, Choi YH, Haldenwang PL, et al. Impact of preoperative statin therapy on adverse postoperative outcomes in patients undergoing cardiac surgery: a meta-analysis of over 30,000 patients. *Eur Heart J* 2008;29:1548–59.
54. Whitlock RP, Chan S, Devereaux PJ, et al. Clinical benefit of steroid use in patients undergoing cardiopulmonary bypass: a meta-analysis of randomized trials. *Eur Heart J* 2008;29:2592–600.
55. Liakopoulos OJ, Schmitto JD, Kazmaier S, et al. Cardiopulmonary and systemic effects of methylprednisolone in patients undergoing cardiac surgery. *Ann Thorac Surg* 2007;84:110–9.
56. Halonen J, Halonen P, Jarvinen O, et al. Corticosteroids for the prevention of atrial fibrillation after cardiac surgery. A randomized controlled trial. *JAMA* 2007;297:1562–7.
57. Morariu AM, Loef BG, Aarts LP, et al. Dexamethasone benefit and prejudice for patients undergoing on-pump coronary artery bypass grafting: a study on myocardial, pulmonary, renal, intestinal, and hepatic injury. *Chest* 2005;128:2677–87.
58. Ouzounian M, Hassan A, Buth KJ, et al. Impact of endoscopic versus open saphenous vein harvest techniques on outcomes after coronary artery bypass grafting. *Ann Thorac Surg* 2010;89:403–9.
59. Lopes RD, Hafley GE, Allen KB, et al. Endoscopic versus open vein-graft harvesting in coronary-artery bypass surgery. *N Engl J Med* 2009;361:235–44.
60. Rousou LJ, Taylor KB, Lu XG, et al. Saphenous vein conduits harvested by endoscopic technique exhibit structural and functional damage. *Ann Thorac Surg* 2009;87:62–70.

61. Zacharias A, Schwann TA, Riordan CJ, Durham SJ, Shah AS, Habib RH. Late results of conventional versus all-arterial revascularization based on internal thoracic and radial artery grafting. *Ann Thorac Surg* 2009;87:19–26.
62. Tatoulis J, Buxton BF, Fuller JA, et al. Long-term patency of 1108 radial arterial-coronary angiograms over 10 years. *Ann Thorac Surg* 2009;88:23–30.
63. Nasso G, Coppola R, Bonifazi R, Piancone F, Bozzetti G, Speziale G. Arterial revascularization in primary coronary artery bypass grafting: direct comparison of 4 strategies – results of the Stand-in-Y mammary study. *J Thorac Cardiovasc Surg* 2009;137:1093–100.
64. Carrier M, Cossette M, Pellerin M, et al. Statin treatment equalizes long-term survival between patients with single and bilateral internal thoracic artery grafts. *Ann Thorac Surg* 2009;88:789–95.
65. Vuković PM, Radak SS, Perić MS, Nežić DG, Knezević AM. Radial artery harvesting for coronary artery bypass grafting: a stepwise-made decision. *Ann Thorac Surg* 2008;86:828–31.
66. Reyes AT, Frame R, Brodman RF. Technique for harvesting the radial artery as a coronary artery bypass graft. *Ann Thorac Surg* 1995;59:118–26.
67. Connolly MW, Torrillo LD, Stauder MJ, et al. Endoscopic radial artery harvesting: results of the first 300 patients. *Ann Thorac Surg* 2002;74:502–5.
68. Attaran S, John L, El-Gamel A. Clinical and potential use of pharmacological agents to reduce radial artery spasm in coronary artery surgery. *Ann Thorac Surg* 2008;85:1483–9.
69. Bergsland J, Lingaas PS, Skulstad H, et al. Intracoronary shunt prevents ischemia in off-pump coronary artery bypass surgery. *Ann Thorac Surg* 2009;87:54–61.
70. Sellke FW, DiMaio JM, Caplan LR, et al. Comparing on-pump and off-pump coronary artery bypass grafting: numerous studies but few conclusions: a scientific statement from the American Heart Association council on cardiovascular surgery and anesthesia in collaboration with the interdisciplinary working group on quality of care and outcomes research. *Circulation* 2005;111:2858–64.
71. Puskas JD, Kilgo PD, Lattouf OM, et al. Off-pump coronary bypass provides reduced mortality and morbidity and equivalent 10-year survival. *Ann Thorac Surg* 2008;86:1139–46.
72. Møller CH, Penninga L, Wetterslev J, Steinbrüchel DA, Gluud C. Clinical outcomes in randomized trials of off- vs. on-pump coronary artery bypass surgery: systematic review with meta-analyses and trial sequential analyses. *Eur Heart J* 2008;29:2601–16.
73. Chu D, Bakaeen FG, Dao TK, LeMaire SA, Coselli JS, Huh J. On-pump versus off-pump coronary artery bypass grafting in a cohort of 63,000 patients. *Ann Thorac Surg* 2009;87:1820–7.
74. Holzhey DM, Jacobs S, Mochalski M, et al. Seven-year follow-up after minimally invasive direct coronary artery bypass: experience with more than 1300 patients. *Ann Thorac Surg* 2007;83:108–14.
75. Bonatti J, Schachner T, Bonaros N, et al. How to improve performance of robotic totally endoscopic coronary artery bypass grafting. *Am J Surg* 2008;195:711–6.
76. Bridges CR, Horvath KA, Nugent WC, et al. The Society of Thoracic Surgeons practice guideline series: transmyocardial laser revascularization. *Ann Thorac Surg* 2004;77:1494–502.
77. Shapira OM, Davidoff R, Hilkert RJ, Aldea GS, Fitzgerald CA, Shemin RJ. Repair of left ventricular aneurysm: long-term results of linear repair versus endoaneurysmorrhaphy. *Ann Thorac Surg* 1997;63:701–5.
78. Dor V, Di Donato M, Sabatier M, Montiglio F, Civaia F; RESTORE group. Left ventricular reconstruction by endoventricular circular patch plasty repair: a 17-year experience. *Semin Thorac Cardiovasc Surg* 2001;13:435–7.
79. Athanasuleas C, Buckberg GD, Stanley AW, et al. Surgical ventricular restoration in the treatment of congestive heart failure due to post-infarction ventricular dilatation. *J Am Coll Cardiol* 2004;44:1439–45.
80. Di Donato M, Castelvécchio S, Kukulski T, et al. Surgical ventricular restoration: left ventricular shape influence on cardiac function, clinical status, and survival. *Ann Thorac Surg* 2009;87:455–62.
81. Dzemali O, Risteski P, Bakhtiyar F, et al. Surgical ventricular remodeling leads to better long-term survival and exercise tolerance than coronary artery bypass grafting alone in patients with moderate ischemic cardiomyopathy. *J Thorac Cardiovasc Surg* 2009;138:663–8.

82. Jones RH, Velazquez EJ, Michler RE, et al. Coronary bypass surgery with or without surgical ventricular reconstruction. *N Engl J Med* 2009;360:1705–17.
83. Birnbaum Y, Fishbein MC, Blanche C, Siegel RJ. Ventricular septal rupture after acute myocardial infarction. *N Engl J Med* 2002;347:1426–32.
84. Poulsen SH, Praestholm M, Munk K, Wierup P, Egeblad H, Nielsen-Kudsk JE. Ventricular septal rupture complicating acute myocardial infarction: clinical characteristics and contemporary outcome. *Ann Thorac Surg* 2008;85:1591–6.
85. Lundblad R, Abdelnoor M, Geiran OR, Svennevig JL. Surgical repair of postinfarction ventricular septal rupture: risk factors of early and late death. *J Thorac Cardiovasc Surg* 2009;137:862–8.
86. David TE, Armstrong S. Surgical repair of postinfarction ventricular septal defect by infarct exclusion. *Semin Thorac Cardiovasc Surg* 1998;10:105–10.
87. Muehrcke DD, Daggett WM Jr, Buckley MJ, Akins CW, Hilgenberg AD, Austen WG. Postinfarct ventricular septal defect repair: effect of coronary artery bypass grafting. *Ann Thorac Surg* 1992;54:876–83.
88. Bonow RO, Carabello BA, Chatterjee K, et al. 2008 focused update incorporated into the ACC/AHA 2006 guidelines for the management of patients with valvular heart disease. A report of the American College of Cardiology/American Heart Association task force on practice guidelines (Writing committee to revise the 1998 guidelines for the management of patients with valvular heart disease). Endorsed by the Society of Cardiovascular Anesthesiologists, Society for Cardiovascular Angiography and Interventions, and Society of Thoracic Surgeons. *J Am Coll Cardiol* 2008;52:1–142 (available at www.acc.org).
89. Cowell SJ, Newby DE, Prescott RJ, et al. A randomized trial of intensive lipid-lowering in calcific aortic stenosis. *N Engl J Med* 2005;352:2389–97.
90. Rossebø AB, Pedersen TR, Boman K, et al. Intensive lipid lowering with simvastatin and ezetimibe in aortic stenosis. *N Engl J Med* 2008;359:1343–56.
91. Antonini-Canterin F, Leiballi E, Enache R, et al. Hydroxymethylglutaryl coenzyme-A reductase inhibitors delay the progression of rheumatic aortic valve stenosis. A long-term echocardiographic study. *J Am Coll Cardiol* 2009;53:1874–9.
92. Bartunek J, Sys SU, Rodrigues AC, Scheurbeeck EV, Mortier L, de Bruyne B. Abnormal systolic intracavity flow velocities after valve replacement for aortic stenosis. Mechanisms, predictive factors, and prognostic significance. *Circulation* 1996;93:712–9.
93. Omran H, Schmidt H, Hackenbroch M, et al. Silent and apparent cerebral embolism after retrograde catheterisation of the aortic valve in valvular stenosis: a prospective, randomised study. *Lancet* 2003;361:1241–6.
94. Levy F, Laurent M, Monin JL, et al. Aortic valve replacement for low-flow/low-gradient aortic stenosis. Operative risk stratification and long-term outcome: a European Multicenter study. *J Am Coll Cardiol* 2008;51:1466–72.
95. Tribouilloy C, Lévy F, Rusinaru D, et al. Outcome after aortic valve replacement for low-flow/low-gradient aortic stenosis without contractile reserve on dobutamine stress echocardiography. *J Am Coll Cardiol* 2009;53:1865–73.
96. Bergler-Klein J, Mundigler G, Pibarot P, et al. B-type natriuretic peptide in low-flow, low-gradient aortic stenosis: relationship to hemodynamics and clinical outcome: results from the Multicenter Truly or Pseudo-Severe Aortic Stenosis (TOPAS) study. *Circulation* 2007;115:2848–55.
97. Horstkotte D, Loogen F. The natural history of aortic valve stenosis. *Eur Heart J* 1988;9Suppl E:57–64.
98. Dal-Bianco JP, Khandheria BK, Mookadam R, Gentile F, Sengupta P.P. Management of asymptomatic severe aortic stenosis. *J Am Coll Cardiol* 2008;52:1279–92.
99. Brown ML, Pellikka PA, Schaff HV, et al. The benefits of early valve replacement in asymptomatic patients with severe aortic stenosis. *J Thorac Cardiovasc Surg* 2008;135:308–15.
100. Pellikka PA, Nishimura RA, Bailey KR, Tajik AJ. The natural history of adults with asymptomatic, hemodynamically significant aortic stenosis. *J Am Coll Cardiol* 1990;15:1012–7.
101. Pellikka PA, Sarano ME, Nishimura RA, et al. Outcome of 622 adults with asymptomatic, hemodynamically significant aortic stenosis during prolonged follow-up. *Circulation* 2005;111:3290–5.

102. Brown ML, McKellar SH, Sundt TM, Schaff HV. Ministernotomy versus conventional sternotomy for aortic valve replacement: systematic review and meta-analysis. *J Thorac Cardiovasc Surg* 2009;137:670–9.
103. Plass A, Scheffel H, Alkadhi H, et al. Aortic valve replacement through a minimally invasive approach: preoperative planning, surgical technique, and outcome. *Ann Thorac Surg* 2009;88:1851–6.
104. Ennker JAC, Albert AA, Rosendahl UP, Ennker IC, Dalladaku F, Florath I. Ten-year experience with stentless aortic valves: full-root versus subcoronary implantation. *Ann Thorac Surg* 2008;85:445–53.
105. de Kerchove L, Rubay J, Pasquet A, et al. Ross operation in the adult: long-term outcomes after root replacement and inclusion techniques. *Ann Thorac Surg* 2009;87:95–102.
106. Grinda JM, Mainardi JL, D'Attellis N, et al. Cryopreserved aortic viable homograft for active aortic endocarditis. *Ann Thorac Surg* 2005;79:767–71.
107. Gulbins H, Kilian E, Roth S, Uhlig A, Kreuzer E, Reichart B. Is there an advantage in using homografts in patients with acute infective endocarditis of the aortic valve? *J Heart Valve Dis* 2002;11:492–7.
108. Avierinos JF, Thuny F, Chalhvac V, et al. Surgical treatment of active aortic endocarditis: homografts are not the cornerstone of outcome. *Ann Thorac Surg* 2007;84:1935–42.
109. Gaudino M, De Filippo C, Pennestri F, Possati G. The use of mechanical prostheses in native aortic valve endocarditis. *J Heart Valve Dis* 1997;6:79–83.
110. Mataraci I, Polat A, Kiran B, et al. Long-term results of aortic root replacement: 15 years' experience. *Ann Thorac Surg* 2009;87:1783–8.
111. Walther T, Dewey T, Borger MA, et al. Transapical aortic valve implantation: step by step. *Ann Thorac Surg* 2009;87:276–83.
112. Wong DR, Ye J, Cheung A, Webb JG, Carere RG, Lichtenstein SV. Technical considerations to avoid pitfalls during transapical aortic valve implantation. *J Thorac Cardiovasc Surg* 2010;140:196–202.
113. Masson JB, Kovac J, Schuler G, et al. Transcatheter aortic valve implantation. Review of the nature, management, and avoidance of procedural complications. *JACC Cardiovasc Interv* 2009;2:811–20.
114. Al-Attar N, Ghodbane W, Himbert D, et al. Unexpected complications of transapical aortic valve implantation. *Ann Thorac Surg* 2009;88:90–4.
115. Zajarias A, Cribier AG. Outcomes and safety of percutaneous aortic valve replacement. *J Am Coll Cardiol* 2009;53:1829–36.
116. Clavel MA, Webb JG, Pibarot P, et al. Comparison of the hemodynamic performance of percutaneous and surgical bioprostheses for the treatment of severe aortic stenosis. *J Am Coll Cardiol* 2009;53:1883–91.
117. Pettersson GB, Crucean AC, Savage R, et al. Toward predictable repair of regurgitant aortic valves. A systematic morphology-directed approach to bicommissural repair. *J Am Coll Cardiol* 2008;52:40–9.
118. Tabata M, Takayama H, Bowdish ME, Smith CR, Stewart AS. Modified Bentall operation with bioprosthetic valved conduit: Columbia University experience. *Ann Thorac Surg* 2009;87:1969–70.
119. Etz CD, Homann TM, Rane N, et al. Aortic root reconstruction with a bioprosthetic valved conduit: a consecutive series of 275 procedures. *J Thorac Cardiovasc Surg* 2007;133:1455–63.
120. Zannis K, Deux JF, Tzvetkov B, et al. Composite Freestyle stentless xenograft with Dacron graft extension for ascending aortic replacement. *Ann Thorac Surg* 2009;87:1789–94.
121. Boodhwani M, de Kerchove L, El Khoury G. Aortic root replacement using the reimplantation technique: tips and tricks. *Interact Cardiovasc Thorac Surg* 2009;8:584–6.
122. Sareyyupoglu B, Suri RM, Schaff HV, et al. Survival and reoperation risk following bicuspid aortic-valve sparing root replacement. *J Heart Valve Dis* 2009;18:1–8.
123. David TE, Armstrong S, Maganti M, Colman J, Bradley TJ. Long-term results of aortic valve-sparing operations in patients with Marfan syndrome. *J Thorac Cardiovasc Surg* 2009;138:859–64.
124. Wilkins GT, Weyman AE, Abascal VM, Block PC, Palacios IF. Percutaneous balloon dilatation of the mitral valve: an analysis of echocardiographic variables related to outcome and the mechanism of dilatation. *Br Heart J* 1988;60:299–308.
125. Song JK, Kim MJ, Yun SC, et al. Long-term outcome of percutaneous mitral balloon valvuloplasty versus open cardiac surgery. *J Thorac Cardiovasc Surg* 2010;139:103–10.

126. Kim JB, Yun TJ, Chung CH, Choo SJ, Hong H, Lee JW. Long-term outcome of modified maze procedure combined with mitral valve surgery: analysis of outcomes according to type of mitral valve surgery. *J Thorac Cardiovasc Surg* 2010;139:111–7.
127. Halkos ME, Craver JM, Thourani VH, et al. Intraoperative radiofrequency ablation for the treatment of atrial fibrillation during concomitant cardiac surgery. *Ann Thorac Surg* 2005;80:210–6.
128. Jahangiri M, Weir G, Mandal K, Savelieva I, Camm J. Current strategies in the management of atrial fibrillation. *Ann Thorac Surg* 2006;82:35–64.
129. Raja SG, Dreyfus GD. Surgery for functional tricuspid regurgitation: current techniques, outcomes, and emerging concepts. *Expert Rev Cardiovasc Ther* 2009;7:73–84.
130. Matsumaya K, Matsumoto M, Sugita T, Nishizawa J, Tokuda Y, Matsuo T. Predictors of residual tricuspid regurgitation after mitral valve surgery. *Ann Thorac Surg* 2003;75:1826–8.
131. Anyanwu AC, Chikwe J, Adams DH. Tricuspid valve repair for treatment and prevention of secondary tricuspid regurgitation in patients undergoing mitral valve surgery. *Curr Cardiol Rep* 2008;10:110–7.
132. Chan V, Burwash IG, Lam BK, et al. Clinical and echocardiographic impact of functional tricuspid regurgitation repair at the time of mitral valve replacement. *Ann Thorac Surg* 2009;88:1209–15.
133. Carabello BA. The current therapy for mitral regurgitation. *J Am Coll Cardiol* 2008;52:319–26.
134. Chua YL, Schaff HV, Orszulak TA, Morris JJ. Outcome of mitral valve repair in patients with preoperative atrial fibrillation: should the maze procedure be combined with mitral valvuloplasty? *J Thorac Cardiovasc Surg* 1994;107:408–15.
135. Bando K, Kasegawa H, Okada Y, et al. Impact of preoperative and postoperative atrial fibrillation on outcome after mitral valvuloplasty for nonischemic mitral regurgitation. *J Thorac Cardiovasc Surg* 2005;129:1032–40.
136. Marui A, Saji Y, Nishina T, et al. Impact of left atrial reduction concomitant with atrial fibrillation surgery on left atrial geometry and mechanical function. *J Thorac Cardiovasc Surg* 2008;135:1297–305.
137. Di Donato M, Frigiola A, Menicanti L, et al. Moderate ischemic mitral regurgitation and coronary artery bypass surgery: effect of mitral repair on clinical outcome. *J Heart Valve Dis* 2003;12:272–9.
138. Paparella D, Mickleborough LL, Carson S, Ivanov J. Mild to moderate mitral regurgitation in patients undergoing coronary bypass grafting: effects on operative mortality and long-term significance. *Ann Thorac Surg* 2003;76:1094–100.
139. Wan CKN, Suri RM, Li Z, et al. Management of moderate functional mitral regurgitation at the time of aortic valve replacement: is concomitant mitral valve repair necessary? *J Thorac Cardiovasc Surg* 2009;137:635–40.
140. Waisbren EC, Stevens LM, Avery EG, Picard MH, Vlahakes GJ, Agnihotri AK. Changes in mitral regurgitation after replacement of the stenotic aortic valve. *Ann Thorac Surg* 2008;86:56–63.
141. Gillinov AM, Blackstone EH, Nowicki ER, et al. Valve repair versus valve replacement for degenerative mitral valve disease. *J Thorac Cardiovasc Surg* 2008;135:885–93.
142. Gillinov AM, Blackstone EH, Alaulaqi A, et al. Outcomes after repair of the anterior mitral leaflet for degenerative disease. *Ann Thorac Surg* 2008;86:708–17.
143. Shimokawa T, Kasegawa H, Matsuyama S, et al. Long-term outcome of mitral valve repair for infective endocarditis. *Ann Thorac Surg* 2009;88:733–9.
144. de Kerchove L, Vanoverschiede JL, Poncelet A, et al. Reconstructive surgery in active mitral valve endocarditis: feasibility, safety and durability. *Eur J Cardiothorac Surg* 2007;31:592–9.
145. Shang E, Forrest GN, Chizmar T, et al. Mitral valve infective endocarditis: benefit of early operation and aggressive use of repair. *Ann Thorac Surg* 2009;87:1728–34.
146. Gillinov AM, Faber C, Houghtaling PL, et al. Repair versus replacement for degenerative mitral valve disease with coexisting ischemic heart disease. *J Thorac Cardiovasc Surg* 2003;125:1350–62.
147. Borger MA, Alam A, Murphy PM, Doenst T, David TE. Chronic ischemic mitral regurgitation: repair, replace or rethink? *Ann Thorac Surg* 2006;81:1153–61.
148. Gillinov AM, Wierup PN, Blackstone EH, et al. Is repair preferable to replacement for ischemic mitral regurgitation? *J Thorac Cardiovasc Surg* 2001;122:1125–41.
149. Suri RM, Schaff HV, Meyer SR, Hargrove WC III. Thoracoscopic versus open mitral valve repair: a propensity score analysis of early outcomes. *Ann Thorac Surg* 2009;88:1185–90.

150. Modi P, Rodriguez E, Hargrove WC III, Hassan A, Szeto WY, Chitwood WR Jr. Minimally invasive video-assisted mitral valve surgery: a 12-year 2-center experience in 1178 patients. *J Thorac Cardiovasc Surg* 2009;137:1481-7.
151. Modi P, Hassan A, Chitwood WR Jr. Minimally invasive mitral valve surgery: a systematic review and meta-analysis. *Eur J Cardiothorac Surg* 2008;34:943-52.
152. Chitwood WR Jr, Rodriguez E, Chu MW, et al. Robotic mitral valve repair in 300 patients: a single-center experience. *J Thorac Cardiovasc Surg* 2008;136:436-41.
153. Shah PM, Raney A. Tricuspid valve disease. *Curr Probl Cardiol* 2008;33:47-84.
154. Rivera R, Duran E, Ajuria M. Carpentier's flexible ring versus De Vega's annuloplasty: a prospective randomized study. *J Thorac Cardiovasc Surg* 1985;89:196-203.
155. Filsoofi F, Anyanwu AC, Salzberg SP, Frankel T, Cohn LH, Adams DH. Long-term outcome of tricuspid valve replacement in the current era. *Ann Thorac Surg* 2005;80:845-50.
156. Iscan ZH, Vural KM, Bahar I, Mavioglu L, Saritas A. What to expect after tricuspid valve replacement? Long-term results. *Eur J Cardiothorac Surg* 2007;32:296-300.
157. Civelek A, Ak K, Akgün S, Isbir SC, Arsan S. Tricuspid valve replacement: an analysis of risk factors and outcomes. *Thorac Cardiovasc Surg* 2008;56:456-60.
158. Moraca RJ, Moon MR, Lawton JS, et al. Outcomes of tricuspid valve repair and replacement: a propensity analysis. *Ann Thorac Surg* 2009;87:83-9.
159. Jokinen JJ, Turpeinen AK, Pitkänen O, Hippeläinen MJ, Hartikainen JEK. Pacemaker therapy after tricuspid valve operations: implications on mortality, morbidity, and quality of life. *Ann Thorac Surg* 2009;87:1806-15.
160. Carozza A, De Santo LS, Romano G, et al. Infective endocarditis in intravenous drug abusers: patterns of presentation and long-term outcomes of surgical treatment. *J Heart Valve Dis* 2006;15:125-31.
161. Hill EE, Herrogods MC, Vanderschueren S, Claus P, Peetermans WE, Herijgers P. Outcome of patients requiring valve surgery during active infective endocarditis. *Ann Thorac Surg* 2008;85:1564-9.
162. Vilacosta I, Gramppner C, San Roman A, et al. Risk of embolization after institution of antibiotic therapy for infective endocarditis. *J Am Coll Cardiol* 2002;39:1489-95.
163. Dickerman SA, Abrutyn E, Barsic B, et al. The relationship between the initiation of antimicrobial therapy and the incidence of stroke in infective endocarditis: analysis from the ICE prospective cohort study (ICS-PCS). *Am Heart J* 2007;154:1086-94.
164. Vlessis AA, Khaki A, Grunkemeier GL, Li HH, Starr A. Risk, diagnosis, and management of prosthetic valve endocarditis: a review. *J Heart Valve Disease* 1997;6:443-65.
165. Eishi K, Kawazoe K, Kuriyama Y, Kitoh Y, Kawashima Y, Omae T. Surgical management of infective endocarditis associated with cerebral complications: multi-center retrospective study in Japan. *J Thorac Cardiovasc Surg* 1995;110:1745-55.
166. Gillinov AM, Shah RV, Curtis WE, et al. Valve replacement in patients with endocarditis and acute neurologic deficit. *Ann Thorac Surg* 1996;61:1125-9.
167. Parrino PE, Kron IL, Ross SD, et al. Does a focal neurologic deficit contraindicate operation in a patient with endocarditis? *Ann Thorac Surg* 1999;67:59-64.
168. Piper C, Wiemer M, Schulte HD, Hortskotte D. Stroke is not a contraindication for urgent valve replacement in acute infective endocarditis. *J Heart Valve Dis* 2001;10:703-11.
169. Ruttman E, Willeit J, Ulmer H, et al. Neurological outcome of septic cardioembolic stroke after infective endocarditis. *Stroke* 2006;37:2094-9.
170. Miró JM, Moreno A, Mestres CA. Infective endocarditis in intravenous drug abusers. *Curr Infect Dis Rep* 2003;5:307-16.
171. Carozza A, Renzulli A, De Feo M, et al. Tricuspid repair for infective endocarditis. Clinical and echocardiographic results. *Tex Heart Inst J* 2001;28:96-101.
172. Arbulu A, Holmes RJ, Asfaw I. Tricuspid valvectomy without replacement. Twenty years' clinical experience. *J Thorac Cardiovasc Surg* 1991;102:917-22.
173. Maron BJ, McKenna WJ, Danielson GK, et al. American College of Cardiology/European Society of Cardiology Clinical Expert Consensus Document on Hypertrophic Cardiomyopathy. A report of the American College of Cardiology Foundation Task Force on Clinical Expert Consensus Documents and the European Society of Cardiology Committee for Practice Guidelines. *J Am Coll Cardiol* 2003;42:1687-713.

174. Marian AJ. Contemporary treatment of hypertrophic cardiomyopathy. *Tex Heart Inst J* 2009;36:194–204.
175. Sherrid MV, Chaudhry FA, Swistel DG. Obstructive hypertrophic cardiomyopathy: echocardiography, pathophysiology, and the continuing evolution of surgery for obstruction. *Ann Thorac Surg* 2003;75:620–32.
176. Maron BJ, Spirito P, Shen WK, et al. Implantable cardioverter-defibrillator and prevention of sudden cardiac death in hypertrophic cardiomyopathy. *JAMA* 2007;298:405–12.
177. Galve E, Sambola A, Saldaña G, et al. Late benefits of dual-chamber pacing in obstructive hypertrophic cardiomyopathy. A 10-year follow-up study. *Heart* 2010;96:352–6.
178. Rinaldi CA, Bucknall CA, Gill JS. Beneficial effects of biventricular pacing in a patient with hypertrophic cardiomyopathy and intraventricular conduction delay. *Heart* 2002;87:e6.
179. Komsuoglu B, Vural A, Agacdiken A, Ural D. Effect of biventricular pacing on left ventricular outflow tract pressure gradient with hypertrophic cardiomyopathy and normal interventricular conduction. *J Cardiovasc Electrophysiol* 2006;17:207–9.
180. Agarwal S, Tuzcu EM, Desai MY, et al. Updated meta-analysis of septal alcohol ablation versus myectomy for hypertrophic cardiomyopathy. *J Am Coll Cardiol* 2010;55:823–34.
181. Ralph-Edwards A, Woo A, McCrindle BW, et al. Hypertrophic cardiomyopathy: comparison of outcomes after myectomy or alcohol ablation adjusted by propensity score. *J Thorac Cardiovasc Surg* 2005;129:351–8.
182. Dearani JA, Ommen SR, Gersh BJ, Schaff HV, Danielson GK. Surgical insight: septal myectomy for obstructive hypertrophic cardiomyopathy – the Mayo Clinic experience. *Nat Clin Pract Cardiovasc Med* 2007;4:503–12.
183. Smedira NG, Lytle BW, Lever HM, et al. Current effectiveness and risks of isolated septal myectomy for hypertrophic obstructive cardiomyopathy. *Ann Thorac Surg* 2008;85:127–33.
184. Minakata K, Dearani JA, Schaff HV, O'Leary PW, Ommen SR, Danielson GK. Mechanisms for recurrent left ventricular outflow tract obstruction after septal myectomy for obstructive hypertrophic cardiomyopathy. *Ann Thorac Surg* 2005;80:851–6.
185. Minakata K, Dearani JA, Nishimura RA, Maron BJ, Danielson GK. Extended septal myectomy for hypertrophic obstructive cardiomyopathy with anomalous papillary muscles or chordae. *J Thorac Cardiovasc Surg* 2004;127:481–9.
186. Kaple RK, Murphy RT, DiPaola L.M. et al. Mitral valve abnormalities in hypertrophic cardiomyopathy: echocardiographic features and surgical outcomes. *Ann Thorac Surg* 2008; 85:1527–36.
187. Khan IA, Nair CK. Clinical, diagnostic, and management perspectives of aortic dissection. *Chest* 2002;122:311–28.
188. Golledge J, Eagle KA. Acute aortic dissection. *Lancet* 2008;372:55–66.
189. Hansen MS, Nogareda GJ, Hutchison FJ. Frequency of and inappropriate treatment of misdiagnosis of acute aortic dissection. *Am J Cardiol* 2007;99:852–6.
190. Hagan PG, Nienaber CA, Isselbacher EM, et al. The international registry of acute aortic dissection (IRAD). New insights into an old disease. *JAMA* 2000;283:897–903.
191. Trimarchi S, Nienaber C, Rampoldi V, et al. Contemporary results of surgery in acute type A dissection: the International Registry of Acute Aortic Dissection experience. *J Thorac Cardiovasc Surg* 2005;129:112–22.
192. Suzuki T, Distant A, Zizza A, et al. Diagnosis of acute aortic dissection by D-Dimer: the International Registry of Acute Aortic Dissection Substudy on Biomarkers (IRAD-Bio) experience. *Circulation* 2009;119:2702–7.
193. Paparella D, Malvindi PG, Scrascia G, et al. D-dimers are not always elevated in patients with acute dissection. *J Cardiovasc Med (Hagerstown)* 2009;10:212–4.
194. Patel HJ, Williams DM, Dasika NL, Suzuki Y, Deeb GM. Operative delay for peripheral malperfusion syndrome in acute type A aortic dissection: a long-term analysis. *J Thorac Cardiovasc Surg* 2008;135:1288–96.
195. Yagdi T, Atay Y, Engin C, et al. Impact of organ malperfusion on mortality and morbidity in acute type A aortic dissections. *J Card Surg* 2006;21:363–9.

196. Estera AL, Miller CC, Goodrick J, et al. Update on outcomes of acute type B aortic dissection. *Ann Thorac Surg* 2007;83:S842-5.
197. Trimarchi S, Nienaber CA, Rampoldi V, et al. Role and results of surgery in acute type B dissection. Insights from the International Registry of Acute Aortic Dissection (IRAD). *Circulation* 2006;114 (1 Suppl):I-357-64.
198. Umana JP, Lai DT, Mitchell RS, et al. Is medical therapy still the optimal treatment strategy for patients with acute type B aortic dissections? *J Thorac Cardiovasc Surg* 2002;124:896-910.
199. Kodama K, Nishigami K, Sakamoto T, et al. Tight heart rate control reduces secondary adverse events in patients with type B acute aortic dissection. *Circulation* 2008;118(14 Suppl): S167-70.
200. Kunishige H, Myojin K, Ishibashi Y, Ishii K, Kawasaki M, Oka J. Predictors of surgical indications for acute type B dissection based on enlargement of aortic diameter during the chronic phase. *Jpn J Thorac Cardiovasc Surg* 2006;54:477-82.
201. Song JM, Kim SD, Kim JH, et al. Long-term predictors of descending aorta aneurysmal change in patients with aortic dissection. *J Am Coll Cardiol* 2007;50:799-804.
202. Onitsuka S, Akashi H, Tayama K, et al. Long-term outcome and prognostic indicators of medically treated acute type B aortic dissections. *Ann Thorac Surg* 2004;78:1268-73.
203. Watanuki H, Ogino H, Minatoya K, et al. Is emergency total arch replacement with a modified elephant trunk technique justified for acute type A aortic dissection? *Ann Thorac Surg* 2007;84:1585-91.
204. Geirsson A, Szeto WY, Pochettino A, et al. Significance of malperfusion syndromes prior to contemporary surgical repair for acute type A dissection: outcomes and need for additional revascularization. *Eur J Cardiothorac Surg* 2007;32:255-62.
205. Hanafusa Y, Ogino H, Sasaki H, et al. Total arch replacement with elephant trunk procedure for retrograde dissection. *Ann Thorac Surg* 2002;74:S1836-9.
206. Sun L, Qi R, Chang Q, et al. Surgery for acute type A dissection with the tear in the descending aorta using a stented elephant trunk procedure. *Ann Thorac Surg* 2009;87:1177-81.
207. Dong ZH, Fu WG, Wang YQ, et al. Retrograde type A aortic dissection after endovascular stent graft placement for treatment of type B dissection. *Circulation* 2009;119:735-41.
208. Patel HJ, Williams DM, Meekov M, et al. Long-term results of percutaneous management of malperfusion in acute type B aortic dissection: implications for thoracic aortic endovascular repair. *J Thorac Cardiovasc Surg* 2009;138:300-8.
209. Feezor RJ, Martin TD, Hess PJ Jr, Beaver TM, Klodell CT, Lee WA. Early outcomes after endovascular management of acute complicated type B aortic dissection. *J Vasc Surg* 2009;49:561-6.
210. Parker JD, Golledge J. Outcome of endovascular treatment of acute type B aortic dissection. *Ann Thorac Surg* 2008;86:1707-12.
211. Szeto WY, McGarvey M, Pochettino A, et al. Results of a new surgical paradigm: endovascular repair for acute complicated type B aortic dissection. *Ann Thorac Surg* 2008;86:87-93.
212. Svensson LG, Kouchoukos NT, Miller DC. Expert consensus document on the treatment of descending thoracic aortic disease using endovascular stent-grafts. *Ann Thorac Surg* 2008;85:S1-41.
213. Parish LM, Gorman JH 3rd, Kahn S, et al. Aortic size in acute type A dissection: implications for preventive ascending aortic replacement. *Eur J Cardiothorac Surg* 2009;35:941-5.
214. Pape LA, Tsai TT, Isselbacher EM, et al. Aortic diameter ≥ 5.5 cm is not a good predictor of type A aortic dissection: observations from the International Registry of Acute Aortic Dissection (IRAD). *Circulation* 2007;116:1120-7.
215. Elefteriades JA, Farkas EA. Thoracic aortic aneurysm. Clinically pertinent controversies and uncertainties. *J Am Coll Cardiol* 2010;55:841-57.
216. Prenger K, Pieters F, Cheriex E. Aortic dissection after valve replacement: incidence and consequences for strategy. *J Card Surg* 1994;9:495-8.
217. Fazel SS, Mallidi HR, Lee RS, et al. The aortopathy of bicuspid aortic valve disease has distinctive patterns and usually involves the transverse aortic arch. *J Thorac Cardiovasc Surg* 2008;135:901-7.

218. Etz CD, Homann TM, Silovitz D, et al. Long-term survival after the Bentall procedure in 206 patients with bicuspid aortic valves. *Ann Thorac Surg* 2007;84:1186–93.
219. David TE, Ivanov J, Armstrong S, Feindel CM, Webb GD. Aortic valve-sparing operations in patients with aneurysms of the aortic root or ascending aorta. *Ann Thorac Surg* 2002;74:S1758–61.
220. Cameron DE, Alejo DE, Patel ND, et al. Aortic root replacement in 372 Marfan patients: evolution of operative repair over 30 years. *Ann Thorac Surg* 2009;87:1344–9.
221. Volguinia IV, Miller DC, LeMaire SA, et al. Valve-sparing and valve-replacing techniques for aortic root replacement in patients with Marfan syndrome: analysis of early outcome. *J Thorac Cardiovasc Surg* 2009;137:1124–32.
222. Etz CD, Plestis KA, Kari FA, et al. Axillary cannulation significantly improves survival and neurologic outcome after atherosclerotic aneurysm repair of the aortic root and ascending aorta. *Ann Thorac Surg* 2008;86:441–6.
223. Apostolakis E, Akinosoglou K. The methodologies of hypothermic circulatory arrest and of antegrade and retrograde cerebral perfusion for aortic arch surgery. *Ann Thorac Cardiovasc Surg* 2008;14:138–48.
224. Halkos ME, Kerendi F, Myung R, Kilgo P, Puskas JD, Chen EP. Selective antegrade cerebral perfusion via right axillary artery cannulation reduces morbidity and mortality after proximal aortic surgery. *J Thorac Cardiovasc Surg* 2009;138:1081–9.
225. Minatoya K, Ogino H, Matsuda H, et al. Evolving selective cerebral perfusion for aortic arch replacement: high flow rate with moderate hypothermic circulatory arrest. *Ann Thorac Surg* 2008;86:1827–31.
226. Strauch JT, Spielvogel D, Lauten A, et al. Technical advances in total aortic arch replacement. *Ann Thorac Surg* 2004;77:581–9.
227. Spielvogel D, Etz CD, Silovitz D, Lansman SL, Griep RB. Aortic arch replacement with a trifurcated graft. *Ann Thorac Surg* 2007;83:S791–5.
228. Uchida N, Ishihara H, Sakashita M, Kanou M, Sumiyoshi T. Repair of the thoracic aorta by transaortic stent grafting (open stenting). *Ann Thorac Surg* 2002;73:444–9.
229. Etz CD, Plestis KA, Kari FA, et al. Staged repair of thoracic and thoracoabdominal aortic aneurysms using the elephant trunk technique: a consecutive series of 215 first stage and 120 complete repairs. *Eur J Cardiothorac Surg* 2008;34:605–14.
230. Estrera AL, Miller CC III, Chen EP, et al. Descending thoracic aortic aneurysm repair: a 12-year experience using distal aortic perfusion and cerebrospinal fluid drainage. *Ann Thorac Surg* 2005;80:1290–6.
231. Estrera AL, Sheinbaum R, Miller CC, et al. Cerebrospinal fluid drainage during thoracic aortic repair: safety and current management. *Ann Thorac Surg* 2009;88:9–15.
232. Coselli JS, LeMaire SA, Conklin LD, Adams GJ. Left heart bypass during descending thoracic aortic aneurysm repair does not reduce the incidence of paraplegia. *Ann Thorac Surg* 2004;77:1298–303.
233. Coselli JS, Lemaire SA, Koksoy C, Schmittling ZC, Curling PE. Cerebrospinal fluid drainage reduces paraplegia after thoracoabdominal aortic aneurysm repair: results of a randomized clinical trial. *J Vasc Surg* 2002;3:631–9.
234. Patel HJ, Sillingford MS, Mihalik S, Proctor MC, Deeb GM. Resection of the descending thoracic aorta: outcomes after use of hypothermic circulatory arrest. *Ann Thorac Surg* 2006;82:90–6.
235. Fehrenbacher JW, Hart DW, Huddleston E, Siderys H, Rice C. Optimal end-organ protection for thoracic and thoracoabdominal aneurysm repair using deep hypothermic circulatory arrest. *Ann Thorac Surg* 2007;83:1041–6.
236. Misfeld M, Sievers HH, Hadlak M, Gorski A, Hanke T. Rate of paraplegia and mortality in elective descending and thoracoabdominal aortic repair in the modern surgical era. *Thorac Cardiovasc Surg* 2008;56:342–7.
237. Bavaria JE, Appoo JJ, Makaroun MS, et al. Endovascular stent grafting versus open surgical repair of descending thoracic aortic aneurysms in low-risk patients: a multicenter comparative trial. *J Thorac Cardiovasc Surg* 2007;133:369–77.
238. Cheng D, Martin J, Shennib H, et al. Endovascular aortic repair versus open surgical repair for descending thoracic aortic disease. A systematic review and meta-analysis of comparative studies. *J Am Coll Cardiol* 2010;55:986–1001.

239. Hnath JC, Mehta M, Taggart JB, et al. Strategies to improve spinal cord ischemia in endovascular thoracic aortic repair: outcomes of a prospective cerebrospinal fluid drainage protocol. *J Vasc Surg* 2008;48:836–40.
240. Louagie Y, Buche M, Eucher P, et al. Improved patient survival with concomitant Cox Maze III procedure compared with heart surgery alone. *Ann Thorac Surg* 2009;87:440–7.
241. Saltman AE, Gillinov AM. Surgical approaches for atrial fibrillation. *Cardiol Clin* 2009;27:179–88.
242. Li H, Li Y, Sun L, et al. Minimally invasive surgical pulmonary vein isolation alone for persistent atrial fibrillation: preliminary results of epicardial atrial electrogram analysis. *Ann Thorac Surg* 2008;86:1219–26.
243. Edgerton JR, McClelland JH, Duke D, et al. Minimally invasive surgical ablation of atrial fibrillation: six-month results. *J Thorac Cardiovasc Surg* 2009;138:109–14.
244. Edgerton JR, Jackman WM, Mack MJ. A new epicardial lesion set for minimal access left atrial Maze: the Dallas lesion set. *Ann Thorac Surg* 2009;88:1655–7.
245. Gillinov AM. Choice of surgical lesion set: answers from the data. *Ann Thorac Surg* 2007;84:1786–92.
246. Voeller RK, Bailey MS, Zierer A, et al. Isolating the entire posterior left atrium improves surgical outcomes after the Cox maze procedure. *J Thorac Cardiovasc Surg* 2008;135:870–7.
247. Scherer M, Dzemali O, Aybek T, Wimer-Greinecker G, Moritz A. Impact of left atrial size reduction on chronic atrial fibrillation in mitral valve surgery. *J Heart Valve Dis* 2003;12:469–74.
248. Doll N, Pritzwald-Stegmann P, Czesla M, et al. Ablation of ganglionic plexi during combined surgery for atrial fibrillation. *Ann Thorac Surg* 2008;86:1659–63.
249. Tung R, Zimetbaum P, Josephson ME. A critical appraisal of implantable cardioverter-defibrillator therapy for the prevention of sudden cardiac death. *J Am Coll Cardiol* 2008;52:1111–21.
250. Epstein AE, DiMarco JP, Ellenbogen KA, et al. ACC/AHA/HRS 2008 guidelines for device-based therapy of cardiac rhythm abnormalities: executive summary. A report of the American College of Cardiology/American Heart Association task force on practice guidelines (Writing committee to revise the ACC/AHA/NASPE 2002 guideline update for implantation of cardiac pacemakers and antiarrhythmia devices). *J Am Coll Cardiol* 2008;51:2085–2105 (available at www.acc.org).
251. del Rio A, Anguera I, Miro JM, et al. Surgical treatment of pacemaker and defibrillator lead endocarditis: the impact of electrode lead extraction on outcome. *Chest* 2003;124:1451–9.
252. Ngaage DL, Cale ARJ, Cowen ME, Griffin S, Guvendik L. Early and late survival after surgical revascularization for ischemic ventricular fibrillation/tachycardia. *Ann Thorac Surg* 2008;85:1278–82.
253. Ferguson TB Jr, Smith JM, Cox JL, Cain ME, Lindsay BD. Direct operation versus ICD therapy for ischemic ventricular tachycardia. *Ann Thorac Surg* 1994;58:1291–6.
254. Hunt SA, Abraham WT, Chin MH, et al. ACC/AHA 2005 guideline update for the diagnosis and management of chronic heart failure in the adult: summary article. A report of the American College of Cardiology/American Heart Association task force on practice guidelines (Writing committee to update the 2001 guidelines for the evaluation and management of heart failure). *J Am Coll Cardiol* 2005;46:1116–43.
255. Jessup M, Abraham WT, Casey DE, et al. 2009 Focused update: ACCF/AHA guidelines for the diagnosis and management of heart failure in adults. A report of the American College of Cardiology Foundation/American Heart Association task force on the practice guidelines in collaboration with the International Society for Heart and Lung Transplantation. *J Am Coll Cardiol* 2009;53:1343–82 (available at www.acc.org).
256. Nicolini F, Gherli T. Alternatives to transplantation in the surgical therapy for heart failure. *Eur J Cardiothorac Surg* 2009;35:214–28.
257. Pocar M, Moneta A, Grossi A, Donatelli F. Coronary artery bypass for heart failure in ischemic cardiomyopathy: a 17-year follow-up. *Ann Thorac Surg* 2007;83:468–74.
258. Maruskova M, Gergor P, Bartunek J, Tintera J, Penicka M. Myocardial viability and cardiac dyssynchrony as strong predictors of perioperative mortality in high-risk patients with ischemic cardiomyopathy having coronary artery bypass surgery. *J Thorac Cardiovasc Surg* 2009;138:62–8.
259. Di Salvo TG, Acker MA, Dec GW, Byrne JG. Mitral valve surgery in advanced heart failure. *J Am Coll Cardiol* 2010;55:271–82.

260. Gorman JH 3rd, Gorman RC. Mitral valve surgery for heart failure: a failed innovation? *Semin Thorac Cardiovasc Surg* 2008;18:135–8.
261. Fattouch K, Guccione F, Sampognaro R, et al. POINT: Efficacy of adding mitral valve restrictive annuloplasty to coronary artery bypass grafting in patients with moderate ischemic mitral valve regurgitation: a randomized trial. *J Thorac Cardiovasc Surg* 2009;138:278–85.
262. Trento A, Goland S, De Robertis MA, Czer LSC. COUNTERPOINT: Efficacy of adding mitral valve restrictive annuloplasty to coronary artery bypass grafting in patients with moderate ischemic mitral valve regurgitation. *J Thorac Cardiovasc Surg* 2009;138:286–8.
263. Braun J, van de Veire NR, Klautz RJ, et al. Restrictive mitral annuloplasty cures ischemic mitral regurgitation and heart failure. *Ann Thorac Surg* 2008;85:430–6.
264. Onarati G, Rubino AS, Marturano D, et al. Mid-term clinical and echocardiographic results and predictors of mitral regurgitation recurrence following restrictive annuloplasty for ischemic cardiomyopathy. *J Thorac Cardiovasc Surg* 2009;138:654–62.
265. Hansky B, Vogt J, Zittermann A, et al. Cardiac resynchronization therapy: long-term alternative to cardiac transplantation? *Ann Thorac Surg* 2009;87:432–9.
266. Yamaguchi A, Ino T, Adachi H, et al. Left ventricular volume predicts postoperative course in patients with ischemic cardiomyopathy. *Ann Thorac Surg* 1998;65:434–8.
267. Prucz RB, Weiss ES, Patel ND, Nwakanma LU, Baumgartner WA, Conte JV. Coronary artery bypass grafting with or without surgical ventricular restoration: a comparison. *Ann Thorac Surg* 2008;86:806–14.
268. Maxey TS, Reece TB, Ellman PI, et al. Coronary artery bypass with ventricular restoration is superior to coronary artery bypass alone in patients with ischemic cardiomyopathy. *J Thorac Cardiovasc Surg* 2004;127:428–34.
269. Buckberg GD, Athanasuleas CL. The STICH trial: misguided conclusions. *J Thorac Cardiovasc Surg* 2009;138:1060–4.
270. Prucz RB, Weiss ES, Patel ND, Nwakanma LU, Shah AS, Conte JV. The impact of surgical ventricular restoration on mitral valve regurgitation. *Ann Thorac Surg* 2008;86:726–34.
271. Starling RC, Jessup M, Oh JK, et al. Sustained benefits of the CorCap cardiac support device on left ventricular remodeling: three year follow-up results from the Acorn clinical trial. *Ann Thorac Surg* 2007;84:1236–42.
272. Mishra YK, Mittai S, Jaguri P, Trehan N. Coapsys mitral annuloplasty for chronic functional ischemic mitral regurgitation: 1-year results. *Ann Thorac Surg* 2006;81:42–6.
273. John R, Kamdar F, Liao K, Colvin-Adams M, Boyle A, Joyce L. Improved survival and decreasing incidence of adverse events with the HeartMate II left ventricular assist device as bridge-to-transplant therapy. *Ann Thorac Surg* 2008;86:1227–34.
274. Lietz K, Miller LW. Destination therapy: current results and future promise. *Semin Thorac Cardiovasc Surg* 2008;20:225–33.
275. Slaughter MS, Rogers JG, Milano CA, et al. Advanced heart failure treated with continuous-flow left ventricular assist device. *N Engl J Med* 2009;361:2241–51.
276. John R. Current axial-flow devices – the HeartMate II and Jarvik 2000 left ventricular assist devices. *Semin Thorac Cardiovasc Surg* 2008;20:264–72.
277. Guo C, Haider HK, Wang C, et al. Myoblast transplantation for cardiac repair: from automyoblast to allomyoblast transplantation. *Ann Thorac Surg* 2008;86:1841–8.
278. Atoui R, Shum-Tim D, Chiu RCJ. Myocardial regenerative therapy: immunologic basis for potential “universal donor cells”. *Ann Thorac Surg* 2008;86:327–34.
279. Tsang TSM, Oh JK, Seward JB. Diagnosis and management of cardiac tamponade in the era of echocardiography. *Clin Cardiol* 1999;22:446–52.
280. Schwefer M, Aschenbach R, Heidemann J, Mey C, Lapp H. Constrictive pericarditis: still a diagnostic challenge: comprehensive review of clinical management. *Eur J Cardiothorac Surg* 2009;36:502–10.
281. Myers RB, Spodick DH. Constrictive pericarditis: clinical and pathophysiologic characteristics. *Am Heart J* 1999;138:219–32.

282. Yared K, Baggish AL, Picard MH, Hoffmann U, Hung J. Multimodality imaging of pericardial diseases. *JACC Cardiovasc Imaging* 2010;3:650-60.
283. Garcia MJ. Constriction vs. restriction: how to evaluate? *ACC Current Journal Review* Jul/Aug 2003.
284. Rajagopalan N, Garcia MJ, Rodriguez L, et al. Comparison of new Doppler echocardiographic methods to differentiate constrictive pericardial disease and restrictive cardiomyopathy. *Am J Cardiol* 2001;87:86-94.
285. McDonald JM, Meyers BF, Guthrie TJ, Battafarano RJ, Cooper JD, Patterson GA. Comparison of open subxiphoid pericardial drainage with percutaneous catheter drainage for symptomatic pericardial effusion. *Ann Thorac Surg* 2003;76:811-6.
286. Ziskind AA, Pearce AC, Lemmon CC, et al. Percutaneous balloon pericardiectomy for the treatment of cardiac tamponade and large pericardial effusions: description of technique and report of the first 50 cases. *J Am Coll Cardiol* 1993;21:1-5.
287. Bertog SC, Thambidorai SK, Parakh K, et al. Constrictive pericarditis: etiology and cause-specific survival after pericardiectomy. *J Am Coll Cardiol* 2004;43:1445-52.
288. Ha HW, Oh JK, Schaff HV, et al. Impact of left ventricular function on immediate and long-term outcomes after pericardiectomy in constrictive pericarditis. *J Thorac Cardiovasc Surg* 2008;136: 1136-41.
289. O'Brien PK, Kucharczuk JC, Marshall MB, et al. Comparative study of subxiphoid versus videothoroscopic pericardial "window". *Ann Thorac Surg* 2005;80:2013-9.
290. Sengupta PP, Eleid MF, Khandheria BK. Constrictive pericarditis. *Circ J* 2008;72:1555-62.
291. Tiruvoipati R, Naik RD, Loubani M, Billa GN. Surgical approach for pericardiectomy: a comparative study between median sternotomy and left anterolateral thoracotomy. *Interact Cardiovasc Thorac Surg* 2003;2:322-6.
292. Clare GC, Troughton RW. Management of constrictive pericarditis in the 21st century. *Curr Treat Options Cardiovasc Med* 2007;9:436-42.
293. Choudhury UK, Subramaniam GK, Kumar AS, et al. Pericardiectomy for constrictive pericarditis: a clinical, echocardiographic, and hemodynamic evaluation of two surgical techniques. *Ann Thorac Surg* 2006;81:522-30.
294. Anderson CA, Rodriguez E, Shammass RL, Kypson AP. Early constrictive epicarditis after coronary artery bypass surgery. *Ann Thorac Surg* 2009;87:642-3.
295. Meissner I, Khandheria BK, Heit JA, et al. Patent foramen ovale: innocent or guilty? Evidence from a prospective population-based study. *J Am Coll Cardiol* 2006;47:440-5.
296. Lamy C, Giannesini C, Zuber M, et al. Clinical and imaging findings in cryptogenic stroke patients with and without patent foramen ovale: The PFO-ASA study. Atrial Septal Aneurysm. *Stroke* 2002;33:706-11.
297. Handke M, Harloff A, Olschewski M, Hetzel A, Geibel A. Patent foramen ovale and cryptogenic stroke in older patients. *N Engl J Med* 2007;357:2262-8.
298. Bannan A, Shen R, Silverstry FE, Herrmann HC. Characteristics of adult patients with atrial septal defects presenting with paradoxical embolism. *Catheter Cardiovasc Interv* 2009;74:1066-9.
299. Papa M, Gaspardone A, Fracasso G, et al. Usefulness of transcatheter patent foramen ovale closure in migraineurs with moderate to large right-to-left shunt and instrumental evidence of cerebrovascular damage. *Am J Cardiol* 2009;104:434-9.
300. Kedia G, Tobis J, Lee MS. Patent foramen ovale: clinical manifestations and treatment. *Rev Cardiovasc Med* 2008;9:168-73.
301. Mas JL, Arquizan C, Lamy C, et al. Recurrent cerebrovascular events associated with patent foramen ovale, atrial septal aneurysm, or both. *N Engl J Med* 2001;345:1740-6.
302. Ford MA, Reeder GS, Lennon RJ, et al. Percutaneous device closure of patent foramen ovale in patients with presumed cryptogenic stroke or transient ischemic attack. The Mayo Clinic experience. *JACC Cardiovasc Interv* 2009;2:404-11.
303. Warnes CA, Williams RG, Bashore TM, et al. ACC/AHA 2008 guidelines for the management of adults with congenital heart disease: executive summary. A report of the American College of Cardiology American Heart Association Task Force on Practice Guidelines (Writing committee to develop guidelines for the management of adults with congenital heart disease). *J Am Coll Cardiol* 2008;52:1890-947.

304. Hörer J, Müller S, Schreiber C, et al. Surgical closure of atrial septal defect in patients older than 30 years: risk factors for late death from arrhythmia or heart failure. *Thorac Cardiovasc Surg* 2007;55:79–83.
305. Gatzoulis MA, Freeman MA, Siu SC, Webb GD, Harris L. Atrial arrhythmia after surgical closure of atrial septal defects in adults. *N Engl J Med* 1999;340:839–46.
306. Ghosh S, Chatterjee S, Black E, Firmin RK. Surgical closure of atrial septal defects in adults: effect of age at operation on outcome. *Heart* 2002;88:485–7.
307. Doll N, Walther T, Falk V, et al. Secundum ASD closure using a right lateral minithoracotomy: five-year experience in 122 patients. *Ann Thorac Surg* 2003;75:1527–31.

