

CHAPTER 1

Applied Anatomy of the Prostate

Prasanna Sooriakumaran¹, Karl-Dietrich Sievert², Abhishek Srivastava¹
and Ashutosh Tewari¹

¹Prostate Cancer Institute and Lefrak Center of Robotic Surgery, James Buchanan Brady Foundation Department of Urology, Weill Cornell Medical College, New York Presbyterian Hospital, New York, NY, USA

²Department of Urology, University of Tübingen, Tübingen, Germany

OVERVIEW

- The prostate is composed of four zones: transitional, central, peripheral, and anterior fibromuscular stroma
- The ejaculatory ducts open into the prostatic urethra on either side of the verumontanum
- The external urethral sphincter (both voluntary and involuntary elements) lies immediately distal to the verumontanum while the internal urethral sphincter (involuntary) lies at the bladder neck
- The prostate lies in a hammock of nerves which can be divided into three zones: proximal neurovascular plate, predominant neurovascular bundles, and accessory distal neural pathways. Cavernous nerves exceed the posterolateral track and distribute in a more widespread range from anterolateral to posterior of the gland
- The prostate is surrounded by prostatic fascia and endopelvic fascia, with Denonvillier's fascia separating it from the fascia propria of the rectum

The basic anatomy

The prostate gland develops after puberty as a result of the testosterone surge. It reaches a size of 20cc in the normal adult, measuring 3 cm in length, 4 cm in width, and 2 cm in depth. Its size and shape can be approximated to that of a walnut. It is located at the base of the bladder, where it surrounds the proximal urethra. In this position, it lies above the urogenital diaphragm between the rectum and the symphysis pubis (Figure 1.1). It is described as having anterior, posterior, and lateral surfaces. Its base is contiguous with the bladder and its apex narrows inferiorly. There is no 'true' capsule to the prostate, but rather a 'false' capsule of fibromuscular stroma which disappears towards the apex of the gland. The prostate is surrounded by fascial structures (Figure 1.2) anteriorly and anterolaterally by the prostatic fascia, and posteriorly by Denonvillier's

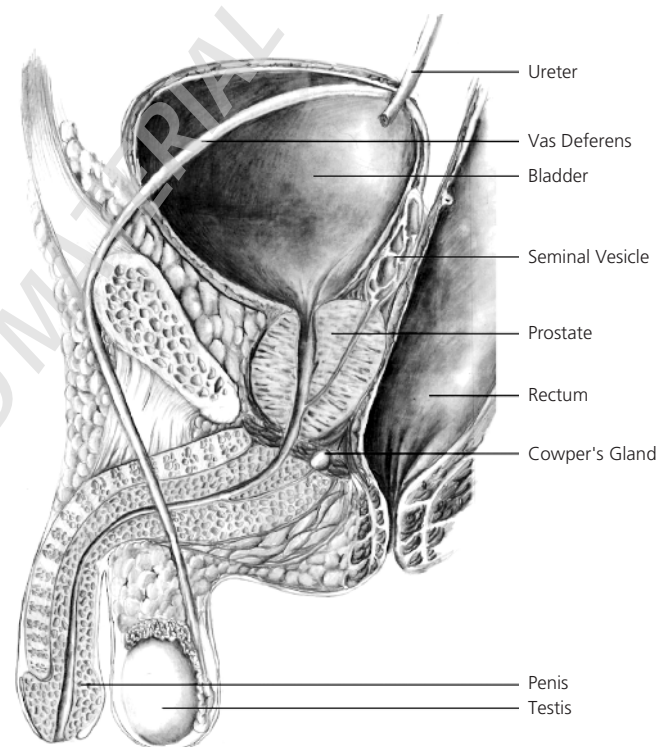


Figure 1.1 Sagittal section of the male pelvis.

fascia which separates it from the fascia propria of the rectum. Laterally, the prostatic fascia merges with the endopelvic fascia (also called the lateral pelvic or levator fascia). The prostatic base is covered with a posterior layer of detrusor apron from the bladder muscle. Abutting the prostate posteriorly are the seminal vesicles and vasa (ducti) deferentia (Figure 1.3).

The prostate gland itself is composed of ducts and alveoli that are lined by tall columnar epithelium (70%) within a stroma of fibromuscular tissue (30%). The urethra does not run straight through the middle of the gland as is the common medical student misconception, but rather takes a curved course, running anteriorly as it proceeds from proximal to distal, such that it ends up close to the prostate's anterior surface. It is lined by transitional epithelium

ABC of Prostate Cancer, First Edition.

Edited by Prokar Dasgupta and Roger S. Kirby.

© 2012 Blackwell Publishing Ltd. Published 2012 by Blackwell Publishing Ltd.

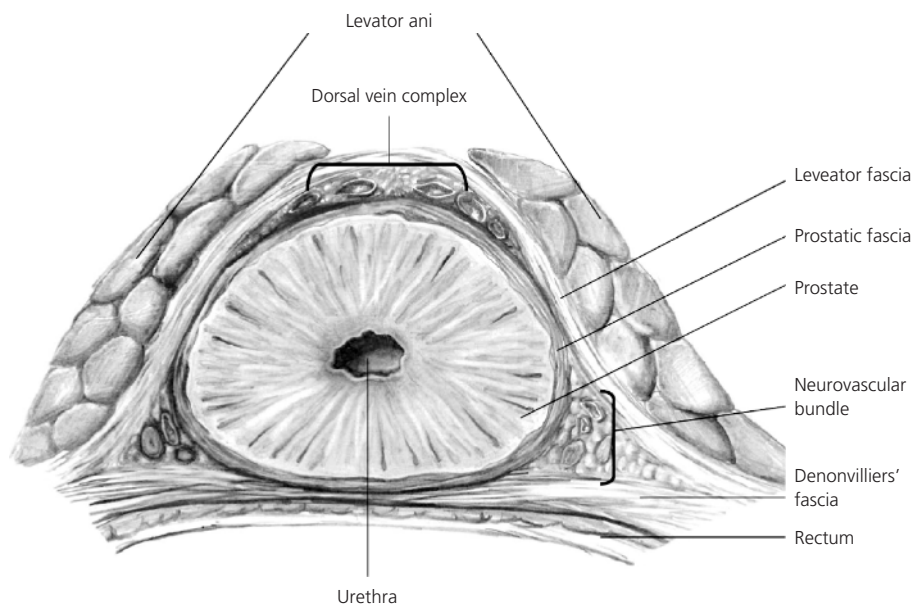


Figure 1.2 Fascial relations of the prostate.

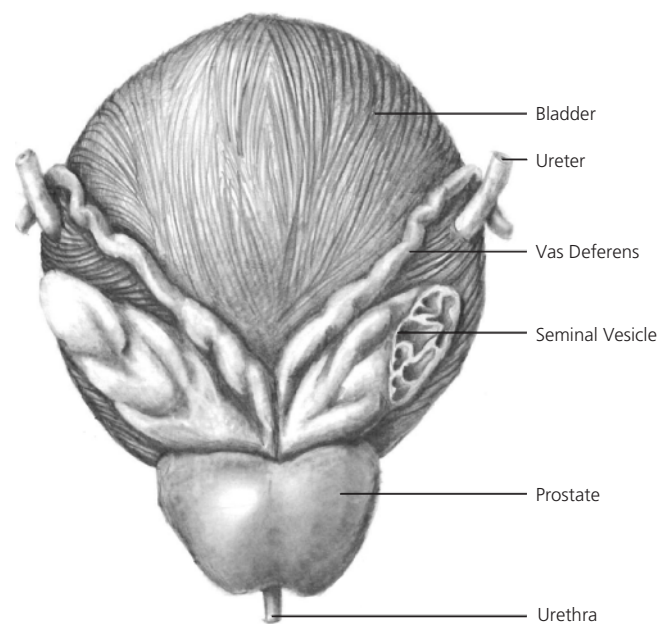


Figure 1.3 The posterior relations of the prostate.

throughout most of its length, and squamous epithelium at its distal end, hence, cancer of the urethra is either transitional cell or squamous cell carcinoma, and not adenocarcinoma as for the prostate. Those urothelial cancers are highly aggressive. A urethral crest runs the length of the prostate and disappears in the striated external urethral sphincter (rhabdosphincter). The prostatic sinuses run alongside the crest and all the prostatic glands discharge into this. The small slit of the prostatic utricle is found on the verumontanum (colliculus). The ejaculatory ducts open just lateral to the verumontanum and this is where the seminal vesicle contents are discharged (via the vasa) during emission (Figure 1.4). This allows the seminal fluid to mix with the prostatic secretions such that the final ejaculate is a mixture of these two components.

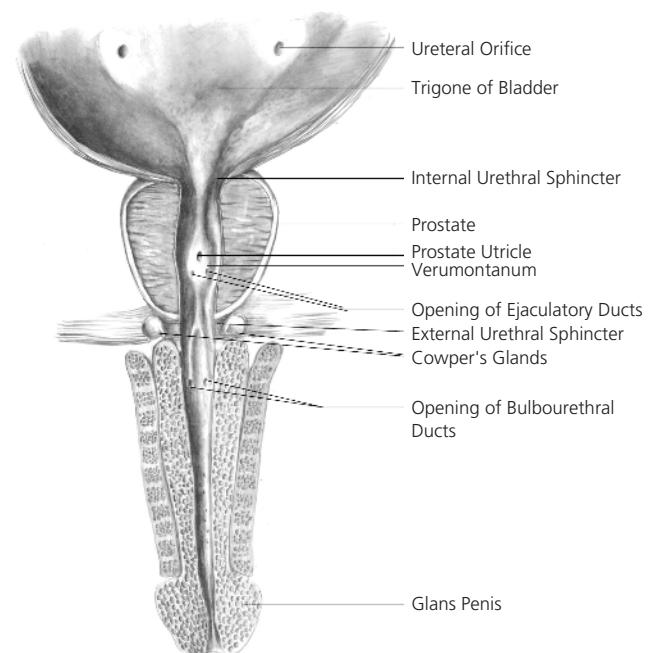


Figure 1.4 Cross-sectional anatomy of the male lower urinary tract.

Just proximal to the verumontanum is the external urethral sphincter (EUS) which is a horseshoe-shaped structure which surrounds the prostatic apex craniodorsolaterally, is deficient posteriorly, and has both striated (voluntary) and smooth muscle (involuntary) components. Hence, during a transurethral resection of the prostate (TURP) for benign prostatic enlargement (BPE), the verumontanum serves as the limit for proximal resection so that the EUS is not damaged. The internal urethral sphincter is located at the bladder neck where the prostato-vesical junction is, and is purely under involuntary control (hence, it is composed of smooth muscle). It not only completes the continence mechanism but also makes antegrade ejaculation possible. The internal urethral sphincter is

invariably damaged during a TURP so that, were the EUS to also be damaged, then urinary incontinence would be inevitable. This is why the verumontanum (or 'veru' to those that know it well) is such an important landmark during TURP.

Lymphovascular supply

The arterial supply to the prostate arises from the inferior vesical artery (itself a branch of the internal iliac artery). As the inferior vesical artery approaches the prostate gland, it becomes the prostatic artery. This then divides into two main groups of arteries: the urethral group and the capsular group. The urethral arteries penetrate the prostatic-vesical junction posterolaterally and travel inward, perpendicular to the urethra. They approach the bladder neck in the 1- to-5 o'clock and 7- to-11 o'clock positions, with the largest branches located posteriorly. The capsular artery gives off a few small branches to the false capsule of the prostate, but, in the main, runs posterolaterally to the prostate along with the cavernous nerves (to form the so-called neurovascular bundle), before ending at the urogenital diaphragm.

The venous drainage of the prostate is via the periprostatic plexus of veins to both the dorsal venous complex (of Santorini) superiorly and the inferior vesical vein to the hypogastric vein. These then both drain into the internal iliac vein. The dorsal venous complex (DVC) lies over the anterior aspect of the prostate and is the commonest source of bleeding during a radical prostatectomy. Just lateral to the DVC are the puboprostatic ligaments (PPL) which are condensations of the endopelvic fascia and attach the prostate to the pubic symphysis. The PPL may be important in maintaining continence, and are thus often spared during radical prostatectomy.

As is true of much human anatomy, the lymphatic drainage of the prostate follows that of the veins. Hence, for the prostate, this is to the obturator and hypogastric nodes, and then on to the internal iliac and aortic nodes. It is important to note, however, that prostatic lymphatic drainage is not always predictable in a stepwise manner, and 25% of cases of prostate cancer drain directly to nodes outside the pelvis (internal iliac or higher), making the extent of pelvic lymphadenectomy in high-risk prostate cancer a subject of much debate.

Zonal anatomy

Throughout the nineteenth century, the prostate was described as having two lobes, with each lobe having its own ducts. In 1906, Howe described a middle (or median) lobe. In 1912, Lowsley described five lobes: two lateral lobes, a posterior lobe, the middle lobe, and an atrophied embryological anterior lobe. However, these lobes were visible only in BPE and not the normal prostate. This lobar concept thus left much to be desired, and in 1968, McNeal replaced it with his concentric zones concept (Figure 1.5).

The transition zone consists of 5–10% of the glandular tissue of the prostate and is responsible for most of the BPE that affects the prostates of older men. The prostatic ducts lead into the junction of the pre-prostatic and prostatic urethra, and travel on the posterolateral aspects of the EUS.

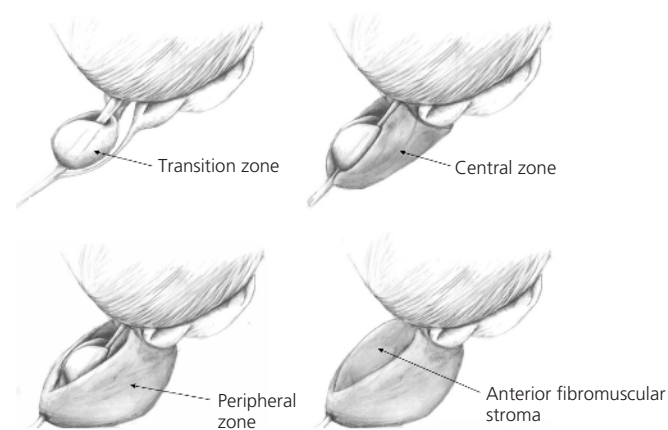


Figure 1.5 McNeal's zones of the prostate.

The ducts of the central zone arise circumferentially around the openings of the ejaculatory ducts. These glands are histologically distinct and appear to be Wolffian (mesonephric) in embryological origin. Only 1–2% of prostate cancers arise from this zone.

The peripheral zone makes up 60% of the prostatic volume. Its ducts drain into the prostatic sinus along the entire length. Some 70% of carcinomas arise from this zone which is also commonly affected by prostatitis (hence, prostatitis and cancer can co-exist in men).

The anterior fibromuscular stroma makes up approximately 30% of the gland, and extends from the bladder neck to the EUS anteriorly. It is compressed in BPE and rarely involved in prostate cancer, though anterior cancers should be suspected when repeat conventional prostatic biopsies which do not sample the anterior aspects well come back negative; hence, the use of saturation or template biopsies to sample these anterior aspects.

Neuroanatomy

Using dissections of male fetuses and newborn cadavers, Walsh and Donker first demonstrated the course of the cavernous nerve (the main nerve responsible for erectile function). This led to the concept of the macroscopic neurovascular bundle (NVB) that is located between the endopelvic and prostatic fasciae and runs along the posterolateral aspect of the prostate until it enters the urogenital diaphragm. However, recently, there have been observations that refute the dogma that the cavernous nerve is always within the NVB. Using intraoperative electrical stimulation with simultaneous measurement of intracavernosal pressure, our group, as well as others, discovered that the distribution of cavernous nerves was wider than that of the neurovascular bundle. Our group described the distribution of these nerves and they can be thought of as forming three broad zones: the trizonal concept.

The first zone is the proximal neurovascular plate (PNP) which is located lateral to the bladder neck, seminal vesicles, and branches of the inferior vesical vessels. Proximally, the PNP is derived from the pelvic (inferior hypogastric) plexus and cavernous nerves run in its most distal part. It is not only composed of parasympathetic nerves as commonly thought, but also has sympathetic contributions from

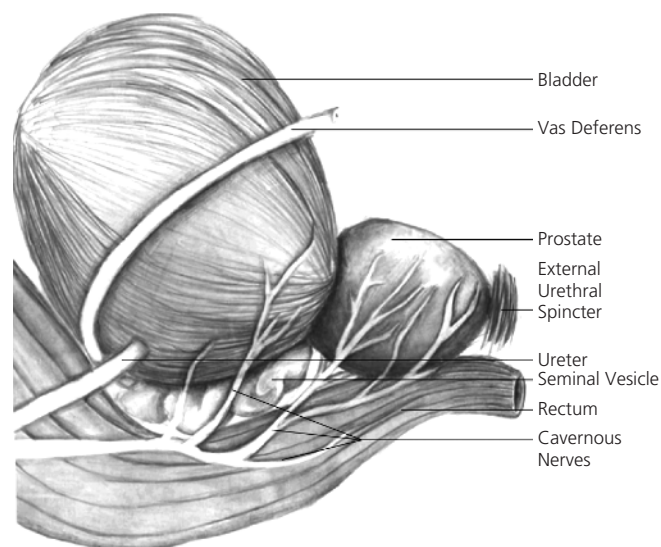


Figure 1.6 Anatomy of the cavernous nerves.

the hypogastric nerve. The second zone is the predominant neurovascular bundle (PNB) which corresponds with the classical NVB. The PNB is located between the endopelvic and prostatic fasciae at the posterolateral aspect of the prostate (the same as the NVB). The third zone is the accessory distal neural pathways (ANP). These smaller accessories off the PNB travel in the prostatic and Denonvillier's fasciae, and may serve as additional conduits for neural impulses to both the cavernous tissues and the EUS. The ANP can cross from one side to the other, and thus may also serve as a safety mechanism to provide back-up neural cross-talk between the two sides.

The prostate can be thought of as lying within a hammock of these nerves, so that the neural zones surround the majority of the gland. This concept is then very different to the conventional concept wherein the prostate lies between two NVBs that course its posterolateral aspects like train tracks.

Recent results show that the posterolateral accumulation of nerves (the NVB) is supplemented by additional main localisations in the anterior mid-part of the prostate and, even more so, on the posterior surface of the prostatic apex. The main extra-capsular prostatic nerves expand from the base to the mid of the prostate before they narrow in the posterolateral and posterior sectors around the prostate. The extent of these additional localisations of nerves seems to vary from individual to individual.

There is evidence for clear differences between the main localisations of nerve qualities along the prostate. Currently the consensus opinion for the most likely localisation of the nerve fibres responsible for erectile functionality is the posterior margin of the NVB. Recent studies provide a differential mapping of nerves of different characteristics. The localisations of cavernous nerves considerably seem to exceed the course of the posterolateral NVB both in the anterior and, to an even greater extent, in the posterior direction, resulting in a main localisation of erectile nerve fibres along an oblique shape in a base-lateral towards postero-apical track around the prostate (Figure 1.6).

Further reading

- Sievert KD, Hennenlotter J, Laible I, Amend B, Schilling D, Anastasiadis A, et al. The periprostatic autonomic nerves: bundle or layer? *Eur Urol* 2008;**54**(5):1109–16.
- Takenaka A, Tewari A, Hara A, Leung RA, Kurokawa K, Murakami G, et al. Pelvic autonomic nerve mapping around the prostate by intraoperative electrical stimulation with simultaneous measurement of intracavernous and intraurethral pressure. *J Urol* 2007;**177**(1):225–9.
- Tewari A, Peabody JO, Fischer M, Sarle R, Vallencien G, Delmas V, et al. An operative and anatomic study to help in nerve sparing during laparoscopic and robotic radical prostatectomy. *Eur Urol* 2003;**43**(5):444–54.
- Tewari A, Takenaka A, Mtui E, Horninger W, Peschel R, Bartsch G, Vaughan ED. The proximal neurovascular plate and tri-zonal neural architecture around the prostate gland: importance in the athermal robotic technique of nerve-sparing prostatectomy. *BJU Int* 2006;**98**(2):314–23.
- Walz J, Burnett AL, Costello AJ, Eastham JA, Graefen M, Guillonneau B, et al. A critical analysis of the current knowledge of surgical anatomy related to optimization of cancer control and preservation of continence and erection in candidates for radical prostatectomy. *Eur Urol* 2010;**57**(2):179–92.

Acknowledgements/Disclosures

Prasanna Sooriakumaran is the ACMI Corp. Endourological Society Fellow 2010–2011, and also receives financial support from Prostate UK.

A.K.T. discloses that he is the principal investigator on research grants from Intuitive Surgical Inc. (Sunnyvale, California, USA), the Prostate Cancer Foundation and the National Institute of Bioimaging and Bioengineering (R01 EB009388-01); he is also the endowed Ronald P. Lynch Professor of Urologic Oncology and Director of the LeFrak Institute of Robotic Surgery, Weill Cornell Medical College.