

# 1

## General Principles Related to the Diagnosis and Treatment of Impacted Teeth

Dental age	2
Assessing dental age	3
When is a tooth considered to be impacted?	5
Impacted teeth and local space loss	6
Whose problem?	6
The timing of the surgical intervention	8
Patient motivation and the orthodontic option	8

In order for us to understand what an impacted tooth is and whether and when it should be treated, it is necessary first to define our perception of normal development of the dentition as a whole and the time-frame within which it operates.

### Dental age

A patient's growth and development may be faster or slower than average and we may assess his age in line with this development [1]. Thus, a child may be tall for his age, so that his morphological age may be considered to be advanced. By studying radiographs of the progress of ossification of the epiphyseal cartilages of the bones in the hands of a young patient (the carpal index) and comparing this with average data values for children of his age, we are in a position to assess the child's skeletal age. Similarly, there is a sexual age assessment related to the appearance of primary and secondary sexual features, a mental age assessment (intelligence quotient, or IQ, tests), an assessment for behaviour and another to measure the child's self-concept. These indices are used to complement the chronological age, which is calculated directly from the child's birth date, to give further information regarding a particular child's growth and development.

Dental age is another of these parameters, and it is a particularly relevant and important assessment, used in advising proper orthodontic treatment timing. Schour and Massler [2], Moorrees et al. [3, 4], Nolla [5], Demerjian et al. [6] and Koyoumdjisky-Kaye et al. [7] have drawn up tables and diagrammatic charts of stages of development of the teeth, from initiation of the calcification process through to the completion of the root apex of each of the teeth, together with the average chronological ages at which each stage occurs.

Eruption of each of the various groups of teeth is expected at a particular time, but this may be influenced by local factors, which may cause premature or delayed eruption with a wide time-span discrepancy. For this reason, eruption time is an unreliable method of assessing dental age.

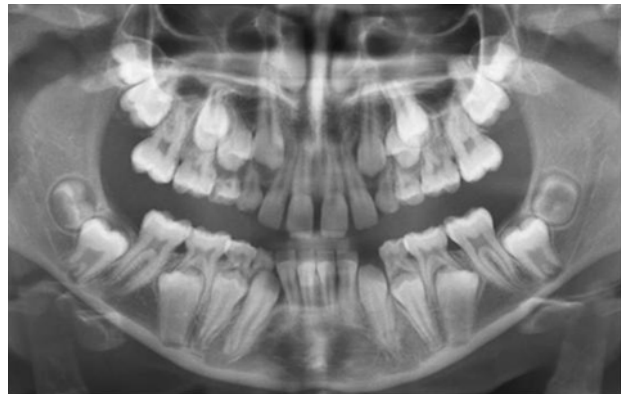
With few exceptions, mainly related to frank pathology, root development proceeds in a fairly constant manner usually regardless of tooth eruption or the fate of the deciduous predecessor. It therefore follows that the use of tooth development as the basis for dental age assessment, as determined by an examination of periapical or panoramic X-rays, is a far more accurate tool.

Thus, we may find that a child of 11–12 years of age has four erupted first permanent molars and all the permanent incisors only, with deciduous canines and molars completing the erupted dentition. If the practitioner were merely to run to the eruption chart, he would note that at this age all the permanent canines and premolars should have erupted, and he would conclude that the 12 deciduous teeth have been retained beyond their due time. The treatment

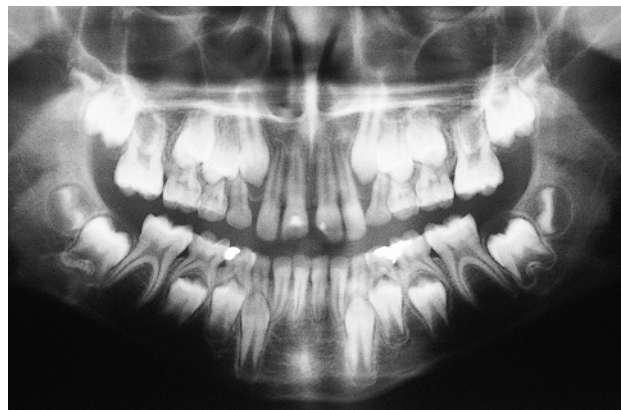
that would then appear to be the logical follow-up of this observation requires the extraction of these 12 deciduous teeth! However, there are two possibilities in this situation and, in order to prevent unnecessary harm being inflicted on the child and his parents, the radiographs must be carefully studied to distinguish one context from the other.

In the event that the radiographs show the unerupted permanent canines and premolars having completed most of their expected root length, then the child's dental age corresponds with his chronological age (Figure 1.1). The deciduous teeth have not shed naturally, due to insufficient resorption of their roots. As such, we have to presume that they are the impediment to the normal eruption of the permanent teeth. Their permanent successors may then strictly be defined as having delayed eruption. Under these circumstances it would be logical to extract the deciduous teeth on the grounds that their continued presence defines them as over-retained.

The second possibility is that the radiographs reveal relatively little root development, more closely corresponding, perhaps, to the picture of the 9-year-old child on the tooth development chart (Figure 1.2). The child's birth certificate



**Fig. 1.1** Advanced root development of the canines and premolars in a 10-year-old child defines these teeth as exhibiting delayed eruption. The overall dental age is 12–13 years, with very late developing second permanent molars, particularly on the mandibular right side.



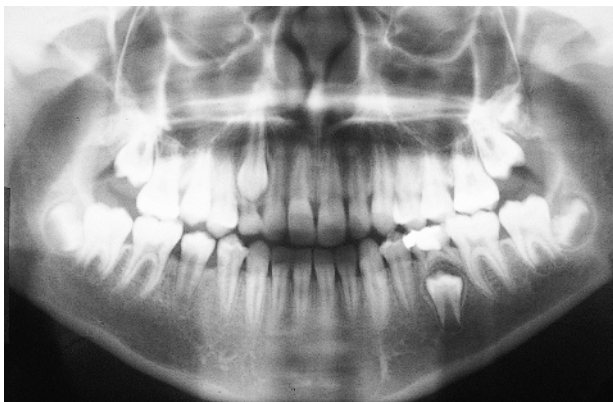**Fig. 1.2** A 12-year-old patient with root development defining dental age as 9 years. Extraction of deciduous teeth is contraindicated.

may indicate that he is 12 years of age, and this may well be supported by his body size and development, and by his intelligence. Nevertheless, his dentition is that of a child three years younger, determining his dental age as 9 years and diagnosing a late-developing dentition. Extraction in these circumstances would be the wrong line of treatment, since it is to be expected that these teeth will shed normally at the appropriate dental age and early extraction may lead to the undesired sequelae characteristic of early extraction, performed for any other reason.

From this discussion, we are now in a position to define the terms that we shall use throughout this text. The first refers to a retained deciduous tooth, which has a positive connotation and which may be defined as a tooth that remains in place beyond its normal, chronological shedding time due to the absence or retarded development of the permanent successor. By contrast and with a negative connotation, an over-retained deciduous tooth is one whose unerupted permanent successor exhibits a root development in excess of three-quarters of its expected final length (Figure 1.3). Thus, a radiograph of the permanent successor is needed to determine the status of the deciduous tooth and, by implication, its treatment.

A permanent tooth with delayed eruption is an unerupted tooth whose root is developed in excess of this length and whose spontaneous eruption may be expected in time. A tooth which is not expected to erupt in a reasonable time in these circumstances is termed an impacted tooth.

Dental age is not assessed with reference to a single tooth only, since some variation is found within the different groups of teeth. An all-round assessment must be made and, only then, can a definitive determination be offered. However, in doing this one should be wary of including the maxillary lateral incisors, the mandibular second premolars and the third molars, the timing of whose development is



**Fig. 1.3** The mandibular left second deciduous molar is retained (extraction contraindicated), since the root development of its successor is inadequate for normal eruption. The right maxillary deciduous canine, in contrast, is over-retained (extraction advised), since the long root of its successor illustrates delayed eruption.

not always in line with that of the remaining teeth [8, 9]. These are the same teeth that are most frequently congenitally missing in cases of partial anodontia (oligodontia). Indeed, reduced size, poorly contoured crown form and late development of these teeth are all considered microforms of missing teeth [9–11]. It is important to note that this variation in the timing of their development is only ever expressed in lateness, and they are not to be found in a more advanced state of development than the other teeth. If the individual dental ages of any of these variable groups of teeth is advanced, then so too is the entire dentition in which they occur.

### Assessing dental age

When studying full-mouth periapical radiographs or a panoramic film several criteria can be used in the estimation of tooth development. The first radiographic signs of the presence of a tooth are seen shortly after the initiation of calcification of the cusp tips. Thereafter, one may attempt to delineate the completed crown formation and various degrees of root formation (usually expressed in fractions), through to the fully closed root apex. By and large, orthodontic treatment is performed on a relatively older section of the child population and, as such, the stages of root formation are usually the only factors which remain relevant.

The stage of tooth development that is easiest to define is that relating to the closure of the root apex. For as long as the dental papilla is discernible at the root end, the apex is open and still developing. Once fully closed, the papilla disappears and a continuous lamina dura is seen to intimately follow the root outline. The accuracy with which one may assess fractions of an unmeasurable and merely 'expected' final root length is far less reliable and much more subject to individual observer variation.

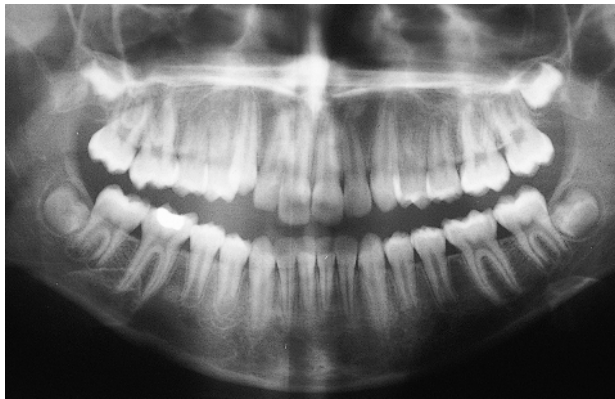Root development of the permanent teeth is completed approximately 2.5–3 years after normal eruption [5]. This allows us to conclude that, at the age of 9 years, the mandibular incisors (which erupt at age 6) will be the first teeth to exhibit closed apices and that these will usually be closely followed by the four first permanent molars. At 9.5 years, the mandibular lateral incisors will complete, while at 10 years and 11 years, respectively, the roots of the maxillary central and normally developing lateral incisors will be fully formed. This being so, when presented with a set of radiographs, we may proceed to assess dental age by following a simple line of investigation, which uses the dental age of 9 years as its starting point and then progresses forward or traces its steps back, depending on its findings.

If the mandibular central incisor roots are complete, we may presume the patient is at least 9 years old (dental age) and we may then advance, checking for closed apices of first molars (9–9.5 years), mandibular lateral incisors (9.5 years), maxillary central incisors (10 years), normally developing

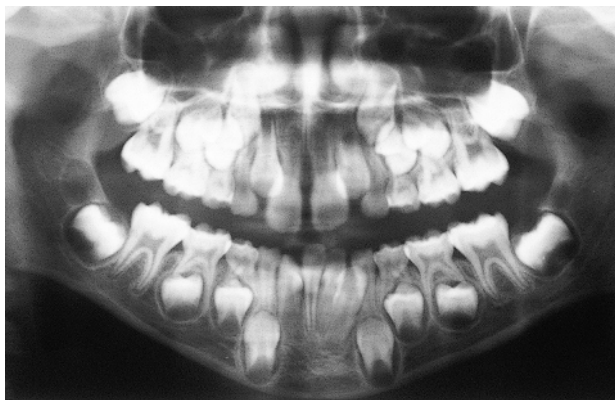maxillary lateral incisors (11 years), mandibular canines and first premolars (12–13 years), maxillary first premolars (13–14 years), normally developing second premolars and maxillary canines (14–15 years) and second molars (15 years).

By this method, we may arrive at a tentative determination for dental age on the basis of the last tooth in this sequence which has a closed apex (Figure 1.4). It is now important to relate the actual development of the remaining teeth in the sequence to their expected development that may be derived from the wall chart or from tables that have been presented in the literature. This may then provide corroborative evidence in support of an overall and definitive dental age determination.

When the dental age is less than 9 years, none of the permanent teeth will have completed their root development and the clinician will have no choice but to rely on an estimation of the degree of root development, degree of crown completion and, in the very young, initiation of crown calcification (Figure 1.5). This is most conveniently done by working backwards from the expected development at age 9 years and comparing the dental development



**Fig. 1.4** Root apices are closed in all first molars, all mandibular and three of the maxillary incisors, excluding the left lateral incisor.

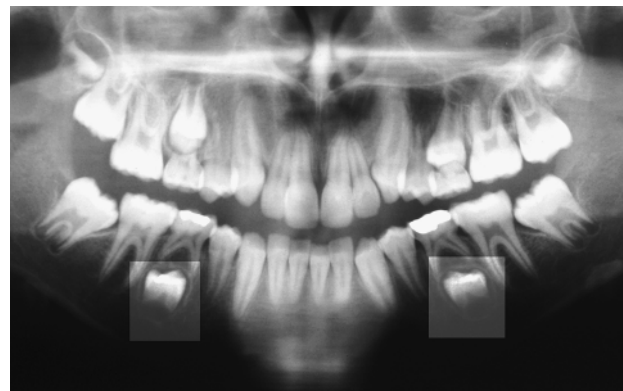


**Fig. 1.5** No closed apices. Dental age assessment 7.5 years.

status of the patient to this, beginning with the mandibular central incisors and the first permanent molars. Thus, at dental age 6 years, one would find one-half to two-thirds root length of these teeth and this could be confirmed by studying the development of the other teeth. At the same time, one should expect unerupted maxillary central incisors with half root length, mandibular canines with one-third root length, first premolars with one-quarter root length, and so on.

As pointed out earlier, variation occurs, and this may lead to certain apparent contradictions. In such cases, excluding the affected maxillary lateral incisors, mandibular second premolars or third molars from the calculation will usually simplify the procedure and contribute to its accuracy. As we have noted, early development of these teeth in relation to the development of the remainder of the dentition does not appear to occur. Individual variability is expressed only in terms of degrees of lateness. This means that the developmental status of these teeth may be used as corroborative evidence for the determination of dental age, provided that their own timing is first confirmed as being in line with the remainder of the dentition.

Unusually small teeth, coniform premolars and mandibular incisors, and peg-shaped lateral incisors are most often seen developing very much later than normally shaped and sized teeth of the same series, sometimes as much as three or four years later, and should not be included in the overall estimation. Thus, in diagnosing dental age for a patient with an abnormality of this nature, one may present a determination for the dentition as a whole, with the added notation that this individual tooth may have a much lower dental age. Typically, we may occasionally examine a 14-year-old patient who has a complete permanent dentition, including the second molars, with the exception that a mandibular second deciduous molar is present. The radiographs (Figure 1.6) show the apices of



**Fig. 1.6** Late-developing second mandibular premolars with retained (not over-retained) deciduous second molars in a child with dental age 11–12 years. The contrast and brightness of the picture have been adjusted in the relevant areas to clearly show the stage of development of these tooth buds.

the first molars, central and lateral incisors, mandibular canines and premolars to be closed, while the maxillary canines and the second molars are almost closed. However, the unerupted mandibular second premolar has an open root apex and development equivalent to about a quarter of its expected eventual length, or less. On the basis of this information, we may assess the dental age of the dentition as a whole to be 14 years. At the same time, we would have to note that the dental age of the unerupted second premolar is approximately 7 years. Having made this determination, we may now confidently say that the second premolar, individually, does not exhibit delayed eruption and the deciduous second molar is not over-retained in the context of the terminology used here. Accordingly, it would not be appropriate to extract the deciduous tooth at this time, but to wait at least a further few years, at which time the tooth may be expected to shed normally. To summarize this discussion, it is essential to differentiate between four different conditions that may exist when we encounter a dentition which includes certain deciduous teeth inconsistent with the patient's chronological age. Because the ensuing classification of these conditions is treatment oriented, the labelling of a patient within one of these groupings indicates the treatment that is required:

- 1 *A late-developing dentition.* The dental age of the patient lags behind the chronological age, as witnessed radiographically by less root formation than is to be expected at a given age, in the entire dentition. Typically, this will be evident clinically by the continued and symmetrical presence of all the deciduous molars and canines on each side of each jaw. The extraction of deciduous teeth is contraindicated, since the teeth are expected to exfoliate normally when the appropriate dental age is reached.
- 2 *Over-retained deciduous teeth.* The dental age of the patient may be positively correlated with the chronological age, but the radiograph shows an individual permanent tooth or teeth with well-developed roots, which remain unerupted. This tends to be localized in a single area and may be due to an ectopic siting of the permanent tooth bud, which has stimulated the resorption of only a portion of the root of its deciduous predecessor, but shedding has not occurred due to the persistence of the remaining part of the root or of a second and unresorbed root. Nevertheless, the condition may occasionally be found symmetrically in a single dental arch or in both arches. Extraction of the over-retained tooth or teeth is indicated.
- 3 *A normal dental age, with single or multiple late-developing permanent teeth.* This condition is commonly found in relation to the maxillary lateral incisor and the mandibular second premolar teeth, and extraction of the deciduous predecessor is to be avoided. Normal shedding of the tooth is to be expected when the root of the

permanent tooth reaches two-thirds to three-quarters of its expected length.

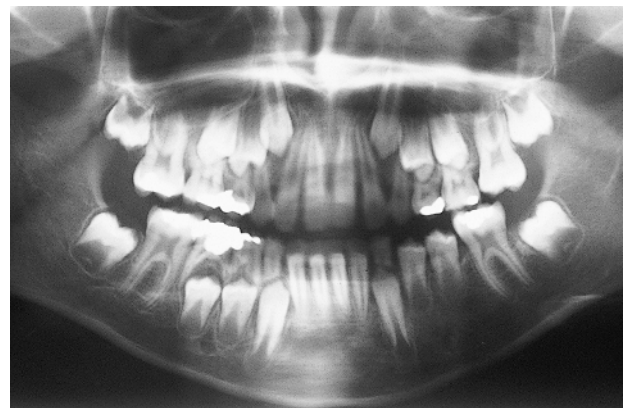- 4 *A combination of the above.* Sometimes one may see features of each of the above three alternatives in a single dentition.

The importance of interpreting the differential diagnosis for a given patient cannot be over-emphasized, since it has far-reaching effects on all the aspects of diagnosis, treatment planning and treatment timing for cases with impacted teeth.

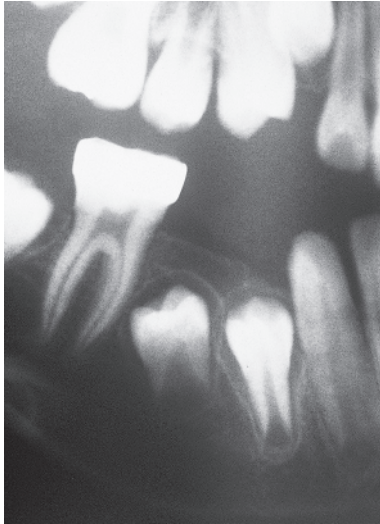
### When is a tooth considered to be impacted?

From the work of Grøn [12] we learn that, under normal circumstances, a tooth erupts with a developing root and with approximately three-quarters of its final root length. The mandibular central incisors and first molars have marginally less root development and the mandibular canines and second molars marginally more when they erupt. We may therefore take this as a diagnostic baseline from which to assess the eruption of teeth in general. Thus, should an erupted tooth have less root development (Figure 1.7), it would be appropriate to label this tooth as prematurely erupted. This will usually be the consequence of the early loss of a deciduous tooth, particularly one whose extraction was dictated by deep caries with resultant periapical pathology.

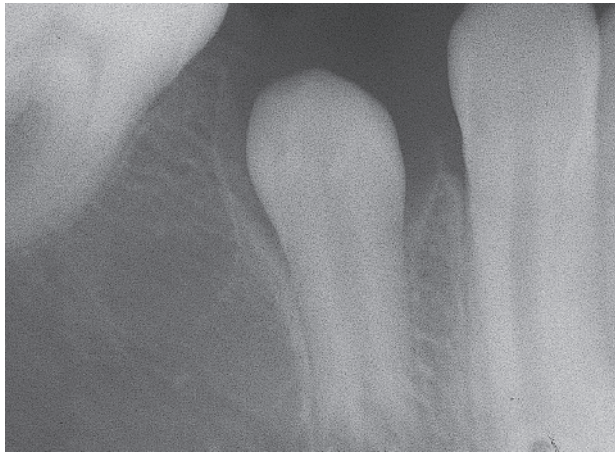At the opposite end of the scale, we find the unerupted tooth which exhibits a more completely developed root. The normal eruption process of this tooth must be presumed to have been impeded by one of several aetiological possibilities. These include such factors as a failure of resorption of the roots of a deciduous tooth, an abnormal eruptive path, a supernumerary tooth, dental crowding, a much enlarged dental follicle/dentigerous cyst, other forms of soft tissue pathology or a disturbance in the eruption mechanism of the tooth. However, a thickened



**Fig. 1.7** The left mandibular premolars are prematurely erupted, with insufficient root development.



(a)



(b)

**Fig. 1.8** (a) The right mandibular second premolar was extracted at age 8.5 years. (b) Seen at age 11, the root of the unerupted first premolar is almost completed.

post-extraction or post-trauma repair of the mucosa (Figure 1.8) should not be overlooked as a potent cause of non-eruption.

Not infrequently, and particularly in the mandibular premolar region, there may be a history of very early extraction of one or both deciduous molars. Delayed or non-eruption of the premolars will occur due to a thickened mucosa overlying the teeth. It is usually possible to palpate these teeth, their distinct outline clearly seen bulging the gum for a period of a year or more, although eruption may not occur.

### Impacted teeth and local space loss

A time lapse exists between the performance of a surgical procedure to remove the cause of an impaction and the full

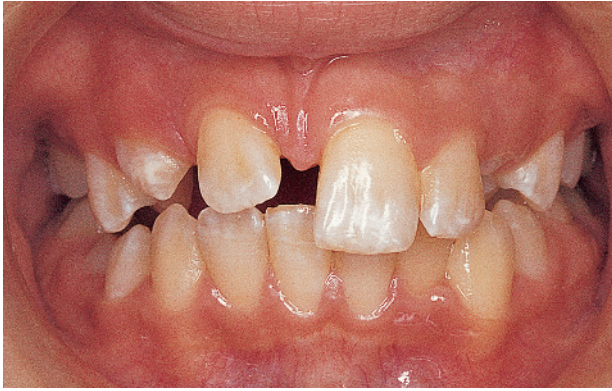eruption of the impacted tooth into its place in the dental arch. The extent of this timespan is dependent on several factors, such as the initial distance between the tooth and the occlusal plane, the stage of development of the particular tooth, the age of the patient and the manner in which hard and soft tissue may be laid down in the healing wound. During this period, therefore, local changes in the erupted dentition may occur as the result of the break in integrity of the dental arch caused by the surgical procedure, such as space loss and tipping of the adjacent erupted teeth. This intervention is no less susceptible to the drifting of neighbouring teeth than is any other factor that may produce interproximal loss of dental tissue.

With an odontome or supernumerary tooth in the path of an unerupted permanent tooth, vertical (and sometimes mesial, distal, buccal or lingual) displacement of the permanent tooth is likely to be considerable. It would be convenient if removal of the space-occupying body could be performed leaving the deciduous teeth intact, since the deciduous tooth would maintain arch integrity during the extended period needed for the permanent tooth to erupt normally. Unfortunately, in order to gain access to perform the desired surgery, one or more deciduous teeth often need to be extracted. This being so, and having regard for the long distance that a displaced permanent tooth may have to travel before it erupts into the mouth, space maintenance should be regarded as essential in most cases, particularly in the posterior area. It should be the first orthodontic procedure to be considered, preferably in advance of the surgical procedure, and it should be retained until full eruption of the permanent tooth has occurred.

Impacted teeth are often associated with a lack of space in the immediate area. This is frequently due to the drifting of adjacent teeth, although crowding of the dentition in general may be the prime cause. In such cases, the spontaneous eruption of an impacted tooth is unlikely to occur unless adequate or, preferably, excessive space is provided. It would be convenient if excision of the associated pathological entity could be comfortably delayed until this time to bring about the desired eruption and permit this corrective treatment to be attempted when the root development of the unerupted tooth is adequate. However, the surgeon will insist on removing most forms of pathology as soon as a tentative diagnosis is reached, in order to obtain examinable biopsy material for the establishment of a definitive diagnosis. Odontomes and supernumerary teeth are generally considered to be exceptions to this rule and the timing of their removal may be considered more leisurely.

### Whose problem?

Patients do not go to their dentist complaining of an impacted tooth. They are frequently unaware that this abnormality exists, since there is no pain, discomfort or swelling. Nor is it obvious to the layman that there is a



**Fig. 1.9** Unerupted right maxillary central incisor with space loss.

missing tooth, since the deciduous predecessor may not shed naturally in these circumstances. The vast majority of impacted teeth come to light by chance, in routine dental examination, and are not the result of a patient's direct complaint. As a general rule, it is the paedodontist or general dental practitioner who, during a routine dental examination, discovers and records the existence of an over-retained deciduous tooth. A periapical radiograph will then confirm the diagnosis.

There are two principal exceptions whereby an abnormal appearance may motivate the patient to seek professional advice. The first of these usually brings the patient to the office at the age of 8–10 years, when a single maxillary central incisor will have erupted a year or so earlier and the parent points out that the erupting lateral incisor of the opposite side has not left enough space for the expected eruption of the second central incisor (Figure 1.9). Often, the deciduous central incisor is over-retained. In this situation, the parent has recognized the abnormality, but will not generally have the technical understanding to suggest the possibility of impaction of the unerupted central incisor.

The second exception occurs with a 14–15-year-old patient who requests the restoration of an unsightly carious lesion on an over-retained maxillary deciduous canine. Generally speaking, the patient will be unaware that this is not a permanent tooth and it will require suitable professional advice to point out that restoration is probably not the appropriate line of treatment, but rather extraction and resolution of the impaction of the permanent canine.

A very small percentage of cases may initially be seen by their general dental practitioner because of symptoms related to relatively rare complications of impacted teeth. Among these symptoms are mobility or migration of adjacent teeth (due to extensive root resorption), painless bony expansion (dentigerous or radicular cyst) or perhaps pain and/or discharge (non-vital over-retained deciduous tooth or infected cyst, with communication to the oral cavity) [13].

Initially, the practitioner should ascertain whether there is a good chance that resolution will be spontaneous once the aetiological factor has been removed or whether active appliance therapy will be needed. To be able to do this, the exact position, long-axis angulation and rotational status of the tooth have to be accurately visualized and an assessment of space in the arch needs to be made. Following this initial assessment, the paedodontist or general dental practitioner now has to decide who should treat the problem.

Many dentists will prefer not to accept responsibility for the case and will refer the patient to an oral and maxillofacial surgeon on the premise that surgery will be needed. Many surgeons will agree that the problem is essentially surgical in nature and will proceed to remove over-retained deciduous teeth, clear away other possible aetiological factors, such as supernumerary teeth, odontomes, cysts and tumours, and will also expose the impacted permanent tooth. If the impacted tooth is buccally located, the surgical flap may be apically repositioned to prevent primary closure and to maintain subsequent visual contact with the impacted tooth after healing has occurred. This will have the effect of encouraging eruption in many cases. Until healing (by 'secondary intention') has occurred, the wound will usually be packed with a proprietary zinc oxide/eugenol-based periodontal pack (e.g. CoePack®) or a gauze strip impregnated with Whitehead's varnish, over a period of a few weeks. Careful placement and wedging of the pack between an impacted tooth and its neighbour is used by surgeons to help free the tooth to erupt naturally when the pack is later removed. Often, in the more difficult impactions, wider surgical exposure is undertaken, which includes fairly radical bone resection, both around the crown and down to the cemento-enamel junction, with complete removal of the dental follicle. The principal aims of this procedure are to clear away all possible impediments to eruption and to ensure that subsequent healing of the soft tissues does not cover the tooth again.

Following a period of many months and (for some of the more awkwardly positioned teeth) sometimes extending into years, the surgeon, family dentist or paedodontist will usually then follow up the spontaneous eruption of the impacted tooth until it reaches the occlusal level. If, at that time, alignment is poor or the tooth still has not erupted, the patient will be referred to the orthodontist.

They may alternatively and preferably refer the patient directly to an orthodontist in the first place. Certainly, the orthodontist cannot directly influence the position of the impacted tooth until appropriate access has been provided surgically and an attachment has been placed on the tooth. Nevertheless, with proper planning and management, including referral for surgical exposure at the appropriate stage in the treatment, a much higher level of quality care may be provided and in a very much shorter time-frame. This will be discussed in the ensuing chapters of this book.

### The timing of the surgical intervention

From the above discussion, we see that the timing and nature of the surgical procedure are determined by the degree of development of the teeth concerned, at the time of the initial diagnosis. At an early stage, a radiographic survey of a very young child may reveal pathology, such as a supernumerary tooth, an odontome, a cyst or benign tumour, which appears likely to prevent the normal and spontaneous eruption of a neighbouring tooth.

At this stage, it would be inappropriate to expose the crown of an immature tooth from every point of view. In the first place, one would not want to encourage the tooth to erupt before an adequate (half to two-thirds) root length has been produced. Second, at that early stage of its development, the tooth cannot be considered as impacted and, given time and freedom to manoeuvre, will probably erupt by itself. Early exposure risks the possibility of damage to the crown and to the subsequent root development of the tooth.

Nevertheless, with the discovery of the pathological condition (Figure 1.10), the potential for impaction exists and leaving the condition untreated will worsen the prognosis. Accordingly, removal of the pathological entity, without disturbing the adjacent permanent teeth or their follicular crypts, should be the aim of any treatment at that time. It may then reasonably be expected that normal development and eruption will eventually occur. Whilst this is an obviously desirable course of action, access to the targeted area may be thwarted by the presence and closeness of adjacent developing structures and delay may still be advised.

The second scenario occurs when the condition is only discovered much later. In this case (Figure 1.11), it may be seen that the superiorly displaced central incisors have fully developed, if angulated, roots and the adjacent lateral incisors have erupted with almost the full length of their roots completed. The central incisors may justifiably be defined as impacted, and the aims of surgical treatment become

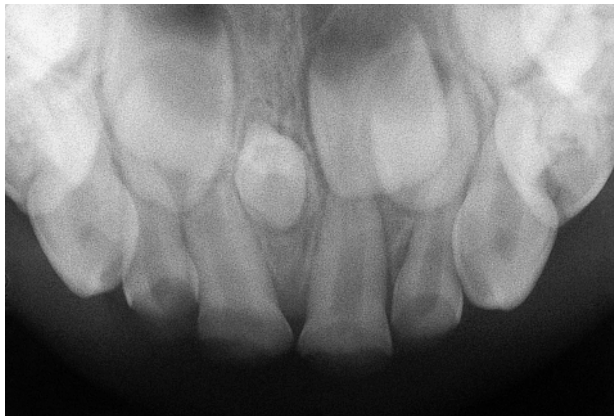two-fold: first, to eliminate the pathology, and then to create optimal conditions for the eruption of the permanent tooth, which is already late. This will usually involve exposure of the crown of the tooth. For many teeth, given adequate space in the dental arch and little or no displacement of the impacted tooth, spontaneous eruption may be expected [14, 15]. As we shall see in subsequent chapters, there are several situations and tooth types where this may not occur, or may not occur in a reasonable time-frame, often due to severe displacement of the affected tooth. For these cases, the natural eruptive potential of the tooth is supplemented and, if necessary, diverted mechanically, with the use of an orthodontic appliance.

### Patient motivation and the orthodontic option

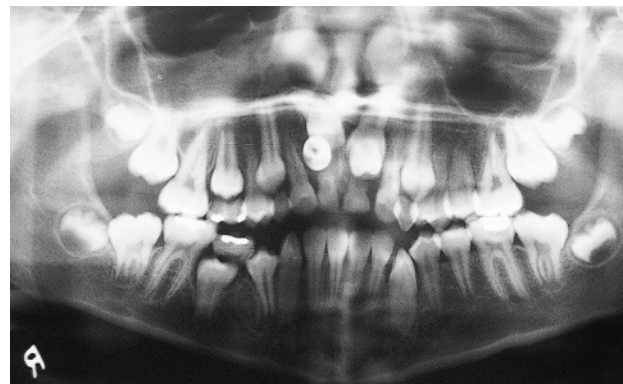Angle's class 2 malocclusion is present in between one-fifth and one-quarter of the child population in most countries of the western world [16, 17]. However, even a cursory analysis of the patient load of any given orthodontic practice will reveal that around three-quarters of the patients are being treated for this malocclusion. The reason for this has to do with the fact that a patient's appearance is adversely affected to a greater extent by this condition than by most others. In other words, appearance plays an extremely large part in the initiative and motivation on the part of the parent of this young patient to seek treatment.

A significant section of the remaining quarter of the patients in this hypothetical orthodontic practice are being treated for various less unsightly conditions (crowding, single ectopic teeth, open bites or class 3 relationships). This leaves only a few patients in this practice sample who have been referred for strictly health reasons, which may not be obvious to the patient.

Appearance is not a problem for this small group of patients, who will have agreed to orthodontic treatment only after they have been motivated by the careful and



**Fig. 1.10** A midline supernumerary tooth (mesiodens) discovered in routine periapical radiographic view of the maxillary incisor area in a 4-year-old child.



**Fig. 1.11** The panoramic view shows erupted maxillary permanent lateral incisors and over-retained deciduous central incisors. The unerupted permanent central incisors can be seen superior to the two unerupted supernumerary teeth. (Courtesy of Dr I. Gillis.)



persuasive explanations of a dentist, orthodontist, periodontist, prosthodontist or oral surgeon, regarding the ills that are otherwise likely to befall them and their dentition.

Most impactions are symptomless and, aside from maxillary central incisors, do not usually present an obviously abnormal appearance. Accordingly, motivation for treatment in these cases is minimal, and much time has to be spent with the patient before he/she agrees to treatment. The story does not end there, since these patients may often require periodic 'pep talks' to maintain their cooperation and the resolve to complete the treatment. Many of them will not maintain the required standard of oral hygiene, and, while it is difficult to justify continuing treatment in these circumstances, it is just as difficult to remove appliances from a patient in the middle of treatment, when impacted teeth have partially erupted and large spaces are present in the dental arch. For these reasons, while ambitious and innovative treatment plans may be suggested, it is essential to take motivation into account before advising lengthy and complicated treatment, since the risk of non-completion may be high.

## References

1. Krogman WM. Biological timing and the dentofacial complex. *J Dent Child* 1968; 35: 175–185.
2. Schour I, Massler M. The development of the human dentition. *J Am Dent Assoc* 1941; 28: 1153–1160.
3. Moorrees CFA, Fanning EA, Grøn A-M, Le Bret L. The timing of orthodontic treatment in relation to tooth formation. *Trans Eur Orthod Soc* 1962; 38: 1–14.
4. Moorrees CFA, Fanning EA, Hunt EE Jr. Age variation of formation stages for ten permanent teeth. *J Dent Res* 1963; 42: 1490–1502.
5. Nolla CM. The development of permanent teeth. *J Dent Child* 1960; 27: 254–266.
6. Demerjian A, Goldstein H, Tanner JM. A new system of dental age assessment. *Hum Biol* 1973; 45: 211–227.
7. Koyoumdjisky-Kaye E, Baras M, Grover NB. Stages in the emergence of the dentition: an improved classification and its application to Israeli children. *Growth* 1977; 41: 285–296.
8. Garn SM, Lewis AB, Vicinus JH. Third molar polymorphism and its significance to dental genetics. *J Dent Res* 1963; 42: 1344–1363.
9. Sofaer JA. Dental morphologic variation and the Hardy-Weinberg law. *J Dent Res* 1970; 49 (Suppl): 1505.
10. Gråhnen H. Hypodontia in the permanent dentition. A clinical and genetic investigation. *Odontol Revy* 1956; 79 (Suppl 3): 1–100.
11. Alvesalo L, Portin P. The inheritance pattern of missing, peg-shaped and strongly mesio-distally reduced upper lateral incisors. *Acta Odontol Scand* 1969; 27: 563–575.
12. Grøn A-M. Prediction of tooth emergence. *J Dent Res* 1962; 41: 573–585.
13. Shafer WG, Hine MK, Levy BM. *A Textbook of Oral Pathology*, 4th edn. Philadelphia: WB Saunders, 1983.
14. DiBiase DD. The effects of variations in tooth morphology and position on eruption. *Dent Pract Dent Rec* 1971; 22: 95–108.
15. Mitchell L, Bennett TG. Supernumerary teeth causing delayed eruption – a retrospective study. *Br J Orthod* 1992; 19: 41–46.
16. Brin I, Becker A, Shalhav M. Position of the maxillary permanent canine in relation to anomalous or missing lateral incisors: a population study. *Eur J Orthod* 1986; 8: 12–16.
17. Massler M, Frankel JM. Prevalence of malocclusion in children aged 14–18 yrs. *Am J Orthod* 1951; 37: 751–760.