1

Determination of Patient Sex and Spay–Neuter Status

Brenda Griffin

Sex Determination

Physical examination should always include determination or verification of each patient's sex. Obviously, this is essential in the context of spay–neuter programs. Wise clinicians never assume a patient is the sex they have been told, but instead always make that determination for themselves prior to performing surgery. Verifying the animal's sex, as well as assessing their reproductive status, informs and prepares the surgeon for the appropriate procedure. It may also prevent him/her from attempting to spay a male calico cat.

Sexing Dogs

Determining the sex of a dog is generally straightforward and can almost always be quickly accomplished through physical examination, including simple visual inspection of the external genitalia. In this species, the male and female anatomy are distinct and easy to identify, even in the case of very young patients. In female dogs of all ages, the vulva is readily identified on the ventral midline in the caudal inguinal area between the hind limbs (Figure 1.1a and b). It consists of two thick folds of tissue (called the *labia pudenda* or vulvar lips), which form a rounded commissure dorsally and a pointed commissure ventrally, producing a tear-drop shape. The vertical slit-like opening between the two labia (known as the vulvar cleft) marks the external orifice of the urogenital tract. Of note is that a fold of skin surrounds the canine vulva. In young puppies, the vulva is small and somewhat recessed in this fold (referred to as an "infantile" or "juvenile" vulva), but becomes increasingly prominent as the pup develops and attains puberty.

In male dogs, both the penis and the scrotum are readily identified on the ventral midline. The penis, encased in its prepuce or sheath, is located in the mid abdominal region caudal to the umbilicus, while the scrotum lies in the caudal inguinal area between the hind limbs (Figure 1.2a and b). Although minimal hair is present in the inguinal region of young puppies, within a few months the prepuce generally becomes well covered by hair, while the scrotum becomes increasingly pendulous. In puppies the testicles descend into the scrotum very soon after birth, usually within the first several days, and are typically palpable by two to four weeks of age depending on the pup's size (Ley et al. 2003). By the time a male puppy is presented for castration (i.e. at six weeks of age or older) both testes should be present in the scrotum and, if not, a tentative diagnosis of cryptorchidism should be made. Although relatively uncommon, testicular descent is sometimes delayed. Later descent is possible because the inguinal canals do not close until the time of puberty, usually around 5–10 months of age

High-Quality, High-Volume Spay and Neuter and Other Shelter Surgeries, First Edition. Edited by Sara White.
© 2020 John Wiley & Sons, Inc. Published 2020 by John Wiley & Sons, Inc.

COPYRIGHTED MATERIAL

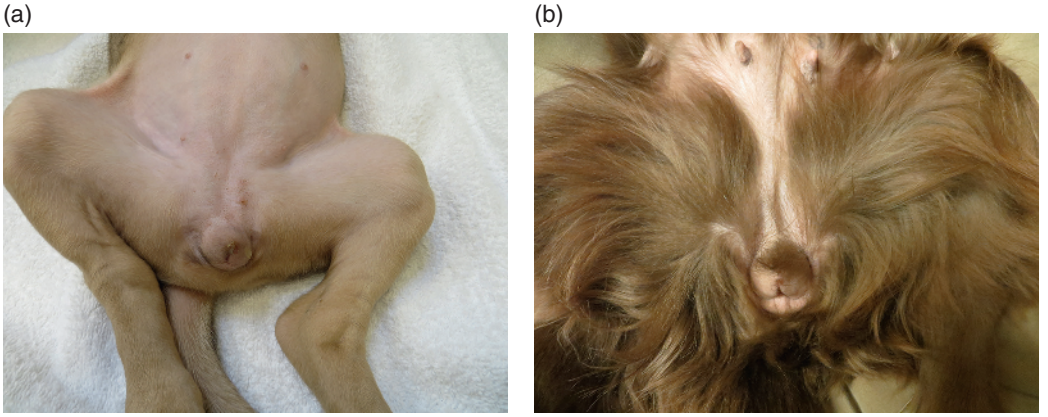

Figure 1.1 External genitalia of a female puppy (a) and adult dog (b). Note the tear-drop shape of the vulva, which is located in the caudal inguinal area between the hind limbs.

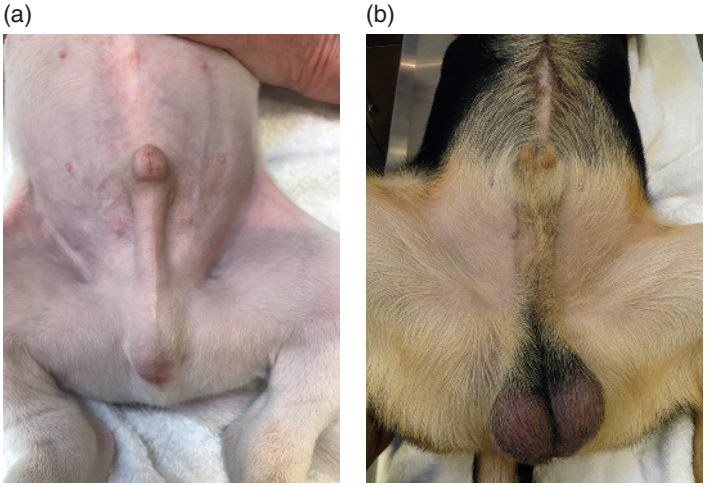

Figure 1.2 External genitalia of a male puppy (a) and adult dog (b). The penis is encased in a sheath (called the prepuce) and the testicles lie within the scrotum. Note that the adult dog's prepuce is well covered with hair and the scrotum is much more pendulous than that of the male puppy.

depending on the individual dog. Although late descent of one or both testicles is possible during this time frame, it may not be desirable to postpone castration (Griffin et al. 2016).

In dogs, the reported prevalence of cryptorchidism ranges from 0.8 to 10%, with the highest rates often occurring in certain breeds, including Chihuahuas, miniature schnauzers, Pomeranians, toy and miniature poodles, Shetland sheepdogs, Yorkshire terriers, boxers, and German shepherd dogs (Yates et al. 2003; Birchard and Nappier 2008). Despite the fact that cryptorchidism is one of the most frequently recognized congenital defects in small animal practice, it is not necessarily the most common reason that one or both testicles are not readily palpable in the scrotum of young puppies. In fact, a more common reason might be temporary retraction into the inguinal area. Indeed, when the testicles are not readily palpable in the scrotum, it may not indicate that a puppy is truly cryptorchid; rather, it may simply be a function of the fact that small, slippery testicles can easily escape

detection during examination because they sometimes retract into the inguinal area when digital pressure is applied. Furthermore, it is possible for one or both testicles to slip back through its respective external inguinal ring into the canal or abdomen. This can occur in awake patients, and in the author's experience it occurs even more commonly when a pediatric puppy is anesthetized and placed in dorsal recumbency. If the testicles are absent from the scrotum on palpation, lifting the patient into an upright position often allows the "missing" testicle(s) to descend back into its proper anatomic location in the scrotum. This can be done by holding the puppy gently around the chest to support its body weight, taking care to support the head and neck if needed, while allowing the hind limbs to gently hang down (Figure 1.3a–c). Alternatively, with the puppy in dorsal recumbency, gentle continuous digital pressure may be applied to "smooth" down the soft tissue of the groin, beginning in the area of the inguinal rings and continuing caudally toward the scrotum; this action will usually push the missing testicle(s) back into the scrotal sac (Figure 1.4a–c). These techniques can be used to locate testicles that "disappear" from the scrotum and help the surgeon avoid unnecessary exploration for the gonads. Whenever possible, the goal should be to verify that both testicles are present in the scrotum prior to surgery, so that the surgeon can plan accordingly if cryptorchidism truly exists. For information on surgical castration of cryptorchid dogs, see Chapter 14.

Sexing Cats

In contrast to dogs, determining the sex of cats can be more challenging, particularly in the case of small kittens. Unlike dogs, where the external genitalia of both sexes are readily visible in the inguinal (groin) area, the external genitalia of male and female cats are located in the perineal region beneath the tail. The small size of the species' penis and vulva, combined with the fact that these structures are generally well covered by hair, further complicates their identification. Upon inspection, the penis is not visually obvious in tomcats at any age and, prior to weaning age, the presence of the testicles in the scrotum is usually not visually apparent either. Although present in the scrotum at or within a few days of birth, the testes are simply too small to be either visually apparent or easily

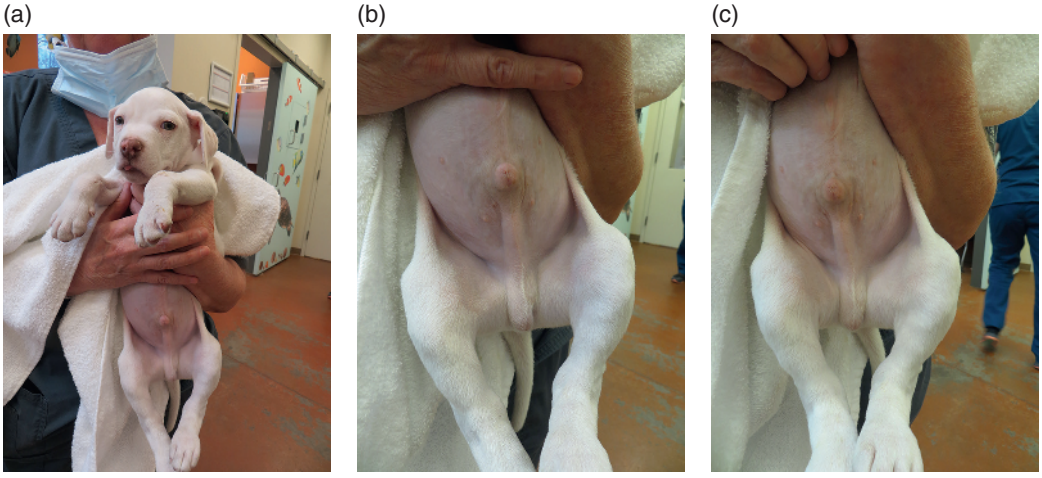

Figure 1.3 (a–c) Holding a puppy upright in this position with the hind limbs hanging down may allow the testicles to descend back into their proper anatomic location within the scrotal sac (a). Initially, the left testicle was retracted back into the inguinal area proximal to the scrotum (b), but it quickly reappeared in the scrotum when the puppy was held in this position (c).

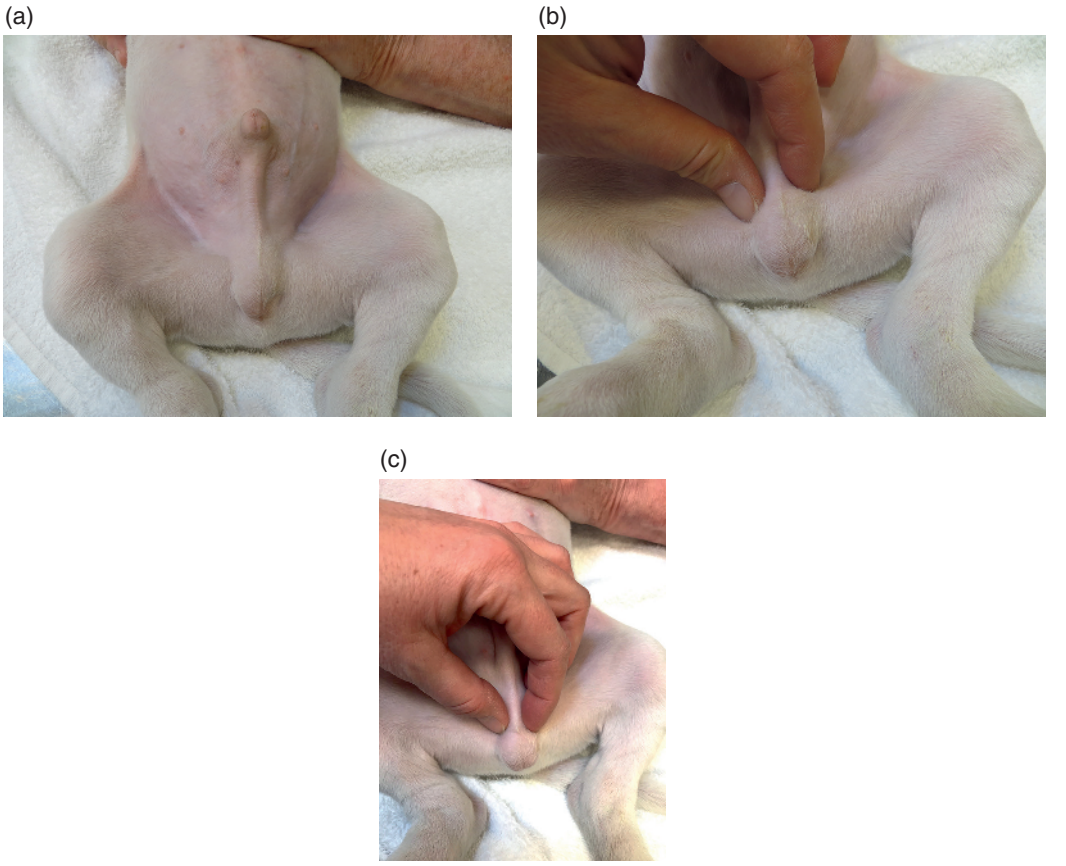

Figure 1.4 (a–c) With the puppy in dorsal recumbency, the soft tissue of the groin can be digitally "smoothed" down from the area of the inguinal rings toward the scrotum in order to gently push the testicles back into the scrotal sac.

palpable in the first few weeks of life. Although the feline penis never becomes visually obvious, the testes do quickly become larger as kittens grow and are increasingly readily visible beneath the anus by six to eight weeks of age. Usually by the time of a kitten's first veterinary visit, the testicles are readily palpable in the scrotum (Griffin 2006). If one or both testicles is absent, a diagnosis of cryptorchidism is highly likely: delayed or late testicular descent is possible but very uncommon in cats. The reported prevalence of cryptorchidism is relatively low in cats (<2%), although much higher rates have been reported in the Persian breed (Millis et al. 1992). As is the case in pediatric puppies, care must be taken to ensure accurate examination, because gentle digital pressure applied during scrotal palpation may cause small testicles to temporarily slip into the inguinal region, where they may elude detection. The techniques previously described for returning such testicles to their proper anatomic location in the scrotum can be used for kittens as well as puppies. Notably, the absence of testicles following neutering can also make sexual determination of a tomcat difficult for untrained observers.

Careful inspection of the perineal area is necessary in order to determine the sex of a cat or kitten. For adults, an individual's overall body type and/or appearance may sometimes suggest the cat's sex. For example, many male cats are larger in stature with heavier bones than female cats, and most calico cats are females (Figure 1.5). That said, such characteristics



Figure 1.5 The body appearance and coat color of the cat on the left suggest that she is a female, while the large size and masculine features of the cat on the right suggest that he is a male. In this case, the visual appearance of these cats does accurately reflect their sex. However, a wise clinician never assumes the sex of a cat based on general appearance alone; careful inspection of the perineal region is essential for accurate assessment.

should never be used to determine sex without concurrent inspection of the perineal area. When there are no obvious testicles present, visual inspection of the perineum focuses on evaluating the distance between the anus and genital opening, as well as the shape of the genital opening itself. This is accomplished by gently lifting the tail, or by stroking the dorsal rump, which often stimulates the cat to lift its tail, allowing visual inspection of this area.

In female cats, the anus and opening to the vulva are spaced very close together, such that the vulva lies just beneath the anus. Furthermore, the opening to the vulva (vulvar cleft) is shaped like a small slit or comma. As such, the female's anogenital anatomy is sometimes described as having the appearance of a semicolon (;). Figure 1.6a illustrates the anogenital anatomy of a young female kitten. In contrast, a tomcat's anus and penile opening are spaced relatively far apart since the scrotum lies between them, while the opening is shaped like a small dot or period. For this reason, the male's anogenital anatomy is sometimes described as having the appearance of a colon (:). Figure 1.6b illustrates the anogenital anatomy of a young male kitten.

The anatomy is smaller and more difficult to visualize in young kittens compared to adults, but the same rules for identification apply regardless. Thus, the anogenital anatomy of a mature female cat can also be described as a semicolon (Figure 1.7). Older intact tomcats are much easier to distinguish because the testicles, which are well covered by hair, are obvious (Figure 1.8). In contrast, neutered tomcats are commonly misidentified as female

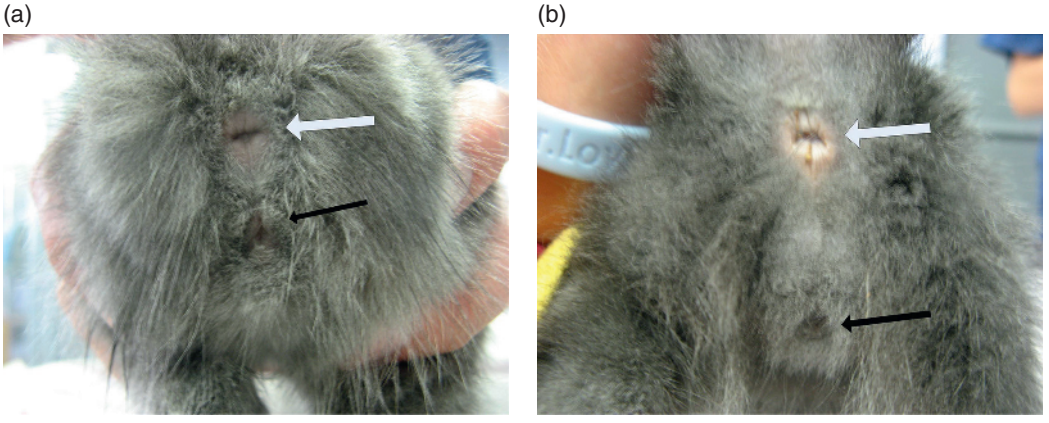

Figure 1.6 (a) Anogenital anatomy of a female kitten. White arrow: anus. Black arrow: small slit-like opening of vulva. Note the relatively small distance between the anal and genital openings. (b) Anogenital anatomy of a male kitten. White arrow: anus. Black arrow: small dot-like opening of penis. Note the relatively large distance between the anal and genital openings.

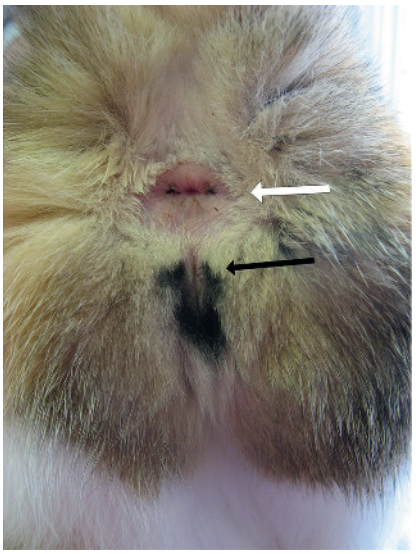

Figure 1.7 Anogenital anatomy of an adult female cat. White arrow: anus. Black arrow: small slit-like opening of vulva. Note the relatively small distance between the anal and genital openings. The anatomy is larger and easier to visualize in adult cats compared to kittens.

cats – the key to their identification is careful visual evaluation of the distance between the anus and genital opening, as well as the shape of the genital opening. Once again, the same rules apply: a neutered male looks like a widely spaced colon (Figure 1.9). That said, the absence of testes in the scrotum does not always indicate that a male cat (or dog) has been neutered.

It is also possible, albeit rare, for a male cat to present without a penis. This occurs in the case of previous perineal urethrostomy surgery. Perineal urethrostomy is a surgical treatment for tomcats with recurrent or complicated lower urinary tract obstruction. The procedure entails removal of both the penis and scrotum and creation of a urethral stoma in the perineal area immediately ventral to the anus for voiding urine. In this case, careful examination of the patient's perineal anatomy will enable the clinician to correctly identify the sex of such a patient (Figure 1.10a and b).



Figure 1.8 Anogenital anatomy of a sexually intact adult tomcat. The hair-covered testicles are readily identifiable beneath the anus. The opening to the penis is not seen because it is obscured from view by the testicles.

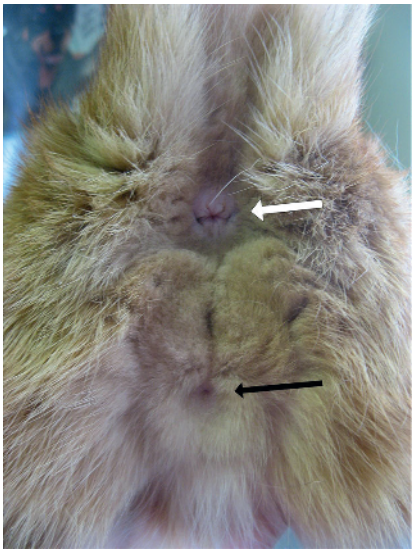

Figure 1.9 Anogenital anatomy of a neutered male adult cat. White arrow: anus. Black arrow: small dot-like opening of penis. Note the relatively large distance between the anal and genital openings. The empty hair-covered scrotum lies in between.

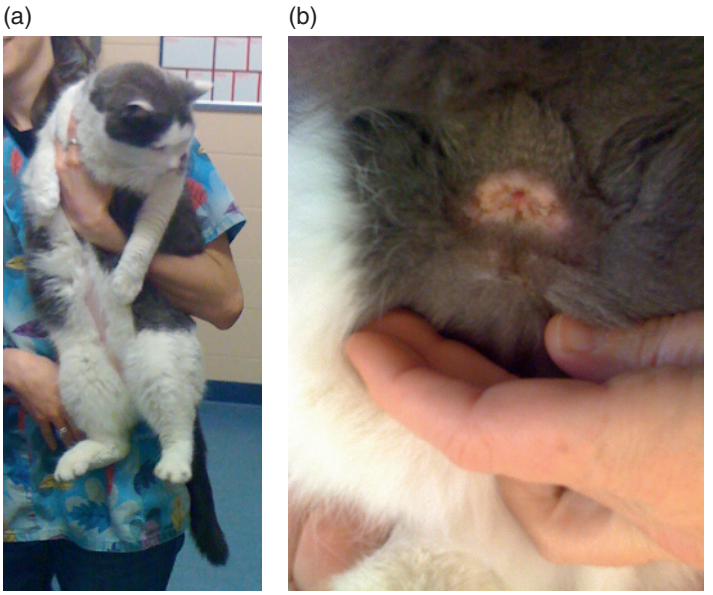

Figure 1.10 (a and b) The large size of this mature cat combined with the lack of facial jowls suggest a neutered male cat; however, inspection of his anogenital region reveals a punctate opening immediately ventral to the anus – somewhat resembling the anogenital anatomy of a female cat. Shaving the area around the urethral stoma revealed scarring from previous suture lines and careful palpation revealed the absence of either a penis or a vulva. This cat was therefore determined to be a neutered male cat that had undergone previous perineal urethrostomy surgery. *Source:* Photo courtesy of Sara White.

On rare occasions, a patient may present with a combination of both male and female sex organs. Chapter 2 includes information about male and female pseudohermaphroditism and other atypical sexual genotypes and phenotypes in dogs and cats.

Distinguishing between Sexually Intact and Previously Altered Dogs and Cats

In preparation for spay–neuter surgery, it is not only important to determine the correct sex of a dog or cat, but one should also make an attempt to determine if the animal has been previously spayed or neutered. This can be surprisingly difficult in some cases, and it behooves the clinician to approach this task carefully and cautiously, especially in the context of a spay–neuter program where the opportunity to neuter any individual animal may not present itself again in the future. Although no one wants an animal to undergo unnecessary anesthesia and surgery, this will sometimes be necessary to ensure that an animal leaves the spay–neuter clinic without the possibility of reproducing in the future. Provided there is no compelling medical reason not to proceed with such surgery, the benefits will likely outweigh the risks for the vast majority of patients when spay–neuter status remains uncertain.

That said, there will be a number of cases where the clinician can verify the spay–neuter status of the patient without surgery. First and foremost, each patient should be carefully inspected for the presence of a standard identification mark indicating previous surgical sterilization. The Association of Shelter Veterinarians (ASV) recommends the use of permanent, visibly distinct identifying marks to indicate that an animal has been spayed or neutered: a green linear tattoo should be used

to identify all neutered pet animals and ear tipping should be used to identify all community cats (Griffin et al. 2016; Figures 1.11 and 1.12). Table 1.1 describes the recommended standard locations for the placement of green linear tattoos. Note that removal of the hair from the ventral abdomen will sometimes be necessary to ensure discovery of green linear tattoos, while the presence of a "tipped" ear in a cat should be visually obvious. Surgical removal of the distal tip of one pinna is the universal symbol for denoting a neutered free-roaming cat. In contrast, ear notching is not recommended, because earflap injuries are common and easily mistaken for surgically notched ears. Caution must be taken not to mistake frostbite of the ear for a surgically tipped ear. Chapter 16 contains detailed information on techniques for identification of neutered animals. Obviously, the presence of a distinct standard mark will greatly facilitate the clinician's assessment. In animals with a distinct mark indicative of previous sterilization, no further action will be necessary.

In addition to inspection of the ventral abdomen for a green linear tattoo and the pinna for tipping, patients should also be scanned for a microchip using a universal scanner. If a microchip is identified, it may be linked through a registry to a known owner and/or medical record, which might provide definitive information regarding the pet's spay–neuter status. Importantly, the discovery of a microchip might also result in pet–owner reunification.

Table 1.1 Association of Shelter Veterinarians (ASV) recommendations for standard placement of green linear tattoos for identification of neutered dogs and cats (Griffin et al. 2016).

Sex and species	Location of green linear tattoo
Female dogs and cats	On or immediately lateral to the ventral midline incision; if a flank approach is used to spay a female patient, the tattoo should be placed in the area where a ventral midline spay incision would have been placed
Male dogs	At the caudal aspect of the abdomen in the pre-scrotal incision or pre-scrotal area immediately lateral to the prepuce
Male cats	In the area where a ventral midline spay incision would typically be placed



Figure 1.11 Green linear tattoo on the abdomen of a cat. The Association of Shelter Veterinarians (ASV) recommends the use of green linear tattoos to identify all spayed or neutered pet cats and dogs.



Figure 1.12 Ear-tipped cat. The Association of Shelter Veterinarians (ASV) recommends the use of ear tipping to identify all spayed/neutered community cats.

For those animals whose spay–neuter status remains undetermined, a thorough and systematic clinical evaluation should follow. To avoid incorrect or invalid determinations, the clinician's assessment should be based on objective findings rather than subjective impressions whenever possible.

Male Dogs and Tomcats: Reproductively Intact, Cryptorchid, or Neutered?

Most male patients that present without the presence of scrotal testicles have been previously neutered. However, a few male patients will lack scrotal testes because of either bilateral cryptorchidism or unilateral cryptorchidism, where surgical removal of the scrotal testicle was previously performed. Distinguishing these animals and ensuring that they are properly sterilized will likely have major positive impacts on their future health and wellbeing.

Definitions

As previously described, cryptorchidism is a congenital defect in which one or both of the testes do not descend into the scrotum at the appropriate time (see also Chapter 2 on common reproductive anomalies). Although unilateral cryptorchidism is more common, bilateral cryptorchidism also occurs. In either case, the testicles may be retained anywhere along their normal path of descent from the abdomen: in the abdomen, inguinal ring, or subcutaneous tissue of the groin between the inguinal ring and scrotum. Monorchidism, which is defined as the presence of only a single testicle, is exceedingly rare in both dogs and cats. For this reason, dogs and cats presenting with only one testicle should be considered cryptorchid until proven otherwise (Ley et al. 2003).

Clinical Signs

Retained testes do not produce spermatozoa, but do produce testosterone (Ley et al. 2003). Thus, the absence of scrotal testicles causes infertility; however, it does not prevent the development of androgen-dependent behaviors. For this reason, cryptorchid dogs and cats may present with a history of urine marking or spraying, fighting, attraction to females, mounting, and in the case of tomcats, urine odor (Millis et al. 1992). This is especially significant in the case of tomcats because urine spraying is a leading reason for relinquishment of pet cats by their owners (Salman et al. 2000). Cryptorchidism is an important differential diagnosis to consider, especially in adolescent or young adult tomcats, since this is the expected time for puberty and the onset of such behavioral effects of testosterone. Although relatively uncommon, this cause of spraying is associated with an excellent prognosis, since removing the retained testicle(s) most often results in resolution of spraying (Griffin 2006).

In dogs, cryptorchidism may be associated with clinical signs of feminization, including gynecomastia (mammary enlargement) and alopecia in affected dogs. This is because abdominally retained testes are at increased risk for development of Sertoli cell tumors, especially in older dogs. Retained testicles are also at increased risk of spermatic cord torsion, which can result in signs of an acute abdomen (Ley et al. 2003).

Diagnosis

In addition to obtaining any available clinical history, diagnostic evaluation should include physical examination. In the case of tomcats, physical examination alone is a highly reliable means of diagnostic determination of neuter status. Unfortunately, the same is not true for dogs and other means of diagnosis such as ultrasound and hormonal evaluation, when available, are often required.

History If history is available, it can be very helpful to the clinician tasked with determining the animal's true neuter status. Even with a history of previous castration, the

possibility of cryptorchidism should not be discounted, since it is conceivable that the surgeon may have removed only a single testicle in a unilaterally cryptorchid animal.

As previously described, cryptorchid dogs and cats may present with a history of undesirable male behaviors. Owners should be questioned carefully regarding the potential for exposure to exogenous hormones, including hormone replacement therapies and anabolic steroids, which could result in such behaviors. Use of therapeutic creams for hormone replacement is common in people and repeated exposure of pets (especially dogs) can occur as a result of licking an owner's contaminated hands (Griffin 2006; Birchard and Nappier 2008).

Physical Examination A complete physical examination should be performed, including careful inspection of the penis and palpation of the inguinal area. In cats, penile spines are reliable external indicators of the presence of testosterone, and are present in unilateral and bilateral cryptorchid cats. Penile spines begin to appear in kittens as early as 12 weeks of age and are obvious by 6 months of age (Aronson and Cooper 1967). They regress within six weeks following castration, and the mucosal surface of the penis becomes flat and smooth. Although it is theoretically possible for a neutered tomcat to develop penile spines as a result of chronic exogenous hormone exposure, this is seldom seen in cats. Thus, it is entirely reasonable for a clinician to consider the presence of penile spines as diagnostic for the presence of a testicle in a tomcat (Richardson and Mullen 1993; Johnston et al. 1996; Griffin 2006; Figure 1.13a). Likewise, the absence of penile spines in an adult tomcat is an objective finding that verifies previous neutering (Figure 1.13b). The absence of penile spines in cats less than six months of age, however, is equivocal, neither supporting nor refuting previous neutering.

Fully extruding the penis of a cat to examine its mucosal surface for the presence of penile spines can be challenging in awake patients (Figure 1.14a–c). If the penis cannot be fully extruded, heavy sedation is required to ensure a thorough examination. Even with heavy sedation, full extrusion of the penis will not be possible in some cats simply as a function of their anatomy. In kittens, the balanopreputial fold connects the penis to the prepuce and prevents full penile extrusion. Its dissolution is an androgen-dependent event, occurring as tomcats mature (Johnston et al. 1996). Tomcats are routinely neutered prior to puberty (which typically occurs between 8 and 13 months of

(a)



(b)



Figure 1.13 (a) The presence of penile spines in a male cat as seen in this photo is diagnostic for the presence of a testicle. (b) The absence of penile spines in an adult tomcat as seen in this photo verifies previous neutering. Within a few weeks of castration, penile spines atrophy and the penile mucosa becomes smooth and flat in appearance.

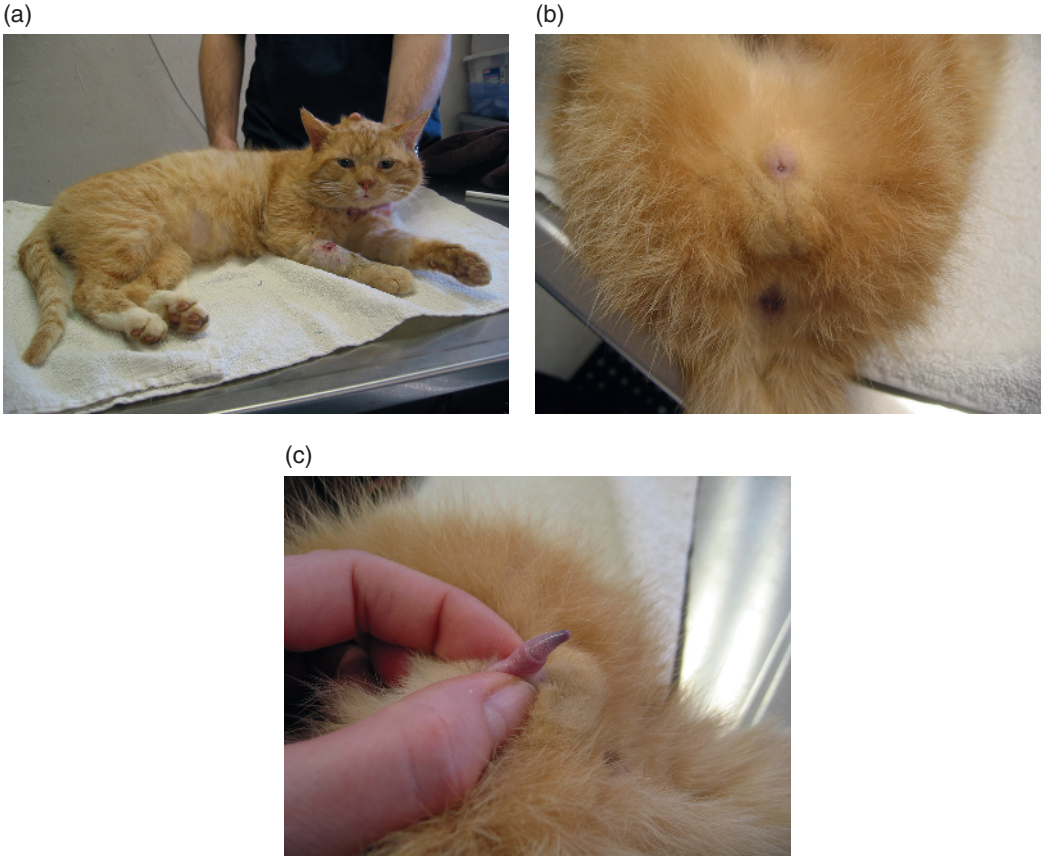

Figure 1.14 (a) This male cat, who was believed to be neutered, presented with a history of undesirable male behaviors including spraying, fighting, and breeding behavior. In this photo he has been sedated for examination. Note the presence of jowls. (b) Examination revealed the absence of scrotal testicles. Note that the anus is at the bottom of the photo in this picture. (c) Examination also revealed the presence of penile spines with full penile extrusion. This cat was a bilateral cryptorchid and both testicles were found in the abdomen at the time of surgery. Following surgery, the cat recovered uneventfully and all of the previously displayed undesirable behaviors ceased.

age) in order to prevent the development of undesired male behaviors. In many tomcats neutered prior to puberty, the balanopreputial fold remains intact and complete penile extrusion is not possible (Root et al. 1996b). Thus, if the balanopreputial fold is intact in an adult cat, this objective finding is consistent with previous neutering (Figure 1.15). In other words, the inability to fully extrude the penis of an anesthetized adult cat can be considered equally reliable as the absence of penile spines for verification of neuter status. Of note is that failure of the balanopreputial fold to regress has not been shown to be clinically significant, though it can be more difficult to exteriorize the penis for catheterization in the event the patient requires a urinary catheter (Herron 1972; Stubbs and Bloomberg 1995; Stubbs et al. 1996; Howe et al. 2000; Spain et al. 2004).

In contrast, penile barbs are not part of the anatomy of male dogs: the penile mucosa appears flat and smooth in both intact and neutered males of this species. Although dogs lack penile spines, there are some physical characteristics of their external genitalia that are consistently observable depending on the age at which



Figure 1.15 The balanopreputial fold of this neutered male cat remains intact, preventing complete extrusion of the penis. Presence of the balanopreputial fold in a post-pubertal male cat indicates previous castration.



Figure 1.16 The infantile appearance of the penis and prepuce of this mature adult beagle is strong evidence that he was neutered at an early age.

an individual dog is neutered. When dogs are neutered as very young puppies (i.e. <12 weeks of age), the penis, *os penis*, and prepuce remain infantile in their appearance compared to those neutered at a more traditional age or as mature adults (Olson 2003). Thus, the presence of an infantile penis and prepuce in an adult dog without testicles is an objective finding that supports previous castration (Figure 1.16).

Physical examination should also include careful palpation of the entire inguinal region (i.e. from the level of the inguinal rings to the scrotum). When compared to scrotal testicles, retained testicles are generally grossly smaller (Ley et al. 2003; Figure 1.17). Testicles located



Figure 1.17 Comparison of scrotal testicle (left) and retained testicle (right) from a cryptorchid tomcat. Retained testicles are generally smaller than scrotal testicles. The retained testicle pictured here was removed from the inguinal ring and palpation was not possible through the large inguinal fat pad of this cat.

in the inguinal region are often difficult to palpate and may be obscured by inguinal fat. In some instances, irregular deposits of fat may be mistaken for retained testicles. Abdominally retained testicles are generally too small to palpate, except in the case of Sertoli cell tumors in dogs, which are frequently quite large. In this case, signs of feminization may also be apparent on physical examination. In dogs, the presence of an obvious pre-scrotal scar may suggest previous neutering, but should be interpreted with some skepticism, since scars may also result from unrelated skin trauma.

Both dogs and cats develop secondary sex characteristics as they mature to puberty. Androgen-dependent physical changes tend to be more consistent and dramatic in tomcats compared to male dogs. For cats, these features include the formation of jowls, widening of the neck, and thickening of the skin (Figure 1.18). Although most tomcats do not develop distinct jowls before two years of age, their skin may subjectively appear "tougher" or more difficult to puncture with a hypodermic needle. In dogs, secondary sex characteristics may be less obvious and vary considerably among breeds. This is not surprising, given that dogs possess more physical diversity than any other species. In general, intact male dogs tend to be more



Figure 1.18 Comparison of facial features of a neutered male cat (left) and an intact tomcat (right). Note the thick neck and the presence of large jowls in the intact tomcat.

massive and muscular compared to neutered males, and changes in the hair coat may occur following neutering. That said, such changes are highly subjective, influenced by many factors besides neuter status, and often go unrecognized except by those who are extremely familiar with a specific breed.

Diagnostic Imaging When available, ultrasonographic examination of the abdomen and inguinal area may allow visualization of retained testicles. Although this may provide the clinician with additional useful information, it is not required, nor is it necessarily definitive for determination of neuter status in dogs and cats. This modality can be particularly helpful for diagnosing testicular tumors and torsion in dogs. Likewise, radiography can also be a useful diagnostic tool in such cases. However, radiography is otherwise unrewarding for detection of retained testicles because of their small size and indistinct radiodensity.

Hormonal Evaluation In dogs, hormonal evaluation is the most definitive pre-surgical diagnostic test available for determination of neuter status. Hormonal evaluation can also be used for diagnosis of retained testicle(s) in the cat, but is not necessary because the presence of penile spines serves as a reliable "bioassay" for testosterone in this species. In both dogs and cats, testosterone is secreted in an episodic, pulsatile fashion throughout the day. As such, a single resting sample where no detectable testosterone is measured does not rule out the presence of a testicle (Johnston et al. 1996). In contrast, a hormone stimulation test is a highly reliable indicator of testosterone production. Stimulation of testosterone secretion can be accomplished by the administration of human chorionic gonadotropin (hCG) or gonadotropin-releasing hormone (GnRH). Baseline serum samples are collected prior to administration and again at one or more intervals following administration. Various protocols are available from diagnostic laboratories. An increase in serum testosterone is diagnostic for the presence of a testis (Memon et al. 1992; Johnston et al. 1996).

More recently, tests for measuring serum concentrations of luteinizing hormone (LH) and anti-Mullerian hormone (AMH) have been investigated as diagnostic aids for determining neuter status in dogs and cats (Olson et al. 1992; Gunzel-Apel et al. 2009; Wheeler and Kutzler 2010; Place et al. 2011; Axner and Strom-Holst 2015; Themmen et al. 2016; Alm and Holst 2018; Krecic et al. 2018; Morrow et al. 2018). In the reproductively intact male, testosterone production by the testes inhibits hypothalamic production of GnRH, in turn

inhibiting pituitary production of follicle-stimulating hormone and LH. Following castration, serum concentrations of these reproductive cascade hormones increase as a result of the lack of negative feedback from the gonads. A commercially available point-of-care LH test (Witness® LS, Zoetis, Parsippany, NJ, USA), which was originally developed as a means of determining ovulation timing in dogs, has been used as a diagnostic aid to elucidate neuter status (Figure 1.19). A "positive" test is consistent with previous neutering, while a negative result supports the need for surgery. In a study of 53 male cats, the reported sensitivity and specificity were 85 and 95%, respectively (Krecic et al. 2018). In a study of 10 dogs, the reported sensitivity and specificity were 100% (Wheeler and Kutzler 2010). Point-of-care tests have the obvious advantages of being very convenient and providing rapid, same-day results. As more data from field studies becomes available to evaluate the performance of this patient-side test in dogs, its use may become an increasingly attractive option for determination of neuter status.

A final diagnostic option is measurement of serum concentrations of AMH through a reference laboratory. AMH is continuously produced by the Sertoli cells of the testes in post-pubescent male dogs and tomcats, and production continues throughout an animal's reproductive life. Thus, positive test results in a post-pubertal patient are consistent with the need for surgery. In contrast, negative test results suggest previous neutering (Axner and Strom-Holst 2015; Themmen et al. 2016). Reported sensitivities and specificities of AMH assays vary: in a study of 27 male cats, the reported sensitivity and specificity were 100% (Axner and Strom-Holst 2015), whereas in a study of 98 male dogs, the sensitivity and specificity were 76 and 100%, respectively (Themmen et al. 2016). In the latter study, AMH testing correctly identified all neutered male dogs, but unfortunately failed to correctly identify a significant number of intact male dogs.



Figure 1.19 Witness LH test device. A commercially available point-of-care LH test (Witness LS, Zoetis, Parsippany, NJ, USA) may be used to distinguish reproductively intact and spayed dogs and cats. This test is simple to use and requires only four drops of serum.

Assessment and Follow-Up

Spay–neuter programs should have policies and protocols in place to optimize identification of previously neutered male dogs and cats and to ensure proper sterilization of cryptorchid animals.

Verification of previous castration is generally much easier in cats, since examination of the penis allows for an accurate assessment in the majority of cases. Only in very young kittens and very recently neutered cats may findings be equivocal. When penile spines are present, surgery is indicated. Conversely, if the cat is verified to be neutered based on the absence of penile spines or an intact balanoprepucial fold in an adult cat, then marking the cat in accordance with the ASV guidelines for identification of neutered cats is indicated. No one will ever have to wonder again!

In dogs, verification of neuter status is frequently more challenging. The one exception might be an adult dog with an infantile penis. In this case, it is probably safe to assume the patient has been previously castrated. In the absence of such a finding, hormonal testing will be necessary for diagnostic confirmation, unless a testicle is readily palpable in the inguinal area or a Sertoli cell tumor is diagnosed. Point-of-care LH test kits are a convenient and promising option. When such hormonal testing is not an option due to lack of resources, assessment of neuter status should be based on

a subjective clinical judgment considering all available information. The decision as to whether or not to pursue additional diagnostics or surgery should take into account the dog's breed, since there are significant known breed predilections for cryptorchidism. Considering all of the information available, if the clinical suspicion for cryptorchidism remains low, it is reasonable to assume that the dog has been previously neutered. However, without definitive determination, neuter identification marking should not be performed. Owners can be advised to watch for signs such as excessive urine marking or attraction to females that could alert them to the need for additional assessment.

Bitches and Queens: Reproductively Intact or Spayed?

The accurate identification of female dogs and cats that have been previously spayed poses a longstanding clinical dilemma. Bitches and queens with unknown histories are commonly presented to veterinarians and animal shelters. Some of these animals undergo anesthesia and surgery, only to reveal that previous ovariohysterectomy has been performed. This can translate into trauma for the animal, expense for the owner, and frustration for the attending veterinarian. It is important to recognize, however, that in the context of most spay–neuter programs, it may not be possible to make a definitive determination of spay status in many cases. As such, surgical exploration will often be the best course of action. Not only is it diagnostic, it will ensure that no female patient leaves without the benefit of an ovariohysterectomy. That said, in some cases surgery can be avoided. Avoiding surgery is especially important for patients that are assessed as potentially "high risk" for anesthesia, such as morbidly obese and brachycephalic animals.

Diagnosis

In addition to obtaining any available clinical history, diagnostic evaluation should also include a thorough physical examination. Imaging may be useful in some cases, but hormonal evaluation, when available, will provide the most definitive diagnostic information without surgery.

History and Clinical Signs

If history is available, it can be very helpful to the clinician tasked with determining the animal's true spay status. Even with a history of previous spaying, the possibility of ovarian remnant syndrome should not be discounted, especially in cats, since it has been reported to occur more frequently in this species compared to dogs (Wallace 1991; Miller 1995). Owners should always be questioned carefully regarding possible displays of estrus behavior or attraction of males. Cat owners may note vocalization, rubbing, and "friendly" behavior. Many estrual queens stretch, squirm, and roll in lateral recumbency, opening and closing their paws. They may also crouch and assume a lordosis stance while treading in place with their hind limbs and deflecting their tail laterally (Figure 1.20). Most cats experience winter anestrus, therefore time of year should be considered when assessing the presence of estrus signs. Cat owners may confuse normal affiliative or greeting behaviors such as head rubbing or tail waving with signs of estrus. Lordosis and treading can usually be induced in estrual queens by stroking the back or dorsal rump. This can be done during the course of an exam



Figure 1.20 Cat in heat. An estrual queen exhibits a typical display of lordosis and tail deflection.

to help verify the presence of behavioral signs of estrus (Griffin 2001, 2006).

In the bitch, estrus is accompanied by dramatic physical changes, including marked enlargement of the vulva and bloody discharge, which are easy to recognize (Figure 1.21). In contrast, physical changes accompanying estrus are very subtle in cats. The queen's vulva becomes only slightly edematous and hyperemic, but remains so small and well covered by hair that changes are rarely noticed. Furthermore, vulvar discharge is scant, and because of the fastidious grooming habits of the queen, rarely noted (Griffin 2001). In cases where the presence of behavioral estrus is present or suspected at the time of examination, vaginal cytology to look for the presence of cornified vaginal epithelial cells can be performed for confirmation. Owners should also be questioned carefully regarding potential exposure to exogenous hormones, such as hormone replacement therapy, that could account for clinical signs (Griffin 2006).

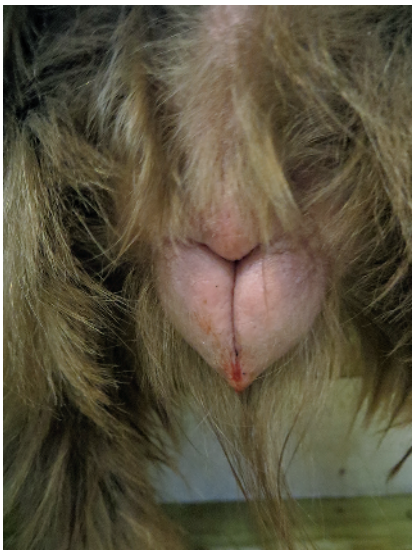

Figure 1.21 Dog in heat. Note the marked swelling of the labia and the presence of bloody discharge.

Physical Examination A complete physical examination should be performed. The overall body condition should be noted. Metabolic rate has been shown to significantly decrease and a tendency toward obesity has been well documented in spayed cats compared to reproductively intact queens (Flynn et al. 1996; Root et al. 1996a). If a cat is very overweight, a clinical suspicion that she has been previously spayed is warranted. In contrast, changes in metabolic rate following ovariohysterectomy have not been as well defined in bitches. These findings are consistent with the common clinical experiences of many surgeons, who find themselves regularly performing "big fat dog spays" but rarely performing ovariohysterectomies in highly obese feline patients.

To facilitate examination, the ventral abdomen should be shaved from the umbilicus to the pubis, and the skin of the midline carefully inspected for the presence of a scar. In some cases, sedation will be necessary for hair removal and thorough examination. Using a good light source to aid in inspection of the area is often rewarding. Applying a small amount of isopropyl alcohol to the skin may aid in visualization of linear scars that may otherwise remain undetected. In the author's experience, palpation is not a reliable indicator of the presence of a spay scar. Some intact females have a prominent linea alba that may be mistaken for a scar, and spayed cats and dogs frequently have scars that are not readily palpable, yet may be visualized once the overlying hair is removed. Although looking for a ventral abdominal scar is recommended, discovery of a scar does not verify that an animal has been previously spayed with certainty and should never be used as the sole criterion for assessment. The clinician must interpret this finding cautiously and in context with all other findings (e.g. history, body condition score, mammary development, etc.) in order to make the best possible assessment. In some cases, scars may be the result of other abdominal procedures such as C-section (Figure 1.22). In addition, previously spayed



Figure 1.22 Intact bitch with a ventral abdominal scar from previous C-section. Note the well-developed mammary glands and vulva. Although looking for a ventral abdominal scar is recommended, discovery of a scar does not verify with certainty that an animal has been previously spayed and should never be used as the sole criterion for assessment.

animals may lack any such evidence of an abdominal incision, particularly if the animal was spayed at a very young age or if a flank approach was used (Griffin 2006).

Careful inspection of the mammary glands should also be performed. Spayed cats and dogs typically have atrophied mammary glands and very small teats subjectively, compared to the well-developed glands and prominent teats of intact females (Figure 1.22). In particular, the teats of cats spayed at very young ages remain underdeveloped and appear as tiny specks (Figure 1.23). Finally, examination of the vulva is indicated in bitches: when ovariohysterectomy is performed prior to puberty, the vulva generally remains small and underdeveloped compared to intact females. When spayed following maturity, well-developed bitches typically experience some vulvar atrophy, but the vulva is unlikely to appear infantile (Olson 2003). That said, dogs can be very diverse physically and the vulva of some intact bitches will appear very small during anestrus, and some well-developed bitches will experience dramatic vulvar atrophy following ovariohysterectomy (Figure 1.24a and b). Although

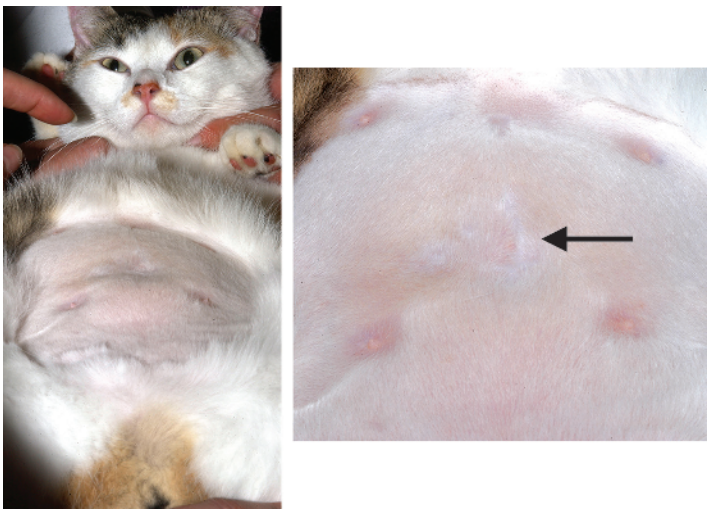

Figure 1.23 The shaved abdomen of a spayed cat. Careful inspection of the mammary glands may be helpful in distinguishing reproductively intact and spayed queens, since the mammary glands of spayed cats are generally underdeveloped or atrophic. Note the presence of a "spay scar" (arrow). This cat's body condition with ample abdominal fat also suggests that she is spayed.

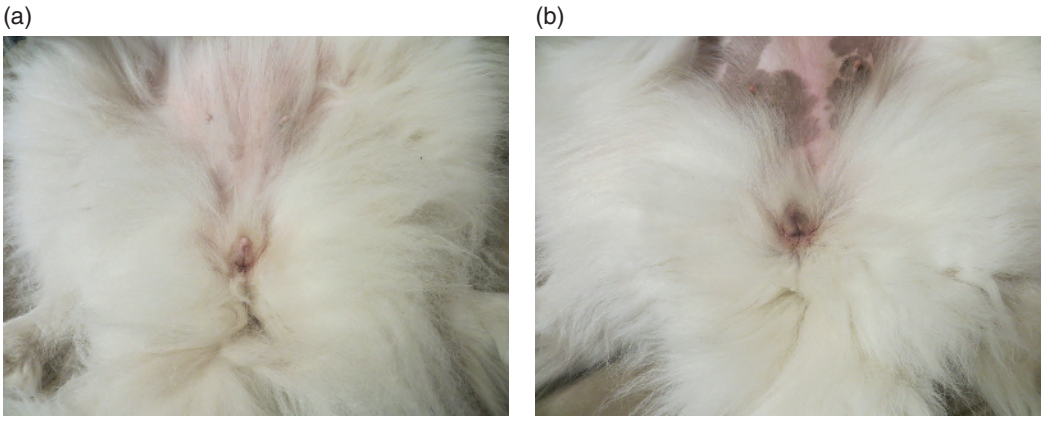

Figure 1.24 Clinicians should never use small vulvar size as a singular means of assessing spay status. In each photo, the vulva appears relatively small and underdeveloped, yet the reproductive status and history of these two bitches are very different. (a) Vulva of a three-year-old intact Great Pyrenees bitch. She whelped a litter six months prior to this photograph being taken. (b) Vulva of an eight-year-old spayed female Great Pyrenees bitch. She was spayed one year prior to this photo being taken.

examination of the external genitalia is recommended, neither mammary development nor vulvar size should be used as the sole criterion for assessment. As always, the clinician must interpret findings cautiously and in context with all other findings.

Diagnostic Imaging When available, diagnostic imaging may be useful in some cases. If uterine enlargement or other pathology is present, radiography can sometimes be helpful, but otherwise this imaging modality is generally unrewarding for confirming or refuting the presence of the ovaries and uterus because of their indistinct radiodensity. In contrast, a highly skilled ultrasonographer with quality equipment should be able to identify the female reproductive tract in a cooperative patient. Practically speaking, however, this technique is infrequently used to assess spay status.

Hormonal Evaluation If reproductive status cannot be determined based on physical examination, hormonal evaluation is ideally recommended prior to consideration of exploratory surgery. In some cases, owners may elect to wait and see if signs of behavioral estrus appear. Whenever possible, definitive determination of reproductive status should be made.

Numerous studies have evaluated the diagnostic usefulness of LH and AMH tests for determination of spay status in female dogs and cats (Lofstedt and VanLeeuwen 2002; Place et al. 2011; Axner and Strom-Holst 2015; Themmen et al. 2016; Alm and Holst 2018; Krecic et al. 2018; Morrow et al. 2018). Serum concentrations of LH increase after ovarian removal as a result of the lack of negative feedback from the gonads. In reproductively intact females, the normal sequence of endocrinological events is such that LH concentrations remain at low basal concentrations, except for very brief periods when ovulation occurs and gonadotropin-releasing hormone stimulates LH release. After this sudden spike, LH returns to basal concentrations, usually within 24 hours. Negative feedback control of LH results from ovarian estradiol secretion and maintains LH at basal concentrations. Following ovariohysterectomy, this negative feedback control is removed, and LH concentrations remain increased indefinitely. Commercially available LH test kits will be "positive" in spayed animals, while negative results are consistent with the need for surgery. Patients should not be tested when signs of estrus are present to avoid false positive test results which occur during the LH

surge. A study of 216 female cats revealed a 91% specificity and a 92% sensitivity using the Witness LH test (Krecic et al. 2018). In this study, it was unknown whether cats were displaying signs of estrus at the time of presentation for ovariohysterectomy. A study of 236 cats revealed a sensitivity of 69% and a specificity of 100% using the same test (Morrow et al. 2018). In other words, the test correctly detected all intact queens, and importantly there were no false positive results that would have incorrectly identified an intact cat as previously spayed. For cats without signs of heat, the point-of-care Witness LH test appears to be a highly useful means of distinguishing intact and spayed cats, while avoiding the need always to perform surgery to confirm spay status.

Alternatively, tests for measuring AMH may be used to distinguish spayed and sexually intact animals, since serum concentrations of AMH are only present in intact animals. AMH is continuously produced by the ovaries in postpubescent queens and bitches, and production continues throughout the animal's reproductive life. AMH tests are positive in mature intact animals, while negative results are consistent with previous ovariohysterectomy (Place et al. 2011; Axner and Strom-Holst 2015; Themmen et al. 2016; Alm and Holst 2018). When using this test, is important to recognize that negative results may also be seen in intact females tested before reproductive maturity or after reproductive senescence. In one study of 31 female cats, AMH testing had 100% sensitivity and specificity (Axner and Strom-Holst 2015).

A recent study of 125 dogs utilized both AMH and LH testing for spay status determination (Alm and Holst 2018). Excluding bitches in heat, LH testing identified 100% of intact bitches compared to 88% correctly identified by AMH testing. In some instances, low concentrations of AMH were obtained in intact bitches, leading to incorrect classification. The convenience of a point-of-care test and the diagnostic accuracy reported to date make the Witness LH test an especially desirable option for spay status determination. Both LH and AMH testing may also be helpful in the diagnosis of ovarian remnant syndrome in dogs and cats. For more information on diagnosis of ovarian remnant syndrome, see Chapter 18.

Assessment and Follow-Up

Spay–neuter programs should have policies and protocols in place to optimize identification of previously spayed female dogs and cats and to ensure that all patients are ultimately spayed. Ensuring that ovariohysterectomy is complete will not only prevent unwanted estrus behavior and pregnancies, it will also safeguard the health and welfare of the individual. Verification of previous spaying with absolute certainty is sometimes difficult and resources to perform hormonal testing may not be available. In some cases, the clinician will be able to make a confident assessment based on multiple findings consistent with a previously spayed animal. For example, it is reasonable to assume that an obese adult cat with a ventral midline scar and underdeveloped mammary glands has been previously spayed. In the event of available testing, it is also very reasonable to assume that dogs and cats with positive LH test results have been spayed, provided they are not tested while in heat.

Exploratory surgery is the final and most definitive diagnostic option for assessing spay status. Many surgeons will not "mark" a female animal as spayed unless they have either personally removed the ovaries or performed a negative exploratory laparotomy themselves. This approach is indeed wise and recommended, given how good the girls can be at fooling us sometimes.

References

Alm, H. and Holst, B.S. (2018). Identifying ovarian tissue in the bitch using anti-Mullerian hormone or luteinizing hormone. *Theriogenology* 106: 15–20.

Aronson, L.R. and Cooper, M.L. (1967). Penile spines of the domestic cat: their endocrine-behavior relations. *Anat. Rec.* 157: 71–78.

Axner, E. and Strom-Holst, B. (2015). Concentrations of anti-Mullerian hormone in the domestic cat: relation with spay or neuter status and serum estradiol. *Theriogenology* 83: 817–821.

Birchard, S.J. and Nappier, M. (2008). Cryptorchidism. *Compend. Contin. Educ. Pract. Vet.* 30: 325–337.

Flynn, M.F., Hardie, E.M., and Armstrong, P.J. (1996). Effect of ovariohysterectomy on maintenance energy requirement in cats. *JAVMA* 209: 1572–1581.

Griffin, B. (2001). Prolific cats: the estrous cycle. *Compend. Contin. Educ. Pract. Vet.* 23: 1049–1056.

Griffin, B. (2006). Feline reproductive hormones: diagnostic usefulness and clinical syndromes. In: *Consultations in Feline Internal Medicine V* (ed. J.R. August), 217–226. St Louis, MO: Elsevier Saunders.

Griffin, B., Bushby, P.A., McCobb, E. et al. (2016). The Association of Shelter Veterinarians' 2016 veterinary medical care guidelines for spay–neuter programs. *JAVMA* 249 (2): 165–188.

Gunzel-Apel, A.R., Seefeldt, A., Eschricht, F.M. et al. (2009). Effects of gonadectomy on prolactin and LH secretion and the pituitary thyroid axis in male dogs. *Theriogenology* 71: 746–753.

Herron, M.A. (1972). The effect of prepubertal castration on the penile urethra of the cat. *JAVMA* 160: 208–211.

Howe, L.M., Slater, M.R., Boothe, H.W. et al. (2000). Long-term outcome of gonadectomy performed at early age or traditional age in cats. *JAVMA* 217: 1661–1665.

Johnston, S.D., Root, M.V., and Olson, P.N.S. (1996). Ovarian and testicular function in the domestic cat: clinical management of spontaneous reproductive disease. *Anim. Reprod. Sci.* 42: 261–274.

Krecic, M.R., DiGangi, B.A., and Griffin, B. (2018). Accuracy of a point-of-care luteinizing hormone test for help in distinguishing between sexually intact and ovariectomized or castrated domestic cats. *J. Feline Med. Surg.* 20 (10): 955–961.

Ley, W.B., Holyoak, G.R., Digrassie, W.A. et al. (2003). Testicular and epididymal disorders. In: *The Practical Veterinarian: Small Animal Theriogenology* (ed. M.R. Kustritz), 457–491. St. Louis, MO: Elsevier Science.

Lofstedt, R.M. and VanLeeuwen, J.A. (2002). Evaluation of a commercially available luteinizing hormone test for its ability to distinguish between ovariectomized and sexually intact bitches. *JAVMA* 220: 1331–1335.

Memon, M.A., Ganjam, V.K., Pavletic, M.M. et al. (1992). Use of human chorionic gonadotropin stimulation test to detect a retained testis in a cat. *JAVMA* 201: 1602.

Miller, D.M. (1995). Ovarian remnant syndrome in dogs and cats: 46 cases (1988–1992). *J. Vet. Diagn. Investig.* 7: 572–574.

Millis, D.L., Hauptman, J.G., and Johnson, C.A. (1992). Cryptorchidism and monorchism in cats: 25 cases (1980–1989). *JAVMA* 200: 1128–1130.

Morrow, L.D., Gruffydd-Jones, T.J., Skillings, E. et al. (2018). Field study assessing the performance of a patient-side blood test to determine neuter status in female cats based on detection of luteinising hormone. *J. Feline Med. Surg.* 21: 553–558.

Olson, P.N. (2003). Prepuberal gonadectomy (early age neutering) in dogs and cats. In: *The ractical Veterinarian: Small Animal Theriogenology* (ed. M.R. Kustritz), 165–181. St. Louis, MO: Elsevier Science.

Olson, P.N., Mulnix, J.A., and Nett, T.M. (1992 May). Concentrations of luteinizing hormone and follicle-stimulating hormone in the serum of sexually intact and neutered dogs. *Am. J. Vet. Res.* 53 (5): 762–766.

Place, N.J., Hansen, B.S., Cheraskin, J. et al. (2011). Measurement of serum anti-Mullerian hormone concentration in female dogs and cats before and after ovariohysterectomy. *J. Vet. Diagn. Investig.* 23 (3): 524–527.

Richardson, E.F. and Mullen, H. (1993). Cryptorchidism in cats. *Compend. Contin. Educ. Pract. Vet.* 15: 1342–1345.

Root, M.V., Johnston, S.D., and Olson, P.N. (1996a). The effect of prepubertal and postpubertal gonadectomy on heat production measured by indirect calorimetry in male and female domestic cats. *Am. J. Vet. Res.* 57: 371–374.

Root, M.V., Johnston, S.D., and Olson, P.N. (1996b). The effect of prepubertal and postpubertal gonadectomy on penile extrusion and urethral diameter in the domestic cat. *Vet. Radiol. Ultrasound* 37: 363–366.

Salman, M.D., Hutchison, J., Ruch-Gallie, R. et al. (2000). Behavioral reasons for relinquishment of dogs and cats to 12 shelters. *J. Appl. Anim. Welf. Sci.* 2: 93–106.

Spain, C.V., Scarlett, J.M., and Houpt, K.A. (2004). Long-term risks and benefits of early-age gonadectomy in cats. *JAVMA* 224: 380–387.

Stubbs, W.P. and Bloomberg, M.S. (1995). Implications of early neutering in the dog and cat. *Semin. Vet. Med. Surg.* 10: 8–12.

Stubbs, W.P., Bloomberg, M.S., Scruggs, S.L. et al. (1996). Effects of prepubertal and postpubertal gonadectomy on physical and behavioral development in cats. *JAVMA* 209: 1864–1871.

Themmen, A.P.N., Kalra, B., Visser, J.A. et al. (2016). The use of anti-Mullerian hormone as a diagnostic for gonadectomy status in dogs. *Theriogenology* 86: 1467–1474.

Wallace, M.S. (1991). The ovarian remnant syndrome in the bitch and queen. *Vet. Clin. North Am. Small Anim. Pract.* 21: 501–517.

Wheeler, R. and Kutzler, M. (2010). LH testing is accurate for diagnosing the presence or absence of testicular tissue and dogs [abstract]. *Clin. Theriogenol.* 2: 382.

Yates, D., Hayes, G., Heffernan, M., and Beynon, R. (2003). Incidence of cryptorchidism in dogs and cats. *Vet. Rec.* 152 (16): 502–504.