1

Oral Anatomy and Physiology

Matthew Lemmons[1] *and Donald Beebe*[2]

[1] *MedVet Medical and Cancer Centers for Pets, Indianapolis, IN, USA*
[2] *Apex Dog and Cat Dentistry, Englewood, CO, USA*

COPYRIGHTED MATERIAL

Within this chapter, the dog will be discussed primarily, although some comparative information will be covered. Related anatomy and variations for other species will be discussed within chapters covering those. It is intended that this chapter serve to provide the foundation knowledge for the chapters that follow.

The practice of veterinary dentistry is concerned with the conservation, reestablishment and/or treatment of dental, paradental, and oral structures. In dealing with their associated problems a fundamental awareness of anatomy and physiology is essential for an understanding of the presence or absence of the abnormal or pathologic structure. Anatomy and physiology are acutely interactive, with anatomy considered the study of structure and physiology that of its function. These deal with bones, muscles, vasculature, nerves, teeth, periodontium, general oral functions, and their development.

1.1 General Terms

Dentes decidui – deciduous teeth.
Dentes permanentes – permanent teeth.
Dentes incisivi – incisor teeth.
Dentes canini – canine teeth.
Dentes premolares – premolar teeth.
Dentes molares – molar teeth.

1.1.1 Three Basic Types of Tooth Development

Monophyodont. Only one set of teeth that erupt and remain in function throughout life (no deciduous teeth), such as in most rodents (*heterodont*) and dolphins (*homodont*), as currently accepted.

Polyphyodont. Many sets of teeth that are continually replaced. Most of these are homodonts. In sharks, the replacement is generally of a horizontal nature with new teeth developing caudally and moving rostrally. In reptiles, the replacement is generally of a vertical nature with new teeth developing immediately apical to the teeth in current occlusion and replacing them when lost.

Diphyodont. Two sets of teeth, one designated deciduous and one permanent. Common to most domesticated animals and man.

1.1.2 Common Terms Used with Diphyodont Tooth Development

Deciduous teeth (Dentes decidui). Considered to be the first set of teeth that are shed at some point and replaced by permanent teeth.

Primary teeth (Dentes primarui). Considered to be the first set of teeth that are shed at some point and replaced by permanent teeth. Some distractors feel this term is not totally correct because in some species primary teeth are also their permanent teeth, and even in diphyodonts some permanent teeth (i.e., the dog: first premolar and molars) may theoretically also classify as primary, since all teeth may eventually be exfoliated. The term primary is acceptable when speaking to the layperson, but not acceptable in the professional setting.

Permanent teeth (Dentes permanentes). The final or lasting set of teeth, that are typically of a very durable nature (opposite of deciduous).

Nonsuccessional teeth (Nonsuccedaneous). Permanent teeth that do not succeed a deciduous counterpart. Classically molars of dogs and cats.

Successional teeth (Succedaneous). Permanent teeth that replace or succeed a deciduous counterpart. Typically certain diphyodont incisors, canines, or premolars.

Wiggs's Veterinary Dentistry: Principles and Practice, Second Edition. Edited by Heidi B. Lobprise and Johnathon R. (Bert) Dodd.
© 2019 John Wiley & Sons, Inc. Published 2019 by John Wiley & Sons, Inc.

Mixed Dentition. The transient complement of teeth present in the mouth after eruption of some of the permanent teeth but before all the deciduous teeth are absent. Commonly seen in diphyodonts during the early stages of permanent tooth eruption, until all deciduous teeth have been exfoliated.

1.1.3 Two Basic Categories of Tooth Types or Shapes

Homodont. All teeth are of the same general shape or type, although size may vary, such as in fish, reptiles, sharks, and some marine mammals.

Heterodont. Functionally different types of teeth are represented in the dentition. The domestic dog and cat have heterodont dentition, characterized by incisors, canines, premolars, and molars.

1.1.4 Three Common Types of Vertebrate Tooth Anchorage

Thecodont. Teeth firmly set in sockets typically using gomphosis, such as dogs, cats, and humans. *Gomphosis.* A type of fibrous joint in which a conical object is inserted into a socket and held.

Acrodont. Teeth are ankylosed directly to the alveolar bone without sockets or true root structure. This type of attachment is not very strong; teeth are lost easily and are replaced by new ones. This formation is common in the order Squamata (lizards and snakes) with the only other teeth formation in this order being pleurodont. Acrodontal tooth attachment is also seen in fish.

Pleurodont. Teeth grow from a pocket on the inner side of the jawbone that brings a larger surface area of tooth in contact with the jawbone and hence attachment is stronger, as in amphibians and some lizards. However, this attachment is also not as strong as thecodont anchorage.

1.1.5 Two Basic Tooth Crown Types

Brachydont. Dentition with a shorter crown to root ratio, as in primates and carnivores. A brachydont tooth has a supragingival crown and a neck just below the gingival margin, and at least one root. An enamel layer covers the crown and extends down to the neck. Cementum is only found below the gingival margin.

Hypsodont. Dentition with a longer crown to root ratio, as in cow, horses, and rodents. These teeth have enamel that extends well beyond the gingival margin, which provides extra material to resist wear and tear from feeding on tough and fibrous diets. Cementum and enamel invaginate into a thick layer of dentin.

Radicular hypsodont (subdivision of hypsodont). Dentition with true roots, sometimes called closed rooted, that erupts additional crown through most of life. These teeth eventually close their root apicies and cease growth. As teeth are worn down new crown emerges from the submerged reserve crown of the teeth, such as in the molars and premolars of the equine and bovine. Known as continually erupting closed rooted teeth.

Aradicular hypsodont (subdivison of hypsodont). Dentition without true roots, sometimes called open rooted, that produces additional crown throughout life. As teeth are worn down new crown emerges from the continually growing teeth, such as in lagomorphs and incisors of rodents. Known as continually growing teeth or open rooted teeth.

1.1.6 General Crown Cusp Terms of Cheek Teeth

Secodont dentition. Having cheek teeth with cutting tubercles or cusps arranged to provide a cutting or shearing interaction, such as premolars in most carnivores, especially the carnassial teeth.

Bunodont dentition. Having cheek teeth with low rounded cusps on the occlusal surface of the crown. Cusps are commonly arranged side by side on the occlusal surface for crushing and grinding, such as molars in primates (including man), bears, and swine.

Lophodont dentition. Having cheek teeth with cusps interconnected by ridges or *lophs* of enamel, such as in the rhinoceros and elephant.

Selenodont dentition. Having cheek teeth with cusps that form a crescent-shaped ridge pattern, such as in the even-toed ungulates, except swine.

1.1.7 Two Types of Jaw Occlusal Overlay

Isognathous. Equal jaw widths, in which the premolars and molars of opposing jaws aligned with the occlusal surfaces facing each other, forming an occlusal plane. Man is an imperfect isognathic, or near equal jaws.

Anisognathous. Unequal jaw widths, in which the mandibular molar occlusal zone is narrower than the maxillary counterpart, such as in the feline, canine, bovine, equine, etc.

1.1.8 The Dog and Cat Dentition

Dogs and cats have diphyodont development, heterodont teeth types, brachyodont crown types, secondont teeth (all premolars, feline mandibular molar and a portion of the canine mandibular first molar), bunodont (feline maxillary molar, canine molars, including a portion of the mandibular first molar), thecodont tooth anchorage and anisognathic jaws.

1.2 Development

Note that the following section will give a brief overview of the embryologic development of the mouth and associated structures. The same tissues in the adult animal will be discussed later in the chapter.

Development of the gastrointestinal tract begins early in embryonic formation. The roof of the entodermal yolk sac enfolds into a tubular tract forming the gut tube, which will become the digestive tract. It is initially a blind tract being closed at both the upper and bottom ends. The bottom ultimately becomes the anal opening and the upper portion connects with the primitive oral cavity known as the stomodeum, or ectodermal mouth. The stomodeum and foregut are at this time separated by a common wall known as the buccopharyngeal membrane. It is located at a level that will become the oropharynx, located between the tonsils and base of the tongue. This pharyngeal membrane eventually disappears, establishing a shared connection between the oral cavity and the digestive tract.

Around day 21 of development, branchial arches I and II are present. By day 23 the paired maxillary and mandibular processes of branchial arch I have become distinct. The mandibular processes grow rostrally, forming the mandible and merging at the mandibular symphysis, which in the dog and cat normally remains a fibrous union throughout life. The paired maxillary processes form most of the maxillae, incisive, and palatine bones.

Initial development of the dental structures occurs during embryonic formation. Rudimentary signs of tooth development occur approximately at the 25th day of development when the embryonic oral (stratified squamous) epithelium begins to thicken. This thickening, known as the dental lamina, forms two U-shaped structures, which eventually become the upper and lower dental arches. The enamel organ, which evenutally is responsible for enamel formation and has a role in induction of tooth formation, arises from a series of invaginations of the dental lamina into the adjacent mesoderm. The oral epithelium, dental lamina, and enamel organ originate from the outer embryonic germ layer known as ectoderm. The dental papilla and sac appear in coordination with the enamel, but originate from mesoderm (ectomesenchyme of the neural crest).

The enamel organ develops through a series of stages known as the bud, cap, and bell (Figure 1.1). The bud stage is the initial budding off from the dental lamina at the areas corresponding to the deciduous dentition. The bud eventually develops a concavity at the deepest portion, noting the start of the cap stage. As the enamel organ enters this stage it is comprised of three parts: the outer enamel epithelium (OEE) on the outer portion of the cap, the inner enamel epithelium (IEE) lining the concavity, and the stellate reticulum within the cap. The onset of the bell stage occurs as a fourth layer to the enamel organ, the stratum intermedium, emerges between the IEE and the stellate reticulum.

Each layer of the enamel organ has specific functions to perform. The OEE acts as a protective layer for the entire organ. Stellate reticulum works as a cushion for protection of the IEE and allows vascular fluids to percolate between cells and reach the stratum intermedium. The stratum intermedium apparently converts the vascular fluids to usable nourishment for the IEE. The IEE goes through numerous changes, ultimately being responsible for actual enamel formation.

The dental lamina buds that form the primary dentition develop lingual extensions referred to as successional

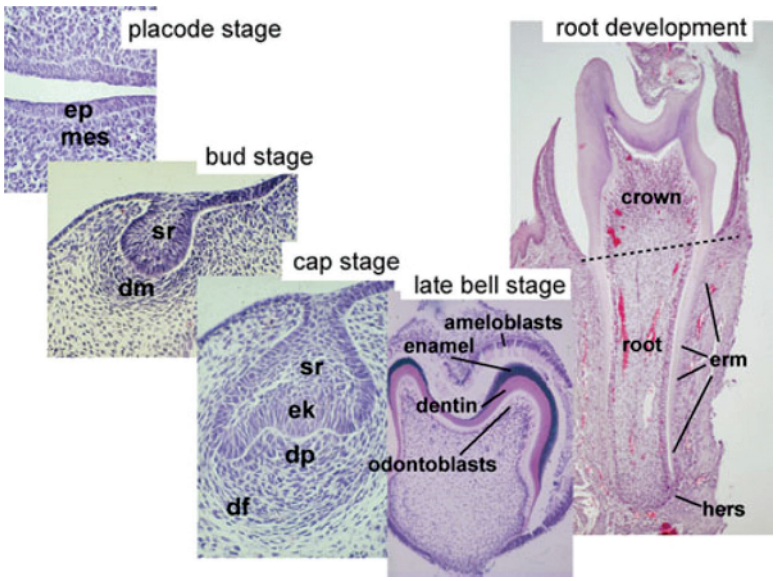

Figure 1.1 Histology of important stages of tooth development. Note that all early development is directed at creating the crown and only then root formation is initiated. Ameloblasts differentiate from the epithelium and odontoblasts from the mesenchyme and they deposit the matrices of enamel and dentin, respectively. Ameloblasts and enamel are missing on the root, which is covered by the softer dentin and cementum. Ep, epithelium; mes, mesenchyme; sr, stellate reticulum; dm, dental mesenchyme; dp, dental papilla; df, dental follicle; ek, enamel knot; erm, epithelial cell rests of malassez; hers, Hertwig's epithelial root sheath. *Source*: from Thesleff, I. and Tummers, M. Tooth organogenesis and regeneration: http://stembook.org/node/551; accessed November 2017.

lamina. The successional laminae progress through bud, cap, and bell stages to eventually form the successional permanent dentition. The non-successional teeth, those permanents not succeeding deciduous counterparts, develop directly from the dental lamina.

During the late bud stage, from an area adjacent to the IEE, mesenchymal cells begin development of the dental papilla and dental sac. The mesodermal cells of the dental papilla form the dentinal and pulpal tissues of the forming tooth. The dental sac is comprised of several rows of flattened mesodermal cells covering the dental papilla and attaching part of the way up the OEE of the bud. It gives rise to cementum, periodontal ligament (PDL), and some alveolar bone.

The frontal prominence, the forehead area of the embryo, occurs in coordination with the stomodeum and mandibular processes. Nasal pits, the beginning of the nasal cavities, are first revealed by two small depressions found low on the frontal prominence. On either side of the nasal pits are the medial and lateral nasal processes. The two medial nasal and two maxillary processes form the upper lip. The groove between the two fills with connective tissue in a process known as migration. If migration fails to occur the tissues will be stretched thin and will tear. This results in a separation between the medial nasal and maxillary process, which causes a cleft lip.

The left and right maxillary processes and the single medial nasal processes also form the palate. The incisal portion (maxilla) of the hard palate is the part from the maxillary incisor teeth back to the incisive foramen. The area of the incisive bone (the premaxilla in some species, and formerly in the dog) is also known as the primary palate and is formed solely by the medial nasal process. The medial nasal process forms the philtrum and helps form the nasal septum. The left and right maxillary processes form two palatal shelves that grow inward toward the midline, beginning rostrally, and then attaching to the primary palate and growing together. This is known as the secondary palate.

Cleft lips and palates are not uncommon. Clefts are generally designated as unilateral or bilateral. A unilateral cleft lip occurs when migration fails to occur between one of the maxillary processes and the medial nasal process. A bilateral cleft lip occurs when both maxillary processes fail to migrate. A unilateral cleft palate occurs when one of the palatal plates of the maxillary processes fails to fuse with the nasal septum. A bilateral cleft palate occurs when both palatal plates of the maxillary processes fail to fuse with the opposite plates at the nasal septum. Clefts of hard or soft palates develop in a wide range of varying degrees of severity.

1.2.1 Enamel, Dentin, and Pulp

These three structures have an intimate relationship during early development, although they do not all develop from the same foundation cells. Enamel is produced by the enamel organ, which is derived from ectoderm. In contrast, the dentin and pulp develop from the dental papilla, which is derived from mesoderm.

During the bell stage, the IEE cells evolve into a taller form and become preameloblasts. The peripheral cells of the dental papilla bordering the preameloblasts transform into low columnar or cuboidal shapes and form odontoblasts. As the newly formed odontoblasts move toward the center of the dental papilla and away from the preameloblasts they leave behind a secreted matrix of mucopolysaccharide ground substance and collagen fibers. This substance appears to stimulate a polarity shift in the preameloblasts of the nucleus from the center of the cell toward the stratum intermedium. It is thought that this shift in polarity is caused by an alteration in the nutritional supply route to the cells. With this shift in polarity, the cells now become ameloblasts and begin secretion of enamel matrix. As this enamel matrix (mucopolysaccharide ground substance and organic fiber) is laid down next to the dentinal matrix, the dentinoenamel junction (DEJ) is formed. As the ameloblasts lay down matrix they move away from the dentin and toward the OEE. Both the dentin and enamel begin to lay down crystal and mineralize at this point into hard tissue.

The enamel matrix is laid down at the end of the bell stage. All of the crystal placed within the rods are laid down at this time. This is known as the mineralization stage of calcification of the enamel rod. The next is the maturation stage of calcification. It is during this stage that the crystals grow in size, becoming tightly packed together within the enamel rod. Should the crystals fail to grow to full size, the rods will be poorly calcified and have less than 96% inorganic composition; this results in a condition known as hypomineralization. As enamel is produced by the ameloblasts, a change occurs in the enamel organ. The ameloblasts gradually begin to compress the two middle layers of the organ, the stratum intermedium and the stellate reticulum. The middle layers are eventually lost and the ameloblasts make contact with the OEE. This activates the final two functions of the ameloblasts to commence. First, a protective layer is laid down on top of the enamel known as the primary enamel cuticle or Nasmyth's membrane. This cuticle remains on the teeth for weeks to months, until it is worn away by abrasion. The cuticle is laid down upon the crown from the tip toward the cementoenamel junction (CEJ). Once the cuticle is formed the ameloblasts merge with the OEE to form the reduced enamel epithelium.

The reduced enamel epithelium is produced on adhesive-like secretion known as the secondary enamel cuticle or epithelial attachment. The epithelial attachment functions to hold the gingiva and tooth together at the bottom of the gingival sulcus. During enamel development, several abnormalities may develop. These are sometimes found on clinical, radiological, or histological examination. Amelogenesis imperfecta is the general term that includes any genetic and/or developmental enamel formation and maturation abnormalities. Enamel hypoplasia refers to inadequate deposition of enamel matrix, i.e., when the density or mineralization is generally normal, but the enamel is thinner than normal. Enamel hypomineralization refers to inadequate mineralization of enamel matrix, resulting in white, yellow, or brown spots in the enamel. This often affects several or all teeth. The crowns of affected teeth may be soft and wear faster than normal teeth.

Mesodermal tissue from the dental papilla forms the pulp. Once developed, it consists of blood vessels, lymphatic vessels, nerves, fibroblasts, collagen fibers, undifferentiated reserve mesenchymal cells, other cells of connective tissue, and odontoblasts. Odontoblasts are an integral part of the dentin, but are also the peripheral cells of the pulp. The pulpal nerves are primarily sensory and transmit only the sensation of pain. There are some motor nerves that innervate the smooth muscles within the blood vessels. These result in constriction of the vessels in response to irritation. Young pulps have a large volume, which is considered primarily cellular, with a small concentration of fibers. The large number of cells allows for repair from trauma. As the pulp ages, it loses volume and reserve cell capacity. This loss of reserve cells is thought to be the reason that older patients are more susceptible to permanent pulpal damage.

1.2.2 Root Formation

Formation of the root begins after the general form of the crown has developed, but prior to its complete calcification. At the point where the OEE becomes the IEE, the stellate reticulum and stratum intermedium are missing from the enamel organ at this deepest point, and is referred to as the cervical loop. These two layers of cells become the epithelial root sheath or Hertwig's epithelial root sheath (Figure 1.2). This sheath begins to grow into the underlying connective tissue by rapid mitotic division, initiating root formation. This growth advanced deep into underlying connective tissue, but at some point, angles back toward the center of the forming tooth. The portion of the sheath that turns back in is known as the epithelial diaphragm. The growth pattern of the epithelial diaphragm determines the number of roots a tooth develops. The point at which

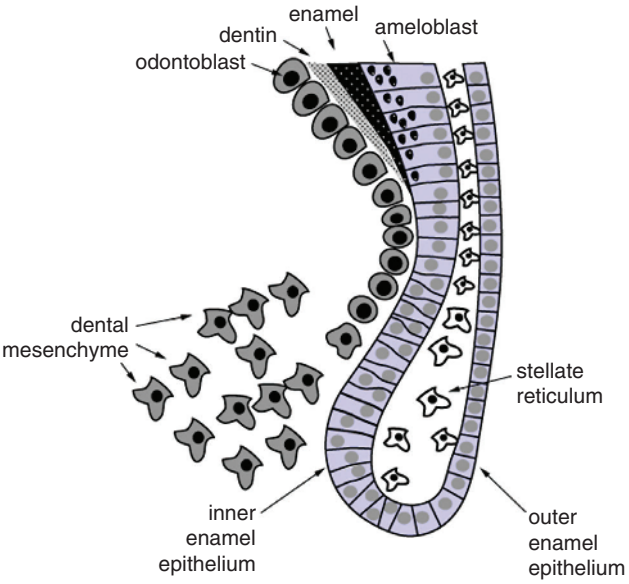

Figure 1.2 Fate of the stem cell progeny in the epithelial stem cell niche of the continuously growing tooth, the cervical loop. Stem cells divide in the stellate reticulum compartment giving rise to cells that will become inserted to the basal layer of epithelium looping around the stellate reticulum. Here the cells proliferate, migrate toward the oral cavity and differentiate into ameloblasts, depositing enamel matrix. *Source:* From Thesleff, I. and Tummers, M. Tooth organogenesis and regeneration: http://stembook.org/node/551 – animation; accessed November 2017.

the epithelial diaphragm meets will be the apex of a single rooted tooth but the furcation in multirooted teeth. As the root sheath makes contact with the dental papilla, it stimulates the peripheral contact cells to differentiate into odontoblasts. Once the odontoblasts begin to produce dentin, the root sheath trapped between the dental sac and the dentin begins to break up. As Hertwig's epithelial root sheath dissolves, the dental sac comes into direct contact with the newly formed dentin. Some of the dental sac cells differentiate into cementoblasts and initiate cementum formation. The cementum that contacts the dentin becomes the dentinocemental junction (DCJ).

The epithelial root sheath cells that move away from the dentin, but fail to dissolve, become entrapped in the PDL and are referred to as epithelial rests or epithelial rests of Malassez. These cell rests are a normal finding, but under the influence of various stimuli, they could proliferate later in life to form epithelial lining of various odontogenic cysts, such as the radicular cyst. When epithelial root sheath cells fail to dissolve and remain in contact with the dentin, they typically convert to ameloblasts. These may secrete enamel on the roots, forming what is known as enamel pearls. If the root sheath's epithelial diaphragm malfunctions, accessory roots may be formed.

1.2.3 Tooth Eruption

The emergence and movement of the crown of the tooth into the oral cavity is typically termed tooth eruption. The eruptive sequence is generally divided into three stages. The pre-eruptive stage commences with crown development and the formation of the dental lamina. With the onset of root development, the eruptive stage begins. This is also sometimes referred to as the pre-functional eruptive stage. When the teeth move into actual occlusion it is termed post-eruptive stage or functional eruptive stage. This stage is considered to continue until tooth loss occurs, or death. In the hypsodont species, this stage may function to serve occlusion in several ways. As the jaws grow, the mandible and maxilla spatial relationship becomes further apart and the teeth continue to erupt to maintain occlusion. With time, attrition results in loss of dental occlusal contacts and it is this further eruption that maintains the occlusal balance. In some cases, this can cause an imbalance in occlusion when teeth are lost and supraeruption of the opposing teeth occurs. Supraeruption is when teeth erupt beyond the normal occlusal line.

Four major theories for eruption have been expounded upon in the literature. Most likely none are totally correct in themselves, but the most accurate picture is probably a combination of them. The theory of root growth is the belief that root growth pushes the crown into the oral cavity. Experiments of removing Hertwig's epithelial root sheath on developing teeth has stopped root formation. However, these rootless teeth still erupt, thus disproving this as a major factor in eruption. The theory of growth of pulpal tissue proposes that continued growth of the pulp tissue while the hard sides of the tooth are forming provides apical propulsion. Yet developing teeth in which the pulp dies or is removed will still erupt, also disproving this as a major factor in eruption. The theory of bone deposition in the alveolar crypt is the precept that bone deposition within the alveolar crypt forces the tooth to erupt. This deposition is not constant and even when the crypt undergoes resorption due to various factors teeth generally still erupt, making this theory a dubious major factor. The theory of PDL force is the hypothesis that it is the PDL's driving force that maintains occlusal contact also thrusts the tooth into the oral cavity. This is the most plausible postulate, although the exact mechanism is unknown. Eruption times are variable not only with size and breed but also within the breeds themselves. Average eruption times of deciduous and permanent teeth can be found in Table 4.1 in Chapter 4 – Developmental Pathology and Pedodontology.

Exfoliation of deciduous dentition is a complex function and not fully understood. It is believed that as the permanent tooth root begins development, the crown makes contact with the deciduous tooth root structure. The pressure of the permanent tooth crown on the deciduous tooth root, and possibly the contact of the permanent tooth's dental sac or the OEE with the deciduous root, stimulates the resorptive process of the deciduous tooth root. Deciduous root resorption occurs in cycles or stages, and is not constant. Once sufficient root support is lost, the crown is shed or exfoliated. Although it is common for deciduous teeth to persist when a permanent successor does not develop, this is not always the case, indicating that other factors may play a part in root resorption.

Persistent deciduous teeth are commonly attributed to four causes. The first is the lack of a permanent successor. The second is ankylosis of the tooth to the alveolus. This may occur during root resorption when holes in Hertwig's root sheath develop and the tooth's cementum makes contact with the alveolar bone and fuses to it. In these cases, it is common to find teeth with almost the entire root structure dissolved, but with the crown still firmly in place. Once the ankylosis is relieved, typically the crown rapidly exfoliates. The third cause for persistent deciduous dentition is failure of the permanent crown to make contact with the deciduous root during eruption. This occurs if either tooth is in an improper position, in comparison to each other. Finally, the fourth reason is hormonal influences, which can affect growth or metabolism.

1.3 Basic Anatomy of the Dental-Periodontal Unit

1.3.1 Directional, Surface, and Ridge Nomenclature

Prior to discussing dental anatomy, a general understanding of directional, surface, and ridge nomenclature is required.

Rostral and caudal are anatomical terms of location applicable to the head in a sagittal plane in non-human vertebrates. Rostral refers to a structure closer to, or a direction toward, the most forward structure of the head. Caudal refers to a structure closer to, or a direction toward, the tail. Anterior and posterior are the synonymous terms used in human dentistry. The term caudal teeth refer to premolars and molars, as opposed to incisors and canines, which are rostral teeth. Incisors, canines, and premolars have four exposed surfaces and a ridge or cusp, making a total of five surfaces. Molars have five exposed surfaces. Sometimes a ridge may be referred to as a surface.

As a general rule, the surfaces of the teeth facing the vestibule or lips are the vestibular surfaces [1] (Figure 1.3). For the incisor and canine teeth, the surface directed toward the lips is commonly called the labial surface. With premolars and molars, the surface facing the cheek is known as the buccal surface. The term "facial" has been used traditionally in human dentistry to refer to the surfaces of the rostral teeth visible from the front. All surfaces facing the tongue are described as lingual, although for the maxillary teeth this surface is often described as the palatal surface. For premolars and molars, the surface making contact with the teeth in the opposite jaw during closure is known as the occlusal surface. The ridge of the premolars that does not make contact with opposing teeth is typically referred to as the occlusal ridge. For the incisors, the ridge along the coronal-most aspect is referred to as the incisal ridge. The cusp is the point or tip of the crown of a tooth. For the canine tooth, the cusp is generally called the cusp surface. Premolars and molars may have multiple cusps. Surfaces facing toward adjoining teeth within the same jaw quadrant or dental arch are collectively called the contact or proximal surfaces. Proximal surfaces may be either distal or mesial. The term distal indicates a proximal surface facing away from the median line of the face. In contrast, the term mesial designates the proximal surface facing toward the median line. The space between two facing proximal surfaces is known as the interproximal space. Apical is a term used to denote a direction toward the root tip. Coronal is a term used to indicate a direction toward the crown tip or occlusal surface. The terms incisal for incisors and occlusal for premolars and molars is also used to indicate the coronal direction. The term cervical either means the juncture of the tooth crown and root or a direction toward that point.

To further break down tooth locations, combinations of the above terms are sometimes used, with one additional term, middle (Figure 1.4). The term middle means at or toward the middle of a designated portion of the tooth and can indicate either a horizontal or vertical middle area.

1.3.2 Crown Line and Point Angles

For the purpose of identifying and classifying distinct areas on teeth in operative dental procedures, the coronal surfaces can be divided and classified by eight line angles and four point angles (see Chapter 17 – Restorative Dentistry). These lines and points are also sometimes used for identification of cavity prep areas.

There are five crown surfaces: vestibular, lingual/palatal, mesial, distal, and occlusal/coronal/incisal. The line angles are simply the dividing lines formed between the surface areas. They are named from two of the five surfaces that divide them. Where the surface terms are joined, the "ar" or "al" ending is dropped and "o" is added. The eight line angles are (i) mesiovestibular (mesiolabial, mesiobuccal), (ii) mesiolingual (mesiopalatal), (iii) mesioincisal (mesiocoronal, mesio-occlusal), (iv) distovestibular (distolabial, distobuccal), (v) distolingual (distopalatal), (vi) distoincisal (distocoronal, disto-occlusal), (vii) linguoincisal (linguocoronal, linguo-occlusal), and (viii) vestibuloincisal (vestibulocoronal, vestibulo-occlusal).

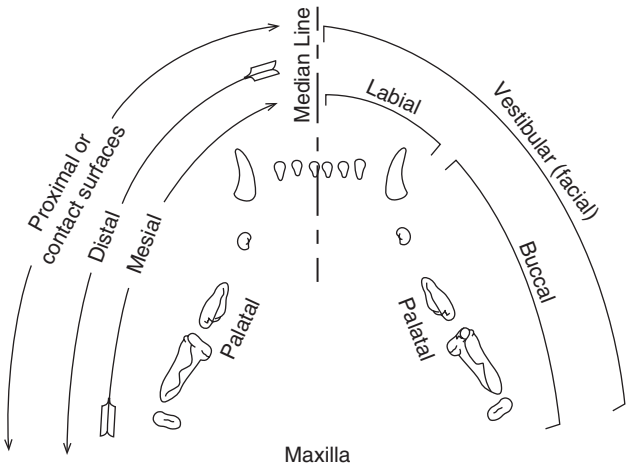

Figure 1.3 Directional nomenclature of the maxillary teeth of the cat. *Source:* Courtesy of Josephine Banyard.

The point angles are the junctures of three of the line angles. There are four coronal point angles, each named for the three surfaces that actually make the juncture or point. The four point angles are (i) mesiovestibuloincisal (mesiovestibulocoronal, mesiovestibulo-occlusal, mesiolabioincisal, mesiolabiocoronal, mesiolabio-occlusal, mesiobuccocoronal, mesiobucco-occusal), (ii) mesiolinguoincisal (mesiolinguocoronal, mesiolinguo-occusal, mesiopalatoincisal, mesiopalatocoronal, mesiopalato-occlusal), (iii) distovestibuloincisal (distovestibulocoronal, distovestibulo-occlusal, distolabioincisal, distolabiocoronal, distolabio-occlusal, distobuccocoronal, distobucco-occusal), and (iv) distolinguoincisal (distolinguocoronal, distolinguo-occusal, distopalatoincisal, distopalatocoronal, distopalato-occlusal).

1.3.3 Contact Points and Areas

Contact points and areas are the sites where adjacent or opposing teeth make contact. The term contact area is considered a more correct term than contact point, since an area is typically making contact rather than a specific point. Adjacent teeth have proximal contact areas, where opposing teeth have occlusal contact areas.

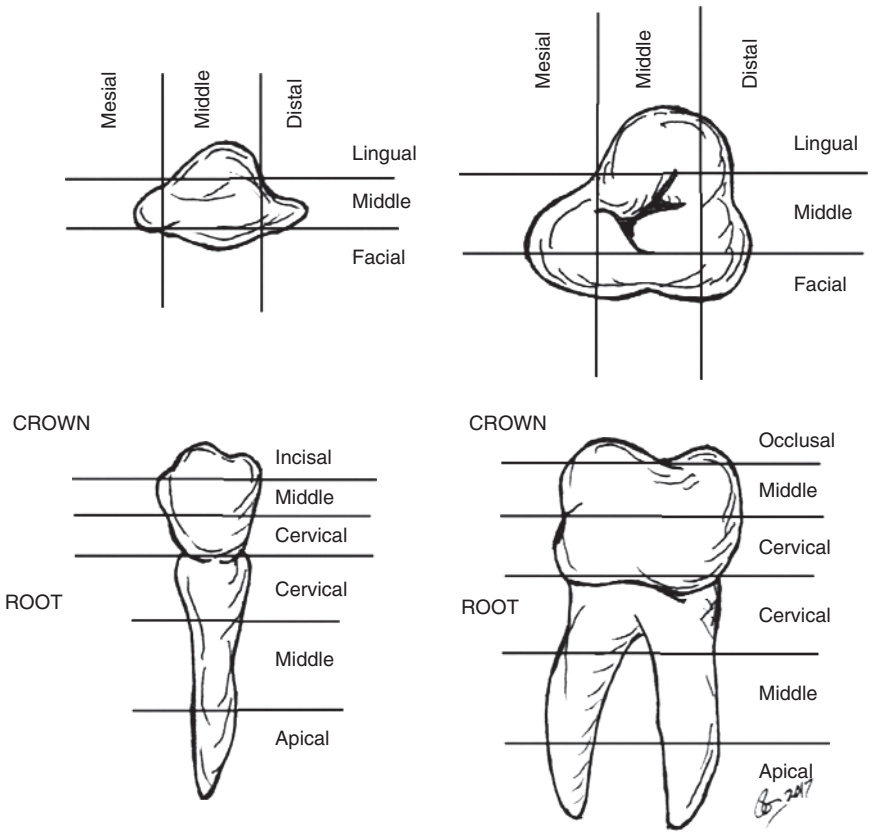

Figure 1.4 Division into thirds. *Source*: Courtesy of Josephine Banyard.

1.3.4 Embrasures

Projecting away from the proximal contact areas are V-shaped areas termed embrasures. They are named for the surface from which they are derived and the direction they radiate toward. There are theoretically four embrasures between each tooth with proximal contacts. The embrasures are the (i) vestibulogingival (labiogingival, buccogingival), (ii) vestibuloincisal (vestibulocoronal, vestibulo-occlusal, labioincisal, labiocoronal, labio-occlusal, buccocoronal, bucco-occlusal), (iii) linguogingival (palatogingival), and (iv) linguoincisal (palatoincisal, palatocoronal, palato-occlusal, linguocoronal, linguo-occlusal).

1.3.5 Tooth Function and Terms

Teeth are multifunctional organs that play an important part in overall animal health and activity. Their shape aids physiologically in protection of the oral mucosa, as well as reduction of stress forces on the teeth and the alveolar process. Teeth are used to catch, hold, carry, cut, shear, crush, and grind sustenance. Besides their masticatory functions, they are used in protection, aggression, and sexual attraction. Sexual dimorphism, such as length of tooth, may play a part in sexual attraction and social behavior for defense.

Each tooth has a crown and a root, except for aradicular hypsodonts (see Chapter 21 – Small Mammal Oral and Dental Diseases). Generally, the brachydont crown is covered with enamel and the root with cementum. Where the enamel of the crown and cementum of root meet is known as the CEJ. The line formed by the CEJ is commonly called the neck, cervix, or cervical line. In many cases, especially during eruption and in hypsodont dentition, not all of the crown may be fully exposed. The entire crown, whether exposed or not, is the anatomical crown. The supragingival portion of the crown is the clinical crown and the subgingival portion is the reserved crown. The reserved crown is occasionally referred to as the clinical root as compared to the anatomical or true root. The incisor teeth are designed to cut, scrape, scoop, pick at or up, and groom. The term incisor means "that which cuts." The actual biting edge of the incisor is the incisal edge or ridge. The incisal edge picks up and cuts food, scrapes meat off bone, grooms the hair, and is used to catch parasites. The concave lingual surface acts as a scoop and, along with the tongue, aids in carrying food into the oral cavity. The canine teeth are designed to pierce and hold a victim. They can also be used to slash and tear when used as weapons in fighting. In the carnivores, canines have the longest crowns and roots. These large roots make them very stable and good anchorage points. Premolars resemble a cross

between canine teeth and molars. They are not as long as canine teeth and generally have multiple functional cusps. Being a cross between a canine tooth and a molar, they are designed to function similarly to both. They help to hold and carry, while also helping to break food down into smaller pieces. Molars have an occlusal surface that can be used to grind food or break it down into smaller pieces. The incisors and canine teeth are referred to as rostral teeth, while the premolars and molars are caudal teeth. The carnassial teeth are considered to be the largest shearing teeth in the upper and lower jaws. In the dog and cat these are the maxillary fourth premolars and the mandibular first molars. The term carnassial (commonly used, not an accepted anatomic term) means flesh cutting.

Crown formation generally occurs from four or more growth centers known as lobes. Their fusion, termed coalescence, can result in various depth grooves known as developmental grooves. Most incisors, canine teeth, and premolars develop from four lobes, three vestibular and one lingual. The two developmental grooves on the vestibular surface of the incisors are the coalescence or fusion points of the three vestibular lobes. The three protrusions along the incisal edge formed by the developmental grooves are the mamelons. The deep developmental grooves in many carnivores and some primates appear to help in cutting the flesh as it slides up the tooth and act as bleeding grooves, allowing for blood to escape from the punctures in the victim while still holding them in a firm grasp. The fourth lobe on the lingual surface typically forms the majority of the tooth bulk at the lingual cervical third and is called the cingulum. Just coronal to the incisor cingulum is a slight concavity known as the lingual fossa.

The proximal contacts are the points at which adjacent teeth make contact. These contacts aid in prevention of food being packed between the teeth from above, while the gingival papilla serve the same purpose from the vestibular and lingual surfaces. The contacts of the rostral teeth are located close to the incisal ridge, whereas they are located more apically in the caudal teeth. With the tooth spacings found in the dog and cat, proximal surfaces do not always make contact with the adjacent teeth. The bulge, curvature, or contour of the tooth aids in directing food away from the gingival sulcus, while using frictional movement of the food to clean the gingivae, cheeks, and lips.

1.4 General Anatomy of the Tooth and Periodontium

It is arbitrary to discuss the tooth and periodontium as separate parts as it is one functional unit. However, to more easily understand the anatomy and physiology, it will be separated into the crown, dentin and pulp, root, and periodontium.

The tooth is made up of basically four tissues, three hard and one soft. The hard tissues are enamel, cementum, and dentin; the soft is the pulp. The pulp tissue occupies the cavern within the tooth known as the pulp cavity. This cavity is further divided into pulp chamber, portion in the crown, and root canal, portion within the root. The bottom of the pulp chamber is referred to as the chamber floor and the most coronal part the chamber horns in which the pulp horns reside (Figure 1.5).

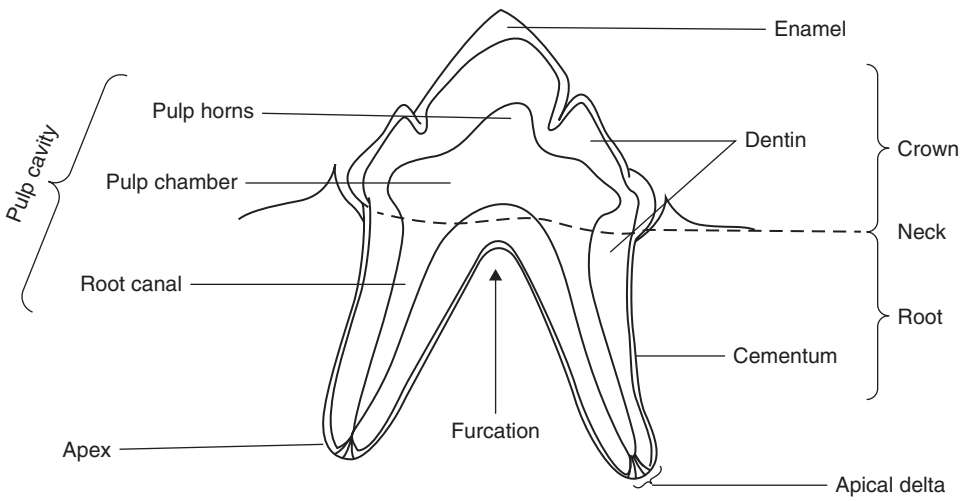

Figure 1.5 Tooth anatomy. *Source:* Courtesy of Josephine Banyard.

1.4.1 Dental Formulas

The currently accepted designations of the dental formula for the dog is as follows:

Deciduous teeth: 2 × (3/3 i, 1/1 c, 3/3 pm) = 28.
Permanent teeth: 2 × (3/3 I, 1/1 C, 4/4 PM, 2/3 M) = 42.

The currently accepted designations of the dental formula for the cat is as follows:

Deciduous teeth: 2 × (3/3 i, 1/1 c, 3/2 pm) = 26.
Permanent teeth: 2 × (3/3 I, 1/1 C, 3/2 PM, 1/1 M) = 30.

(Additional dental formula information for the dog and cat can be found in Chapter 2 – Oral Examination and Diagnosis – and for other species in their related chapters.)

1.4.2 Crown

The crown is the portion of the tooth typically erupted though the gingiva. The brachydont crown is completely covered by enamel. Enamel is the hardest substance in the body and contains the highest percentage of mineral. It has a semi-translucent white color, although it may appear as other colors due to the refraction of the underlying dentin (e.g., intrinsic discoloration). Extrinsic staining and color changes of the enamel can occur with age. Enamel is approximately 96% inorganic in composition. This inorganic portion is calcium phosphate in the form of hydroxyapatite crystals. Fluoride, magnesium, strontium, and lead may also be present [1]. The remaining 4% of enamel composition is principally water and fibrous organic material. Enamel varies in thickness over the surface of the tooth, often thickest at the cusp and thinnest at its border with the cementum at the CEJ [1]. Despite its hardness, enamel is subject to wear attrition from friction of use. Fluorinated enamel has an improved resistance to degradation by acids generated from bacterial activity. Enamel is avascular and has no capability to regenerate itself when damaged; however, it is not a static tissue as it can undergo mineralization changes.

The basic building block of enamel is the enamel rod. Each rod is a column of enamel that extends from the DEJ to the coronal surface of the tooth. These rods are generally perpendicular both to the DEJ and the surface. Each rod is composed of two parts, the rod core and the rod sheath. The rod core is composed of hydroxyapatite crystals. The rod sheath, which surrounds the columnar side of the rod core, is composed mostly of the organic fibrous substance. Crystals are present between rod sheaths called interrod enamel. These crystals are not aligned in the same direction of rod enamel. The rod sheath is incomplete in circumference, allowing contact between the rod and interrod enamel. The shape of the rods in the enamel is round to quad-lobed at the inner layer and hexagonal at the outer layer of enamel. Enamel rods have a round shape in the cat [2].

Three layers of enamel have been described in the cat and dog: a non-prismatic layer at the surface, a regular prismatic layer, and an inner layer with prominent bands of Hunter and Schreger, which may indicate multidirectional orientation of the rods [2]. Bands of Hunter and Schreger are not a true structure but an optical illusion produced by changes in direction between groups of rods [1]. The striae or stripes of Retzius are darker lines in the enamel that radiate out in a curve from the DEJ. These are areas of slight variation in the crystal content of the rods. It appears that approximately every fourth day in the ameloblast cycle, there is a change in the rod development or cycle of rest that results in these lines or striae. As these striae of Retzius are visible on the exposed surface enamel, they cause slight horizontal lines or ripples in the enamel. These are known as imbrication or perikymata lines. These perikymata are not present on the surface of dog or cat teeth, likely due to the angle of the striae of Retzius being nearly parallel to the tooth surface [2].

Enamel tufts are small, branched hypomineralized ribbon-like defects that run longitudinally to the tooth axis and extend from the DEJ one-fifth to one-third the way into enamel toward the enamel surface [3]. They are commonly found on histologic sectioning, especially in bunodont dentition of animals that crush hard materials such as nuts or mollusk shells. Although they have been noted to be a potential source of enamel fractures that arise after extended use or overloading, it appears that they then enable enamel to resist the further progression of these fractures, ultimately preventing mechanical failure [4]. This fracture resistance is one reason why tooth enamel is three times stronger than its constituent hydroxyapatite crystallites that make up its enamel rods [5]. Enamel tufts are frequently confused with enamel lamellae, which are also enamel defects, but which differ in two ways: lamella are linear, and not branched, and they exist primarily extending from the enamel surface, through the enamel and toward the DEJ, whereas enamel tufts project in the opposite direction. The most common form is that caused by trauma resulting in hairline cracks in the enamel. Lamellae can be of clinical significance depending on number and severity [6].

Enamel tufts should also not be confused with the similar enamel spindles. Enamel spindles are also linear defects, similar to tufts and lamellae. They are formed by entrapment of odontoblast processes between ameloblasts prior to and during amelogenesis. Like enamel tufts, spindles are found only at the DEJ; they are typically found histologically and have no known clinical significance.

There is evidence that the enamel of dogs and cats is much thinner than that found in man. In humans, the thickness is reported to be 2–4 mm compared to 0.1–0.3 mm in cats and 0.1–0.6 mm in dogs [7]. Additionally, the cervical bulge often found at the level of the free gingiva does not represent a thickening in the enamel, but a general thickening in the tooth [7].

1.4.3 Root and Periodontium

The tooth root is covered by cementum and anchored to the jaws by the periodontium. The periodontium consists of the cementum, the PDL, the dental alveolus, and the gingiva. The periodontium exists to anchor the tooth, cleanse and protect the tooth, and to serve as sensory tissue.

The root surface is covered by cementum and is located apical to the attached gingiva in health. Teeth may have single or multiple roots. The point at which roots diverge is the furcation; this can be bifurcation, trifurcation, etc. Although there is individual variation, the number of roots is determined by species and type of tooth. In this chapter the dentition of the dog and cat will be the focus.

The incisors and canine teeth of the dog are all single-rooted teeth. The maxillary first and second and all three of the incisors in each mandible have relatively straight roots, which are round to triangular when examined in cross-section. The root of the maxillary third incisor is often triangular to trapezoidal in shape and has a curvature with the greater curvature being mesial to mesiobuccal and the lesser curvature being distal to distobuccal. This curvature may make closed extraction challenging. The root of the maxillary canine tooth is digitally palpable via the jugum. The apices of mandibular canine teeth are positioned lingual to the crowns. This functionally creates more buccal bone at the apical portion of the root and should be kept in mind during exodontia and related surgical procedures. The first premolar of each quadrant has a single root. The second and third premolars have two roots, typically with one root mesial to the other. In brachycephalic dogs the premolars may be rotated 90° such that one root is palatal to the other. Although not typical, a third root of the maxillary third premolar may be found; it is located palatally between the mesial and distal roots. In this case, a palatal cusp of the maxillary third premolar is often present. The maxillary fourth premolar has three roots, two mesial (mesiobuccal and mesiopalatal) and one distal. The maxillary first and second molars have three roots, two buccal (mesiobuccal and distobuccal) and one palatal. The second, third, and fourth premolars of the mandible are two-rooted (one mesial, one distal). The first and second molars are two-rooted (one mesial, one distal). The third molar has a single root. A longitudinal groove may be present on the mesial and distal roots of the mandibular first molar and on the mesial surface of the distal root of the maxillary fourth premolar. These radicular grooves correspond with alveolar ridges in the alveoli and provide extra retentive surfaces and prevent rotation. The grooves may be appreciated radiographically giving the appearance of two PDLs and should be kept in mind during exodontic procedures [8]. Radicular grooves of the mandibular first molar may continue into the furcation, leading to a domed shape of the furcation. This shape should be kept in mind when performing periodontal therapy of this tooth [9]. Similarly, the maxillary fourth premolar has a domed shape at the furcation of the distal root and mesial root trunk as well as a fluted area just coronal to the furcation of the mesial roots [10].

The incisors and canine teeth of the cat are also all single-rooted. The maxillary first premolar is absent. The maxillary second premolar may have a single root, two individual roots, or two fused roots [11]. The maxillary third premolar has two roots and the maxillary fourth premolar has three roots, similar to the dog. The single maxillary molar may have a single root, two individual roots, or two fused roots [11]. The mandibular first and second premolars are absent. The mandibular third and fourth premolars and single mandibular molar each have two roots. The mesial root of the mandibular molar is approximately three times as wide (mesial to distal) as the distal root.

Cementum is an off-white or ivory colored hard substance that covers the root surface. Its composition is approximately 45–50% inorganic and 50–55% organic materials and water. The inorganic portion is primarily hydroxyapatite crystals and the organic part primarily collagen fibers and mucopolysaccharide ground substance.

Cementum formation begins at the neck or cervical circumference of the tooth, forming the CEJ. This junction is generally one of three types formed. These are cementum slightly overlapping the enamel, cementum meeting enamel evenly, or cementum failing to meet the enamel. In this third category, a cervical exposure of dentin occurs, which can result in tooth sensitivity should gingival recession occur.

Cementoblasts secrete cementum as they move away from the DCJ. In the cervical half to two-thirds of the root, the cementoblasts remain on the surface as the cementum is deposited and few if any of these cells become entrapped in the cementum, which is referred to as the acellular cementum. In the apical third, cementoblasts commonly surround themselves with cementum and become trapped. These trapped cells are referred to as cementocytes, and this portion of the cementum is identified as cellular cementum.

The cementoblast on the surface of the cementum deposits cementum around the ends of the PDL, making contact with them, and attaching them to the tooth. These fibers trapped within the cementum are known as Sharpey's fibers. The ends of the fibers entrapped in the alveolar bone are also known as Sharpey's fibers.

The cellular cementum of the root apex typically increases in thickness with time due to occlusal stresses of the tooth. This thickening is known as hypercementosis and is especially common in cats. Should this become excessive, a bulbous apex may form that can increase the difficulty of dental extraction.

Cementum is vital and has the ability to repair itself when injured. The cementoblasts on the surface and the embedded cementocytes receive nourishment from blood vessels of the PDL.

The bone of the jaws that form the socket support for the teeth is known as the alveolar bone. In the mature animal, the bone is approximately 65% inorganic and 35% inorganic in composition, and is mesodermal in origin. The alveolus is composed of three distinct layers. The compact bone on the inside of the socket next to the tooth is known as the cribriform plate and radiographically is termed the lamina dura. It has no periosteal covering, but is covered instead by the PDL. The fibers of the PDL embedded in the cribriform plate are called Sharpey's fibers (as are the Sharpey's fibers that are embedded within cementum). The compact bone rises to the top of the socket and then turns back to form the cortical plates. The top of the compact bone where the cortical and cribriform plates meet is known as the alveolar margin. The cortical plates are covered with periosteum. Between the two plates is spongy, cancellous, or trabecular bone. This is a form of bone marrow. The cribriform plate is constantly undergoing remodeling due to occlusal stresses. This may lead to additional bone being laid down on the plate, referred to as bundle bone.

The PDL is derived from the mesodermal cells of the dental sac. This formation begins after cementum deposition has been initiated. The dental sac on contact with the cementum forms fibroblasts, which produce collagen fibers at the same time other components of the PDL are developing. These are blood vessels, lymphatics, nerves, and various types of connective tissue cells. The nerves of the PDL are quite important in that they provide additional senses to the tooth. It has pain fibers, which the pulp has, but also pressure, heat, and cold fibers, which the pulp does not.

As the fibers of the PDL form, they begin to arrange themselves into three distinct categories, gingival, transseptal, and alveolodental. There are three types of gingival fibers, the dentogingival, alveologingival, and the circular gingival. Dentogingival fibers run from the cementum to either attached or free gingiva, providing a firm support for these tissues. Alveologingival fibers run from the alveolar bone to either attached or free gingiva, providing further support for these tissues. The circular gingival fibers are found in the free gingiva running in a circular pattern around the tooth, providing additional support to hold it firmly against the tooth. Transseptal fibers extend from the cementum of one tooth, across the interproximal area to the cementum of an adjacent tooth. Alveolodental fibers run from the alveolar bone to the cementum and are typically divided into five types: alveolar crest, horizontal, oblique, apical, and interradicular. Alveolar crest fibers run from the crest in an apical-oblique direction to the cementum. These aid in resistance to extrusion and horizontal movement of the tooth. The horizontal fibers also run from the cementum to the alveolar crest, but horizontally, to resist horizontal tooth movements. Oblique fibers extend from the cementum in a coronal-oblique pattern to the alveolar bone and resist occlusal stresses. Apical fibers run from the apex to the alveolar bone and resist extrusional forces. The interradicular fibers are found only in multirooted teeth and go from the interradicular crestal bone to cementum, counteracting various types of movement according to their direction of attachment.

The gingiva is discussed in Section 1.5.1 on oral mucus membrane found below.

1.4.4 Dentin and Pulp

Dentin and pulp should be thought as a single unit as the pulp produces the dentin throughout the life of the tooth and the dentin contains cellular units of the pulp.

Dentin is the hard yellow substance covered by the enamel and cementum. It is approximately 70% inorganic hydroxyapatite crystal (mucopolysaccharide ground substance) and about 30% organic (collagen fibers and water). Dentin grossly appears to be a solid structure, but is perforated by a multitude of openings. In microscopic cross-section, dentin has three distinct areas. The first is the dentinal tubule, which is a tube extending from the DEJ to the pulp. The odontoblastic process or Tomes' fiber is a cellular extension of the odontoblast within the dentinal tubule. The tubule is surrounded by the peritubular dentin. Intertubular dentin comprises the bulk of the dentinal substance and is located between dentinal tubules. The peritubular dentin is more highly mineralized than the intertubular dentin. In the dog the tubule is more ovoid at the periphery and circular toward the pulp. The tubule width has been measured to be 2.2 to 2.5 μm in diameter in the dog and 1–2 μm in the cat [12]. There are approximately 29 000 to 52 000 dentinal tubules per square millimeter of dentin cut in the maxillary canine of the dog [13]. The number increases with patient size and as the cut approaches the pulp.

Primary and secondary dentin are the two normal types of dentin. Primary dentin forms adjacent to the enamel prior to eruption of the tooth and secondary dentin forms after eruption. Primary dentin includes mantle dentin and the granular layer of Tomes. Mantle dentin is found adjacent to enamel and its organization differs from the rest of primary dentin [14]. The granular layer of Tomes is the area of primary dentin adjacent to cementum [14]. This layer is hypomineralized relative to dentin with a higher organic content and it has been hypothesized that the higher organic content may act to dissipate force transmitted through the PDL [15].

Secondary dentin is laid down in layers within the pulp cavity throughout life as long as the pulp is vital, resulting in the pulp cavity gradually decreasing in diameter with age via a process called pulp recession.

Tertiary dentin is formed in response to traumatic stimulation. This type of dentin differs histologically from the normal dentin in that it generally has few if any dentinal tubules present and appears to be very dense and unorganized. It forms immediately below the cause of the irritation and can result in alteration of normal pulp cavity anatomy. The amount of tertiary dentin formation is related to the amount of secondary dentin remaining after injury and the rate of formation appears to be dependent on the type of trauma [16]. Tertiary dentin may be subdivided into reactionary and reparative. Reparative dentin occurs when reserve mesenchymal cells differentiate into new odontoblasts which repair dentin in areas of trauma. Reactionary dentin occurs when existing odontoblasts are involved in the formation of tertiary dentin [1]. As tertiary dentin forms, odontoblasts may become trapped in the dentin, producing osteodentin [1]. Dead tract dentin occurs in an area of dentin in which the dentinal tubules are empty. This typically occurs due to some form of trauma that kills the odontoblasts, leaving the dentinal tubule empty. These open tubules are pathways for bacteria and other substances to make rapid access to the pulp. If the pulp remains viable, reparative dentin may close off the dead tract dentin [1].

Sclerotic dentin is dentin in which the tubule is mineralized. This process increases with age and trauma. This type of dentin increases the transparency of the dentin.

Interglobular dentin is areas of hypocalcified dentin found next to the mantle dentin. It is hypocalcified dentin that occurred during formation. Increased amounts of interglobular dentin occurs in cases of rickets and dental fluorosis [1]. Although Tomes' granular layer and interlobular dentin are both hypomineralized layers adjacent to the outer covering of the tooth, the layers differ more than by location only. The two layers also differ in individual mineral and proteoglycan content [17].

The pulp of the root is contained within the root canal. It consists of blood vessels, nerves, fibroblasts, collagen fibers, undifferentiated reserve mesenchymal cells, other cells of connective tissue, and odontoblasts. The pulp is divided into four zones: odontoblastic, cell-free or zone of Weil, cell-rich, and the pulp core. Odontoblasts are an integral part of the dentin, but are also the peripheral cells of the pulp, which is why pulp and dentin are often thought of as a complex versus individual tissues. As mentioned before, the odontoblastic process is an extension of the odontoblast found within the dentinal tubule. There has been speculation that the process may not typically reach the DEJ [18], but the current accepted theory is that, since components of the process are found through the whole tubule, the process must run the length of the tubule [1]. Odontoblasts do not undergo cell division and must be replaced by undifferentiated ectomesenchymal cells found within the cell-rich zone [1]. The potential for differentiation into new odontoblasts decreases with age and the veterinary dentist should consider this when deciding if vital pulp therapy and direct pulp capping are appropriate for a patient. The nerves are primarily sensory and transmit only the sensation of pain. There are some motor nerves that innervate the smooth muscles within the blood vessels. These result in constriction of the vessels in response to irritation.

The presence of lymphatics within the dental pulp of man and dog is controversial. While most historic studies in man demonstrate the presence of lymphatics, many studies in dogs do not. Recent studies using immunohistochemistry methods did not demonstrate the presence of classic lymphatics in man or the dog [19, 20].

When examined in medium sized dogs, the root canal topography roughly mirrors the external topography of the tooth. The exception is a mesiopalatal root of the maxillary fourth premolar that is compressed buccal to palatal [21]. The endodontist should consider this anatomy as the root canal may appear cylindrical when radiographs are studied, but may be oval, elliptical, or ribbon shaped.

The termination or apical end of the root is the apex. The apex can have a single opening, apical foramen, or multiple openings, the apical delta, through which vessels, nerves, and other structures may pass into the tooth to merge with the pulp. Canine and feline root anatomy is generally in the form of an apical delta. Each opening of the delta is known as an apical ramification. In one study the number of apical ramifications in the dog was found to be 5–20 with a decrease in the number of ramifications with increased age of the patient [22]. When a single apical foramen is present, cementum enters into the foramen. In the case of an apical delta, cementum does not enter into the apical ramifications [22]. The root canal terminus is several millimeters from the

surface of the root in the dog and cat and can be up to 6 mm in the cat [23]. This distance increases with age [23].

Non-apical ramifications or accessory canals occur where there is a break in Hertwig's epithelial root sheath during development. This prevents formation of dental hard tissue in a focal area and allows the pulp to communicate with the periodontium. These canals are typically found in the apical 1/3 of the root. Studies of incisors, canines, and maxillary fourth premolars of dogs showed an incidence of lateral canals to only be 2.4%. Of the four teeth that had lateral canals, one was a canine tooth and the other three were maxillary fourth premolar teeth [24]. When examining the maxillary fourth premolar and mandibular first molar, accessory canals were present in 68% of maxillary fourth premolars and 28.4% of mandibular first molars [25]. It has been demonstrated that the canine tooth of the cat has an average of 12.5 apical ramifications [23]. The endodontist should consider the likelihood of accessory canals when performing standard and surgical root canal therapy.

1.5 Mouth

The mouth (*os*) is the entrance or the oral cavity. It is solely the opening between the lips, designating the beginning of the digestive tract. The most rostral extent of the oral cavity is secured by the lips (*labia oris*). The upper lip (*labium superius*) and lower lip (*labium inferius*) converge at the angles of the mouth (*angulus oris*), forming the commissures of the lip.

1.5.1 Oral Mucous Membrane

The stratified squamous epithelium that runs from the margins of the lips to the area of the tonsils and lines the oral cavity is known as the oral mucosa or oral mucous membrane. These oral mucous membranes are divided into three categories. The first is the specialized mucosa, which is found on the dorsum of the tongue. Second is the masticatory mucosa, which undergoes routine masticatory trauma and stress and is generally parakeratinized or keratinized. This is the tissue of the hard palate and gingivae. The third is the general or lining mucosa, which comprises the remaining oral mucosa. It is non-keratinized to parakeratinized with an underlying connective tissue containing fairly well-developed collagen fibers that provide support, but still allow substantial movement of the overlying epithelium.

An interdigitation exists between the epithelium and the underlying connective tissue. The interdigitation of the submucosal connective tissue into the epithelium is termed the dermal papilla. The pegs of epithelium that insert into the connective tissue are known as rete ridges or pegs and cause small dimples in the gingival tissue known as gingival stippling. Stippling can be present or absent in healthy or diseased gingival tissue and therefore is not a reliable indication of gingival health [26–29]. The length of the pegs determines how tight or mobile the epithelium is attached to the underlying connective tissue. The lining mucosa has poorly developed pegs and is therefore fairly movable above the connective tissue. In comparison, the masticatory mucosa has well-developed rete pegs and consequently a tighter attachment.

The gingival masticatory mucosa is one of the most important support structures for the tooth. It is divided into two major parts, the attached gingiva and the free gingiva (marginal gingiva). The attached gingiva is attached to the alveolar bone via periosteum making it relatively immobile. It also has direct attachment to the cementum coronal to the alveolar bone. The width of the attached gingiva is important in planning periodontal treatment. It is widest on the maxilla at the canine teeth and generally thinner at the distal aspect of the fourth premolar and molars. On the mandible it is widest at the region of the first molar. The width of the attached gingiva is measured from the most apical aspect of the sulcus or periodontal pocket to the mucogingival junction.

The free gingiva projects in a coronal direction from the attached gingiva and is not attached to the tooth or alveolar bone. The free gingiva reflects toward the tooth to form shallow groove known as the gingival sulcus. The apical attachment of the sulcus is the epithelial attachment or the junctional epithelium, which directly attaches the gingiva to the tooth. In periodontal disease it is common for the sulcus depth to increase as attachment is lost. A peak of gingiva is found between proximal teeth known as the interdental papilla. The interdental papilla plays an important part in maintenance of gingival health by preventing food and debris from being impacted between the teeth. Between the vestibular and lingual aspects of the interdental papilla may be a peak or a valley of gingiva known as the col. The epithelium lining the sulcus, the col and the junctional epithelium are the very few areas of masticatory mucosa that are typically non-keratinized.

The mucogingival junction is the demarcation between the attached gingiva and alveolar mucosa, which is part of the general or lining mucosa. The mucogingival junction is also referred to as the mucogingival line or margin; it is most distinct on vestibular surfaces and less apparent on lingual and palatal surfaces.

1.5.2 Oral Cavity

The oral cavity (*cavum oris*) is typically considered to be the area extending from the lips to the oral pharynx at the level of the palatine tonsil. Rostrally it is bound by the lips, laterally by the cheeks (*buccae*), dorsally by the hard

and soft palates, and ventrally by the floor of the mouth. The oral pharynx is also the location where the digestive and respiratory tracts share a common, intersecting pathway.

The oral cavity is generally subdivided into two parts, the vestibule (*vestibulum oris*) and the oral cavity proper (*cavum oris proprium*). The vestibule is the theoretical space between the lips or cheeks and the teeth, gums, and alveolar ridges. The oral cavity proper extends from the alveolar ridge and teeth to the oral pharynx. It is additionally defined by the roof and floor of the mouth and is generally filled by the tongue.

1.5.2.1 Vestibule

The lips are comprised of three components, one of which is the facial stratified squamous epithelium portion. The vestibular component is covered with oral mucosa that is non-keratinized to parakeratinized squamous epithelium. The juncture where the lips meet the surrounding skin is the vermilion border [30], and the pigmented area within the borders is called the vermilion zone (named after the typical red color in human lips). The transitional zone between facial and vestibular components is the vermilion zone of the lip. The facial or skin part of the upper lip at the midline has an indentation known as the philtrum. Cleft lips are most commonly seen to occur at the lateral board of the philtrum. The point at which the oral mucosa and the top or bottom of the vestibule turn toward the alveolar ridge is known as the mucobuccal or mucolabial fold. The attachment of the mucosa to the alveolar bone is loose and movable, and the point where it becomes tightly attached is the mucogingival junction.

Within the vestibule is also contained the frenula, which are areas where folds of alveolar mucosa form a noticeable ridge of attachment between the lips and the gum. The dog has three primary frenula: one upper and two lower. The upper extends from the midline of the lip to the gingiva immediately below the two central incisors. The lower two extend from the lip to the level of the mandibular canine teeth.

1.5.3 Oral Cavity Proper

Within the oral cavity proper is contained a multitude of structures. Among those are the hard and soft palate, tongue, and floor of the mouth.

1.5.4 Hard Palate

The hard palate (*palatum durum*) is the soft tissue covered, bony vault of the oral cavity proper. It has a median raphe dividing the left and the right sides. The transverse epithelial ridges that radiate out from the median raphe are known as rugae. The rugae should meet symmetrically at the median raphe. Asymmetrical junctures of the rugae at the raphe may be an indication of poor migration of the left and right maxillary processes and a tendency toward cleft palate formation. It is not uncommon to find this asymmetrical rugal pattern in parents of cleft palate puppies. At the beginning of the raphe, immediately caudal to the two central incisor teeth, is a single rounded elevation of tissue known as the incisive papilla (*papilla incisiva*). At each lateral side of the incisive papilla are slit-shaped openings to the incisive ducts (*ductus incisivus*), which pass through the palatine fissure connecting the nasal and oral cavities. From the incisive papilla, the paired incisive ducts travel dorsocaudally to open into each nasal fossa; along their route they also communicate with the paired vomeronasal organs (*organum vomeronasale*). Deep to the incisive papilla is the incisive foramen through which the nasopalatine nerve travels to the soft tissue palatal to the rostral maxillary teeth.

1.5.5 Soft Palate

The soft palate (*palatum molle* or *velum palatinum*) is the unsupported soft tissue that extends caudally from the hard palate, free of the support of the palatine bone. It is relatively thick at its attachment to the hard palate and thins at the margins. In a relaxed state it typically makes contact with the oral surface of the epiglottis, but may also make contact with the respiratory surface of the epiglottis. The hard and soft palates serve to separate the oral cavity from the nasal cavity.

1.6 Osseous Tissue

The head consisting of the skull and mandible support all the teeth. The incisive (formerly premaxillae in the dog and still considered such in some species), maxillary, and mandibular bones have sockets, in which the teeth are seated. This firm attachment of teeth to support is termed *thecodontia*. The alveolar process is that portion of these bones that encompass and support the tooth structure. It is comprised of a cortical plate, trabecular bone, and the cribriform plate. The cortical plate is the outside wall of the process. The cribriform plate, known radiologically as the lamina dura, is the thin layer of bone within the tooth socket. Trabecular bone acts as the support between the cortical plate and the lamina dura. The alveolar crest is the occlusal portion of the alveolar process near the neck of the tooth. The bony partitions between adjacent teeth are referred to as interalveolar septa. Partitions between roots of an individual tooth are known as interradicular septa. The mandibles and maxillae containing the teeth are known as the jaws.

The paired incisive bones accommodate the six maxillary incisor teeth. The bones meet at the mesial line and each articulates with the ipsilateral maxilla at the incisivomaxillary suture. The root of the maxillary canine tooth passes through this suture with the incisive bone housing a portion of the alveolus on the palatal side. The paired palatine fissures are situated in the palatine process of each maxillae directly caudal to the incisor teeth. The main branches of the palatine vessels pass through these fissures. The maxillae act as the mooring for the remainder of the upper dentition. This includes the bulk of the canine, four premolars, and two molars in each maxilla in the dog. The maxillae contain the canine, three premolars, and single molar in the cat. Its lateral wall is relatively thin. This results in prominences in the alveolar bone lateral to many of the tooth roots. These prominences, called alveolar juga, act as landmarks in certain surgical endodontic procedures. The palatine process of each mandible projects medially and along with the paired incisive and palatine bones, serve as the bony support of the hard palate. The mandibles are two bilateral bones attached rostrally at the midline by a strong fibrous joint, referred to as the mandibular symphysis. Each mandible is comprised of two major sections, the body, and ramus (Figure 1.6). The body is composed of the incisive part (*Pars incisiva*) containing the incisors and the molar part (*Pars molaris*), which contains the premolars and molars. On the medial surface of the body at the caudal extent the mandibular foramen is present, located at midpoint between the third molar and angular process in the dog. The mandibular artery, vein, and nerve enter the mandibular canal through this foramen. The artery, vein, and nerve exit the mandibular canal via the rostral, middle, and caudal mental foramina. The rostral mental foramen is located in the incisive part of the mandible between the first and second incisors. The middle mental foramen is located in the molar part at about the level of the apex of the mesial root of the second premolar in the dog and at the level of the labial frenulum in the cat. The caudal mental foramen is located between the two roots of the third premolar.

The ramus constitutes the coronoid process, the condylar process, and the angular process and serves as the majority of insertion for the muscles of mastication. Projecting caudal from the ramus is the neck of the mandible, which supports the head, making the condylar process (http://www.avdc.org/nomenclature.html). The temporomandibular joint (TMJ) is formed by the condylar process of the mandible and the mandibular fossa of the temporal bone. This joint is sometimes referred to as the craniomandibular articulation (CMA). Depending on the species, the joint makes both translation and rotation movement capabilities, which allows for both rostral and lateral movement to a degree, as well as its rotation hinge action. The joint is separated into two compartments, the dorsal (temporal) and ventral (mandibular) by an articular disc. The disc attaches to the temporal bone caudomedially and to the condylar process laterally [31]. Fibrous tissue surrounds the joint capsule, which forms its strong lateral ligament.

A shallow concavity is present on the lateral aspect of the ramus named the masseteric fossa, which is the

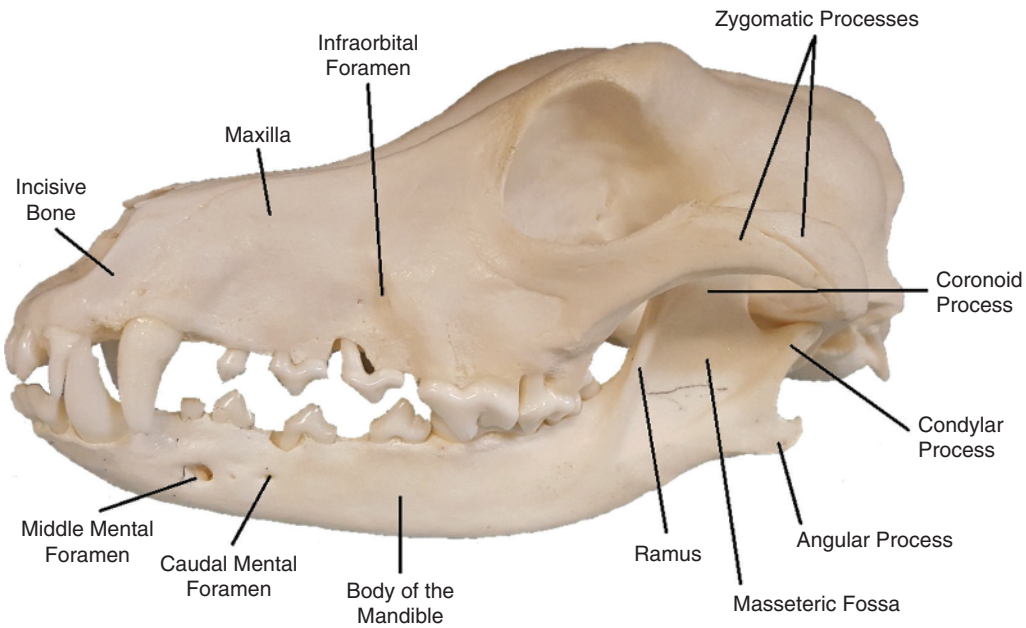

Figure 1.6 Normal skull anatomy of the dog.

insertion for the masseter muscle. Dorsal to the masseteric fossa is the crest of the ramus named the coronoid process. Ventral to the condylar process is a caudally projecting structure, which serves as insertion for the pterygoid and masseter muscles, named the angular process.

The morphology of the mandibular symphysis has been categorized into four types (I, II, III, and IV) [32]. Dogs and domestic cats have type I, meaning the interdigitation between folds of fibrocartilage from each side is shallow, allowing for less rigidity of the joint. Not all Felid species have this type. Many have type III, meaning the interdigitations are deeper and more numerous [32].

Although there is little lateral movement of the canine mandibles due to the strong lateral ligament and occlusion of the Canid dentition, unilateral lateral movement was described by Scapino [31]. This is a two-phase movement beginning with contraction of the zygomaticomandibularis muscle to nearly align the primary cusp of the mandibular first molar with the primary cusp of the maxillary fourth premolar. The caudal aspect of the mandibular symphysis then widens to allow the opposite mandible to move closer to its original position. With this two-phase movement, only one mandible and maxilla are chewing at a time. The zygomaticomandibularis muscle has been described by some as a portion of the masseter and as a separate muscle originating from the medial aspect of the zygomatic bone and inserting in the masseteric fossa of the vertical ramus [33].

The mandible and skull together can form various head types or shapes. Brachycephalic, mesaticephalic, and dolichocephalic are the three most common terms used to describe head shape. Brachycephalic indicates a short, wide head. The shortness of the head commonly results in rotation of premolar teeth. Boxers, Boston Terriers, Chinese Pugs, Bull Dogs, and Pekingese are some of the breeds commonly called brachycephalic. Mesaticephalic designates a head shape of medium portions. Beagles, German Shepard Dogs, Labrador Retrievers, and Poodles are typical examples. Dolichocephalic refers to a long, narrow head shape. The Collie, Borzoi, and Russian Wolf Hound are representative of this head type. Caudal crossbites, where the maxillary fourth premolar is in linguoversion (lingual) relative to the lower first molar, are more common in these breeds.

1.7 Muscles and Related Nerves of Mastication

The majority of the muscles associated with the masticatory action function to close the mandible [34]. Of this group the temporalis muscle is the largest and most powerful in the dog. Its origin is the temporal fossa. It inserts on the lateral and medial surfaces of the coronoid process of the ipsilateral mandible. In the dolichocephalic dog the paired muscles meet dorsally and form a middorsal sulcus where in the brachycephalic dog they do not meet [35]. The masseter muscle consist of three layers: superficial, middle, and deep. The muscle originates from the zygomatic arch (ventrally and medially) and inserts on the ramus of the mandible at the masseteric fossa and at the ventrolateral and ventromedial surfaces of the ramus. The lateral pterygoid muscle arises from the sphenoid bone and medial pterygoid muscles originates from the sphenoid, pterygoid, and palatine bones [35]. The lateral inserts on the medial aspect of the condylar process of the mandible. The medial inserts on the ventromedial aspect of the angular process of the mandible, forming a raphe with the masseter muscle. Identification of this fibrous raphe and elevation the medial pterygoid muscle is useful in the surgical approach to the caudal mandible [36].

The digastric muscle is responsible for opening the jaws, and arises from the paracondylar process of the occipital bone and inserts on the mandible along the ventral border. It has both a rostral and caudal portion (belly) separated by a raphe.

These muscles are all innervated by the mandibular branch of the trigeminal (V) nerve. Only the rostral belly of the digastric muscle is stimulated by the trigeminal nerve, as the caudal belly is innervated by the facial (VII) nerve. Of the muscles innervated by the trigeminal nerve, the masseter, temporal, medial, and lateral pterygoid, tensor tympani, and tensor veli palatine muscles have a unique myosin isoform type 2M, distinguished from the common type 2C fibers of limb muscles [37–39]. Although the rostral belly of the digastric muscle is innervated by the trigeminal nerve, it does not contain type 2M fibers [37]. In the case of masticatory myositis, circulating antibodies are directed specifically to these 2M muscle fibers and inflammation is limited to muscles with this unique myosin component [38]. The etiology of masticatory myositis (MM) is unknown, although it has been speculated that MM may result from antibodies generated in response to an infectious agent cross-reacting with endogenous antigens [39]. These fibers are also found in most carnivores and primates, but masticatory myositis of type 2M fibers has only been reported in the dog.

These muscles, in coordination with the teeth, have a tremendous biting force potential. Biting force is the pressure, typically measured in pounds per square inch (psi), exerted by the teeth when engaged by the muscles of mastication. In man they have been shown to have about 250 to 300 psi of passive biting force [40]. Additionally, with man the abrupt closing or snapping of the jaws shut on the few millimeters of tooth cusp

contact can reach a sudden localized biting force of 25 000 to 30 000 psi, which can easily result in tooth fractures or injury to the periodontal structures [41]. In the dog the passive biting force has been indicated to be possibly much greater than that of a human, reaching between the 300 to 800 psi range [42]. This would place the sudden localized biting force potential at 30 000 to 80 000 psi, if correct.

1.8 Neurovascular Structures of Clinical Significance

The arteries of significance in clinical dentistry and oral surgery have a common origin in the common carotid artery. This artery branches into the internal and external carotid arteries. The internal carotid artery blood supply is insignificant in the cat. The external carotid artery continuing as the maxillary artery provides the majority of cerebral blood flow. The maxillary artery lies medial to the angular process of the mandible and branches into the maxillary rete before entering the skull through the orbital fissure. The intracranial portion of the rete forms the cerebral arteries. The extracranial portion is bordered by the pterygoid muscles medially and temporal muscle laterally. It is currently believed that overextension of the mandibles of the cat can lead to compression of the rete and/or compression of the maxillary artery by the angular process of the mandible, leading to cerebral ischemia and resulting in temporary or permanent cortical blindness, loss of hearing, or possibly death [43, 44]. Thus use of spring-loaded speculums is not recommended in feline patients.

The maxillary artery is a branch of the external carotid artery. Just caudal to the maxilla the minor palatine artery branches off the maxillary artery and courses ventral to the palatine bone and maxilla before anastamosing with the major palatine artery. The major palatine artery shares a common trunk with the sphenopalatine artery [34]. The major palatine artery exits the maxilla through the major palatine foramen, located at the level of the distal extent of the fourth premolar and between the corresponding dental arch and palatal midline. The artery travels rostrally through the ipsilateral palatine groove. A branch of the artery travels buccally between the maxillary third incisor and canine [34]. The remainder of the artery passes the palatine fissure and anastamoses with the sphenopalatine artery. The major palatine nerve exits through the same foramen. It is of clinical significance if regional anesthesia for palatal surgery is to be performed. The artery sharing a trunk with the major palatine is the sphenopalatine artery, which courses along the ventral floor of the nasal cavity before anastamosing with the major palatine, as mentioned previously.

The infraorbital artery is the continuation of the maxillary artery after the trunk containing the major palatine and sphenopalatine arteries. It enters the maxilla via the maxillary foramen caudally and travels through the infraorbital canal, giving branches to the zygomatic gland and the alveolar bone of the maxillary teeth [35]. The artery exits the infraorbital foramen just mesial to the mesiobuccal root of the maxillary fourth premolar at the level of the apical half of the root. It begins to branch after exiting the foramen into the dorsal and lateral nasal arteries. The infraorbital nerve follows the same course.

The mandibular arteries and the associated veins are paired structures coursing through the mandibular body, providing the primary blood supply for the teeth and periodontium of the mandibles. The artery is a branch of the maxillary artery. In enters into the mandible via the mandibular foramen. This foramen is located on the medial side of the mandible and between the third molar and angular process in the dog and between the molar and angular process in the cat. The mandibular artery travels through the mandibular canal. The canal is not a medullary canal and treating fractures of the body via an intramedullary pin through this canal will damage the associated neurovascular bundle. When examined in cross-section, the mandibular nerve is located in the dorsolateral portion of the canal with the vein in the ventromedial portion and the artery in the middle [35]. The caudal, middle, and rostral mental arteries are the terminus of the mandibular artery and exit through the same named foramina.

1.9 Tongue

The tongue (*lingua*) is a mobile prehensile structure of the oral cavity used for grooming and the intake of food and fluids. It is formed primarily of skeletal muscle covered by a mucosal membrane. Its actions are controlled by both intrinsic and extrinsic muscles of the tongue (*musculi linguae*). The intrinsic muscle of the tongue is the m. lingualis proprius, which contains superficial longitudinal, deep longitudinal, perpendicular, and transverse muscle fibers. These as a unit produce the complicated protrusion and prehensile movements of the tongue and prevent trauma from teeth. It is innervated by the hypoglossal nerve. The extrinsic muscles are the m. styloglossus, m. hypoglossus, and m. genioglossus. The m. styloglossus draws the tongue caudally, the m. hypoglossus retracts and depresses it, and the m. genioglossus depresses and protrudes the tongue. All three of the extrinsic muscles are also innervated by the hypoglossus nerve. The total innervation of the tongue is by the lingual (V), chorda tympani (VII), glossopharyngeal (IX), and hypoglossal (XII) nerves. The afferent activities

of tactile, pain, thermal, and taste, and the efferent activities of tongue gland innervation are controlled by the lingual (V), chorda tympani (VII), and glossopharyngeal (IX) nerves.

The tongue is divided into a tip (*apex linguae*), margin (*margo linguae*), body (*corpus linguae*), and a root (*radix linguae*). It is wide and thin at the two lateral margins that meet at the tip or most rostral portion of the margins, but it becomes thicker toward the body and root. The dorsum is covered with a thick, rough cornified mucous membrane known as the lingual mucosa (*tunica mucosa linguae*). The ventral surface is covered with a smooth, thinner, and less cornified surface. The thicker dorsal mucosa forms into papillae with various shapes and functions. The rostral two-thirds is thickly covered with short, pointed, filiform papillae (*papillae filiformes*) with their tips directed caudally, which may aid in grooming. In the root area are found soft, long, conical papillae (*papillae conicae*) pointing caudally, which probably have a mechanical function. Fungiform papillae (*papillae fungiformes*) are mushroom shaped and scattered along the dorsal sides and the anterior portion of the tongue. Each contains up to eight taste pores, although some have none. A small number of vallate papillae (*papillae vallate*) are found at the posterior border of the tongue where the conical papillae begin. There are three to six vallate papillae in the dog, with four being the most common. These may be simple or complex and contain taste buds. The foliate papillae (*papillae foliatae*) are immediately rostral to the palatoglossal fold located on the dorsolateral aspect of the caudal third of the tongue and contain taste buds. Marginal papillae (*papillae marginales*) are present at birth along the margins of the rostral half of the tongue in the dog. They are mechanical in nature, aiding in nursing by sealing the lips to the nipple for suction and reduce milk spillage around the tongue. These normally disappear as puppies progress to more solid foods. The taste buds (*caliculus gustatorius*) are pear-shaped organs located in the gustatory papillae: fungiform, vallate, and foliate papillae. The filiform, conical, and marginal papillae are mechanical papillae containing no taste buds. There is an extensive number of lingual salivary glands (*glandulae linguales*) in the surface of the tongue. The dorsum of the tongue is divided by a median groove in the anterior portion.

The ventral part of the tongue is covered by smooth mucous membrane. Extending from the floor of the mouth to the anterior ventral base is a fold of tissue known as the lingual frenulum (*frenulum linguae*). Within the ventral portion of the tip, along the midline, is a fusiform cord, composed of fat, muscle, occasionally islands of cartilage, and fibrous sheath tissue known as the lyssa. The lyssa, formerly known as the lytta, is typically about 4 cm in a medium-sized dog and may act as a stretch receptor for the rostral portion of the tongue. Beneath the smooth mucosa of the underside of the tongue is a highly vascular network. The primary blood supply to the tongue is through the paired lingual arteries (*arteria lingualis*) with return via the lingual veins.

The base of the lingual frenulum rests in the floor of the mouth. To either side of this base are small elevations of tissue known as the sublingual caruncles (*caruncula sublingualis*). These serve as the anatomical locations of the duct openings for the sublingual and mandibular salivary glands. A fold of tissue known as the sublingual fold (*plica sublingualis*) extends back from the sublingual caruncle along the floor of the mouth with the side of the tongue. This fold marks the path of numerous structures that run across the floor of the mouth, including the ducts for the sublingual and mandibular salivary glands.

1.10 Salivary Glands

Submerged beneath the mucous membranes of the oral cavity exists a complex system of salivary tissues. These salivary tissues secrete saliva, a serous and mucous fluid, which contains a complex mixture of inorganic and organic substances such as electrolytes, proteins, hormones, minerals, bactericidal substances, vitamins, and, in some species, enzymes. In most animals, a relatively high concentration of amylase is found in saliva from the parotid and slightly lower levels in mandibular secretions. The concentrations of amylase, however, are relatively low in the domestic dog and cat. Fluid formation in the salivary tissue occurs in the acini.

Isotonic water transport is an acinar secretory process in which the main active step is a sodium transport system from the intracellular to the intercellular space. The duct epithelium can secrete and absorb water as well as the basic electrolytes calcium, chloride, bicarbonate, sodium, and potassium. It is also involved with the concentration of iodide and thiocyanate. The concentrations of some salivary constituents such as iodide, calcium, and bicarbonate is dependent upon their blood plasma levels; therefore, the saliva/plasma ratio of these electrolytes remains relatively constant.

Regulation of saliva secretions is controlled by the autonomic nervous system. The centers for saliva secretion are located on the salivary nuclei in the medulla oblongata. The salivary glands are regulated by a double efferent pathway via the parasympathetic and sympathetic portions of the autonomic nervous system. A basal flow of saliva is continuously stimulated by the parasympathetic system's efferent impulses from the salivary nuclei. Sight, taste, and olfactory stimulation initiates afferent impulses to the nuclei, which in turn release

efferent impulses to the parasympathetic system to increase salivation. Sympathetic stimulation may increase salivary flow to the mouth due to contraction on the myoepithelial cells by constriction of the lumen of both the acini and the ducts. Sympathetic stimulation actually increases salivary secretion by the acinar cells of some salivary glands in the cat.

Saliva has both qualitative and quantitative aspects. The quantitative properties are twofold, the basal and surge flowrates. The basal production level maintains the protective moist mucoid layer environment for the teeth and mucous membranes. This layer possibly aids in protecting the mucosa from the detrimental effects of bacterial and other toxins, as well as to minor traumas. The flowrate aids to mechanically flush and cleanse the teeth and mucous membranes of the oral cavity, possibly limiting the microbial population in the oral environment. The elevated surge flowrate aids to flush mucoid trapped bacteria and foreign materials from the mouth and into the acidic gastric system for destruction. Additionally, the mucous coats foodstuffs to lubricate while the serous volume acts to carry the material through the tract with the aid of muscular activity.

Qualitatively it is a complex combination of organic and inorganic substances, with a pH component. In broad groups these can be classified as minerals and electrolytes, enzymes and other proteins, low molecular weight compounds, and vitamins. The ultimate composition is generally regulated by the autonomic nervous system, the serum level of systemic counterparts, and humoral activity. The qualitative portion contains a potent antimicrobial component consisting of mucous, pH, lysosomes, antilactobacillus thiocyanate-dependent factors, immunoglobulins, fluoride, and many other possible factors. The teeth are theoretically affected by saliva by reduction of tooth solubility, buffering acids, remineralization, antimicrobial actions, and mechanical cleansing. Enzymes, such as amylase, aid in initiation of digestion while food is still in the mouth. The mixed pH of saliva varies widely, even in individuals. It is affected by numerous factors, but flowrate and duration appear to be the most important. As compared to a slightly acidic average of pH 6.5–7.5 for humans, dogs have shown salivary pH values in a range from 8.5 to 8.65 [45]. Lavy also suggested that the higher salivary pH in dogs compared to humans, while protecting against carious lesions, could lead to precipitation of calcium salts and lead to increased calculus accumulation. Most other domestic animals demonstrate a slight alkaline pH (the horse at 7.5 [46]), except ruminants, which are distinctively alkaline (the cow at 8.53–8.71 [47]).

There is a large assortment of salivary glands and tissue in the oral cavity or that empty into it. The lingual, labial, buccal, and palatine salivary glands represent a large number of very small disseminated glands that secrete minute amounts of serous or mucus fluid into the oral cavity. The lingual salivary glands are located in the submucosa and muscles of the tongue in its caudal third, with numerous small excretory ducts. The labial glands are found scattered throughout in the submucosa of the lips, with numerous small excretory ducts. The buccal glands are situated in the submucosa of the buccal cavity, with numerous small excretory ducts. The palatine glands are located in the submucosa of the ventral surface of the soft palate. There are four or five larger glands more clinically significant in disease and saliva production. In the dog these are the parotid, mandibular, sublingual, and zygomatic (Figure 1.7). In the cat the molar salivary glands are also of clinical importance (Figure 1.8).

The parotid salivary gland (*glandula parotis*) is divided into a superficial portion (*par superficialis*) and a deep portion (*pars profunda*). The gland is generally V-shaped and is located beneath the ear and behind the posterior border of the mandible and the TMJ. Although a part of the gland is superficial in location, its blending with the surrounding anatomy makes it typically difficult to palpate. The parotid lymph nodes usually lie under the rostroventral border of the parotid salivary gland.

The parotid duct (*ductus parotideus*) is formed by the union a few millimeters from the gland of two or three tributaries originating from the ventral third of the rostral border of the gland. It proceeds rostrally and toward the cheek along the lateral surface of the masseter muscle, closely paralleling the muscle fibers. Near the terminal end, the duct generally makes two slight right-angle turns, one medially and one vertically, before passing through the buccal mucosa and opening into the buccal vestibule. The opening is at the parotid papilla located at the rostral end of a blunt ridge of mucosa superficial to the distal root of the upper fourth premolar. For catheterization of the ducts, the terminal angulations can be relatively straightened by lightly retracting the papilla rostrally. The gland produces a primarily serous type saliva.

Accessory parotid glands (*glandulae parotis accessoria*) are typically present in the dog. These are usually located bilaterally above the duct and range from single, small lobules to glandular masses over a centimeter in length. These each have small ducts that empty into the main parotid duct.

The mandibular gland (*glandulas mandibularis*) is an ovoid, compact, yellow to buff colored gland. In the dog, cat, and most domestic animals, the gland is located just caudal to the angle of the jaw and is easily palpable. In most primates, however, it is located beneath the mandible and is referred to as the submandibular salivary gland. The gland shares a connective tissue capsule with a portion of the sublingual gland. In the dog it rests

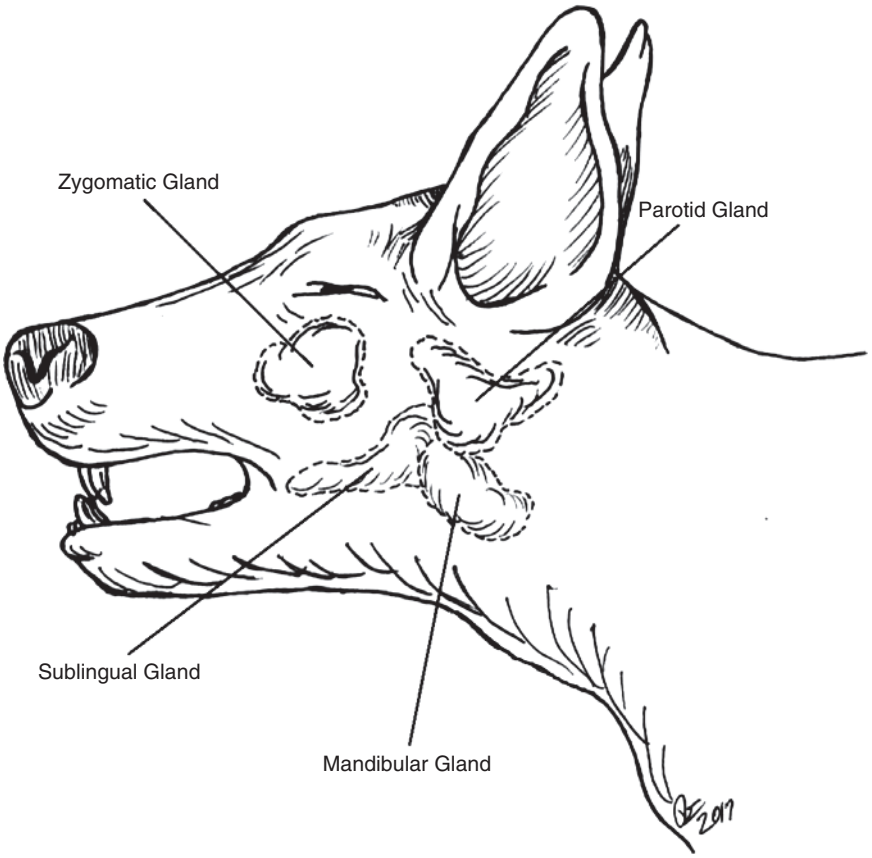

Figure 1.7 Salivary glands of the dog.
Source: Courtesy of Josephine Banyard.

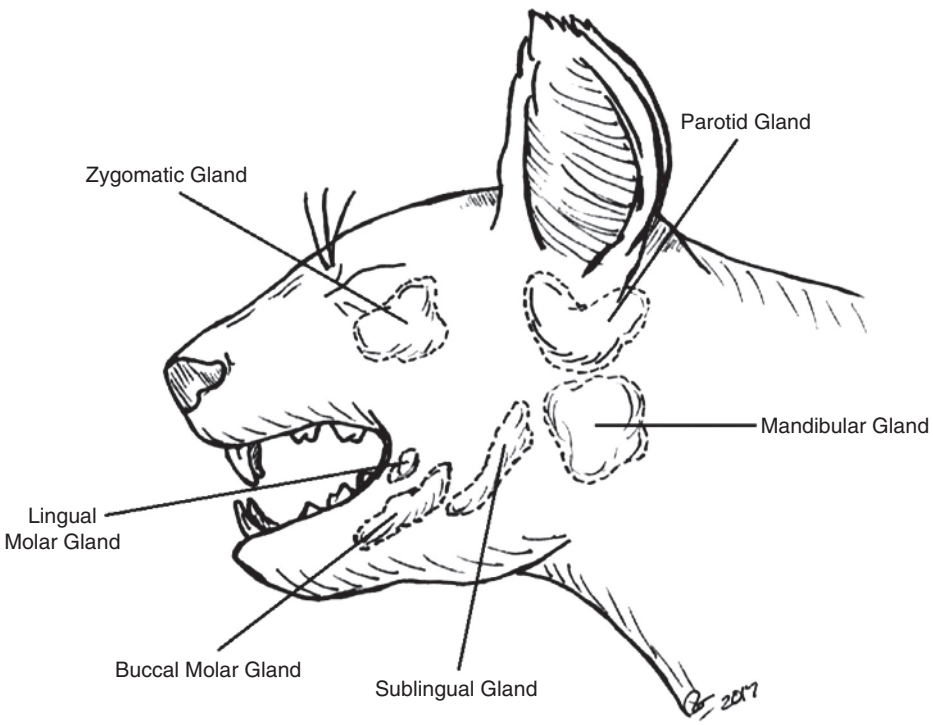

Figure 1.8 Salivary glands of the cat.
Source: Courtesy of Josephine Banyard.

between the linguofacial and maxillary veins, while in the cat these veins may unite over the lateral surface. It is classified as a mixed gland in the dog.

The mandibular duct (*ductus mandibularis*) emerges from the deep or medial surface of the gland. It courses rostromedially between the mylohyoid and styloglossus muscles, medially to the mandible. The duct emerges from the sublingual mucosa into the oral cavity proper below the tongue on the small sublingual papilla or caruncle (*caruncula sublingualis*), near the rostral attachment of the lingual frenulum. The small opening of the duct appears as a small red slit along the frenulum's ventral surface. Approximately 30% of dogs have a shared or common opening with the sublingual duct.

The sublingual salivary gland (*glandula sublingualis*) is a slightly darker pink than the mandibular gland and is the smallest of the four major salivary gland pairs in the dog. The gland is divided into monostomatic (*par monostomatica*) and polystomatic (*pars polystomatica*) portions. The monostomatic part consists of the portion contained within the mandibular gland capsule and a group of loose lobules that cluster close to the sublingual and mandibular ducts near the root of the tongue. These all discharge into the major sublingual duct (*ductus sublingualis major*), which typically travels just dorsal to the mandibular duct, opening one to two millimeters caudal to, or in common with, it on the sublingual caruncle.

The polystomatic portion is a group of 6–12 small scattered lobules of sublingual salivary tissue. These do not communicate with the major sublingual duct, but empty into several minor sublingual ducts (*ductus sublingualis minores*). These empty into the oral cavity between the tongue and mandible in the lateral sublingual recess. The sublingual gland is smaller in the cat with the polystomatic portion sometimes absent.

The zygomatic gland (*glandula zygomatica*) is an enlarged member of the dorsal buccal gland group and was formerly known as the orbital gland. It is located ventral to the rostral end of the zygomatic arch, making access relatively difficult. It is well developed in most carnivores and found only in the dog and cat in domestic mammals. There is one major duct (*ductus glandulae zygomaticae major*) and up to four minor ducts (*ductus glandulae zygomaticae minores*) that travel from the gland to the caudal part of the buccal vestibule. The major duct opens caudal to the parotid papillae and caudal to the last upper molar on a ridge of mucosa at the zygomatic papilla (*papilla zygomatica*). The minor ducts open caudal to the major ducts and appear as a line of small red dots on the mucosa.

There are two paired well-developed molar salivary glands in the cat. The buccal molar gland (*glandula molares buccalis*), also referred to as the labial molar gland, is a modified ventral buccal gland located between the orbicularis oris muscle and the mucous membrane of the lower lip at the angle of the mouth. It empties into the buccal cavity by several small ducts. The second gland is the lingual molar gland (*glandula molars lingualis*), located within a membranous bulge lingual to the mandibular molar tooth. This gland is the tubuloacinar gland with multiple small openings through several small ducts that open on the lingual surface of the membrane [48].

References

1 Nanci, A. (2013). Enamel: composition formation and structure. In: *Ten Cate's Oral Histology: Development, Structure, and Function*, 8e, 122–164. St. Louis, MO: Elsevier.

2 Skobe, Z., Prostak, K. S., and Trombly, P. L. (1985). Scanning electron microscope study of cat and dog enamel structure. *J. Morphol.* 184: 195–203.

3 Osborn, J. W. (1971). The relationship between the optical density of prism borders in dog tooth enamel and the angle from which they are viewed. *Arch. Oral Biol.* 16 (9): 1055–1059.

4 Chai, H., Lee, J. J., Constatino, P. J. et al. (2009). Remarkable resilience of teeth. *Proc. Natl Acad. Sci.* 106 (18): 7289–7293.

5 Bajaj, D., Nazari, A., Eidleman, N., and Arola, D. D. (2008). A comparison of fatigue crack growth in human enamel and hydroxyapatite. *Biomaterials* 29 (36): 4847–4484.

6 Walker, B. N., Makinson, O. F., and Peters, M. C. (1998). Enamel cracks. The role of enamel lamellae in caries initiation. *Aust. Dent. J.* 43 (2): 110–116.

7 Crossley, D. A. (1995). Tooth enamel thickness in the mature dentition of domestic dogs and cats – preliminary study. *J. Vet. Dent.* 12 (3): 111–113.

8 Dupont, G. A. and DeBowes, L. J. (2009). Intraoral radiographic anatomy of the dog. In: *Atlas of Dental Radiography in Dogs and Cats*, 5–80. St. Louis, MO: Saunders.

9 Smith, M. M., Massoudi, L. M., Nunes, J. D. et al. (1992). Furcation anatomy of the first mandibular molar in dogs. *Am. J. Vet. Res.* 53 (2): 242–245.

10 Smith, M. M., Moon, M. L., Callan, M. et al. (1990). Furcation entrance anatomy of the fourth maxillary premolar in dogs. *Am. J. Vet. Res.* 51 (12): 2050–2053.

11 Verstraete, F. J. and Terpak, C. H. (1997). Anatomical variations in the dentition of the domestic cat. *J. Vet. Dent.* 14 (4): 137–140.

12 DeLaurier, A. L., Boyde, A., Horton, M. A., and Price, J. S. (2006). Analysis of the surface characteristics and mineralization status of feline teeth using scanning electron microscopy. *J. Anat.* 209: 655–669.

13 Robb, L., Mark, J., Steenkamp, G. et al. (2007). Scanning electron microscopic study of the dentinal tubules in dog canine teeth. *J. Vet. Dent.* 24 (2): 86–89.

14 Nanci, A. (2013). Enamel: dentin-pulp complex. In: *Ten Cate's Oral Histology: Development, Structure, and Function*, 8e, 165–204. St. Louis, MO: Elsevier.

15 Shackleford, J. M. (1971). The structure of Tomes' granular layer in dog premolar teeth. *Anat. Rec.* 170 (3): 357–363.

16 Ivanovic, V. and Santini, A. (1989). Rate of formation of tertiary dentin in dogs' teeth in response to lining materials. *Oral Surg. Oral Med. Oral Pathol.* 67: 684–688.

17 Tsuchiya, M., Sasano, Y., Kagayam, M. et al. (2001). Characterization of interglobular dentin and Tomes' granular layer in dog dentin using electron probe microanalysis in comparison with predentin. *Calcified Tissue Int.* 68: 172–178.

18 Holland, G. R. (1975). The dentinal tubule and odontoblast process in the cat. *J. Anat.* 120 (1): 169–177.

19 Gerli, R., Secciani, I., Soziio, F. et al. (2010). Absence of lymphatic vessels in human dental pulp: a morphological study. *Eur. J. Oral Sci.* 118 (2): 110–117.

20 Martin, A., Gasse, H., and Staszyk, C. (2010). Absence of lymphatic vessels in the dog dental pulp: an immunohistochemical study. *J. Anat.* 217: 609–615.

21 Rochette, J. (1996). Identification of the endodontic system in carnassial and canine teeth in the dog. *J. Vet. Dent.* 13 (1): 35–37.

22 Masson, E., Hennet, P. R., and Calas, P. L. (1992). Apical root canal anatomy in the dog. *Endod. Dent. Traumatol.* 8: 109–112.

23 Hennet, P. R. and Harvey, C. E. (1996). Apical root canal anatomy of canine teeth in cats. *Am. J. Vet. Res.* 57: 1545–1548.

24 Gioso, M. A., Knobl, T., Venturini, M. A. F. A. et al. (1997). Non-apical root canal ramifications in the teeth of dogs. *J. Vet. Dent.* 14 (3): 89–90.

25 Hernandez, S. Z., Negro, V. B., and Maresca, B. M. (2001). Morphologic features of the root canal system of the maxillary fourth premolar and the mandibular first molar in dogs. *J. Vet. Dent.* 18 (1): 9–13.

26 Greene, A. H. (1962). Study of the characteristics of stippling and its relation to gingival health. *J. Periodontol.* 33: 176.

27 Hurt, W. C. (1976). *Periodontics in General Practice*, 1–65. Springfield, IL: CC Thomas Pub.

28 King, J. D. (1945). Gingival disease in Dundee. *J. Dent. Res.* 65: 9.

29 Orban, B. (1948). Clinical and histological study of surface characteristics of the gingiva. *Oral Surg.* 1: 827.

30 Zwemer, T. J. (1993). *Boucher's Clinical Dental Terminology*, A Glossary of Accepted Terms in all Disciplines of Dentistry, 4e. St. Louis, MO: Mosby.

31 Scapino, R. P. (1965). The third joint of the canine jaw. *J. Morphol.* 116: 23–50.

32 Scapino, R. (1981). Morphological investigation into the functions of the jaw symphysis in carnivorans. *J. Morphol.* 167: 339–375.

33 Yang, H. M., Hu, K. S., Song, W. C. et al. (2010). Innervation patterns of the canine masticatory muscles in comparison to human. *Anat. Rec.* 293: 117–125.

34 Evans, H. E. and deLahunta, A. (2000). The head. In: *Miller's Guide to the Dissection of the Dog*, 5e, 259–276. Philadelphia, PA: Saunders.

35 Evans, H. E. (1993). The heart and arteries. In: *Miller's Anatomy of the Dog*, 3e, 586–681. Philadelphia, PA: Saunders.

36 Verstraete, F. J. M., Arzi, B., and Bezuidenhout, A. J. (2012). Surgical approaches for mandibular and maxillofacial trauma repair. In: *Oral and Maxillofacial Surgery in Dogs and Cats*, 259–264. Philadephia, PA: Saunders.

37 Bubb, W. J. and Sims, M. H. (1985). Fiber type composition of rostral and caudal portions of the digastric muscle in the dog. *Am. J. Vet. Res.* 47 (8): 1834–1842.

38 Shelton, G. D., Bandman, E., and Cardinet, G. H. (1985). Electrophoretic comparison of myosins from masticatory muscles and selected limb muscles in the dog. *Am. J. Vet. Res.* 46 (2): 493–498.

39 Shelton, G. D., Cardinet, G. H., and Bandman, E. (1988). Expression of fiber type specific proteins during ontogeny of canine temporalis muscle. *Muscle Nerve* 11 (2): 124–132.

40 Melmed, C., Shelton, G. D., Bergman, R., and Barton, C. L. (2004). Masticatory muscle myositis: pathogenesis, diagnosis and treatment. *Compend. Cotin Educ. Vet.* 26 (8): 590–605.

41 Fagan, D. A. (1986). Diagnosis and treatment planning. *Veterinary Clinics of North America: Small Animal Practice* (ed. P. Frost) 16 (5): 789.

42 Tholen, M. A. (1983). *Concepts in Veterinary Dentistry*, 135. Edwardsville, KS: Veterinary Medicine Publishing Co.

43 Stiles, J., Weil, A. B., Packer, R. A., and Lantz, G. C. (2012). Post-anesthetic cortical blindness in cats: twenty cases. *Vet. J.* 193 (2): 367–373.

44 Barton-Lamb, A. L., Martin Flores, M., Scrivani, P. V. et al. (2013). Evaluation of maxillary arterial blood flow in anesthetized cats with the mouth closed and open. *Vet. J.* 196: 325–331.

45 Lavy, E., Goldberger, D., Friedman, M., and Steinberg, D. (2012). pH values and mineral content of saliva in different breeds of dogs. *Israel J. Vet. Med.* 67 (4): 244–248.

46 Alexander, F. (1966). A study of parotid salivation in the horse. *J. Physiol.* 184: 646–656.

47 Reid, J. T. and Huffman, C. F. (1949). Some physical and chemical properties of bovine saliva which may affect rumen digestion and synthesis. *J. Dairy Science.* 32 (2): 123–132.

48 Okuda, A., Inouc, E., and Asari, M. (1996). The membranous bulge lingual to the mandibular molar tooth of a cat contains a small salivary gland. *J. Vet. Dent.* 13 (2): 61–64.