

# Structure and function of the skin, hair and nails

*Skin, skin is a wonderful thing,  
Keeps the outside out and the inside in.*

Anon.

It is essential to have some background knowledge of the normal structure and function of any organ before you can hope to understand the abnormal. Skin is the icing on the anatomical cake, it is the decorative wrapping paper, and without it not only would we all look rather unappealing, but also a variety of unpleasant physiological phenomena would bring about our demise. You have probably never contemplated your skin a great deal, except in the throes of narcissistic admiration, or when it has been blemished by some disorder, but hopefully by the end of this first chapter you will have been persuaded that it is quite a remarkable organ, and that you are lucky to be on such intimate terms with it.

---

## Skin structure

The skin is composed of two layers: the *epidermis* and the *dermis* (Figure 1.1). The epidermis, which is the outer layer, and its appendages (hair, nails, sebaceous

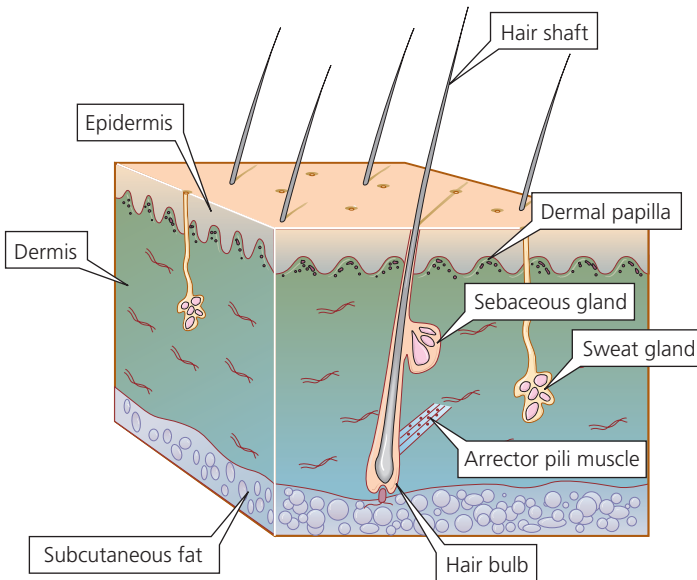
glands and sweat glands), are derived from the embryonic ectoderm. The dermis is of mesodermal origin.

## The epidermis

The epidermis is a stratified squamous epithelium, with several well-defined layers.

## Keratinocytes

The principal cell type is known as a *keratinocyte*. Keratinocytes, produced by cell division in the deepest layer of the epidermis (basal layer), are carried towards the skin surface, undergoing in transit a complex series of morphological and biochemical changes known as *terminal differentiation* (keratinization) to produce the surface layer of tightly packed dead cells (stratum corneum or horny layer), which are eventually shed. In health, the rate of production of cells matches the rate of loss so that epidermal thickness is constant. Epidermal kinetics are still not fully understood, particularly the balance between stem cells and those cells which differentiate into fully functional keratinocytes. This differentiation process is under genetic control and mutations in



**Figure 1.1** The structure of the skin. The relative thickness of epidermis and dermis varies considerably with body site.

the genes controlling epidermal function are responsible for a variety of diseases, such as atopic eczema and the ichthyoses.

So-called *intermediate filaments*, present in the cytoplasm of epithelial cells, are a major component of the architectural construction of the epidermis (the *cytoskeleton*). The intermediate filaments are composed of proteins known as keratins, each of which is the product of a different gene. Pairs of keratins are characteristic of certain cell types and tissues. The mitotically active keratinocytes in the basal layer express the keratin pair K5/K14, but differentiation progresses as the cells migrate towards the epidermal surface and the expression of K5/K14 is down-regulated and that of K1/K10 is induced.

As cells reach the higher layers of the epidermis, the filaments aggregate into *keratin fibrils* under the influence of a protein known as *filaggrin* (filament-aggregating protein) - filaggrin is derived from its precursor *profilaggrin*, present in *keratohyalin granules*, which constitute the granules in the granular layer. Derivatives of the proteolysis of filaggrin are major components of natural moisturizing factor (NMF), which is important in the maintenance of epidermal hydration. Loss-of-function mutations in *FLG*, the gene encoding filaggrin, have profound effects on epidermal barrier function, underlying ichthyosis vulgaris and strongly predisposing to atopic eczema; carriers of these mutations have reduced levels of NMF in the stratum corneum.

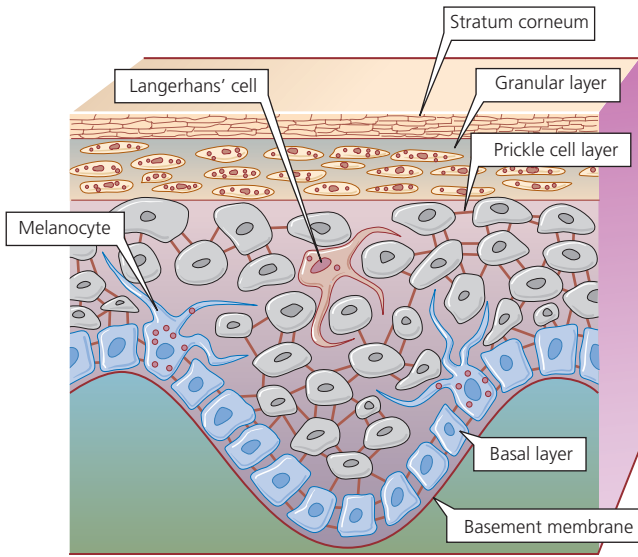
In the final stages of terminal differentiation, the plasma membrane is replaced by the *cornified cell envelope*, composed of several proteins the production of which is also under genetic control. Cells that have developed this envelope and have lost their nucleus and organelles constitute the *corneocytes* of the stratum corneum.

## Basal layer

Now let us look at the layers more closely (Figure 1.2). The *basal layer*, which is one to three cells thick, is anchored to a *basement membrane* that lies between the epidermis and dermis.

## Melanocytes

Interspersed among the basal cells are *melanocytes* - large dendritic cells derived from the neural crest - which are responsible for melanin pigment production. Melanocytes contain cytoplasmic organelles called *melanosomes*, in which melanin is synthesized from tyrosine. The melanosomes migrate along the dendrites of the melanocytes and are transferred to the keratinocytes in the prickle cell layer. In white people, the melanosomes are grouped together in membrane-bound *melanosome complexes*, and they gradually degenerate as the keratinocytes move towards the surface of the skin. The skin of black people contains the same number of melanocytes as



**Figure 1.2** The epidermis. Contrary to expectation, keratinocytes are highly active cells. Note how their appearance changes (along with their function) as they transit the epidermal layer.

that of white people, but the melanosomes are larger, remain separate and persist through the full thickness of the epidermis.

The main stimulus to melanin production is ultraviolet (UV) radiation. Melanin protects the cell nuclei in the epidermis from the harmful effects of UV radiation. A suntan is a natural protective mechanism, not some God-given cosmetic boon created so that you can impress the neighbours on your return from an exotic foreign trip! Unfortunately, this does not appear to be appreciated by the pale, pimply, lager-swilling advert for British manhood who dashes on to the beach in Ibiza and flash fries himself to lobster thermidor on day one of his annual holiday.

Skin cancers are extremely uncommon in people of dark-skinned races because their skin is protected from UV damage by the large amounts of melanin that it contains. However, albinism in people of colour greatly predisposes them to skin cancer because their production of melanin is impaired and they are therefore without its protective influence.

### Prickle cell layer

Above the basal layer is the *prickle cell/spinous layer*. This acquires its name from the spiky appearance produced by the intercellular bridges (desmosomes) that connect adjacent cells. Important in cell-cell adhesion are several protein components of desmosomes (including cadherins (desmogleins and desmocollins) and plakins). Production of these is

genetically controlled, and abnormalities have been detected in some human diseases.

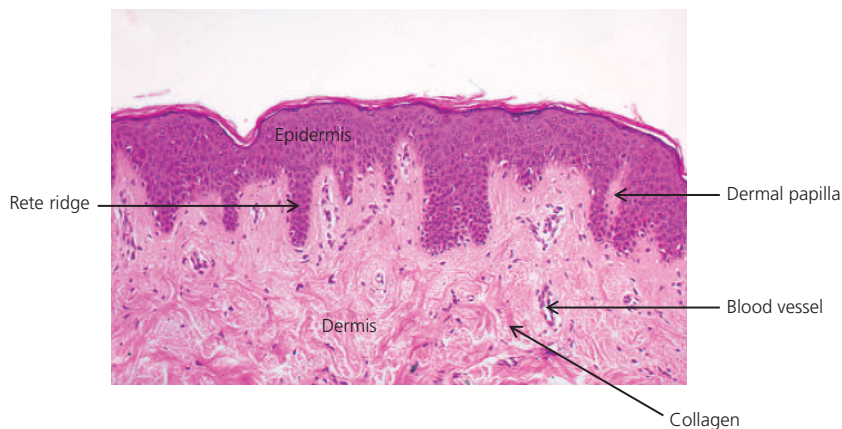
Scattered throughout the prickle cell layer are *Langerhans' cells*. These dendritic cells contain characteristic racquet-shaped 'Birbeck' granules. Langerhans' cells are probably modified macrophages that originate in the bone marrow and migrate to the epidermis. They are the first line of immunological defence against environmental antigens (see the section on 'Functions of the Skin').

### Granular cell layer

Above the prickle cell layer is the *granular layer*, which is composed of flattened cells containing the darkly staining keratohyalin granules (which contain filaggrin). Also present in the cytoplasm of cells in the granular layer are organelles known as lamellar granules (Odland bodies). These contain lipids and enzymes, and they discharge their contents into the intercellular spaces between the cells of the granular layer and stratum corneum – providing the equivalent of 'mortar' between the cellular 'bricks', and contributing to NMF and the barrier function of the epidermis.

### Stratum corneum

The cells of the *stratum corneum* are flattened, keratinized cells that are devoid of nuclei and cytoplasmic organelles. Adjacent cells overlap at their margins, and this locking together, in combination with intercellular



**Figure 1.3** Section of skin stained with haematoxylin and eosin, showing the appearance of a normal epidermis. ‘Rete ridges’ (downward projections of the pinker epidermis) interdigitate with ‘dermal papillae’ (upward projections of the dermis). Note the dark pink flattened cells of the *stratum corneum* at the surface.

lipid, forms a very effective barrier. The stratum corneum varies in thickness according to the region of the body. It is thickest on the palms of the hands and soles of the feet. The stratum corneum cells are gradually abraded by daily wear and tear. If you bathe after a period of several days’ avoidance of water (a house without central heating, in mid-winter, somewhere in the Northern Hemisphere, is ideal for this experiment), you will note that as you towel yourself you are rubbing off small balls of keratin – which has built up because of your unsanitary habits. When a plaster cast is removed from a fractured limb after several weeks *in situ*, there is usually a thick layer of surface keratin, the removal of which provides hours of absorbing occupational therapy.

Figure 1.3 shows the histological appearance of normal epidermis.

## Basement membrane zone

The basement membrane is composed of three layers: lamina lucida (uppermost), lamina densa and lamina fibroreticularis. It is important to have some knowledge of these layers because certain diseases are related to abnormalities in them. The basic structure is shown in Figure 1.4. Basal keratinocytes are attached by *hemidesmosomes* to the epidermal side of the membrane; these have an important role in maintaining adhesion between the epidermis and dermis. A system of *anchoring filaments* connects hemidesmosomes to the lamina densa, and *anchoring fibrils*, which are closely associated with collagen in the upper dermis, connect the lamina densa to the dermis beneath.

The hemidesmosome/anchoring filament region contains autoantigens targeted by autoantibodies in immunobullous disorders (including bullous pemphigoid, pemphigoid gestationis, cicatricial pemphigoid and linear IgA bullous dermatosis – see Chapter 15), hence the subepidermal location of blistering in these disorders.

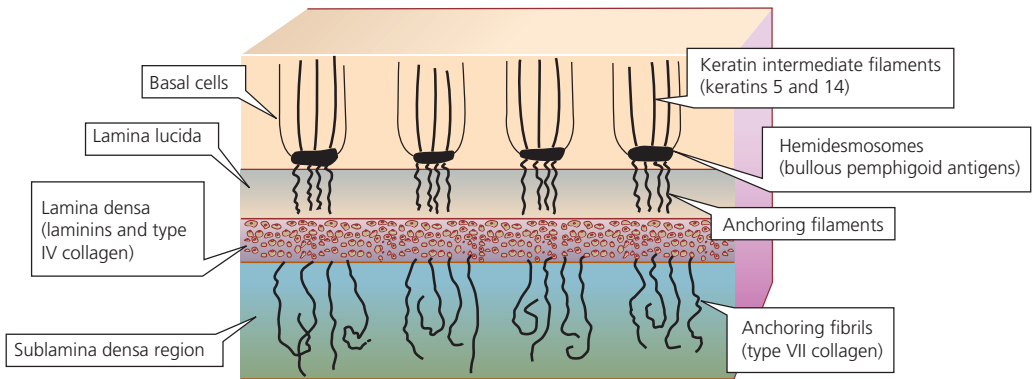
The inherited blistering diseases (see Chapter 15) occur as a consequence of mutations in genes responsible for components of the basement membrane zone; for example, epidermolysis bullosa simplex, in which splits occur in the basal keratinocytes, is related to mutations in genes coding for keratins 5 and 14, and dystrophic epidermolysis bullosa, in which blistering occurs immediately below the lamina densa, is related to mutations in a gene coding for type VII collagen, the major component of anchoring fibrils.

## Epidermal appendages

The epidermal appendages are the eccrine and apocrine sweat glands, the hair and sebaceous glands and the nails.

### Eccrine sweat glands

Eccrine sweat glands are important in body temperature regulation. A human has between 2 and 3 million eccrine sweat glands, covering almost all the body surface. They are particularly numerous on the palms of the hands and soles of the feet. Each consists of a secretory coil deep in the dermis and a duct that conveys the sweat to the surface. Eccrine glands secrete



**Figure 1.4** Schematic representation of the structure of the basement membrane zone.

water, electrolytes, lactate, urea and ammonia. The secretory coil produces isotonic sweat, but sodium chloride is reabsorbed in the duct so that sweat reaching the surface is hypotonic. Patients with cystic fibrosis have defective reabsorption of sodium chloride, and rapidly become salt-depleted in a hot environment. Even more dramatic is the effect of anhydrotic ectodermal dysplasia, in which individuals are completely unable to sweat and may die of hyperthermia. Eccrine sweat glands are innervated by the sympathetic nervous system, but the neurotransmitter is acetylcholine.

### Apocrine sweat glands

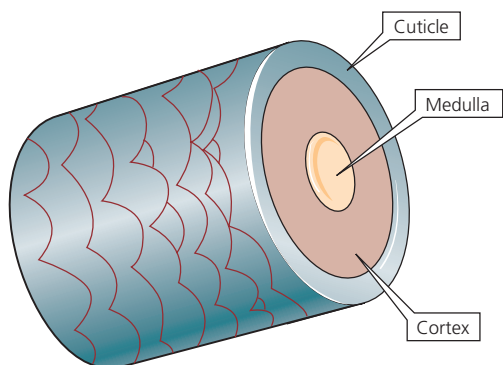
Apocrine sweat glands are found principally in the axillae and anogenital region. Specialized apocrine glands include the wax glands of the ear and the milk glands of the breast. Apocrine glands are also composed of a secretory coil and a duct, but the duct opens into a hair follicle, not directly on to the surface of the skin. Apocrine glands produce an oily secretion containing protein, carbohydrate, ammonia and lipid. These glands become active at puberty, and secretion is controlled by adrenergic nerve fibres. Pungent axillary body odour (axillary bromhidrosis) is the result of the action of bacteria on apocrine secretions. In some animals, apocrine secretions are important sexual attractants, but the average human armpit provides a different type of overwhelming olfactory experience.

### Hair

Hairs grow out of tubular invaginations of the epidermis known as follicles, and a hair follicle and its associated sebaceous glands are referred to as a *pilosebaceous*

*unit*. There are three types of hair: fine, soft *lanugo* hair is present *in utero* and is shed by the eighth month of fetal life; *vellus* hair is the fine downy hair that covers most of the body, except those areas occupied by terminal hair; and thick and pigmented *terminal* hair occurs on the scalp, eyebrows and eyelashes before puberty – after puberty, under the influence of androgens, secondary sexual terminal hair develops from vellus hair in the axillae and pubic region, and on the trunk and limbs. On the scalp, the reverse occurs in male-pattern balding: terminal hair becomes vellus hair under the influence of androgens. In men, terminal hair on the body usually increases in amount as middle age arrives, and hairy ears and nostrils and bushy eyebrows are puzzling accompaniments of advancing years. One struggles to think of any biological advantage conferred by exuberant growth of hair in these sites.

Hair follicles extend into the dermis at an angle (see Figure 1.1). A small bundle of smooth muscle fibres, the arrector pili muscle, is attached to the side of the follicle. Arrector pili muscles are supplied by adrenergic nerves and are responsible for the erection of hairs in the cold or during emotional stress ('goose flesh', 'goose pimples', horripilation). The duct of the sebaceous gland enters the follicle just above the point of attachment of the arrector pili muscle. At the lower end of the follicle is the hair bulb, part of which, the hair matrix, is a zone of rapidly dividing cells that is responsible for the formation of the hair shaft. Hair pigment is produced by melanocytes in the hair bulb. Cells produced in the hair bulb become densely packed, elongated and arranged parallel to the long axis of the hair shaft. They gradually become keratinized as they ascend in the hair follicle.



**Figure 1.5** Schematic representation of the structure of terminal hair.

The main part of each hair fibre is the cortex, which is composed of keratinized spindle-shaped cells (Figure 1.5). Terminal hairs have a central core known as the medulla, consisting of specialized cells that contain air spaces. Covering the cortex is the cuticle, a thin layer of cells that overlap like the tiles on a roof, with the free margins of the cells pointing towards the tip of the hair. The cross-sectional shape of hair varies with body site and race. Negroid hair is distinctly oval in cross-section, and pubic, beard and eyelash hairs have an oval cross-section in all racial types. Caucasoid hair is moderately elliptical in cross-section and mongoloid hair is circular.

The growth of each hair is cyclical – periods of active growth alternate with resting phases. After each period of active growth (anagen) there is a short transitional phase (catagen), followed by a resting phase (telogen), after which the follicle reactivates, a new hair is produced and the old hair is shed. The duration of these cyclical phases depends on the age of the individual and the location of the follicle on the body. The duration of anagen in a scalp follicle is genetically determined, and ranges from 2 to more than 5 years. This is why some women can grow hair down to their ankles, whereas most have a much shorter maximum length. Scalp-hair catagen lasts about 2 weeks and telogen from 3 months to 4 months. The daily growth rate of scalp hair is approximately 0.45 mm. The activity of each follicle is independent of that of its neighbours, which is fortunate because if follicular activity were synchronized, as it is in some animals, we would be subject to periodic moults, adding another dimension to life's rich tapestry. At any one time, approximately 85% of scalp hairs are in anagen, 1% in catagen and 14% in telogen. The average number of hairs shed daily is 100. In areas other than the scalp, anagen is relatively short – this is

also fortunate, as if it were not so, we would all be kept busy clipping eyebrows, eyelashes and nether regions.

It is a myth that shaving increases the rate of growth of hair and that it encourages the development of 'thicker' hair; nor does hair continue growing after death – shrinkage of soft tissues around the hair produces this illusion.

Human hair colour is principally dependent on two types of melanin: eumelanins in black and brown hair and phaeomelanins in red, auburn and blond hair.

Greying of hair (canities) is the result of a decrease in tyrosinase activity in the melanocytes of the hair bulb. The age of onset of greying is genetically determined, but other factors may be involved, such as autoimmunity – premature greying of the hair is a recognized association of pernicious anaemia. The phenomenon of 'going white overnight' has been attributed to severe psychological stress – it is said that the hair of (Sir) Thomas More and Marie Antoinette turned white on the night before their executions. However, this is physically impossible unless related to the washing out of temporary hair dye, but it might occur over a period of a few days or weeks as a result of alopecia areata occurring in an individual with a mixture of white and pigmented hair in whom there is selective loss of pigmented hair.

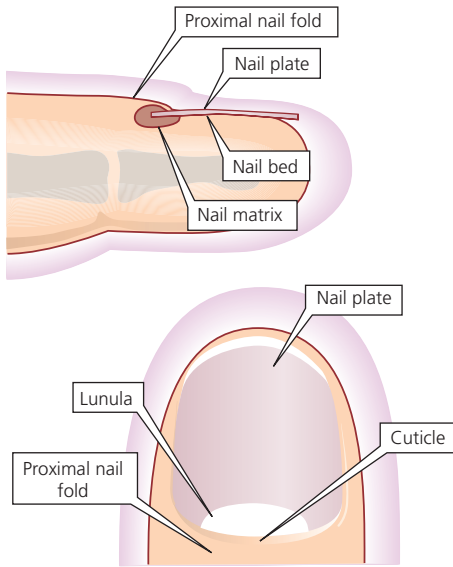
### Sebaceous glands

Sebaceous glands are found everywhere on the skin apart from the hands and feet. They are particularly numerous and prominent on the head and neck, the chest and the back. Sebaceous glands are part of the pilosebaceous unit, and their lipid-rich product (sebum) flows through a duct into the hair follicle. They are holocrine glands – sebum is produced by disintegration of glandular cells rather than an active secretory process. Modified sebaceous glands that open directly on the surface are found on the eyelids, lips, nipples, glans penis and prepuce, the vulva and the buccal mucosa (Fordyce spots).

Sebaceous glands are prominent at birth, under the influence of maternal hormones, but atrophy soon after, and do not enlarge again until puberty. Enlargement of the glands and sebum production at puberty are stimulated by androgens. Growth hormone and thyroid hormones also stimulate sebum production.

### Nails

A nail is a transparent plate of keratin derived from an invagination of epidermis on the dorsum of the terminal phalanx of a digit (Figure 1.6). The nail plate



**Figure 1.6** Schematic representation of the structure of human finger and toe nail.

is the product of cell division in the nail matrix, which lies deep to the proximal nail fold, but is partly visible as the pale 'half-moon' (lunula) at the base of the nail. The nail plate adheres firmly to the underlying nail bed. The cuticle is an extension of the stratum corneum of the proximal nail fold on to the nail plate. It forms a seal between the nail plate and proximal nail fold, preventing penetration of extraneous material.

Nail growth is continuous throughout life, but is more rapid in youth than in old age. The average rate of growth of fingernails is approximately 1 mm/week, and the time taken for a fingernail to grow from matrix to free edge is about 6 months. Nails on the dominant hand grow slightly more rapidly than those on the non-dominant hand. Toenails grow at one-third the rate of fingernails, and take about 18 months to grow from matrix to free edge.

Many factors affect nail growth rate. It is increased in psoriasis, and may be speeded up in the presence of inflammatory change around the nail. A severe systemic upset can produce a sudden slowing of nail growth, causing a transverse groove in each nail plate. These grooves, known as Beau's lines, subsequently become visible as the nails grow out. Nail growth may also be considerably slowed in the digits of a limb immobilized in plaster.

## The dermis

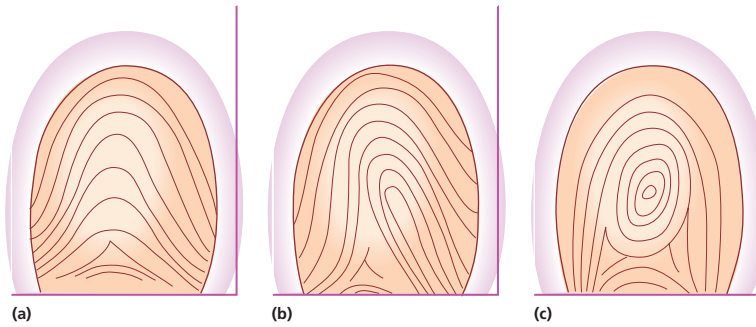
The dermis is a layer of connective tissue lying beneath the epidermis, and forms the bulk of the skin. The dermis and epidermis interdigitate via downward epidermal projections (rete ridges) and upward dermal projections (dermal papillae) (see Figures 1.1 and 1.3). The main feature of the dermis is a network of interlacing fibres, mostly collagen, but with some elastin. These fibres give the dermis great strength and elasticity. The collagen and elastin fibres, which are protein, are embedded in a ground substance of mucopolysaccharides (glycosaminoglycans).

The main cellular elements of the dermis are fibroblasts, mast cells and macrophages. Fibroblasts synthesize the connective tissue matrix of the dermis and are usually found in close proximity to collagen and elastin fibres. Mast cells are specialized secretory cells present throughout the dermis, but they are more numerous around blood vessels and appendages. They contain granules, the contents of which include mediators such as histamine, prostaglandins, leukotrienes and eosinophil and neutrophil chemotactic factors. Macrophages are phagocytic cells that originate in the bone marrow, and they act as scavengers of cell debris and extracellular material. The dermis is also richly supplied with blood vessels, lymphatics, nerves and sensory receptors. Beneath the dermis, a layer of subcutaneous fat separates the skin from underlying fascia and muscle.

## Dermatoglyphics

Fingerprints, the characteristic elevated ridge patterns on the fingertips of humans, are unique to each individual. The fingers and toes and the palms and soles are covered with a system of ridges that form patterns. The term *dermatoglyphics* is applied to the configuration of the ridges. If you look closely at your hands, you will see these tiny ridges, which are separate from the skin creases. On the tips of the fingers, there are three basic patterns: arches, loops and whorls (Figure 1.7). The loops are subdivided into ulnar and radial, depending on whether the loop is open to the ulnar or radial side of the hand. A triangular intersection of these ridges is known as a triradius, and these triradii are present not only on fingertips, but also at the base of each finger, and usually on the proximal part of the palm.

Not only are the ridge patterns of fingerprints useful for the identification and conviction of those who covet their neighbours' goods, but characteristic dermatoglyphic abnormalities frequently accompany many chromosomal aberrations.



**Figure 1.7** Dermatoglyphics: (a) arch; (b) loop; (c) whorl.

## Functions of the skin

*Skin is like wax paper that holds everything in without dripping.*

*Art Linkletter, A Child's Garden of Misinformation*

It is obvious from the complex structure of the skin that it is not there simply to hold all the other bits of the body together. Some of its functions are as shown in the box.

### Skin Functions

- Prevents loss of essential body fluids.
- Protects against entry of toxic and allergenic environmental chemicals and microorganisms.
- Provides immunological functions.
- Protects against damage from UV radiation.
- Regulates body temperature.
- Provides cutaneous sensation.
- Carries out synthesis of vitamin D.
- Is important in sexual attraction and social interaction.

In the absence of a stratum corneum, we would lose significant amounts of water to the environment and rapidly become dehydrated. The stratum corneum, with its overlapping cells and intercellular lipid, blocks diffusion of water into the environment. If it is removed experimentally, by stripping with tape, water loss to the environment increases 10-fold or more.

It is also quite an effective barrier to the penetration of external agents. However, this barrier capacity is considerably reduced if the stratum corneum is hydrated or its lipid content is reduced by the use of lipid solvents. The structural integrity of the stratum corneum also protects against invasion by microorganisms, and when there is skin loss (e.g. in burns or toxic epidermal necrolysis (see Chapter 14)), infection is a major problem. Other factors, such as the acid pH of sweat and sebaceous secretions, antimicrobial peptides (AMPs) known as *defensins* and *cathelicidins* (which kill a variety of microbes) and complement components all contribute to antibacterial activity. The rarity of fungal infection of the scalp in adults is thought to be related to changes at puberty in the fatty acid composition of sebum, its constituents after puberty having fungistatic activity.

The skin is an immunologically competent organ and plays an important part in host defence against 'foreign' material. The dendritic Langerhans' cells are antigen-presenting cells that take up antigens, process them and migrate to regional lymph nodes, where the antigens, in association with major histocompatibility (MHC) class II, are presented to receptors on T cells. A naïve T cell that interacts with an antigen proliferates to form a clone that will recognize the antigen if re-exposed to it. Such primed (memory) T cells circulate around the body. If the antigen is encountered again, the primed T cells are activated, and secrete cytokines that cause lymphocytes, polymorphonuclear leucocytes and monocytes to move into the area, thereby causing inflammation. This mechanism also forms the basis of the inflammatory reaction in allergic contact dermatitis.

Cytokines are polypeptides and glycoproteins that are secreted by cells (e.g. lymphocytes, macrophages and



keratinocytes). They include interleukins, interferons (IFNs), tumour necrosis factor (TNF), colony-stimulating factors and growth factors. Their main role is to regulate inflammatory and immune responses.

Although detailed discussion of immunology and inflammation is beyond the scope of this book, it is important for you to understand some of the basic mechanisms involved, for a variety of reasons – not least because such knowledge is necessary in order to comprehend the modes of action of the increasingly sophisticated treatments being developed today (e.g. biological therapies, which are being used to treat psoriasis (see Chapter 9) by targeting components of its pathomechanism (see Chapter 23)).

The protective effect of melanin against UV damage has already been mentioned, but in addition to this there is an important system of enzymes responsible for repair of UV-damaged DNA. Such damage occurs continuously, and the consequences of a non-functioning repair system can be seen in the recessively inherited disorder xeroderma pigmentosum (XP). In XP, cumulative UV damage leads to the premature development of skin neoplasia.

The skin is a vital part of the body's temperature regulation system. The body core temperature is regulated by a temperature-sensitive area in the hypothalamus, and this is influenced by the temperature of the blood that perfuses it. The response of the skin to cold is vasoconstriction and a marked reduction in blood flow, decreasing transfer of heat to the body surface. The response to heat is vasodilatation, an increase in skin blood flow and loss of heat to the environment. Perspiration helps to cool the body by evaporation of sweat. These thermoregulatory functions are impaired in certain skin diseases – patients

with exfoliative dermatitis (erythroderma), for example, radiate heat to their environment because their skin blood flow is considerably increased and they are unable to control this by vasoconstriction. In a cold environment, their central core temperature drops, despite the production of metabolic heat by shivering, and they may die of hypothermia. As already noted, the absence of sweat glands in anhydrotic ectodermal dysplasia markedly impairs heat loss from the skin surface.

Vitamin D (cholecalciferol) is produced in the skin by the action of UV light on dehydrocholesterol. In those whose diets are deficient in vitamin D, this extra source of the vitamin can be important. Excessive avoidance of UV exposure has been blamed, in part, for a recent rise in vitamin D deficiency.

The skin is also a huge sensory receptor, perceiving heat, cold, pain, light touch and pressure, and even tickle. As you are probably still grappling with the conundrum of the biological significance of hairy ears in elderly men, try switching your thoughts to the benefits of tickly armpits!

In addition to all these mechanistic functions, the skin plays an essential aesthetic role in social interaction and sexual attraction.

Hence, you can see that your skin is doing a good job. Apart from looking pleasant, it is saving you from becoming a cold, UV-damaged, brittle-boned, desiccated 'prune'.



Now visit [www.lecturenoteseries.com/dermatology](http://www.lecturenoteseries.com/dermatology) to test yourself on this chapter.